COUNTWAY LIBRARY
HC 4NGP B

DR. A. HAGGART,
COMPA[illegible] URGEON
OTTAW[illegible] CAR WORKS.

N. F. Mills

A Haggart.
Ottawa Ks

BOSTON
MEDICAL LIBRARY
8 THE FENWAY

TREATISE

ON

DISEASES OF THE SKIN

FOR THE USE OF

Advanced Students and Practitioners

BY

HENRY W. STELWAGON, M.D., PH.D.

Professor of Dermatology in the Jefferson Medical College, Philadelphia; Dermatologist to the Howard and Philadelphia Hospitals; Consulting Dermatologist to the Pennsylvania Institution for the Deaf and Dumb, to the Pennsylvania Institution for Feeble-Minded Children, and to the Widener Memorial Training School for Crippled Children; Member of the American Dermatological Association; Associate Member of the Society of Dermatology and Syphilography of France, and of the Society of Dermatology and Syphilography of Italy

Fifth Edition, Thoroughly Revised

With 267 Illustrations in the Text, and 34 Full-page Colored and Half-tone Plates

PHILADELPHIA AND LONDON

W. B. SAUNDERS COMPANY

1907

BOSTON MEDICAL
JUN 13 1929
LIBRARY

27.A.282.

Set up, electrotyped, printed, and copyrighted June, 1902. Reprinted and recopyrighted February, 1903. Revised, reprinted, and recopyrighted January, 1904. Reprinted November, 1904. Revised, reprinted, and recopyrighted October, 1905. Reprinted August, 1906. Revised, reprinted, and recopyrighted, August, 1907.

Copyright, 1907, by W. B. Saunders Company.

ELECTROTYPED BY
WESTCOTT & THOMSON, PHILADA.

PRESS OF
W. B. SAUNDERS COMPANY

TO

LOUIS A. DUHRING, M.D.,

PROFESSOR OF DISEASES OF THE SKIN IN THE UNIVERSITY OF PENNSYLVANIA,

THE DISTINGUISHED AMERICAN DERMATOLOGIST WHOSE WORK, PUBLICATIONS, AND OTHER WRITINGS HAVE DONE SO MUCH FOR THE ADVANCEMENT OF THIS BRANCH OF MEDICINE,

THIS TREATISE,

BY HIS FORMER ASSISTANT, IS WITH HIS PERMISSION

DEDICATED

WITH SENTIMENTS OF HIGH REGARD AND ESTEEM

Digitized by the Internet Archive
in 2025

https://archive.org/details/treatiseondiseas0000henr_o4w3

PREFACE TO FIFTH EDITION.

THE present—fifth—edition represents a revision from the standpoints of both elision of unnecessary or obsolete material and addition of new matter reflected in investigations and literature since the appearance of the last edition. The elision has given sufficient space for the added matter, as well as for additional illustrations, without perceptibly increasing the size of the volume—in all, an increase of only fifteen pages. While most of the subject matter has been gone over, the main additions and changes will be found in those diseases rendered more important by our closer touch with tropical countries. The articles on "frambesia" and "oriental sore" have been rewritten, and those on "verruga peruana" and "tinea imbricata" changed or added to; and among the new tropical subjects introduced are to be especially mentioned "dhobie itch" and "uncinarial dermatitis." The eruptions of the leukemias receive some attention for the first time in this edition; and that rare condition "meralgia paresthetica" is also briefly presented. The new illustrations number fifteen: thirteen in the text and two plates; and while it is hoped that all are of interest and of clinical and diagnostic value, the most important are those of the tropical diseases, frambesia, verruga peruana, and tinea imbricata.

H. W. S.

1634 SPRUCE STREET,
PHILADELPHIA, *August*, 1907.

PREFACE.

In the preparation of this book I have endeavored to keep one aim predominantly in view—to present the practical part of the subject in a sufficiently complete manner as to make the work one that will give those engaged in general practice a full comprehension of the symptomatology, diagnosis, and treatment of the various affections with which they are most likely to come in contact. The symptoms are, therefore, detailed at some length, and often in the plain, elementary way that I have found in college and postgraduate teaching most successful in giving a clear grasp of the essential characters. As a preliminary to this the primary and consecutive lesions which are essentially the groundwork of dermatology are allotted more than the usual space. Diagnosis, apparently the most difficult and confusing part of cutaneous medicine, has been given considerable attention. The elaborated remarks under General Diagnosis may, it is hoped, be of substantial aid in surmounting some of the difficulties. With the purpose of emphasizing the clinical and diagnostic aspects I have made use of a large number of illustrations from my own collection of original photographs, supplemented by those generously placed at my disposal by my dermatologic colleagues, to whom I wish to express my sincere thanks, and who will be found specifically mentioned and credited in connection with the individual cuts. To strengthen this feature also the publishers have kindly permitted the insertion of a number of selected colored plates from their well-known Mracek *Hand-Atlases of Diseases of the Skin and Syphilis.*

The other practical part of dermatology—treatment—has in the most important diseases been described more or less in detail, in some places, to those who are experienced, possibly to the point of tedious simplicity, but observation has taught me that student and practitioner should have pointed out not only what in a general way is to be prescribed, but, when possible, some definite directions as to selection and method. In addition to the remedies and methods used in my own practice, I have referred largely also to those employed and advised by others, the various standard treatises and contributions by other writers being frequently cited, not only, in fact, in this, but likewise in other divisions of this work.

Although the practical parts, including etiology, have been allotted the greater space, it has not been my intention to neglect pathology and pathologic histology, but to give these in a sufficiently ample manner as to be a complete, but relatively brief, reflex of our present knowledge. In the presentation of the pathologic histology, the studies and observations of those who are especially

skilled and known in this department are largely drawn upon and the sources acknowledged; illustrations have, when space permitted, been inserted to aid in an understanding of the text. But while the writing of this work was approached from the standpoint of its practical use, it is hoped that the somewhat exacting labor of gathering together and sifting the writings, investigations, and opinions of others will be of value not only to the practitioner who may desire to follow up the study of a particular disease, but also prove of time-saving help to my dermatologic colleagues. Most references are to literature published within the past twenty-five years, but many of those given, as mentioned therewith, cover by review and references contributions which had preceded.

I am indebted to several gentlemen for aid in the preparation of this book: To Dr. William M. Welch, of the Municipal Hospital (for exanthemata), for the papers on small-pox, scarlet fever, and measles; to Dr. Emanuel J. Stout, Instructor in Dermatology in the Jefferson Medical College, for the framework of some articles; to Dr. Samuel H. Brown, Assistant in the Skin Dispensary of the Howard Hospital, for preparing some schedules of important literature; to Dr. Franklin Machette, Assistant in the Skin Dispensary of the Jefferson Medical College Hospital, for the well-prepared index; and to Mr. Charles P. Fisher, Librarian of the College of Physicians of Philadelphia, for materially facilitating the consultation and verification of literature. I also desire to acknowledge the courtesy of D. Appleton and Company and William Wood and Company, of New York, and J. B. Lippincott Company and F. A. Davis Company, of Philadelphia, for their permission to use matter previously contributed to their publications; and although this privilege has been but scantily drawn upon, the cordial consent given to do so is not the less appreciated.

The formulæ and other medicinal measures are expressed both according to the usual apothecaries' scale and the metric system, the quantities in the latter always being given in grams. The spelling and the fusing of compound words in the text are in accord with the desire of the publishers that their books be uniform in this respect.

H. W. S.

PHILADELPHIA, *1634 Spruce Street.*

CONTENTS.

PAGE

Anatomy and Physiology of the Skin . . . 17
General Symptomatology . . . 53
Subjective Symptoms . . . 53
Objective Symptoms . . . 54
Elementary or Primary Lesions . . . 55
Consecutive or Secondary Lesions . . . 64
Lesional Configuration, Distribution, and Other Features . . . 71
General Etiology . . . 73
General Pathology . . . 82
General Diagnosis . . . 84
General Remarks on Treatment . . . 101
Constitutional Treatment . . . 102
Local Treatment . . . 110
Classification . . . 129

CLASS I.—HYPEREMIAS.

Erythema . . . 136
Erythema Hyperæmicum . . . 136
Erythema Intertrigo . . . 140
Erythema Scarlatinoides . . . 142

CLASS II.—INFLAMMATIONS.

Erythema Multiforme . . . 146
Erythema Nodosum . . . 152
Erythema Induratum . . . 156
Erythema Elevatum Diutinum . . . 159
Pellagra . . . 161
Urticaria . . . 164
Urticaria Pigmentosa . . . 173
Œdema Angioneuroticum . . . 176
Pityriasis Rosea . . . 179
Dermatitis Exfoliativa . . . 183
Dermatitis Exfoliativa Epidemica . . . 188
Dermatitis Exfoliativa Neonatorum . . . 189
Prurigo . . . 191
Lichen Planus . . . 194
Lichen Scrofulosus . . . 205
Pityriasis Rubra Pilaris . . . 208
Psoriasis . . . 214
Eczema . . . 240
Regional and Infantile Eczema . . . 292
Eczema Seborrhoicum . . . 308
Herpes Simplex . . . 320

PAGE

Herpes Zoster 324
Hydroa Vacciniforme 334
Pompholyx 336
Dermatitis Herpetiformis 340
Pemphigus 346
Epidermolysis Bullosa 360
Dermatitis Repens 363
The Impetigos 365
Impetigo Contagiosa 367
Ecthyma 373
Impetigo Herpetiformis 375
Furunculus 377
Carbunculus 381
Phlegmona Diffusa 383
Dissection Wounds 384
Postmortem Pustule 384
Equinia 385
Pustula Maligna 386
Erysipelas 389
Erysipeloid 394
Sphaceloderma 396
Dermatitis Gangrænosa Infantum 396
Multiple Gangrene of the Skin in Adults 398
Diabetic Gangrene 399
Symmetric Gangrene 400
Dermatitis Calorica 402
Dermatitis Ambustionis 402
Dermatitis Congelationis 404
Dermatitis Traumatica 405
Dermatitis Venenata 405
X-Ray Dermatitis 411
Dermatitis Factitia 416
Dermatitis Medicamentosa 417
The Exanthemata 430
Scarlatina 431
Rubeola—Measles 440
Rötheln 445
Varicella 447
Variola 451
Vaccinal Eruptions 460

CLASS III.—HEMORRHAGES.

Purpura 466

CLASS IV.—HYPERTROPHIES.

Lentigo 476
Chloasma 478
Nævus Pigmentosus 489
Acanthosis Nigricans 495
Clavus 497
Callositas 500
Keratosis Palmaris et Plantaris 501

PAGE
Keratosis Senilis 505
Keratosis Pilaris 508
Keratosis Follicularis 512
Verruca 517
Cornu Cutaneum 528
Ichthyosis 531
Porokeratosis 541
Angiokeratoma 544
Scleroderma 547
Sclerema Neonatorum 558
Œdema Neonatorum 560
Elephantiasis 561
Myxedema 569
Dermatolysis 572

CLASS V.—ATROPHIES.

Albinismus 576
Vitiligo 578
Glossy Skin 583
Atrophia Senilis 584
Striæ et Maculæ Atrophicæ 586
Diffuse Idiopathic Atrophy of the Skin 589
Kraurosis Vulvæ 592
Ainhum 593
Perforating Ulcer of the Foot 596
Morvan's Disease 598

CLASS VI.—NEW GROWTHS.

Cicatrix 601
Keloid 603
Dermatitis Papillaris Capillitii 610
Molluscum Contagiosum 612
Multiple Benign Cystic Epithelioma 618
Adenoma Sebaceum 622
Adenoma of the Sweat-Gland 625
Lymphangioma 626
Lymphangioma Circumscriptum 630
Multiple Benign Tumor-Like New Growths 633
Xanthoma 634
Xanthoma Diabeticorum 641
Colloid Degeneration of the Skin 644
Nævus Vasculosus 646
Telangiectasis 654
Angioma Serpiginosum 657
Fibroma 658
Lipoma 664
Myoma 666
Neuroma 668
Rhinoscleroma 669
Tuberculosis Cutis 671
    Tuberculosis Ulcerosa 672
    Tuberculosis Disseminata 673

PAGE

Tuberculosis Verrucosa 675
Scrofuloderma 678
Lupus Vulgaris 682
Lupus Erythematosus 714
Syphilis 728
Cutaneous Manifestations of Acquired Syphilis 729
Macular Syphiloderm 735
Pigmentary Syphiloderm 737
Papular Syphiloderm 739
Palmar and Plantar Syphiloderm 744
Moist Papule 750
Vesicular Syphiloderm 753
Pustular Syphiloderm 753
Bullous Syphiloderm 761
Tubercular Syphiloderm 761
Gummatous Syphiloderm 768
Cutaneous Manifestations of Hereditary Syphilis 771
Oriental Sore 799
Frambesia 802
Verruga Peruana 809
Carcinoma Cutis 812
Paget's Disease 813
Epithelioma 817
Xeroderma Pigmentosum 835
Sarcoma Cutis 839
Granuloma Fungoides 847
Leukemia Cutis; Pseudoleukemia Cutis 853
Lepra 855

CLASS VII.—NEUROSES.

Hyperesthesia 876
Dermatalgia 877
Erythromelalgia 878
Pruritus 879
Anesthesia 888

CLASS VIII.—DISEASES OF THE APPENDAGES.

1. Diseases of the Nails.

Onychauxis 889
Atrophia Unguium 894
Onychomycosis 898

2. Diseases of the Hair and the Hair-Follicles.

Hypertrichosis 901
Atrophia Pilorum Propria 909
Fragilitas Crinium 910
Trichorrhexis Nodosa 911
Monilethrix 914
Piedra 916
Tinea Nodosa 917
Lepothrix 918
Canities 918
Alopecia 923

PAGE
Alopecia Areata 930
Folliculitis Decalvans 945
Sycosis Vulgaris 948

3. Diseases of the Sebaceous Glands.

Seborrhea 956
Asteatosis 962
Milium 963
Steatoma 965
Comedo 967
Acne 971
Acne Varioliformis 988
Acne Rosacea 992

4. Diseases of the Sweat-Glands.

Hyperidrosis 1000
Anidrosis 1006
Bromidrosis 1007
Chromidrosis 1009
Hematidrosis 1012
Uridrosis 1013
Sudamen 1014
Hydrocystoma 1015
Granulosis Rubra Nasi 1018
Miliaria 1019

CLASS IX.—PARASITIC AFFECTIONS.

A. Diseases Due to Vegetable Parasites.

Favus 1024
Ringworm 1035
Ringworm of the General Surface 1037
Ringworm of the Scalp 1042
Ringworm of the Bearded Region 1045
Tinea Imbricata 1065
Tinea Versicolor 1067
Erythrasma 1071
Dhobie Itch 1073
Pinta Disease 1074
Myringomycosis 1075
Actinomycosis 1076
Mycetoma 1081
Blastomycetic Dermatitis 1083

B. Diseases Due to Animal Parasites.

Pediculosis 1088
Pediculosis Capitis 1090
Pediculosis Corporis 1092
Pediculosis Pubis 1094
Other Animal Parasites, of Minor Importance, Attacking the Skin 1096
Scabies 1098
Other Animal Parasites, of Minor Importance, Penetrating the Skin 1104

SUPPLEMENTARY SECTION.

PAGE
Leukoplakia 1111
Furrowed Tongue 1116
Transitory Benign Plaques of the Tongue 1117
Black Tongue 1119
Cheilitis Glandularis 1121
Fordyce's Disease 1122
La Perlèche 1124

INDEX 1125

EXPLANATION OF ABBREVIATIONS.

Jour. Cutan. Dis. = *Journal of Cutaneous and Venereal Diseases*, 1883–87, *Journal of Cutaneous and Genito-Urinary Diseases*, 1888–1902, and *Journal of Cutaneous Diseases*, since 1903, New York.

Arch. Derm. = *Archives of Dermatology*, 1875–82, New York.

Brit. Jour. Derm. = *British Journal of Dermatology*, London.

Annales = *Annales de dermatologie et de syphiligraphie*, Paris.

Jour. mal. cutan. = *Journal des maladies cutanées et syphilitiques*, Paris.

Revue pratique = *Revue pratique des maladies cutanées, syphilitiques et vénériennes*, Paris.

Annales mal. vén. = *Annales des maladies vénériennes*, Paris.

Monatshefte = *Monatshefte für praktische Dermatologie*, Hamburg.

Archiv = *Archiv für Dermatologie und Syphilis*, 1869–73; *Vierteljahresschrift für Dermatologie und Syphilis*, 1874–88; and *Archiv für Dermatologie und Syphilis* since 1889.

Dermatolog. Zeitschr. = *Dermatologische Zeitschrift*, Berlin.

Dermatolog. Centralbl. = *Dermatologisches Centralblatt*, Leipzig.

Giorn. ital. = *Giorne italiano delle malattie veneree e delle malattie della pelle*, Milan.

Unna, *Histopathology* = *Histopathology of the Diseases of the Skin*, by P. G. Unna. English translation of the German work by Norman Walker, Edinburgh.

Besnier and Doyon's French translation of Kaposi's treatise (*Die Pathologie und Therapie der Hautkrankheiten*) refers to Besnier and Doyon's notes in the same. Paris.

Leloir and Vidal, *Traité descriptif*, refers to their work, *Traité descriptif des maladies de la Peau*, Paris.

Kaposi, *Diseases of the Skin*, refers to the English translation of Kaposi's treatise by James C. Johnston, New York.

International Atlas refers to the *International Atlas of Rare Diseases of the Skin.*

Bangs and Hardaway's *American Text-book* = *An American Text-book of Genito-Urinary Diseases, Syphilis, and Diseases of the Skin*, edited by L. Bolton Bangs and W. A. Hardaway (W. B. Saunders Company, Philadelphia).

Morrow's *System* = *A System of Genito-Urinary Diseases, Syphilology, and Dermatology*, edited by Prince A. Morrow (D. Appleton and Company, New York).

Twentieth Century Practice = *Twentieth Century Practice of Medicine*, edited by Thomas L. Stedman (William Wood and Company, New York).

ANATOMY AND PHYSIOLOGY OF THE SKIN.

ANATOMY.

THE integument is not to be viewed merely as the protective envelope or covering of the body, but as an integral and closely associated part of the general economy, with correlated and independent functions, and with duties to perform that give it a good claim to be looked upon additionally as an independent, and probably much underrated, organ. A proper understanding of its histologic construction and of its important physiologic functions is necessary in order to obtain a clear idea of the various pathologic processes that take place in its component tissues, and the clinical external objective lesions to which they give rise.

The integument is a somewhat complex elastic fibrous structure, enveloping the whole body, and merges into the mucous membrane, with which it is continuous, at all the natural mucous orifices. Through its own connective tissue, its numerous blood-vessels, nerves, lymphatics, etc., it forms a close and firm association with the structures of the body beneath. Although the surface is, as a whole, approximately smooth, close inspection shows innumerable ridges, furrows, and pores, and the presence of variously sized hairs, and, at the end of the terminal phalanges of the extremities, the hardened nail formations. The ridges are due to the row-like arrangement of the papillæ of the skin, sometimes straight, slightly wavy, and crescentic; the crescentic are more pronounced in certain parts. In many regions the surface is divided up by fine lines and furrows into many irregularly sized triangular, quadrilateral, polygonal, elongated, and oval-shaped areas or spaces. The larger furrows are much more pronounced about the joints, whereas the smaller or surface lines are more noticeable on the extensor surfaces. The pores—minute depressions—represent the orifices of the follicles and glands of the skin. According to Philippson, some of the lines and ridges, which might be termed "primary," are dependent upon proliferation of the rete and linear depressions of the horny layer; and others "secondary," or physiologic furrows, in the neighborhood of the articulations, resulting from the constant creasing induced by the incessant joint motion. It is probable, too, that the distribution of the connective-tissue fibers and bundles to which presumably are due the **lines of cleavage** of Langer, may have an important and contributory bearing on the production of these furrows and folds.

In a general way and in its gross features the skin can be divided into two parts—the epidermis and the corium; commonly a third division, of subcutaneous tissue, is added, but this last is in reality an extension or part of the corium, the natural connecting tissue that joins

the skin proper to the underlying body structures. Inasmuch, however, as it is closely associated with the corium proper and often contains the deeper glandular organs of the skin and the fat-cells, and as many of the pathologic processes invade its substance, a knowledge of its anatomic structure and characters becomes a necessary part

FIG. 1.—Vertical section through the skin: general diagrammatic view (after Heitzmann).

of cutaneous histology. The epidermis is subdivided into several layers. In addition to these parts the sebaceous glands, the sweat-glands, the hairs, hair-follicles, and nails, commonly known as the appendages of the skin, together with the blood-vessels, lymphatics, nerves, and muscles connected with the integument and its nutrition

and functions, are all to be considered as parts of its structure, and are sometimes involved jointly or independently in its various morbid processes.[1]

THE EPIDERMIS.

The epidermis, also called the cuticle, cuticula, scarf-skin, or epithelial layer, is the outer or surface part of the skin, and is conveniently divided into four layers—the outermost layer, or **stratum corneum**, known as the *horny layer;* below this an ill-defined, shining layer, or **stratum lucidum**; and beneath this a granular layer, or **stratum granulosum**; and, finally, the innermost layer, or **rete Malpighii**, commonly spoken of as the *mucous layer*, *rete*, or *Malpighian layer*. The outermost part of the epidermis is constituted of closely packed cells, of horny and dry character, the cells becoming less dense and less closely crowded, and softer and even succulent as the lowest layer of the rete is approached. It varies considerably in thickness in different parts of the body, its thickest development being observed on the palms and soles, and its thinnest on such parts as the eyelid, the prepuce, etc., and due

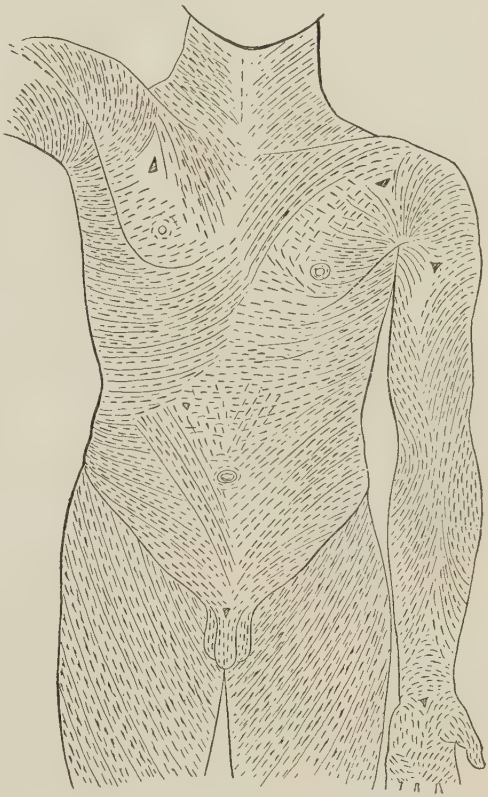

FIG. 2.—Lines indicating cleavage of the skin (Langer).

[1] In the preparation of this section I am considerably indebted to Professor Duhring's admirable description and judicial review, embodying the investigations of Ranvier, Kolliker, Heitzmann, Robinson, Unna, Sappey, Bowen, and others contained in his work, *Cutaneous Medicine*, Part I. Moreover, in order to combine terseness and brevity with clearness in this description, I have frequently consulted and often borrowed expressions from the shorter and graphic contributions by Robinson, in his *Manual of Dermatology;* by Louis Heitzmann, in Morrow's *System*, vol. iii. (Dermatology); by Allen, in *Twentieth Century Practice*, vol. v. (Diseases of the Skin); and by Bowen, in Bangs-Hardaway's *American Text-Book*. For a complete account of the development of the chief cutaneous structures the articles "On the Development of the Human Epidermis and its Appendages" by Macleod, in the *British Journal of Dermatology*, beginning with 1898, p. 183, may be consulted, which, besides containing much original work and many original illustrations, give a full and impartial presentation of the contributions of others; and which together with much other pertinent matter is also to be found in his recent publication, *Practical Handbook of the Pathology of the Skin*. See also a valuable but briefer account in Piersol's *Histology*.

to different thicknesses of the corneous layer, the rete remaining relatively uniform. It is developed from the ectoderm. In earliest embryonic life this latter is primarily composed of but one layer of cells,—epitrichial layer,—below which several rows of epithelial cells develop, the epitrichial layer finally disappearing toward the sixth month of fetal life (Bowen).

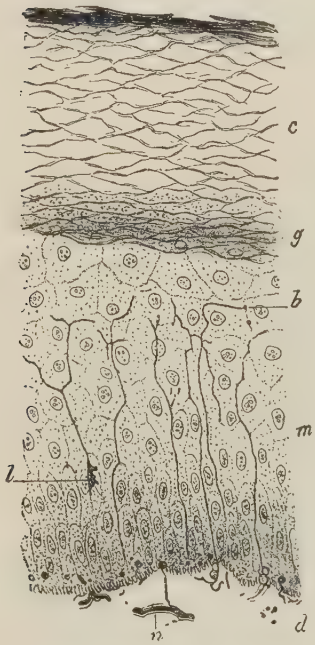

FIG. 3.—The epidermis: *c*, Corneous (horny) layer; *g*, granular layer; *m*, mucous layer (rete Malpighii); the stratum lucidum is the layer just above the granular layer; *d*, corium. Nerve terminations: *n*, Afferent nerve; *b*, terminal nerve-bulbs; *l*, cell of Langerhans (Ranvier).

Stratum Corneum.—The stratum corneum, horny layer, or dead layer, is the outer or surface division of the epidermis, and is composed of several layers of flattened, imbricated epithelial cells that have undergone various degrees of keratinization, and that, in vertical section, appear spindle shaped, irregular, and wrinkled. In the outermost layer these cells have lost their cell characteristics or appearance, and appear simply as thin, flattened, dry scales. This appearance pervades to some extent the whole thickness of the corneous layer, but is less marked as the lower part is approached, the cell character becoming more and more recognizable, although not conspicuously so, as the rete or living layer of the epidermis is reached. In the lowest cells, with their sometimes still visible polygonal outlines, a nucleus is often faintly indicated. The outer scales are being continuously cast off during life, and are constantly renewed by the lower layer of the epidermis, with which it is histogenetically connected. This layer can readily be called the dead layer of the epidermis, as it gives no evidence of life, granular protoplasm being found, according to Unna, only in the basal and superbasal layers.

Stratum Lucidum.—The stratum lucidum, so designated by Oehl, or translucent or shining layer, is a thin, ribbon-like, not always well-defined, layer, situated immediately below the stratum corneum, of which it is considered by some to be a part. It is constituted of closely set glistening or translucent epithelia, flattened and running parallel with the surface, the separate cells not always being distinguishable. According to Kaposi, this layer is supposed to be due to some chemicobiologic change that the immediately underlying granular or rete cells must undergo in order to become horny cells. It presents no evidence of the granules of the subjacent layer, which have disappeared presumably as a result of the peculiar change or in consequence of the process of keratinization. According to Bowen,

it is deeply stained by certain reagents, especially those that have an affinity for horny tissue.

Stratum Granulosum.—The stratum granulosum, as designated by Langerhans, or the granular or hyaline layer, is next below the stratum lucidum, and lies immediately upon the rete, of which it is usually considered to be a part—the uppermost layer. It is composed of one or two, rarely more, strata of coarsely granular, nucleated epithelia. This granular material, composed of some peculiar chemical substance, is, beyond the now generally accepted belief of its relationship to the process of cornification, still a subject of discussion. It takes the hematoxylin and picrocarmin or methyleosin stains well. Ranvier, who considered it of partially fluid form, called it eleidin, whereas Waldeyer named it keratohyalin, believing it to be of more solid character and to resemble the nature of hyalin, and to be concerned in the process of keratinization. According to Buzzi, these are two distinct substances: the first is fluid, and is found chiefly in the lowest part of the horny layer, the second (keratohyalin) representing the granules found in the cells of the stratum granulosum. On the other hand, the granular material is thought by some to be a nitrogenous substance known as chitin, which is also found in the skin of insects and in the shells of crustacea. The precise character and nature of these granules cannot, therefore, as yet be considered as settled, Kromayer even denying that they are concerned in the process of cornification.

Rete Malpighii.—The rete, rete mucosum, mucous layer, germ layer, or Malpighian layer, as it is variously known, is an important layer of the epidermis, and is concerned in most of the pathologic processes of the skin. It lies immediately upon the papillary layer of the

FIG. 4.—Section of developing skin from human fetus of three and one-half months: *a*, Layer of cuboidal cells representing rete mucosum; *b*, polyhedral elements forming superficial layers; *c*, outermost flattened plates, probably the remains of the epitrichial layer; *d*, mesodermic tissue forming corium (Piersol).

corium, the granular layer forming its uppermost layer or boundary. It is, therefore, the deepest stratum, and might be known as the living stratum of the epidermis. In fact, as the studies of Carl Heitzmann and, subsequently, Stricker indicate, the epithelia composing it together constitute a layer of reticulated protoplasmic living matter. It consists of several strata of distinctly nucleated cells, irregularly polyhedral in shape, especially in the upper part, rich in protoplasm, and arranged in parallel rows. They readily take the carmin stain, as well as other coloring-matters. The upper rows of cells, compared to those adjacent to the corium, are somewhat broad and slightly flattened. The cells of the lowermost part are columnar or cylindric

in shape, with the nuclei correspondingly elongated, arranged in a palisade-like manner, and with the lower broad or basal portion firmly fused with the papillary layer of the corium by an interlacing of the projecting papillæ, and the dipping-down elongations of the mucous layer. In addition, the cells of the rete are furnished with radiating spines or prickles, and these project into the corium and lock into one another; this interlocking, together with the presence of a transparent albuminous substance or cement that permeates the rete, makes this layer of the epidermis a compact, resisting mass.

Owing to these prickles, spines, thorns, or spokes, the rete cells are also known as "*prickle-cells*," and the layer as the "*prickle layer*" or "*thorny layer*" of the epidermis. They are of the same structure as the cells themselves, and result in a firm interlacing, becoming less prominent as the uppermost layer of the rete is approached. These prickles have been thought to be canals for the transference of fluid, but are now generally considered to be simply outgrowths of protoplasm, although it is not improbable that the resulting interlacing channels left facilitate the circulation of lymph and give space possibly for nerve-threads, etc. It is in the lower cells of the rete that the coloring-matter or pigment of the skin is found, varying in different individuals and in different races, as will be referred to further on. The so-called Herxheimer's spiral fibers and Langerhans's cells remain to be described.

FIG. 5.—"Prickle-cells" of the rete greatly magnified (Robinson).

The **Herxheimer's "spiral fibers"** or **"epithelial fibers"** are delicate fibrils found at the basal portion of the rete, close to or at its junction with the papillary layer of the corium, projecting upward parallel with the columnar cells, usually in a spiral or tortuous manner, anastomosing with one another. They are made clearly definable only by special methods of staining. Their origin and purpose are not clearly understood. Various opinions have been advanced: that they are canals for the transference of nutritive material to the rete, projections of fibrin from the corium, pigment-carrying wandering cells from the latter, and epithelial fibers—the last being the more generally accepted view. The **cells of Langerhans** are occasional cell-bodies found usually in the deeper strata of the rete, and variously viewed as colorless tissue corpuscles, wandering cells, lymphoid cells, and as pigment-cells deprived or devoid of pigment. They are without nucleus, and are elongate and irregularly stellate in shape.

CORIUM.

The corium, or true skin, also known as the cutis, cutis vera, or derma, is a development from the mesoblast; and, according to Unna, even at birth the most superficial portion, which forms the foundation of the subsequent papillary layer, consists of young granulation tissue with very few fibrillæ, whereas the cutis proper, or pars reticularis, has at this time already acquired consider-

able thickness and density, in consequence of the continuous deposition of collagenous substance between its cells. It immediately underlies the row of columnar cells of the rete, with which, by its papillary projections and the corresponding interpapillary dippings of the rete and the prickles of the cells of the latter, it makes a firm connection that is not readily disturbed. It is composed of masses of fibrous and elastic tissue, especially the former, which are closely intertwined, forming a dense and firm meshwork, most compact at the uppermost part, becoming less so as the subcutaneous tissue is approached. The bundles of anastomosing fibrous connective tissue run parallel to the surface of the skin, and are arranged on a definite plan, to which are due the lines of cleavage of the skin. They are most numerous and in greatest abundance on those parts where resistance and not elasticity is essential, as on the sole of the foot. On the other hand, the elastic fibers are in greater number in regions where motion and extensibility are necessary, as about the joints. Compared to the amount of fibrous connective tissue, however, the elastic tissue is relatively scanty, becoming more abundant with advancing years. It is only during late years that the elastic fibers have received much attention, more especially by Lustgarten and Unna, this being rendered possible by means of new staining methods, the ordinary methods not sufficing to make them visible. In addition to these fibrous components, spindle-shaped connective-tissue corpuscles or cells are seen here and there, and there is a cement-like substance permeating the parts.

The corium constitutes the elastic and fibrous envelope of the body, and contains blood-vessels, lymph-vessels, glandular structures, hairs, fat-cells, muscle elements, and the nerves with their terminal organs of touch and sensation. It varies in thickness on different parts, at different ages, and in different individuals; it is thickest over the palms, soles, back, and buttocks, and thinnest on the eyelids and prepuce. It is conveniently divided into two parts or layers—the papillary layer, or pars papillaris, and the reticular layer, or pars reticularis, although it is an arbitrary division, and one that is not sharply defined.

Pars Papillaris.—The pars papillaris, or papillary layer, is the upper portion of the corium, which touches the rete above and extends to just below the basal portion of the papillæ. The papillary layer is not an even or a level one, but is a wavy or zig-zag line made so by the innumerable glove-finger-like projections or upward prolongations of the corium into the rete—the so-called papillæ. The rete layer fills up the intervening gaps by corresponding downward juttings—the interpapillary rete prolongations. The papillæ, composed of fine connective-tissue fibers running parallel to their long axis, vary considerably in size, more especially in different regions, but even in the same place there is often some variation. The largest, the so-called "compound papillæ," are due to a bunching or an apparent fusing together of the basal portions of several or more, the upper parts, of various length, projecting like so many crowded fingers or like teats from an udder. Probably most of them are, however, small conic or blunt protrusions. They are arranged in rows, which may

be straight, curved, or, as on the finger-tips, concentric or crescentic, readily recognizable by the naked eye. Their number is beyond computation: according to Sappey's calculation, there are about 150,000,000 over the entire surface, and 100 on a square millimeter. They are more numerous in some situations than in others, and inasmuch as they contain the nerve terminals or organs, they are found most abundantly on parts where sensitiveness or the sense of touch is most acute, as on the terminal phalanges, penis, clitoris, nipple, etc. Some of the papillæ contain loops of blood-vessels—vascular papillæ; others, the nerve terminals or organs—nervous papillæ. The latter have, as a rule, only a limited vascularity, but some papillæ

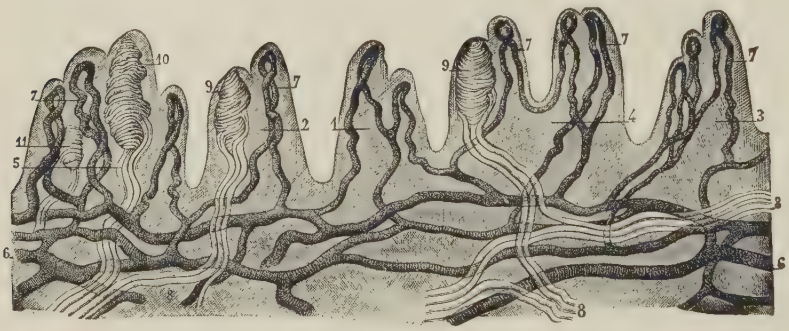

FIG. 6.—Section of palm of hand showing single and compound papillæ and their blood-vessels, with terminal vascular loops: 1, 2, 3, 4, 5, Compound papillæ, containing one or more vascular loops; 6, 6, network of blood-vessels; 7, 7, 7, 7, 7, vascular loops; 8, 8, 8, beginning subpapillary nerve-plexus · 9, 9, and 10, 11, tactile corpuscles with from two to four nerve-fibers (Sappey).

contain both nerve-endings and vascular loops, especially the compound papillæ.

Pars Reticularis.—The papillary layer passes imperceptibly into the reticular layer, this latter merging into the subcutaneous tissue beneath. It is of looser texture than the pars papillaris, and the bundles of connective-tissue fibers are larger and coarser. The fasciculi, especially in the lower part, have a more oblique direction. It has received the name reticular layer from its reticulated appearance. It constitutes the bulk of the corium. It contains some of the glandular structures, hair-roots, and muscles, and, like the papillary layer, is liberally supplied with blood-vessels, etc.

SUBCUTANEOUS TISSUE.

The subcutaneous tissue, or hypoderm, as it is designated by Besnier, immediately underlies the reticular layer of the corium, and probably, as Unna states, owes its recognition as a distinct layer "only to the circumstance that, in consequence of the macroscopically appreciable deposit of fat in it, a distinct border-line is visible even to the naked eye." The division is, however, usually considered higher up than the layer of fat-cells, although most authors agree that it is a purely arbitrary one, with no sharp or appreciable boundary-line.

Like the corium, the subcutaneous tissue is composed of a network of interlacing and anastomosing fasciculi and bundles of connective tissue, less densely arranged than those in the corium, and inclosing irregular and rhomboidal spaces containing the masses of fat-cells. Lymphoid corpuscles are present in this layer, especially in the neighborhood of the blood-vessels and glands. It is essentially a continuation of the reticular layer, so far as its connective-tissue formation is concerned, with looser meshes, and gradually disappears into and is attached to the fasciæ and aponeuroses of the muscles and the deeper structures beneath.

The roundness and fulness of the integumental covering are due to the presence of the masses of fat-cells contained within its interstices, and should they disappear by absorption or depletion in consequence of starvation, fever, or emaciating disease, a looseness or wrinkling results.

The fat-globules are spheric vesicles consisting of an elastic capsule, with an oval nucleus at one point, and a drop of oil filling the cavity. They are grouped in a lobular manner, and are separated from one another by delicate fibrous connective tissue with a comparatively abundant supply of blood-vessels having an afferent artery, one or two efferent veins, and a capillary plexus (Louis Heitzmann). Owing to the abundance of the fat-cells present this structure is designated *panniculus adiposus*, *stratum adiposum*, or *adipose tissue*. Warren's studies showed, especially where the cutis is thick, fat columns (columnæ adiposæ) projecting from the subcutaneous tissue obliquely upward through the corium to the bulb of the smaller hairs, and some containing a coil-gland that they help to support, their axes being parallel with the arrectores pilorum. The fat-globules are absent in certain regions, as on the eyelid, in the auricles, on the penis, scrotum, and labia minora. The subcutaneous tissue contains the sweat-gland coils, the deeper-lying hair-follicles, trunks of blood- and lymph-vessels, nerves, corpuscles of Vater, and the Pacinian bodies.

BLOOD-VESSELS.

Both the corium and the subcutaneous tissue are highly vascular and liberally supplied with truncal and capillary vessels. The epidermis has no vascular supply. Two horizontal and parallel plexuses are to be seen—a deep and coarser one, in the subcutaneous tissue, and a fine, delicate, and minutely ramifying layer just beneath the papillæ, and loops from this system extending up into the latter. In some of the papillæ the loops are quite well defined, but in those containing the developed nervous structures the vascular supply is not so clearly recognizable, some, according to Robinson, frequently having no blood-vessels, although Thin believed that the nervous papillæ contained loops, these being of an extremely fine and delicate character. This upper plexus is connected with the lower vascular network by numerous large truncal vessels. The vessels forming this lower plexus consist of fairly large arterial and venous channels, from which ramifications extend to the coil-glands and to the fat-cells. The coil-glands are liberally supplied, being more or less sur-

rounded by a delicate plexus of arterioles that empty into two or three small veins, one of which always follows the duct upward, finally anastomosing with the veins of the papillary layer. The sebaceous glands and hair-follicles are likewise abundantly supplied, the hair papilla having its own arteriole branching into looped capillaries; transversely arranged capillaries are found between the layers of the follicles, which also penetrate their inner sheath, and the venous plexuses accompany the arterial in all parts, the venous vessels being usually somewhat larger than the arterial.

According to Tomsa, as cited by Louis Heitzmann, the skin has three distinct vascular districts, each of which is supplied with its own arterioles and roots of veins; the deepest is that of the subcutaneous fatty tissue, the middle that supplying the sweat-glands, and the uppermost belonging to the derma with its hair-follicles and sebaceous glands.

LYMPHATICS.

Lymphatic vessels are abundantly supplied to the integumentary tissues, and have been studied especially by Sappey, Biesiadecki, Neumann, Klein, and a few others. They are found forming numerous plexuses (Klein), but more particularly a superficial and a deep network. The former is just below the superficial plexus of blood-vessels, and consists of minute ramules, from which blind shoots or short loops extend into the larger papillæ. Intercellular lymph-spaces are to be found in the epithelial layer of the epidermis, and seem, from injection demonstrations, to be in some manner connected with the lymphatic system of the derma. Indeed, lymph-channels and spaces without independent walls exist in all parts of the skin (Neumann, Unna, and others), and especially in the interstices of the fibrous tissue of the corium, and although a part of the lymphatic system, their relation to the lymphatic vessels is still not known definitely. Klein believes that the lymphatics have open communication, by true stomata, with these spaces, which he looks upon as lymph-rootlets. The deeper plexus of lymphatics is situated close to the subcutaneous network of blood-vessels; in fact, blood-vessels and lymphatics are found for the most part accompanying one another (Louis Heitzmann). The superficial and deeper layers, as well as other lymphatics, are joined by anastomosing branches. Many of the larger vessels have valves and corresponding constrictions. According to Neumann, the hair-follicles, as well as the sebaceous and sweat-glands, have their own system of lymphatic capillaries, and Klein likewise divides them into several systems, corresponding to these parts and also to the connective-tissue matrix and the adipose tissue.

NERVES.

The skin is well endowed with both medullated and non-medullated sensory nerve-fibers, the former sometimes losing their sheath and continuing as non-medullated fibers. They are found often in combination. The medullated are most abundant where the Pacinian and tactile corpuscles are numerous. They arise from nerve-bundles that are found spread out in the form of plexuses corresponding to the subpapillary and subcutaneous vascular network.

The glands, blood-vessels, and Pacinian corpuscles are supplied from the nerve-bundles in the subcutaneous tissue and lower corium —from the lower plexus. These bundles pass upward, the fibers spreading out and running horizontally, and forming a subpapillary plexus consisting of a close and fine network of non-medullated fibers. Within the papillæ, around the capillaries, they form a dense plexus of thick or fine varicose fibers with many nuclei (Robinson). From this plexus, again quoting Robinson, non-medullated fibers pass toward the epidermis and enter it either directly or after running a short distance parallel to its surface. Penetrating the rete, they lie between the epithelial bodies and form a plexus. Langerhans believes that they anastomose between the cells and end in minute swellings or club-shaped extremities, whereas according to Unna's observations the final distribution is intracellular, each cell containing a pair of nerve-endings.

The nerve-fibers do not all, however, terminate in this way, for many, as previously stated,—and this concerns especially the medullated nerves,—end in the Pacinian corpuscle, whereas some of those projecting upward to the surface terminate in the tactile corpuscles of the papillæ—the so-called corpuscles of Meissner or Wagner, and of Krause—and in Merkel's touch-cells. A large number of the medullated fibers, however, pass upward to the papillæ, where they form loops and return to the subpapillary region, and several of these looped medullated fibers are sometimes present in a single papilla (Robinson).

The exact or relative purpose and function of these various bodies are not fully known, except that it is generally agreed that they are sensory organs. According to Merkel, cited by Duhring, the tactile corpuscles and the touch-cells are organs for the finer perceptions, and the bulb-corpuscles and Pacinian bodies for localization and common sensation; the free nerve-endings in the epidermis may subserve touch as well as temperature, and those in the hair, both touch and sensation.

Pacinian Corpuscles.—The Pacinian corpuscles, also known as the corpuscles of Vater, are most numerous in the subcutaneous tissue of the last phalanges of the fingers and toes and the palms and soles. They are also abundantly met with on the nerves of the joints (Duhring). As many as 95 have been found upon the index-finger, and 608 on the entire hand (Herbst). Their function is not clearly understood, but, as Bowen states, their situation in parts especially sensitive indicates some connection with the tactile sense,

although this view is seemingly opposed by their deep position. They are clearly defined, oval, elliptic, or pear-shaped grayish bodies, made up of concentrically arranged capsules—20 to 60, according to Kölliker—with an elongated central clear space containing a transparent matrix and limiting membrane and inclosing a stalk-like nerve terminal—the ending of a medullated nerve-fiber that enters at the lower extremity of the corpuscle.

The various concentric layers are separated by septa into smaller and larger spaces, containing a clear serous fluid, and lined with a single layer of epithelium; they are composed of connective-tissue fibers and connective-tissue corpuscles. The fibers are arranged in

FIG. 7.—Pacinian corpuscles from the derma of the palm of the hand; stained with aurum chlorid (× 500): *a*, Transverse section; *b*, longitudinal section (Louis Heitzmann).

a longitudinal layer, especially toward the inner portion, and in a circular layer toward the outer portion; these two layers are, according to Ranvier, connected or crossed by transverse or "radial" fibers. The medullary sheath and sheath of Schwann cease at the entrance of the nerve into the central clear space (Robinson). Unna considers the corpuscle due to an enormous enlargement of the latter sheath into concentric lamellæ, with nuclei and endothelial lining.

Tactile Corpuscles.—The tactile or touch-corpuscles, also known as the corpuscles of Meissner or of Wagner, are ovoid or roundish fibrous bodies found in the papillæ, occupying the greater portion and sometimes the entire extent, and usually those papillæ that have no vascular loop. Occasionally they are found somewhat beneath, in the papillary layer. They are exceedingly numerous, varying in number on different parts, being most abundant on the fingers, especially the last phalanges, where, according to Meissner,

one papilla in every four contains a tactile corpuscle. Occasionally two, rarely three, are found on one papilla, although in some instances, according to Robinson, one corpuscle has the semblance of two, this resulting from a constriction caused by the nerve. They are well defined, with transverse bands or striations, and small nuclei (Bowen), the mass of the body consisting of nucleated connective tissue (Langerhans, Thin), although their exact structure is involved in some uncertainty. One or two medullated nerves, ascending from the corium, enter the corpuscle at its extremity or side, their myelin sheath being lost in the fibrous mass of the capsule; dividing into delicate fibrillæ, they wind spirally in a variable course along and through its structure, anastomosing with one another, their termination being a matter of some doubt—in a number of terminal fibrils (Bowen), in slight pear-shaped or cylindric enlargements (Louis Heitzmann), or, after a greater or lesser number of windings, leave the corpuscle at its apex as one, sometimes as two, efferent fibers (Robinson). In fact, according to Robinson, each corpuscle has an afferent and an efferent nerve.

FIG. 8.—Tactile corpuscle from finger-end, treated with osmium, showing the two afferent nerves (purposely accentuated), disappearing in the upper part. The transverse nuclei belong to the neurilemma of the nerve-fibers (after Kölliker).

Corpuscles of Krause, bulb-corpuscles, or **end-bulbs,** originally described and designated by Kölliker as "papillæ fungiformes," and regarded by him as undeveloped touch-corpuscles, resemble the inner structure of the Pacinian body, and seem to be the terminal corpuscle of some of the medullated nerves coming from the deeper plexus. They vary somewhat in form between this and that of the tactile corpuscle, although Krause believes that they possess features that serve to distinguish them. They are observed especially about the sensory mucous membrane—the vermilion of the lips, the tongue, the conjunctiva, the glans penis, and the clitoris; in the two last-named regions they are larger and mulberry shaped, and lie deeply under the papillæ—the genital nerve-corpuscles of Krause.

Merkel's Touch-cells.—Merkel has described minutely a touch-cell in which a medullated nerve terminates, situated in the epidermis and superficial corium. These touch-cells have since been studied by Kölliker and Ranvier. They are ovoid in shape, with a nucleus

and nucleolus, and are found in regions where tactile corpuscles are few in number, as upon the abdominal surface. According to Kölliker's observations, they are numerous also on the finger-tips and plantar surface. There is still considerable diversity of opinion both as to their nature and their function.

Vasomotor and Motor Nerves.—The sensory nerves are not the only nerves of the skin, as, according to Kölliker, cited by Duhring, motor nerves are found on the smooth muscles and on all glands that have a muscular layer. The vasomotor nerves also probably play an important rôle, but although they are often spoken of in discussing the pathology of diseases, but little in reality is known concerning them. The general belief is that they probably exist in two varieties, those having connection or association with the central nervous system, and those connected with the ganglionic plexuses adjacent to the integument itself. Being particularly abundant around the cutaneous arterioles, it can readily be seen how they can, by increase or diminution of the circulation, and by dilatation or tension, exercise a marked influence upon the vascular, muscular, and glandular systems of the integument.

The well-known occurrence of flushing and blanching of the skin, the "cold sweat" in sudden nervous perturbation, the production of "goose-flesh," etc., all point to the possibly profound pathologic action that emotional, toxinic, or other disturbance of these nerves may excite.

MUSCLES.

The skin is supplied with both striated and smooth muscles, the latter being much more abundant than the former.

The **striated muscles** are found chiefly in certain regions, as on the face and neck, and arise from the subcutaneous tissue and deeper-seated muscles, and extending upward vertically or obliquely between the glands into the corium.

The **non-striated** or **smooth muscles** are very numerous, and run obliquely or parallel to the general surface; if the latter, they run either in a straight or in a circular direction. The straight muscles anastomose with one another and form a network or plexus, as in the scrotum,—constituting the tunica dartos,—prepuce, and perineum; those running circularly form a ring-like muscle, as in the areola of the nipple. According to Unna, fasciculi arranged in strata, and lying almost perpendicularly to the direction of cleavage, are found in the corium. The majority of the obliquely running muscles are connected with the hair-follicles and sebaceous glands, although they are also observed, according to Tomsa, Unna, and others, in many regions, as on the forehead, the cheeks, the back, etc., independently of these structures.

The follicular muscles—the **arrectores** or **erectores pilorum**—extend from their point of origin in the inner sheath of the follicle obliquely upward, close to the lower surface of the sebaceous gland, to the papillary layer of the corium. In its course upward it frequently divides into two or more bundles, these secondary bundles

afterward pursuing different directions, or uniting with fibers from other muscles, and forming a network in the corium; occasionally several secondary bundles run nearly parallel to one another, and terminate either separately or conjointly (Robinson). According to Klein, Unna, Nékam, Balzer, and others, they have an abundance of traversing and surrounding elastic fibers, and terminate in veritable tendons of similar elastic tissue. It is probable that the muscular and elastic fibers together play an important part in influencing and regulating circulatory and glandular action. The arrector muscles are of general distribution; they are seen most completely developed and in greatest abundance in the scalp, on the mons veneris, and on the scrotum, whereas in certain hairy regions, according to Kölliker, as in connection with the hairs of the eyelashes, eyebrows, and the axillæ, they are wanting. The erectile condition known as "goose-flesh," or cutis anserina, is produced by the sudden contraction of these muscles over the general surface. Overlying the sebaceous glands as they do, their contraction naturally tends to compress and evacuate these structures, this probably being an important part of their function.

PIGMENT.

The pigmentation of the skin has its chief seat in the lower strata of the rete, appearing as a darkened stratum above the papillary layer of the corium. It is due to a faint staining of the cells themselves, most pronounced in the nuclei, and to the deposition of fine granules of pigment—melanin—in the cell cavity. The resulting color of the skin is naturally considerably influenced or modified by the degree of vascularity. Unna is strongly of the opinion that the color of the white race is due largely to the presence of the granular layer, whereas Kromayer, as cited by Duhring, attributes it to several conjoint factors—principally to translucency of the epidermis and corium, the anemic condition of the papillary layers, and the presence of fat in the subcutaneous connective tissue. In the dark-skinned races the quantity of pigment deposit is markedly greater, varying according to the degree of coloration of the skin. The pigment-cells are more highly colored, and the staining involves the whole rete and upper corium, and usually extends to some degree to the cells of the horny layer. The pigment granules are much darker, and occur in greater abundance than in the white race. The children of dark-skinned races are usually born apparently white, or relatively so, coloration then taking place rapidly. Morison's investigations as to the negro skin show, however, that beginning pigment deposits are found several weeks or more before birth. Thomson, cited by Macleod, detected pigment granules in the skin of a negro fetus as early as the fifth month, forming a yellow stain in the deeper cells of the prickle-cell layer. According to Karg, white skin transplanted upon the negro becomes pigmented, and the color of the negro skin transferred to the white man soon disappears.

The origin of the pigment is involved in some uncertainty. Various views are held, among them being the following: That it

is carried up by the leukocytes from the underlying subcutaneous tissue (Bichat, Riehl, Aeby, and Ehrmann), that it is due to the migration of the pigmented cells of the adjacent connective tissue (Kölliker); or that it is formed within the protoplasm of the cells *in loco*, the earliest pigment appearing within mesoblastic cells that have entered the epidermis while still uncolored (Piersol). Unna considers that the pigment is formed from the coloring-matter of



FIG. 9.—Section of negro skin, including epidermis (*a*) and papillary layer (*b*) of the corium. The pigment is contained in the deepest layer (*c*) of the epidermis (Piersol).

the blood, and is carried up to the epidermis by "chromatophores" or "wandering cells," a view practically shared by List. Macleod thinks it probable that the "chromatophores" are lymph-cells, and that the pigment formed from the blood in the cutis is carried in the lymph-stream to the interepithelial spaces, and reaches the nuclear region of the cells by passing along the tracks of the nerve-fibers.

SWEAT-GLANDS.

The sweat- or coil-glands, also known as sudoriparous glands, glandulæ sudoriferæ, glandulæ glomiformes, are seated in the subcutaneous tissue and in the lowermost part of the reticular layer of the corium. They consist of a simple tubule coiled upon itself, forming an ovoid or globular convoluted body with a blind end in the central or outer part of the coil, and the excretory duct. This latter is essentially a continuation of the tubule somewhat altered, beginning usu-

ally in the middle or upper central portion of the mass, and traversing the corium directly and generally straight upward and between the papillæ, its course becoming somewhat less regular in the rete, and passing through the corneous layer in a peculiar wavy, spiral, or cork-screw manner, and opening upon the surface in a rounded, funnel-shaped aperture—the so-called sweat-pore.

The coil or gland proper is the secreting part of the tubule, and consists of a lining of secreting cuboidal or polygonal, somewhat granular-looking epithelia, of a basement or investing membrane made up of flattened endothelial cells and, between the latter and the layer of secreting cells, some unstriped muscular fibers. A layer of such fibers is also found in certain glands, especially those of the axillæ, external to the investing membrane (Robinson). Virchow states that the

FIG. 10.—Sweat-glands of different size (of moderate magnification) showing coil or convolutions forming gland proper, the blind end of tubule, and excretory duct (Sappey).

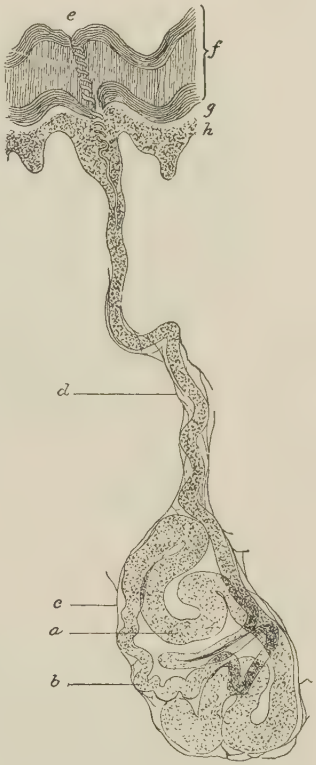

FIG. 11.—Section through sweat-gland, duct, and outlet (of greater magnification): *a*, Coils forming gland; *b*, beginning of excretory duct; *d*, excretory duct; *e*, sweat-pore; *f*, corneous layer; *g*, stratum lucidum; *h* granular layer (von Brunn).

covering membrane is made up of connective-tissue fibers and connective-tissue nucleated cells, running longitudinally with the canal, the inner portion representing the membrana propria.

The secreting epithelial layer is made up of a single layer of cells, with nuclei and one or two nucleoli, and, according to Heynold, their inner surface shows a delicate limiting membrane, especially defined in the larger glands. There is a well-marked lumen in which, as well as in the cell-body, oil-globules are usually present. The glandular structure is imbedded in considerable, but somewhat loose, fibrous connective tissue, which is denser and contains a larger number of lymphoid cells between the tube-coils. The vascular supply is

abundant, the blood-vessels from the deep plexus surrounding the coils like a network, with numerous vessels penetrating between the coils. Ranvier has shown also the existence of an inclosing network

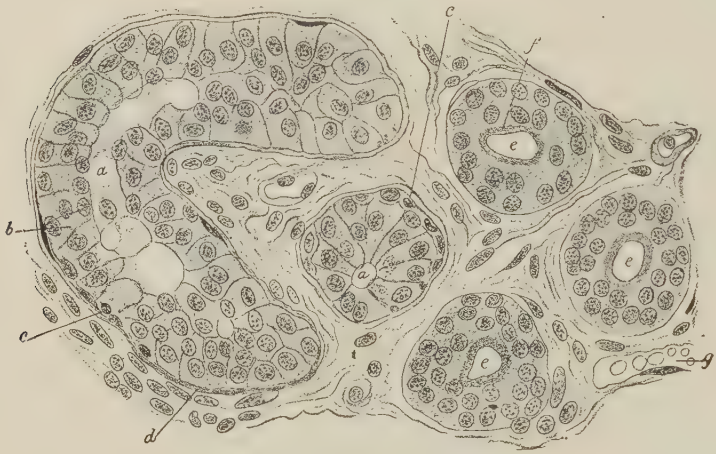

FIG. 12.—Section through a sweat-gland (× about 400) : *a*, *a*, Secreting part of coil ; *b*, gland-cells ; *c*, smooth muscle-fibers ; *d*, membrana propria of the duct ; *e*, *e*, *e*, cross cut of duct ; *f*, cuticular lining of duct ; *g*, blood-vessel (Rabl).

of nerve-fibers, some of which penetrate through the investing membrane to the muscular layer.

The excretory duct presents a somewhat different structure from that of the coil. As the duct extends upward there is an increase in the number of epithelial cells, these forming a double layer and gradually showing a distinct lining or cuticular covering. The duct loses its investing membrane and muscle-fibers when it enters the rete, and, in this region, eleidin granules have been observed in the cells. In the stratum corneum the duct-wall is formed of cells of this layer.

FIG. 13.—Section of skin of human fetus, showing developing sweat-glands. The latter grow as epithelial cylinders from the rete mucosum of the epidermis into the underlying corium ; the characteristic coil appears later (Piersol).

The first recognizable signs of the **development of the sweat-glands** are observed in the fifth month of fetal life, and consist of an ingrowing or budding of the rete cells in the form of conic epithelial processes into the corium. By the sixth month elongation has taken place, and from that time on the coil-formation gradually progresses ; in the seventh month the canal appears, and the lower end of the tube is observed to be dilated and somewhat twisted ; by the ninth

month the tube is coiled upon itself and the gland proper is formed (Robinson). Their distribution is extensive and general, although Klein and Robinson failed to find them on the margin of the lips and in the glans penis. Their number is extremely large—estimated to be, for the entire surface, slightly over 2,000,000 (Krause, Sappey). They are most numerous on the palms and soles, where, according to Krause, from 2600 to 2700 exist in a square inch. They vary somewhat in size in different situations, being largest in the axilla and in the anal region. The larger coils sometimes show irregularly distributed constrictions and dilatations, and, according to Kölliker, the tubules of some of the large glands of the axilla exhibit a number of fork-shaped branching sacs.

SEBACEOUS GLANDS.

The sebaceous glands, known also as oil-glands, glandulæ sebaceæ, glandulæ sebiferæ, and hair-follicle glands, are racemose or acinous glands usually connected with or in close relation to the hair-follicle, and seated in the corium. They are also observed in regions where there are no hairs, as on the glans penis, inner surface of the prepuce, labia minora, and red border of the lips. Unna would designate the

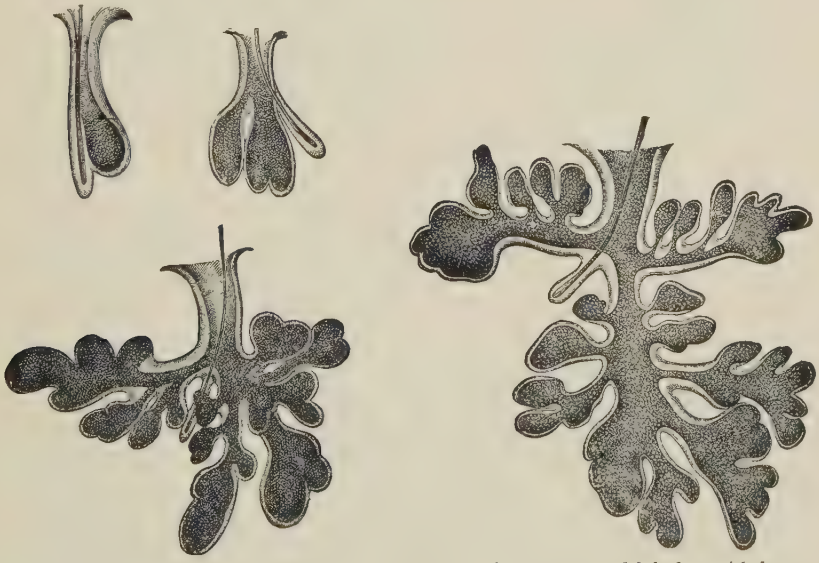

FIG. 14.—Sebaceous glands of the face—simple pouch to compound lobular, with lanugo hair and small or rudimentary hair-follicle, the largest from the nose (Sappey).

glands of these several regions as the "sebaceous glands of the mucous orifices." They are, therefore, to be found upon almost all parts, although they are absent on the palms, soles, and dorsum of the third phalanges. In connection with large hairs the gland is essentially an appendage of the hair-follicle, into which it empties; this is especially shown with the scalp-hairs. With small lanugo hairs, on

the contrary, the reverse appears to be the case, the glandular structure and duct being relatively much larger than the hair and follicle, as conspicuously noticeable in the nose-glands. The largest are found upon the nose, especially at the labionasal fold, the cheeks, eyelids (Meibomian glands), the areola of the nipple, the mons veneris, the labia majora, the scrotum, and about the anus. The glands found upon the penis and inner surface of the prepuce—Tysonian glands, unconnected with hair and opening upon the free surface—vary in development, and are somewhat inconstant, sparse, or numerous.

Although fundamentally the same in structure, sebaceous glands vary considerably in size and form. The simplest is a mere small

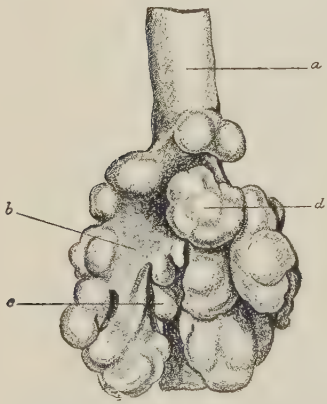

FIG. 15.—Model of sebaceous gland group of a scalp hair: *a*, Hair-follicle; *b*, lobulated gland; *c*, tubular gland; *d*, alveolar gland (Bauer).

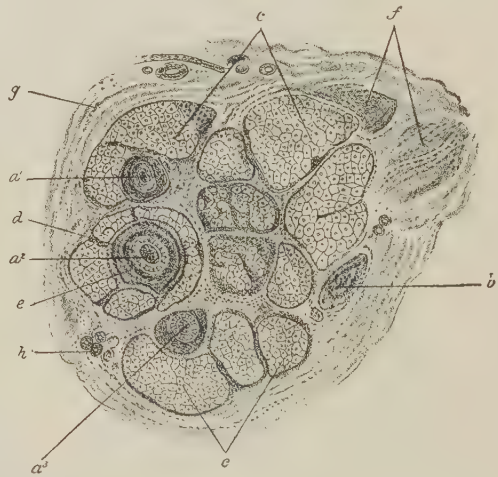

FIG. 16.—Cross-section of skin of scalp on a level with the sebaceous glands: a^1, a^2, a^3, Hairs; *c*, *c*, sebaceous glands; *d*, inner root-sheath; *e*, outer root-sheath; *f*, arrector pili; *g*, connective tissue; *h*, sweat-gland (× 30) (Rabl).

pouch-like body, and various forms from this up to one distinctly multilobular and racemose are to be seen, as shown in the accompanying cuts.

The gland-structure consists of a secretory portion and duct, the latter emptying between the surface of the hair and the inner root-sheath of the latter. The hyaline basement membrane of the gland is surrounded by dense connective tissue arising from the hair-follicle or from the corium, and containing blood-vessels, nerves, and lymphatics. Upon the basement membrane are seated several layers of epithelial cells, the outermost resembling those of the rete. In this layer the cells are cylindric and columnar; toward the inner portion they become larger and more or less cuboid or polyhedral, and contain fat-globules, the fatty degeneration of the cells taking place in the center of the cells; this is most noticeable in the cells of the innermost layer. The various lobules or acini empty into a common gland cavity, which is observed to contain fat-globules, fat crystals, and epithelial débris, and this finds final exit through the

excretory duct, which is also lined with epithelial cells, into the hair-follicle, or, where there are lanugo hairs, often more or less directly upon the free surface of the skin. The glandular product, together with the epithelial débris from the excretory duct, constitutes what is known as sebum or sebaceous matter. The so-called smegma, formed about the glans penis and inner side of the prepuce, is not at present believed to be the product of the sebaceous glands, but to be due chiefly to an exfoliation of the horny layer of the epidermis. It is not improbable, however, that both may be factors in its production. Not uncommonly a parasitic mite, the *acarus*, or *demodex folliculorum*, generally considered to be harmless, is found in the sebaceous gland, especially its duct, with its head usually toward the gland.

The first sign of the **development of the sebaceous glands** is usually noticed in the third or the fourth month of fetal life, and appears as a budding from the external root-sheath of the hair-follicle; primarily they consist of epithelial cells that, by multiplication and further projection downward, form the gland. They have a rich vascular supply, and are surrounded by a network of capillaries. Like the hairs, they appear first in the skin of the eyebrows and forehead, and spread over the trunk to reach the extremities last (Macleod).

THE HAIR.

Hairs are short or long, rounded or cylindric, horny formations derived from the epidermis, having their seat in obliquely directed pouch-like depressions in the corium, commonly known as the hair-follicles or hair-sacs. As a rule, but one hair is implanted in each follicle, but exceptionally two and even three hairs have been observed.

The hair varies considerably in different individuals, and especially in those of distinct nationality or type, the differences being due mainly to the degree of straightness or curl, caliber, length, and color (Duhring). The negro hair-follicle and its contained portion of the hair-shaft, according to the studies of Browne, C. Stewart, and Anderson Stuart, are much longer than in the white, and are remarkably curved, this latter feature, Anderson Stuart suggests, accounting for the curl in the projecting shaft. The hairs are very abundant, but their number varies considerably. On the scalp of average growth there are about 1000 to the square inch, approximately 120,000 to the entire region (E. Wilson). The hair of lightest color always shows the greatest number (140,000), whereas red hair is least abundant (90,000), the brown (109,000) and the black (108,000) occupying a middle position between these two extremes (Duhring). Owing to the direction of the obliquely set follicles, which bears some relation to the various planes of the surface, the hair-growth has various centers, and, as Eschricht has shown, exhibits in the arrangement of both the short and long hairs, curves and whorls.

Hairs are found in all regions except the palms, soles, backs of the last phalanges of the fingers and toes, lips, glans penis, and inner surface of the prepuce. They may be divided into three forms: (1)

Lanugo, or fleecy or downy hairs, which are short, soft, and extremely fine, as with those usually seen upon the face, trunk, buttocks, and limbs; (2) short, strong, or bristly hairs, somewhat thick, such as the eyelashes, the eyebrows, and those in the nares and in the outer auditory canal; (3) long hairs, of variable length from a few inches upward, and exemplified by the hairs of the scalp, beard, axillæ, and genital region.

Two parts of a hair are usually distinguished—the **hair-shaft**, or that portion exterior to the skin, and the **hair-root**, or that contained within the follicle. The hair-root is thicker than the shaft proper, and becomes more markedly so at its lower part, where it expands into a bulb-shaped body, known as the **hair-bulb**, which is seated upon and grasps the hair papilla. Both in its shaft and root a hair consists of an outer thin covering or cuticle, a cortical mass, and usually a medullary portion, or medulla.

The cuticle is a transparent membrane enveloping the whole hair, and composed of thin, non-nucleated imbricated lamellæ arranged in an overlapping fish-scale and shingle-like manner, with the free or outer portion, slightly elevated and pointing toward the distal end of the hair, giving it a serrated or reticulated appearance. The cortical substance or mass, or main body of the hair, is made up of delicate flat, fusiform, nucleated, firmly attached epidermal scales, which are so closely fused or agglutinated as to form narrow, elongated, spindle-shaped bundles of fibers; they show longitudinal striations, are more or less uniformly colored, and often contain, both within and between the scales, a varying amount of pigment-granules and diffuse pigment. The medulla, or medullary portion, in the center of the shaft, is not present in all hairs, being usually absent in lanugo, and most clearly shown, as a rule, in thick, short, and strong hairs. It extends from the bulb almost to the free end, often uniformly as a cord-like structure; sometimes, however, it is somewhat irregular or broken. It consists of epidermal elements, often pigmented, and frequently showing granules that were formerly thought to be pigment-granules and fat, but that, according to recent investigations, are now believed to be, in great part at least, air-vesicles.

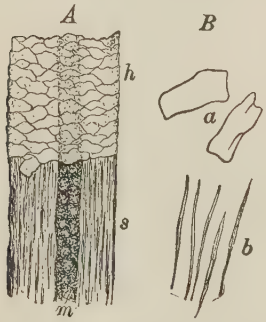

FIG. 17.—*A*, Human hair: the upper half of the figure represents the superficial horny cells (*h*) constituting the cuticle; the lower half (*s*), the fibrous structure of the cortical substance and *m*, the medulla. *B*, isolated elements of the hair: *a*, Cuticular scales; *b*, thin fiber-cells of cortical substance (Piersol).

The hair-root, or the part of the hair implanted in the skin, or within the hair-follicle, is, in its upper part, structurally the same as the outlying shaft. Toward the lower portion, or hair-bulb, however, the fiber-like character gradually disappears, the lamellæ becoming softer, and changing into spindle-shaped nucleated cells. Further down they are polyhedral in shape, and the lowermost, those about

the hair papilla, are cylindric. These cells resemble closely those of the rete, and often contain pigment-granules—so many, in some instances, as to constitute true pigment-cells.

In the deepest portion of the hair-bulb are found a variable number of stellate pigment-cells that are, presumably, as believed by Kölliker, Aeby, and Riehl (cited by Duhring), wandering connective-tissue cells from the hair papilla, and of importance in the function of pigment-formation.

The hair-bulb lies within either the corium or upper subcutaneous tissue, the lower part, in the stronger hairs, not infrequently extending into the latter. It is a club-shaped expansion, seated upon and embracing the hair papilla. It is surrounded by the inner root-sheath, or root-sheath proper, of the hair-follicle, which extends upward to the duct of the sebaceous gland. In transverse section the hair is of rounded or elliptic form, the latter being most pronounced in markedly curly hair, and least so in straight hair.

The **color of the hair** is due mainly to the varying amount of pigment-granules and diffuse pigment present in the cortex, or body of the hair, and the medullary portion. The presence of air, usually as air-vesicles, is also, doubtless, an important factor, especially in contributing toward light blonde, white, or gray hair. Indeed, according to Pincus, the presence of air in the cortical substance or in its outer portion may give the hair a whitish or grayish color, even though the central part be distinctly dark. It is presumably owing to a rapid evolution of air-vesicles that "sudden graying of the hair" (*q. v.*) is produced.

The first sign of the **development of the hair** is observed usually at the end of the third fetal month, and consists of a downward, cone-like or club-shaped projection of the rete, covered with the horny layer. According to Unna, this is first observed on the face, and not until toward the seventh or the eighth month on other parts. Macleod states that the earliest development is noted on the forehead and eyebrows, between the second and the third month, and on the back, breast, and abdomen, about the fourth month, reaching the dorsal aspects of the hands and feet between the sixth and the seventh month. This rudimentary formation is gradually surrounded by connective-tissue cells, extends more deeply, expands at its lower end, and grasps the papilla, which, in the mean time, has arisen from the corium. The young hair continues to grow, and after a time—about the end of the fifth month—its pointed tip perforates the cone, through the horny layer, and the hair becomes exposed. The embryonal or early hairs are always of the lanugo type, and devoid of medullary substance, having a small and short follicle, and usually a relatively large sebaceous gland. When a hair has reached its full term of existence it falls, and is replaced by a new hair formed around the old papilla, and whose growth has frequently started before the old hair has been entirely cast off, the latter often being pushed out by the new growing hair.

The term **bed-hairs,** so named by Unna, are those early or embryonal hairs, unprovided with papilla, that push out from the sides of shallow follicles from epithelial offshoots, and that fall out

and are supplanted by young papillary hairs, usually near the end of intra-uterine life or shortly after birth.

The embryonal hairs are shed in utero, beginning with the seventh or the eighth month, their place being taken by new hairs growing in the same follicle; and if this hair-shedding, or normal hair change, is not finished at birth, it completes itself in the first few months afterward. The long black hairs on the scalp sometimes observed at birth are in reality embryonal or lanugo hairs, the shedding of which has merely been postponed until after birth.

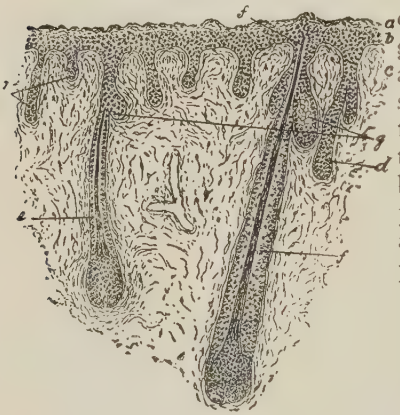

FIG. 18.—Section of skin of fetal kitten exhibiting hairs in various stages of development: *a*, Superficial layers of epidermis; *b*, rete mucosum, from which rudimentary hair-follicles extend into connective tissue (*c*) of the primitive corium; *d*, *d*, *e*, *f*, *f*, hairs in different stages of development; *g*, sebaceous glands growing from young hair-follicle (Piersol).

There is some difference of opinion as to the manner of hair growth. C. Heitzmann believes—and his view is shared by Professor Duhring—that the new growth takes place within the province of the root-sheath proper exclusively, being a product of the latter, the young hairs, as shown by Kölliker and Lang, forming around the old papilla.

Hair-follicle.—The hair-follicle or sac is the root-bed of the hair, and consists of an obliquely directed, pouch-like depression in the skin, into the central part of the base of which projects the hair papilla. The follicle proper is usually considered to include, in its strictest limitation, all that part of the sac below the point of entrance of the sebaceous duct, which is the narrowest part, or neck of the follicle; the outlet above this, or the mouth of the follicle, is funnel shaped, and the part below expands somewhat broadly down to the base. The sheaths of the follicle, which is essentially a depression from the surface, practically correspond to the epidermis and corium, the former representing the inner coat and the latter the outer coat (C. Heitzmann). The accompanying longitudinal and transverse sections of the follicle and inclosed hair show the construction and the different layers of both of these structures.

The **dermic** or **external coat,** which gives substantial and firm form to the follicle, consists of bundles of connective-tissue fibers running parallel to the follicle, with some elastic fibers, occasional muscular fibers from the arrector pili, circularly disposed, and scanty fat-cells. The outermost part (external layer) is richly supplied with blood-vessels and some medullated nerve-fibers; the middle layer showing some capillaries, in the main transversely disposed, extends into the papilla, and bears some resemblance to muscular tissue—so much so that there is a difference of opinion regarding this point. The inner layer (internal layer) of the dermic coat, also known as the *hyaline*

or *vitreous membrane* or *glassy layer*, is of homogeneous structure, thin at the upper portion of the follicle, becoming thicker as it approaches the base, and thinning again as it nears the papilla.

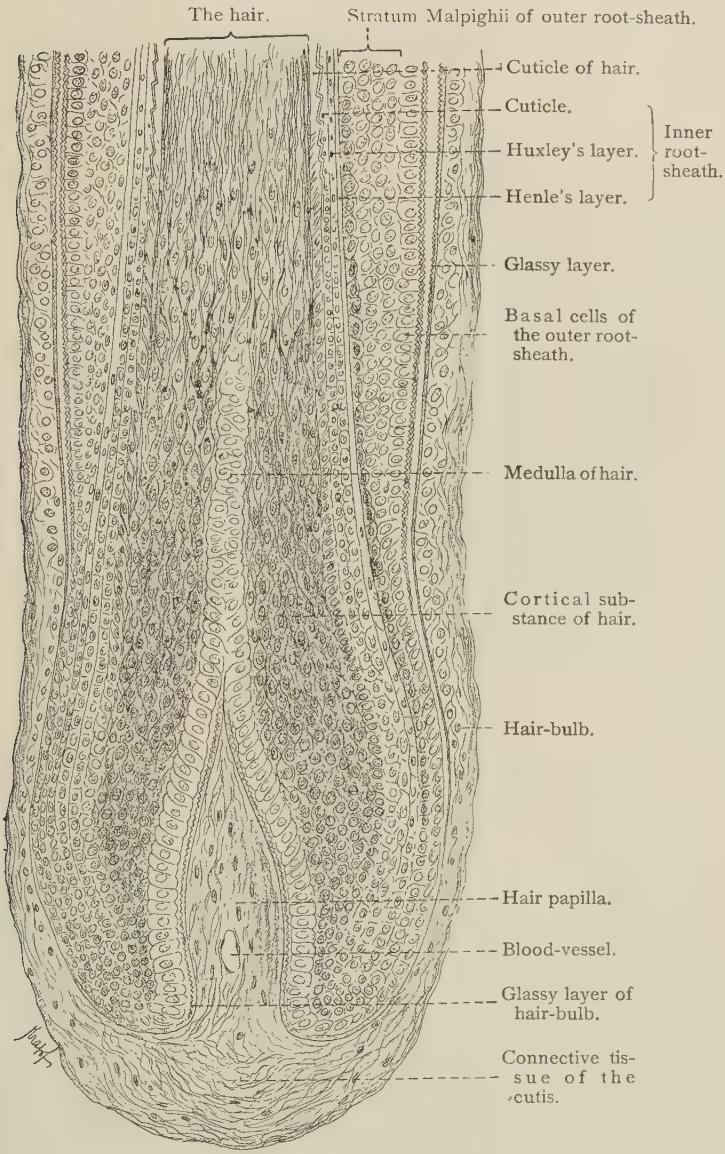

FIG. 19.—Longitudinal section of human hair and its follicle (× about 300) (Böhm and Davidoff).

The **epidermic** or **inner coat**, more generally known as the *outer* or *external root-sheath* (Professor Duhring designates this the *epidermis of the hair-follicle*, and Unna, the "*prickle-cell layer of the hair-folli-*

cle"), consists essentially of a turning inward of the rete, which, contiguous to the inner or vitreous membrane of the dermic coat, dips downward, lining the whole follicle, thinning at the base and into the neck of the hair papilla as one or two rows of cells, and merging with those of other layers. From this sheath the epithelial budding or pouch is produced, which develops into the sebaceous gland. It is thickest at the middle of the follicle, and is several times thicker than the root-sheath proper.

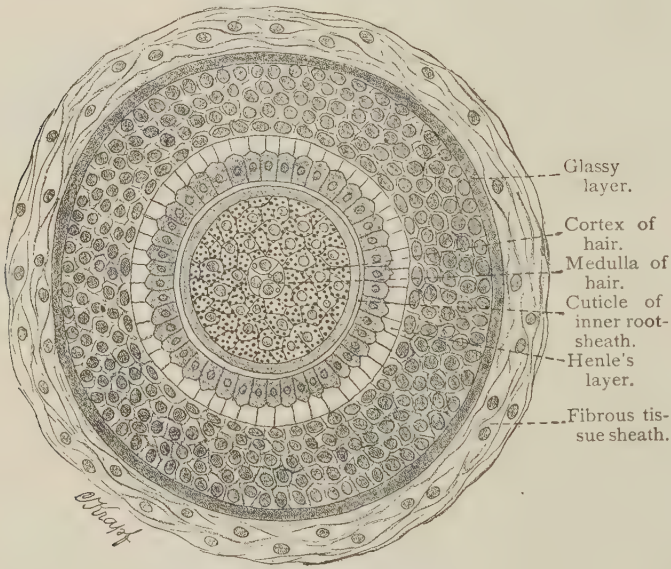

FIG. 20.—Cross-section of human hair with its follicle (× about 300) (Böhm and Davidoff).

The **root-sheath proper of the hair** (Unna and Kölliker), more generally known as the *inner* or *internal root-sheath*, has two layers—an outer, or sheath of Henle, and an inner, or sheath of Huxley. It arises from the cylindric cells covering the hair papilla (Robinson). As Macleod states, these layers are "only parts of a single layer, so modified by differences in tension and pressure, and by the presence of more or less keratohyalin in their cells, as to suggest that they have had a different origin." The former consists of pale and finely granular polyhedral, somewhat elongated, non-nucleated epithelia, or with indistinct nuclei. In the inner sheath the cells are coarsely granular and nucleated. At the base of the follicle the sheath doubles on itself and surrounds the papilla; the cells are soft, broader, polygonal, and rounded, contain granules of keratohyalin, and fuse with contiguous layers of the hair, forming a broadened knob—the hair-bulb.

The root-sheath proper is covered with a closely adherent cuticular membrane, with overlapping, shingle-like cells directed downward (Ebner, cited by Duhring), the reverse of those of the hair cuticle, so that the scales of these two contiguous layers interlock. As has

been stated previously, the hair is believed to be a solid elongation of this root-sheath.

The Hair-papilla.—This is a club-shaped or spheric formation, arising from the corium as a narrow neck-like projection or pedicle, and expanding upward into the hair-bulb, by which it is surrounded. It is about twice as long as it is broad, its breadth, according to Robinson, being in direct proportion to the length of the hair. It is composed of a delicate fibrous or myxomatous connective tissue, devoid of fibrillæ and elastic fibers, freely supplied with colorless or pigmented connective-tissue corpuscles, and containing a number of blood-vessels, with a loop in its apex similar to that of the papilla of the corium. Knowledge as to the nerve-supply of the hair-papilla is somewhat indefinite. Robinson states that non-medullated nerve-fibers are to be found within its structure; and according to Merkel, Ranvier, and Bonnet, nerves and nerve-endings are observed in abundance close by in connection with the follicle and its membranes.

THE NAILS.

The nails are horny, elastic, transparent, shield-shaped, plate-like formations, derived from the epidermis, imbedded in the corium on the dorsal aspect of the distal phalanges of the fingers and toes. They are moderately curved downward from side to side, and less decidedly from the root, or posterior part, to the anterior or free edge.

In substance a nail proper corresponds to the horny layer of the epidermis, and differs from it only in being harder and firmer, with a soft layer beneath, corresponding to the rete, constituting in reality a part of the nail-bed. According to Bowen, it is a modification of the stratum lucidum. It is made up of separate strata, composed of polygonal cells, or little plates, of which the lower ones exhibit indistinct nuclei, the outermost resembling epidermal scales. Sometimes, in the intercellular spaces, and also in the interior of the plates, small or large air-vesicles occur, and produce by reflected light the so-called "white spots," "gift spots," etc.

Various names are used to designate different portions of its substance, and the couch or surface upon which it grows and rests.

The nail (*unguis*) is divided into two parts—the uncovered part, or **nail body**, and the imbedded portion, or **nail-root.** The former is usually spoken of as the nail proper.

The top surface of the nail is smooth, horny, and glossy; the under surface shows a number of longitudinal ridges, which, with the postero-anterior papillary ridges of the underlying corium, form an interlocking, giving the nail a much firmer seat than if the under surface were smooth and even. The nail is imbedded posteriorly, and to some extent laterally, into a depression between the matrix and overlapping skin, known as the **nail-groove,** which also extends on upward along the free side; the overlapping portion of skin is known as the **nail-fold,** or **nail-wall,** and the thin, film-like layer of cuticle extending forward from the fold over the body of the nail posteriorly for a short distance is the **eponychium,** or **nail-skin,** whereas the epidermis bordering the whole nail is called the **perionychium,** and that underlying the body of the nail upon which it rests, the **hyponychium.**

The term **nail-bed** is usually employed to designate that part upon which the uncovered portion of the nail rests, although in reality it signifies the whole nail couch; that part, however, beneath the nail-root, or imbedded portion of the nail, is known as the **matrix**. These two parts of the nail couch are separated by the **lunula**, a more or less convex line or half-moon-shaped area at the base of the uncovered portion, and that is most distinct on the thumb, although usually well defined on the other fingers; it is often ill defined or absent on the toes, although in many instances it becomes visible after the nail-fold has been pushed back. There is some difference of opinion concerning its formation. According to Hebra, it corresponds to a part of the matrix or nail couch devoid of papillæ. Ranvier, Toldt,

FIG. 21.—Nail (longitudinal section) (× 100): *H*, Nail-plate corresponding to horny layers; *R*, *R*, rete mucosum; *P*, *P*, papillary layer; *B*, bed of nail; *E*, epidermis; *D*, derma with injected blood-vessels; *N. S*, nail-skin; *N. F*, nail-fold; *N. G*, nail-groove (L. Heitzmann).

Duhring, Bowen, and others ascribe it to opacity or decreased transparency of the nail-tissue at this place. The latter seems to be the correct view; the opaque elements are, according to Henle, Duhring, and others, transitional cells thickly covered with points that by reflected light appear whiter than the granular cells. Macleod thinks it is probably due to the presence of refractive keratohyalin granules in the transitional cells.

The nail-bed is formed of the rete, corium, and subcutaneous tissue, and, in the region of the root of the nail, at the matrix, there is a gradual transformation from the epithelial cells of the rete into those of horny character, resulting in the production of the hard nail substance itself. The rete layer of the epidermis constitutes the germ-layer of the nail or the matrix, and this is the only part of the nail couch that is concerned in generating the nail. The subjacent papillary layer of the corium is highly developed, especially the papillæ of the matrix. The papillæ are shorter, broader, and more closely set in the matrix than anteriorly, and in the former region project forward; they are arranged in parallel rows longitudinally disposed, forming comb-like ridges that tend to converge symmetrically in their posterior division.

The subcutaneous tissue underlying the corium contains no fat. The ascending connective-tissue fibers arise from the periosteum of the last phalanges, and extend in a brush-like manner toward the nail-root, constituting the retinacula unguium of Kölliker. The nail-bed is highly vascular, being well provided with blood-vessels, especially the papillæ of the matrix. The nerve supply is not so abundant as that of the surrounding skin.

The **development of the nail** begins in the third fetal month as a fold in the epidermis. Before the end of the fourth month the entire fingers and toes are covered with a continuous layer of "granular and bladder cells," representing, in the region of the nails, a persistent and thickened portion of the epitrichial layer of the young embryos, and in which region Unna has designated it the eponychium; beneath this the nail makes its appearance, formed from peculiar cells in the upper part of the rete containing deeply stained granules of kerato-hyalin (Bowen). During the fifth month, Bowen further states, the epitrichial covering of the nail, or the eponychium, is cast off from the

FIG. 22.—Section through dorsal portion of ungual phalanx of four-months'-old fetus: *c*, Nail-bed; *m*, mucous layer; *e*, upper strata of mucous layers, showing cells with eleidin-like granules; *n*, nail lamellæ; *ep*, eponychium (Kölliker).

body of the nail, and the free surface exposed; whereas, at the edges the bladder and granular cells are heaped up in great numbers in a ridge-like manner, and, undergoing a process of keratosis, form a part of the normal stratum corneum.

Nail-growth varies somewhat in different individuals and in different nails; it is more rapid in the young and during the summer, and slower in the nails of the toes than in those of the hands. Exposure of the latter to light and air has probably a determining influence. According to Moleschott, the difference of rapidity in summer is much more noticeable in the nails of the right hand. Berthold states that the growth from the lunula to the free edge of the fingers requires an average of about four months, and Dufour's observations practically agree with this. Quain gives a growth of $\frac{1}{32}$ of an inch in a week. Moleschott found, from observations on his own person, that the nails of the hands and feet together produce about 9.2 milligrams of nail substance in a day, equivalent to about $3\frac{1}{2}$ grams a year.

PHYSIOLOGY.[1]

The skin is to be viewed as a complex organ with complex functions. It is one of the four emunctories of the body, and probably in this function not unimportant, although it is generally so considered.

To some extent a partial suppression of the excretory action of one of these four—intestinal tract, kidneys, lungs, and skin—is made up by compensating activity of the other three. An absolute suppression of the functions of the skin might, however, lead to untoward or grave results, although the experiments made from time to time by Socoloff, Ellenberger, Senator, and others, cited by Ziemssen, of varnishing the cutaneous surface or covering it with some impermeable substance, are somewhat conflicting, and yet too scanty to warrant definite conclusions. In rabbits, varnishing the surface after removing the hair is sooner or later followed by death, preceded by symptoms of acute febrile disease, with subsequent diminution in temperature; nor is it necessary that the entire surface be covered, but the more completely it is covered, the more rapid is the issue. In other larger animals the effects are apparently less marked and slower; and the experiments of Senator seem to show that man is still less affected than the latter, the effects in his experiments on adults being practically nil.

The well-known instance of the fatal result quickly following the gilding of a boy at the installation of Leo X. is often quoted, and apparently proves the contrary; but both Senator and Ziemssen are inclined to doubt the relationship of cause and effect in this case, from the fact that death followed so rapidly, whereas in most animal experiments the result has been observed to be slow.

The physiologic functions of the skin are to be considered chiefly from the standpoints of its offices as a protective, sensory, respiratory, heat-regulating, and secretory organ.

Protective Function.—The several layers,—epidermis, corium, and subcutaneous tissue,—together with the nerves, glands, and appendages, act not only as an elastic incasement of the body, but also as a guard against injuries of various kinds from without, and a barrier to too rapid loss of liquids and heat from within. The corium and subcutaneous tissue, especially the former, owing to its firmness, high elasticity, and flexibility, and the latter to its loosely meshed character and adipose layer, are well adapted for protecting the underlying structures, muscles, nerves, and blood-vessels from external pressure, blows, and other possible damaging traumatic agencies.

The epidermis, on account of its thickness and the great impermeability and insensibility of its corneous layer, serves as a protection to the injurious effects of high and of low temperature and of the action and absorption of many caustic and poisonous liquids and other deleterious substances. The oily coating furnished by the glands is also an important aid to this end, and this oily coating and the horny layer together are chiefly concerned in the prevention of too great evaporation of water from within. The hair of the head is

[1] In addition to the several valuable sources of information consulted, mentioned on page 19, I also desire to acknowledge my indebtedness to Ziemssen's paper on Physiology, in the *Handbook of Skin Diseases*, edited by him.

an additional protection to this important part, guarding the brain from the effect of extremes of temperature and from mechanical injury.

Sensory Function.—The surface of the skin is extremely sensitive both as to touch and general sensation, due to its abundant nerve supply. As shown by the studies of Landois, Goldschneider, Weber, Couty, and others, the sensory function is not uniform on all parts of the body, nor to all influences or agencies on the same part. The temperature or thermal sense especially varies in acuteness in different localities, and is responsible for illusions, according to Landois, as to other properties of material substances—as, for example, a warm object seeming lighter than a cold one of equal weight.

According to the experiments of Blix and Goldschneider, following the theories of Müller and Helmholtz, affirming the specific energy of the sensory nerves, the skin has a separate nerve apparatus for heat, for cold, and for pressure; their experiments, made independently of one another, showing that sensation does not seem to depend upon the kind of irritation, but on the specific property of the nerve-endings or the nerve-fibers themselves. Their investigations indicate, therefore, that the points on the skin sensitive to pressure, heat, and cold are severally distinct.

The tactile sensibility, or the sense of touch, through which are made known the size, form, and other characters of bodies, varies greatly in intensity in different parts; it is the most highly developed in the finger-tips, where the tactile corpuscles and sensory nerves are most numerous—and these are most abundant where the papillæ are found in greatest numbers. It is dullest in the middle of the limbs. As acutely developed as it naturally is, it is capable of much higher cultivation in the line of its most frequent employment, as when it is called upon to aid in replacing the sense of sight, as in the blind. Goldschneider has shown that the tactile sense has two kinds of sensitive nerves, and that the tactile corpuscles, which are usually considered to be of paramount importance in this function, are to be looked upon mainly as a protective organ to the nerve-endings. Landois also holds the opinion that two kinds of nerve-fibers, functionally distinct, are found in the sensory nerves—pain, or sensitive fibers, and tactile, or touch-fibers.

The **vasomotor nerves**, although not involved in the sensory function, may here be briefly referred to. The non-striped muscles of the arterial system are well supplied with these vasoconstrictor nerves, and as these are concerned in the constriction and dilatation of the cutaneous vessels, must have an important bearing in many pathologic conditions, not only owing to the diminished or increased blood supply, but also from the effect of this latter upon the temperature of the part. They are brought into action in two ways: either from a stimulation or depression of the governing centers in the medulla oblongata, and possibly in the cord, or from some action exerted through the circulatory fluid upon the peripheral endings.

Although we often refer to an affection of the skin as being a trophoneurosis, we know little about the existence and mode of action of the so-called **trophic nerves**; the nutrition of most of the peripheral parts, as shown by Charcot and others, is governed or influenced by the spinal cord (Duhring).

Respiratory Function.—The respiratory function of the skin, as compared to the lungs, is, of course, insignificant. It is similar to the latter, however, in the exhalation of water and carbonic acid, and the inhalation or absorption of oxygen, although the amount of carbonic acid and oxygen respectively given off and taken in is doubtless small. Seguin states that the amount of loss taking place through the skin daily is one sixty-seventh of the body-weight. According to Scherling, 10 grams of carbonic acid are given off in twenty-four hours, whereas Aubert makes the quantity much smaller—3.9 grams. Compared to the lungs, quoting from Kaposi, carbonic acid exhalation is $\frac{1}{220}$, and oxygen inhalation $\frac{1}{180}$. Gerlach gives the latter a slightly larger proportion—$\frac{1}{137}$. Water is, however, given off in large quantities. There is considerable doubt as to exhalation of nitrogen and ammonia, even as to small amounts. The mode of egress is probably through the sweat-glands; however, it is not impossible that direct transpiration of carbonic acid and water from the capillaries of the papillæ also takes place, although it is known that the horny layer is scarcely penetrable by fluids, and the exhalation could hardly be appreciable, unless, as Kaposi suggests, it might occur between the crevices of the epidermic cells, which are connected with the lymph-spaces of the rete cells.

Absorption by the skin can be considered in connection with the respiratory function. As previously stated, the epidermis forms practically an impermeable barrier to the absorption of liquids and also to solid substances, but is less resistant to gaseous and volatile bodies. The natural oily coating of the skin is also an additional obstacle to penetrability. Sources of error in the investigation of these matters are so readily possible that there is still much to learn before positive and definite conclusions can be formulated. It is known, however, that water, and substances dissolved in water, are not absorbed by the epidermis. The same may be stated, but probably somewhat less strongly as to some substances, of alcoholic solutions. The evidence as to alcoholic and watery solutions applied as sprays is somewhat conflicting, although, as a rule, unless the contained substance is gaseous or volatile, no absorption takes place. Occasional exceptions have been noted as to substances in solution and to a few solids or semisolids, but what the favorable conditions are is unknown. A defective epidermis, or a skin freed of its oily coating and outer hardened horny cells by washing with soap and water, would lessen the natural protection against the absorption of such solutions, and it is not improbable that the various exceptional substances which have been noted to be absorbed, first change the character, and modify or damage the upper corneous cells, as Ritter's researches seem to indicate. Certainly tar, iodin, arsenic, sulphur, and a few other substances are capable of being taken up, even though not applied in ointment or oily form. Many volatile materials, as already intimated, are readily absorbed to a variable degree, and Röhrig, cited by Duhring, has remarked that such volatile substances are those that act upon and destroy the continuity of the epidermis.

The matter is somewhat different, however, with substances dissolved or suspended in oils or fats; some substances, when so applied, are taken up, but for the most part, only when well rubbed in. All

substances are apparently not absorbable, certainly not equally so, even when applied in this manner, although Lassar's experiments upon rabbits show, in general, a ready absorbability when so applied. The most readily absorbed is mercury in the form of mercurial ointment; some of its salts incorporated in fat are likewise readily taken up, although, as a rule, not so freely. The ready absorbability of this drug is thought by some to be due to the fact that it may undergo vaporization, gaseous or vaporized substances, as already stated, usually being more readily absorbed. Substances applied by means of vapor baths are likewise more readily taken up, but with these also there is a good deal of variation, and absorption will be much prompter and more decided if the skin had been previously washed with soap and water, for reasons just given.

It is believed, however, that absorption usually takes place through the gland-ducts, most experiments bearing upon this point naturally having been made with substances dissolved or suspended in oils or fats, and for the most part with mercury. The investigations of Neumann, Auspitz, and others bear out this view, in which Duhring, Robinson, and many others concur, although Rindfleisch, Fleischer, Voit, and others contend that the particles pass through the epidermis. The former is doubtless the correct explanation, and this is in accord with Ehrmann's observations as to the introduction of dissolved substances by means of cataphoresis. According to Wasmuth's experiments with different bacteria, quoted by Louis Heitzmann, the port of entrance, for micro-organisms at least, appears to be between the hair-shaft and the sheaths, and not by way of the sebaceous and sweat-glands. In furuncles, etc., the organisms probably enter in this manner, aided usually by friction, as on the back of the neck, from the collar-band. In fact, the mechanical element of rubbing is an important factor in promoting absorption by the skin, as it is believed with mercury that the minute portions or globules of the substance are thus forced into the ducts, where absorption is favored or where it first undergoes chemical change, rendering it more easily absorbable.

Heat-regulating Function.—The skin has an important function in regulating the amount of heat given out by the body through evaporation, radiation, and conduction, and thus exercises a controlling influence in maintaining an equable heat of the blood. In this function the epidermis, more particularly the horny layer, plays an important rôle. It is a bad conductor of heat, and limits, by this property, too great a loss of heat from the superficial blood-vessels, and by its firm, unyielding character a certain amount of pressure is directed against the underlying capillaries, preventing overfilling and consequent heat-loss. The vasomotor nerves also have an active and prominent part in this function, acting as a regulator of the cutaneous blood supply by reflex impressions from without, and probably also in response to excessive or reducing heat-producing processes within. A cold atmosphere without acts upon the cutaneous fibers, and these sentinels, thus apprised, bring about, through the agency of the muscular fibers of the blood-vessels, a contraction of the capillaries, in this manner directly reducing heat-loss by lessening the

volume of surface blood, and indirectly by diminishing the supply to the sweat-glands, with the consequent reduction or temporary suppression of this secretion, thus preventing or lessening the chilling that results from its evaporation. On the other hand, the reverse takes place when there is an external warm or hot atmosphere or an overproduction of heat within—the vessels relax, the integument becomes full-blooded, the sweat-glands secrete freely, and there results, in consequence, a compensating loss of heat by radiation, conduction, and evaporation, and in this manner chiefly an equilibrium is maintained. But the changes and vicissitudes of climate are so variable that animals exposed are still further protected by a hairy coating of sufficient growth for the season, whereas man, for the same reason, is obliged to supplement the natural principle of heat-regulation by wearing apparel of different thicknesses.

The Secretory Function.—The sweat- and sebaceous glands are secretory glands of the skin, and are of functional importance to this organ, keeping it lubricated and soft, and playing an important part in the regulation of an equable heat of the blood. In addition to this office, however, they have also another function, that of excretion, removing some of the deleterious or used-up products from the body. In the latter function the sebaceous glands probably have an insignificant or minor rôle.

Sweat Secretion.—Sweat is secreted in the coil or gland proper, finding its way to the surface through the duct. It is also not impossible, as Ziemssen states, that some sweat is secreted from the lymph-spaces directly through the sudoriferous ducts. While more or less constant, ordinarily it escapes by evaporation as rapidly as it is produced, so that its presence is not perceived—*insensible perspiration;* if, for any reason, however, their function is increased, as the result of exercise, work, or heat, the secretion is formed much more rapidly than it vaporizes, and collects on the surface of the body in the form of drops or a continuous layer—*sensible perspiration.* In some parts of the body the secretion is more profuse than in others, due usually to the presence of larger and more numerous glands, or to increased heat of the part; this freer secretion is especially noticed on the palms, soles, face, neck, axillæ, and genitocrural region. The amount normally excreted in the twenty-four hours varies somewhat, depending upon the surrounding temperature, the average being about two pounds—according to Seguin, one and one-half to two, and according to Röhrig, one pound nine ounces troy. The amount can, however, be enormously increased if desired, as, for example, by active exercise, the drinking freely of liquids, by hot baths, and by taking certain diaphoretics, particularly pilocarpin—with the last much more markedly when the individual is kept thickly covered with clothing, blankets, or similar material, and is given warm liquids. On the other hand, inactivity, scanty covering, abstention from drinking freely of water or other fluids, and certain drugs, especially atropin, materially limit the amount. The effect of external heat or cold, either of natural or intentional production by scanty or overthick clothing, etc., is also shown by interchangeable activity of the sweat-glands and kidneys. In summer or during warm weather the skin normally acts freely, and the kidney elimination is relatively reduced,

whereas in cold winter weather, when the general surface is chilled or cool, the perspiratory glands are inactive, and there is a compensatory increase in the amount of urine passed. The nervous system is also an important factor—the so-called "cold sweat" from fright is a familiar example of this influence; in fact, the sweat secretion is especially dependent upon the influence of the nerves, the centers of which are situated in the spinal cord as far up as the medulla oblongata, which latter, according to Luchsinger, contains a general center.

Increased activity is, as with all glands, usually accompanied by dilatation of the capillary blood-vessels, but although there is a close connection between the nerve-fibers that control sweating and vasomotor fibers,—which Landois believes are together in the same nerve-trunks,—the former may act independently of the latter, as shown in the instances where there is increased sweating, even though the skin is pale and the circulation depressed.

The composition of sweat is somewhat complex, although water forms about 99 per cent. of the whole secretion. It contains sodium chlorid, urea, volatile fatty acids,—acetic, formic, butyric, propionic, caproic, and caprylic, in variable quantity,—and small amounts of neutral fats, palmitin and stearin, and cholesterin. There is also a trace of earthy phosphates and sodium phosphate.

Ordinarily, sweat is a clear, watery liquid of saltish taste, with a variable odor, substantially the same in some individuals, but slightly or markedly different in many others; the odor varies also in different regions of the same person. It has an acid or an alkaline reaction, according to circumstances; it is generally considered to be normally acid, but, according to the observations of Luchsinger and Trümpy, the acidity would seem to be due to the admixture of sebaceous matter, as they found that in the palms of the hands, where there are no sebaceous glands, it is alkaline; and also of this reaction on other parts after the skin is carefully freed of sebaceous secretion. This appears to be further corroborated by Heuss, who found that as the sweat becomes profuse by the administration of diaphoretics the reaction is neutral and alkaline; this was also noted by Luchsinger and Trümpy in profuse sweating from natural causes—in short, the acidity due to the sebaceous admixture is neutralized or overcome by the alkalinity of the increased sweat secretion, although Heuss does not put this construction upon his observations, and considers the sweat normally acid in individuals when at rest.

The belief foreshadowed by the observations of Simon, Krause, and Kölliker that, in addition to the secretion of sweat as ordinarily understood, the coil-glands also secrete fat for the lubrication of the skin, has been substantiated through the careful observations and investigations of Meissner and Unna, and this view is now generally accepted. This is readily recognizable in the palms of the hand, the integument here being kept soft and supple by oily lubrication produced by the coil-glands.

Sebaceous Secretion.—This, the product of the sebaceous glands, known as sebum, or sebaceous matter, is, in its purest or normal physiologic state, a fluid or semifluid fat, especially within the glands, which, becoming somewhat firmer in the ducts, passes out insensibly, lubricates the hairs and epidermis, without giving a

perceptible oiliness to these structures. In addition to this function, which keeps the hairs oiled and the skin soft and pliable, the imperceptible oily coating of the skin serves to prevent too great evaporation from the surface, and to guard against the effects of long-continued action of moisture, as well as probably to aid in protecting against external infection. As ordinarily observed, it consists of cast-off nucleated granular epithelial cells, fat-globules, fatty matter, débris, and cholesterin crystals; and, chemically, of water, palmitin, olein, palmitic and oleic acid, saponified fats, cholesterin, a casein-like albuminoid, and inorganic salts, such as phosphates and chlorids. In sebaceous matter is frequently found the microscopic mite, the acarus, or demodex folliculorum, usually considered harmless. There are, however, in the amount and consistence of the secretion, many variations within the limits of apparent health. To some extent, too, it varies according to the individual and also on different parts of the body. It is usually more abundant where the glands are largest and most numerous. Sometimes, especially where the glands are large and probably only in what must be considered as a pathologic state, the secretion collects in the glandular orifices as a tallow-like mass, taking a worm-like form when pressed out; or it may be produced in considerable quantity and be of somewhat thick, mush-like consistence, exuding on the surface as a distinct oily or greasy coating. In these conditions, observed usually about the nose, there is generally associated a perceptible gaping or patulousness of the duct outlets. Such abnormal or excessive secretion is most commonly noted between the ages of fifteen, or puberty, and twenty-five, when the sebaceous glands are especially active.

On the scalp, even in physiologic states, if the secretion is allowed to collect indefinitely, the parts being washed only at long intervals, and only carelessly brushed and combed, it tends to collect in minute, thin, greasy scales, producing a slight pseudoseborrheic aspect. In fact, in the seborrheic secretion the difference between a physiologic and a pathologic process, as Professor Duhring states, is often ill defined.

The exact mechanism of the sebaceous gland secretion is not fully understood, and the part that the nerves play, if they play any, is not known, although this observer (Duhring) believes this secretion, as in the case of that of the sweat, to be under the control of the nervous system, and subject to variations. It is probable, as Bowen suggests, that it is increased by dilatation of the blood-vessels and by an increase in the temperature of the skin. A warm external temperature perceptibly increases the oiliness of the skin, but whether this increase is a product of heightened action of the sebaceous glands or of the sweat-glands, or of both, is not definitely known. The secretion is, however, doubtless a continuous one, though probably somewhat fluctuating. It is generally accepted as consisting of a fatty degeneration of the epithelial cells, filling them with fat, and the subsequent rupture of the cell-wall and escape of the oily matter to the surface, the evacuation being principally, if not wholly, due to the contracting action of the arrectores pili muscles, which skirt one side of the gland structure.

GENERAL SYMPTOMATOLOGY.

A DISEASE of the skin is made known by integumentary structural lesions visible to the eye and usually appreciable to the touch, and by certain sensations emanating in its tissues, recognizable only by the patient, and having no outward sign. The former are known as objective symptoms, and are to be found with but few exceptions in all cutaneous affections; the latter, as subjective symptoms, which are usually associated with structural lesions, but which also, like the former, may exceptionally, as in pruritus, constitute the sole symptomatology of the disease.

Objective symptoms speak for themselves, and constitute, therefore, the foundation upon which our knowledge of diagnosis must be built—in some instances, conjointly with an examination into the histologic features, history of the disease, and other factors. Subjective symptoms, while sometimes of valuable aid, are often unreliable, owing to the fact that they are only under the cognizance of the patient, and therefore subject to exaggeration, undervaluation, and misinterpretation, according to the temperament, nervous susceptibility, intelligence, and honesty of the individual.

While these two classes of symptoms alone constitute the semeiology in most dermatologic cases, in a small minority the symptoms are not limited to the integument itself; in some instances an affection of the liver, kidneys, stomach, or nervous system is present, but in the majority of such cases the eruption is merely an accidental consequence of such, and not an associated symptom of some general underlying pathologic process. Such diseases, it is true, may bear an etiologic relationship, although it may not be a direct one.

The constitutional symptoms usually observed in connection with some cases do not possess any distinct characteristics, and even in those diseases in which they may occasionally be observed, as in erythema multiforme, they are extremely variable as to degree. In other instances, as in the later stages of granuloma fungoides, leprosy, and the like, the ensuing systemic symptoms are not so much a part of the disease itself as a consequence of the resulting septic infection which commonly occurs.

Subjective Symptoms.—Subjective symptoms consist of a feeling of heat or burning, tingling, pricking, stinging, formication, itching, and pain. Disturbed sensation, such as diminished and heightened sensibility, designated respectively anesthesia and hyperesthesia, also to be considered in this class, are occasionally noted. Pain is a rare, or at least an uncommon, symptom, but is met with in such affections as boils, carbuncles, in some ulcerations, especially of the deeper kind, and may be of a burning, aching, boring, or shooting character. The neuralgic pain frequently associated with the development of zoster is an example of the last named. Shooting and darting pains are also of common occurrence in some stages of leprosy. In many skin affections, however, subjective symptoms are wholly wanting.

Itching, or pruritus, is, however, the most frequent symptom com-

plained of, and is present in a variable degree in many diseases of the skin. It is a particularly troublesome one, as a rule, in eczema, and especially in the papular and vesicular types, although present in all varieties—sometimes slight, at other times severe, almost constant or paroxysmal. In urticaria, dermatitis herpetiformis, scabies, pediculosis, and some cases of psoriasis it is also present usually to a disturbing degree. In occasional instances it exists independently of any visible lesional symptoms, constituting the malady known as "pruritus," in which it is often intense. Itching varies in character, as well as in degree, sometimes being more of the nature of pricking sensations, tingling, and biting. In other cases it may consist of the sensation as if insects were crawling in the skin—formication. It is probably due to various causes acting upon the peripheral nerves, such as an irritant operating or gaining entrance from without, as in certain of the parasitic diseases, an irritation from some general toxic substance from within, as in jaundice and some instances of uric acid saturation, and also from the direct action of local inflammatory processes, either through pressure on the nerve filaments or through their irritant products.

Objective Symptoms.—The varied nature of the pathologic processes which take place in the skin, with the modifications influenced by the peculiar character of its anatomic structure, gives rise, as might be supposed, to various and diverse structural alterations which produce the cutaneous symptoms known as the elementary or primary lesions. Each variety of lesion has characteristics that serve to distinguish it from the others, although there be much diversity as to size, shape, color, and other features, and some may show a transition stage verging into another form, as a papule into a vesicle, a vesicle into a pustule, and so on. These elementary or primary lesions, as the qualifying term signifies, are the objective lesions with which cutaneous diseases begin. Even if the eruption, as a whole, has undergone changes, the component individual lesions losing their elementary characters in the coalescence or massing that often ensues, still, here and there, as a rule, may be found some that throw light upon the initial features and materially aid in diagnosis.

The elementary lesions may continue as such, or may, as stated, undergo modification, either from accidental or natural change or from extraneous causes, and pass into what are known as the consecutive or secondary lesions. These are the two divisions into which the objective symptoms can be conveniently and naturally placed, and the various kinds of lesions of which these two classes are composed must be clearly understood, as a knowledge of their appearance and nature is of essential importance for the intelligent study and comprehension of the various cutaneous diseases. A few lesions not readily classifiable under the subdivisions usually made, such as horns, some warts, the "burrow," or "cuniculus," produced by the itch-mite, etc., will receive sufficient attention in considering the diseases which they represent or of which they may form a part.

ELEMENTARY OR PRIMARY LESIONS.

Macules.—*Synonyms.*—Spots; Erythematous spots; Maculæ; *Fr.*, Taches; *Ger.*, Flecke.

Macules are variously sized, shaped, and tinted spots and discolorations, or circumscribed alterations in the color of the skin, without, as a rule, appreciable elevation or depression.

They may constitute a part or the whole of the eruption, or may simply be an early stage or an associated symptom in mixed cases. They may also be congenital or acquired, evanescent or permanent, scanty or abundant, and may or may not disappear under pressure. Depending upon the character and origin of the lesions, there may or may not be associated itchiness. In size they vary from that of a pin-point to that of the palm or larger, and while commonly, especially the small macules, more or less rounded or oval, they are not infrequently somewhat irregular in outline; they may have a sharp definition or be ill defined. The color may be of any tint or shade, depending upon the disease of which it may be a part or symptom. The lesion is the result of numerous pathologic processes. It may be produced by simple hyperemia or congestion, the most familiar example of which is the pinkish or reddish spots and patches of erythema, in erythema hyperæmicum, and which may also, by coalescence and profusion, form an eruption more or less diffused over the surface. The pinkish or reddish macules of the various exanthemata, of typhoid fever (rose-spots), and of copaiba and other drug rashes, are also examples of the hyperemic type. The ring or zone of hyperemia sometimes found surrounding other lesions, known as the areola or halo, might also be considered as an annular erythematous spot or macule; it is usually, however, distinctly inflammatory. The hyperemic macule has sometimes a trifling degree of underlying accompanying inflammatory action, but rarely sufficient to give perceptible elevation. When there is a slight escape of the coloring-matter of the blood, the hyperemic color is soon mellowed by a yellowish or yellowish-white tinge. Sometimes, in such macules, there may be extremely slight, scarcely perceptible, branny scaliness; this is also observed in the spots or macules of tinea versicolor.

Occasionally the erythematous spots tend to merge or develop into slight elevations,—a midway lesion between macules and papules,—known as *maculopapules* or *erythematopapules*, and, when this characteristic is predominant, the eruption is described by the qualifying term *erythematopapular* or *maculopapular*.

Other macules may be the direct consequence of hemorrhage into the skin, without preceding or accompanying hyperemia or inflammation, as the spots of purpura, which are usually first bright red, unaffected by pressure, and change to a dull red, yellowish, and finally fade away. Long-continued inflammatory action with deposit of the coloring-matter of the blood or the deposition of pigment, as in lichen planus, syphilis, and some other diseases, especially when on dependent parts, leaves behind dark-red or brownish colored macules or *stains* of more or less persistence. Other examples of pigmentary macules are freckles, chloasma spots and patches, and

nævus pigmentosus, which are due to excessive pigment deposit, and may be of different degrees of shade from light yellow to almost black. When such deposit is diffused, involving large areas and of more or less uniform distribution, it is commonly designated a *discoloration.*

Small circumscribed discolored spots sometimes are of artificial origin, resulting from the forced introduction of pigment-matter in or beneath the skin, as in tattoo-marks and powder-stains. The skin may also be discolored temporarily by certain chemicals or dyes. In contradistinction to the dark macules are the white spots of vitiligo, and those associated with other atrophic changes of the skin, as in leprosy and other disorders. Casual mention may also be made of the reddish spots or macules due to capillary dilatation or new growths, as in the acquired blemish designated telangiectasis, and in the congenital formation known as vascular nevus.

Wheals.—*Synonyms.*—Pomphi; Urticæ; *Fr.*, Plaques ortiées; *Ger.*, Quaddeln.

Wheals are variously sized and shaped, whitish, pinkish, or reddish edematous elevations, of an evanescent character.

Their common and most typical expression is as the lesion of urticaria, although they can also be produced by the bite of a mosquito or by the sting of the common nettle. They are closely related to erythema, and can almost be considered as erythematous spots or macules with underlying edema. The peripheral portion of a typical wheal is usually pinkish or reddish, the central and main portions whitish or pinkish white, and they not infrequently have a shining aspect. Sometimes they are, however, almost wholly white, and in others pink or red, with a mellowing toward a white color centrally. In shape they are most commonly rounded, or ovoid, pea- to bean-sized, and considerably elevated; if numerous and close together, from enlargement and the arising of new efflorescences in the interspaces, solid plaques result, usually in their main aspect appearing to be white, edematous, elevated, flattened infiltrations, with or without pinkish shading here and there, and generally with a pink or red edge or areola. In other instances, mixed in with the ordinary rounded forms, there may be linear wheals, from a fractional part of an inch to several inches or more in length, and, if not arising spontaneously, such forms can commonly be brought out by rubbing or scratching. By a coalescence of ordinary wheals, linear forms, etc., gyrate or ring-like plaques of irregular configuration sometimes result. In some cases, and also in occasional individuals free from ordinary attacks of urticaria, signs, letters, and various characters can be produced by firmly drawing the finger or the blunt end of a pencil over the parts—a condition known as "dermatographism" (*q. v.*).

Exceptionally, wheals are much smaller than are commonly seen, especially in young children, in whom some or all of them may be more of the nature of conic or acuminate papules, often capped with a minute vesicular point—the so-called urticaria papulosa. In some cases, too, in adults, as well as in those younger, the edematous exudation is so rapid and profuse that the epidermis is lifted up, and a bleb, or bulla, produced—urticaria bullosum.

Wheals are always attended with more or less burning, a feeling of heat, and itching, and these subjective symptoms, especially the itching, often exist to an intense and annoying degree; the scratching and rubbing thus induced lead to aggravation of the lesions present and the development of new ones. The lesion is of rapid formation, usually fully developed in a few seconds or a few minutes; it is evanescent and capricious, often coming and going quickly and in the most erratic manner, without any subsequent scaliness or exfoliation. It is angioneurotic in character, due to some irritation from within or without, and has its seat in the papillary layer or in the body of the corium. There is, first, a dilatation of the vessels, then a sudden exudation of serum takes place, followed by a contraction of the vessels, which prevents absorption; as soon as the spasm of the vessels abates, absorption gradually or quickly takes place, and the wheal disappears.

Papules.—*Synonyms.*—Pimples; Papulæ; *Fr.*, Papules; *Ger.*, Knötchen.

Papules are small, usually superficially seated, pin-head to pea-sized, circumscribed solid elevations.

They show considerable variation in size, shape, and color, and are of diverse character and origin, and therefore are due to many different pathologic processes, and have their seat in different structures of the skin. They may be white or whitish, as in milium, which produces a papular elevation; yellow, as in xanthoma; bright red, as in eczema; dark or coppery, as in syphilis; violaceous, as in lichen planus; and almost black, as in some of the papular infiltrations of some varieties of sarcoma.

The papule, or beginning solid pimple of acne, and the red pin-point to pin-head-sized papule of eczema are its most familiar examples. In both of these the lesion is usually rounded at the base, and conic or pointed in shape, whereas the papule in lichen planus is usually irregular at the base and flat or umbilicated in form. The papules of the papular type of erythema multiforme are also generally somewhat flattened, and sometimes, and exceptionally also in lichen planus, with a tendency to slight central depression or partial absorption and simultaneous peripheral extension, the papules then being faintly or distinctly circinate or annular. In other lesions, instead of being acuminate or flat, the top may be convex or bluntly rounded. In addition to the various examples of papules already referred to, may be mentioned those which are formed by epidermic collections about the hair-follicle outlets, as in keratosis pilaris, and which are harsh, rough, and grayish, with, sometimes, a reddish base. The same may be said of the follicular papules observed in pityriasis rubra pilaris and in ichthyosis. It will thus be seen that this lesion may be inflammatory or plastic in origin, as in eczema; due to duct obstruction or obliteration, as in acne and milium; to cellular or new-growth infiltration, as in xanthoma and lupus; to hypertrophy of the epidermic layer or scale accumulation, as in keratosis pilaris; or of the papillary layer,—the papillæ,—as in ichthyosis and warts. They sometimes arise from erythematous spots, and may

not become fully developed papules, being *erythematopapular* or *maculopapular*. As a rule, inflammatory papules are itchy, sometimes markedly so, as in papular eczema and lichen planus; other papular formations are rarely attended with active subjective symptoms.

Papular lesions persist as such, or in some diseases at times change into vesicles, as in eczema, or into pustules, as in acne and some syphilitic papules. Some are, as already described, essentially squamous; others may become so, as with lichen planus and the papular syphiloderm, constituting the *squamous papule;* the eruption in which such feature is predominant is designated *papulosquamous*. Sometimes the transformation into a vesicle or pustule is incomplete or partial, the lesion remaining comparatively solid, and thus arise the lesions known as *papulovesicles* or *vesicopapules* and *papulopustules;* and when this is displayed in a greater number of the lesions the eruption is described as *vesicopapular* or *papulovesicular* and *papulopustular*. The duration of papular lesions is variable, depending upon their nature, origin, and management.

The term *lichen* is sometimes erroneously used to designate a papular eruption as a whole, and the word *lichenoid*, as synonymous with the term papular, but the former, especially, is a misleading and more or less obsolete term, unless used with a qualifying adjective—as, for example, lichen planus and lichen scrofulosus. *Lichenification* is a term that the French apply to a condition of the skin usually observed about the joints, characterized by some thickening, with closely crowded or coalescing slight, flat, dull-reddish, papular elevations, which they believe results from chronic inflammatory processes; others are inclined to consider it as an expression of lichen planus.

Tubercles.—*Synonyms.*—Nodules; Small tumors; Tubercula; *Fr.*, Tubercules; *Ger.*, Knoten.

Tubercles are solid, usually clearly circumscribed, rounded, pea-sized, somewhat deep-seated, elevations, generally of a persistent character.

Clinically there is a close analogy between papules and tubercles, and the latter might almost be described as or named an exaggerated papule; it is not always an easy matter to classify them. It can be considered as an intermediate or merging lesion between a papule and a small tumor. The tubercle commonly consists of a cellular infiltration, is usually neoplastic, as in the tubercles of leprosy, lupus, syphilis, etc., although it may also be hypertrophic and inflammatory. The deep-seated character, its more intimate association with the corium or subcutaneous tissue, and its commonly convex or bluntly rounded projecting portion are the features that distinguish it from its near affinity, the larger-sized papules. These latter are more of the nature of surface lesions, with but slight tendency to downward growth; in short, a papule may be said to be a solid lesion, extending upward; a tubercle, a solid lesion projecting both upward and downward.

Some confusion has been added to the term tubercle, so long used

in dermatologic description to designate this primary lesion variety, by its more recent application to a product of tuberculosis. In dermatology it refers solely to the form and general characters of the lesion, and not to its nature.

While generally circumscribed and rounded, tubercles may also be conic and somewhat flat or irregular in outline. They are of gradual growth, and when close together, coalesce and form solid infiltrated areas, with sometimes an entire disappearance of their original nodular character. Usually, however, more or less distinct characteristic tubercles are to be recognized at the peripheral portion, or outlying close to the border. In color a tubercle is usually dull reddish, but in xanthoma they are yellow, in fibroma normal or pinkish, in molluscum contagiosum pinkish and waxy, and in some cases of sarcoma and carcinoma purplish red or blackish.

Tubercles are not only of slow formation, as a rule, but sluggishly persist, and are extremely slow in disappearing. Some persist indefinitely, with no tendency to involution, as in fibroma. In others, after some weeks, months, or at times even years, involutionary changes set in, and they disappear by absorption without trace, or with some remaining atrophy and discoloration; or they undergo degenerative and destructive changes and ulcerate, as often observed in the tubercles of syphilis, lupus, leprosy, etc., and are followed by scar-formation.

Tumors.—*Synonyms.*—Tumores; Phymata; *Fr.*, Tumeurs; *Ger.*, Knollen; Geschwülste.

Tumors are soft or firm, usually more or less circumscribed, though variously sized and shaped, elevations, having their seat in the corium and subcutaneous tissue. They are generally large and prominent formations, the smallest size commonly accepted under the term—a somewhat vague one—being that of a large pea or a large tubercle, the dividing-line from the latter being more or less arbitrary, as tubercles are often spoken of as small tumors. More commonly, however, it implies a growth of dimensions exceeding those of a cherry. They are frequently walnut to egg-sized or larger. Their color is usually that of the skin, but the latter is sometimes put upon the stretch, and may look thinned, glistening, and often pinkish or reddish.

They are generally semiglobular in shape, originate, as a rule, deeply, either in the subcutaneous tissue or conjointly in this and the corium, and gradually develop to their normal size or to indefinite proportions—to a slight extent spreading out into the deeper structure, to a greater degree laterally, and in many instances probably most upward where there is less resistance, finally resulting in variously sized, shaped, and constituted firm or soft prominences, sharply or fairly well circumscribed, or intimately associated or blended with the adjacent tissues, or forming pendulous tumors. In those of markedly inflammatory or active origin, as in carbuncles, gummata, and similar growths, there is a good deal of lateral extension, the mass becomes suppurative and necrotic, the skin dark to purplish red, with its gradual destruction in totality or at points. The tumors of granu-

loma fungoides, sarcoma, carcinoma, leprosy, and like malignant affections also usually undergo final destructive changes, terminating in small or large ulcerating masses or open ulcers. On the other hand, the sebaceous cyst, ordinary fibroma, angioma, keloidal growths, lipoma, myoma, lymphangioma, etc., are benign, or relatively so, usually maintaining their integrity throughout. Tumors are, therefore, as is to be inferred from the various cited examples, of different constitution, character, growth, and termination, according to the seat of origin and the nature of the pathologic process, influenced probably by accidental or extraneous factors or conditions.

Vesicles.—*Synonyms.*—Little blisters; Vesiculæ; *Fr.*, Vesicules; *Ger.*, Bläschen.

Vesicles are pin-point to small pea-sized, whitish, yellowish, or reddish, circumscribed epidermal elevations, containing clear or opaque fluid. They arise as vesicles or are formed from preexisting papules. They may be acuminate, conic, or rounded, sometimes slightly flattened. Their color depends upon their contents and the degree of the accompanying inflammatory action. The contents may be, as usually always at first, perfectly clear and watery, consisting of pure serum, which may subsequently, and in some instances almost from the start, show a slight cloudiness; later some lesions become seropurulent, and in others there is a slight admixture of blood. Thickness of the epidermal covering is also an influencing factor in the coloring, as shown in the sago-grain-like vesicles of pompholyx. For the most part inflammatory vesicles are well distended and conic or acuminate. Those of eczema are usually minute, pin-point to pin-head in size, or sometimes slightly larger, yellowish and glistening, aggregated or crowded together, superficially seated, with thin walls, and generally tending to spontaneous rupture. The lesions may be so close together as to coalesce, sometimes almost before completely formed, and undermine the horny layer of the epidermis. The tendency to the appearance in groups, aggregations, or closely packed masses seems to be more or less characteristic of the lesion, although in some diseases they may be scanty, isolated, or discrete, even if generally disseminated. The former is shown in eczema, herpes simplex, herpes zoster, and dermatitis herpetiformis; the latter in miliaria, sudamen, hydrocystoma, and varicella.

While ordinarily rounded, conic, or acuminate, they may be oblong or somewhat linear, as frequently seen in some lesions in scabies, or oblong, irregular, or angular, both at the base and in their body, as in dermatitis herpetiformis and some cases of herpes. In these latter two diseases, as well as in others, sometimes instead of being distended and tense, they are only partly full and flaccid. Exceptionally in the larger vesicles a tendency to umbilication is exhibited. Some display but little, if any, tendency to spontaneous rupture, as in herpes simplex, herpes zoster, hydrocystoma, etc. This latter feature depends upon their point of origin, whether superficial or deep, and the thickness of the stratum corneum. Some simply have the upper corneous layers as the epidermal covering,

others the entire horny stratum, while still others are still farther down, beneath the granular layer. In the palms and soles, owing to the thickness of the horny layers, their covering is commonly thick and tough; in this region, too, owing to this fact, undermining sometimes results. They are usually the result of exudation from the vessels of the papillæ; sometimes they are due to sweat retention, generally in some part of the gland-duct. They may be one-celled or simple, having but a single chamber or cavity, as in the vesicles of eczema and sudamen, or multilocular or compound, having two or more cavities or chambers, as in the vesicles of variola, herpes, and varicella.

Vesicles are rarely persistent as such, but break spontaneously and crust over, as in eczema; dry up and desiccate into a thin crust, as usually in herpes simplex and herpes zoster; the contents are in part or completely absorbed or evaporated, the covering wall exfoliating as a thin scale, as in sudamen; develop into blebs through either coalescence or enlargement, as sometimes in herpes zoster, and frequently in dermatitis herpetiformis; or they become pustules, as in variola, and sometimes in eczema. In this last, however, as in some other diseases, the lesions often do not become strictly purulent, but are of a seropurulent character, forming *vesicopustules*, and when such a feature is a predominant one, the eruption is usually designated *vesicopustular* or *pustulovesicular*. In exceptional instances the vesicles undergo considerable enlargement, approaching to or almost merging into blebs, or they may be originally of fairly large size, and in such the eruption is often termed *vesicobullous*, although this same designation is also sometimes applied to mixed vesicular and bullous eruptions. As a rule, vesicular eruptions are attended by a good deal of burning and itching, although in some instances, as in sudamen and hydrocystoma, subjective symptoms are entirely absent.

Blebs.—*Synonyms.*—Blisters; Bullæ; *Fr.*, Bulles; *Ger.*, Blasen.

Blebs are rounded or irregularly shaped, tense or flaccid, pea- to egg-sized or larger, epidermic elevations with serous or seropurulent contents; they are, in brief, similar to vesicles except as to dimensions. While commonly rounded or oval, they may be, as with vesicles, somewhat irregular in shape. They sometimes arise from vesicles, either by direct extension or growth, or from the coalescence of several lesions. In their most typical, although probably not most common, expression, as in pemphigus, they frequently spring from a seemingly healthy or non-inflammatory surface, so that they may or may not have a mildly inflammatory or hyperemic areola. They arise in dermatitis herpetiformis either as blebs or by coalescence of vesicles from an apparently normal or reddened skin, or develop upon preëxisting erythematopapular lesions. As accidental lesions, they may develop upon urticarial efflorescences, as in urticaria; upon an erythematous or erythematopapular base, as in erythema multiforme; or arise in erysipelas, leprosy, and some other diseases. They are not an uncommon feature of rhus poisoning and other forms of dermatitis. In their earliest formation bullæ are, as a rule, clear or

pale yellowish, their contents being serous and of a neutral or alkaline reaction; later they usually become somewhat clouded or turbid, and whitish or yellowish in color; if containing blood, uniformly mixed, the color is reddish or brownish; if this admixture is not evenly distributed through the bleb, the appearance is whitish or yellowish, with an intermingling of reddish or brownish streaks or flakes. Sometimes they are seropurulent from the beginning.

At first they are usually tense and distended, but unless spontaneously or accidentally ruptured, the walls become flaccid; in some instances the latter character is noted throughout. They are unilocular or one-chambered, have, as a rule, somewhat tough walls, which do not readily burst. In some cases, however, their covering is thinner than ordinarily, ruptures early either spontaneously or as the result of trifling external accidental agencies, the broken walls remaining temporarily attached to the skin as thin, irregular shreds. In pemphigus foliaceus this is especially noticed, the thin walls breaking rapidly, scarcely before there is much observable exudation, and new exudation frequently taking place before the corneous layer has been fully replaced, and as soon as slightly lifted up breaks again, and so the process continues; frequently in these cases the lesions are so closely contiguous that they coalesce, the exudation producing essentially a more or less general undermining. The base of the broken blebs varies somewhat in appearance and character, ordinarily being simply the red rete or corium, appearing as a red superficial abrasion, which soon heals over. At other times it is a decided erosion, dotted or streaked over with seropurulent or purulent matter or blood, and continuing to secrete actively for a variable time; occasionally the surface shows a vegetating or papillomatous tendency.

The course of bullæ is essentially the same, therefore, as with vesicles, and they terminate in the same way by suppuration, by partial absorption, desiccation, and crusting, and by rupture and thin crusting; those becoming purulent finally ending in like manner as those which remain serous or seropurulent—by rupture, desiccation, and crusting, the latter being thicker and sometimes quite bulky.

Blebs are, as remarked, usually unilocular or one-chambered, and, as with vesicles, have their seat in the epidermis, either in the superficial or deeper layers; in some instances the entire epidermis is lifted up. As a rule, they are rarely accompanied by active subjective symptoms, although often a sensation of tension and slight burning attend their development. Their presence is usually to be considered either an accidental one, as in urticaria, erythema, etc., due to the intensity and rapidity of the inflammatory action and effusion; or an expression of some general nerve disturbance or depression, chronic autointoxication, septicemia, a depraved or cachectic state of the health, and the like, as in dermatitis herpetiformis, pemphigus, and syphilis.

Pustules.—*Synonyms.*—Pustulæ; *Fr.*, Pustules; *Ger.*, Pusteln.

Pustules are pin-point to finger-nail-sized circumscribed epidermic elevations containing pus. They are, in brief, similar to vesicles and to the smaller blebs having an inflammatory areola, except that the

contents are purulent instead of serous or seropurulent, as in these lesions. They originate as pustules or arise from vesicles, and, if from the latter, sometimes may become only incompletely purulent, constituting *vesicopustules.* They may also develop from a papule, and here likewise the transition in some lesions or cases may be incomplete, the papular basis being maintained, the suppurative change taking place at the central apex portion, resulting in the lesions known as *papulopustules.* In many instances, however, when arising from vesicles or papules, the pustular metamorphosis may be so rapid that the vesicular or papular origin can scarcely be recognized. As a rule, however, in such instances there is an intermingling of the primary formations, which have continued as such, or undergone only slight transformation; in fact, it is usual to find lesions in all stages of transition.

In color pustules are usually yellowish, unless they contain an admixture of blood, when they are reddish or brownish yellow. In shape they are acuminate, as often in eczema and sycosis; conic or rounded, as usually in acne, furuncle, and an occasional type of impetigo (Duhring's impetigo simplex); or flat or flattened, as in most cases of impetigo, in ecthyma, flat pustular syphiloderm, etc.; in some diseases with central depression or umbilication, as in variola and the varioliform syphiloderm; and occasionally oblong or somewhat linear, as sometimes in scabies. In size they vary from a pin-point, as in the smallest pustules of eczema, to that of a finger-nail, as in the lesions of impetigo and ecthyma. They may be superficially seated, as in eczema and impetigo pustules; or moderately deep, as in some lesions of the latter disease and of sycosis; or deep seated, as in most pustules of the last-named affection, in acne, and in furuncle. They are, therefore, as regards the point of origin, somewhat variable, that of eczema, impetigo, and ecthyma usually or chiefly in the mucous layer, that of sycosis around the hair-follicle, that of acne in or about the sebaceous gland, and that of boils deep in the corium. The hair-follicle plays an important part in most pustular lesions, either as the sole or conjoint seat of the suppurative process or as the port of entrance for pyogenic cocci. As a rule, pustules form rapidly and are generally attended by a good deal of inflammatory action, sometimes with considerable burning, pain, and tenderness, but itching, except in those of eczema, is rarely complained of. Exceptionally their formation is slow, as occasionally in the pustules of impetigo, ecthyma, and syphilis; this usually results in a flattening and a tendency to central depression, or in stratification of the crust, as particularly shown in the condition known as rupia. In this latter the covering and upper portion of the contents of the pustule or small purulent bleb dry to a crust that is lifted up by the gradually forming and extending purulent collection beneath; this in turn dries to a crust while the base of the lesion is still enlarging and secreting, and in this manner it may continue for a variable period. When fully formed, the entire overlying crust is thick and stratified, with that of small diameter at the top and the largest at the under part, presenting an oyster-shell-like arrangement. In impetigo and ecthyma the central part sometimes dries and becomes firmly attached to the

underlying part, while the purulent collection to a slight degree extends peripherally as a spreading purulent wall.

Upon the whole, pustules usually, like vesicles and blebs, tend to rapid development, course, and termination, varying somewhat according to their cause, nature, and seat. As with vesicles, they may be unilocular or have but one cavity, or multilocular, with several or more chambers. They generally end by rupture and discharge, with subsequent slight crust-formation and repair; or they may break imperfectly, with but little escape of fluid, and gradually dry into a rather thick, firm crust that finally drops off; or they may dry up without rupture. The color of the crust varies from a yellowish or yellowish brown, as in eczema, to reddish or dark brown, in syphilis, and may be thin, thick, friable, or firm, depending upon the character of the morbid process and other circumstances. The processes involving the corium may be followed by scar-formation, as in variola, syphilis, acne, ecthyma, and the like.

CONSECUTIVE OR SECONDARY LESIONS.

Excoriations.—*Synonyms.*—Excoriationes; Abrasions; Erosions; Scratch-marks; *Fr.*, Excoriations; *Ger.*, Hautabschürfungen; Excoriationen.

Excoriations are variously sized and shaped, but usually small, irregular, or linear, solutions of continuity, generally of a superficial character, and the result of traumatic or mechanical causes.

The most familiar and chief examples are the red denuded points, small abrasions, jags, and lines or shallow furrows produced by the finger-nails in the act of scratching, in efforts to gain relief from the troublesome itching in certain diseases, notably eczema, pruritus, scabies, and pediculosis. Not infrequently they are, especially the points and small areas, more or less irregularly covered with thin crusts composed of blood and the exuded serum. As a rule, they involve the epidermis only, rarely extending more than superficially into the papillary layer of the corium. The epidermis being denuded, the rete or corium is laid bare, and the lesions thus resulting are slightly depressed, although scarcely perceptibly, and are usually bright or dark red in color, with sometimes a yellowish or mellowed tinge, due to a thin coating of desiccated exuded serum; or they may be of a brownish or almost blackish color, owing to the presence or admixture of dried blood. They may be bordered by a narrow band or areola, with sometimes slight inflammatory elevation. At times the excoriations are somewhat elevated, due to the fact that the lesions scratched are papules, as in papular eczema, the summits alone getting the brunt of the injury. The extent and depth of the excoriations depend upon the force employed in scratching and the resisting power or susceptibility of the skin; the latter may be an inherent peculiarity of the individual or be due to the cutaneous disease, as is frequently observed in eczema. The great difference in the character, amount, and depth of the excoriations in cases in which the disease is apparently of similar extent, the itching as intense, and the scratching as vigorous, is not an uncommon clinical observation.

The nails are not the only agents by which excoriations are produced, although the usual and common one; they may be the result of slight traumatisms of other kinds. Pricks and scratches caused by pins, needles, and other familiar articles are often responsible for isolated lesions; "skinning" the finger, "barking the shin," giving rise to an abraded or "raw" condition of the skin, can also be cited. The simple act of rubbing, and even the friction of the clothing itself, will, in vesicular lesions and vesicopapules, often remove the surface and give rise to superficial punctate tears or abrasions. Persistent and repeated scratching in eczematous and other inflammatory processes often leads to greater infiltration and inflammatory activity; and in diseases in which itching occurs independently of any exciting structural changes, as in pruritus and pediculosis, a mild or moderate degree of dermatitis or eczematous inflammation is sometimes thus provoked. Long-continued scratching and rubbing of a part, as in a long-continued pediculosis, pruritus, eczema, and other diseases, will also, in addition to the induced inflammatory infiltration and thickening, sometimes produce more or less pigmentation; this is especially observed in those who have for a long time been the subjects of pediculosis, producing a pigmentation so extensive and dark colored as even to suggest Addison's disease.

As a rule, excoriations being of superficial character, are rarely followed by scarring, but in some instances, where they are deep, involving the corium, slight atrophic whitish spots are to be seen, and these especially about the upper back in the chronic affection last mentioned. Excoriations are often accompanied by small and large pustules, the opened points and abrasions giving ready opportunity for local integumentary infection by pyogenic cocci; in such instances, as well as occasionally in others where distinct pustular lesions are not formed or conspicuously present, there is sometimes noted a swelling of the neighboring lymphatic glands.

These lesions are frequently an important feature in many skin affections, and their character and distribution often alone suffice to the formation of a correct diagnostic conclusion, as illustrated especially in pediculosis and scabies. Their presence, too, is always significant of itching, and in the differentiation this factor bars out a number of diseases that may have other symptoms in common.

Fissures. — *Synonyms.* — Cracks; Rents; Clefts; Rhagades; Rimæ; *Fr.*, Fissures; *Ger.*, Hautschrunden; Rhagaden; Einrisse; Fissuren.

Fissures are linear cracks or wounds involving the epidermis or epidermis and corium, and the result of disease or injury.

They are most commonly met with where the epidermis is thickened and infiltrated, when due to cutaneous disease, which impairs the local nutrition and renders the parts inelastic; and especially if upon regions where there is a great deal of natural active or frequent movement. They are, therefore, most frequently observed about the palms, fingers, soles and toes, and joints, especially the flexures; also at the angles of the mouth and lips, and about the

nares and the anus. They are also not infrequent back of the ear. More commonly, but by no means always, they occur in the natural lines and furrows. They are usually seen in eczema, not infrequently also in other chronic inflammatory infiltrated diseases, especially those of a dry character, as in ichthyosis, scleroderma, psoriasis, lichen planus, dermatitis, and similar affections. In such diseases their production is often induced, aggravated, or increased by applications that cause dryness, especially the free use of soap. Indirectly the tendency is added to, moreover, as in eczema of the hands and fingers, by the frequent use of water and contact with irritating substances, as with cooks, laundresses, polishers, pasters, etc., the underlying disease or tissue weakness being thus increased. In those of sensitive and especially naturally dry skin, exposure to cold and wind will suffice to bring about a variable fissuring of the lips and hands—so-called "chaps" or "chapping." Fissures are also frequently noted at the angles of the mouth and about the anus in congenital syphilis.

They may be of various lengths, widths, and depths, the margins usually being abrupt and sharply defined; although generally straight, they may be curved or crooked. They may be dry or moist, and reddish in color, more particularly toward the base, and if they are at all numerous and deep, impair the free movement of the part through fear of the accompanying pain and the possible deeper opening of the cracks and the production of new breaks.

Scales.—*Synonyms.*—Exfoliating epidermis; Epidermal exfoliations; Squamæ; *Fr.*, Squames; *Ger.*, Schuppen; Hornplättchen.

Scales may be defined as dry, usually laminated, epidermal exfoliations or desquamations; or as collections, on the surface, of loose, dry epidermis, resulting from some underlying morbid process.

A mild degree of ordinarily invisible or scarcely perceptible exfoliation in the form of minute, thin epidermic particles is physiologically taking place constantly, which, if its removal is not facilitated by baths and soap-and-water washings, may accumulate sufficiently to be, on close inspection, noticeable as a branny roughness, as not infrequently observed in those of the dispensary class. It is more pronounced or more quickly noted after discontinuance of ablutions in those of a naturally dry skin. Pathologic scaliness, however, with which we are concerned, is due to the rapidity of epidermic cell-formation or to an interference with the process of normal horny transformation, and is the result of various morbid processes. It presents itself from that of scaliness of a scarcely greater degree than that of the physiologic exfoliation already mentioned, to that of thick, circumscribed, or more or less generalized, imbricated, horny, epidermal accumulations, produced slowly and in slight or moderate quantity, or rapidly and in great abundance. As illustrating the extremes and the intermediate degree may be mentioned the insignificant branny or flour-like scaliness, or, as commonly designated, *furfuraceous scales*, of tinea versicolor; the scarcely greater of so-called pityriasis capitis; the slightly more emphasized in some cases of erythematous eczema; moderate or fairly abundant in squa-

mous eczema, seborrhea, the milder types of ichthyosis, lichen planus, etc.; and the usually profuse in psoriasis, the severer grades of ichthyosis, some types of dermatitis exfoliativa, and pityriasis rubra pilaris. Sometimes the exfoliation is of the nature of thin, variously sized flakes, or *lamellæ*, as frequently in eczema, the milder varieties of dermatitis exfoliativa, erythema scarlatinoides, scarlatina, etc.; in the last two, usually taking place, especially about the extremities, as thin, parchment-like or sheet-like more or less extensive films; in others, in the form of thicker imbricated masses, as especially well shown in psoriasis in advanced stages of pityriasis rubra pilaris, and severe cases of ichthyosis—in the last named occurring usually as thick, plate-like masses. They are generally loosely attached to the underlying epidermis, but exceptionally, as in lupus erythematosus, they adhere somewhat firmly.

In character scales are dry, harsh, horny, brittle, with a disposition to break up into thin flakes or minute particles; occasionally, however, from the admixture of oily secretion, as in some seborrheic scales, or of dried serous or seropurulent exudation, as is observed in some scaly masses in eczema, the accumulations are seen to be more closely agglutinated, less brittle, and sometimes slightly oily or gummy, forming, in reality, a mixture of scale and crust—*crustæ lamellosæ*—which, when thin, can be well designated *crusty scales*, and when thick, *scaly crusts*, although these terms are commonly used interchangeably. These latter scaly masses are usually dull yellowish, dirty yellowish, sometimes with a brownish cast or deeper hue; whereas ordinarily scales are white or grayish, and either lusterless or, as in some instances, as often seen in psoriasis, in some cases of eczema, lichen planus, etc., with a glistening, micaceous aspect.

Crusts. — *Synonyms.* — Crustæ; Scabs; *Fr.*, Croûtes; *Ger.*, Krusten; Borken.

Crusts are dried effete masses of exudation, usually with an admixture of more or less epithelial débris. They vary greatly in thickness, color, size, form, and in other features. They are thin, flattened, and yellowish, as in impetigo contagiosa and in some cases of eczema; flat and thick and dark yellow to reddish brown in ecthyma and in some of the pustules of syphilis and pustular eczema; and thick, irregular, and of a brownish, dark-red, or blackish color, in some ulcerations, especially those of syphilis. In the last-named disease some of the pustules, bullous lesions, or ulcerations become covered over with oyster-shell-shaped crusts,—rupia,—as referred to in describing pustules. The crusts of syphilis, and also less frequently those in other purulent processes, are sometimes of a greenish hue. Crusts are, at times, somewhat soft and friable, frequently but lightly attached, as commonly observed in those of eczema and impetigo contagiosa, those of the latter often looking as if "stuck on" or imperfectly pasted on. Others are firmer, tougher, and more adherent to the subjacent tissues, as in ecthyma and syphilis.

These several characters depend chiefly upon the nature of the secretion, the crusts being variously composed of serum, pus, blood, and extraneous matter; sometimes exclusively of serum, as the com-

mon yellowish or candied-looking crusts of vesicular eczema; often of serum and pus, as the dirty, dark yellow, or greenish yellow of seropurulent eczema and impetigo; and frequently with a varying quantity of blood, giving the crust a reddish or blackish appearance. They usually contain also more or less epithelial débris. The thickness depends upon the amount of the discharge, more especially when the latter is dense and tenacious; to their firmer adherence to the underlying part, together with the duration. The crusts or "scabs" covering ulcerations are usually thickest and the most bulky; if removed, and the subjacent ulcerations still remain, the part soon scabs or crusts over again. More or less surface destruction underlies those of ecthyma, lupus, epithelioma, syphilis, etc., and in the last two especially it may be quite deeply seated.

Crusts other than those named possess some peculiarities. Those of seborrhea and of mixed seborrheic and eczematous processes are usually more or less unctuous to the touch, light or dirty yellowish, at times darker, somewhat lamellated, and adherent, possessing features of both crusts and scales,—crusty scales, scaly crusts, crustæ lamellosæ,—as referred to in describing scales. The crusts of favus, when more or less isolated and circumscribed, consist of somewhat thick yellow concavoconvex discs, friable and granular, with the convex side pressed down on or in the skin; but if the disease has been long continued, these crusts may be so closely set and continuous as to lose this peculiar shape, and form thick, confluent, yellowish, mortar-like masses; it is made up chiefly of the vegetable fungus, to which the disease is due, together with epithelial cells and débris. The crusts observed in certain forms of eruption due to the ingestion of bromids are sometimes thick and brownish or brownish yellow; they cover the part and dip down between the papillomatous projections usually present, forming an interlocking that gives them a firm setting, these crusts being noted especially for their persistence and tenacious attachment. The same characters, but, as a rule, much less pronounced, are also seen in some forms of iodid eruption.

Ulcerations.—*Synonyms.*—Ulcers; Ulcera; *Fr.*, Ulcères; *Ger.*, Geschwüre.

Ulcerations are rounded or irregularly shaped and sized losses of cutaneous tissues, sometimes extending into the subcutaneous structures, resulting from disease.

Excluding those arising from traumatic influences, and the ordinary simple leg ulcers with which dermatologists are rarely concerned, these excavations are the result—of impaired nutrition of the part, as in the ulcers on the lower part of the legs associated with varicosities and eczema; of suppurative inflammations, as in boils and ecthyma; of cell-growth combined with suppuration, with subsequent cell and tissue destruction, as in gummata and erythema induratum; and of cell-growth or infiltration, with retrograde metamorphosis, as in neoplastic formations, such as lupus and other forms of cutaneous tuberculosis, tubercular syphiloderm, leprosy, sarcoma, carcinoma, etc. By far the larger number of cases of ulcerations encountered

are due to syphilis, and commonly to the tubercular and gummatous syphilodermata.

Ulcerations may be small or large; some are scarcely larger than a pin-head, and from this intermediate sizes up to those covering a good deal of surface occur. In shape, they vary considerably: they may be rounded, oval, or irregular, and often, as in syphilis, and less frequently in lupus, crescentic, kidney-shaped, or segmental; when several of the latter are close together, they form a more or less wavy, irregular, and serpiginous tract. As dermatologically met with, ulcerations are, as a rule, superficial and shallow, as in many cases of lupus and tubercular syphiloderm, but in occasional cases of lupus, in some cases of the tubercular syphiloderm, in syphilitic gummatous lesions, in erythema induratum, in many cases of epithelioma, and in other neoplastic affections they may extend considerably into the subcutaneous structures. The character of the edges, which are usually clearly defined, sometimes with bordering inflammation and infiltration, differs materially—abrupt, almost as if the ulcer were punched out, sloping, everted, or undermined. Their bases are smooth or uneven, sometimes clean, others covered with a slough, and occasionally exhibiting a papillomatous or vegetating tendency, and discharging a scanty or abundant, offensive or inoffensive, serous, seropurulent, or purulent secretion.

Syphilitic ulcers, which may be either shallow or deeply seated, in addition to showing, usually, crescentic or segmental shapes, generally have perpendicular, sometimes undermined, edges, uneven floor, with a free purulent discharge, and ordinarily but little surrounding infiltration; if there is crusting, it is generally thick and dark colored or greenish. Lupus ulcerations are, as a rule, shallow, small, rounded sloping excavations often close together, running into each other, usually with but little, if any, surrounding infiltration, and having generally but a scanty discharge of a serous or seropurulent character; the crust, if present, is usually thin and yellow or yellowish-brown. The ulceration of superficial epithelioma is shallow, usually single, with sloping walls and surrounding slight infiltration, often with an elevated, roll-like, pearly, or waxy-looking border, and having generally but a scanty serous or viscid discharge, occasionally with a trifling blood admixture, and with or without a thin to slightly thickened brownish or reddish-brown crust. The deeper type of epithelioma shows greater excavation, more infiltration, somewhat inflammatory borders, the discharge similar to that of the superficial type, or more abundant, and sometimes more purulent, frequently with blood streaks or flakes; and often with a tendency to thick brownish or reddish-brown crust-formation.

Ulcerations may occur upon any part, but are common upon the leg, here usually of a simple inflammatory character, frequently in association, as previously stated, with varicosities and eczema. Those of lupus are most frequent upon the face, especially about the nose. Those due to syphilis are also common in the facial region, although likewise seen frequently upon other parts. Ulcerations may or may not be painful and tender. They may be stationary, progressive, or, except in malignant forms, undergo healing, always with the formation of cicatricial tissue.

Scars.—*Synonyms.*—Cicatrices; *Fr.*, Cicatrices; *Ger.*, Narben.

A scar or cicatrix is a connective-tissue new formation replacing loss of substance which had involved the corium or the tissues more deeply.

Scars may, therefore, be small, large, rounded, oval, or irregularly shaped, depending upon the size and other characters of the preceding ulcer or ulceration or the morbid processes that have led to their formation. Scars are not always, however, evidence that active or necrotic destruction has preceded, as is instanced by those of lupus erythematosus, scleroderma, favus, atrophy of the skin, and some cases of lupus vulgaris and syphilis. In some of these diseases the cutaneous structures are the seat of cell infiltration, which, in undergoing absorption or retrogressive, but non-ulcerative, changes, lead to superficial scar-formation, as in both varieties of lupus and syphilis. In the several other affections named the tissues undergo direct atrophy from distention, as in linea albicantes and other forms of atrophia cutis, or from pressure, as that in favus; or they may result from neoplastic overgrowth of the fibrous elements, as in keloid. Generally speaking, however, the presence of a scar points to a previous ulcerative process or loss of tissue from traumatism, and their shape naturally is determined by the form of the previous ulceration or destruction. When, in certain diseases, this has been at all peculiar or characteristic, as in the crescentic, kidney-shaped, and serpiginous ulcers of syphilis, the forms of the resulting scars have a diagnostic value in passing judgment as to the causative disease and also as to ulcerative processes that may still be present nearby or elsewhere on the surface. Soft thin scars, especially when showing on their surface somewhat deeper, small, pea-sized, depressions; small, rounded, thin scars arranged in segmental groups or in a serpentine manner; and scars with scallop-like edges—are all also suggestive, and usually conclusive, of syphilis. Thin scars on the face, with a somewhat glistening and stretched appearance, studded with minute depressions, corresponding to the gland-duct outlets, are characteristic of lupus erythematosus. Thickish, tough, and fibrous scars, sometimes of a slightly corded character, are frequent in lupus vulgaris, and when about the face, where this disease is most common, are an almost invariably conclusive factor in the diagnosis between this affection and the tubercular syphiloderm that it resembles. A fibrous, stringy, or cord or ribbon-like thickening, frequently with a general keloidal tendency, commonly suggests burns as its origin, and almost conclusively so if at all extensive. The significance of the numerous, scattered, small, pea-sized, white, depressed scars, especially marked and abundant on the face, as pointing to a previous attack of small-pox, is well known. Numerous minute, pin-head-sized scars, disseminated over the general surface, with a tendency to groups or aggregations, but commonly scanty or with no special predominance on the face, usually is clearly indicative of a preexisting secondary miliary papulopustular or pustular syphiloderm. If somewhat larger and irregularly disseminated, they are significant of the small or varioliform pustular syphiloderm; and if finger-nail to bean-sized, flat, slightly depressed, generally distributed, but not necessarily numerous, the large flat pustular syphiloderm

has usually gone before. The scar, therefore, is not only valuable as indicating the disease that has caused it, but its presence, especially if indicative of syphilis, may often afford valuable aid in determining the nature of obscure associated skin-lesions as well as the nature of some obscure organic or general disease. Recent scars are pinkish or reddish; the color is gradually lost, and gives place to a glistening or dead white; exceptionally, however, they are pigmented to a variable degree, which is commonly most pronounced at the margin or limited to this portion. Occasionally the redness is more or less persistent, even acquiring a purplish tinge.

Scars are usually smooth, soft, and more or less pliable, but occasionally, as just referred to, may be uneven, thick, tough, stringy, puckered, or distinctly keloidal or hypertrophic. They consist of new formations of connective tissue, containing blood-vessels, lymphatics, and nerves, but unless extremely superficial, no hairs or glandular structures. From their very nature they are persistent formations, sometimes, however, becoming, in the course of years, less conspicuous, and coming up almost to a level with the surface. On the other hand, exceptionally, they may undergo hypertrophic change, growing thicker and elevated, tough, stringy, corded, and uneven, but remaining limited to the original destroyed or ulcerated area, constituting the so-called *hypertrophic scar;* less frequently still the hypertrophic scar-tissue growth extends, projecting into the bordering healthy skin, more or less uniformly or in the form of irregularly disposed or claw-like processes, thus developing into *keloid.* As a rule, scars are painless formations, but in occasional instances they may be the seat of some itching or pain, rarely constantly, but usually intermittently or of a paroxysmal character.

LESIONAL CONFIGURATION, DISTRIBUTION, AND OTHER FEATURES.

The varying size of the lesions of different kinds, as well as of those of the same variety, has already been considered, and some of the terms usually employed were named incidentally. Several others may be here briefly referred to.

A single group or aggregation of lesions or area of disease constitutes a *patch,* and this, alone or with other lesions, groups, areas, or patches, considered as a whole, is known as an eruption. When the eruption is made up of the same type of lesion it is said to be *uniform;* if of several or mixed types, *multiform, polymorphous.* The lesions, patches, or areas of disease, which are also sometimes designated as *efflorescences,* may be distinctly separated—*discrete;* if the component lesions tend to form groups or bunches of several or more, as in herpes simplex, herpes zoster, etc., the eruption is said to be *herpetiform;* or they may be close together or crowded—*aggregated;* or they may be fused, forming solid patches or sheets—*confluent;* or they may be seated only in one or two regions—*limited* or *localized;* more or less uniformly distributed over most of the entire surface—*diffused, general,* or *generalized;* involving the whole surface—*universal;* irregularly scattered—*disseminated.*

When a patch or area of disease is sharply defined, it is said to be *circumscribed;* if rounded and of sharp contour—*orbicular* or *discoid.* The term *circinate* is applied to those of circular outline, but its most usual application is to circular patches with *clearing* center, as in tinea circinata, whereas an *annular* or ring-like patch is a round or circular patch made up of a free or *clear* center and an inclosing ring or band; to a rounded area composed of several concentric rings, usually of different duration and stage, and therefore somewhat variegated as to coloring, the term *iris* is added, as in erythema iris and herpes iris.

The term *gyrate* refers to an irregular or festoon-like configuration, usually resulting from the coalescence of several contiguous rings, the eruption disappearing at the points of contact, as in some cases of psoriasis; and *serpiginous* when the eruption spreads in a creeping-like manner at the border, clearing up at the older part, as in the tubercular syphiloderm. An area of disease is said to be *marginate* when it is abruptly defined against the healthy skin, as in eczema marginatum and erythema marginatum.

The regional localization is sometimes added to the name of the disease, or, as for example, herpes *facialis*, seborrhea *capitis*, etc.; and occasionally the lesional origin or anatomic involvement, as keratosis pilaris; and sometimes the age or life period is indicated, as pemphigus *neonatorum*, pruritus *senilis*.

Additional names and terms other than those already given will be found in the course of the text, and, as with the foregoing, are mostly those with which students of anatomy and medicine in general have already been made acquainted, and which are, moreover, as a rule, self-explanatory.

GENERAL ETIOLOGY.

Diseases of the skin are symptomatic or idiopathic. The most typical examples of the symptomatic class are the eruptive fevers, such as scarlet fever, measles, rötheln, chicken-pox, small-pox, and the eruptions of typhus and typhoid fever; likewise the cutaneous outbreaks due to other constitutional diseases, infections, or other internal systemic provocation, as syphilis, leprosy, scurvy, purpura, erythema multiforme, urticaria, medicinal rashes, and the like. These are merely symptomatic of some known or unknown constitutional infectious agent, bacterial, chemical, or toxic, and the eruptive phenomena may be simply one of the direct symptoms of the underlying general cause or disturbance, or an indirect one through some action on the nerves or nervous system or the vasomotor apparatus. On the other hand, an eruption may be idiopathic, have no relationship to the general economy, but arise in the cutaneous tissues, and remain limited to these structures, as in most of the atrophies and hypertrophies, the local parasitic diseases, and the various affections due to other irritating causes, as those of dermatitis venenata, etc. The skin, like any other organ or structure of the body, is subject to disease originating in and limited to its own tissues. It is true, however, that in many affections the local damaging or causative factors in idiopathic diseases are often influenced or even made operative by certain constitutional conditions or organic disturbances. The latter may also serve to favor continued action of the former and make the malady less amenable to external treatment—this not by any direct relationship, but indirectly by the general enfeebled condition of the health induced, in which the cutaneous tissues share and by which their resisting power is lessened.

The more common and important of the etiologic influences may be here discussed briefly, reserving special consideration of this point for the diseases in which one or the other may be more specifically concerned.

Climate.—Common observations show that some diseases are practically limited to certain climates or regions; others, while not confined chiefly to such limitation, may be much more frequent in special countries.[1] It is not probable, however, that the climate is alone responsible, but that this, together with the character of the food, habits of the people, their mode of living, and allied factors constitute an *ensemble* of influences to which this difference is due. Thus, prurigo is relatively frequent in Austria, and comparatively unknown or rare in many other countries,—as, for instance, in England and our own land, —whereas urticaria, inflammatory glandular diseases, and some other maladies are relatively more common with us. Leprosy, as is well known, is not uncommon in some climates or countries, and is rarely

[1] See valuable and interesting papers by: J. C. White, "Variations in Type and Prevalence of Diseases of the Skin in Different Countries of Equal Civilization," *Proceedings Internat. Med. Cong.*, Philadelphia, 1876; also "Immigrant Dermatoses," *Jour. Cutan. Dis.*, 1890, p. 369. Hyde, "Observations Based Upon the Statistics of Cutaneous Diseases in America," *Trans. Internat. Cong. Derm. and Syph.*, Paris, 1889.

seen in others. Lupus is an every-day affair in Vienna, other parts of Austria, as well as in other European lands, but with us one or two cases a month at our clinics of ordinary size seem to be a fair average. Favus is extremely common in Italy, and also, although less so, in Scotland. Pellagra is chiefly limited to Italy, and especially to the northern part; and the greater frequency and even limitation of frambesia and of filarial elephantiasis, mycetoma, ainhum, Delhi boil, and others to one or several regions, mostly tropical, are known.

In the same climate or region the effect of different **seasons** is also noted, some diseases, as winter pruritus (pruritus hiemalis), as the name signifies, occurring in the cold season; and at this time, some of the chronic inflammatory diseases, such as eczema and psoriasis, are usually much worse, and not infrequently measurably or completely disappear as the warm season approaches. Miliaria, or prickly heat, on the other hand, is essentially a disease of the hot season, while erythema multiforme is relatively more common in the spring and autumn months.

Not only the climate, region, and season may sometimes be instrumental in favoring certain diseases, but the **abode** or **habitation** itself, if unhygienic, improperly ventilated, damp, deprived of the beneficent and health-giving action of sunlight, and contaminated with poisonous emanations,—as, for instance, sewer-gas,—will have so damaging an influence upon the nutrition and vital powers that the skin becomes a more ready prey to morbid action. Furuncular and phlegmonous processes, as well as the development of the scrofulous diathesis, with its consequent tissue weakness, can sometimes be traced to such agency.

Heredity.[1]—That heredity plays an important part in disease can scarcely be questioned, although, doubtless, the disease itself, except such as syphilis, ichthyosis, and a few others, can hardly be considered transmissible. It is rather a tissue weakness, or **predisposition,** that is inherited; other and favoring circumstances being necessary to produce the malady, and without which the individual, might remain entirely free from its development. The list of dermatoses of which the heredity is evident is, as White has pointed out, very short. In addition to the several diseases named, the tendency seems to be displayed, however, in many cases of psoriasis, eczema, xanthoma, and in some other maladies.

Certain families seem peculiarly prone to a particular class of diseases,—**family diseases,**—some chiefly heart affections, others pulmonary, others zymotic, others again showing special proclivity to cutaneous affections, and sometimes without associated heredity. This hereditary and family tendency can also be observed in the greater families or nationalities constituting the different **races.** The tendency to favus seems to follow the Italian and Hungarian, even into this country, the associated American born, although equally exposed, showing but little susceptibility. Morison[2] has shown that

[1] See "Hereditary Dermatoses," by J. C. White, *Trans. Internat. Cong. Derm. and Syph.*, Paris, 1889, p. 363.

[2] Morison, "Personal Observations on Skin Diseases in the Negro," *Trans. Amer. Derm. Assoc. for 1888; Jour. Cutan. Dis.*, 1888, p. 429.

the negro seems to be more liable to some affections, as keloid, chilblain, ainhum, etc., and that acne, lupus, and eruptive disturbance or irritation due to animal parasites are uncommon. The rare diseases, xeroderma pigmentosum and idiopathic multiple pigmented sarcoma, appear to be observed more frequently in those of the Hebrew race.

Sex—Age.—The etiologic influence of **sex** is often noted. Lupus erythematosus, the milder types of acne rosacea, impetigo herpetiformis, and Paget's disease are more common in women, and the last two diseases are confined almost exclusively to this sex; whereas men are more frequently the subjects of epithelioma, the severer grades of acne rosacea, and the various occupation dermatoses; sycosis is obviously seen only in this sex. The influence of **age** is often shown; certain diseases are more frequently encountered at definite periods of life; some only at such times. Infancy, youthful development, mature growth, and old age all have their cutaneous vulnerabilities. In the first months or years are seen, beginning with birth or shortly afterward, pemphigus neonatorum, dermatitis exfoliativa neonatorum, the congenital syphilodermata, eczema, especially of the face or face and scalp, chicken-pox, and other exanthemata, impetigo contagiosa, ringworm of the scalp, etc.

Dentition occurring at an age of peculiar susceptibility is often given an important place as an etiologic factor, but while a disturbing element, with effects upon the nervous system, digestion, etc., and therefore also of nutritional and neurotic influence upon the skin, it is usually overrated. Lupus more commonly develops during childhood, and likewise urticaria and the erythemata are not uncommon.

During the age of puberty and maturing manhood acne and other diseases of the sebaceous glands, as seborrhea, are common, as at this period these structures are unusually active. During this time psoriasis usually first shows itself, and eczematous inflammation of the hands and forearms, excited by irritating substances incidental to various occupations or trades (trade eczema), frequently presents. At this time too, or later, sycosis in men is more commonly observed, and at this period of life lupus erythematosus likewise.

Diathesis.[1] **Organic and Constitutional Disease.**—The significance of the word diathesis is not clear, often indicating family tendency or predisposition, with an underlying, acquired or hereditary, susceptibility to such diseases as tuberculosis—**tuberculous** or **scrofulous diathesis** or **strumous diathesis**; or gout or rheumatism—**gouty diathesis, rheumatic diathesis, uric acid diathesis,** or **arthritic diathesis.** Certain diseases, such as furuncular, abscess-like, and atrophic types of acne, and some cases of eczema are often seen in individuals who appear to possess a scrofulous or tuberculous tendency or history, and which do well under appropriate remedies directed against this. The influence of the variously named rheumatic and gouty diatheses, arthritic diathesis, lithemia, and uric-acid saturation in the etiology of eczema, psoriasis, pruritus, etc., is not, I am sure,

[1] Hutchinson, *The Pedigree of Disease* (*Temperament, Idiosyncrasy, and Diathesis*), London, 1804; New York, 1885. In an interesting paper "On Cutaneous Affections in Various Diseases with Especial Reference to Certain Angio-neuroses," *Brit. Jour. Derm.*, 1906, pp. 305, 354, 387, and 417, Dore reviews the etiological influence of these various diseases referred to, and gives a full bibliography.

an unimportant one, and requires attention in the management of the cutaneous disease. The frequent and well-known association of rheumatic symptoms, especially with erythema multiforme, erythema nodosum, purpura, and other affections, is suggestive of a common etiologic cause or relationship. Other conditions shown by the **urinary excretion**, such as oxaluria, uric acid excess, diabetes, albuminuria, etc., are sometimes of direct or indirect etiologic influence in some cutaneous diseases. **Saccharine diabetes** is seen in connection with xanthoma diabeticorum, and improvement or temporary abeyance in the sugar loss means a partial or complete recovery from the skin-lesions. The association of diabetes with boils, carbuncles, pruritus, eczema, dermatitis herpetiformis, and some other affections has been not infrequently noted, and the influence of the conditions underlying albuminuria upon cutaneous processes, as eczema, pruritus, chronic urticaria, and the like, is likewise of importance; such relationship has received particular attention by Bulkley,[1] Kaposi,[2] Thibiérge,[3], Gamberini,[4] Winfield,[5] Hartzell,[6] Sherwell,[7] and others.

Organic and functional disturbances of the **uterus** and **utero-ovarian system**[8] are sometimes of evident import in the erythemata, acne, acne rosacea, chloasma, and other disorders, probably through their direct or indirect influence upon the nervous and vasomotor system, and even in the male urethral irritation, through reflex action, has been thought to play an occasional part in erythema multiforme, and is even suspected of influence in some cases of acne.[9] The erythemata occasionally seen in the course of gonorrhea, independent of possible drug rashes, are possibly thus to be explained; or they may be attributable to absorption of the toxic products of the organisms.

Both sexual excess and sexual continence—directly antagonistic conditions—have been blamed for acne and some other affections, but with questionable evidence; the former doubtless by its disturbing or depressing influence on the nervous system might be an indirect factor in some maladies.

During the active sexual life the periods of **pregnancy** and **lactation** are sometimes contributory factors, and outbreaks of eczema, psoriasis, and dermatitis herpetiformis are of relatively frequent

[1] Bulkley, "The Relations of the Urine to Diseases of the Skin," *Arch. Derm.*, 1875–76, p. 1.

[2] Kaposi, "Ueber besondere Formen von Hauterkrankung bei Diabetikern," *Wien. med. Presse*, 1883, p. 1605.

[3] Thibiérge, "Des Relations des Dermatoses avec les affections des reins et l'albuminurie," *Annales*, 1885, pp. 424 and 511, with numerous references.

[4] Gamberini, "L'urina in rapporto colle dermopatie," *Giorn. Ital.*, 1884, H. 3, May–June; brief abstract in *Monatshefte*, 1884, p. 313.

[5] Winfield, "Glycosuria in Dermatitis Herpetiformis," *Jour. Cutan. Dis.*, 1893, p. 447.

[6] Hartzell, "Diseases of the Skin Associated with Glycosuria," *Internat. Clinics*, Oct., 1898; and "Cutaneous Diseases Accompanying Diabetes," *Jour. Amer. Med. Assoc.*, Jan. 26, 1901. Other references, including some in reference to gout and rheumatism, will be found in connection with special diseases.

[7] Sherwell, "Cutaneous Manifestations in Diabetes," *Med. News*, June 29, 1901.

[8] See paper by Duhring and Hartzell, in Keating and Coe's *Clinical Gynecology*, 1895, p. 978; and by Rohé, "Diseases of the Skin Associated with Disorders of the Female Sexual Organs," in *Buffalo Med. and Surg. Jour.*, Feb., 1889 (with references).

[9] Sherwell, *Jour. Cutan. Dis.*, Nov., 1884; Denslow, *Med. Record*, Nov. 7, 1885; Winfield, *Jour. Cutan. Dis.*, 1891, p. 93.

occurrence. At the menopause, urticaria, eczema, and other cutaneous diseases sometimes develop or are aggravated, although this physiologic transition period, like that of dentition, is often undeservedly blamed. In advancing years and old age, pruritus, keratoses, and epithelioma are most usually encountered.

In fact, the **nervous system**, as clinically observed and shown by the writings of Weir Mitchell,[1] Bulkley,[2] Mayer,[3] Leloir,[4] Schwimmer,[5] Crocker,[6] Winfield,[7] Zeisler,[8] Frick,[9] and others,[10] is probably of considerable import, not only in its effect upon distribution of eruptions, but also in its causal relationships. While we use the term "trophoneurosis" in connection with various diseases, our knowledge concerning the same, and the chain of evidence connecting cause and effect, are elementary and without much precise information or demonstrable facts.

The influence of the sympathetic system in diseases of the integument, the study of which is yet more or less academic, is probably a much more potent one than is commonly supposed. Some diseases, too, are doubtless influenced or caused by vascular dilatation, contraction, or fluctuation, due to irritation, stimulation, depression, or other action upon the vasomotor centers or nerves. Among affections in which the nervous system seems to be operative or contributory may be mentioned pruritus, glossy skin, Raynaud's disease, hyperidrosis, some cases of alopecia areata, scleroderma, herpes zoster, dermatitis herpetiformis, and pemphigus.

To the various morbid states of etiologic relationship already mentioned should be added **malaria**, which is, as pointed out by Yandell[11] and others, sometimes the active exciting cause, or certainly a not infrequent important contributory factor. The not uncommon association of chlorosis with the more marked types of seborrhea and with chloasma is suggestive of a possible predisposing influence, although it may be that they are simply associated manifestations of a common underlying cause.

The most potent conditions, however, in many cases, exciting or predisposing in character, are to be found in **digestive disturbance.** This acts by either reflex action or by, in some manner, interfering

[1] Weir Mitchell, *Injuries of Nerves and their Consequences*, Philadelphia, 1872.

[2] Bulkley, *Arch. Electrol. and Neurology*, Nov., 1874; May, 1875.

[3] Mayer, *De l'influence des emotions morales sur le developpement des affections cutanées*, Paris, 1876.

[4] Leloir, *Recherches cliniques et anatomo-pathologiques sur les affections cutanées d'originie nerveuse*, Paris, 1881.

[5] Schwimmer's *Die neuropathischen Dermatonosen*, Vienna 1883.

[6] Crocker, "Lesions of the Nervous System Etiologically Related to Cutaneous Disease," *Brain*, 1884, p. 343 (with numerous references).

[7] Winfield, "The Influence of the Nervous System in Skin Disease," *Med. News*, 1897, vol. lxxi., p. 174.

[8] Zeisler, "Trophic Neuroses Following Fractures," *Jour. Cutan. Dis.*, 1898, p. 418-

[9] Frick, "Influence of the Nervous System in the Production of Skin Diseases," *Kansas City Med. Index*, 1896, p. 386.

[10] Blaschko, "La topographie des nerfs cutanés et sa signification au point de vue dermato-pathologique," *Revue pratique*, 1906, pp. 131, 160, and 198 (an elaborate paper, with review of the subject, illustrated); Leredde, "Le rôle du système nerveux dans les dermatoses," *ibid.*, p. 5, contends that the rôle of the nervous system is overrated, or at least without substantial proof. Blaschko also inclines to the belief that we are holding too much to this factor.

[11] Yandell, "Malaria and Struma in their Relations to the Etiology of Skin Diseases," *Amer. Practitioner*, 1878, p. 18.

with metabolism, or by direct influence through the resulting nutritional impairment, or by the probably more frequent development of ferments or toxins,—**autointoxication**,—to which last Pick,[1] Hallopeau,[2] and others have directed attention. I am firmly convinced that this last is one of the most important causes, and probably the sole cause, in many instances of erythema multiforme, urticaria, and similar affections—developing spontaneously in the gastro-intestinal tract or as the result of the ingestion of food-products which had previously, or subsequent to their ingestion, undergone putrefactive or other change; and in the production of which constipation is often an important contributory factor.

Food—Drugs.—An improper diet, as well as either a too bountiful or a too meager supply, is a variously operative factor in many diseases of the skin, but whether such influence is direct or indirect it is difficult to say. Spoilt food is, as has just been intimated, probably often an unsuspected factor. It is doubtless owing to this that oysters, clams, crabs, lobsters, fish, and pork meats—foods that are apt to undergo rapid change and deterioration—occasionally provoke urticaria or erythema multiforme in individuals who can usually take these articles without the slightest evidence of disagreement. Often it is true **idiosyncrasy** to these or other foods, as strawberries, buckwheat, etc., which is not infrequently observed, that is the explanation, but in such cases the effect is constant and not occasional, as in the instances to which I have alluded. It is not improbable, however, that many of the opinions regarding the harmfulness of certain foods in diseases of the skin so firmly held by the laity, and also by members of the profession, are based upon examples of idiosyncrasy rather than upon a sufficient foundation of constantly observed facts.[3] Thus, oatmeal, as well as other foods, is commonly believed to be detrimental in diseases of the skin,—causative or instrumental in the continuance of the eruption,—and yet, gauged by common observation, it scarcely deserves so sweeping a judgment; idiosyncrasy or weakness in digestive power for starchy foods is the probable explanation. Foods or condiments of difficult digestion or that are too stimulating, such as cheese, pastries, pork meats, veal, spices, mustard, pepper, pickles, excessive use of coffee or tea, etc., are certainly to be avoided, if for no other reason than that they are disturbers of digestion, with the resulting consequences. They are to be considered of possible etiologic import in some, and doubtless in many, cases; and, moreover, indigestion means frequently the more ready development of stomachic and intestinal toxins.

The causative action of the ingestion of certain **drugs** in the production of various cutaneous efflorescences and even suppurative and more serious action is well known, as a glance at the subject of

[1] A. Pick, "Ueber die Beziehungen einziger Hauterkrankungen zur Störungen in Verdauungstracte," *Wien. Med. Presse*, 1893, p. 1213.

[2] Hallopeau, "Des toxines en dermatologie," *Annales*, 1897, p. 854.

[3] See interesting papers by J. C. White, "An Introduction to the Study of Influence of Diet in the Production and Treatment of Skin Diseases," *Jour. Cutan. Dis.*, 1887, pp. 409 and 436; also by the same author, "What Effect do Diet and Alcohol have upon the Causation and Course of the Eczematous Affections and Psoriasis," *Trans. Amer. Derm. Assoc.*, 1896; and by Corlett, "Diseases of the Skin due to Defective Alimentation," *Med. Record*, 1888, 2, p. 172.

"dermatitis medicamentosa" will readily prove. The drugs capable of such action are almost innumerable, among which, as being probably best known, may be mentioned the bromids, iodids, copaiba, quinin, together with many others. With some the action is more or less constant, with others, due to individual idiosyncrasy. Alcohol often exerts a detrimental influence, more especially if indulged in to any great extent, probably through its dilating action upon the cutaneous capillaries. Doubtless in its abuse, its disturbing influence on digestion, liver, and kidneys is partly responsible for its untoward action in some dermatoses, notably those of an inflammatory type.[1]

EXTERNAL INFLUENCES.

It is not unlikely that external causes constitute important, and often unsuspected and unrecognized, factors in many diseases—in some being the exclusive factors, in others exciting or contributing, and supplementary to some underlying constitutional or integumentary condition or state. They will be considered more specifically in connection with the subjects of eczema and dermatitis, as well as with other affections in which they may play a part. Climate, season, and habitation, already touched upon, may be considered, in a measure, as external causes, but the effect is chiefly due to their action or influence upon the general health, vigor, or nutrition, and are therefore more properly considered among the general etiologic factors.

Personal Hygiene.—There is a prevalent belief that skin diseases as a whole are indicative of filth and uncleanliness, and no one can gainsay that such have some effect as contributing factors in some of the cutaneous eruptions among the poor and uncared-for. These factors naturally tend to make the distinctly parasitic affections more numerous with such classes. They are, however, more than set off by the habits, customs, and overfeeding—in themselves matters of hygiene, which have already been considered—of the luxurious, and by the active life and tension of the middle and upper strata of society. Compared to the number of affections or cases due to mental or physical exhaustion, occupation, and luxurious indulgence, those in which filth and uncleanliness are the chief agents are not conspicuously numerous. Extreme cleanliness—the too free or injudicious use of soap, water, Turkish baths, etc.—is also sometimes responsible for the production or aggravation of certain integumental diseases, as chafing, miliaria, dermatitis, eczema, and some others. On the other hand, scant use of such measures, not necessarily to the point of absolute uncleanliness, is sometimes an element in seborrhea, acne, keratosis pilaris, and a few others.

Another possible cause that can here be referred to is the **clothing.** "Too much clad," as in babies, during the hot weather, is often responsible for miliaria and its not infrequent associated consequence, furuncles, in such subjects. And this alone, or together with the rough or coarse flannel usually worn, will sometimes, in the working-

[1] See J. C. White's paper, *loc. cit.*, and that by Janin, *De l'influence de alcoolisme sur le développement et l'evolution des affections cutanées*, Paris, 1881.

classes, result in the production of a mild dermatitis, pruritus, or an eczema, as well as favor the affections just mentioned. This is especially so when the garment worn next the skin is dyed, owing to the added irritant properties common to some dye-stuffs; some individuals are much more susceptible than others. Moreover, the sweat saturation with the resulting uncleanliness of the garment is a favoring factor in seborrhœa corporis, and its near ally, eczema seborrhoicum, as well as in tinea versicolor. Hutchinson,[1] Foley,[2] and others have called attention to several of these factors.

Chemical and Mechanical Irritants.—These embrace a large number of external factors that are often of etiologic importance, and which will be again more or less specifically mentioned under dermatitis. The irritating effect of different plants with many persons, and the irritating action of many drugs, such as iodoform, turpentine, and others, are well known. The action of dye-stuffs in connection with wearing apparel has already been mentioned; their irritating effects are also frequently seen on the hands and forearms in workmen—dyers—who have to do with such employment. Indeed, the effect of **occupation**—occupation dermatoses—is frequently observed in dermatologic practice. The dermatitis or eczema due to such causes, as observed in polishers, plasterers, bakers, grocers, and others in the course of their work, and directly attributable to the irritating action of the materials with which they are engaged, is quite common, and concerning which many writers—among others, Foley and Lassar[3]—have made journal contributions. The latter observer particularly called attention to surgical eczema, or dermatitis which is observed in surgeons and nurses as the result of the constant vigorous soap-and-water scrubbing and the free use of antiseptics, many examples of which have come under my own observation. The irritation due to the constant use of strong soap and water is also seen in the washerwoman. The possibility of occupation with animal products giving rise to greater chance of poison wounds, malignant pustule, and such affections has often been shown.

Those who are exposed to **heat** and **cold** are also more liable to certain affections, especially eczema, pruritus, etc.[4] The action of prolonged exposure to the actinic rays of the sun upon some skins, and the action of heat in the production of miliaria, and of cold and wind in causing frost-bite, favoring eczematous irritation and rosacea, are well known. Prolonged **scratching**, as in pediculosis corporis and in pruritus, occasionally gives rise to a dermatitis or an eczema, and also opens up the tissues to local infections by pus-cocci, etc.[5]

Parasites.—At the present day one need scarcely enlarge upon the etiologic aspects of this cause; nor is it necessary to enumerate the large number of diseases that, in a broad sense, might be placed

[1] Hutchinson, *Arch. of Surgery*, vol. ii., 1890–91, plate 23 (from dyed undershirt).

[2] Foley, "The Influence of the Clothing on the Skin," *Montreal Med. Jour.*, vol. xix., 1890–91, p 406.

[3] See under dermatitis and eczema for literature references.

[4] See valuable contributions on this subject by Hyde, "On Affections of the Skin Induced by Temperature Variations in Cold Weather," *Chicago Med. Jour. and Exam.*, March, 1885, and Feb., 1886, and by Corlett, *Jour. Cutan. Dis.*, 1894, p. 457.

[5] Klotz, "The Infected Scratch and its Relations to Impetigo and Ecthyma," *Jour. Cutan. Dis.*, 1896, p. 46.

under this etiologic heading. To the parasitic affections produced by the grosser animal and vegetable parasites, such as scabies, pediculosis, favus, ringworm and others, could be added numerous others due to the lower micro-organisms,[1] such as impetigo, furuncle, tuberculosis cutis, leprosy, etc. Absolute and conclusive proof as to the alleged cause and effect is still wanting in connection with the by-far larger number of the diseases presumably due to micro-organisms, but no one can deny their growing importance in the etiology of disease, and the great value of original investigation in this direction.

With the advent of this etiologic element the subject of **contagion** has naturally been pushed into the foreground, and an expression of opinion on this point in a particular disease is often hedged about with difficulties. While admitting the probable parasitic origin of many diseases, and the inferential deduction of communicability that naturally follows, still observation shows that in many instances, more especially in those in which the disease is presumably due to the lower organisms, contagiousness does not seem to be even suggestively demonstrated in practice—at least not with any degree of certainty. In many diseases, therefore, for which we even now accept a parasitic factor we must assume that favoring conditions of the systemic state or the local tissues exist, and without which the successful invasion or pathogenic multiplication of the micro-organism fails or remains harmless. Even prolonged exposure, unless conditions are favorable, is in many such diseases without result; the vegetable parasitic affection, tinea versicolor, judged by clinical experience, is only in the rarest instances communicated from husband to wife or the reverse, and yet the fungus exists in abundance and is readily demonstrable. Nor, apparently, is every person to the same extent a *persona grata* to even the more active animal parasites—bedbugs, fleas, and even the louse and itch-mite, although the last two are the least fastidious as to the character of their prey. Apparently some inherent peculiarity of the skin or the odor of its secretions measurably protects some individuals against successful parasitic invasion.

[1] Among valuable contributions on this subject may be mentioned those by Payne "Bacteria in Diseases of the Skin," *Lancet*, 1896, vol. ii., p. 1; Elliot, "The Rôle of the Pus-organisms in Skin Diseases," *Trans. Amer. Derm. Assoc. for 1899;* and *Jour. Cutan. Dis.*, 1900, p. 49, with many literature references; Gilchrist, "Bacteriological and Microscopical Examination of Vesicular and Pustular Lesions of the Skin," *Trans. Amer. Derm. Assoc. for 1899;* C. J. White, "The Rôle of the Staphylococci in Skin Diseases," *Boston Med. and Surg. Jour.*, 1899, 2, p. 235, with bibliography. Other references will be found in the course of the text in connection with the special diseases.

GENERAL PATHOLOGY.

While pathology, in the correct and widest employment of the term, includes practically everything concerning the study of disease, by common sanction its meaning is considerably narrowed, and now refers, in the main, to facts to be gleaned from microscopic and bacteriologic examination. To the knowledge thus gained, however, are to be added other facts that throw any light upon the nature of the disease and the morbid processes that characterize it, such as macroscopic features and mode of growth, character of the contained fluids, as in vesicular, bullous, and similar diseases, examination of the urine, etc. These all aid in a final conclusion. It is needless to say that the study of pathologic anatomy must primarily be based upon a well-grounded knowledge of normal histology. The feeling shared by many students and physicians, judged by lack of interest, that in the study of morbid structures and processes the pathologic anatomy of the skin occupies an obscurely subservient position, scarcely to be considered except by the dermatologic specialist, is one difficult to explain in view of the knowledge that its investigation has disclosed. We have to do with a structure subject to almost all the phenomena found in connection with internal organs—hyperemia, inflammation, hypertrophies, atrophies, neoplasms, the character, behavior, and effects of micro-organisms, etc., and that can be the more clearly studied, not only in full development, but in various stages as well, and in tissues that are obtainable during life, and therefore not subject to the changes and consequent errors of observation and deduction necessarily connected with the examination of tissue from the dead. A thorough study of the commoner pathologic processes in this structure should not, therefore, be left to the specialist alone; the teacher of pathology can find no tissue so well adapted for the elucidation of the elementary and more important morbid changes to the student mind, and no structure whose careful study of its various diseases will throw so much light upon the problems of pathology in general. Indeed, in its general features cutaneous pathology can scarcely be said to differ from that of other organs, although, as would naturally be suspected, its nearest kin in this respect is that of the neighboring stratified epithelial surfaces—such, for instance, as the tongue.

The value of pathologic studies in cutaneous diseases, in adding to our knowledge of the nature of the cutaneous malady, its anatomic seat, the morbid changes, and its causes, has already been demonstrated repeatedly. The significance of the grosser fungi and the small micro-organisms has gradually been gaining greater and greater recognition, and on these lines the clinician looks for future suggestions of increasing value for treatment, and also for the prevention of diseases in which these organisms hold a pathogenic relationship.

Pathology and etiology are closely united, and one bears materially upon the other, and their elucidation bears just as strongly upon the subject of the therapeutic management. The various

exciting and contributory causes that give rise to the pathologic local alterations and appearances have been referred to in etiology, and the initial step in the local action leading to these changes may be in the vessels, nerves, rete, upper part of the epidermis, the corium, especially the papillary layer, in the glandular structures or the deeper tissues. The papillary layer and the rete are important cutaneous structures, and their involvement, either primarily or secondarily, a common occurrence in cutaneous pathology, the latter the starting-point of epithelial new growths. The hairs and nails are also sometimes the seat of certain changes. Not only, however, may the disease take its origin in some particular division of the skin, and from a particular constituent of this division, but also from a special part of this constituent: it may be in the cells themselves, in their protoplasm, in the interstitial tissue, fibrous tissue, elastic tissue, collagen, muscular fibers, endothelium, or other component. The changes may be simply congestive, inflammatory, atrophic, hypertrophic, neoplastic; show hyperemia, exudation, and infiltration, hyperplasia, with new-tissue formation or degeneration. Depending upon its character, seat, and limitations, it may appear merely as a diffused change, or it may result in wheals, papules, vesicles, pustules, blebs, or destructive alterations, often with secondary changes as a direct consequence of the process itself, or partly or wholly from external or accidental factors.

The presence of micro-organisms, scantily or in numbers, in the involved tissues of certain diseases can usually be readily demonstrated, sometimes, however, requiring special preparation and staining, and the corroboration of culture experiments; the grosser parasites are easily shown by moderate power, the lower organisms often requiring extremely high magnification.

An attempt has been made in the following pages to present the chief data and gross features concerning the pathology and pathologic anatomy, somewhat briefly from necessity, but not to the extent, it is hoped, of the omission of details for a proper comprehension of the essential characters. The subject, however, in recent years has broadened to such an extent that the writer of an average-sized volume on cutaneous medicine, desirous of making it full in its practical working parts, can scarcely present the histopathologic matter in the manner and to the extent that might be wished, unless peculiarly gifted in the art of selecting the essence from the mass of material and expressing it in terse, clear-cut, but yet readily understandable, manner. The reader desirous, therefore, of going further into this branch of the subject is referred to Unna's treatise on the histopathology, to Leloir and Vidal's histologic atlas, and to Macleod's recent handbook on the Pathology of the Skin and to the various monographs referred to in the course of the text.

GENERAL DIAGNOSIS.

It is needless to say that without the ability to make a diagnosis in cutaneous diseases the management of the case in hand is haphazard, unscientific, and culpable. Apparently it is the most difficult part of the subject to the student and practitioner, and yet one in which the seeming difficulties, if some careful thought and study, combined with moderate clinical facilities for observation, be given to it, will, as regards the commoner diseases,—those with which the physician is most likely to come in contact,—soon disappear. Text-books cannot, however, take the place of clinical opportunities, but with a relatively small amount of the latter, and especially with the added advantage of good atlas illustrations or cuts, book study is of great service in furthering and increasing the knowledge thus gained. This presupposes, of course, a clear idea of the characters and nature of the elementary and consecutive skin-lesions—the *a b c* of dermatology. So much knowledge and training possessed, subsequent errors are commonly due either to negligence or to lack of thoroughness in the examination, or to the rarity or anomalous character of the disease.

For diagnosis are required a good light, a good eye, and a good microscope. The first two are essential; the last is in many instances supplementary, but in some cases, as in determining the nature of tumors and growths, and in detecting the presence of parasites, it is indispensable. In fact, its great value in studying pathologic processes cannot be too highly appreciated. In the examination of the eruption gas-light is not satisfactory, as the color and other characters of the efflorescences are obscured. He who would guard against error must also insist upon seeing the whole or at least the greater part of the eruption, for not infrequently the disease in a patch, area, or region may be somewhat atypical or not wholly clear, and yet upon other parts be so characteristic that all doubt vanishes. According to my observations regarding students and practitioners, the failure to recognize the disease most often hinges upon the laxity as to this point, and most of my own earlier mistakes were likewise due to this cause. To avoid this pitfall, therefore, *a large portion, and in doubtful or obscure cases the whole eruption, should be inspected.* The word of the patient is not to be accepted in lieu thereof, for this, especially when the eruption is on covered parts, to save trouble or exposure or unintentionally from ignorance as to the existence of other spots, areas, or patches, is frequently unreliable. For example, the scalp may show a scaly eruption not always readily differentiated from eczema or seborrhea, and yet bearing some suggestion of psoriasis; if the latter, small spots or patches will almost surely be on other parts, especially the extensor surface of the knees or elbows, ill developed, perhaps, and yet their existence, even if of scarcely noticeable character, and probably wholly overlooked by the patient, will, in almost all instances, be a conclusive factor in favor of psoriasis. Full inspection discloses, moreover, the

distribution, the color, evolution of the lesions, tendency, if any, to patch formation, scaliness, etc. The temperature of the room should be that of a comfortable living-room, as cold especially is apt to cause a confusing paleness or mottling, and sometimes materially changes the color of the lesions.

The *distribution* is of great importance from a diagnostic standpoint, and especially when considered in connection with an associated factor, such as sex, age, duration, and the presence or absence of subjective symptoms or some other features. Pye-Smith[1] and, following him, Hardaway[2] are, I believe, the only writers who have sufficiently emphasized this valuable factor in diagnosis, the former also using diagrammatic drawings for this purpose.

Some regions are especially liable to certain affections, and free or relatively so from many others, and this fact, known to its fullest extent, will often immediately narrow the diagnostic possibilities down to a comparatively small number of diseases, and the chance for error is accordingly reduced; the differentiation can be then made by a consideration of the other factors or features of the case. *Duration* is of considerable import, and on this score inquiry can be made before inspection. *History*, though often valuable, is, as a rule, apt to be misleading in many instances, except with patients of keen perception and unusual intelligence, and, upon the whole, is best reserved for a supplement to the objective examination. The character of the *lesion* is to be noted, as determined by sight and touch, and its method of growth or formation, whether erythematous, papular, vesicular, etc., and if uniformly so or mixed with other lesions; and whether there is any tendency to special *grouping* or *configuration*, or any disposition to *atrophy*, *ulceration*, and *scarring*. The presence or absence of *itching*—usually disclosed, if intense in character, by excoriations—is sometimes a factor of value.

Moreover, the age, social position, and environment of the patient may occasionally be of some moment. For instance, in infants and young children eczema of the face and scalp is quite frequent, and inflammatory disease of any duration in these parts can usually, therefore, be set down as this affection. Lupus vulgaris and the scrofuloderm having its origin in the cervical glands usually present in childhood; and miliaria, erythema intertrigo, and impetigo contagiosa are also most common at this period. Acne is common to growing youth; sycosis and trade eczemas—usually of the hands—to the active working period of life, while in advancing years pruritus, eczema of the legs, face, and epithelioma, and some of the other grave diseases, are more frequent. Ringworm of the scalp, quite common in children, is a rare anomaly in the adult, and may be considered as practically never occurring in the latter. Parasitic diseases are, as is to be expected, more prevalent among the lower and poorer classes. Syphilis is also more frequent among this class, and the late tubercular syphiloderm much more so, owing to the less persistent treatment followed by this class of patients. Some diseases are more common in the one or the other sex, and a few are practi-

[1] Pye-Smith, *Diseases of the Skin*, 1893.
[2] Hardaway, Morrow's *System*, vol. iii. (Dermatology), p. 48.

cally limited to males, a few to females, but, upon the whole, this is of but little value in diagnosis.

The value of a *conspicuous feature or symptom*, if present, in the case is also very great, usually bringing the diagnosis within three or four diseases, as in those cases where the malady is upon the scalp, and of which a striking symptom is a patchy loss of hair; or in cases, say on the face or elsewhere, where ulceration, or its result, scarring, is an associated factor. With these preliminary remarks the diagnosis may now be considered from several of the standpoints named.

DISTRIBUTION AS A DIAGNOSTIC FACTOR.

Scalp.—In infants and young children the *visibly inflammatory* (quite red, sometimes infiltrated) diseases commonly met with and in which there is, as a rule, no hair loss and never patchy hair loss, are eczema, eczema seborrhoicum, impetigo contagiosa, and pediculosis; non-inflammatory, or seemingly so—ordinary seborrhea, alopecia areata, and some cases of pediculosis; slightly or moderately inflammatory, sometimes scarcely visibly so, and with patchy hair loss—ringworm, favus. In children of moderate age the same diseases, with the possibility of psoriasis mildly to markedly inflammatory. Rarely, also, boils, cutaneous abscesses, and syphilis might possibly be seen. In youth and adults the same diseases as above except ringworm, and only exceptionally impetigo contagiosa; but also frequently alopecia, exceptionally lupus erythematosus and epithelioma, and some rare diseases. The most frequent diseases are eczema, eczema seborrhoicum, seborrhea, ringworm (except in youth and adults), alopecia areata, psoriasis, and pediculosis (usually in dispensary practice).

Face.—In infants and young children eczema and impetigo contagiosa are common, especially the former, and constitute the bulk of the cases. Eczema seborrhoicum, ringworm, miliaria, seborrhea, herpes simplex, herpes zoster, and milium, furuncles, or cutaneous abscesses occasionally; lupus vulgaris somewhat rarely; syphilis is possible, and pigmentary and vascular nævi are not uncommon. In older children about the same, but lupus vulgaris and other scrofulodermata less rarely; freckles are common, erysipelas occasional, and rhus poisoning is not infrequent. In youth and adults the same, but miliaria practically never, except in connection with a generalized outbreak; impetigo contagiosa relatively seldom, herpes simplex and ringworm less frequently; but milium, seborrhea, eczema seborrhoicum, syphilis, rhus poisoning, and erysipelas are more common. Other diseases observed are comedo, acne, acne rosacea frequently; epithelioma and lupus erythematosus occasionally, and hydrocystoma rarely. In the **bearded and mustache region** of the male adult, sycosis, alopecia areata, and ringworm (tinea sycosis), and in this region, as well as about the **eyebrows** and nose, eczema seborrhoicum is not uncommon. The brow is the common situation for chloasma, and also, usually, conjointly with the scalp, for that rare disease, acne

varioliformis. On the **eyelids,** xanthoma, and this and neighboring skin are the common seat of milium; eczema about the edges, and also rarely pediculosis; at the inner canthus epithelioma often originates. The **eyebrows** may also be the seat of alopecia areata and rarely pediculosis. The **nose and immediate neighborhood** are the usual site of acne rosacea, lupus erythematosus, and a not uncommon situation for tubercular syphiloderm and lupus vulgaris, epithelioma, seborrhea, and eczema seborrhoicum, and the usual location for the rare affection, adenoma sebaceum. At the edge and within the **nostril orifice,** sycosis (folliculitis), impetigo contagiosa, herpes simplex, eczema, and furuncles are not infrequent; lupus vulgaris, syphilitic eruption or ulceration, and epithelioma, not infrequently begin here, as well as rhinoscleroma, an exceedingly rare affection. The **lips** are often the seat of eczema, herpes, and, especially at the angles, syphilis, and the initial lesion is occasionally observed here; the lower lip is a common site for epithelioma. On the **ears,** the most frequent diseases seen are eczema, eczema seborrhoicum, lupus erythematosus, tubercular syphiloderm, lupus vulgaris, and epithelioma.

Psoriasis and other usually more or less generalized diseases are never seen limited to the face, nor the rarer diseases, lichen planus, pemphigus, etc. In countries where leprosy is not uncommon this region, especially the brow, is frequently one of the first to show the disease. The most frequent benign or practically non-destructive diseases upon the face in youth and adults are eczema, acne, acne rosacea, seborrhea, eczema seborrhoicum, and, in our country, dermatitis from rhus plants. The most frequent malignant or destructive diseases—characterized by atrophy, ulceration, and scarring—are syphilis, lupus erythematosus, epithelioma, and lupus vulgaris.

Neck.—In children intertrigo is common, usually anteriorly, and eczema resulting from this or arising spontaneously is not infrequent; occasionally ringworm is observed, and also scrofuloderm beginning in the cervical glands just beneath the angle of the jaw. In growing youth and adults eczema, acne lesions, ringworm, and, at the upper (hairy) part, sycosis; impetigo contagiosa is also occasionally seen; at the nape, furuncles are common, and carbuncles are not infrequent; occasionally also herpes zoster extending up on to the face or down on the shoulder and arm is observed.

Arms.—Eczema not uncommon; herpes zoster and tubercular syphiloderm occasional. Extensor surfaces, especially at the **elbow** or most marked at this region: Psoriasis, ichthyosis, and very exceptionally xanthoma lesions; on the flexor aspects eczema, and exceptionally xanthoma. Below the elbow, on the **forearm,** particularly the flexor surface, lichen planus; and on the dorsal aspect, usually extending over the hand also, the papular type of erythema multiforme. Ringworm is not unusual in this situation. Eczema is quite commonly seated conjointly on the lower forearms and hands. The arms frequently share in other more or less generalized diseases.

Hands.—Dorsal surface, papules and rings of erythema multi-

forme, usually extending part way up the forearm; and also lichen planus, ringworm, eczema, and very rarely lupus erythematosus, tuberculosis verrucosa cutis, blastomycetic dermatitis; and occasionally tubercular syphiloderm, and in those of advancing years, epithelioma. On the palmar aspect eczema, pompholyx, callositas, keratosis palmaris, bullous erythema multiforme; and syphiloderm, usually of squamous character. Involving all the parts more or less, but generally especially pronounced about the fingers and the interdigital surfaces—eczema, pompholyx, and scabies, the last, however, only in association with the eruption elsewhere. This region, alone or with the forearms, and sometimes the face and other parts, is the seat of rhus poisoning and other forms of dermatitis. The rare affections, dermatitis repens and erysipeloid, are also usually seated here. The fingers alone are sometimes the seat of eczema, pompholyx, and frost-bite. The dorsal surfaces of the hands and forearms conjointly with the face are, as a rule, the seat of the bullous iodid eruption.

Axilla.—Eczema, eczema seborrhoicum, ringworm (eczema marginatum), and furuncles; the lesions of scabies are usually quite numerous here, especially in the folds. This is also one of the usual sites for the rare disease, erythrasma.

Chest.—Tinea versicolor, frequently extending down over the lower part of the trunk, in the axillæ, and occasionally in the groins and flexures of the elbows and knees, and exceptionally on to the neck and upward. The chest region, especially the sides, is also the starting-place in pityriasis rosea. Anteriorly and posteriorly, one or both, especially in the sternal and interscapular regions—seborrhœa corporis, eczema seborrhoicum. Over the sternum, keloid; eczema, especially in women about the nipple; and under the breast, frequently beginning as intertrigo. Lesions of scabies are usual about the nipple in connection with their presence in other regions. The mammary gland is, as known, a common seat for carcinoma, and the areola and nipple for eczema and Paget's disease. Posteriorly, and over the shoulders, acne lesions are common; and over the shoulders and upper part of the back the excoriations and lesions of pediculosis corporis are usually most numerous. The side of the thorax region is one of the most frequent sites for herpes zoster, and an occasional one for the tubercular syphiloderm. The upper part of the back is a not unusual site for carbuncle.

Abdominal Region.—This, as all other regions, may be the seat of eczema, and the umbilicus is a favorite site; and this latter region, as well as the lower part of the abdomen, commonly shares in the eruption of scabies. Most of the cutaneous irritation in pediculosis pubis is about the pubes and lower abdomen. The side of the abdominal region, like that of the thorax, is not infrequently the seat of herpes zoster. The **trunk**, as a whole, is the chief, and sometimes the sole, seat of pityriasis rosea and tinea versicolor; and in common with other parts of the surface usually shares in the general eruptive diseases, such as urticaria, lichen planus, pityriasis rubra pilaris, syphilis, pruritus, erythema multiforme, dermatitis herpetiformis, pemphigus, the exanthemata, etc.

Nates.—The eruption of congenital syphilis is often pronounced here, and this region also usually shows an abundance of lesions in scabies, especially at the anal cleft and in children. It is also a favorite situation for furuncles; and in urticaria often exhibits the most pronounced and the most itchy wheals. The **anus** is a frequent site for eczema, pruritus, moist papules, and occasionally acuminated warts.

Genitocrural Region.—Erythema intertrigo, eczema, eczema seborrhoicum, pediculosis pubis, rhus poisoning, usually numerous lesions in scabies, ringworm (eczema marginatum), and erythrasma. The **scrotum**—a part of the genitocrural region—usually shares in the eruptions just named, but may alone be the seat of diffused or follicular eczema, pruritus, ringworm, furuncles, and elephantiasis. The same can be said of the **penis,** on some part of which syphilis generally has its starting-point, and on which also several or more lesions in scabies are to be found; herpes simplex is usually limited to the **glans** and **prepuce.** The **vulva** is likewise the seat of the same diseases as observed in the male, pruritus and eczema being the usual ones; lupus vulgaris is also exceptionally seen here, and also the rare affection kraurosis vulvæ. Both the penis and vulva are occasionally the seat of epithelioma.

Leg.—On the upper part, or **thigh,** on its front and outer aspects, keratosis pilaris; usually here alone, but occasionally conjointly with it here, is also seen on the outer and posterior portions of the arms and exceptionally elsewhere. On the same aspects of the thigh also the lesions of pediculosis corporis are relatively numerous, while the inner sides usually share predominantly in the scabies eruption. The thigh is not uncommonly the seat of a sycosiform or follicular, sometimes almost furuncular, eczema. The extensor surface of the whole leg shows marked involvement in prurigo and ichthyosis, the latter more especially well marked at the **knee.** This latter region is also, usually conjointly with the elbows, and in most cases other parts, a common seat for psoriasis lesions. The **popliteal space** is frequently alone or one of several involved regions in eczema. Below the knee purpura lesions are usually most numerous, with, as a rule, some but relatively less abundant above the knee, and not infrequently upon the forearms, and occasionally more or less generally. The tibial surface is the favorite one for erythema nodosum, and the sides and posterior aspects for the rare affection, erythema induratum. By far the most common, and, one might readily say, the usual, disease of this region (lower part of the leg) is eczema, frequently associated with varicose veins, and occasionally originating in a dermatitis from the coloring-matter of the stockings. It is also a frequent situation for that relatively infrequent disease, lichen planus. Leg ulcers of all kinds, traumatic, varicose, and syphilitic, are often seen here. The legs are also common locations for pruritus, especially pruritus hiemalis and bath pruritus.

Foot.—Eczema, callositas, keratosis plantaris, pompholyx, the last two usually on the soles alone, occasionally extending up over the sides; in the latter region, also, hyperidrosis, with erythematous, soggy edges. The toes and the interspaces are often the seat of eczema, and likewise usually share in the scabies eruption.

More or Less Generalized.—Most common: Eczema, exanthemata, psoriasis, urticaria, erythema multiforme, secondary syphilodermata, pediculosis corporis, scabies, pruritus, medicinal eruptions. Less frequent: Ichthyosis, miliaria, sudamen, eczema seborrhoicum, dermatitis herpetiformis, rhus poisoning, pityriasis rubra pilaris, lichen planus, granuloma fungoides, multiple pigmented sarcoma, purpura, scleroderma, xanthoma diabeticorum.

Universal.—Eczema, psoriasis, ichthyosis, erythema scarlatinoides, dermatitis exfoliativa, pityriasis rubra pilaris.

DURATION AS A DIAGNOSTIC FACTOR.

Many cases of skin disease are, as to duration, essentially chronic; others are more or less acute. This fact can sometimes be utilized in diagnosis, for very often when patients come under observation the malady has already been of some days' or weeks' standing, and if so, if no spontaneous tendency to natural defervescence has set in, the diseases of short duration, which the one in hand may resemble, may ordinarily be shut out in the diagnosis, unless the malady is evidently kept up by a continuance of the causative factors, as is possible in erythema intertrigo, miliaria, dermatitis medicamentosa, and some others.

To illustrate how this factor sometimes comes into play, take impetigo contagiosa and eczema, which sometimes present a close resemblance. Both are common in infants and young children, the former more especially in the dispensary classes. If the duration has been more than ten days or two weeks, and still with no apparent tendency to spontaneous subsidence, it is probably eczema; if of more than one or two months' duration, surely so. The same as to eczema and rhus poisoning, the latter so common with us during our season of vegetation. Another application of this fact is in the differentiation between psoriasis and the secondary general papulo-squamous syphiloderm; if the patient's eruption is more than of several months' duration, the latter diagnosis becomes less probable; if a year or more, absolutely excluded.

The **short-duration eruptions,** those scarcely exceeding several weeks' duration, and sometimes much less, are, it is true, relatively few, but among these usually are: Acute circumscribed edema, dermatitis medicamentosa, ecthyma, erysipelas, erythema intertrigo, erythema simplex, erythema scarlatinoides, furuncle, herpes simplex, herpes zoster, impetigo contagiosa, miliaria, urticaria, rhus poisoning, and other cases of dermatitis due to temporary chemical, plant, or other irritant; and frequently erythema multiforme, erythema nodosum, and ringworm of the non-hairy surface.

The **moderate-duration eruptions,** scarcely exceeding one or two months or by that time showing a spontaneous tendency to disappearance, excluding those of variable and possible or probable chronicity, are: Dermatitis exfoliativa (some cases), erythema multiforme, erythema nodosum, pityriasis rosea, pompholyx, purpura (some exceptions), ringworm of the non-hairy surface, and most cases of the secondary syphilodermata.

TYPE OF ERUPTION AS A DIAGNOSTIC FACTOR.

It is superfluous to say that it is unnecessary to consider eruptions of a vesicular, pustular character, etc., in the diagnosis of a case in which the rash is distinctly papular. The type of lesion is therefore often of great service to the student, as well as to the practitioner, in bringing the disease within reasonable proximity to a correct diagnosis. To a limited extent this subject was touched upon in describing the lesions of the skin, but an elaboration and a tabulation of the different more common maladies upon this basis will prove of value. The size of the lesions, region, and other characters and features calculated to be of some additional aid will be parenthetically commented upon.

Erythematous eruptions may be: Common: Eczema (usually with slight scaling; about face if acute, sometimes simulating erysipelas), erythema simplex, erythema intertrigo, erythema multiforme (usually mixed with other forms), dermatitis (as from ivy, chemicals, sun's rays, etc.), scarlet fever, measles, rötheln, erysipelas (usually face, with considerable edematous swelling and sharply marginate border, and constitutional disturbance), medicinal eruptions (especially from copaiba, quinin, belladonna, chloral, opium, etc.).

Rare: Erythema scarlatinoides.

Erythematopapular.—Common: Erythema multiforme (usually dorsal surface of forearm and hands), urticaria (more or less general), insect-bites.

Rare: Dermatitis herpetiformis (occasionally or at times), measles (occasionally), varicella (earliest stage), variola (earliest stage).

Papular.—Common: Eczema (small, usually aggregated or confluent, and commonly regional; itchy), miliaria—prickly heat (small, and usually in infants and young children; often itchy), keratosis pilaris (small, discrete; thighs, outer aspects), erythema multiforme—papular variety (large and usually backs of hands and forearms, often crowded together; rarely itchy), milium (small, whitish, cystic, discrete; commonly about eyelids), papular syphiloderm (general, small or miliary variety, often with tendency to group; large variety irregularly scattered; dark red or ham colored), acne (face, sometimes shoulders; small or large, discrete, usually mixed with pustules), acne rosacea (nose and immediate neighborhood, associated with passive hyperemia and often capillary dilatation), sycosis vulgaris (bearded region—male; associated generally with a predominance of pustules)

Occasional: Lichen planus (usually flat, dark colored, sometimes slightly umbilicated; tendency to aggregation or confluence, with scaliness; itchy), xanthoma palpebrarum (yellowish, soft, tend to form confluent band), molluscum contagiosum (usually face, especially about eyelids; pearly, translucent-looking, discrete, with central minute depression and aperture), warts.

Rare: Pityriasis rubra pilaris (scaly, and tend to form solid scaly sheets); prurigo, especially on extensors of legs, with board-like hardness and thickening; itchy), lichen scrofulosus (usually on trunk, in one or several patches, as yellowish red or yellowish-gray follicular papules, closely crowded and slightly scaly).

Follicular papules are also usually seen in association with the milder types of ichthyosis.

Papulosquamous.—Common: Psoriasis, eczema, keratosis pilaris. Not infrequent: Lichen planus, papulosquamous syphiloderm. Rare: Pityriasis rubra pilaris, lichen scrofulosus.

Tubercular (Nodular).—Most common: Erythema multiforme (dorsal surface of hands and forearms; rarely itchy), acne (face, sometimes shoulder and back also; associated with pustules and papules), acne rosacea (nose and neighborhood, sometimes also cheeks, chin, and middle of forehead; associated with hyperemia and capillary dilatation and commonly with pustules); tubercular syphiloderm (usually limited area, with tendency to segmental configuration, and with pigmentation, atrophy, or ulceration), xanthoma palpebrarum (see under papular).

Infrequent: Lupus vulgaris (commonly about face, frequently the nose, usually small or moderate-sized area, with disposition to group, with tendency to ulceration and scar-formation; occasionally whole region involved), molluscum contagiosum (see under papular).

Rare: Xanthoma multiplex and xanthoma diabeticorum (general distribution, but predominantly on the extremities; yellow). Epithelioma often begins as a tubercle.

Vesicular.—Common: Eczema (regional, small, aggregated, confluent, spontaneously rupturing; markedly inflammatory and itchy; exceptionally, as on the fingers, discrete and somewhat firmer).

Not infrequent: Miliaria (as a rule, general, minute, numerous, and crowded, but discrete, with but little tendency to spontaneous rupture; inflammatory, usually itching, but of variable degree), herpes simplex (usually large—except herpes progenitalis; regional, generally scanty, and commonly on or near the lips; bunched or grouped; but little tendency to spontaneous rupture), herpes zoster (regional, unilateral, large lesions, and forming groups upon hyperemic or inflammatory skin, with little tendency to rupture; frequently neuralgic pain and burning), sudamen (general, especially trunk; minute, crowded, but discrete, clear, translucent, and with little tendency to spontaneous rupture; not inflammatory; seen in association with systemic febrile diseases), varicella (more or less general, most on trunk; discrete), scabies (about fingers especially, associated with pustules, and with evidences of the eruption on the other usual parts), rhus poisoning (small, large, discrete, and crowded and confluent, often with considerable erythematous swelling; most common about face, hands, and forearms, sometimes genitalia or other parts, and generally quite itchy), impetigo contagiosa (usually face or face and hands, after early stage becoming seropurulent, flattening, enlarging, and crusting).

Occasional: Erythema multiforme, urticaria (in both diseases an accidental association with a predominance of the ordinary lesions). Somewhat rare: Pompholyx (hands, feet, or both, especially palmar and plantar regions; beginning deep seated; discrete and confluent, commonly going on to bullous development; inflammatory, and usually of rapid development), dermatitis herpetiformis (more or less general, with tendency toward small groups of three or four, and often associated with bullous and erythematous lesions; inflammatory and

usually markedly itchy; chronic, with exacerbations), variola (early stage—general, but most abundant on face and hands), hydrocystoma (face, scattered, firm, shiny, translucent, with a bluish cast).

Rare: Hydroa vacciniforme (usually in boys, develops in early life, is mostly on uncovered parts, and generally in summer, and leaves variola-like scars; disappears toward adult age). Exceptionally vesicular eruptions may be medicinal in origin. Erysipelas may also show vesiculation.

Bullous.—Erythema multiforme—erythema bullosum (an accidental or anomalous development, usually about the hands, forearms, and face, and frequently in association with the ordinary symptoms of the malady), urticaria—urticaria bullosum (likewise an accidental or anomalous development, and associated with the ordinary features of the disease; the bullous lesions most commonly on the extremities), impetigo contagiosa (in some cases several, and exceptionally all the lesions, are distended and typical blebs; generally, however, in association with other characteristic lesions), rhus poisoning (usually with vesicles and considerable erythematous swelling; face, hands, and forearms common sites, sometimes genitalia or other parts), dermatitis herpetiformis (general, with tendency toward small groups of three or four, usually with associated vesicles and erythematous lesions; as a rule, markedly itchy, chronic, with exacerbations), pemphigus (general, irregularly scattered, well distended, rounded, or oval blebs; occasionally flaccid; often arising from sound skin, and often with systemic disturbance—an extremely rare disease in this country), syphilis—bullous syphiloderm (usually congenital, appearing at or just after birth, commonly most numerous about the palms and soles, becoming purulent, and associated with other symptoms of the disease), medicinal eruptions (exceptional; from iodids, and, as a rule, or predominantly, on the extremities and face; possibly also from other drugs).

Pustular.—Common: Acne (face, or with shoulders and back, or exceptionally this last alone; discrete; associated with papules, comedones, and sometimes small, pit-like scars), eczema (most commonly about scalp, and sometimes in association with pediculosis capitis; not infrequently elsewhere, especially in connection with the hair-follicles, as on face, thighs, and other regions; sometimes minute, crowded, and rapidly forming crusts; in others discrete and larger; quite itchy).

Not infrequent: Impetigo contagiosa (face, hands, and sometimes elsewhere; developing from vesicles or vesicopustules, or originating as pustules; if the latter, usually plump and rounded; tendency to coalescence and crusting; frequently associated with the ordinary vesicular or vesicopustular lesions of this disease), bromid and iodid eruptions (most abundant on the ordinary acne regions; rather bright pink or red base, with, as a rule, relatively small pustular portion; exceptionally much larger, and even the size of blebs; in the latter usually with papillomatous tendency), furuncle (commonly single, but sometimes several in same region, always discrete, and most commonly at the back of the neck; markedly inflammatory base, and painful and tender; sometimes beginning deep seated, in others as a

pustule at the hair-follicle), sycosis vulgaris (bearded and mustache region, connected with hair-follicle; discrete, crowded, and confluent; some lesions may be papular; inflammatory and chronic), tinea sycosis, or ringworm of the bearded region (deep seated, nodular, or lumpy, furuncular, or pseudocarbuncular, and usually some small surface pustules—see tumor eruptions following), scabies (especially about the hands, where, as well as on the other ordinary parts for this disease, other lesions are also seen associated), pediculosis (occasional pustules not uncommon; in pediculosis capitis, chiefly or wholly occipital; pediculosis corporis, most common across shoulders and above buttocks; in pediculosis pubis, scattered over pubic region), syphiloderm (generalized and secondary eruptions—minute miliary, with tendency to group, and associated with minute papules; in larger, acne-like, and varioliform eruptions—with no grouping tendency, although usually numerous; in flat and large, or ecthymaform eruptions—rarely in numbers, but also scattered over surface, with usually underlying ulceration; other symptoms present. In late syphilis the papulotubercular or tubercular lesions, forming regional or limited area or patch, may become pustular), variola (numerous and general, but most abundant on face and backs of hands; usually umbilicated; constitutional symptoms).

Infrequent: Ecthyma (large, flattened, markedly inflammatory base and areola; usually on legs, and commonly in those of the vagabond class; lesions rarely numerous). As is well known, vesicles often become pustular.

Squamous.—Common: Eczema (usually one or several large areas; regional; rarely extensive, and if so, frequently a history or presence of gummy oozing in one or two places; seated upon a thickened red surface; good deal of infiltration, and rarely sharply defined; back of neck, legs, face, and hands, common sites), psoriasis (sharply circumscribed, variously sized patches, usually general and scattered, with preponderance toward the extensors, especially knees and elbows; scaliness commonly abundant, and seated upon slightly elevated, red, flat papules or patches, with but little infiltration; sometimes scales have been rubbed off by clothing and perspiration; chronic and recurrent, usually history of one or more years; exceptionally universal, and then essentially similar to dermatitis exfoliativa).

Frequent: Papulosquamous syphiloderm (in general aspects, similar to psoriasis, but patches rarely larger than a silver quarter, with no predilection for the extensor surfaces, less disposition to abundant scaliness, seated upon dark-red, infiltrated papules or patches, with always some solid papules with no scaling tendency; relatively short history and associated other symptoms of syphilis; may persist or appear as a late manifestation in the palms and soles), seborrhea and eczema seborrhoicum (usually scalp, nose and neighborhood, bearded region, or sternal and interscapular region; greasy or unctuous characters; on scalp, commonly diffused, with little, sometimes no, underlying redness; on nose and neighborhood, usually thin, greasy scales or thin crusts, on pale or hyperemic surface often showing sebaceous gland-duct involvement. On sternal and interscapular regions, greasy

scales or crusts, red base, often segmental in arrangement, and often showing follicular dipping; sometimes projecting and pseudopapular). Eczema seborrhoicum represents the cases in which there is underlying redness, with slight, but variable, infiltration.

Less frequent: Lichen planus (usually regional and most frequently on flexor surface of forearms and on the lower part of legs; when confluent, form thick, scaly plaques, but, as a rule, at the edge or just beyond it are discrete, flattened, often slightly umbilicated, dark-red, purplish, or violaceous papules, with and without a minute scale; chronic and usually markedly itchy; exceptionally more general), ringworm (scalp, scaliness branny, and extremely slight; patch or patches usually rounded, and some hair loss and hair stumps; on non-hairy surfaces ring-like patch with clearing center, scaliness slight; slightly or moderately inflammatory edges; sharply defined and usually of short duration; on crurogenital region, features of eczema, but sharply marginate).

Occasional: Ichthyosis (appears from first to third years, various degrees: slight grade, usually noticeable only on extensors of the arms and legs, especially about knees and elbows, and disappears in warm weather. Moderately developed,—more marked on above situation, and often arranged somewhat like squarish plates, frequently with some follicular elevation, and also slight general scaliness,—disappears partly or completely in summer; in extreme of winter may also show some scaliness about face, and likewise an eczematous tendency. Marked grade—scaliness more or less general, most marked on extensors, where it consists of thick plates; eczematous tendency or exposed parts in cold weather; much better in warm weather, but does not disappear entirely. Ordinarily, unless complicated by eczema, the malady is not inflammatory), favus (scalp usually, and in irregular patches or areas; yellowish, mortar-like crusting, generally here and there saucer- or cup-shaped, and the skin beneath usually red and atrophic; hair involvement and loss), lupus erythematosus (usually face, and often on or near nose; well-defined, red, elevated margin, with generally a tendency to involution or atrophy in central part; scaliness slight and adherent, whitish or grayish in color; gland-ducts usually perceptibly involved and often patulous), pityriasis rosea (usually limited to trunk or extending to thighs and upper arms, sometimes further; faint red, and often with salmon tint; scaliness slight to moderate, and patches variously sized, some or many with tendency to clear centrally; comes out within several days or a week, and lasts from one to two months; as a rule, not itchy).

Somewhat rare: Dermatitis exfoliativa (more or less universal, scaliness slight or marked, and often exfoliated in large masses or sheets; skin red, in some cases infiltrated, and in others often apparently thinned; sometimes preceded and accompanied by constitutional disturbance; lasts several months or indefinitely; usually recurrent; exceptionally fatal), lupus vulgaris (sometimes, instead of undergoing destruction, lupus patches exfoliate,—lupus exfoliativus—the other characters being as already described under tubercular).

Rare: Pityriasis rubra pilaris (more or less general, but usually with some places showing the beginning follicular papules; thicken-

ing and variable scaliness, usually abundant, grayish, and quite hard. Erythema scarlatinoides, scarlet fever, etc., present a thin, paper-like exfoliation or scaling; a slightly scaly condition is also not infrequently seen with scleroderma, elephantiasis, and leprosy.

Multiform (Mixed—Two or More Lesional Forms).—Eczema (any part or several regions; usually a predominance of one lesional form; itchy), erythema multiforme (more or less general; commonly papules and erythematous patches or rings, exceptionally with vesicles and even blebs), dermatitis herpetiformis (general, commonly vesicles, blebs, and erythematous patches; less frequently pustules also; usually very itchy), acne (face, or face, shoulders, and back, or exceptionally last alone; comedones, papules, and pustules), scabies (more or less general, but usually worse on fingers, hand, wrists, axillary folds, genitalia, anal cleft, and feet; papules, vesicles, pustules, sometimes blebs, and often "burrows"; very itchy), pediculosis (papules, often scanty, small and large pustules, and excoriations; pediculosis corporis—general, except face, head, and hands, but most marked over shoulders, about waist, sacrum, and outside of thighs), sycosis vulgaris (papules and pustules—bearded and mustache region), granuloma fungoides (usually generalized, with eczematous-looking patches, nodules, and fungating tumors).

Crusted.—Vesicular and pustular eczema, eczema rubrum, seborrhea, eczema seborrhoicum, favus (see under squamous), impetigo contagiosa, ecthyma, and sometimes the various other vesicular, pustular, and bullous diseases.

Papillomatous.—Warts, syphilis, sycosis vulgaris, epithelioma, tuberculosis verrucosa cutis, lupus vulgaris, blastomycetic dermatitis, mycetoma, some bromid and iodid eruptions.

Atrophic or Cicatricial (Without Preceding Suppuration or Ulceration).—The most common are favus (scalp), lupus erythematosus (usually face and sometimes scalp), acne (some cases, slight pitting).

Less frequent: Tubercular syphiloderm (some cases; atrophic thinning, usually with pigmentation), lupus vulgaris (some cases; atrophic thinning).

Rare: Morphea (usually one or several areas; on trunk, limbs, or face), scleroderma (extensive distribution; extremities, trunk, and face), folliculitis decalvans (scalp), glossy skin (fingers), maculæ et striæ atrophicæ (usually trunk or limbs), leprosy. Also acne varioliformis, in which the pustulation is sometimes scarcely noticeable.

Ulcerative.—Chiefly syphilis, epithelioma, lupus vulgaris, and other varieties of tuberculosis cutis. Rare: Blastomycetic dermatitis, mycetoma, actinomycosis, erythema induratum, leprosy; sometimes ecthyma, sycosis vulgaris, tinea sycosis, acne, and, in rare instances, ingestion of iodids and other drugs, produce superficial destruction; both furuncle and carbuncle may destroy a variable amount of tissue. The ordinary leg ulcer, commonly varicose ulcer, is also a well-known ulcerative lesion.

Tumor.—More or less generalized: Fibroma (variously sized nodules and tumors, mostly sessile, with occasionally some pendulous), granuloma fungoides (small and large tumors, and fungating

growths, commonly associated with erythematous, eczematous-looking areas), sarcoma (usually melanotic and multiple pigmented varieties), molluscum contagiosum (pearly-looking, usually sessile, with central punctum and depression—extremely rare as a generalized eruption), leprosy.

Regional: Steatoma, gumma, molluscum contagiosum (usually about face; see tubercular), ringworm (chin and bearded region, especially under jaws, several or crowded, tumor-like, deep seated; frequently discharging; exceptionally may consist of a single circumscribed nodular mass, suggestive of carbuncle), erythema induratum (usually legs from knees down, especially laterally and posteriorly; several or more, as a rule; tendency to break down), keloid, and some others, both of regional and general distribution.

Pigmentary and Pseudo-pigmentary (Discoloration).—Common: Chloasma (usually about forehead, ill-defined, patchy, or irregular areas; yellowish brown to brown; no textural change), freckles, tinea versicolor (chiefly the trunk, and especially upper part, variously sized yellowish or fawn-colored patches, areas, and sheets; often extremely slight branny desquamation noticeable; no other symptoms; sometimes itchy when patient is warm), vitiligo (in whites, the brownish pigmentation surrounding whitened vitiligo patches proper may in some instances be much the more conspicuous feature; face and back of hands favorite situations; no other symptoms). The various syphilodermata (usually but temporary, although in some, as in the flat pustular, it is, especially on the legs, often more or less lasting), nævus pigmentosus (generally single; various kinds, from simply freckle-like spot to one thickened, dark, and hairy), sebaceous wart (usually in the old, about face, back, or hands; elevated, and generally covered with greasy, adherent, thin crust), purpura (most commonly about legs; spots small or large, red, changing to bluish, yellowish, and fading; hemorrhagic; no textural changes), scurvy (dark reddish brown to brownish-black areas usually about the ankles), pediculosis corporis (if long continued, with the consequent scratching, more or less pigmentation remains, often well pronounced over the back and shoulders).

Rare: Lichen planus (frequently more or less permanent brownish discoloration, especially when on the lower part of leg), chromidrosis (especially about the eyes, where it is dark colored; also the axilla, where it may be variously colored, often due to the presence of bacteria), urticaria pigmentosa (more or less general; urticarial efflorescences leaving sometimes yellowish, thin, xanthoma-like lesions, but usually yellowish to violaceous stains; begins in early life, and persists, as a rule, to late youth), xeroderma pigmentosum (more or less general, freckle-like spots, and telangiectases; later, with epitheliomatous growths; begins early in life), acanthosis nigricans (more or less general, usually presenting features of pigmented nevus, verruca, and ichthyosis).

Scleroderma has often associated with it a variable degree of brownish pigmentation, and chronic, persistent eczema of the region of the ankle is frequently followed by more or less permanent staining. Pigmentation is likewise observed in long-continued, markedly

itchy cases of dermatitis herpetiformis. It is also a not uncommon feature of leprosy.

A CONSPICUOUS CHARACTER OR FEATURE AS A DIAGNOSTIC FACTOR.

In some instances many of the difficulties in the way of a diagnostic conclusion can be surmounted by picking out a striking or somewhat unusual symptom or combination, and, when possible, letting this be the point from which the differentiation is approached. This is already indicated in the consideration of the value of lesion type in the diagnosis. Taking only the diseases with which the student or general practitioner is likely to meet, omitting therefore the rare diseases, the value of this method in many cases becomes in practice clearly evident, and few of these points may be here profitably touched upon, even if necessitating some repetition.

Patchy Hair Loss.—This, if present, even when but a single area and not complete, is a striking and visible sign, and one that in children usually brings the diagnosis within three diseases—ringworm, alopecia areata, and favus. It is true that a bald area might result from a "blind boil" or cutaneous abscess, not uncommon with children of the dispensary class; or from traumatism, or from some other destructive agent or disease, but the first and second are almost invariably self-evident from inspection or history, and the others, rare.

In adults ringworm of the scalp is necessarily excluded, and the diseases are narrowed to two, and if the case does not correspond to the one or the other, then other rarer diseases in which this feature occurs are to be considered—lupus erythematosus and folliculitis decalvans. Scar tissue, evidently resulting from previous ulceration, if present, will also suggest syphilis. Patchy hair loss of the eyebrow is sometimes an associated part of alopecia areata of the scalp, although it may be the first sign of this disease. In the bearded region it generally means the same, or tinea sycosis, or possibly sycosis vulgaris or lupus erythematosus, or, if due to previous ulceration, syphilis or lupus vulgaris.

Ulceration.—The diseases likely to be met with in which this, or its result, *scarring*, is a feature, especially when on the face or other region, excepting the lower part of the leg, are syphilis, epithelioma, and lupus vulgaris, or occasionally other varieties of tuberculosis cutis; syphilis—usually the tubercular or gummatous syphiloderm—being responsible for the very large majority, lupus vulgaris being, in this country especially, relatively rare. It is true boils, carbuncles, acne, and other diseases already alluded to (see under head of "ulcerative" eruptions) may produce destruction and scarring, but these are accidental, readily explainable, or a rare feature. The scarring of lupus erythematosus is more of the nature of atrophy—no previous actual destruction, as commonly understood. On the lower part of the leg, in addition to the several diseases named, it may be traumatic or a simple ulcer, so often present here, and not infrequently associated with varicose veins and eczema; and it may exceptionally be due to erythema induratum or other rare

affection. As a rule, ulceration of this region in those under the age of thirty-five, if not traumatic or due to varicose veins, is almost invariably of syphilitic origin; occasionally to lupus vulgaris, and exceptionally erythema induratum.

Ring-like Configuration.—Clearly cut annular patches or rings, with partially or wholly normal central portion, are seen in erythema multiforme (erythema annulare, erythema iris, herpes iris), occasionally in some patches of psoriasis and the older patches of ringworm and pityriasis rosea (some patches); with partially clear or clearing central portions—ringworm, psoriasis, syphilis, erythema multiforme (especially some of the older papules in the papular type), and both secondary (more especially in the negro) and the late tubercular syphiloderm, pityriasis rosea, eczema seborrhoicum (more especially on sternal and interscapular regions), impetigo contagiosa (rarely more than one or two patches), and to a slightly developed extent in lupus erythematosus. It is also usually seen as a part of the eruption in the erythematous type of dermatitis herpetiformis, and occasionally in the bullous form. Exceptionally it may also be observed in one or several of the larger papules of lichen planus, in lupus vulgaris, and in some patches in extensive general urticaria. On the face, when of short duration, it usually signifies ringworm; syphilis or lupus erythematosus when of considerable duration (the former frequently with ulceration); on the hands or forearms, ringworm, erythema multiforme (recent, either perfect rings, as in erythema annulare, or merely with less pronounced fading center, as in papular erythema), or tubercular syphiloderm; on the trunk, possibly the last two, but about as probably eczema seborrhoicum (circinate, segmental, and irregular, usually sternal or interscapular, with greasy scales or crusts; recent or of long duration with fluctuations), psoriasis (in some or many patches, but not in all; clearing or clear center, elevated, inflammatory, and scaly band-like border, occasionally fusing and forming gyrate figures; eruption also elsewhere); or pityriasis rosea (recent, slightly scaly spreading rings, clearing centrally, often fusing, along with variously sized, slightly scaly macules). About the crurogenital region, usually ringworm.

Segmental or Crescentic Grouping or Outline.—This may be seen in the various maladies just referred to except lupus erythematosus and lichen planus, and especially in ringworm and psoriasis as the patches are finally disappearing; but most frequently points to the tubercular syphiloderm (usually of long duration and often with ulceration), and to eczema seborrhoicum (usually on trunk; occasionally on scalp; exceptionally elsewhere).

Itching.—**Generalized.**—This immediately suggests the possible generalized maladies, and the investigation most commonly leads to a diagnosis among the diseases, urticaria, eczema, pruritus, scabies, pediculosis corporis, sometimes psoriasis (itching cases). If such conclusion is impossible after examination, then other diseases, such as lichen planus, miliaria, some medicinal eruptions, and the rarer affections in which this symptom is usually a factor can be taken up. The syphilodermata do not itch; to this statement, however, exception must be noted as to the negro, who often complains of pruritus in

connection with these eruptions, especially with the miliary papular and pustular manifestations.

Localized itching as a symptom in regional eruptions is also of some value, the most common maladies thus characterized being eczema, pruritus, pediculosis capitis, pediculosis pubis, seborrhea, and eczema seborrhoicum (often absent), lichen planus, urticaria of limited distribution (uncommon; the eruption usually general), regional miliaria, rhus poisoning, and other forms of dermatitis venenata, etc., and also in some of the less frequent maladies. Pompholyx (hands, feet, or both) in some cases is quite itchy, but, as a rule, the subjective symptoms are more frequently or predominantly those of burning and soreness.

Color.—This has already been partly considered under the subheading of "pigmentary and pseudopigmentary" in discussing the lesional types of eruption. The yellowish or fawn color of tinea versicolor; the brownish of chloasma; the bright red, not disappearing upon pressure, and changing through several shades to yellowish, of purpura; the yellowish to black of the freckle, pigmentary nevus, etc.—all are of value in leading to a correct diagnosis. The character of the color—the brightness or deepness of the red in inflammatory and other diseases—is sometimes of at least corroborative aid in limited or general eruptions, whether erythematous, papular, or other type. The brilliant red of scarlet fever and the usually deeper brilliant red of erythema scarlatinoides are much alike, but the shade of difference sometimes exists and is recognized by the practised eye. The brighter, more inflammatory tint of eczema, psoriasis, etc., as compared to the sluggish red, coppery, or ham tint of the syphilodermata, may also sometimes be utilized. The usually slight yellowish cast mellowing the red of lupus vulgaris frequently may be used as one point of difference from the copper or ham tint of the red of the tubercular syphiloderm. The yellowish tinge very commonly present in eczema seborrhoicum is, as a rule, not observed in ordinary eczema. The deep red, with violaceous tint, or distinctly purplish papules of lichen planus, is different from other papular manifestations. The yellow color of the tubercles or continuous band about the eyelid is characteristic of xanthoma, and also of the more generalized eruption exceptionally seen in this disease and xanthoma diabeticorum. The yellow color of the friable crust-masses of favus is also usually helpful, sometimes distinctive.

The value of these positive differences in color is recognizable both by the general physician as readily as by the expert, but for the finer differences of shade some training and experience are necessary.

Odor.—This is occasionally of some value, as the mousy odor of favus, the characteristic fetid odor of small-pox, the often offensive smell of the ulcerative syphilitic lesions, while that of bromidrosis is peculiarly penetrating and disagreeable, and that of gangrene usually characteristic, as also the nauseating odor of the condition sometimes brought about in pediculosis capitis. It is subject, however, to so much modification, lessening, or intensification, or covered up by other or worse smells, due to the habits and environment of the patient, that, except as a corroborative factor, it is not very reliable.

GENERAL REMARKS ON TREATMENT.

THE guiding principles in the treatment of diseases of the skin differ in no respect from those which govern in the management of maladies of other organs. A correct diagnosis is essential except in diseases running an acute course, which get well in spite of the bungling often consequent upon error; but such affections are not very common in dermatologic practice, and usually a *sine qua non* to success is first to know what the disease is.

The proper diagnosis in its relation to therapeutics does not consist, however, in merely naming the disease correctly, but also includes an appreciation, so far as possible, of the etiologic and pathologic factors in the case. Thus founded, treatment will be most promising as to results, especially as to permanency. It is true, in most instances, that it is not always possible to discover the true etiologic influences, and to a great extent, therefore, the therapeutic management is often that which practical experience has proved of service.

A cure, if possible, should be brought about as quickly as practicable. The belief of the laity that impurities are trying to get out, and that it is, therefore, dangerous to the general health to cure or to cure too rapidly, and which formerly found honest believers among physicians, is wholly without foundation. This view has been strongly supported purposely by advertising nostrums, and has likewise been a convenient cloak for medical advisers helplessly at sea in cutaneous therapeutics. On the contrary, the putting of the skin, an important organ and emunctory of the body, into a healthy state, will not only relieve the patient of an annoyance and worry, but conduce to his general well-being.[1] The main difficulty, unfortunately, in many diseases is our inability to cure quickly enough.

In most diseases both local and constitutional measures are required. There is some diversity as regards the value of internal medication, which in times remote held the prominent place in treatment, but which was gradually displaced by those holding the opinion that skin diseases are purely local maladies, with no relationship to the general organism, and therefore manageable by purely external measures—a view which reached its greatest prevalence under the late Professor Hebra, and is still held to a greater or less extent by most of the German writers, the French, English, and Americans taking a conservative middle ground. The strongest support of this latter view is found in the fact that many American specialists, as well as many in England, spent a few years under the distinguished tutelage of Hebra, Neumann, and Kaposi, whose views as to local treatment practically coincided, and returned home thoroughly imbued with this idea, but which, under the test of increasing personal experience, has gradually given place to the opinion that while external remedies are essential in almost all cases, the proper constitutional management in many diseases is likewise important, and that the maintenance of good health keeps up the

[1] This is also referred to under eczema.

tissue-resisting power, and therefore is of potent influence in the permanency of cure in cutaneous as well as other diseases. It is true that many affections are purely local, often parasitic, and that, therefore, systemic measures are scarcely called for, but in some of these, doubtless, cutaneous tissue weakness, induced by general ill health due to constitutional or organic disease, favors successful parasitic invasion, and therefore systemic invigorating measures are sometimes of service. This is often demonstrated also in pulmonary tuberculosis. The various therapeutic measures and special remedies, both local and constitutional, will be referred to, more at length, in connection with the individual diseases. A brief preliminary review of the underlying principles and of some of the chief remedies may, however, be of some service.

CONSTITUTIONAL TREATMENT.

For the most part, in the general constitutional management of those diseases of the skin in which this seems advisable, it is not so much to be based upon the malady present as it is upon the patient —in short, the individual is to be studied rather than the skin disease with which he is afflicted, and in the general run of cases much more is to be expected than if remedies with alleged direct specific action upon the malady or the cutaneous tissues are depended upon. Such remedies, though relatively few in number, are not, however, completely to be ignored, for they sometimes have a decidedly useful influence. As remarked in discussing the physiology of the skin, it is to be considered as one of the four emunctories of the body, and when this is diseased or its full usefulness compromised, the functional deficiency is partly, sometimes completely, made up by compensatory activity of the other three, more especially, however, the kidneys and intestinal tract; and, conversely, impairment of one of the latter may indirectly, or possibly directly, be influential in provoking cutaneous disorders, as referred to under general etiology, either by the superinduced increased activity, or, and more probably, by the action of certain excretory products which ordinarily should find their outlet through the kidneys or intestinal tract. This possibility is to be borne in mind in the treatment. Very often in the management, increased activity of the kidneys and intestinal tract, by remedies which increase the flow of urine and promote free movement of the bowels, has a material influence in lessening and modifying cutaneous disturbances, particularly those of an inflammatory character. The general treatment, therefore, is to keep in view the maintenance of a proper condition of the general health of the patient, and if that be defective, be corrected or modified, if possible, by suitable measures and remedies. A clue is sometimes given by the amount or character of the urine. In fact, all etiologic possibilities are to be considered. In the absence of any special indications, and yet where the character and extent of the malady, especially in inflammatory affections, are strongly suggestive of some systemic factor, the family history will often throw light upon the possible underlying disease tendency—diathesis, or constitutional weakness.

Hygienic living, proper food, well-ventilated rooms, plenty of sunlight, outdoor life, unless contraindicated by the weather; and, especially in those of sedentary habits, exercise in moderation; rest in some diseases and cases; and sometimes, when feasible, temporary change of scene and climate—are all to be considered of therapeutic importance. As already indicated in discussing general etiology, in the large majority of cases commonly met with, digestive disorders, such as dyspepsia, gastric catarrh, constipation, etc., are the factors which most frequently call for correction, and the various known remedies for these conditions accordingly play an important rôle.

The *dietary*, therefore, is often of importance, and sometimes requires supervising directions. In some affections, it is true,—as, for instance, taking the extreme examples of verruca and xanthoma palpebrarum, and the parasitic affection, scabies, etc.,—the consideration of the question of food would be an absurdity. On the other hand, however, the cases of extensively distributed eczema, of xanthoma diabeticorum, many instances of pruritus, psoriasis, acne, dermatitis herpetiformis, and others, improper feeding is often an important factor, or at least an aggravating influence, and its proper regulation requires attention.

The patient is not, however, to be wholly ignored in this consideration: his tastes, wants, and idiosyncrasies are to be consulted, for sometimes articles of food usually readily digested by others may, in individual instances, be not only distasteful, but disturbing and fermentative. As a rule, the well-to-do class consumes too much nitrogenous food, and this is not infrequently a more or less damaging factor in some of the inflammatory diseases. Even with this, however, an extreme position is generally unwarrantable, for there are cases encountered in which gastric weakness is a cause, and in which starches are badly borne, the stomachic condition being overcome or palliated by chiefly a meat diet, the eruption often undergoing perceptible improvement as the digestion is thus improved. In other cases a purely milk diet can be employed for a time with benefit; or, more frequently, conjointly with meat once daily. The use of *alcohol* is, in the inflammatory affections, particularly eczema, prejudicial and directly damaging, and should be interdicted or at least limited, depending upon the habits and needs of the patient—as, for instance, in the old and feeble. The excessive, and sometimes moderate, use of tea, coffee, and tobacco is likewise to be prohibited. As to particular foods, those of difficult digestion, and others concerning which there may be a possibility of unfavorable influence, are best avoided; and among such may be named pork in all forms, especially sausage and scrapple, lobsters, crabs, clams, oysters (except in cold winter season), and other "shell-fish," veal, fish, pastries of all kinds, fresh breads, "hot cakes," waffles, cheese, dressed salads, acid fruits, seeded and acid berries, pickles, usually condiments, except in moderation, nuts, and sweets; potatoes in excess, cauliflower, cabbage, and onions are likewise, especially in some individuals, often detrimental. The cereal foods may ordinarily be taken in moderation, with milk or cream and salt, if desired, but ordinarily with no sugar.

General tonics, both simple and nutritive, as readily to be inferred from etiologic considerations, are often useful in certain skin diseases in which debility or loss of general tone is an influence, as often in eczema, pompholyx, seborrhea, acne, and other affections. Anemic conditions are met with—iron, manganese, sometimes small doses of arsenic and the hypophosphites; quinin and strychnin are also indirectly not infrequently of service. The most valuable general nutritive tonic, however, in some cases, is cod-liver oil in small or moderate dosage. The digestives and ordinary bitter digestive tonics, sometimes with an acid, sometimes with an alkali, by their influence on digestion are often of service in promoting general invigoration; frequently such, with a laxative, as required to keep the bowels free, will be all that seems necessary or indicated.

Aperients find more than occasional use in cutaneous disease, and the maintenance of a free action of the bowels, especially in the inflammatory affections, cannot be overestimated, as aiding in getting rid of toxic products, and usually improving digestion as well. Except in anemic individuals, the **salines** are usually to be preferred; they are given in dosage sufficient to produce free action, but not, except rarely, active purgation. As a frequent or daily saline, magnesium sulphate is probably the best, often usefully given with iron, as in the "mistura ferri acida," but sodium sulphate, sodium phosphate, and the various natural aperient mineral waters are likewise valuable. Calomel, usually in quickly following small doses, administered at intervals of several days or more, can sometimes be employed with advantage, especially if there is suspected torpidity of the liver. One of the most valuable laxatives, as an occasional one, is the antacid magnesia, particularly valuable when gastro-intestinal toxin development is probable. Among the **vegetable laxatives** cascara, as the extract or fluid extract, is, in my judgment, the most useful, although the other well-known drugs are often used. For infants and young children castor oil, cascara, and gray powder are the most serviceable. Plain enemata, often used, both in infants and adults, as a rule are not to be commended except as a temporary measure, although in some instances in adults an occasional full flushing out of the lower bowel may prove beneficial.

Gastro-intestinal antiseptics are of considerable value in some instances of eruptions seemingly due to autointoxication, as urticaria, erythema multiforme, some cases of eczema, etc. Among those that may often be used with advantage are the laxative antacid magnesia, minute doses of calomel administered at half-hour intervals every several days, charcoal, salol, sodium salicylate, minute doses of carbolic acid, and some others.

Diuretics.—These are often useful, and the free action of the urinary flow thus promoted, together with occasional laxatives, often proves very serviceable in some of the inflammatory and hyperemic affections. They can often be employed with advantage especially in eczema, psoriasis, markedly inflammatory acne, and acne rosacea, dermatitis exfoliativa, dermatitis herpetiformis, and like inflammatory disorders. The saline diuretics are, upon the whole, the best, and in this class potassium acetate and potassium bicarbonate. These

are also valuable **antilithemic remedies**, and it is, as a rule, especially in cases with this etiologic basis, that they are found most useful. In such cases, too, sodium salicylate, ammonium salicylate, salophen, etc., often find an important place. In pruritus and other neurotic affections small doses of belladonna can be conveniently used conjointly, as this also has diuretic action, as well as other influence. Other vegetable diuretics are also sometimes given. In all instances water should be taken freely, as this in itself is a good diuretic. Possibly the influence of oil of turpentine, oil of copaiba, etc., noted occasionally in a few diseases, may be due, in a measure at least, to diuretic action.

General Alteratives.—All remedies, whether simple tonics, digestives, etc., which improve nutrition are naturally to be classed as general alteratives, but the drugs referred to here are those which possess this property independently of such influence. The chief alteratives of this class are the mercurials, iodin preparations, and the animal extracts. It is not unlikely that the alleged alterative effect of some of these drugs may in fact be attributable to their germicidal influence, as referred to further on. There can be no question of the value of mercury in both the early and late stages of syphilis, and of the iodids in the late syphilitic manifestations, for the evidence of eruptions quickly melting away under their influence is overwhelming. As will also be seen in the course of the text, the iodin preparations are not without effect in some cases of strumous affections. The favorable action of the iodid salts in actinomycosis and blastomycetic dermatitis is also attested; its influence in large doses in some cases of psoriasis is undoubted, but whether from alterative action or its effect as an alkaline salt is not definitely known. The potassium iodid is the salt most commonly prescribed, but in my own experience sodium iodid is just as effectual in syphilis, and less apt to be disturbing.[1]

The preparation of the mercurial to prescribe is greatly a matter of prejudice or personal custom. The protiodid for active administration in the early eruptions of syphilis, and the biniodid in association with potassium or sodium iodid salt in the late syphilodermata, are probably in most general use, and are those which I usually prefer. In the later stages, however, corrosive sublimate is likewise a favorite remedy with many. Mouth administration is usually satisfactory, but cases are encountered which do not seem to yield to this plan, and in such, inunctions with blue ointment are generally curative. The hypodermic method is a favorite plan with some. This remedy is likewise found useful in some cases of lichen planus and a few other affections.

Tar and carbolic acid are also remedies which occasionally appear to possess alterative properties, and are sometimes prescribed for this purpose, especially in psoriasis and eczema. The same may be said of phosphorus, which, in $\frac{1}{100}$ to $\frac{1}{20}$ grain (0.0007 to 0.0035 gm.) dose thrice daily, in pill or oily solution, is sometimes prescribed for lupus erythematosus, lupus vulgaris, and other diseases. It presumably acts through the nervous system, but there is no uniformity of

[1] See dermatitis medicamentosa.

opinion as to its value; it has practically no place in treatment with the large majority of dermatologists. In one or two instances of erythema induratum it seemed to me of value; and in zoster, zinc phosphid, from $\frac{1}{10}$ to $\frac{1}{5}$ grain (0.007 to 0.014 gm.) four or five times daily, is sometimes of distinct service. Antimony, warmly supported by Malcolm Morris for acute and subacute inflammatory diseases in robust individuals, notably in eczema and psoriasis, is prescribed in dosage of from 3 to 10 minims or more of the wine three or four times daily. Although this remedy is also somewhat favorably referred to by Crocker, Duhring, and a few others, it is not in very general use, probably owing to the care required in its continued administration, lest depressing or other untoward action should result. Turpentine has been advised in the same affections by Crocker, to be given conjointly with free diluent drinks. Copaiba, according to my observations, occasionally acts favorably in the same class of cases. It is probable that the last two, in addition to some general alterative action, benefit by their diuretic effect as well and possibly also have some special alterative influence directly upon the cutaneous structures. Quinin, which is sometimes apparently useful in erythema multiforme, erythema nodosum, herpes zoster, eczema, and other diseases, especially if there is an underlying malarial element, might also be included in this class.

Animal extracts have lately been playing an important experimental rôle in cutaneous therapeutics, as well as in other branches of general medicine, and that some have a general alterative influence, as well, possibly, as a special alterative action, cannot be denied; the action is not, however, a regular one, but, on the contrary, exceptional. Thyroid extract has proved valuable in myxedema, and occasionally has some influence in cases of psoriasis, and has also been employed with alleged benefit in lupus vulgaris and other chronic diseases, but its possible untoward effects have limited its use. The dose of the desiccated extract, as furnished in tablet form, varies from $\frac{1}{2}$ to 10 grains (0.035 to 0.65 gm.) or more three times daily, always beginning with moderate doses, and, if necessary, increasing, but cautiously. A glycerin extract is also made. Suprarenal gland extract has recently been extolled for vitiligo.

Special Alteratives.—The influence of the various remedies mentioned under germicides, as well as some of those under general alteratives and other heads, might also possibly be due to special alterative or direct action upon the skin, but the chief exponent of this class, which might likewise be termed "special cutaneous stimulants," is arsenic, when administered in dosage to get its special effects, and which is entirely distinct from its use in small doses as a general tonic. This drug probably acts both directly and through the nervous system, and particularly, as shown in the experiments by Ringer, Murrell, Nunn, and others, upon the epithelial layers. Clinical observation, both as to its therapeutic action and toxic effects, is corroborative of these observations.[1] It is likewise to be con-

[1] In a recent elaborate and exhaustive paper on "The Action of Arsenic on the Skin as Observed in the Recent Epidemic of Arsenical Beer-Poisoning," *Brit. Jour. Derm.*, 1901, p. 121 (with many case and histologic illustrations, review of the subject, and

sidered a potent nerve stimulant, and therefore also of possible value in some diseases of neurotic origin. It is a remedy which is more especially indicated in the superficial dermatoses. Like most remedies which possess some certain value, it was formerly given almost the standing of a panacea, Hunt being one of its most extreme advocates; and following this comes the rebound, and in comparatively recent years there has been a tendency with some dermatologists to belittle its value and set it aside, but this is, in my judgment, just as unwarranted as the other extreme. It is, it is true, still much overrated by the general profession, who often prescribe it indiscriminately, frequently merely upon the basis of a "skin disease," and much harm thus results. Its chief value, upon the whole, is in sluggish and sluggishly inflammatory cases of cutaneous disease, those which originate in the epithelial layers or in which these are prominently involved, as psoriasis, lichen planus, and a limited number of persistent dry eczemas; and also in those diseases of neurotic character, as pemphigus, dermatitis herpetiformis, and some others.

Jaborandi, or its active ingredient, pilocarpin, is sometimes of value in cases in which benefit is to be derived from stimulation of the sweat function, as in the dry, scaly diseases, ichthyosis, psoriasis, etc. Calcium sulphid, sulphur, elsewhere referred to, and some other remedies have also been accredited with special alterative action in certain diseases, the sulphur preparations especially in the diseases of the glandular structures.

Germicides.—While probably no remedy administered internally is distinctly germicidal, there are, doubtless, some which, in a few diseases, in some manner, make the body and its tissues an unfavorable habitat for micro-organisms, or which are antidotal to their products. We know that the value of quinin in malaria is based upon this fact, and it is scarcely to be doubted that mercury acts the same way in syphilis. It is not improbable that other remedies strikingly useful in other diseases may owe part of their success to this action. Cod-liver oil often seems to have this property, independently of its nutritive influence. Sulphur, owing to its exhalation through the skin, internally, may also possibly have a slight influence in lessening the hold of cutaneous micro-organisms, as in the alleged favorable action of calcium sulphid in boils, seborrhea, acne, etc. It has appeared to me that those whose skin has naturally more or less of a sulphurous exhalation, as shown by the rapidity with which silver or silver-containing jewelry is tarnished, are less liable to exhibit such parasitic diseases as tinea versicolor, ringworm, etc., and on this supposition its administration in such affections may be an advantage conjointly with the proper local treatment.

references), Brooke and Leslie Roberts conclude as follows: "In the face of the facts which we have endeavored to place before the reader, we have no hesitation in saying that arsenic, and the other members of the nitrogen group, must be distinguished from all other medicaments by the fact that their action, whether therapeutical, pharmacological, or toxicological, is entirely dynamic, and consists essentially in altering the ratio to the tissues of one of the most active normal ingredients of the body—namely, oxygen." See also dermatitis medicamentosa for toxic effects upon the skin and for other literature references.

Tuberculin and other prepared toxins or vaccines are remedies or agents whose anticipated effects were presumably based upon some germicidal or antidotal properties. It is well known that in recent years the hypodermic injections of "tuberculin" for lupus vulgaris and the other forms of cutaneous tuberculosis have been employed, and sometimes with a decided effect upon the disease, which is more fully referred to in connection with these maladies. The uncertain and variable effect, however, of this and other prepared toxins, or vaccines, gradually led to their practical abandonment; but in the past few years, chiefly through the enthusiastic work of Wright and others,[1] who have endeavored to place their employment upon a scientifically exact basis, various "vaccines" are again being cautiously and tentatively tried in several dermatoses. Wright found by experimental investigation in certain diseases, as, for instance, sycosis, furunculosis, acne, tuberculosis, and a few others, that the phagocytic power of the blood was reduced, and that this was neither due to the serum nor to the leukocytes, but to the diminution of some unknown constituents, which he called "opsonins," and further, that the hypodermic injection of an appropriate "vaccine" would influence the quantity or activity of the "opsonins," and have an effect upon phagocytosis, and indirectly upon the disease. If the dosage of the vaccine was correct, the "opsonic" power of the blood, and consequently phagocytosis, was increased, and by a series of proper dosages, could be brought up to normal and exert a favorable curative action; but on the other hand too large a dosage would still further decrease the "opsonins" and thus lessen the phagocytic power and probably have an intensifying effect upon the disease. This opsonic action is believed to be due to some alteration in the microbes which permits their being ingested by the leukocytes. He devised a method (a modification of Leishman's method) of measuring the opsonic power of the blood which need not be detailed here, and by doing this from time to time, he was enabled by this "opsonic index" to reach an approximately correct dosage, and also to regulate its frequency; and in the various diseases named, as stated by him and a few other observers, the curative influence was striking. As is readily inferred, therefore, if "vaccine" treatment of any disease is determined upon, the first doses should be the smaller, and subsequent doses, as well as frequency, regulated by a study of the "opsonic index."

Vasomotor Constringents.—Several drugs are credited with this action upon the cutaneous vessels, leading to their contraction and the reduction of hyperemia. They are more especially employed in acne rosacea, and less frequently in purpura, pruritus, and a few other affections. Ergot is sometimes prescribed for this purpose,

[1] Literature, Wright and Douglass, "An Experimental Investigation of the Rôle of the Blood Fluids in Phagocytosis," *Proceedings of the Royal Society of London*, 1903, vol. lxxii., p. 357 and 1904, vol. lxxiii., p. 128; Potter, Ditman, and Bradley, "The Opsonic Index in Medicine," *Jour. Amer. Med. Assoc.*, 1906, pp. 1722 and 1793 (with review of important papers and complete bibliography); Houghton, "A Review of the Opsonins and Bacterial Vaccines," *Therapeutic Gazette*, January 15, 1907 (with complete bibliography); Pernet and Bunch, "The Opsonic Treatment of Certain Diseases of the Skin," *Brit. Jour. Derm.*, 1906, pp. 339, 397 and 427; and Houston and Rankin, "The Blood in Relation to Skin Diseases," *Brit. Med. Jour.*, October 6, 1906.

principally in acne rosacea and purpura, usually in moderate dosage. It has also been used in ordinary acne, where lack of tone in the muscular fibers of the skin is suspected. Inasmuch, however, as there is in these cases often gastric irritability or digestive weakness, which the drug frequently seems to increase, its field of usefulness is somewhat restricted. Ichthyol has been highly extolled, especially by Unna, for promoting vasomotor contraction, and as especially useful in acne rosacea, and also in such affections as lupus erythematosus and other hyperemic diseases. It is usually administered in capsules, 3 to 15 minims or more three times daily, but opinion as regards its value as a constitutional remedy is by no means unanimous. My own observations do not give it very high rank. Thiol has also been suggested as possessing the same properties as ichthyol.

Analgesics.—Antipruritics.—It may be stated, as a rule, that in the inflammatory dermatoses most drugs known as analgesics are often of aggravating influence in their after-effects; less frequently they are directly damaging. This scarcely holds true, however, in such diseases as herpes zoster, which sometimes, on account of the neuralgic pain, requires the administration of such remedies. In this malady opium or morphin can be used if deemed advisable, but in others, especially those of itchy character, it is apt in its later influence to increase this symptom. The safest drugs to employ for the pruritus, when necessary, as it sometimes is, to procure a night's rest, are the bromids and chloral; belladonna, gelsemium, phenacetin, and antipyrin may also be used for this purpose, and in some cases lupulin in full doses may be tried. Upon the whole, however, they are best avoided if possible; relief from the itching can usually be obtained by certain local applications, to be referred to.

Natural Mineral Waters.—The use of the stronger natural aperient waters has already been incidentally referred to; their good effects are due to their laxative action. The milder aperient waters, usually taken at the various springs, have the same influence, but, in addition, the large quantities taken serve to keep the kidneys in free action as well, and thus act in two ways. The value of the alkaline waters taken freely is undoubted, but whether of any more service than the administration of ordinary alkalies with plenty of drinking-water is somewhat problematic. The iron waters and arsenic waters are also well known, and as substitutes for the ordinary drugs have a value, and the same may be said of the sulphur waters, in which laxative influence and alterative and probably antilithemic action are combined; but these waters are not useful in gastric catarrh or dyspeptic cases. Inasmuch as the underlying factor in many cases is a gastro-intestinal catarrhal or digestive disturbance, usually with constipation, the most useful spring waters, on the whole, are those of alkaline and slightly laxative character. These are also beneficial in underlying rheumatic conditions. The moderately active laxative waters of an alkaline character are more especially to be preferred with *bons vivants*—those who have been storing up the effects of overfeeding and overdrinking.

No one can doubt the favorable influence of the natural spring waters if taken liberally, for the reasons given, but taken at home,

their effect is relatively nil compared to the influence gained at the resorts themselves, where, in addition to the free drinking of a mildly therapeutic water, are conjoined usually a rigorous dietary supervision and the unquestioned effect of change of scene, climate, release from care, etc. These last are the influential factors at drinking springs; the medicinal ingredients of the water are the least potent in the final effect gained.

Electricity.—The general tonic and alterative action of general faradism, galvanism, or static insulation or shock can sometimes be made use of with advantage in cutaneous diseases associated with lack of nervous tone, especially galvanism and static electricity. Shoemaker, Brocq, and one or two others are the only ones who have given much attention to the advantages of electrization, an adjuvant in the management of some cases which, from my own experience with its use, I can indorse. In some cases of eczema, urticaria, pruritus, and other maladies or cases showing neurotic relationship its influence is sometimes considerable.

LOCAL TREATMENT.

As a rule, in cutaneous diseases external applications are necessary both for the favorable or curative action exerted upon the malady itself, as well as for the relief of the accompanying itching or other troublesome subjective symptoms. External treatment is, therefore, of great importance, and generally much more essential for immediate relief than systemic remedies, although in many affections, as already stated, a judicious blending of the two will give far more satisfactory permanent results in the aggregate than local measures alone. It is true some of those running an acute short course, and some of the chronic disturbances,—relatively few in number, however,—are not influenced by external treatment, and unless demanded by annoying itching, burning, or pain, local applications are unnecessary.

The measures employed in the external management of skin diseases are varied, and are mentioned with more or less detail, and their special manner of employment described in connection with the diseases in which they are employed, each more particularly in that disease wherein the method or drug finds its most prominent employment. To avoid unnecessary repetition, but brief reference in a general way will, therefore, be made here, and only to those most commonly resorted to. The essential underlying principles of external treatment should be mild, soothing, and protective applications for acutely inflamed surfaces; similar preparations in the early part of the treatment of subacute inflammatory types, moderately stimulating for those of sluggishly subacute or with slight infiltration, and actively stimulating for thickened, infiltrated, sluggish areas. Various modifications are often required to suit the individual case. Fortunately, most of the remedies thus employed are antiseptic, and this is a very important factor in cutaneous therapeutics.

Water.—**Baths.**—Water is employed for two purposes—cleanliness and to remove the products of disease. As a general rule, in

acute inflammatory disease, notably in many cases of eczema, it is prejudicial, and its use, therefore, restricted as much as is consistent with the requirements just stated; in some instances of acute irritability its place must be taken by some cleansing oil or grease, such as olive oil, almond oil, cold cream, or vaselin. A thorough soaking with one of these, especially the oils, will usually soften crusts or scales rapidly and facilitate their removal; sometimes the parts must be kept bathed with it by means of compresses, and renewed from time to time. In such instances water can almost be dispensed with or used only at intervals. Rain water or boiled water is less irritating than ordinary water.

In some of the hyperemic and more acute diseases, and in chronic diseases of a somewhat acute or subacute type, such as dermatitis exfoliativa and some cases of eczema, baths made mucilaginous with gelatin (about ½ to 1½ ounces to the gallon), starch (about ½ to 1 ounce to the gallon), bran (about 1 or 2 ounces to the gallon), are usually soothing in character, and sometimes permissible and palliative in their effect. On the other hand, in some cases and some diseases of a sluggish, chronic, scaly character, such as, for instance, ichthyosis and most cases of psoriasis, the free use of water for washing and cleansing, or in the form of baths, plain or medicated, is not only not damaging, but is often a very important factor in the treatment. The warm to hot bath is frequently sufficient in the less aggravated cases, or it can be made alkaline, as is frequently necessary, by the addition of a varying quantity of an alkaline salt, depending upon the character and tenacity of the scales and the irritability of the skin. Those commonly used for this purpose are sodium bicarbonate (averaging 1½ drams to the gallon), sodium borate, potassium carbonate, or ammonium muriate (averaging a dram to the gallon). The sulphur bath is occasionally used in the chronic sluggish dermatoses, and is best made with potassium sulphid or Vleminckx's solution (averaging a dram to the gallon). The salt bath (averaging 3 ounces to the gallon), as commended by Piffard, is also useful in some of these cases. Tar baths are, at present, not much used. Corrosive sublimate baths will be referred to in the course of the text. An ordinary tub-bath takes about 30 gallons. The bath should always be taken warm enough to permit of immersion for from three to twenty minutes without chilling.

Steam and hot-air baths are only occasionally advisable in dermatologic practice, and in the same diseases in which alkaline baths are prescribed. The cold shower or plunge may also be of service in exceptional instances, but in cutaneous therapeutics has an extremely limited usefulness. The same may be said of the wet-pack. The natural spring-water baths are also sometimes resorted to, and the effects, owing to the methodic manner in which they are carried out, and supplemented by the advantages of change of environment, diet, etc., are sometimes striking.

Soaps are frequently demanded in connection with the use of water for cleansing purposes, but should be even more rigorously excluded in acute eczematous disease and similar conditions. But the same reasons why water must sometimes be used also hold with

soap, but great care should be taken to remove such washings with clean water There are two classes of soaps, the mild and the strong—the soda soaps, of which Castile soap is a representative, and the potash soaps, of which sapo viridis is the one commonly employed. The soda soap should be as nearly neutral as possible. Its use for toilet purposes has an influence in keeping the skin in healthy condition, but in those of thin epidermis and sensitive skin must be employed in moderation, and exceptionally individuals are met with whose exposed skin, especially the face, does not bear well even its occasional use; in some instances, however, this signifies that the soap contains too much free alkali. As a rule, the washing of the face when using soap, especially on skin at all sensitive, should be done at bedtime; if done during the day, the exposure to wind and weather is irritating. An attempt to overcome this has led to the manufacture of a "superfatty soap," which is less irritating to some skins, but it is sometimes uncertain in this respect with others. Soda soap, more freely used than for ordinary toilet purposes, is of advantage in the treatment of acne and some other affections, and it may also be used in some cases in connection with the warm bath in place of the alkaline salt. Sapo viridis may also be so used, but it represents a stronger alkaline bath.

This latter, known also as sapo mollis, or green soap, is a strong soap, and should not be employed in diseases of an acute or, as a rule, subacute type. For removing adherent scales and crusts in sluggish conditions, however, it is sometimes valuable; also in some cases of acne, seborrhea, and psoriasis of the scalp, etc. It may often in these cases be used with greater advantage in the form of the tincture of sapo viridis, corresponding to the spiritus saponatus kalinus of Hebra. The best sapo viridis is that imported from Germany; the extemporaneously made soap having, especially in tincture form, proved, in my experience, often unsatisfactory.

Medicated soaps, made by the addition of various drugs to the soda soap basis, are now prepared by various manufacturers, and while their action is often questionable and their field of usefulness small, occasionally they may be prescribed advantageously—as, for instance, the sulphur-naphthol soap, for body toilet use after an apparent cure of tinea versicolor. Medications have also been made to the superfatted basic soda soap. The tincture of green soap can often be advantageously medicated with resorcin and other drugs for use in the shampoo for seborrhea, etc.

Dusting-powders have a somewhat limited field in cutaneous medicine. They are prescribed in the erythemata, especially erythema intertrigo, in erythematous eczema, hyperidrosis, bromidrosis, and some other affections. Those in more common use are zinc oxid, starch, lycopodium, rice, talcum, magnesium carbonate, boric acid, zinc oleate, zinc stearate, and others, those most valuable being referred to under eczema and other diseases in which they are employed. They are variously used for their protective, antiseptic, astringent, and drying properties. They are not applicable where there is free gummy or purulent discharge. The first requisite of a good dusting-powder is that it should be absolutely free from gritti-

ness, which can be readily ascertained by rubbing some between the two finger-ends.

Lotions are much more agreeable applications than ointments, and are useful in many diseases, in some of which they may be used alone. In others they are found too drying to employ continuously, but can be satisfactorily used intermittently or conjointly with ointments. They are probably most frequently applicable in acne, urticaria, pruritus, erythema intertrigo, some cases of eczema, etc. In some cases the drying effect can be lessened or abolished by the addition of from 1 to 5 or 10 minims (0.065 to 0.33 or 0.65 gm.) of glycerin to the ounce (32 gm.), but this ingredient should rarely exceed this amount in most instances, as it may prove irritating, whereas in minute quantity it is often a valuable addition. From 5 to 10 minims (0.33 to 0.65 gm.) of alcohol to the ounce (32 gm.) may also frequently be added with advantage for the pleasant, cooling sensation it produces—when not contraindicated, as it would be in exceedingly acute conditions, more especially, however, when the rete or corium is exposed.

According to the effect desired, lotions are of various characters, as indicated by the following qualifying names—soothing lotions, antiseptic lotions, astringent lotions, stimulating lotions, antipruritic lotions, etc. They will be found specifically referred to in connection with the various diseases in which they find application.

As an example of an extremely mild, soothing lotion may be mentioned that usually designated *calamin liniment*, *calamin-zinc-oxid liniment*, consisting of 1 to 2 drams (4–8 gm.) of zinc oxid and calamin, 4 to 10 minims (0.26–0.65 gm.) of carbolic acid, and 2 ounces (64 gm.) each of lime-water and oil of sweet almonds. These pulverulent ingredients make it of a slightly astringent and protective character. In some instances linseed oil instead of the almond oil seems more acceptable. It is to be applied frequently by tapping it on, or the parts can be kept enveloped with cloths or lint wet with it. Closely similar, but distinctly drying in its character, is the plain or aqueous well-known *calamin-and-zinc-oxid lotion*, consisting, in the average formula, of about 1 or 2 drams (4 to 8 gm.) each of calamin and zinc oxid to the 4 ounces (128 gm.) of water, or of 2 ounces (64 gm.) each of lime-water and plain water; to this is sometimes added, in minute quantity, as stated above, carbolic acid and glycerin. This is especially valuable in some cases of erythematous and vesicular eczema of the acute type, in erythema intertrigo and some other affections. Both these powders seem also to be slightly antiseptic, but this property of the lotion can be further emphasized by the addition of from 5 to 15 grains (0.35 to 1 gm.) of boric acid to the ounce (32 gm.), and which does not compromise its soothing character. Lotio nigra, with an equal quantity of water or lime-water, is another example of a soothing antiseptic lotion. As a plain antiseptic, soothing lotion, free from sediment, may be mentioned one of boric acid of the strength just indicated, and which can often be used alone, but also more frequently with great advantage conjointly with a soothing salve. It is one of the most valuable mild antiseptic lotions we possess, and in my practice is indispensable. Astringent lotions in the strictest sense are

those containing tannin, alum, zinc sulphate, and the like, used most commonly in hyperidrosis. The stimulating lotions are well illustrated by the sulphur washes and tarry lotions, prescribed respectively in acne and chronic eczema. Antipruritic lotions will be referred to under the head of antipruritics.

Ointments are the most frequently employed preparations in cutaneous therapeutics, and, upon the whole, in many cases, are by far the most valuable; they probably find their greatest usefulness as applications in eczema, to which the reader is referred for many points concerning the various formulas and other matters not here touched upon. The best ointment bases are: (1) Prepared lard, which is the best all-around base, possessing penetrating powers scarcely exceeded by any other fat, but which has the disadvantage of tending, after a time, to rancidity, and should therefore always be fresh; (2) petrolatum, or its equivalent, vaselin or cosmolin, is also valuable, having but little tendency to change, constituting a good protective, but lacking somewhat in its power of penetration, although Luff's experiments point to the contrary; occasionally, either from imperfect purification or for other cause, it is found to disagree; (3) cold cream (unguentum aquæ rosæ) is soothing and cooling, and is to be considered an admirable base, when properly made, and may often be used when other fatty applications disagree. These three, used sometimes separately, sometimes in mixture of two or all, are those which will be found most satisfactory. To these, other fatty substances, such as spermaceti, wax, suet, and the like are sometimes added for special purposes, and of which simple cerate (ceratum simplex), simple ointment (unguentum simplex), are some pharmaceutic examples. The stiffer substances are necessary when a good deal of liquid medication is to be added, such as lead-water, oil of cade, etc.; if an aqueous substance, and in much quantity, enough lanolin with which it can first be rubbed up, together with variable amounts of simple cerate and lard, or petrolatum, can be satisfactorily employed as the base. Lanolin, introduced by Liebreich, and since more or less generally advised, is said to surpass in its power of penetration all other bases, but this is not borne out by experience; and it is an unsatisfactory and even impracticable base when used alone, but in the proportion of from 10 to 20 per cent. to other bases, it is sometimes a valuable addition in seborrhœa and ringworm of the scalp, and some other maladies. Water readily mixes with it, but this ingredient with this fat does not seem to have the cooling influence that it does in cold cream. Adeps lanæ is a closely similar preparation to lanolin. Glycerite of starch is another base occasionally employed, but is not in general use, and sometimes produces irritation. Upon exposed surfaces it is sometimes an advantage, purely cosmetic, to add a small quantity of calamin, umber, etc., to give the ointment selected a skin color (see under eczema).

Ointments are of various characters as regards the incorporated medicament—soothing, stimulating, etc. Soothing or mild ointments find their use in irritable and acutely inflamed cutaneous maladies, as in eczema of such type, and not only protect the skin from irritation, moisture, air, or other injurious influences, but are directly

comforting and healing to the diseased surface. The best exponents of this class are the zinc-oxid ointment, cold cream, simple ointment, cucumber ointment, and a few others. Zinc oxid, as well as calamin, bismuth subnitrate, and some other substances, in the proportion of from 5 to 15 per cent. or more, add slightly astringent and mildly antiseptic properties to such ointments, and are rarely detrimental. The addition of from 2 to 5 grains (0.135 to 0.33 gm.) of salicylic acid or from 5 to 10 grains (0.33 to 0.65 gm.) of boric acid, adds still further to the antiseptic character, and, as a rule, is not in this quantity disturbing, even in acute conditions, but all such additions in these cases must be made with caution. Cocoa-butter can also sometimes be added with advantage in the quantity of from 5 to 10 per cent.; it has a stiffening influence on the ointment consistence. Diachylon ointment is much used in Vienna, and if well made and fresh, is in many cases grateful, but it does not seem possible to be sure of a good preparation, and one improperly compounded or old or rancid is sure to irritate. Mild ointments are applied either by anointing or by spreading on patent lint or other suitable material; if lint is used, the ointment should be spread on the woven side, as, being free from fuzzy particles which are apt to stick to the skin, as well as being less likely for the fibers to break apart when the salve is spread on. It may also be applied on paraffined or waxed paper, being thinly spread; this is more especially applicable on parts where there is but little motion.

A good example of an antiseptic, and yet mild salve, in addition to those named, is the boric acid ointment (unguentum acidi borici). Stimulating ointments are constituted of one or more of the several bases named, with the addition of a drug having stimulating properties, such as sulphur, tar, white precipitate, calomel, or other mercurial, resorcin, salicylic acid, chrysarobin, etc., and, according to the proportion present, they vary from one scarcely stronger than a soothing salve to that actually caustic. Stimulating salves are usually to be well rubbed in.

Pastes are a form of ointment suggested by Lassar and elaborated by Unna and others, which are largely made up of pulverulent substances, most commonly starch and zinc oxid, with usually a petroleum fat as the fatty constituent. Lassar's formula—Lassar's paste—consists of 1 part each of zinc oxid and starch and 2 parts of vaselin, to which is commonly added 1 or 2 per cent. of salicylic acid—salicylic acid or salicylated paste. Duhring commends highly a somewhat softer paste, and more cleanly, consisting of 1 part boric acid, 3 parts each of zinc oxid and starch, and 12 parts vaselin. Others will be found referred to under eczema. These preparations are often of greater value than ordinary ointments in some cases of eczematous disorders of a subacute or not too acute type, owing to their stiffer consistence and to their greater adhesiveness, and also to their porosity; they make a thin, usually rapidly drying, protective coating.

Attempts have been made from time to time to find cleaner, ready made and spread ointment applications to take the place of

the ordinary salves, but so far the preparations known as salve-mulls or salve-muslins, devised by Unna and manufactured in Germany, and now obtainable in most of our large cities, are the only satisfactory substitutes; these often act very satisfactorily, the zinc oxid salve-mull being especially valuable. Their costliness is a disadvantage, and considerably limits their employment. **Plaster-mulls,** or **plaster-muslins,** also devised by Unna, are adhesive, plaster-like applications, variously medicated with mild to stimulating or caustic ingredients which have a more limited field; a tolerably fair substitute is now found in the "rubber plasters" of our own plaster manufacturers.

Oils are sometimes used in place of salves, both for the removal of crusts and scales and for the purpose of medication, especially upon the scalp; they may be variously medicated. Olive oil, almond oil, liquid petrolatum, and oil of cade, are among those most frequently employed. These and others will be referred to in connection with the diseases in which they are used. Oily preparations, as well as lotions without sediment, are best applied to the scalp by means of an "eye-dropper," putting a drop here and there and then rubbing in with a piece of woolen rag.

Fixed Dressings.—But little reference need be made to such in this place, inasmuch as those commonly used are sufficiently fully considered under eczema and psoriasis. In a way the salve-mulls, plaster-mulls, and rubber plasters already referred to are to be considered in this class, especially the latter two, which are adhesive and can sometimes be kept applied several days without change. Their use is, however, limited, and principally to some sluggish, chronic, thickened, dry types of eczema, patches of lichen planus, keratosis palmaris, and other epidermic thickenings, as clavus, and in some cases of lupus and tubercular syphiloderm.

Tragacanth, bassorin, and acacia mucilaginous applications, as well as gelatin dressings (glycogelatin), have been employed in recent years, and will be referred to specifically under eczema.

Collodion and liquor gutta-perchæ also furnish rapidly drying coatings, and may likewise be variously medicated. Collodion is more valuable than the gutta-percha solution, as it dries more quickly, is a thicker, firmer film, and exerts a more positive compressing action, which is of advantage. It has its chief field in psoriasis, in lupus erythematosus, in ringworm, small thickened patches of sclerous eczema and of lichen planus, callositas, and other keratoses. In psoriasis and ringworm, chrysarobin, formerly known as chrysophanic acid, is usually the medicinal ingredient, in from 10 to 15 per cent. proportion, sometimes with from 2 to 5 per cent. salicylic acid; and frequently this last alone, as in occasional cases of ringworm, callosities, clavus, etc. Oil of cade, pyrogallol, known formerly as pyrogallic acid, and other drugs are also thus used. Collodion paintings, especially of pyrogallol and resorcin, sometimes act with unexpected energy, so that some caution is at first necessary. As a rule, unless the added ingredient is an oily one, a mixture of equal parts of plain collodion and flexible collodion is a more satisfactory vehicle, the former alone tending to crack too easily, the latter drying somewhat

less rapidly and not possessing the same compressing power. In those instances where this last property is especially desired, as usually in lupus erythematosus, the plain collodion is the best. Other details will be found in connection with the various diseases in which this vehicle is employed, especially psoriasis. The gutta-percha solution, or traumaticin, is used chiefly as a vehicle for chrysarobin or salicylic acid, in the treatment of psoriasis and some keratoses.

Salve-pencils and **paste-pencils**, the former composed of wax, oil, sometimes with a gummy or resinous substance added, and the latter usually of a variable mixture or compound of tragacanth, acacia, starch, and other ingredients, have been brought forward, with different medicaments incorporated, for application to small spots or areas, but their field of usefulness is so extremely small that special comment is not necessary.

Antipruritics.—Carbolic acid is the most valuable antipruritic, and is often added for this purpose to ointments or lotions—in the former from 3 to 30 grains (0.2 to 2 gm.), and in the latter from 2 to about 10 grains (0.135 to 0.65 gm.) to the ounce (32 gm.), the proportion dependent upon the condition of the skin and the obstinacy of the pruritus, markedly inflammatory cases, and especially in children, requiring the smallest quantity. It is most agreeably prescribed in lotion form. Occasionally it is not well borne. Liquor carbonis detergens (formula under eczema), a solution of coal-tar in an alcoholic solution of soap bark, is somewhat similar, and an exceedingly valuable remedy, used in lotions chiefly from 1 to 3 drams (4 to 12 gm.) or more to the half pint (256 gm.); or in ointments, 5 to 30 minims (0.35 to 2 gm.) to the ounce (32 gm.). Resorcin, from ½ to 5 or 10 grains (0.035 to 0.65 gm.) to the ounce, according to the condition or disease, frequently exercises an antipruritic and quieting action. Boric acid in solution, usually saturated, also seems at times to exert, probably indirectly, a mild, quieting, soothing, or anesthetic action, and can often with advantage be made the basis for the other more active remedies just mentioned. Weak alkaline lotions, 2 to 16 grains (0.135 to 1 gm.) of borax or sodium bicarbonate to the half pint (256 gm.), are also sometimes of service in certain itching diseases, but are usually not to be employed in eczema. Menthol, hydrocyanic acid, liquor picis alkalinus, other tarry preparations, and other drugs, are sometimes employed for antipruritic effect, and will be referred to elsewhere, especially under eczema and pruritus.

Parasiticides are those remedies which are destructive more especially to the grosser animal and vegetable parasites. Among the most valuable are sulphur and its compounds; among the latter, especially sulphurous acid, the sulphite and hyposulphite of sodium, the sulphid of calcium, especially as the compound known as Vleminckx's solution, and potassium sulphid. These, as others, such as naphthol, the mercurials, and carbolic acid, are destructive to both animal and vegetable parasites, and find their employment chiefly in ringworm, favus, tinea versicolor, and scabies. Chrysarobin and iodin are also valuable vegetable parasiticides, and both Shoemaker and Crocker speak well of copper oleate in ringworm, and the former commends its action also in other vegetable parasitic diseases. In

scabies precipitated or sublimed sulphur and naphthol, of those named, are most commonly employed; frequently also styrax and balsam of Peru. The mercurials, especially corrosive sublimate solution, white precipitate, sulphur, stavesacre, and naphthol ointments, are commonly used against pediculi. In fact, the so-called parasiticides are numerous, as will be found in the text devoted to the parasitic diseases. They are in reality the same as antiseptics and bactericides, these latter usually meaning those which are, as a rule, somewhat weaker, and employed against the lower organisms, such as the pus-cocci, etc. In this class are boric acid, carbolic acid, resorcin, weak corrosive sublimate solutions, weak solutions of formaldehyd, washings with tincture of green soap and water, and many others, the most valuable in dermatologic practice being boric acid and resorcin. The value of ichthyol as an external application, the first knowledge of which we owe to Unna, is, in part at least, due to its bactericidal property, as attested by its favorable action in sycosis, furuncles, acne, etc. There are two varieties on the market, sodium ichthyol and ammonium ichthyol, the former usually going under the name of ichthyol. Aristol, acetanilid, iodoform, and others are also occasionally resorted to, but the last named, owing to its offensive odor and its venereal suggestiveness, should find rare application among respectable ambulatory patients.

Caustics are substances or agents which are more or less active destroyers of tissue. Among the strongest more commonly employed in dermatologic practice, and which are destructive alike to normal and morbid tissue, are caustic potash, chromic acid, zinc chlorid, and the galvanocautery and actual cautery, including the Paquelin cautery. They are used in malignant growths; chromic acid and caustic potash are sometimes used on warts. Caustic potash is an active caustic, and sometimes misleading at the time of its application as to the actual amount of destruction taking place; unless, therefore, care is exercised, it may destroy too much. When sufficient action has been effected, vinegar or dilute acetic acid should be applied to the part to neutralize it and prevent further destruction. The pain is considerable at the time, but rapidly subsides. Zinc chlorid, usually applied in paste (see lupus and epithelioma), is slow and increasingly painful, but valuable, producing a hard, leathery slough. Another caustic frequently resorted to, and which is in a sense elective, sparing, as a rule, normal tissue unless applied for too long a time, is arsenic. It is used in limited growths, such as small epitheliomata, as a paste with usually 1 or 2 parts of acacia; or to more extensive areas, as in lupus, as a 5 to 10 per cent. ointment. It requires from one to several days, according to the strength used; sometimes a repetition is necessary. It is painful, and produces marked inflammatory edematous swelling, but if used with proper precautions, it can scarcely be said to be dangerous. Pyrogallol has the same elective action, but not so constantly. Its method of application, as well as that of the other caustics, will be referred to under lupus vulgaris and epithelioma. Pyrogallol in collodion sometimes acts unusually sharply, and when so prescribed, must be done, at first at least, with caution. Nitric acid and the acid nitrate of mercury, are

comparatively superficial caustics, and are sometimes employed in warts, nævi, and other cases in which slight or surface destruction is sought. Lactic acid, if used freely and continuously, also has caustic action, but if applied scantily, its effect is superficial, or more that of a discutient. Among other discutients or keratolytics is salicylic acid, used as a 10 to 25 per cent. rubber plaster or plaster-mull, and which in epidermic thickening is often of great service. Other caustics are occasionally used, and will be found referred to in the course of the text.

Mechanical or Operative Measures.—Excision is practised in epithelioma, lupus, and other malignant formations. The cases of lupus and epithelioma, the two principal affections sometimes thus treated by dermatologists, in which permanent success is most promising, are those in which the disease exists as a small, sharply defined, circumscribed patch, the knife going well beyond the apparent limiting border. In more extensive cases of lupus this method has also been recently employed, following it up with skin-grafting by the Reverdin or Thiersch plan; with proper technic and under antiseptic precautions, good results have been secured by those skilled in this method.

Curetting, with the ordinary cutaneous curets, is a much more common recourse in dermatologic practice, and is extremely valuable in certain diseases, more especially in lupus vulgaris and epithelioma, but it should rarely be relied upon alone, a supplementary light cauterization, especially with pyrogallol salve or caustic potash solution, as described under these diseases, always being practised. Under this conjoint plan recurrences are much less likely to present than if curetting alone is depended upon. This instrument, with sharp or blunted edges, is also employed for other minor purposes, and such will be referred to in the discussion of the individual diseases in which it finds use.

The **galvanocautery** and **Paquelin cautery**, and Unna's small modification of the latter, the **microcautery** (Microbrenner), already mentioned under caustics, are often used to destroy tissue, in lupus especially. Besnier is a strong advocate for the galvanocautery in this disease, used with sharp and pointed instruments.

Linear and **punctate scarifications** with the single blade or sharp point, or with the variously devised multiple scarifiers, are found useful chiefly in lupus vulgaris. They are sometimes employed also in lupus erythematosus, and occasionally in small thickened sclerous eczematous areas. Punctate scarification is also resorted to in acne rosacea. The puncturing and incising knife or acne lance can often be employed with advantage in sluggish and suppurating acne lesions.

The **cutaneous punch** or **trephine**, brought into prominence by Keyes, and made in various sizes from that with scarcely more than a pin-sized opening to one $\frac{1}{4}$ to $\frac{1}{3}$ of an inch or greater in diameter, is occasionally resorted to for minor operations, as in the removal of gunpowder grains, small-sized tattoo-marks, moles, epitheliomata, and other growths. Probably its most common use is in the removal of diseased tissue for pathologic investigation.

Comedo extractors are variously shaped small instruments with a

central hole, varying from that of the ordinary watch-key-like instrument to that somewhat similar to a long double curet, but with the shank curved toward the ends.

Electrolysis, sometimed termed the electric or electrolytic needle operation, which we owe principally to Hardaway, is an extremely valuable procedure in certain diseases or conditions, as in the smaller nævi, telangiectasis, acne rosacea, warts, for the removal of superfluous hair, etc., and its method of employment will be found described in connection with these maladies. Electrolytic destructive action can also be effected by means of small metallic discs, and is sometimes employed for this purpose in lupus vulgaris (*q. v.*), as originally recommended by Gärtner, Lustgarten, and Jackson.

Electricity can also be used in other ways, the faradic current being valuable in some cases of acne, in alopecia, alopecia areata, and a few other diseases; in the first, applying it by means of an ordinary electrode or roller electrode, and in alopecia by a special metallic comb or brush, and in alopecia areata by means of a tinsel brush. The galvanic current is also a decided cutaneous stimulant, and is useful in sluggish conditions in alopecia areata used cautiously, in acne rosacea, acne vulgaris, in herpes zoster, and in some other affections. It is not improbable that there may be much more value in the treatment of superficially circumscribed dermatoses by drugs introduced by means of electric cataphoresis than the past few experiments in this direction would seem to indicate. The static current is likewise of adjuvant service, especially in diseases of a neurotic character, the roller applied over the clothing sometimes starting the absorption of infiltration; and the spark applied with the pointed electrode, carefully used, a decided stimulant to the patches of alopecia areata.

Radiotherapy[1] (**Röntgen-ray Treatment.—x-Ray Treatment**).—Ever since the experimental therapeutic use of this agent was stimulated by the recognition of its occasional accidental action on the cutaneous structures, observed by various skiagraphers, the literature of the day has furnished varying statements of its value in many of the dermatoses. Led mainly by Freund and Schiff in Vienna, Pusey and Williams in this country, Walsh, Morris and Sequeira in England, and Oudin, Barthélemy and Darier in France, its employment has been gradually adopted by all, or almost all, those engaged in dermatologic practice. For the past several years it has outranked everything else in its wide application, and the cutaneous disease was rare indeed that has escaped its trial. Continued observation and experience, including my own, though showing that some of the claims were extravagant, nevertheless very properly accord it a most important position in the treatment of certain diseases of the skin; while it should not be allowed to supplant other means and methods, it is to be recognized as a potent and helpful addition to our resources, especially in epithelioma, lupus vulgaris, and other cutaneous tuberculoses, in lupus erythematosus, sycosis, extreme and obstinate types of acne, in limited rebellious cases of eczema, ringworm

[1] Those desiring to pursue the subject further are referred to the book publications on Radiotherapy, by Freund, Williams, Pusey and Caldwell, Allen, and Belot, in which references to the extensive journal literature will also be found.

of the scalp, and some other diseases to be referred to in the course of the text. Its possibilities for evil, both for the patient and operator, should rightly limit its use within reasonable bounds and under sufficient precautions. Its reckless and indiscriminate application to any dermatosis, otherwise easily treated and handled, is to be deplored. It is true that the dangers, with improved technique, and the exercise of care, have been almost reduced to insignificance. There are, however, individual idiosyncrasies to be considered. Caution, therefore, should be the invariable rule in the use of this powerful agent, and the first several exposures should be tentative, not closer than 10 inches to the tube, and not more than 3 to 5 minutes' duration. A certain amount of bold hazard, when one is experienced, is occasionally permissible in such cases as the more malignant epitheliomata, and extreme cases of cutaneous tuberculosis, for frequently improvement is not brought about till the first, and sometimes the second, degree of *x*-ray dermatitis is provoked; but in such diseases as acne, sycosis, eczema, and the like no such risk would be warranted, and action beyond the production of the mildest erythema should be carefully guarded against. While the general hints given here and in connection with the diseases in which it is used will probably suffice for the intelligent, cautious worker, it would be a great advantage for those desiring to employ this treatment largely and thoroughly, if opportunity were first sought to gain at least a moderate practical knowledge with the apparatus and technique from one already familiar with the method.

The *x*-ray tube can be excited by either a coil or a static machine, and either will prove satisfactory in cutaneous cases. As to the size of the coil or static machine, the larger (within reasonable limit), probably the better, but the coil capable of a good 6-inch spark, or a static machine capable of an 8-inch spark, will be capable of doing good work; the small apparatus requires a somewhat longer exposure, and the rays from a static machine are weaker than those from a coil, but such can be readily compensated for by longer exposure or shorter distance, or both. A coil capable of a 12-inch spark is that in most common use, and this, as well as the larger and heavier static machines, are to be preferred, especially if they are also to be used, with the additional requisite apparatus, for the production of high-frequency currents. The static machine can be operated by hand, water, or electric power; the coil with currents from storage batteries or the street current. The coil has, as is well known, the greater advantage of reliability. Of the various forms of interrupters —mechanical or vibratory, mercury dip, or mercury jet or turbine, and electrolytic—the so-called mechanical interrupter is, upon the whole, the simplest and least troublesome, although they are all efficient, and each has advocates. It is not possible to give a fast rule as to the necessary amperage of current for the coil in the treatment, as this varies, depending upon voltage, and size and construction of the coil. Now that such instruments of precision as special ammeters to measure the number of milliamperes actually going through the tube are on the market, greater accuracy and standardization of current may soon be realized.

The *x*-ray tube should be, preferably, the kind that admits of regulation of the vacuum. My work has been performed with the Queen and the Gundlach tubes, and these have been satisfactory. There are many other tubes, however, that will do just as well. The vacuum of a tube is an important factor in the treatment of cutaneous diseases. As is well known, the rays from a tube of low vacuum exert their action chiefly superficially, and those from one of high vacuum, mainly in the deeper parts. As a rule, in skin diseases, with some exceptions, a deep action is not required; it should not be more than equal to a 2-inch-spark gap—in other words, a so-called low vacuum or "soft" tube. This has seemed to me the most efficient. Some, however, favor a higher or "medium" or "medium soft" vacuum, and others, again, a higher vacuum, or "hard" tube. I consider it a mistake to hold the tube at the same vacuum throughout the exposure; it is much better, I believe, to secure even action upon all the areas (superficial and deeper) of diseased tissue and cells, to set the vacuum equal to a 1- to 2-inch spark, and then disconnect or put out of action the regulating device; during the time of exposure the vacuum will slowly and gradually rise. If the dermatosis is exceedingly superficially seated, the vacuum can be set low—$\frac{1}{4}$- to $\frac{1}{2}$-inch spark gap—and then allowed to rise. Should the desire be, in some instances, or at times, to have the extreme outer surface of the skin relatively spared, as obtains in some stages of the treatment of epithelioma and lupus, where surface action is to be avoided or has already been sufficient or troublesome, then a thin sheet of aluminum can be interposed (Thompson) between the tube and the part treated, thus shutting off or limiting the short or superficially acting rays. Instead of the aluminum sheet, I employ old tubes for this purpose, those that have become considerably darkened and coated with metal.

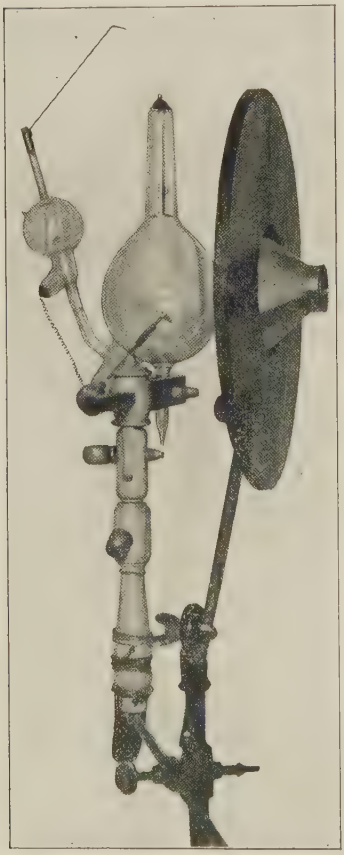

FIG. 23.—Stand with tube-holder and protecting disk referred to in the text.

Great care should be exercised that the wires connecting the tube with the coil or static machine are firmly attached and so placed that there is no possibility of their getting loose or in any other way coming in contact or even in close proximity to the

patient, in order that unpleasant shock and unnecessary alarm may be prevented.

An important desideratum in *x*-ray treatment is the protection of the other parts not being treated. Various plans are in vogue, and are well known. The most common is the covering over of the surrounding and nearby parts with thin sheet-lead or several layers of tinfoil, an opening being made sufficiently large for the diseased area. If the disease is on the face, a mask can be made (pasteboard or gauze) and covered with four or five layers of tinfoil, except at the part immediately over the disease, which can be cut out. These devices,



FIG. 24.—Same stand, with protecting box, referred to in the text.

however, consume time. In my own work, which is largely for disease seated upon the face or some parts of it, I employ either of the two shields, as is shown in the illustrations. This simple plan I have found quite convenient. One model consists of a thin wooden or stiff pasteboard disk, 15 inches in diameter, with one side covered with thin leadfoil; this disk has a large central opening which may be made smaller for the individual case by means of attached, swinging, or hanging smaller-sized perforated disks. The disk is attached to the end of the projecting arm of a photographer's head-rest; it can be thus turned and adjusted at any height or angle and

in almost any position. This stand, with its protecting disk, was suggested to me by Dr. Pfahler, who has longer employed it. I have added to its usefulness by retaining the back-rest, to which can be fastened the movable support and arms of an ordinary wooden tube-holder stand for holding the tube. As thus rigged, the stand answers the purpose of both a protecting screen and tube-holder. It is simple, convenient, inexpensive, and requires but little space. When the distance of the tube from the patient is to be more than 5 or 6 inches, a projecting funnel, as shown in the illustration, with proper-sized opening, can be fastened to the screen with rubber bands, and the projecting aperture brought directly over the part to be treated. Since my *x*-ray work has increased, I now, especially when the exposure is of any duration, prefer the box, as this shuts off all rays from other parts of the room, and thus more fully protects both patient and operator from diffused rays. Either is, however, satisfactory.[1] With such an arrangement one could do away with the necessity of attaching any protecting foil to the patient; but it is probably better to place a narrow band of foil around about the diseased area, to protect the surrounding skin from stray rays; this can be fastened with adhesive plaster. Particular attention should be given to the protection of the scalp, hair, eyebrows, and eyelashes, for exceptionally a single exposure, especially if at all prolonged, will be followed by complete hair-loss of the part exposed; a regrowth, however, finally takes place. In long exposure the lips should also be protected.

In ordinary therapeutic work the protection, by the above measure, thus given the operator will usually be sufficient to prevent any damaging action. In addition to this an arrangement can readily be rigged so that the current is stopped before the operator approaches the tube. An additional screen can also be placed between the tube and the part of the room where the physician or attendant is seated while the exposure is going on. With such precautions, protecting foil-lined or interlined gloves or mits that I formerly used are no longer absolutely necessary.

Further data as to the action of the rays, both therapeutically and pathologically, as well as the distance of the tube and duration of exposure, will be found under *x*-ray Dermatitis and in connection with the diseases in which the method is employed.

In place of the *x*-ray, **radium** and other radio-active substances have been variously extolled. Radium has apparently about similar radio-active properties, but is weak in comparison. For use in cavities, such as the mouth, nose, etc., and for easy application to small cutaneous lesions it has some advantages, more especially of convenience. It can be used either in a properly arranged applicator; or on surface lesions the glass receptacle or aluminum capsule containing the radium can be fastened with adhesive plaster. The duration of application should be at first 20 minutes daily, and if there are no reactive symptoms the time gradually increased up to a few hours or longer; the average being about 1 to 2 hours daily. Much de-

[1] Several similar protecting shields are now on the market; the Friedländer shield is an especially convenient one.

pends upon the activity of the preparation employed—it should have a radio-activity of not less than 7000 units, and it is much better if it is of 20,000 and upward; with the weaker the lessened power must be made up by increased quantity, and much longer application. The weaker, being comparatively inexpensive and safer, can be entrusted to the patients with instructions for exposure at short intervals.

FIG. 25.—Finsen hollow compressing lens referred to in the text; the two tubes are for ingress and egress of water. Cut is about two-thirds its actual size.

Actinotherapy.—To Finsen, chiefly, we owe the established usage of the application of concentrated light deprived of its heat rays to the treatment of cutaneous disorders. His experimental studies with the concentrated light, demonstrating its destructive action upon bacterial life, led him to apply it to the treatment of lupus vulgaris. Since then he and others have broadened its therapeutic field, and it is now, in some of its forms of application, also used in lupus erythematosus, epithelioma, alopecia areata, and some other diseases. While Finsen at first resorted to sunlight, applying it through a properly shaped water-containing lens, owing to the uncertainty of this source, he and his associates Forchhammer, Bang, and others, subsequently discarded this for the carbon arc-light of high power, this being richer in the acting rays, and always available. The main forms of apparatus are: First of all, the Finsen (so-called large Finsen), and the smaller, similar (Finsen-Reyn) lamps; in these the principle of several condensing lenses, arranged for concentration in a telescope-like tube, is the essential part. This, it is maintained, and doubtless rightly, is necessary for the deep penetration of the rays, and in order to get sufficiently deep curative action. It naturally necessitates some distance between the actual light and the part being treated, and requires more prolonged exposure to obtain reaction; the light, therefore, is focused upon the required point. One of the sections between the lenses is filled with distilled water, and around this section there is a thin hollow jacket, through which ordinary water is kept circulating; the heat rays are thus filtered and overheating of the apparatus prevented. In addition, on the part treated there is firmly pressed a hollow compressing lens, consisting of two quartz lenses set in a metal band, through which water is also kept circulating; besides still further straining out the heat rays, this compression lens also serves to press out the blood from the tissues, the blood being a hindrance to the deep penetration of the rays. The pressure is maintained by fastening this hollow lens with straps or elas-

tic bands, aided by the attendant. The large Finsen lamp requires with medium commercial voltage a current of 80 amperes; the Finsen-Reyn lamp 20 amperes. Lortet and Genoud, and, later, others, in order to lessen the time of application, as well as to reduce the cost of the apparatus, and the amount of current required, discarded the principle of the telescopically arranged condensing lenses, and constructed an apparatus so as to bring the light close to the part treated. This consists of a basin- or bowl-shaped, thin, hollow metallic shield, at the projecting center of which is set a lens, on each side of the shield; the arc light, of carbon points, is brought up close to the inner lens, and against the outer lens the patient presses the part to be treated; the apparatus is kept cooled and the heat rays strained out by keeping water continually circulating through the thin cavity of the shield and lenses. While at first this form of apparatus, known as the



Fig. 26.—The Finsen hospital lamp (showing the method of employment): The projecting tubes can be shortened and lengthened so as to permit the focusing of the light upon the diseased area being treated; the light is directed through the hollow lens (through which water is circulating), which is kept pressed down upon the part under treatment. It will be noted that both attendants and patients are provided with dark glasses to protect the eyes from the brilliant dazzling light.

French, or Lortet and Genoud, lamp, and as the London Hospital lamp, was lauded as an improvement, further experience has shown it to be much less penetrating, and much less effective in the treatment of lupus. It usually brings about a much more rapid surface-action, but fails in depth, even when the time of exposure is continued as long as with the Finsen lamps.

It has, however, a field of usefulness in superficial dermatoses, such as superficial lupus vulgaris, alopecia areata, and some others. It requires from 5 to 15 amperes. Bang and others, in efforts to save time in application, constructed a somewhat similarly arranged

pressure lamp, having, instead of carbon, hollow-iron electrodes at the arc, which were kept cooled by water running into their cavities. The arc of iron electrodes is rich in the erythema-producing short rays, and a decided surface reaction can be brought about in a few minutes, but it is still less penetrating than the Lortet and

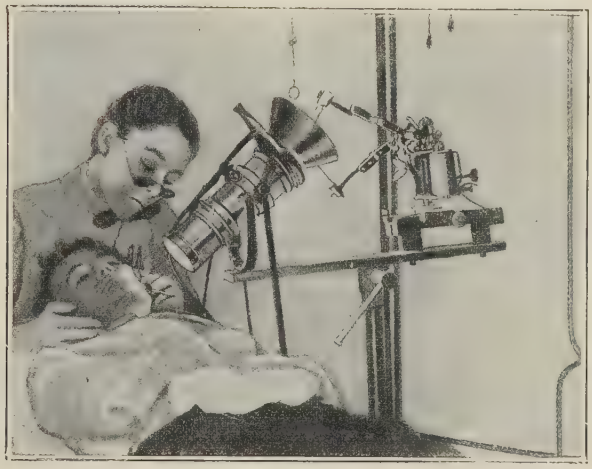

FIG. 27.—The Finsen-Reyn lamp in operation (Allen).

Genoud lamp. It is, however, useful where a quick superficial action is desired. Moreover, it requires but a few amperes of current. Somewhat similar, but still less active, lamps are those devised by Görl, Leduc, Piffard, and others, in which the light comes from the electric spark between several, or more closely contiguous, metal electrodes; this light is rich in the ultraviolet rays, but its action is exceedingly superficial. There seems to be no question that in lupus vulgaris the most efficient lamps are those known as the large Finsen, and the later smaller one known as the Finsen-Reyn lamp.[1] The Finsen method will be further considered in the section on treatment of tuberculosis of the skin.

In addition to these several lamps intended for the close or concentrated treatment of a limited area, there are others now employed with carbon, carbon-iron, and iron electrodes by which the actinic light is projected by means of a parabolic reflector upon large surfaces; the heat effects in some of these latter are also of therapeutic value in some cases. These larger reflecting lamps are found

[1] Finsen, *La semaine médicale*, Dec. 22, 1897; Finsen and Forchhammer, *Mittheilungen aus. Finsen's med. Lyseninstitut*, Nos. 5 and 6, Jena, 1904. (This covers all work done at the Finsen Institute to date.) Bang, *Monatshefte*, July, 1, 1898; Valdemar Bie, *Brit. Med. Jour.*, Sept. 30, 1899; Macleod, *Brit. Jour. Derm.*, Sept. 1899; Stelwagon, *University Med. Mag.*, Phila, Dec., 1900; Discussion, Section Dermatol., *Trans. Internat. Cong.*, Paris, 1900; Discussion, Brit. Med. Assoc., *Brit. Jour. Derm.*, 1901, p. 381; Leredde and Pautrier, *Annales*, 1902, pp. 327, etc.; Hyde, F. H. Montgomery, and Ormsby, *Jour. Amer. Med. Assoc.*, 1903, xl., p. 1; F. H. Montgomery, *Jour. Cutan. Dis.*, 1903, p. 529; Morris and Dore, *Practitioner*, April, 1903. Also the recent book publications by Freund, Williams, Leredde and Pautrier, and Allen.

useful in those diseases usually benefited by sun exposure, as psoriasis, some cases of eczema, etc.

The **high-frequency current** (known both as high-frequency and high-tension currents) probably had its first introduction in medicine by W. J. Morton, of New York, but the experiments by Tesla, with modern apparatus, and the enthusiasm of D'Arsonval led to its present position in medical therapeutics; it was Oudin, however, who gave it this impetus in the treatment of diseases of the skin, and whose enthusiasm stamped it with almost alluring powers. Many of the claims made for it have failed of corroboration by other writers, but that it has value in some dermatoses, no one who has conscientiously tried it can deny. It is still, however, in the experimental stage, and needs much more experimentation before its proper status can be known. The subject has excited sufficient interest to lead to the publication of some monographs and to giving it an important place in works on allied subjects.[1] Variously shaped electrodes have been designed for its application, but those of greatest value and most generally useful in dermatology are the hammer-shaped vacuum electrode and the carbon, and glass-point, electrodes.

Sundry other measures and instruments sometimes have a use in dermatologic therapeutics, such as poultices for removing crusts; roller bandages for supporting dressings and otherwise aiding in the treatment, as in eczema of the legs associated with varicose veins; rubber or elastic bandages and elastic stockings for similar purpose, but these must be used with caution, owing to possible irritation. Counterirritation over the vasomotor centers controlling the affected region—a local measure with, however, a constitutional influence—has been highly commended by Crocker in obstinately recurring eczema and similar inflammatory diseases; it may be effected by sinapisms, blisters, or with the galvanic electrode, or with the point or roller electrode of the static current. Massage or rubbing with oils or ointments is sometimes of service in starting up the absorption of inflammatory exudates or induration, and is also valuable in elephantiasis, scleroderma, in alopecia, and some other affections.

In addition to the various instruments already indicated may be mentioned the dental burr and hook used in the destruction of isolated tubercles in lupus vulgaris; the depilating forceps, with easy spring, for extracting hairs; a hypodermic syringe, and a slightly larger but similar syringe for washing out acne-abscess cavities; an atomizer for spraying and cleansing purposes; and a small massage cup for local massage of the face, and for favoring bleeding and discharge in the opening of acne lesions, etc. In some cases a glass pleximeter to observe the lesional appearance under pressure, a magnifying glass for more accurate inspection in occasional instances, small grappling forceps, and some other instruments usually contained in an ordinary pocket case, together with other special instruments and apparatus mentioned for particular purposes in the course of the text will be found of service in dermatologic practice.

[1] Denoyés, *Les Courants de Haute Frequence*, Paris, 1902; Chisolm Williams, *High-frequency Currents in the Treatment of Some Diseases*, London, 1903; Freund's *Radiotherapy*, and Allen's recent work.

CLASSIFICATION.

PROBABLY in no field of medicine has the proper and rational classification of diseases been fraught with so much difficulty as in that of dermatology. In the earliest period, with knowledge lacking both as to the seat and character of the histologic changes and the nature of etiologic factors it was natural that the attempts should have been based upon external appearances or crude anatomic forms. Thus arose the classification of Willan, which was a development on the lines previously suggested by Plenck, and inasmuch as in this plan papular eruptions were placed in one group, vesicular eruptions in another, and so on, it had some advantages for diagnostic study, and has even yet much to commend it. Although it had the advantage of simplicity, it linked together totally dissimilar diseases, and gave no intimation of the pathologic process and the cause of the malady, and therefore no hint as to therapeutic management.

Alibert endeavored to build up a classification upon a somewhat similar but broader basis, according to the clinical character and inherent natural affinities of the various diseases, but, owing to the many contradictions necessarily entailed in its elaboration, it did not gain universal acceptance. The French have, as a rule, always favored the emphasizing of the constitutional etiologic factors, as displayed in Bazin's classification, but the weakness of such a foundation is the assumption of data of cause and effect that in great measure are purely hypothetical. Nor did Erasmus Wilson's scheme, grounded essentially upon the anatomic structure of the skin, meet with general favor..

The system that has been received with the greatest support is that elaborated by Rokitansky and Hebra, who, with the pathologic knowledge of the former and the pathologic knowledge and clinical experience of the latter, formulated a classification, based principally upon pathologic histology, and yet with some, although minor, reference to etiology, anatomy, and physiology. In following this plan, however, certain inconsistencies are evolved, but much less strikingly at the time of its adoption than at the present day. Other praiseworthy attempts, displaying much thought, dividing the diseases into natural classes and subdivisions, based, for the most part, primarily upon the general pathologic factors,—using the term pathologic in its broadest sense,—have been made by Auspitz and Bronson,[1] and although their scientific elaborations appeal to the trained dermatologic mind, that promulgated by Hebra would seem to be less complex and to form a better working basis for teaching and study.

Professor Duhring,[2] who, in his former treatise, adopted Hebra's

[1] Bronson, *Jour. Cutan. Dis.*, 1887, pp. 371 and 427; also gives an analysis of Auspitz's classification in the same publication, 1884, pp. 161 and 202.

[2] Duhring, *Jour Cutan. Dis.*, 1898, p. 97: and *Cutaneous Medicine*, part ii., p. 223.

system, with some slight modification, recently urged, doubtless, by the changing views in late years regarding the causes of disease, still further modified it by more or less completely eliminating etiology and omitting an etiologic class, its foundation being essentially clinical features, normal and pathologic anatomy. While it has many advantages, and shows the usual careful and profound thought of this distinguished dermatologist, the elimination of the long-recognized and accepted class of "parasitic diseases" and their transference to the "inflammations" constitute too great an overthrow of established usage for the wisdom of this plan to gain immediate recognition, although, in view of the prevailing belief that many other cutaneous diseases not included therein are due to micro-organisms, the abolition of such a class would seem to be a necessary logical outcome. It is only too true that a perfectly satisfactory classification—one that is free from criticism—is, in the present state of our knowledge, an impossibility, and the "alphabetic" arrangement adopted by some American and French authors, and for the present also in use by the American Dermatological Association, is sufficient evidence of this.

I had long thought to accept the latter plan as an easy way out of difficulty, and one that has some advantages; but on mature consideration I feel that a classification, although it may be imperfect and inconsistent in many of its details, yet contains much knowledge and information that readers and students unconsciously assimilate. The system here adopted for this purpose is Hebra's system, which, I believe, with its modifications by Crocker, of placing, for more convenient reference, the diseases of the appendages in one class, and with the further slight modifications by Morrow, still constitutes, in spite of its inconsistencies, the most practical one. The propriety of transferring some diseases from one section to another upon the basis of more recent clinical observations and pathologic investigation, has occurred to me, and most strongly as regards erythema induratum scrofulosorum, lichen scrofulosus, lupus erythematosus, etc., about which there is a growing belief, in which I share, that we have to do with affections due either directly or indirectly to the tubercle bacillus, and if so, properly classifiable among the tuberculoses of the skin; but the evidence is not yet sufficiently conclusive to warrant such transference without some risk that the change may not be a permanent one. Rearrangement, it seems to me, should be only upon the basis of at least tolerably assured certainty. I have, therefore, made but a few, and these immaterial, changes, more especially in the grouping and order of consideration of the diseases in a few of the classes, and have added a supplementary chapter for the brief presentation of a few diseases of the adjoining mucous membranes.

Class I.—HYPEREMIAS.

	Essential Character.
Erythema hyperæmicum. Erythema intertrigo. Erythema scarlatinoides.	Active congestion.

Class II.—INFLAMMATIONS.

	Predominant Clinical Characters.
Erythema multiforme.	Erythematous, erythematopapular, or multiform.
Erythema nodosum.	Erythematonodular.
Erythema induratum.	Erythematonodular and ulcerative.
Erythema elevatum diutinum Pellagra.	Erythematous.
Urticaria. Urticaria pigmentosa. Œdema angioneuroticum.	Erythematous, edematous.
Pityriasis rosea. Dermatitis exfoliativa. Dermatitis exfoliativa epidemica. Dermatitis exfoliativa neonatorum.	Erythematosquamous.
Prurigo. Lichen ruber. Lichen planus. Lichen scrofulosus.	Papular.
Psoriasis. Pityriasis rubra pilaris.	Papulosquamous.
Eczema.	Erythematous, papular, vesicular, pustular, squamous, or multiform.
Eczema seborrhoicum.	Erythematosquamous, erythematopapular, or multiform.
Herpes simplex. Herpes zoster.	Vesicular—grouped.
Hydroa vacciniforme. Pompholyx.	Vesicular and bullous.
Dermatitis herpetiformis.	Usually vesicular and bullous; less frequently erythematous, erythematopapular, pustular, or mixed.
Pemphigus.	Bullous.
Dermatitis repens.	Epidermic denudation and serous undermining.
Impetigo contagiosa.	Vesicopustular.
Ecthyma.	Pustular—large, with markedly inflammatory base.
Impetigo herpetiformis.	Pustular—miliary, grouped, and spreading concentrically.
Furunculus. Carbunculus. Phlegmona diffusa.	Phlegmonous.
Dissection wounds. Equinia. Malignant pustule.	Pustular, papillomatous, necrotic.
Erysipelas. Erysipeloid.	Erythemato-edematous.
Sphaceloderma— Dermatitis gangrænosa infantum. Multiple gangrene in adults. Diabetic gangrene. Symmetric gangrene.	Necrotic and gangrenous.

Dermatitis calorica. Dermatitis traumatica. Dermatitis venenata. X-ray dermatitis. Dermatitis factitia. Dermatitis medicamentosa.	Varied—multiform, superficial, or deep-seated.
Exanthemata. Scarlatina. Rubeola. Rötheln.	Erythematous, maculopapular.
Varicella.	Vesicular.
Variola.	Primarily papular, then vesicular and pustular.
Vaccinal eruptions.	Erythematous, vesicular, pustular, multiform, etc.

Class III.—HEMORRHAGES.

	Essential Character.
Purpura.	Blood extravasation.

Class IV.—HYPERTROPHIES.

	Predominant Feature.
Lentigo.	Circumscribed pigmentation.
Chloasma.	Diffused pigmentation.
Nævus pigmentosus.	Circumscribed pigmentation with variable tissue increase.
Acanthosis nigricans.	Pigmentation, with verrucous growths.
Clavus.	Circumscribed epidermic thickening.
Callositas. Keratosis palmaris et plantaris.	Hardened epidermic thickening.
Keratosis senilis.	Circumscribed horny epidermic thickening or accumulation.
Keratosis pilaris.	Epidermic follicular papules.
Keratosis follicularis.	Pilosebaceous horny plugs.
Verruca.	Circumscribed epidermic papillary formation.
Cornu cutaneum.	Projecting epidermic horny formation.
Ichthyosis.	Epidermic thickening, with variable papillary elevations.
Porokeratosis.	A spreading plaque with a dyke-like epidermic horny periphery, and usually atrophic center.
Angiokeratoma.	Circumscribed telangiectatic, epidermic, wart-like formation.
Scleroderma. Sclerema neonatorum.	Cutaneous induration and infiltration, with sometimes later atrophic changes.
Œdema neonatorum.	Edema, infiltration, with variable induration.
Elephantiasis.	Thickening and enlargement.
Dermatolysis.	Hypertrophy and looseness.

Class V.—ATROPHIES.

	Prominent Characters.
Albinismus.	Absence of pigment, congenital—patchy or universal.
Vitiligo.	Patchy absence of pigment with peripheral increased pigmentation ; acquired.
Glossy skin.	Glossy thinned skin, usually of fingers or hand.
Atrophia senilis.	Thin, wrinkled skin, with circumscribed pigmentation and often scurfy spots.
Striæ et maculæ atrophicæ.	Linear and patchy thinning ; white, pearly, or pinkish.
Diffuse idiopathic atrophy.	Thinning, limited or general, with often associated whiteness or pigmentary changes and wrinkling.
Kraurosis vulvæ.	Thinning, shriveling, with constriction.
Ainhum.	A constricting, contracting corneous band.
Perforating ulcer of the foot.	Penetrating progressive circumscribed ulcer leading to the formation of a sinus.
Morvan's disease.	Analgesic whitlows.

Class VI.—NEW GROWTHS.

	General Character.
Cicatrix. Keloid. Dermatitis papillaris capillitii. Molluscum contagiosum. Multiple benign cystic epithelioma. Adenoma sebaceum. Lymphangioma circumscriptum. Xanthoma. Xanthoma diabeticorum. Colloid degeneration of the skin. Angioma. Nævus vascularis. Telangiectasis. Angioma serpiginosum. Fibroma. Lipoma. Myoma. Neuroma.	Benign.
Rhinoscleroma. Tuberculosis cutis. Tuberculosis ulcerosa. Tuberculosis disseminata. Tuberculosis verrucosa. Scrofuloderma. Lupus vulgaris. Lupus erythematosus. Syphilis. Aleppo boil. Frambesia. Verruga.	Of possible malignancy.

Carcinoma. Paget's disease. Epithelioma. Xeroderma pigmentosum. Sarcoma. Granuloma fungoides. Leukemias. Leprosy.	Malignant.

Class VII.—NEUROSES.

	Chief Symptom.
Hyperesthesia. Dermatalgia.	Increased or painful sensation.
Erythromelalgia.	Pain and burning, with lividity.
Pruritus.	Itching.
Anesthesia.	Decreased sensation.

Class VIII.—DISEASES OF THE APPENDAGES.

	Predominant Process or Symptom.
1. Nails.	
Onychauxis.	Overgrowth, with or without malformation or inflammation.
Atrophia unguium.	Defective growth, degenerative or dystrophic changes.
Onychomycosis.	Degenerative, granular, and friable, due to vegetable parasitic invasion.
2. Hair; Hair-follicles.	
Hypertrichosis.	Excessive growth.
Atrophia pilorum propria	Atrophic changes.
Fragilitas crinium.	Defective growth, fragibility.
Trichorrhexis nodosa.	Nodular swelling and bursting.
Monilethrix.	Intermittent thinning of hair-shaft.
Piedra. Tinea nodosa. Lepothrix.	Concretions on hair-shaft.
Canities.	Loss of pigment.
Alopecia.	Baldness.
Alopecia areata.	Baldness in patches.
Folliculitis decalvans.	Follicular inflammation, with consequent atrophy and hair loss.
Sycosis.	Follicular inflammation, with papulation and pustulation.
Conglomerate suppurative folliculitis.	
3. Sebaceous Glands.	
	Predominant Process or Symptom
Seborrhea.	Increased and altered secretion.
Milium. Steatoma.	Retention cystic formations.
Comedo.	Blocking up of glandular outlet, with retention.
Acne.	Inflammation, with papule or pustule formation.
Acne varioliformis.	Inflammation, with resulting scarring.
Acne rosacea.	Inflammation, with vascular stasis or dilatation.

4. Sweat-glands.

Anidrosis. Hyperidrosis. Bromidrosis. Chromidrosis. Hematidrosis. Uridrosis. Phosphoridrosis.	Disordered secretion without structural change.
Sudamen. Hydrocystoma.	Disordered secretion with structural change.
Miliaria.	Disordered secretion with inflammatory structural change.

Class IX.—PARASITIC AFFECTIONS.

A. Vegetable.

	Part Involved and General Character.
Favus.	Hair and skin; yellowish, mortar-like crusting.
Ringworm.	Hair and skin; patchy scurfiness, usually rounded, ring-like, with hair brittleness.
Tinea imbricata.	Skin; concentric, imbricated scaly rings.
Tinea versicolor.	Skin; chiefly upper trunk; fawn-colored patches.
Erythrasma.	Skin; axillary and genitocrural regions; reddish or yellowish-brown patches.
Dhobie itch.	Skin; inflammatory; usually axillary and genito-crural regions.
Pinta disease.	Skin; variously colored patches.
Myringomycosis.	Skin; ear canal; scurfiness.
Actinomycosis. Mycetoma.	Skin and subcutaneous tissue; infiltration, nodulation, and usually sinuses.
Blastomycetic dermatitis.	Skin and subcutaneous tissue; tubercular and papillomatous.

B. Animal.

Pediculosis—capitis, corporis, pubis. Cimex lectularius. Pulex irritans. Miscellaneous. { Ixodes. Dermanyssus avium. Culicidæ. Similidæ. Apidæ, etc.	Living on or attacking the skin.
Scabies. Leptus autumnalis. Pulex penetrans. Dracunculus. Cysticercus cellulosæ. Demodex folliculorum. Miscellaneous. { Œstridæ. Craw-craw. Echinococcus cutis, etc.	Penetrating the skin—either the parasites or their larvæ.

CLASS I.—HYPEREMIAS.

In the class of hyperemias (hyperæmiæ), or congestions, should be included only those cutaneous conditions characterized by an abnormal flux of blood, unattended by ordinary inflammatory changes. This class is directly opposed to that known as *anemias*, sometimes included in dermatologic treatises, in which there is an abnormal diminution of blood in the part, resulting in pallor of the skin. This latter is merely a passing condition without significance or a more or less permanent state symptomatic of systemic blood impoverishment; it belongs, therefore, more properly to general medicine, and need not be considered here. Although hyperemias are to be considered as simple congestion, it is not unusual to find often a slight, although scarcely perceptible, tendency to inflammatory action. On the other hand, instead of being an active phenomenon, it may be purely a passive congestion, really a stasis, and which may be of a dark, livid color,—livedo,—and due to local causes or to general circulatory weakness, sometimes resulting in a more or less general passive, livid congestion of the surface—cyanosis. The active hyperemias are represented by the non-inflammatory or non-exudative erythemata.

ERYTHEMA.

When used alone, this term is a somewhat indefinite one, and indicates a hyperemia or redness of the skin that may be congestive or exudative. Ordinarily, however, it refers merely to the simple hyperemias coming under the head of erythema hyperæmicum seu simplex, those erythemata that are exudative coming under the head of inflammations. The dividing-line between the erythemata without exudation and the erythemata with exudation and the mildest grades of dermatitis cannot always be clearly drawn.

ERYTHEMA HYPERAEMICUM.

Synonyms.—Erythema simplex; Erythema congestivum.

Definition.—Erythema hyperæmicum may be defined as a hyperemic disorder, appearing in the form of variously sized and shaped, circumscribed or diffused, limited or more or less general, pinkish or red, non-elevated patches.

The erythemata are usually divided into two general classes—idiopathic and symptomatic. In the former are included all those erythemata due to external agencies. In the latter, all those cases in which the erythema precedes or accompanies systemic febrile disease; and those due to disorders of the digestive tract, to the development of intestinal toxins, and to the ingestion of certain drugs.

Symptoms.—Of the Idiopathic Class.—The essential symptom is redness, which may vary as to degree, but is without perceptible elevation or infiltration. It disappears under pressure, to reappear as soon as pressure is withdrawn. It varies in extent in different

instances, dependent upon the amount of surface exposed to the etiologic factor, most of the cases naturally being of a limited area.

If the cause continue, the condition may progress from an erythema to a dermatitis; such cases will be considered under the latter head. If the erythema occurs repeatedly in the same location, there may be, in consequence, more or less pigmentation, but this is usually slight in character.

In this class are to be found the erythemata due to heat and cold —**erythema caloricum.** That due to artificial heat is sometimes designated **erythema ab igne,** and that occurring from the effects of the sun's rays, **erythema solare.** The former is seen on the lower parts of the legs of those who may be in the habit of sitting close to the fire, such as cooks, stokers, and engineers. It appears as ill-defined red spots, sometimes with a tendency to be gyrate and annular; after cessation of the cause it may give place to moderate pigmentation. The erythema due to the sun's rays is well known, being, according to the duration of exposure and season, and in a measure to the sensitiveness of the individual skin, from a light to a brilliant red in appearance. Although heat doubtless has an influence in its production, it is now known that the chemical or actinic rays of light play the important part. Prolonged exposure, in those with sensitive skin, may result in a dermatitis, usually of a vesicular character. Repeated exposures result in gradual pigmentation which, owing doubtless to the pigment protecting the parts from the actinic rays, leads to more or less invulnerability.

Under erythema caloricum belongs also the erythema due to exposure to cold,—**erythema pernio, chilblains,**—more frequently met with in children and old people with feeble circulation. The common sites are the heel, toes, ears, nose, and fingers. The affected part is dark red, especially when it is brought in proximity to heat of any kind. It is more or less in abeyance in mild weather, and is especially troublesome in winter, particularly after being out in the cold. There is often considerable burning and sometimes, also, itching. The condition is frequently persistent, and often rebellious to treatment.

Another source of the erythemata of the idiopathic class is traumatism of mild degree—**erythema traumaticum.** This is due to pressure or friction—as, for example, from tightly fitting garments, a truss, garters, tight bandages, etc. It is localized, and disappears rapidly upon removal of the cause.

Erythema paratrimma is a term, now almost obsolete, sometimes applied to erythemata due to pressure, more particularly to the erythema preceding the formation of a bed-sore. Probably of pressure origin is that erythema seen not infrequently at the back of the neck in infants, sometimes extending up into the hair—**erythema nuchæ,** which is usually transitory.

Erythema venenatum is a name given to those simple erythemata produced by the irritation of various mineral and vegetable substances, such as mustard, arnica, strong soap, dye-stuffs, certain plants, and the like.

Symptoms.—Of the Symptomatic Class.—Redness, disappearing

upon pressure, is likewise the essential symptom characteristic of this class. The erythema varies in extent in different cases, and may consist of but one or two insignificant patches, or the general surface may be more or less covered. The emotional flushings, for instance, of which repeated blushing is the mildest example, can doubtless be included under this class. The color of the symptomatic erythemata varies usually from a bright pink to red, but it may be of a darker hue, and may even be somewhat livid. As a rule, there are no subjective symptoms, although in some cases slight burning and a feeling of warmth may be experienced. Itching is rarely present to any degree, and is usually entirely absent. Several varieties may be referred to.

Erythema læve may properly belong in this class, although there is a local element in its production, and it is usually persistent. This refers to the shiny and glistening redness of the skin sometimes observed in connection with edema of the legs.

Erythema fugax, as the term signifies, applies to those erythemata, of obscure origin, which appear in one or more areas, and which are capricious in their appearance and disappearance. Such an erythema may appear suddenly, most commonly on some part of the face, and disappear again in the course of a few minutes or several hours, to remain away or to reappear. It is possibly allied to urticaria, although itching is rarely present to any degree.

Erythema urticans is somewhat similar, but usually evanescent in character and quite itchy. It is, as in almost all the cases of this class, unattended by desquamation.

In other cases the erythema, or rash, is more or less general, presenting either as areas or sheets of continuous redness or as closely crowded or scattered red spots. Sometimes the redness is punctate, but as a rule it is uniform. *Roseola* is a term that has been applied more or less indiscriminately to some of the symptomatic erythemata, and may be regarded as a designation for the more or less general rashes of this class; it is applied more particularly, however, to those erythemata characterized by spots or patches, rather than by diffused rashes. The symptomatic erythemata may be seen sometimes preceding or in the course of some systemic diseases, such as vaccinia, diphtheria, variola, etc., or they may arise from some stomachic and intestinal diseases and from intestinal toxins. In the generalized rashes due to these latter causes there may be some slight febrile action, which, however, soon subsides. The *erythema infectiosum* of Esherich, Shaw,[1] and others appearing in children in the spring and summer, and characterized by somewhat generalized macular and patchy erythema, more especially on the face, legs, and arms, with sometimes slight systemic disturbance, is probably due to a mild toxemia of gastro-intestinal origin.

The rash of symptomatic erythemata may last from several hours to several days, and exceptionally may show slight desquamation, although this is never a striking feature except in the types more properly coming under the head of erythema scarlatinoides, which will be described separately. Drugs are also responsible for some

[1] Shaw, *Amer. Jour. Med. Sci.*, Jan., 1905.

of the erythemata of this class, and these will be referred to again under dermatitis medicamentosa.

Diagnosis.—The diagnosis of most of the erythemata of the idiopathic class is usually readily made. The erythemata of the symptomatic group are occasionally somewhat obscure, especially in those in which there may be some febrile action and constitutional disturbance. The absence of the characteristic features of the rashes of measles, scarlatina, and of the other symptoms of these diseases can be utilized in questionable cases.[1]

Treatment.—The treatment of the various erythemata described is purely of an expectant or symptomatic character. In the idiopathic rashes a removal of the cause is, as a rule, all that is required. Dusting-powders, mild lotions, such as are advised in erythema intertrigo, may be prescribed, if necessary. The calamin-zinc-oxid lotion is admirably suited for eczema solare, and may be used as a preventive measure. For this last purpose pure calamin powder lightly dusted over the parts will also have a preventive influence; this property is due to the pinkish or reddish color of the calamin acting as an obstacle to the action of the actinic rays.

In chilblain stimulating local remedies are, as a rule, required. An occasional painting, every two or three days, with tincture of iodin, pure or diluted with alcohol, at times acts well. Painting on several coatings of collodion, at intervals of a few days, will, through the pressure it exerts, also exercise a favorable effect. Applications of balsam of Peru have gained a reputation in this affection, but like other drugs, it often fails to exert an influence. Frictions with oil of turpentine, pure or diluted with oil, have also cured some cases. The same may be said of strong ointments—3 to 10 per cent. strength of carbolic acid and creasote. Ichthyol is to be commended as a lotion, diluted with two or three parts of water, or as an ointment of 25 per cent. strength. These various applications should be made once or twice daily, according to circumstances.

In obstinate and troublesome cases the application of a mild galvanic current—two or three milliampères, three or four times weekly—will sometimes prove of value: the positive pole is to be applied to the affected part, and the negative to a neighboring region, near the truncal nerve, or it may be held in the hand.

If a case of chilblain comes under observation immediately after its first appearance, mild applications, such as calamin-and-zinc oxid lotion; or a boric acid ointment, 10 per cent. strength, with one or two grains of menthol to the ounce, may be prescribed.

In those susceptible to this condition warm clothing should be worn, and, as a rule, warm water should be used in bathing the affected part, which should then be well dried with a soft linen towel. As chilblains are most frequent in the weak and in those of debilitated constitution and weakened circulation, tonics, such as strychnin, arsenic, nitroglycerin, iron, and, in suitable cases, cod-liver oil, are often of importance.

The symptomatic erythemata require but little treatment, but

[1] Winfield, "Erythematous Rashes Simulating the Acute Exanthemata," *Brooklyn Med. Jour.*, 1902, vol. xvi., p. 349.

a careful study of the individual case and the discovery of the cause will indicate the appropriate remedies to be prescribed, and, what is more important, will be of value in guarding against recurrences. In many of these cases there is an absence of any recognizable factor, and in such a good plan is to give a mild saline laxative, or, in children, a sufficient dose of gray powder, to bring about free action of the bowels. Small doses of intestinal antiseptics, such as are prescribed in erythema multiforme, should also be prescribed. Cases of any severity should be kept indoors, and if there is febrile action, the patient should remain in bed. Local treatment is rarely required; if this is necessary, the simple dusting-powders may be used, or, in exceptional instances in which there may be burning and some itching, if the dusting-powder does not relieve, a weak carbolic acid lotion, 0.5 to 1 per cent. strength, may be prescribed.

ERYTHEMA INTERTRIGO.

Synonyms.—Chafing; Intertrigo.

Definition.—Erythema intertrigo is a hyperemic disorder occurring on parts where opposing surfaces of the skin come in contact, and is characterized by redness, to which may be added an abraded surface and maceration of the epidermis.

Symptoms.—The skin of the involved region gradually becomes hyperemic, and may be attended by a feeling of heat, tenderness, or soreness. As a rule, there is no elevation or infiltration. If the condition is long continued and there are increased warmth and perspiration and resulting moisture of the parts, a variable amount of maceration of the epidermis and a mucoid discharge occur. If persistent or neglected or if too vigorously treated, actual inflammation of a superficial character may eventually result, and the mucoid discharge may become somewhat purulent. In fact, in some such instances the erythema gradually changes into a true eczema. The disease may have its seat about the nates and genitalia, in the axillary region, folds of the neck, perineum, or beneath the mammæ; in fact, it may occur in any region where opposing surfaces come together. In some instances in persistent cases superficial dermic abscesses or boils may be superadded.

The course is variable as to duration, depending upon the conditions and upon persistence or disappearance of the cause.

Etiology.—The causes are usually local. It is seen chiefly in children, especially in fat subjects, in whom friction and moisture of contiguous parts of the body, most commonly the buttocks, genitalia, and region of the neck, are the exciting factors. Uncleanliness or the reverse—the too free use of soap and water, especially soaps of irritating character—will often suffice to produce the disease. In infants the malady, when involving the genitocrural and anal regions, is frequently due to negligence in not promptly removing wet or soiled napkins. Although the exciting factors are usually external, the affection is more frequently seen in those with stomach and intestinal dis-

turbances. In erythema intertrigo of the genitalia in adults diabetes mellitus may be the predisposing and active factor (Hardy).

Diagnosis.—The disorder is rarely difficult to recognize. It is to be distinguished from eczema, and, when it occurs about the genitalia, from the erythema of hereditary syphilis. The difference between erythema intertrigo and eczema is really, so far as the objective symptoms are concerned, one of degree. The former is, however, free from any infiltration or thickening, and is rarely itchy; the mucoid discharge, when present, does not stiffen linen (Crocker); and the disease disappears promptly upon removal of the cause or after some simple mild application.

The syphilitic erythema about the buttocks and genitalia of some infants with hereditary syphilis (Fournier) sometimes resembles it very closely, but this is somewhat dark in color; there is a shade of infiltration, and the color does not disappear entirely upon pressure, usually leaving a slight yellowish tint. Moreover, there are generally other evidences of cutaneous syphilis, more or less characteristic, upon other parts, and other symptoms pointing to that disease. In doubtful cases a few days' observation would serve to establish the diagnosis—a marked change for the better would result in erythema intertrigo, and other developments would probably show themselves in syphilis.

Prognosis.—As already intimated, this is always favorable. An inquiry into the cause, followed by its correction or removal, will often suffice. Or this, together with mild applications, will usually bring about a cure rapidly. Any predisposing constitutional condition should be corrected, otherwise the case may be more or less persistent, tend to frequent recurrence, or develop into eczema.

Treatment.—The folds or parts affected are to be kept from contact by means of lint or absorbent cotton, these to be frequently changed; or by flat bags of thin cheese-cloth or similar fabric filled with a dusting-powder (Unna). Cleanliness is absolutely essential, but it is to be kept within the bounds of common sense. The most appropriate applications are dusting-powders and lotions; ointments, as a rule, are not so satisfactory, and, indeed, not infrequently aggravate. Of the dusting-powders, boric acid, zinc oxid, talcum, and chalk are probably the most frequently used, and may be prescribed separately or together. The following has been of good service:

℞.	Pulv. ac. borici,	ʒj (4);
	Pulv. zinci oxidi,	ʒij (8);
	Pulv. talci,	ʒv (20).

In persistent cases in which the epiderm has become macerated and the discharge is somewhat offensive, a few grains of salicylic acid may be added to the ounce of this formula. The powder should be applied freely two or more times daily, depending upon circumstances; the parts previously bathed gently with tepid water, and mopped dry, occasionally using a minimum quantity of a mild, neutral soap. The various lotions advised and employed for the treatment of the acute types of eczema will also be useful in this disorder.

Of particular value is one composed of the following, known commonly as the "calamin zinc-oxid" lotion:

℞. Pulv. calaminæ,		
Pulv. zinci oxidi,	āā ʒiij	(12);
Glycerin,	♏xv	(1);
Alcoholis,	f℥ss	(2);
Aquæ,	q. s. ad Oss	(256).

Lotions are best applied by thoroughly dabbing on several times daily; or linen cloths may be wet with them, and kept applied for ten or fifteen minutes, removed, and the lotion dabbed directly on the parts.

Ointments may be required in some instances, particularly in infants who frequently soil the napkins, the layer of grease protecting the surface from the irritating discharges. For this purpose zinc-oxid ointment, cold cream, and Lassar's paste are the most acceptable.

In some instances lotions applied during the day and the ointment at night will bring about a favorable result most quickly.

ERYTHEMA SCARLATINOIDES.

Synonyms.—Erythema scarlatiniforme (Hardy); Roseola scarlatiniforme (Bazin); Desquamative exfoliative erythema; Erythema scarlatinoides; Erythema scarlatinoides recidivans; *Fr.*, Erythème scarlatinoïde; Erythème scarlatiniforme desquamatif.

Definition.—Erythema scarlatinoides is a term employed to designate those cases of more or less diffused erythema followed by partial or complete desquamation.[1]

Symptoms.—There are various grades of this condition, from those in which but a part of the body is involved, to those in which the rash is almost continuous over the entire surface; with insignificant or no constitutional disturbance, to that of severe degree with high temperature (Besnier, Brocq, Atkinson, and others). Moreover, the rash is occasionally of a morbilliform character; by far the majority, however, present a scarlatinous appearance. This latter may in some instances be punctiform at first, but, as a rule, the redness soon becomes uniform. The color may vary between a bright pink or red to a sluggish or livid red. Upon the whole, its color and general appearance are similar to those of scarlet fever. The rash may be of acute onset, with more or less constitutional disturbance, or it may be somewhat subacute, with slight or no systemic symptoms. As a rule, it is ushered in with the ordinary symptoms of mild

[1] Some important literature: Brocq, *Jour. Cutan. Dis.*, 1885, p. 225, full account and bibliography to date; I. E. Atkinson, *ibid.*, 1886, p. 295; Ohmann-Dumesnil, *ibid.*, 1890, p. 293, with bibliography; Besnier, *Annales*, 1890, p. 1, and Brocq, p. 265; Payne, *Brit. Jour. Derm.*, 1894, p. 129 (unusual persistent types); Ohmann-Dumesnil (in typhoid fever), *Jour. Cutan. Dis.*, 1890, p. 293 (with some references), and *St. Louis Med. and Surg. Jour.*, July, 1893; Elliot, *New York Med. Jour.*, Jan. 11, 1890; Blanc, *International Clinics*, Oct., 1891, and *Jour. Cutan. Dis.*, 1893, p. 11; Sligh (Case of Annual Skin-Shedding), *Internat. Med. Mag.*, June, 1893 (with illustrations); Hartzell, *University Med. Mag.*, Aug., 1895.

febrile disease, with a concomitant development of the skin redness; or this latter may not appear for several hours to a day or so later.

The constitutional symptoms, when present, frequently abate upon the appearance of the erythema. In extreme cases, however, the systemic disturbance may persist for several days or longer; in fact, this depends upon the cause responsible for the eruption. In most instances the rash begins to subside in from twenty-four hours to three or four days, with desquamation, which may be branny or may take place in large thin sheets. Exceptionally, desquamation is scarcely perceptible. In extreme cases the tongue and throat may share in the eruption, and exceptionally the nails be shed, and even the hair be lost. These cases, judged by the reports of French

FIG. 28.—Erythema scarlatinoides in a frail young woman of thirty years, and of generalized distribution, the trunk showing branny exfoliation, the extremities that of a thin, flake-like or lamellar character. There was no infiltration, the earliest stage being a faint or moderately defined scarlatiniform erythema. An attack annually for several years, lasting about four or five weeks. No general symptoms except mild and evanescent prodromal febrile action and slight malaise.

writers (Vidal, Besnier, Brocq), are more common in France than with us or in other countries.

Recurrences are not uncommon in many cases (recurrent exfoliative erythema; erythema scarlatinoides recidivans), but the later attacks may be less severe (Elliot, Hartzell, and others). The course of the eruption is usually run in from one to three or four weeks. As a rule, there are no subjective symptoms.

The various cases of **shedding of the skin** (*skin-shedding*, deciduous skin) are apparently related to this malady. The erythematous element is, however, seldom so pronounced. In these cases there is often a tendency to periodicity, the most remarkable in this respect being that reported by Sligh (*loc. cit.*), in a man, aged thirty-seven, who had shed his skin annually since birth, the beginning evidences of recurrence always showing on the same date. Indeed, in these cases there

is a suggestive resemblance to "moulting" observed in some animals, and to the periodic shedding of the cuticle in serpents. A case recently came to my own notice, through Dr. Harmon, of Phillipsburg, Pa., of a boy of fifteen who had been "shedding his skin" twice yearly—July and December—for the past five years; there was but slight redness, and no subjective symptoms except a preliminary feeling of dryness of the skin; the process required about two weeks to run its course.

Etiology and Pathology.—There are doubtless many causes for this form of erythema, which also demands, perhaps, a peculiar individual idiosyncrasy. The various toxemias, general or intestinal, are probably most frequently responsible. Septic infection seems at times causative. The condition is also seen in association with albuminuria, rheumatism, gonorrhea, etc., and may likewise result from the eating of certain foods, especially "shell-fish" and spoiled meats, or from the ingestion of certain drugs. External irritation may also be the starting-point of the erythema—as, for instance, after operation and from the use of mercury and iodoform. The rash produced by this latter is, however, usually more inflammatory and belongs more properly under dermatitis exfoliativa (*q. v.*). Other causes mentioned are sewer-gas poisoning (Crocker), digestive derangements (McCall-Anderson) following injuries and operations (Atkinson), obscure changes of tissue or secretion about wounds (Hoffa), malaria (Cheadle), prolapsed and enlarged ovary (Elliot), autointoxication with ptomains (Lépine and Molière). The manner in which the eruptive phenomena are produced is unknown; this may be from disturbance of the nerve-centers, direct irritation on the peripheral blood-vessels or nerves, or of reflex origin. Brocq considers the disease a mild form of dermatitis exfoliativa.

Diagnosis.—At times there is considerable difficulty the first day or two in reaching a positive opinion. It resembles closely scarlet fever, but the intensity of the constitutional symptoms of this latter, the peculiar strawberry tongue, and the swollen fauces are wanting. Moreover, the erythema is rarely so general in its distribution as the rash of scarlatina. Occasionally, also, it presents some resemblance to measles, but the peculiar associated symptoms of measles would be absent, and, moreover, the eruption of erythema rarely begins on the face, and not infrequently spares this region. From rötheln it may be distinguished by the absence of the glandular enlargement and the lack of a history of contagion. This latter can also be utilized in differentiating from scarlet fever and measles. It must be admitted, however, that in the beginning of a tolerably well-marked case of erythema scarlatinoides the diagnosis cannot always be made with certainty, and the case should be in such instances isolated; one or two days' observation will usually clear up any doubt.

Prognosis.—This is always favorable; in ten days to three or four weeks the patient is usually entirely over the attack. It may, however, recur; and, in exceptional cases, recurrences may follow somewhat rapidly one after another, partaking more of the nature of dermatitis exfoliativa (*q. v.*). In one case (Tilbury Fox) there had been 100 attacks.

Treatment.—The systemic treatment depends upon the cause which may have provoked the erythema; when this is ascertainable, the appropriate remedies should be advised. In many cases, however, the treatment must necessarily be based upon general principles. A saline laxative, occasionally repeated, along with moderate doses of sodium salicylate, quinin, salol, charcoal, and other intestinal antiseptics, is to be prescribed. In debilitated subjects strychnin is of value, and later other of the well-known tonics. To guard against recurrences, patients should be carefully advised as to diet, avoiding all questionable foods. The possibility of certain drugs being at times responsible is to be borne in mind.

External treatment is rarely called for. If necessary, dusting-powders may be used; in fact, the same applications as advised in erythema hyperæmicum.

DR. A. HAGGART,
COMPANY SURGEON
OTTAWA CAR WORKS.

CLASS II.—INFLAMMATIONS.

ERYTHEMA MULTIFORME.

Synonyms.—Erythema exsudativum multiforme; *Fr.*, Érythème exsudatif multiforme; Érythème polymorphe; *Ger.*, Erythema exsudativum multiforme.

Definition.—Erythema multiforme may be defined as an inflammatory disease of an acute character, characterized by reddish or purplish red, often variegated, macules, papules, and tubercles, occasionally becoming vesicular or bullous, and occurring as numerous scattered or grouped lesions of various size and shape.[1]

Symptoms.—The hands and forearms, especially the dorsal surfaces, the face, and the legs, particularly on the tibial aspects, are the most common sites invaded, but it may be more or less extensive. Exceptionally it may be limited to the trunk (Pick, Lewin) and to the face (Jamieson). It is occasionally of general distribution. The eruption usually makes its appearance suddenly, and may present itself as erythematous patches of more or less irregular outline and of various forms, or it may consist almost entirely of small to large pea-sized flattened papules or tubercles; or the eruption may be of a mixed character. In most instances, however, there is a predominance of one type of lesion. In the first few days the lesions are likely to increase somewhat in size, and new efflorescences appear. In fact, there may be fresh outbreaks every day or two for five to ten days, when the process begins to decline. Or the eruption may consist of but one moderate or extensive outbreak, remain more or less stationary for several days, and then gradually fade. In color the efflorescences are usually at first of a somewhat bright pink or red, as a rule becoming later violaceous or purplish, especially in the papular and tubercular forms of the disease.

The most common type of the eruption is that which consists predominantly or entirely of papules (**erythema papulatum**). The papules are usually small to large pea-sized, flattened, sometimes with a slight sinking in of the central portion. They may be discrete or crowded together. They tend to increase somewhat in size, the central part

[1] Some important literature: Lewin (malignant and other forms), *Berlin. klin. Wochenschr.*, 1876, No. 23, and *Charité-Annalen*, 1878, vol. iii., p. 622, Berlin; Schwimmer, *Die neuropathischen Dermatonosen*, p. 101; Düring, "Beitrag zur Lehre von den polymorphen Erythemen," *Archiv*, 1896, vol. xxxv., pp. 211 and 323 (a valuable exhaustive paper, discursive and analytic, bearing upon infectious, epidemic, and other characters, with many literature references); Besnier (pathogeny), *Annales*, 1890, No. 1; Polotebnoff, "Zur Lehre von den Erythemen," *Unna's dermatolog. Studien*, 1887, Leipzig; Molènes-Mahon, "Contribution à l'étude des maladies infectieuses—De l'érythème polymorphe," *Thèse de Paris*, 1884, No. 60; Osler, "The Visceral Manifestations of the Erythema Group" (4 papers), *Amer. Jour. Med. Sci.*, Dec., 1895, and Jan., 1904; and *Brit. Jour. Derm.*, 1900, p. 227; and *Johns Hopkins Hosp. Bull.*, 1904, vol. xv., p. 259; Schamberg, "An Inquiry into the Etiology and Nature of the Toxic Erythemata," *Jour. Cutan. Dis.*, 1904, p. 461; Panichi, "Erythème exsudatif polymorphe," *Giorn. ital.*, 1903, pp. 22–179—résumé by the author in *Annales*, 1904, p. 818 (review, with report of 16 cases, with histologic examination); Kreibich, *Archiv*, 1901, vol. lviii., p. 125 (histologic).

PLATE I.

Erythema multiforme of erythematous and papular type.

often becoming depressed and flat, so that some or many of these lesions have an ill-defined or well-marked ring appearance. In color they are dark red or violaceous. The most frequent sites of this type are the dorsal surfaces of the hands and forearms; the legs and feet, and not infrequently the face also, often share in the eruption. The tubercular type (**erythema tuberculatum**) is similar to the papular, except that the lesions are somewhat larger and deeper seated; these two types are commonly seen together. Interspersed nodose lesions, such as distinguish erythema nodosum, are also occasionally associated.

In other instances the larger part of the eruption consists of erythematous patches of various sizes and shapes. Often this type is made up of distinct rings, constituting the so-called **erythema annulare**; or, instead of single rings, the patches may consist of several concentric rings, the outer rings forming after the inner ones have appeared, and necessarily, therefore, of different tints of coloring, giving rise to the term, sometimes employed, of **erythema iris.** The erythematous eruption may, too, present itself as one or several or more extensive spreading patches, with a sharply defined border, the older part fading away as the patches spread at the other side—so-called **erythema marginatum.** In some instances in which the eruption consists of rings, these rings may extend to considerable size and coalesce, the coalescing edges usually disappearing; there results an eruption of serpentine lines or bands, sometimes found described as **erythema gyratum.** To a rare and peculiar persistent type of eruption, partaking somewhat of the nature of both erythema hyperæmicum and erythema multiforme is given the name **erythema perstans**[1]; it consists usually of erythematous spots or patches, which frequently assume annular, marginate, and gyrate configuration.

In other cases, more especially in the papular and tubercular types, the inflammatory process may be sufficiently intense as to give rise to true vesiculation at the central point of the lesions and furnish the clinical variety, at times designated **erythema vesiculosum.** In fact, the exudation may be sufficiently pronounced to produce distinct blebs—so-called **erythema bullosum.** In occasional instances, instead of concentric erythematous rings, there result concentric vesicular or bullous rings, forming the **herpes iris** of some authors; in this type the several concentric rings being of slightly different duration, the coloring is brilliant in one, purplish in another, and violaceous in another, hence the use of the qualifying term iris. The vesicular and bullous rings of a patch may coalesce and give rise to large and distended blebs simulating the pemphigus eruption. In cases of the herpetic type the eruption is most commonly about the hands and wrists, and not infrequently in the palms, and on the lower part of the legs. Vesicular lesions are also occasionally found on the lips and in the mouth.

In some cases of erythema multiforme the eruption may be made up of an admixture of the various types. In extensive cases of the erythematopapular type the eruption may be more or less general and seemingly partake of the nature of both this disease and urticaria.

[1] G. W. Wende, in his paper (*Jour. Cutan. Dis.*, 1906, p. 241), reporting 2 cases, gives a review, with references, of other reported cases.

The subjective symptoms are rarely troublesome—frequently entirely wanting; in some, slight burning and itching. In the vesicular and bullous types the patches are often painful. In occasional instances, however, especially in those cases having an urticarial element, the subjective symptoms of burning and itching may be quite intense.

The constitutional disturbance in erythema multiforme is rarely of any significance. Düring noted temperature-elevation in 31 cases out of 105. My own observations would place it at even less. According to Jarisch, swelling of the lymphatic glands, especially the cervical glands, is sometimes noted. In some cases, however, especially those of a general character, there may be a good deal of febrile action, and often with accompanying swelling and pain about one or more of the joints. There may also be some anorexia, digestive disturbance, and malaise. Endocarditis has been noted (Gerhardt) in rare instances. In exceptional cases of the severe types the febrile action may be quite pronounced, and continue for several days or longer, or even throughout the disease. In fact, in some exceptional cases such symptoms may exist a few days before the eruption appears (Rigler, Lipp, Lewin, Düring, and others). The observation has been occasionally made also that in some instances the cutaneous lesions are preceded by an inflamed or congestive or eruptive condition of the fauces (Solstier, Boeck, Jamieson, Fuchs), or less frequently a mild conjunctivitis (Fuchs, Düring). Exceptionally, too, the lips and mouth show vesicles or blebs before the skin is involved (Pringle, Crocker). Grave cases of erythema multiforme have been reported (Lewin, Gerhardt, Osler, and others), with visceral involvement or complications of considerable severity, and in some of which purpuric symptoms presented. In these cases, among other symptoms were noted throat complications (Osler), diarrhea and colic (Galliard), endocarditis (Gerhardt), and laryngeal symptoms (Cotte). It is difficult to place such cases, but they probably belong either to a serious systemic infection of which this eruption is but a part, or they (some of them) belong to the domain of purpura. Certain it is that in average cases, and especially those of the papular type, in which the eruption is limited to the hands and forearms, face, and possibly the legs, there are no perceptible systemic symptoms. In fact, the disease ordinarily is benign, and runs an acute course.

Etiology.—The disease is not uncommon, constituting between 0.5 and 1 per cent. of all cases. The causes which lead to erythema multiforme are still obscure. My own experience would give weight to the belief that the development of intestinal toxins is an all-important factor in many cases. Stale articles of food, especially meats, oysters, fish, crabs, and lobsters, are, I believe, often causative. On the other hand, the more severe and rare grave types are thought to be of an infectious nature (Lewin, Molénes-Mahon, Vidal, Leloir, and others); in support of which are quoted epidemics (Rigler, Gaal, Herxheimer, Düring) and the various bacteriologic findings in the blood (Cordua, Luzzato, Manssurrow, Legrain, Simon, Haushalter, Leloir, Finger, and others). As yet, however, there has been no uniformity in the micro-organisms found.

There are certain facts generally recognized in association with this disease. It is more frequently observed in the spring and autumn

PLATE II.

Erythema multiforme of bullous variety, in a young woman, on the dorsal surfaces of the hands and forearms symmetrically; in places a central bleb, surrounded by outer ring-shaped bulla—a tendency to "herpes iris." Duration, eight days.

Erythema multiforme of erythematovesicular, circinate, and bullous varieties, in a young mulatto woman, of one week's duration. The bullæ on arm have coalesced, forming serpiginous tracts. Eruption occupies the face and the forearms and hands symmetrically.

months, during which seasons atmospheric conditions are somewhat variable, and the weather often damp and rainy. It is apt to recur for one or two years. Moreover, there are not infrequently associated rheumatic symptoms. It is common to both sexes, but is somewhat more frequent in females; all ages are liable, but it is most frequent during adolescent and early adult life. It is also noted that newly arrived immigrants and young servants coming to city-living from the country (Tilbury Fox) are especially prone to it. Another possible etiologic factor not to be lost sight of is drug action; it has followed the administration of such drugs as potassium iodid, copaiba, some of the coal-tar group, and others. Antitoxin and other serums are sometimes causative.

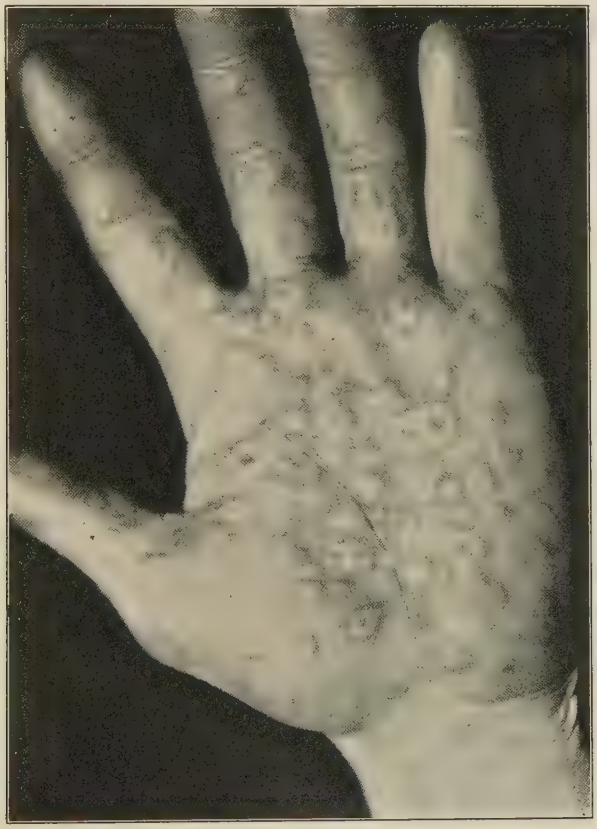

Fig. 29.—Erythema multiforme bullosum—herpes iris.

Other factors also seem to have an influence. Urethral irritation (Kaposi, Lewin) and in women uterine disturbances have been looked upon as of etiologic importance (Hebra, Pick, and others). Besnier believes there must be in all cases an underlying neurotic basis. Urine examinations give no insight into the cause.

Pathology.—Erythema multiforme is a mildly inflammatory disorder, somewhat similar to urticaria, due doubtless primarily to some impression upon the nervous system, and secondarily upon the periph-

eral circulatory system; in short, an angioneurosis (Landois, Lewin, Auspitz, Schwimmer). It would seem probable, from the presence of organisms in the blood demonstrated in several instances, already referred to, and to the fact that some cases seem due to spoilt food, that the vasomotor disturbance which gives rise to the lesions must be of toxic origin; in other words, that the disease is a toxic angioneurosis (Claisse and Legendre); the toxin possibly of diverse character. It is probable that it may act either centrally or peripherally. The association with rheumatism noted has led many to believe that it is due to the same underlying cause (Bazin, Boeck). The fact that extravasations of blood are occasionally observed in the lesions has led to an expression of belief that it is a form of purpura (Bohn, Legrand, Purdon, and others); and the grave cases reported (Osler and others) are strongly suggestive in this direction, as already referred to. The characters of the cutaneous lesions are determined by the amount of exudation, which is variable. The first step is doubtless a simple hyperemia due to vascular dilatation, followed by a paresis of the cutaneous vessels, arterioles, and capillaries, with cell proliferation and edema.

The anatomy of the process has been clearly presented by the studies of Leloir, Lewin, Villemin, Unna, Jadassohn, Crocker, Gilchrist, Pardee, and others. As is to be expected, the epidermic changes are more marked in the vesicular and bullous lesions. The papillary layer is the seat of the principal inflammatory changes, consisting of dilatation of the vessels, around the walls of which are found cell proliferation, cell emigration, and edema of the cutis, and sometimes extravasation of red corpuscles and colored blood-serum. The epidermis shares in the edematous infiltration; this edema reaches generally from the subepithelial vascular net to the epidermis, and doubles or trebles the thickness of the papillary layer (Unna). The migratory cells are to be found in more or less abundance in the upper rete layers (Cornil and Renaut). The covering of the vesicles and bullæ, as in similar lesions in other diseases, consists of the corneous layer, sometimes of the entire epidermis (Pardee). Kreibich and Panichi, from their histologic studies, believe the disease should be regarded as an inflammatory dermatitis rather than as an angioneurosis.

Diagnosis.—The diagnosis of erythema multiforme rarely gives rise to serious difficulty if the multiformity of the eruption, the size of the papules, frequent tendency to ring shape, the frequent limitation, especially of the papular type, to certain parts, the course of the disease, and the entire or relative absence of subjective symptoms are considered. It resembles urticaria to some extent, but the lesions of this latter disease are evanescent, disappearing and reappearing in the most capricious manner, and are usually whitish in the central portion. The papules of erythema multiforme persist for several days at least, and usually a week or more. Moreover, urticaria is intensely itchy, and the eruption is most pronounced, as a rule, upon covered portions of the body, especially about the buttocks and lower lumbar region and shoulders. The papules of erythema multiforme are usually somewhat dark colored, with a tendency to take on a purplish or violaceous hue, and often with a slight depression of the central portion. Those types of erythema multiforme characterized by distinct rings

PLATE III.

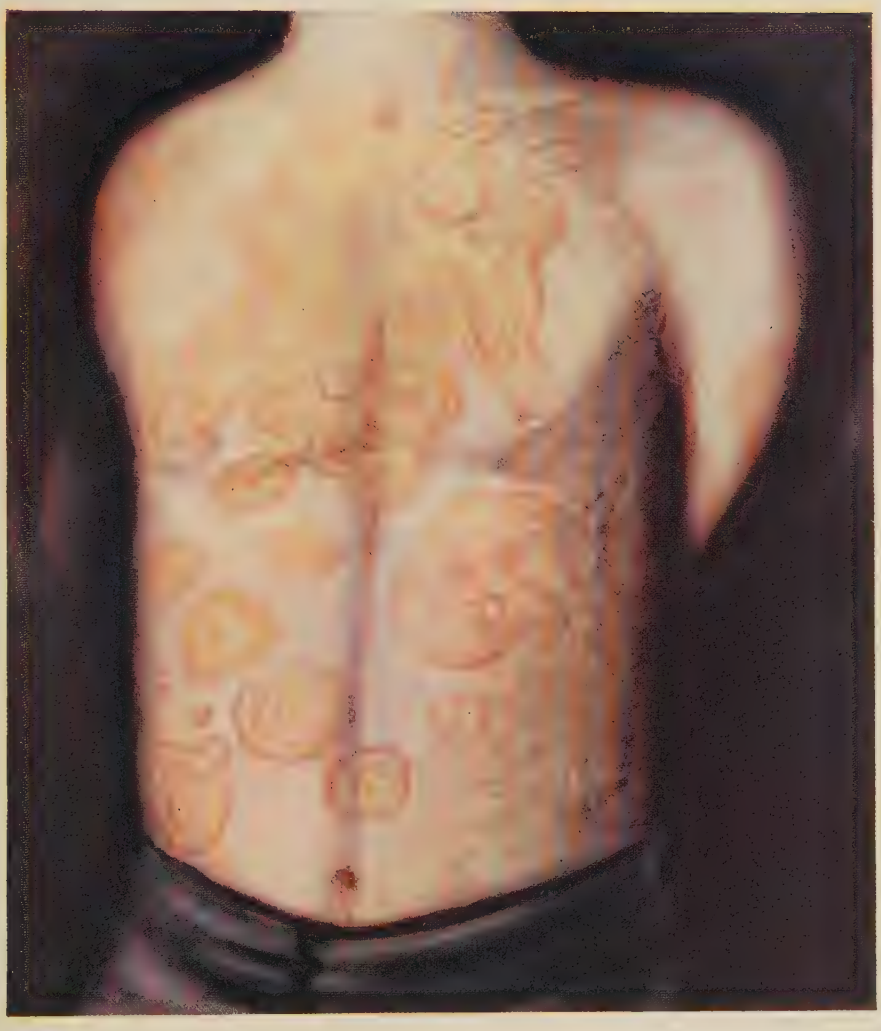

Erythema multiforme—erythema and herpes iris—of unusually extensive development, some of the patches consisting of six rings and of varied coloring. (Case reported in *Medical News*, October 14, 1882.)

can scarcely be confounded with any other disease; ordinary care would serve to distinguish it from ringworm, to which it bears rough resemblance. This latter disease has usually a scaly or papular border, and a slightly scaly center; moreover, rarely more than a few patches are present.

In those cases of vesicular and bullous types in which, from confluence of the vesicles and small bullæ, distinct blebs arise, may be confused with pemphigus, but the distribution of the eruption and the method of formation of the bullæ, and usually the presence of some characteristic erythema multiforme patches, will serve to differentiate. It can scarcely be mistaken for erythema nodosum; in this latter disease the location of the eruption and the size of the lesions and color will furnish sufficient points of difference.

Prognosis.—This is, as judged by the observations of all American dermatologists, practically always favorable, in average cases the eruption disappearing in from ten days to several weeks, and without permanent trace. The graver cases are apparently more frequent in Europe. In some instances, however, new crops may appear from time to time for a month or more, and the course of the disease be prolonged. One or more recurrences in succeeding years are not uncommon. In exceptional cases, especially of the vesicular and vesicobullous type, in which the mouth and lips are sometimes involved, frequent and closely connected recurrences may give the disease almost a chronic aspect; and it may, in fact, last for months and years (Bazin, Kaposi, Hutchinson, Polotebnoff, Colcott Fox, Payne, and others). These cases, in which there may be troublesome itching, more properly belong, however, to dermatitis herpetiformis.

In those rare and grave cases referred to in which the eruption is doubtless a part of a general systemic disease, or distinctly infectious, the prognosis would depend upon the character and gravity of the constitutional involvement. I have never met with this grave type, except in one or two instances when the eruption was simply a comanifestation of septicemia; others (Uffelmann, Vidal, Leloir, and others) have, however, recorded deaths, usually from visceral involvement or complication.

Treatment.—It is difficult to state how far treatment influences the course of the disease, but that it has no effect whatsoever, as many contend, is not in accord with my own observations. As it is probable that the development of intestinal toxins plays an important rôle in many of these cases, the treatment most commonly to be prescribed, and which in my experience is the most satisfactory, should consist of such remedies as sodium salicylate, salol, thymol, and sodium benzoate, in fairly full dosage. Conjointly with one or more of these an occasional laxative dose of calcined magnesia should be given. In fact, saline laxatives alone are often sufficient. Of these, magnesium sulphate and sodium phosphate are the most satisfactory; or the well-known laxative mineral waters may be substituted. In the more stubborn cases large repeated doses of quinin sometimes prove of benefit. Probably the remedies most frequently to be prescribed in this disease are salol or sodium salicylate, with small doses of charcoal and an occasional laxative dose of calcined magnesia, or they may be prescribed in combination as follows:

℞. Pulv. salol., gr. xx (1.35);
Pulv. magnesiæ calcinat.,
Pulv. carb. ligni, āā gr. xl (2.65).

To be divided into 20 parts and put in capsules. Of these, one is to be taken every three or four hours—about four daily.

In those cases in which rheumatic swellings and pains are present, sodium salicylate in full doses, with an occasional saline purge, will give the most prompt relief. In those constantly recurring cases in which the lips and mouth are coinvolved particular attention should be given to the condition of the digestion, and intestinal antiseptics, along with arsenic, should be administered, with other remedies which might be called for by some special condition of the patient; continued doses of quinin, arsenic, iron, and strychnin, and, in some cases, cod-liver oil, will prove of service. Among other remedies advised may be mentioned salicin (Jamieson), potassium iodid, 30 grains daily (Villemin, Elliot), more especially in the vesicular and bullous types (Elliot); for the relapsing and frequently recurring forms, quinin (Duhring, Pelon, Payne) and ergotin (Schwimmer).

As a rule, external treatment is, in the simple erythematous and papular manifestations, rarely required. In the more or less generalized cases, however, especially those in which the disease presents an urticarial aspect, with burning and itching, antipruritic applications, such as are employed in urticaria, may be advisable.

The larger vesicular and bullous lesions should be punctured, and the contents gently pressed out. In these latter cases the "calamin-zinc-oxid" lotion, named under the head of eczema, may also be employed with advantage, or one of the mild soothing ointments can be applied, spread on lint. In those patients in whom erythema multiforme tends to recur yearly a course of intestinal antiseptics and occasional purgation, previous to the usual time of the outbreak, together with the avoidance of dietary indiscretions, will, I believe, sometimes ward off the attack.

ERYTHEMA NODOSUM.

Synonyms.—Dermatitis contusiformis; *Fr.*, Érythème noueux; *Ger.*, Erythema nodosum.

Definition.—Erythema nodosum is an inflammatory affection of an acute type, characterized by the formation of variously sized, roundish, more or less elevated, erythematous nodes or swellings, attended with a variable degree of systemic disturbance.[1]

Symptoms.—Erythema nodosum is usually ushered in with

[1] Some important literature: S. Mackenzie (analysis of 108 cases and relation to rheumatism), *London Clin. Soc. Trans.*, 1886, vol. xix, p. 215; Schulthess (analytic study), *Correspondenzbl. f. Schweiz. Aerzte*, 1895, No. 3; Numa Bés (association with diseases of genito-urinary organs), *Thèse de Paris*, 1872; Amiaud, *L' Érythemenoueux; ses Complications viscérales*, 1879, Paris; Uffelmann (associated with tuberculosis), *Archiv*, 1874, p. 174; 1877, p. 230; and also Oehme, *ibid.*, 1878, p. 324; Knipe (cases simultaneously in same family), *Brit. Med. Jour.*, 1882, vol. ii., p. 974, and also Demme, *Fortschritte der Med.*, 1888, No. 7; Düring, *loc. cit.*; Harrison, *Brit. Jour. Derm.*, 1900, p. 250 (analytical remarks concerning 80 cases); E. Hoffmann (etiology and pathogenesis), *Deutsch. med. Wochenschr.*, 1904, vol. xxx., p. 1877.

febrile disturbance, gastric uneasiness, malaise, and, not infrequently, with rheumatic swellings and pains about the joints. These constitutional symptoms may be of a mild and scarcely noticeable character, or they may be severe. The cutaneous eruption makes its appearance suddenly, either concomitantly with the foregoing systemic symptoms, or some hours or a day after their onset. The lesions are seen for the most part upon the tibial surfaces, and may often be limited to these regions; not infrequently, however, other regions may be involved, more especially the arms and forearms. The lesions may also occur, though only exceptionally, on the mucous surfaces of the mouth and throat (Duhring, Pospelow, Kaposi, Rasumow). They are rarely present in great number, the eruption usually being made up of from several to twenty or thirty nodes. They begin, as a rule, as deep-seated nodules, rapidly growing larger and becoming elevated. They are from a cherry to a hen-egg or even larger in size, are rounded or oval, tender and painful, and have a glistening and tense look, and are of a bright red, erysipelatous color that merges gradually into the sound skin. They are not sharply circumscribed. Later the color grows of a darker hue and becomes purplish or violaceous, and, in disappearing, gradually undergoes the various color changes of a bruise—bluish, bluish-yellow, and greenish, muddy yellow. In occasional instances they are distinctly hemorrhagic. When first appearing they are quite firm, but gradually, after reaching their full development, in the course of several days or one or two weeks, they soften, become semi-fluctuating, and appear as if about to break down, but suppurative or destructive changes, however, never occur, absorption invariably taking place; there are several recorded exceptions (Demme, Uffelmann, Hardy, Purdon, Haisolt), but which must have been due, I believe, to some accidental factor or complication. There may be, in some cases, associated lesions of erythema multiforme. The subjective symptoms are rarely severe, although occasionally troublesome, consisting of tenderness, pain, and sometimes throbbings.

The course of the disease varies somewhat in different cases. As a rule, the nodes do not all come out at one time, but there is, at first, an appearance of three or four, and these are soon followed by others. After some days or a few weeks new lesions cease to appear, and the process gradually declines, the oldest fading away first, going through the various color changes referred to. In the course of several weeks or a few months all traces of the eruption will have entirely disappeared.

The constitutional symptoms usually abate in average cases after the first several days. In extreme instances, however, there may be continuous febrile action, similar to that observed in fevers, and exceptionally it seems to partake of the nature of a prolonged febrile disease (Hutchinson, Bäumler). Cases of this disease have also been reported from time to time in which there were signs pointing to visceral involvement and even cerebral invasion, these graver symptoms sometimes markedly ameliorating or abating upon the appearance of the eruption upon the skin. Endocarditis is occasionally noted; in Mackenzie's cases (108), in 5 cases heart murmurs developed during the attack, apparently due to this disease.

Etiology.—The disease is met with most usually in those under the age of thirty. Mackenzie's statistics of 108 cases give: 14 cases under the age of ten; 69 cases between the ages of ten and thirty; 15 between thirty and forty; and 10 in those over forty years of age. Females are much more frequently affected than males—by one analysis (Mackenzie), 5 to 1; by others (Schulthess and Harrison), 3 to 1. It is more common in cold and damp seasons (Duhring). While it may occur in those seemingly in good health, its most frequent subjects are among the weak and anemic. The frequently associated rheumatic symptoms observed would indicate some connection with this disease (Garrod, Mackenzie, Begbie, Durian, Legrand, Besnier, Boeck, and others), but whether causative or simply as a manifestation of the same underlying factor is not known. The urine discloses practically nothing, although Curschmann states that in 25 cases he met with hemorrhagic nephritis 5 times. Among other factors which have been variously thought to be of influence may be mentioned malaria (Boicesco, Moncorvo), digestive disorders, auto-intoxication, defective sanitation (Moore), drugs, etc. It is not a common disease.

Pathology.—The nature of the disease is not clear. The febrile action and the occasional visceral involvement or complications would, I believe, point rather strongly to a specific infection, and this is the present trend of opinion.[1] The simultaneous occurrence of the disease in two or more members of the same family (Knipe, Demme), or one after another (Nash, Little), would lend support to this belief, but such cases are extremely rare. Doubtless in the grave cases reported the disease may be due to septic infection. The reported cases (Amiaud, Uffelmann, Oehme, Lailler, Goldschneider, Talamon, Buisine) of associated or subsequent tuberculosis, usually grave in character, would indicate simply the presence of a predisposing factor, and must be considered rare or purely accidental. Its occurrence in the course of syphilis (Despres, Leloir, Mauriac, Testut, Jackson) is too rare to be viewed more than as a coincidence.

Its relation to erythema multiforme is certainly a close one, and many (E. Wilson, Lewin, Auspitz, Polotebnoff, Kaposi, Besnier, Brocq, Boeck, Crocker, Hyde, and others) believe it to be a manifestation of this disease, and cases are occasionally reported, among which recently those by Gibb,[2] Glück,[3] and Schein,[4] in which lesions of both erythema multiforme and erythema nodosum are alleged to have been present. In a few cases under my own observation the eruption seemed of mixed character. Nevertheless, the distinct individuality of erythema nodosum is strenuously maintained by many leading clinicians and pathologists (Hebra, Neumann, Düring, Vidal, Leloir, Duhring, Schulthess, Veiel, Unna, Jadassohn, Jarisch, and others). Düring, in 105 cases of erythema multiforme, never saw an erythema nodosum lesion.

There is some difference of opinion as to how the lesions are produced—whether the disease is an angioneurosis (Lewin), the

[1] Lendon, in his recent work, "Nodal Fever; Synonym—Erythema Nodosum, Erythema Multiforme," London, 1905, holds this view strongly, but one must confess that as yet the evidence is not conclusive.

[2] Gibb, *Lancet*, April 23, 1898.

[3] Glück, abs. in *Monatshefte*, vol. xxvii., 1898, p. 467.

[4] Schein, *ibid.*, vol. xxviii., 1899, p. 411.

cutaneous phenomena resulting, as in erythema multiforme, or an inflammation of the lymphatics (Hebra), or due to embolism (Bohn, Panum).

From anatomic investigations made (Lewin, Kaposi, Campana, Phillipson, Jadassohn), the inflammatory character of the process is disclosed. Dilatation of the blood-vessels and closely crowded cells are to be noted in the corium and papillary layer, and in some instances extravasations of blood or transudation of blood coloring-matter. Granular cell infiltration of connective-tissue bundles and cell collections packing the lymphatic vessels are also at times observed. In the blood-vessels, particularly the veins, the leukocytes are sometimes so massed that they have the aspect of white thrombi (Unna). Hoffmann found phlebitis of the larger subcutaneous veins. In addition there is marked serous infiltration in the cutaneous, and usually subcutaneous, tissues. The epidermis rarely shares in the morbid process.

Diagnosis.—Erythema nodosum should not be confounded with bruises, abscesses, gummata, and the lesions of erythema induratum, to which it may, at times during its course, bear resemblance. If the beginning bright red, rosy tint, with the later color changes, the apparently violent character of the process, the number, the situation, and course of the lesions, are borne in mind, an error in diagnosis is not likely to occur. Bruises, abscesses, and gummata are rarely present to a greater number than one or two or three. The course of the latter two diseases is entirely different—the nodes of erythema nodosum never break down, and the disease is frequently accompanied by rheumatic pains and swellings about the joints. The lesions of erythema induratum are slower in their course, are usually dark in color in the very beginning, soon show evidences of breaking down and of ulceration, and are unaccompanied by any febrile and rheumatic symptoms. Moreover, this latter disease is usually seen in subjects with tuberculous tendencies.

Prognosis.—This is favorable, the disease usually running its course in several weeks to one or two months. A few grave and fatal cases have been reported (Demme, Schmitz, Lewin, and others), but there always arises a question that these are examples of a general systemic septic infection, of which the erythema nodosum is simply a symptom and a part or an accidental complication. At all events, as met with in this country, the disease, while in exceptional instances severe and even temporarily alarming, as a rule gives rise to no anxiety, and always ends in recovery. The condition of the heart should, however, be investigated, especially in cases associated with rheumatic symptoms.

Treatment.—For the most part the treatment of this disease is symptomatic and expectant. Rest, relative or absolute, depending upon the severity of the case, should be enjoined. The diet should be plain and unstimulating. A saline laxative and intestinal antiseptics and alkalies are most commonly prescribed. Full doses of quinin are useful in some cases. Duhring especially indorses the value of sodium salicylate and quinin. As a rule, an occasional saline laxative, with sodium salicylate or sodium benzoate, and moderate doses of quinin, constitute the essence of the treatment.

In some instances the tender and painful character of the cutaneous lesions will demand external treatment. Lead-water and laudanum, and 3 to 10 per cent. ichthyol ointments, may be used for this purpose.

The rheumatic swellings and pains often about the joint will also require at times similar soothing applications; the parts may also be enveloped with cotton batting.

ERYTHEMA INDURATUM.[1]

Synonyms.—Erythema induratum scrofulosorum; Érythème induré des scrofuleux (Bazin); Erythème noueux chronique des membres inférieurs (Besnier).

Definition.—A sluggish chronic disease, usually of the leg, characterized by the more or less continuous formation of subcutaneous nodules, which enlarge to variable size, become purplish or purplish red in color, and terminate after long duration in absorption or necrosis.

Symptoms.—The disease, first clearly described by Bazin, and later by Besnier, Feulard, Colcott Fox, J. C. White, and others, is usually slow and insidious in its appearance, presenting a symptomatology resembling both erythema nodosum and syphilitic gummata. Several or more nodules are usually found about the legs, and, most frequently, on the lower calf region, and, as a rule, at the sides and slightly posteriorly. They have been, however, observed on the entire leg region, and also on the lower part of the thigh. The lesions are first not perceptible to the eye, but are felt on palpation as deep-seated, hard, indurated, pea-sized nodules. Gradually in the course of days or weeks enlargement ensues, and they reach the size of a small or large cherry or even as large as a walnut; the skin during this enlargement becomes at first a pale purplish red, later darker in tinge, and finally a dull violaceous. The formations are still noted to be somewhat hard or slightly doughy, but when of large size, lose their well-defined character and seem to fuse with sur-

[1] Literature: Bazin, *Leçons sur la scrofule*, second edit., 1861, p. 146; Besnier, *Annales*, 1889, p. 25 (case demonstration); Feulard, *ibid.*, p. 206; Colcott Fox, *Westminster Hosp. Reps.*, 1888, p. 144; and *Brit. Jour. Derm.*, 1893, pp. 225 and 293 (with colored plate and report of 9 cases—a clear clinical presentation and review and references to literature of the disease); also *ibid.*, 1896, p. 178 (case with associated angiokeratoma); Patteson, *ibid.*, p. 338; Hutchinson (a number of suggestive cases), *Archives of Surgery*, 1893–94, vol. v., pp. 31 and 98; Crocker, *Diseases of Skin*, second edit., 1893, p. 107 (refers to cases with arm lesions); J. C. White, *Jour. Cutan. Dis.*, 1894, p. 471 (four cases, one a boy aged twelve); Thibiérge, *Semaine Méd.*, 1895, p. 545; Pringle, *Brit. Jour. Derm.*, 1896, p. 96 (male subject); Méneau, *Jour. de Méd. de Bordeaux*, 1896, vol. xxvi., p. 105 (case demonstration); Truchi, *Thèse*, Toulouse, 1898, brief abs. in *Annales*, 1898, p. 1034 (histolog. exam.); Mackenzie (case demonstration), *Brit. Jour. Derm.*, 1897, p. 79; Audry, *Annales*, 1898, p. 209 (histolog. exam.; and animal inoc.—negative); Leredde, *ibid.*, p. 893 (histolog. exam.); Dade, *Jour. Cutan. Dis.*, 1899, p 306 (full clin. report of a case, with histolog. exam. by Ewing); Johnston, *ibid.*, p. 312 (with associated necrotic granulomata; histolog. exam.; review of subject and allied cases, with bibliography); also *Philada. Monthly Med. Jour.*, Feb., 1899; Bronson, *Jour. Cutan. Dis.*, 1899, p. 240 (case demonstration); Abraham, *Brit. Jour. Derm.*, 1899, p. 206 (demonstration—doubtful case—with discussion). Thibiérge and Ravaut, "Étude sur les lésions et la nature de l'érythème induré," *Annales*, 1899, p. 513 (report of 3 cases, with 4 colored histologic cuts; review of the subject and references). See also a suggestive paper by Macleod and Ormsby, "Report on the Histopathology of Two Cases of Cutaneous Tuberculides, in one of which Tubercle Bacilli were found," *Brit. Jour. Derm.*, 1901, p. 367 (with 2 histologic cuts, review, and references).

rounding infiltrated tissue. They may continue at this stage for some time, and then gradually soften and disappear by absorption, with slight desquamation and sometimes atrophy, or undergo necrosis and result in a punched-out, somewhat deep, sluggish-looking, irregular ulcer. Exceptionally, as in the cases of Burns[1] and W. Pick,[2] there is very little or no disposition to ulceration, and the condition is suggestive of a chronic erythema nodosum, under which title Pick places his case. Both terminations are usual in an average case, a few lesions disappearing, the larger number breaking down. Some lesions remain small and scarcely recognizable, except by palpation. There is never distinct abscess formation, but slight softening takes place, the skin becomes necrotic at one point, and there may be a slight, seropurulent discharge, followed by gradual necrosis of the whole nodule; or this latter takes place *en masse*, without previous spot necrosis. Occasionally the nodule necroses first at several points, and then rapidly or gradually in its whole mass, the surface breaking down at first, and the deeper parts, quickly or slowly afterward. In some cases several nodes may be in close proximity, and as they grow practically fuse together, although to the sight and to touch there usually remains an ill-defined outline of the several lesions composing the mass. In these cases there may be a noticeable surrounding sluggishly inflammatory infiltration.

The ulcers, the maturing nodes, and the atrophic depressed areas left from absorbed lesions are surrounded by deep, dark red, or purplish areola. This dark color remains for some time subsequently to healing. Some of the ulcers may gradually heal, others remain open and sluggish, with a slight seropurulent or watery discharge; if several are in close proximity, there may result an irregular, ulcerated area, with here and there a "bridge" of purplish colored infiltrated skin and tissue; in such cases the consequent scarring is usually pronounced. A variable degree of edema of a doughy or inelastic character is sometimes noted, which is occasionally followed by slight tissue hypertrophy.

The disease is almost invariably limited to the parts named, although Bazin, Crocker, Pringle, and Colcott Fox have exceptionally observed lesions elsewhere as well, more especially, however, on the arms. Johnston and DuCastel have each observed a case with characteristic nodes upon the legs and suggestive necrotic tuberculous looking lesions on other parts. It is slow and persistent, and more pronounced in its expression in the cold season. As a rule, the lesions are not painful except upon pressure—certainly not painful to a marked degree.

Etiology and Pathology.—The disease is met with almost exclusively in girls and women between the ages of twelve and thirty, and especially among those whose occupation keeps them on their feet.[3] It is a rare malady, and particularly among the well-to-do classes.

[1] Boston Derm. Soc. Trans., *Jour. Cutan. Dis.*, 1905, p. 177.

[2] *Archiv.*, 1904, vol. lxxii., p. 360 (1 plate).

[3] Hirsch, *Arch. Derm.*, 1905, vol. lxxv., pp. 56 and 181, shows in a review-summary of 80 collected cases, that only 11 were males; as to age, there were 18 under twenty, 18 between twenty and thirty, 11 between thirty and forty, 5 between forty and fifty, 1 between fifty and sixty, and 1 at sixty-eight; in 30 of the cases there were other evidences of tuberculosis.

The nature of the disease is obscure. It is not a thrombosis nor a phlebitis, as the characteristic symptoms of these conditions are lacking; nor is it connected with syphilis in any way, although the clinical picture is extremely suggestive. There are often associated symptoms, past or present, of a scrofulous diathesis; this has been noticeably so in the cases under my observation. In fact, its tuberculous origin is more in accord with the clinical data.[1]

Histologic and bacteriologic investigations led Audry and Truchi to conclude that it is not tuberculous, but a manifestation of a nature similar to erythema nodosum. Johnston, although believing that it is an expression of tuberculous disease, could not corroborate it by histologic findings. On the other hand, Thibiérge and Ravaut's studies place it among the cutaneous manifestations of tuberculous infection. They found in all three cases examined by them that the vascular channels were chiefly affected with inflammatory and degenerative changes, and there was a large number of giant-cells; moreover, they succeeded, by experimental animal inoculation, in producing a general tuberculosis. Leredde, who also examined a case histologically, compares the lesion to a necrotic tuberculide. The bacillus has, however, never been found, although as yet the examinations have been meager. It may be possible that there are two types, one of which being tuberculous (Whitfield).[2]

Diagnosis.—Erythema nodosum and syphilitic gummata are to be excluded. The acute character of the former, its surface involvement in the very earliest stage, some lesions remaining small and surface lesions throughout; the bright pink or red color, with the gradual change of color often observed; the painful and tender character of the node, and its usually occupying preferably the tibial surface; the absence of tendency to break down; and its course—are all different from the symptoms of erythema induratum. The nodes in erythema nodosum, it is true, are often suggestive of softening, but this never ensues, a few cases of ulcerative ending are on record, but one may ask, in view of its resemblance to erythema induratum, whether it was not confused with this latter disease.

The clinical expression of the ulcers is strikingly like syphilis, but gummata are usually rapid, remain rather sharply circumscribed, are generally more painful and inflammatory, and suppurate and are markedly purulent; in erythema induratum the destruction of tissue results from necrosis rather than from suppuration. Moreover,

[1] Harttung and Alexander's case, *Archiv.*, vol. lx., April, 1902, p. 39 (clinical and histologic, with 2-colored histologic plates, and full bibliography), died of pleuropneumonia—the autopsy showed pulmonary tuberculosis; second paper, *ibid.*, 1905, vol. lxxi., p. 385 (5 cases, 1 doubtful): there were histologically two groups—those showing tuberculous changes and those showing inflammatory changes; Thomas, *Rev. gen. de clin. et thér.*, Jan. 24, 1903, p. 49, case with scrofulous symptoms and pluropneumonia; Söllner, *Monatshefte*, 1903, vol. xxxvii., p. 545, has reported a case in which there was an association with both lichen scrofulosorum and pulmonary tuberculosis.

[2] Whitfield's, *Brit. Jour. Derm.*, 1901, p. 386, and 1905, p. 241, investigations led him to conclude that there are two types—one being of a tuberculous nature, occurring almost entirely in young girls; the others occurring in middle-aged women of poor circulation, having nothing to do with the tuberculous process, and which might be called by Philippson's name of "phlebitis nodularis necrotisans"; Alexander, *Berlin. klin. Woch.*, 1904, vol. lxi., p. 897, an association with folliclis.

syphilitic gummata are rarely numerous, and rarely on both legs. Further, syphilitic lesions yield rapidly, as a rule, to antisyphilitic remedies—erythema induratum, on the contrary, not only is uninfluenced, but often aggravated, by such treatment.

Prognosis and Treatment.—The disease is persistent and obstinate, but with the patient's cooperation the results are satisfactory. The constitutional treatment of most value is that based upon the assumption that the disease is scrofulous. Cod-liver oil, iron, quinin, strychnin, and phosphorus, with full nutritious diet, are the remedies indicated, cod-liver oil being the most useful. Rest, with the leg in a recumbent or supported posture, is of great importance. Antiseptic applications of boric acid, hydrogen dioxid, and resorcin are especially valuable. An ointment of resorcin, 5 to 10 per cent. strength, made up with Lassar's paste (see eczema), is a useful application. The plan I have found most satisfactory when patients cannot give the time to absolute or even relative rest is to wash daily the ulcers, and also the general leg surface, with a saturated solution of boric acid containing 3 to 10 grains (0.2 to 0.65 gm.) of resorcin to the ounce (32 gm.), dressing the ulcers with a powder of boric acid or with the foregoing paste, and putting on a roller-bandage. As soon as a clean condition of the ulcers is established and they are looking less active, which usually ensue in from ten days to a few weeks, this treatment, provided the ulcers are not numerous, is somewhat changed; the preliminary washing of the entire leg is the same, but the ulcers are sprayed with hydrogen dioxid, and then a gelatin dressing of zinc oxid and ichthyol (see eczema for formula) is put on, leaving a "window" over each ulcer. The ulcers are then dressed with the powder or ointment as above and changed daily. The gelatin dressing is renewed every three or four days. If the ulcers are numerous, this gelatin bandage treatment is not feasible until the smaller have been healed and but several remain. Whitfield had a good result from treatment with injections of tuberculin R, dosage and frequency according to Wright's method of testing the opsonic index of the blood.

ERYTHEMA ELEVATUM DIUTINUM.

Under this title Crocker and Williams[1] have called attention to a rare malady, of unknown nature, characterized by persistent, raised, pinkish to purplish, flattened nodules or patches, with sharply defined edges, and usually free from any subjective symptoms. These writers also refer to somewhat analogous or allied cases by Bury,[2] Hutchinson,[3] and Boeck, and present abstracts of the same. The features of

[1] Crocker and Williams, *Brit. Jour. Derm.*, 1894, pp. 1 and 33 (with colored plate and references to similar or allied cases).

[2] Bury, *Illust. Med. News*, May 18, 1889, p. 145 (with colored plate).

[3] Hutchinson, *Illust. Clin. Surg.*, vol. i., 1878, p. 39 (with colored plate); *Brit. Jour. Derm.*, vol. i., 1888–89, p. 10; *Arch. Surg.*, vol. i., 1889–90, p. 372; *ibid.*, vol. ii., 1890–91, plate lxi. (this last is Bury's case). Gilchrist, *Trans. Amer. Derm. Assoc. for 1900*, p. 221, also recorded a case presenting some resemblance to the disease under consideration, occurring on the extremities, in a child, but exhibiting a ringed nodular appearance. F. J. Smith also reports a case, *Brit. Jour. Derm.*, 1894, p. 144. According to Crocker, *Brit. Jour. Derm.*, 1894, p. 148, model 1599 (Quinquaud's case, child's hand), in the Museum of the Hôpital St. Louis, Paris, labeled "fibrômes multiples nodulaires des extrémités, histologiquement fibrômes fasculés," is a case of this disease.

the several cases, while in many respects similar, differed in some minor particulars. In the Bury and Crocker and Williams cases the lesions were situated over the articulations and on the palmar surfaces; began as nodules, becoming confluent, resulting in a flattened patch, disclosing, however, its nodular origin; the lesions were at first erythematous and later purplish; all were persistent, some indefinitely so, others finally undergoing involution; no tendency to spread over large areas; the subjects (3 cases) were young females. In the Hutchinson type there was no special localization shown, but usually over flat bony surfaces; the lesions began as flattish nodules, if close together coalesced, and lost their nodular character, forming elevated, flattened patches; they were purplish from the beginning, and were persistent, with no involution tendency, and disposed to spread widely; the subjects (4 cases) were males and somewhat advanced in years. The lesions were somewhat less firm than the Bury type; the elevation could be almost removed by long-continued pressure, being apparently chiefly due to edematous infiltration.

The common features were the purplish hue, marked elevation with abrupt edges, the rather solid or firm character of the efflorescences, their persistence for months, years, or indefinitely, and their occurrence in subjects of gouty or rheumatic nature or history. In some cases, in one or more patches, there was dilatation of a few surface capillaries. The eruption was scanty in a few cases, consisting of one to several areas, and in others, while scarcely abundant, patches were to be seen over a number of places, sometimes widely scattered.

I have met with 3 cases with some of the features here described —2 women and 1 man, all past the age of forty, one past fifty. The eruption in 2 of these cases consisted of but a single patch on the nose, and in the other a patch on each cheek. They appeared in the course of several days in 1 (last-mentioned) instance, in the other 2 in the course of several weeks. The area was about 1 to 2 inches in diameter, rounded or ovalish. When first seen by me, they were flattened, elevated areas, showing no nodulation; according to the patients, they began as flat nodules and spread peripherally. The patches were dark pink at first, but later with a distinct purplish tint, and in 2 cases (on the nose) with a few enlarged capillaries coursing over. The areas were firm, markedly elevated,—scarcely less than a quarter of an inch,—with sharply defined precipitous edge, the immediately surrounding skin being normal. The surface was flattened, except in one nose case, in which there was a tendency to a little greater elevation centrally. There was no pain—no subjective symptoms. The nose cases suggested to some extent the possibility of sarcoma. Professor Duhring saw one of these with me in consultation, and was inclined to view it as possibly of the nature suggested or an anomalous condition due to deep invasion of the trichophyton fungus. There was no scaliness, however; in fact, no surface change from the normal skin except the color, and in the nose cases the capillary dilatation. The 3 cases recovered—1 (cheek case) in three or four weeks, and the other 2 in two to four months, leaving for some time a dusky pink or violaceous stain. They are lacking, therefore, in the longer and indefinite persistence and the scant

amount of eruption of the other cases referred to, and may possibly not be identical with them, but their objective features have much in common.

In some of the reported cases pressure appeared to be a determining factor for the site of some of the lesions. For the most part, however, the cause, beyond a possible gouty or rheumatic relationship, was unknown. In the 3 suggestive cases seen by me there was nothing to explain the origin of the patch. Microscopic study of Crocker and Williams's case showed the seat of the morbid changes to be between the epidermis and deep portion of the corium, immediately adjacent to the coil-glands, and to be fibrocellular in character, the process being of a chronic inflammatory nature.

Crocker and Williams's case, a child aged six, showed improvement, presaging recovery, under Fowler's solution internally and diluted liquor carbonis detergens (1 : 8) externally. The other reported cases were apparently uninfluenced by the treatment variously employed. In my 3 cases the cheek case recovered spontaneously or possibly from a mild astringent protective lotion employed; the nose case (male) was treated, at Professor Duhring's suggestion, by dilute application of Vleminckx's solution; and the other patient (female—nose case) recovered under continuous application of mercurial plaster.

PELLAGRA.

Synonyms.—Lombardian leprosy; Erythema endemicum; *Fr.*, Pellagre; Mal de misère; L'érythème pellagreux; *Ital.*, Mal Rosso; Risipola Lombarda; Mal del Sole; Scorbuto alpino.

Definition.—Pellagra is an endemic systemic disease, characterized by cutaneous manifestations of an erythematosquamous and pigmentary character, and associated with disturbances of the cerebrospinal system and digestive tract. It is of endemic occurrence in certain regions of Italy (Lombardy, Venetia, Aemilia) and Spain; also in the Tyrol, Bukovina, and Roumania. Its first occurrence in Spain is referred to the year 1735.

Symptoms.—This disease usually appears in spring, and is frequently preceded by lassitude, great fatigue, vertigo, headache, pain in the epigastrium, and diarrhea. The cutaneous phenomena are, as a rule, the last to appear, and these can be divided roughly into three stages—the first, congestion or erythema; the second, with added scaliness, thickening, and pigmentation; and the third, a tendency to atrophic thinning. When first presenting, therefore, the eruption is erythematous in character and primarily dark red in color, which later becomes dark brown. It appears on uncovered portions, those which are commonly exposed to the sun, as the back of the hand and lower part of the foreams, face, and, in persons who go bare-footed, on the dorsal surface of the feet. This last statement, however, is called in question by the observations of Raymond[1] and others, who have also noted it on the feet in those who are foot-clad. The skin, which assumes a reddish color, soon develops a variable degree of thickening, and to these changes are added burning and

[1] Raymond, "Les altérations cutanées de la pellagre," *Annales*, 1889, p. 627.

itchy sensations, and, later on, there may be loss of sensibility. The inflammation may have its seat in the superficial or deeper layers. The epidermis desquamates, the amount of scaliness varying somewhat in different cases and in different attacks; the underlying surface appears red, and not infrequently is fissured. Vesicles, bullæ, and petechiæ are also not uncommon associated manifestations. Pigmentation takes place during and after the erythematous attacks, the parts remaining more or less thickened. These latter features become more pronounced with succeeding attacks. At the advent of winter the cutaneous phenomena show signs of improvement, and the disease gradually abates and exceptionally may disappear. Usually, however, as late spring approaches, it recurs, and the disease may thus repeat itself for several or more years, and in addition to the cutaneous changes brings in its course muscular weakness and mental despondency. These intervals are, as a rule, mere remissions in the malady, and not a disappearance with subsequent recurrence. After repeated attacks the skin becomes wrinkled, thinned, lax, and takes on a senile appearance, and presents a bluish-red or dark-brown color, and tends to exfoliate in large flakes. The fingers become more or less fixed in a semi-flexed position. Gradually the patient becomes debilitated and greatly emaciated, owing to digestive weakness and to frequent coexistent diarrhea, and also, doubtless, as a result of the changes brought about by the involvement of the cerebrospinal system. Later, as the pulse becomes weak and the muscular weakness increases, pains in the head and spinal cord and convulsions present, stupor and melancholia develop, and quite frequently insanity results; sooner or later a fatal termination ensues.

Etiology and Pathology.—The disease occurs among the poorer classes, and develops most frequently in those of mature adult age. It is not contagious, nor is it now believed to be hereditary. It is met with in almost all the European countries, being, however, peculiarly frequent in Italy and Roumania. In our country it is scarcely known, Sherwell[1] having met with an instance in a Genoese sailor in New York. It has been attributed to the eating of damaged maize, but Kaposi, Scheiber,[2] and others have observed the malady in those who had never used this food. Hardy[3] also states that he has had cases in the Hôpital Saint-Louis in which maize had played no rôle. Alcoholic excess, poverty, poor hygienic surroundings, and exposure to the sun are predisposing factors, the last considered by many as being almost essential, but some exceptions to this are now known. There is no question, however, about the active influence of the sun's rays, and this effect is, as pointed out by Bouchard[4] and others, more especially due to the chemical rays. According to Neusser,[5] the poisonous principle is developed in diseased or fer-

[1] Sherwell, *Jour. Cutan. Dis.*, 1883, p. 142.

[2] Scheiber, "Ueber Pellagra in Rumänien," *Archiv*, 1875, p, 417.

[3] Hardy, "De la pellagre," *Gaz. des Hôp.*, 1882, p. 793; and translation in *Jour. Cutan. Dis.*, 1883, p. 123.

[4] Bouchard, "Expériences relatives à la production de l'érythème solaire et plus particulièrment de l'érythème pellagreux," *Comp. Rend. de la Soc. de Biologie*, 1877, p. 253.

[5] Neusser, *Die Pellagra in Oesterreich und Rumänien*, Vienna, 1887.

mented maize under the influence of the bacteridium maïdis. Lombroso's[1] investigations seem to corroborate the causative action of the fermented maize toxins, and he has experimentally produced symptoms apparently similar. Guertin's[2] study of the malady led him to conclude that it is rather a condition than a specific disease, and due to impaired nutrition, which brings about a state of cachexia and misery; and it may, therefore, be symptomatic of very different affections, and met with in chronic illnesses, in alcoholism, and in lunacy, which act by producing a general deterioration. The domain of the sympathetic and its central nerves and arterial channels are believed to be effected by the toxic principle which is presumably formed in the intestines. The postmortem findings are pachymeningitis, sclerosis of the brain and cord, and anemic and atrophic conditions of internal organs, fatty degeneration, and pigmentary changes. The cutaneous changes, according to Raymond, are essentially those of a mild congestion and irritation, and more especially a hyperkeratinization with atrophy of the rete.[3]

Diagnosis.—Outside of the usual districts for the disease some difficulty might well arise in the diagnosis in the earlier period. The most prominent characteristic signs are the parts affected (backs of hands, lower forearms, face, and often dorsal surface of feet), the character of the eruptive phenomena—dermatitis, usually of a mild grade, with sometimes vesiculation and bullous lesions, and together with, especially later, thickening and pigmentation. These symptoms and the associated general disturbance of digestion, frequent diarrhea, nervous involvement, melancholy, or other evidences of mental despondency will usually prevent error. If to these is added the knowledge that the patient has lived largely on maize, the diagnosis becomes more certain. It should not be confused with another rare condition—pseudopellagra[4]—observed in alcoholics with peripheral neuritis.

Prognosis and Treatment.—In slight attacks the outlook is favorable, provided the proper food can be given and the surroundings improved. Severe cases are prone to prove fatal; the average duration is five years, although it may continue for ten or fifteen.

There are no specific remedies, the essential management consisting in placing the patient in good hygienic surroundings, and improving the general health by good nourishing food and such tonics as may seem indicated. Arsenic and iron preparations, especially the former, are the remedies upon which most support has been placed, and which sometimes influence the disease favorably.[5]

[1] Lombroso, *Die Lehre von der Pellagra*, Berlin, 1898 (an exhaustive monograph with histologic cuts).

[2] Guertin, *Thèse de Paris*, abs. in *Brit. Jour. Derm.*, 1889, p. 169.

[3] Dejerne, *Gaz. hebdom.*, 1881, p. 462, and *Annales*, 1881, p. 719, has also made histologic examinations (2 of Hardy's cases).

[4] Roussel, *Traité de la pellagre es des pseudo-pellagres*, Paris, 1866.

[5] Among other valuable papers on the disease may be especially mentioned: Hirsch, "Geograph. and Histor. Path.," *Syd. Soc'y Translat.*, vol. ii., 1885, p. 217; Berger, *Wiener Klinik*, Pellagra, 1890, p. 161—abridged translation by Barendt in New Syd. Soc'y's *Selected Monographs on Dermatology*, London, 1893, p. 343; and Jules Arnould, "Pellagre," in *Dict. encyc. des Sci. Méd.*, 2me sér., vol. xxii., p. 310, Paris, 1886; Sandwith, "Pellagra in Egypt," *Brit. Jour. Derm.*, 1898, p. 395; Tuke, *Klinische und Anatomische Studien über die Pellagra*, Berlin, 1893.

Acrodynia.—*Synonyms.*—Erythema epidemicum; Cheiropodalgia; *Fr.*, Acrodynie; Mal des pieds et des mains; Maladie de Paris; *Ger.*, Acrodynie.

This title was given by Chardon to a disease first observed in Paris and in other parts of France from 1828 to 1830, occurring as an acute epidemic and having some resemblance to both ergotism and pellagra. Occasional cases are observed from time to time among soldiers and prisoners, and exceptionally in others.[1] Most cases have occurred in Eastern countries. The malady is ushered in with constitutional symptoms consisting of anorexia, nausea, vomiting, and diarrhea; and the face, hands, and feet are noted to be swollen, and the conjunctivæ injected. It is accompanied by disorders of the nervous system, characterized by pricking and burning sensations; at first there is marked hyperesthesia of the extremities, which in turn is followed by anesthesia; severe pains in the extremities are one of the characteristic features of the disease. Early in the course of the malady the eruptive phenomena make their appearance, and present as erythematous spots primarily on the hands and feet, especially on the palms and soles, and spreading upward on the arms and legs, and sometimes involving the trunk. The affected portions of the skin desquamate and are thickened and brownish; black pigmentation may supervene. The disease is afebrile and usually runs its course in a fortnight to four weeks. In aggravated cases paresis, edema of the limbs, and toxic spasms may ensue.

The nature of the disease is obscure. Some observers attribute it to a toxic agent affecting the nerve-centers, developed in damaged grain; others recognize its analogy to pellagra and ergotism, and Marquez[2] remarks upon the similarity of the general and local symptoms to those resulting from chronic arsenical poisoning. In several of the fatal cases inflammation of the spinal arachnoid has been noted.

The malady usually, however, except in those greatly debilitated or in advanced years, runs a favorable course, recovery ensuing within one or two months. Treatment is upon general principles. Counterirritation over the spine has been employed, and is generally advised.

URTICARIA.

Synonyms.—Hives; Nettlerash; *Fr.*, Urticaire; *Ger.*, Nesselsucht; Nesselausschlag.

Definition.—Urticaria is an inflammatory affection characterized by evanescent whitish, pinkish, or reddish elevations or wheals, somewhat variable as to size and shape, and attended by itching, stinging, and pricking sensations.

Symptoms.—The eruption in urticaria usually comes out suddenly, occasionally being preceded by burning or itching of variable intensity. It is erythematous in character and consists of scanty or profuse pea- to bean-sized elevations, linear streaks, or small or large irregular patches, or an admixture of these forms. It may be lim-

[1] Tholozan, "De l'acrodynie," *Gaz. méd.*, [illegible], pp. 647, 661, 689, 724, and 821, has reported 20 cases and described the [illegible] fully.

[2] Marquez, *Gaz. hebdom.*, 1889, p. 91.

ited in extent and distribution, or more or less general and abundant. While no part of the body is exempt from possible manifestations, covered parts, especially the lower trunk, buttocks, and upper outer chest, around about the axillary regions, are favorite localities. The outbreak may be preceded and accompanied by symptoms of gastric derangement, and exceptionally and in extensive and markedly acute cases by some febrile action. In many cases, however, the cutaneous eruption is unaccompanied by any other recognizable symptoms. The lesions are fugacious in character, disappearing and reappearing in the most capricious manner. They are somewhat firm, with an average size in the typical wheal of a flattened large pea. They may

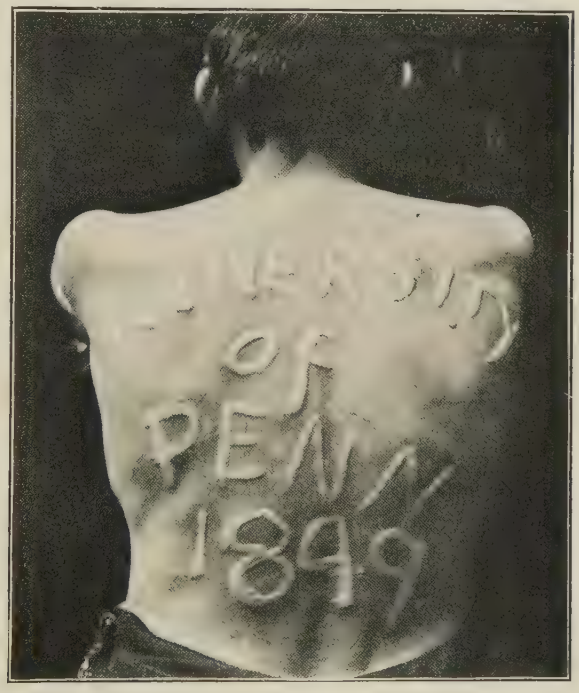

FIG. 30.—Dermatographism in a male adult. Tracing done with the blunt end of a lead-pencil, making slight pressure, the "welts" reaching full and prominent development in several minutes (courtesy of Dr. C. N. Davis).

vary in tint in different cases, and in different lesions in the same case. They are pinkish or reddish, with usually a whitish central portion. At times they are almost entirely whitish, with a narrow, pinkish areola. The subjective symptoms are, as a rule, quite marked, consisting of stinging, intense burning or itching, or a combination of these symptoms. Rubbing or scratching the parts to obtain relief will ordinarily provoke a new outcropping in such regions. The lesions are distinctly evanescent, lasting from several minutes to a fractional part of a day, the average being about an hour or two. The intervening skin is perfectly normal in appearance, new lesions presenting rapidly from time to time. In exceptional cases the indi-

vidual lesions may persist for several days or a week or longer—urticaria perstans. In some instances, with or without a few or more wheals on other parts, the disease presents itself as an ill-defined puffiness of the hands and fingers and feet, accompanied with intense subjective symptoms of burning and itching.

During an outbreak of urticaria, and in exceptional instances without actual outbreak, and even in the interim of attacks, it is possible in some persons to bring out linear wheals by simply rubbing the finger or drawing a lead-pencil somewhat firmly over the surface. In this manner letters, symbols, and words may be produced at will and last for minutes or hours. This, or a phase of it, constitutes the so-called **urticaria factitia, dermatographism, autographism.**

Barthélemy[1] has thoroughly studied this peculiar condition, and finds that while it is commonly associated with urticarial attacks at short or long intervals, it not infrequently may exist independently, and the subject learn of its existence only accidentally. One such instance as the last named has come under my notice. The lines or figures brought out at will in these cases last a variable time—from twenty or thirty minutes up to twenty-four hours. The tendency in some instances, according to Barthélemy, occasionally disappears temporarily.

The eruption in urticaria is not always confined to the external surface. The mucous membranes of the mouth, throat, larynx, and possibly the intestinal mucous surfaces, may exceptionally be the seat of wheals and edematous swellings, a number of instances of which have been recorded, more especially in recent years (Delbrel, Madison Taylor, Hinsdale, Merx, and others).[2] Occurring about the throat and larynx, the symptoms are sometimes alarming.

Urticaria may be acute or chronic; in most instances the former, the outbreak coming on rapidly, with slight variations as to the intensity of the attack. The lesions may continue to appear and disappear in the most capricious manner, for several hours to two or three days, and then disappear entirely; or there may be one more or less extensive outcropping of wheals, reaching its acme in an hour or so, and then gradually fading away. The duration of an acute attack is from several hours to several days, the average being twenty-four to forty-eight hours. It may recur in some instances from time to time at intervals of weeks or months upon exposure to the necessary etiologic factor or factors. In exceptional cases of urticaria, but more partic-

[1] Barthélemy, *Étude sur le Dermographisme ou Dermoneurose Toxivasomotrice*, Paris, 1893 (an admirable and complete monograph with a review bibliography of the literature and notes of many cases and 17 illustrations).

[2] Delbrel, "Contribution à l'etude de l'urticaire des voies respiratoires," *Thèse de Bordeaux*, 1896 (reviews 25 cases from literature and adds 2 of his own); Madison Taylor (larynx and skin), *Phila. Med. Jour.*, April 2, 1898; Hinsdale, *Phila. Polyclinic*, July 30, 1898; Freudenthal (recurrent and chronic of larynx and skin), *New York Med. Jour.*, Dec. 31, 1898; Chittenden (buccal, pharyngeal, and nasal mucous membrane and skin, chronic in character, with recurrent hematemesis), *Brit. Jour. Derm.*, 1898, p. 158; Goodale and Hughes (chronic and of tongue only, controlled by salol), *Amer. Jour. Med. Sci.*, April, 1899; Merx (recurrent, tongue, throat, and skin; with bibliography), *Münch. med. Wochenschr.*, 1899, p. 1174; F. A. Packard, Soc'y Trans., *Phila. Med. Jour.*, July 22, 1899, and *Archives of Pediatrics*, 1899, p. 729 (showing apparent connection between respiratory disturbances and urticarial eruptions).

ularly in the hemorrhagic form, pigmentation results which may last for some months or longer.

Chronic urticaria, fortunately, is not very common. In these cases the lesions are usually evanescent, as in the acute type, and very often somewhat scanty, but fresh efflorescences continue to appear from day to day and from week to week almost indefinitely, the patient's general health often suffering from the constant worry and discomfort produced by the itching and burning. Very exceptionally the lesions, or some of them, instead of being evanescent, are somewhat persistent, lasting days or weeks—**urticaria perstans** (Pick).

Instead of the characteristic lesions of the disease, the eruption may be atypical, thus arising the types known as giant urticaria, papular urticaria (urticaria papulosa), hemorrhagic urticaria (urticaria hæmorrhagica, purpura urticans) bullous urticaria (urticaria bullosa).

The conditions variously described as **giant urticaria, urticaria tuberosa, urticaria œdematosa,** and **acute circumscribed edema** are closely allied or identical, varying usually as to degree, and presenting the cutaneous symptoms of tumor-like swellings of evanescent character. They are frequently a part of a more or less general urticaria in which most of the symptoms are of the ordinary wheal type, presenting the edematous swellings here and there, more especially about the eyelids, mouth, and ears. Occasionally, however, acute circumscribed edema seems to be entirely or sufficiently independent of urticarial manifestations, and free from subjective symptoms, to be entitled to separate description (*q. v.*).

Urticaria papulosa, also known as **lichen urticatus,** consists essentially of an urticaria in which the lesions are discrete and scattered and usually upon the limbs. They may appear as small, more or less typical wheals, which disappear, leaving behind persistent eczema-like papules, though somewhat larger than the papules in the latter disease. Or the lesions may, for the most part, appear as papules from the start, with here and there a scattered typical wheal. In addition to the serous exudation of the ordinary wheal, there seems to be in this type a markedly inflammatory element. These papules usually itch intensely, and as a result the summits of many of them are scratched and covered with minute blood-crusts. They disappear but slowly, new papules coming out from time to time. This type may last from one to several months or longer, and tends to recur. It is almost entirely confined to young children and to those in a depraved state of health. It is rather rare in this country. It is possible that this form, instead of being a true urticaria, may be an example of mild prurigo, a disease which is not uncommon in Austria and other European countries.

Urticaria hæmorrhagica seu purpura urticans is characterized by efflorescences similar in size and shape to those of ordinary urticaria except that there is a variable amount of hemorrhage into the wheals. It is probable that in the majority of these cases the purpuric condition is the primary one, and the wheal formation secondary; in fact, in some cases the purpuric element may be of a somewhat grave character, with hemorrhages from the mucous membranes.

Urticaria bullosa, or **bullous urticaria,** is that form of urticaria in which the lesions become capped with a vesicle or bleb or in which the wheals are rapidly displaced by blebs. This anomaly is seen most frequently upon the extremities, although this lesion may in exceptional instances constitute the larger part of the eruption—so much so as to suggest pemphigus, dermatitis herpetiformis, or bullous erythema multiforme. Apparently the inflammatory action has been sufficiently great to give rise to considerable fluid effusion, in this manner the wheals resulting in the formation of bullæ.

Etiology.—Urticaria may occur at all ages and in both sexes, and in all countries. It is much more frequent, however, between the ages of early childhood and middle adult age, and is possibly somewhat more common in the female sex. The papular type is more frequent in England[1] than elsewhere, and is almost exclusively seen in children. There are many causes, but there is some peculiar individual predisposition necessary, inasmuch as the same cause may not produce the eruption in different subjects. In some instances a hereditary influence or predisposition is observed, especially in the cases associated with giant lesions and edematous swellings. The etiologic factors may be considered under the heads of external and internal causes, or direct and indirect.

As exemplifying the external causes may be mentioned the bites or irritation produced by jelly-fish, mosquitoes, fleas, stinging nettle, certain kinds of caterpillars, bedbugs, etc. Constant scratching or any persistent skin irritation, as in scabies and pediculosis, will at times also be provocative. While, as a rule, in urticaria produced by this class of etiologic factors the urticarial lesions appear only at the points or immediate neighborhood of the irritation, yet this is not always the case, as in particularly susceptible individuals a general outbreak may result.

The internal or indirect causes are numerous, here again the individual peculiarity having a potent contributory influence. Most of this class act through the stomach and intestinal tract. Among the more common factors in this class may be mentioned oysters, clams, crabs, lobsters, shrimps, mussels, fish, pork, more especially sausages and scrapple, veal, nuts, mushrooms, strawberries, and cucumbers. In addition to the articles of food named, others may be causative in special instances, owing to some striking idiosyncrasy, such, for instance, as oatmeal and butter. The irritation from intestinal worms may also be the cause in the urticarias of children. The malady is not infrequent in immigrants during their first several months' stay in our country, doubtless due to the complete change of diet and mode of living. An attack may also result from the ingestion of certain medicinal substances, more especially copaiba, cubebs, chloral, turpentine, quinin, opium, the iodids, and many of the coal-tar products. The use of antitoxins has added another cause occasionally provocative.

Emotional or psychic causes, such as anger, fright, or sudden grief, will sometimes excite an outbreak, more especially if occurring during or directly after a meal, the process of digestion being appa-

[1] Colcott Fox, "On Urticaria in Infancy and Childhood," *Brit. Jour. Derm.*, 1890, pp. 133 and 176.

rently interfered with, possibly permitting the development of toxins. Urticaria is at times observed in association with malaria, jaundice, albuminuria, and diabetes mellitus. The not infrequent occurrence of the disease in rheumatic and gouty individuals would point to these constitutional conditions as likewise predisposing. Functional and organic diseases of the uterus may also be found to be the important underlying etiologic factors, especially in the recurrent and chronic cases. Surgical operations, more particularly upon the abdominal cavity, exceptionally appear to be of causative influence. In fact, whatever gives rise to profound nervous disturbance must be looked upon as of some import. My own impression has been that these various factors act principally by the disturbing influence they

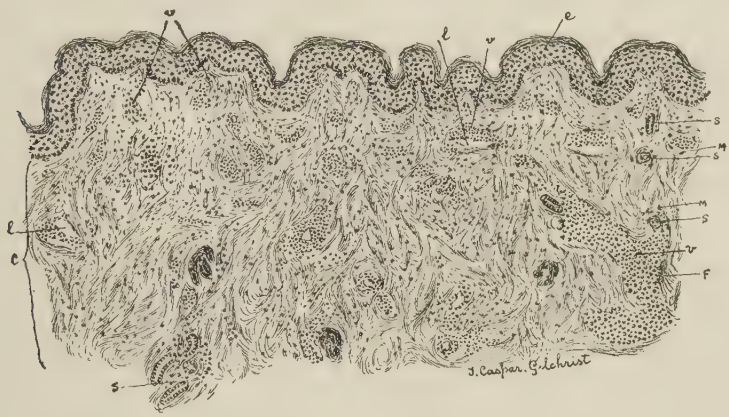

FIG. 31.—Urticaria—section of a wheal: *e*, Epidermis, practically no alteration; *c*, corium, showing acute inflammatory changes, swollen and infiltrated with serous exudation, with the blood-vessels (*v*, *v*, *v*), especially those accompanying the sweat-ducts (*s*, *s*, *s*, *s*) dilated and surrounded by and containing numerous polynuclear leukocytes; lymphatic vessels (*l*, *l*) and spaces also enlarged, containing granular matter; numerous mast-cells (*m*, *m*) scattered through the corium (courtesy of Dr. T. C. Gilchrist).

may have upon the act of digestion. Beyond question, toxins from without or within—autointoxication—must in this, as in some other diseases of the skin, especially erythema multiforme, be considered as the most common cause of the outbreak. The action of nervous influence, direct or indirect, is shown by a case reported by Oliver,[1] where the eruption was due to eye-strain, persisting or recurring when a change in lenses was necessary.

Pathology.—The pathology of urticaria is closely similar to that of erythema multiforme. The disease is an angioneurosis, the lesions being, primarily at least, due to vasomotor disturbance, which may be of diverse origin, but doubtless most commonly toxinic. Barthélemy believes dermatographism to be due to a toxic vasomotor dermatoneurosis. In urticarial lesions dilatation following spasm of the vessels results in effusion, and in consequence the overfilled vessels of the central portion are emptied by pressure of the exudation, and

[1] Oliver, *Philada. Med. Jour.*, Jan. 14, 1899.

the pink or reddish color gives place to central paleness, while the pressed back blood accentuates the bright red tint of the periphery. Philippson,[1] from animal experiments, believes, with Heidenhain, that the secretion of lymph is not a passive process due to intravascular pressure, as contended by most dermatologists, but that a secretory action of the vascular endothelium is involved; and that the edema of urticaria is similarly produced by direct action of poisonous substances upon the vessels in the neighborhood. Török and Hari's[2] experimental studies are also in accord with this view. Wright and Paramore[3] believe that an attack of urticaria may be directly due to a diminution of the lime salts in the blood, with consequent associated defective blood coagulability—is of the nature of a serous hemorrhage.

The pathologic anatomy of a wheal, studied by various observers (Vidal, Unna, Gilchrist, and others), shows it to be a more or less firm elevation of a circumscribed or somewhat diffused collection of semifluid material, more especially in the upper layers of the skin. While it has its usual seat in the derma proper, in intense cases the subcutaneous tissue may also be involved in the process. Gilchrist[4] found the epidermis unaltered, but the whole corium the seat of acute inflammatory changes; the blood-vessels, especially those accompanying the sweat-ducts, enlarged, containing and surrounded by a large number of polynuclear leukocytes; the lymphatic vessels and the juice-spaces were also much enlarged, containing only granular material; large numbers of polynuclear cells were found to pervade the whole region, even into the papillæ, but only a few had found their way into the epidermis. There were numerous mast-cells throughout the corium, and the latter was much swollen and infiltrated with serous exudation.

Diagnosis.—This rarely gives any difficulty. In fact, the disease is so common and well known that the diagnosis is usually made by the patient. The character of the lesions, their evanescent nature, the irregular and general distribution, usually abundant upon covered parts, and the accompanying intense itching, will afford sufficient basis for its recognition. These points will serve to differentiate it from erythema multiforme, to which it bears some resemblance. Urticaria bullosa might, upon first and careless inspection, lead to a confusion with pemphigus or dermatitis herpetiformis, but the usually preceding wheal upon which the bleb arises, and the presence here and there of the ordinary type of the eruption, together with the history and course, will prevent error.

Chronic urticaria has essentially the same features as the acute disease, except the eruption is usually less abundant. It is not to be forgotten that both pediculosis and scabies, as well as the irritation of other animal parasites, may occasionally be responsible for scattered

[1] Philippson, *Giorn. ital.*, 1899, Fasc. vi., p. 675, abs. in *Brit. Jour. Derm.*, 1900, p. 217.

[2] Török and Hari, "Experimentelle Untersuchungen über die Pathogenese der Urticaria," *Archiv.*, 1903, vol. lxv., p. 21.

[3] Paramore, (experimental study), *Brit. Jour. Derm.*, 1906, pp. 239 and 248.

[4] Gilchrist, quoted by Duhring, *Cutaneous Medicine*, Part ii.

wheals, but the other eruptive features of such maladies (*q. v.*) are usually sufficiently distinctive to prevent confusion.

Prognosis.—The acute disease is of short duration, disappearing, spontaneously or as the result of treatment, in several hours or a few days; it may recur upon exposure to the exciting cause. Patients with urticarial tendency should give special attention to the dietary, and avoid those articles which may cause indigestion or which experience has taught them may, owing to some idiosyncrasy, provoke the disease. The prognosis of chronic urticaria is to be guarded, and will depend upon the ability to discover and remove or modify the etiologic factor. Recurrences are not uncommon.

Treatment.—Acute urticaria, the most common expression of the disease, is usually due to stomach or digestive disturbance of acute character. If the case is urgent and seen early, an emetic, to rid the stomach quickly of the offending material, may be given; this is, however, rarely required. The usual plan is to give a purge. For this purpose there is nothing better than the antacid magnesia, although any of the various salines will usually act satisfactorily. In addition to the purgative, an antacid should be administered at several hours' interval, such as sodium salicylate or sodium bicarbonate or benzoate; of the salicylate, 5 to 10 grains (0.35–0.65) three or four times daily, and of the others, 10 to 20 grains (0.65–1.35) at a dose; in children the doses should be smaller. The diet for the time should be plain. In the vast majority of the acute cases this simple plan of treatment will prove sufficient to end the attack. If the attack should be somewhat persistent, the alkali should be continued, and, in addition, small doses of salol and a few grains of charcoal added to each dose. The calcined magnesia, too, should be administered about every other night until the disease has yielded.

It is, however, the chronic cases of urticaria which often tax our therapeutic resources. Such cases require the most rigorous and careful examination, in order to discover, if possible, the underlying etiologic factor or factors. The possibility of diabetes, albuminuria, disease of the liver, and utero-ovarian disease being the influential cause should be eliminated. The urine should be carefully and repeatedly examined, for this sometimes gives the clue to the acting factor. Particular attention should be given to the digestive apparatus, for probably this, as in the acute cases, is the most common source of the disease. The patient's habits as regards the use of alcohol and the use of drugs should also be inquired into, as having a possible bearing.

There are many cases, it is true, of chronic urticaria in which the etiology remains obscure, even after the most careful investigation, and such cases must be treated empirically. Experience has taught that the remedies most frequently successfully used in such cases are quinin, sodium salicylate, atropin (Schwimmer and many others), pilocarpin (Pick), ergot, potassium bromid, salol, strophanthus (Riffat), ichthyol, strychnin, calcium chlorid (Wright), along with saline laxatives. Arsenic may also be tried in resistant cases, although, except indirectly, in small doses as a tonic, it is usually disappointing. The most efficient of these in a given number of cases are atropin and sodium salicylate.

Frequent and repeated doses of saline laxatives sometimes cure when all the ordinary remedies have failed to make a permanent impression. For this purpose calcined magnesia, taken every second or third night, or Carlsbad salts, magnesium sulphate, sodium sulphate, Hunyadi Jànos water, or Friedrichshall water, taken every morning or every second morning, can be prescribed. The dose should be sufficient to produce free and prompt action, but not sufficiently large to bring about a condition of diarrhea. The following also has given me satisfaction:

℞. Sodii sulphat. granulat.,	℥ij (64.);
Sodii chlorid.,	ʒiiss (10.);
Sodii bicarbonat.,	ʒvss (22.).

This should be kept in a closely stoppered, wide-mouthed bottle, and one to two teaspoonfuls taken dissolved in a half to a tumblerful of hot water twenty or thirty minutes before breakfast; or in some cases it seems to act better when taken in smaller doses—a half to one teaspoonful—before each meal. In obstinate cases spinal galvanization, static insulation, and the static current with the roller electrode applied along the spine should be tried.

It is understood that in all these cases the diet is to be carefully regulated, and all indigestible foods interdicted, and especially those articles which experience has taught are not infrequently causative factors. Coffee and tea in excess should also be avoided; in fact, these drinks should be, in rebellious cases, forbidden absolutely. Resorting for a time to an exclusively milk diet will sometimes prove curative, or at least remove the disease for a time. In persistent cases of the disease which have proved rebellious to all plans, especially those dependent upon neurasthenic conditions, change of scene and climate will sometimes give temporary, and not infrequently permanent, freedom.

If the eruption is extensive the itching is likely to be so troublesome a feature that the patient loses much sleep, and in such instances, occasionally, recourse must be had to potassium bromid, chloral, sulphonal, acetanilid, phenacetin, and the like. In a few instances two or three daily doses of acetanilid or phenacetin in moderate quantity have, as already intimated, afforded more or less permanent relief. Opiates are usually to be avoided, inasmuch as they often increase the subjective symptoms.

In most cases of urticaria it is found necessary to resort to *local applications* to give some relief to the intense itching and burning which usually characterize the malady. The most efficient are those remedies which are known to have an antipruritic action. Carbolic acid in lotion form is one of the most valuable antipruritics in our possession. It may be prescribed as in the following:

℞. Acid. carbolici,	ʒss–ʒj (2.–4.);
Glycerini,	ʒss (2.);
Alcoholis,	ʒj (32.);
Aquæ,	q. s. ad ℥viij (256.).

Liquor carbonis detergens is another valuable preparation, and may be used in the strength of 1 to 2 or 3 ounces (32. to 96.) to the pint (500.) of water. A lotion of thymol, such as the following, will likewise be found of value:

℞.	Thymolis,	gr. viiss–xv (0.5–1.);
	Glycerini,	℥ij (8.);
	Alcoholis,	℥ij (64.)
	Liquor potassæ,	ʒj (4.);
	Aquæ,	q. s. ad ℥viij (256.).

Alkaline baths are also of great benefit in some cases. These may be made with borax, sodium carbonate, sodium bicarbonate, 1 to 4 ounces (32. to 128.) to the bath of about 30 gallons; ammonium muriate, 1 to 2 ounces (32. to 64.) to the bath, is also useful. The patient should remain in the bath from several minutes to ten or fifteen minutes, and the temperature should be sufficiently warm that chilliness does not occur.

In mild cases, and even in some of the more severe cases, the use of a dusting-powder on the affected surfaces will be sufficiently soothing, and has the advantage of cleanliness and ease of application. For this purpose any of the ordinary dusting-powders, such as zinc oxid, rice flour, talc, and boric acid can be used.

Ointments are rarely of service in the ordinary type of this disease, but in the types described as the vesicular and bullous varieties, they may be demanded for their soothing and protective influence. For this purpose the plain zinc oxid ointment, with 5 or 10 grains (0.35 or 0.65) of resorcin or carbolic acid to the ounce (32.), will prove satisfactory. A boric acid ointment—1 dram (4.) of boric acid to the ounce (32.) of cold cream—may also be of use. If there is a good deal of irritation, the calamin-zinc-oxid lotion may likewise be employed in these cases.

URTICARIA PIGMENTOSA.[1]

Synonyms.—Xanthelasmoidea; Urticaria perstans pigmentosa.

Definition.—An urticaria-like eruption, in which the lesions are usually persistent and show accompanying or subsequent pigment deposit, with, in some, a new growth element.

[1] Literature: For cases, etc., antedating 1883 (Nettleship, Morrant Baker, Tilbury Fox, Barlow, Sangster, Morrow, Goodhart, Mackenzie, Cavafy), see paper by Colcott Fox, *Trans. Med.-Chir. Soc'y*, London, 1883, p. 329; also Crocker's paper, *Trans. Clin. Soc'y*, London, 1885, p. 12; also Raymond, "Urticaire pigmentée," *Thèse de Paris*, 1888 (giving a complete review of the subject—referring to 29 cases). Among the many cases reported since may be mentioned: Elliot, *Jour. Cutan. Dis.*, 1891, p. 296; Hallopeau (leaving white cicatrices), *Annales*, 1892, p. 628; Bronson (soc'y discussion)—*Jour. Cutan. Dis.*, 1894, p. 260; Morrow, *ibid.*, 1895, p. 445 (leaving in places tabs of loose skin—this case was over twenty years' duration); Jadassohn, *Verhandl. d. IV. Deutsch. derm. Cong.*, Vienna, 1894; Fabry, *Archiv*, 1896, vol. xxxvi., p. 21; Gilchrist, *Johns Hopkins Hosp. Bull.*, vol. vii., 1896, p. 140; Dubrisay et Thibiérge, *Annales*, 1896, p. 1303; Colcott Fox, *Brit. Jour. Derm.*, 1898, p. 411 (especially bearing upon urticaria pigmentosa and true urticaria leaving pigmentation); Brongersma, *Brit. Jour. Derm.*, 1899, p. 179 (a good résumé of the pathology); Woldert, *Jour. Amer. Med. Assoc.*, Oct. 21, 1899, p. 1022; Stelwagon (3 cases), *Jour. Cutan. Dis.*, 1898, p. 576; Duhring's *Cutaneous Medicine*, Part ii., p. 300; Graham Little (an admirable paper—clinical, histologic, experimental and review, with tabulation of reported cases), *Brit. Jour. Derm.*, 1905, pp. 355, 393, 427, and 1906, p. 16.

Symptoms.—The eruption, which, with rare exceptions, makes its appearance in the first several months of life, is, as a rule, scarcely distinguishable in its beginning from ordinary urticaria; but the lesions, or the most of them, instead of disappearing quickly, are persistent, and after some days or a few weeks show pigment deposit. An individual lesion may continue for weeks, months, or at times longer, gradually flatten down, and leave behind slight or pronounced

FIG. 32.—Urticaria pigmentosa in a female child eleven months old. Began in the fourth month, at first on the legs, and gradually invaded the entire surface, including the scalp. The lesions present as ordinary wheals, but are persistent, subsiding somewhat, becoming yellowish, later with a violaceous tinge; after continuing for several months or longer they disappear, leaving purplish and bluish-yellow stains. Some of the lesions have a slight resemblance to xanthoma. Itching was, as a rule, moderate, only occasionally troublesome. Several years later the malady was much less active, and the lesions relatively sparse. General health excellent.

stain. This stain may be at first quite purplish and later become less pronounced, and finally, sometimes only after years, entirely disappear. Quite commonly rubbing the affected region will bring up wheals at the sites of the stains of disappearing lesions. Instead of the purplish or bluish tinge, the lesion may be of a yellow or salmon color. These latter bear some resemblance to xanthoma. In some instances the lesions are yellowish, bluish, or purplish almost from the start. Occasionally, after they disappear, their site will show a scarcely perceptible wrinkled appearance, as in one of

my own cases, which persists; or exceptionally slight atrophy or scarring (Hallopeau, Brongersma) or tissue-formation (Morrow's case). Exceptionally some distinct atrophy has been noticed. In several or more lesions of some cases there may be a tendency to vesicular capping. New efflorescences continue to appear from time to time, some of which are more or less evanescent, like ordinary urticaria. There may be a feeling of solidity in the lesions, or they may be somewhat soft to the touch. They are small to large pea-sized, and sometimes even nodular. The eruption may be somewhat scanty or profuse.

The covered regions of the body usually show the eruption most abundantly, although other parts, especially the face and the neck, are often likewise involved. The disease continues for years, with periods of comparative quiescence, during which but few new lesions will make their appearance. Itching may be present to a marked degree, or it may be slight, or exceptionally entirely wanting. The general health remains unaffected, although occasionally loss of sleep, as a result of intense itching, may give rise to some nervousness and debility.

Etiology and Pathology.—It is seen in children, in most instances beginning before the third or fourth months; in a case reported by Crocker it was practically congenital. Exceptionally it appears at a much later period—the extreme, at twenty-seven years (Elliot). Boys seem to furnish the majority of cases. The essential cause, and even contributing or predisposing causes, are as yet unrecognized There is sometimes a history of urticarial tendency in the family. The subjects are, as a rule, otherwise seemingly in good health. In one instance (Woldert) the disease followed varicella. It is, judging from case reports, much more common in England than elsewhere.

A review of the various cases reported would lead to the opinion that in some the true urticarial element is preponderating, while in others, especially those presenting the soft, persistent, xanthoma-like lesions, there is a new growth element. The impression conveyed by the 3 cases under my observation is that the disease is essentially an urticaria, primarily at least, and that the subsequent peculiarities are due to secondary changes in the lesions. The anatomic studies (Thin, Colcott Fox, Unna, Gilchrist, Brongersma, and others) show that it has in some respects the structure of a wheal, with edema and pigment deposit in the epidermal portion, and cellular infiltration made up principally of mast-cells. This last feature may, indeed, be considered characteristic; the origin of the cells is still in doubt, Unna believing that they develop from connective-tissue cells. The investigations of Gilchrist and Brongersma seem to indicate, as summarized by the latter, that the mast-cells existed before the formation of the wheal, and as a result of the rapid edema and other changes coincident with the formation of the wheal, have been swept together from the tissues in the neighborhood, where they had already existed in large numbers. Little is inclined to believe that there is a general tendency, probably congenital, to overproduction of mast-cells in the skin of these patients, the local excessive accumulation (clinically represented by macules or nodules) determined by various accidental phenomena.

Diagnosis.—The diagnostic features are the early appearance of the eruption, the persistent, urticaria-like lesions leaving stains, the usually associated ordinary wheals of urticaria, and chronicity. In those instances in which the activity of the malady has subsided, and in which the yellowish, xanthoma-like lesions are present, there might be some suggestion of multiple xanthoma, especially if there is no itching; but the history of the case, the characters of the early lesions, and the usually occasional presentation of wheals, will prevent error. Moreover, rubbing the hand firmly over the lesions will usually cause them to become more pronounced.

Prognosis and Treatment.—The disease is chronic and persistent, but almost invariably begins to subside as puberty is approached, and rarely extends into adult life. Nor is it, unfortunately, much influenced by therapeutic measures. The usual remedies for urticaria should be experimentally prescribed. The most promising are sodium salicylate, pilocarpin, belladonna, and arsenic, in moderate dosage, continued for some length of time. The diet should be looked after, and indigestible foods interdicted. Any contributory condition of ill health should be corrected. External treatment is sometimes necessary for the relief of the itching, and for this purpose the various applications prescribed for urticaria may be employed.

OEDEMA ANGIONEUROTICUM.

Synonyms.—Acute non-inflammatory edema; Acute circumscribed edema; Angioneurotic edema; Œdema circumscriptum; Œdema cutis circumscriptum acutum; Quincke's disease; Giant urticaria and Urticaria œdematosa (many cases); *Fr.*, Œdème aigu.

Definition.—An affection, characterized by one, several, or more acute circumscribed edematous swellings, usually in regions where the tissues are readily distensible, as the eyelid, ear lobe, lip, etc. Quincke was the first to call special attention to this somewhat rare and peculiar malady, since which time Jamieson, Strübing, Riehl, Collins, Osler, and many others have reported cases.[1]

Symptoms.—The swelling may present itself without constitutional or other symptoms. In some instances, however, there are a variable degree of premonitory malaise, gastro-intestinal disturbance, and a feeling of being generally out of sorts, which usher in the cutaneous phenomena and sometimes persist throughout the attack. Doubtless in some instances these may be due to edema-

[1] Some important literature references: Quincke, *Monatshefte*, 1882, p. 129; Jamieson, *Edinburgh Med. Jour.*, June, 1883, p. 1090; J. E. Graham, *Canadian Practitioner*, Feb., 1885, p. 33; Strübing, *Zeitschr. f. klin. Med.*, 1885, p. 381 (with numerous references); Matas, *New Orleans Med. and Surg. Jour.*, vol. xv., 1887–88, p. 257; Riehl, *Wien. med. Presse*, pp. 354, 398, and 431, 1888 (with references); Osler, *Internat. Jour. Med. Sci.*, 1888, p. 362; Elliot, *Jour. Cutan. Dis.*, 1888, p. 19; Unna, *Monatshefte*, 1880, vol. viii., pp. 446 and 490; Hartzell, *University Med. Magazine*, May, 1890; Collins, *Amer. Jour. Med. Sci.*, vol. civ., 1892, p. 654 (an admirable analytic paper with full bibliography); E. W. Jacob, *Brit. Jour. Derm.*, 1892, p. 155 (with bibliography); Schlesinger, *Wien. klin. Wochenschr.*, 1898, p. 235; Wende, *Jour. Cutan. Dis.*, 1890, p. 178; Onuf (Onufrowicz), *Med. Record*, Aug. 5, 1899, p. 183 (and allied conditions); Baruch, *ibid.*, Aug. 19, 1899, p. 257. Kohn, *American Medicine*, Dec. 21, 1901, p. 997 (with review of the literature and full bibliography); Morichaut-Beauchant, *Annales*, 1906, p. 22 (review with many references).

tous swellings in the gastric wall, in others to the development of toxins which provoke the malady. The swelling itself, however, is acute, coming on suddenly, and reaching full and usually enormous development in a few seconds or minutes. Occasionally, however, it comes on somewhat gradually, one or two hours elapsing before its acme is attained. The swelling is, as a rule, rather sharply circumscribed; rarely with a diffusing tendency into the neighboring tissues. If the eyelid is the region involved, the eye is usually completely closed; if the lip, the part is stiff and large, and for the time scarcely admits of opening; and if both lips are attacked, temporarily incapacitating for talking or eating. The nose is also occasionally the site of this swelling, and attains considerable dimensions, but not so large as the lip, ear lobe, or eyelid, where the tissues permit of greater distention. The extremities are likewise frequently subject to these swellings. Less commonly other parts may be attacked, even the tongue and glottis. According to the analysis of 71 cases collected and tabulated by Collins, the first attack was noted on the face in 29 instances, on the extremities in 22, trunk 6, larynx 5, genitalia 3, stomach 3, gums and palate 1, neck 1, and mastoid region 1. While the swelling is usually enormous, in some cases it is relatively slight, or may vary somewhat in different attacks. As a rule, but one part is swollen at one time, although in some instances several lesions may appear simultaneously or one after the other; it is more commonly shifting, disappearing in one place and reappearing in another. The swelling may be of the normal color of the skin or somewhat paler, or it may be of a pinkish or reddish hue. It is somewhat hard, does not pit like ordinary edema, although a slight depression of transitory character may usually be made by pressure.

The duration of the swelling varies; it may disappear as rapidly as it came, or more commonly last several hours, or in some instances a few days, and then rapidly or gradually melt away. The attack may thus end, or it may continue by the appearance of one or more swellings elsewhere, and persist for several days or one or two weeks; exceptionally for months or a year or more, as in Graham's case,[1] the patient is scarcely free from these evanescent swellings.

It is not uncommon for the malady to recur from time to time, and it is believed that there is a tendency to recur at a point previously involved, but this is probably merely due to the fact that there are comparatively few regions at which it is prone to occur, rather than to any engendered weakness of the part. In some cases there is itching or burning, and almost always more or less tension or a feeling of stiffness in the part occurs. The surface temperature in some cases has been noted to be slightly elevated, in others reduced, and in others again undisturbed. While some of the edematous swellings—one or several—may be free from subjective symptoms, in others there is intense itching, and there may also be here and there, scattered over the surface, ordinary urticarial efflorescences. In some instances partial local anesthesia or numbness has been noted for a short time after the disappearance of the swelling.

Etiology and Pathology.—The affection is met with in both

[1] E. E. Graham, *Annals of Gynecology and Pediatry*, April, 1894.

sexes and almost at any age, being probably most frequent between early youth and middle life. The manifestation is closely allied to urticaria, as shown by the not infrequent association of ordinary wheals, or history of urticarial attacks. Some cases, however, seem to be free from suggestive subjective symptoms and other evidences of an urticarial character. Strübing, Quincke, Osler, and others have called attention to the frequently shown family predisposition. Osler in one instance elicited a history of its occurrence in five generations. Various causes are apparently exciting, the most frequent, as also observed in urticaria, being articles of food which disturb digestion or give rise to the development of gastric or intestinal toxins. Its most common subjects are found in those of weak digestion and easily disturbed nervous system. In Matas's case of daily attack, the swellings seemed to take the place of a malarial attack. In many instances there appears to be a systemic sympathy or auto-intoxication; Lodor[1] states that all his cases, except one, showed a marked malaise and depression preceding the attack, and his patients could thus foretell the approaching outbreak. Horwitz[2] observed 3 cases follow traumatism, and in Ashton's[3] patients the attacks followed exposure to draught or sudden cooling of the surface. The outbreaks in Oppenheimer's patients were excited by alcoholic beverages. Wende noted in the attacks in his case an association of albuminuria and hemoglobinuria.

Acute circumscribed edema is of angioneurotic origin—a vasomotor neurosis, in short, and similar to urticaria. It is probably true, as Riehl concluded, that the exciting cause of these peripheral vasomotor disturbances is to be found in the central nervous system. Lodor's studies lead him to believe that the presence in the blood of a lymphagogue in pathologic quantity, and the rapid rise of lymph pressure, produce, in areas of lessened resistance, a sudden and rapid vasomotor paralysis in such regions. He quotes Heidenhain's observation as to the various substances which, when injected into the circulation, have the power of largely increasing the flow of lymph,—such food-products as mussels, etc., sometimes egg-albumen, sugars, and the like,—and to which often an attack is to be ascribed.

Diagnosis.—The features of angioneurotic edema—its usually sudden appearance and disappearance, the absence of positive pitting upon pressure, and the regions likely to be involved, with frequently a history of former attacks or family tendency, and often of urticarial outbreaks—are sufficiently characteristic to prevent error. Persistent edema observed as a symptom in association with other diseases, with lymphatic or glandular obstruction, is readily distinguished by its very persistence.

Prognosis and Treatment.—The malady is usually a benign, although often a troublesome, one. Rare exceptions, however, of fatal termination due to involvement of larynx and glottis have been observed. An immediate attack is generally amenable to treatment, but freedom from future attacks cannot be assured. Much will depend upon the patient's mode of living, freedom from nervous disturbance,

[1] Lodor, *Medicine*, Nov., 1898. [2] Horwitz, *Medical News*, April 16, 1892.
[3] T. G. Ashton, *Medical News*, April 8, 1893.

and strict attention to dietary. The management, in fact, is essentially that of urticaria. Saline laxatives and antacids, more especially sodium salicylate, have proved most useful in my hands, and Hartzell also has had most satisfaction with this plan. Sodium benzoate in 5- to 20-grain (0.35 to 1.35) doses, three times daily, can be used in place of sodium salicylate, and for purgative or laxative purpose I can cordially commend the ordinary antacid magnesia (see urticaria). Salol as a gastro-intestinal antiseptic is valuable. Arsenic (Matas), pilocarpin by subcutaneous injection, atropin, ergot, bromids, etc., may also be mentioned, of which the most valuable are pilocarpin and atropin.

PITYRIASIS ROSEA.[1]

Synonyms.—Pityriasis maculata et circinata (Bazin); Herpes tonsurans maculosus (Hebra); *Fr.*, Pityriasis rosé.

Definition.—A mildly inflammatory affection, characterized by discrete and frequently confluent, plain or circinate, salmon-tinted, pinkish or pale red, variously sized, slightly raised, scaly efflorescences, seen most abundantly upon the trunk.

Symptoms.—The trunk, and especially laterally, usually first shows the eruption. It may appear rapidly and attain full development in the course of several days; or its appearance may be slow and gradual, coming out irregularly or in several distinct crops, one to two weeks elapsing before its acme is reached. In some cases, as Brocq[2] has pointed out, the affection is heralded by a primary, somewhat large, efflorescence, which is seen most frequently anteriorly near the middle of the waist, and this is the forerunner of the more or less generalized eruption, which appears from four to ten or twelve days later. The lesions are, as a rule, but slightly elevated, well or irregularly rounded or oval macules, and with trifling or moderate scaliness. They vary in size from a small pea to a silver quarter, are usually quite numerous, pinkish or pale red in color, and often, especially toward the period of defervescence, present a distinct salmon tinge. The eruption may be scanty, consisting of thirty to sixty or seventy patches, or, as more commonly occurs, is quite abundant. The scaliness is somewhat variable, usually slight, but in occasional instances in some of the lesions may be quite pronounced. As a rule, however, the lesions do not remain, as just described, but some or many of them spread peripherally and become less marked centrally, presenting a circinate patch; the central part is noted to be but slightly involved, while the periphery, by its more pronounced scaliness, is quite distinct. In many cases the circinate character presents only after the disease has lasted for several days or longer; in others it is a part of the eruption from the start. The scaliness is rarely abundant in these latter cases, but usually bran-like or flaky,

[1] Early literature: Gibert, *Traité pratique des maladies de la péau*, Paris, 1760, p. 402; Duhring, "Pityriasis Maculata et Circinata," *Amer. Jour. Med. Sci.*, Oct., 1880; Behrend, "Ueber Pityriasis rosea (Gibert), maculata et circinata (Bazin), *Berlin. klin. Wochenschr.*, 1881, p. 552; Colcott Fox, "On the Disease of the Skin named Pityriasis Maculàta et Circinata," *Lancet*, Sept. 20, 1884, p. 485.

[2] Brocq, "Note sur la plaque primitive du pityriasis rosé de Gibert,," *Annales*, 1887. p. 615.

and of a gray or dirty-gray color, and in a majority of cases most marked peripherally. As the circinate patches extend, the central portions are gradually clearing up, and several or more sometimes coalesce and form large irregular areas. The skin is rarely thickened, shows practically no infiltration, the process being usually superficial.

The eruption may be limited to the trunk, or trunk, neck, upper arms, and thighs; exceptionally it is of wider distribution. The face

FIG. 33.—Pityriasis rosea in an adult aged thirty, of two weeks' duration, and involving trunk, upper part of the thighs, and arms; showing the slightly to moderately scaly macular and circinate patches—in some places confluent.

is not often involved. After one or two weeks, in average cases, the eruption begins to decline, and in the course of several weeks, or at the most a few months, it has entirely disappeared. Exceptionally, it is somewhat slower in its course. Slight itching may be present, especially when the patient is warm or perspires, but in most instances there is an entire absence of subjective symptoms. As a rule, there is no constitutional involvement, although in extremely extensive

cases there may be at the outset slight general disturbance of mild character.

Etiology.—The disease is rather infrequent. It is met with in both sexes, and almost at any age, but is more common in grown children and young adults, less frequently in those of dark hair and complexion than in those of the medium and blonde types.[1] The essential cause is unknown, but that time will disclose a parasitic factor is scarcely to be doubted. According to Thibiérge, the disease does not recur, but this, I believe, does occasionally take place. There is a growing tendency, not without reason, to consider the disease as possessing contagious properties of, however, a feeble character; 2 cases in the same family have been observed by Crocker,[2] Zeisler,[3] Fordyce,[4] and G. H. Fox.[5]

Pathology.—Many of the European dermatologists, especially those of Austria, have looked upon this disease as disseminated ringworm, called by them herpes tonsurans maculosus; but English, French, and Americans are well assured of the individuality of the disease, in which ringworm fungus is never found. The truth of the matter seems to be that there is a disseminated ringworm, infrequent, it is true, but seen chiefly in Austria, which closely resembles it, although many of the cases so considered are doubtless those of pityriasis rosea.

While pityriasis rosea is probably of parasitic origin, as yet no one, excepting Vidal,[6] whose findings have never been corroborated, has ever discovered a parasite. Other views held as to the nature of the disease are: that it is allied to eczema seborrhoicum, and that it may be a mildly inflammatory disease, somewhat similar to psoriasis. There is, it is true, in some cases a close clinical resemblance to the seborrheic disease, which was pointed out by Besnier.[7]

The pathologic anatomy of this disease has been investigated by Jacquet, Unna, Tandler, and Towle, and, upon the whole, indicates that the process in the earlier stage or in mild cases is an extremely mild inflammation seated in the upper cutis, of a serous and hyperplastic character, always more marked toward the periphery; in the later stages or in more pronounced lesions the inflammatory changes are emphasized, and there is displayed a tendency to irregularly formed minute pressure vesicles beneath the corneous layer, but which are not macroscopically visible. Almost the whole papillary body is

[1] Towle, *Jour. Cutan. Dis.*, April, 1904, from an analysis of 202 cases—158 from the records of the dermatologic department of the Massachusetts General Hospital, and 44 from the private records of Dr. John T. Bowen—states: Pityriasis rosea occurs in the two forms—the macular and the circinate—with about equal frequency; affects most often the trunk and upper part of the extremities, but is occasionally limited to one part; it is more frequent in the autumn months, and by far more common in women than in men; recurrences, though rare, do occur; race and occupation have no influence. His other conclusions are about the same as outlined in the text.

[2] Crocker, *Diseases of the Skin*, second edit., p. 288 (2 instances in 2 members of the same family).

[3] Zeisler, *Jour. Cutan. Dis.*, 1893, p. 494 (husband and wife).

[4] Fordyce, *ibid.*, p. 497 (husband and wife), and *ibid.*, 1898 (Soc'y Trans.), p. 340 (in 2 sisters occupying same room).

[5] G. H. Fox, *ibid.* (mother and child).

[6] Vidal, *Annales*, 1882, p. 22.

[7] Besnier, *Annales*, 1889, p. 108; D. W. Montgomery, *Jour. Cutan. Dis.*, 1906, p. 167, discusses this as well as other points in an analytical paper (38 cases).

converted into a net of spindle-cells with stellate connecting processes.

Diagnosis.—The disease is to be distinguished from seborrheic eczema, tinea circinata, psoriasis, and the maculopapular scaly syphiloderm.

Seborrhea differs in having greasy scales, in its more gradual appearance, in its usually taking its start from a seborrhea of the scalp or eyebrows, and in the evolution and character of the patches and its persistent course. Seborrheic patches sometimes show (over the sternum) slight projection into the sebaceous follicles; in some cases the diagnosis may be difficult at first, but a short observation will usually suffice to clear up any doubt.

Ringworm is rarely seen in such profusion as pityriasis rosea, the ring shape is more distinct, there is a more decided disposition to central clearing, even when the patches are small; the peripheral portion is usually more sharply marginate and occasionally is vesicopapular or vesicular. Typical ringworm patches are also often seen about the face and hands, unusual sites for pityriasis rosea. In suspected cases scrapings from the peripheral portion should be examined by the microscope (see ringworm).

Psoriasis is, as a rule, more inflammatory, the periphery more sharply marginate, the scaling more profuse, and patches are also frequently seen in the scalp, especially toward the border of the forehead and mastoid regions, and generally to be found likewise on the extensor surfaces of the knees and elbows. It usually comes on slowly, and at first rarely displays any tendency to ring-formation.

The maculopapular syphiloderm, if scaly, bears a close resemblance, but there is usually distinct infiltration, it is of a darker color, and lesions are not unusual on the palms and face; as it is an eruption of the active stage of syphilis, one or more corroborative symptoms are always to be found.

Prognosis and Treatment.—The disease usually runs its course in three or four weeks to a few months, disappearing spontaneously. As a rule, there is no special tendency to recurrence. It has seemed to me that the use of certain external applications tends to shorten its course, such as a mild sulphur ointment, from 20 to 60 grains (1.3 to 4.) to the ounce (32.) of petrolatum or benzoated lard, or one containing from 10 to 30 grains (0.65 to 2.) of salicylic acid; or an ointment containing both of these ingredients may be prescribed:

℞.	Acid. salicylici,	gr. xv (1.);
	Sulphur. præcip.,	gr. xxx (2.);
	Petrolati,	
	Ungt. aquæ rosæ,	āā ℥ss (16.).

The selected ointment is to be gently rubbed in, in small quantity, once daily; the excess wiped off, and a mild dusting-powder applied. The application is to be preceded every day or every other day by an ordinary soap-and-water bath; or, in cases in which the scaliness is somewhat more abundant than usually observed, with an alkaline bath. Lotions applied with a piece of lint or as a spray can be employed in place of the ointments, but do not seem to exercise as much influence,

although they are more agreeable, and have more effect in controlling the itching if present; the following may be used: Carbolic acid, 1½ drams (6.) to the pint (500.) of water, to which a dram (4.) of glycerin and an ounce (32.) of alcohol may be added; and a lotion of boric acid, 15 grains (1.) to the ounce (32.) of water, with also from 5 to 10 grains (0.32 to 0.65) of resorcin added. In addition to the external applications a saline laxative may be occasionally prescribed, along with, if in any way indicated, such tonics as quinin, strychnin, and iron.

DERMATITIS EXFOLIATIVA.[1]

Synonyms.—Pityriasis rubra; General exfoliative dermatitis; Acute general dermatitis; *Fr.*, Dermatite exfoliatrice; Érythrodermie exfoliante (Besnier).

Definition.—A more or less generalized, exceptionally limited, exfoliating inflammatory disease of acute or subacute type and of variable duration, arising primarily as such or supervening upon other chronic scaly affections.

Symptoms.—As a primary affection the disease may begin insidiously in several scattered regions, probably more commonly (Leloir and Vidal) about the axillæ, genitocrural region, and other flexures; it rapidly spreads, and together with the appearance of new areas soon covers the greater part or the entire surface; or there may be at once more or less general involvement. Exceptionally, the disease may remain, for a time at least, more or less limited in its distribution (Crocker, Bulkley, and others). I have met with several cases in which the chief brunt of the process was borne by the extremities.

In many cases the outbreak is preceded by a distinct chill or chilliness, malaise, and sometimes vomiting and febrile action; these

[1] Important literature: Erasmus Wilson, *Med. Times and Gazette*, 1870, 1, p. 118, and *Treatise on Diseases of the Skin;* Hebra, in Hebra and Kaposi's *Hautkrankheiten*, second edit., 1874, vol. i., p. 398; Hebra, Jr., *Archiv*, 1876, p. 508; Anderson, *Brit. Med. Jour.*, Dec. 8, 1877, p. 812; Baxter, *ibid.*, 1879, ii., pp. 79 and 119 (an important paper); Jamieson, *Edinburgh Med. Jour.*, Apr., 1880, p. 879; Duhring, *Philada. Med. Times*, Jan. 17, 1880; Pye-Smith, *Guy's Hosp. Repts.*, vol. xxv., 1881, p. 27; Hyde, *Chicago Med. Jour. and Examiner*, Feb., 1881; Brocq, "Étude critique et clinique sur la dermatite exfoliatrice généralisée," *Thèse de Paris*, 1882; abstract in *Annales*, 1883, p. 90 (an important paper), and (pityriasis rubra) *Archives Géneral de Méd.*, 1884, p. 550; Vidal (histology), *Bull. de la Soc. Méd. des Hôpitaux de Paris*, 1882, p. 101; Mackenzie, *Brit. Jour. Derm.*, 1889, p. 285 (an important paper—an analytic study of 21 cases); Besnier (érythrodermie) in French translation of Kaposi's treatise by Besnier and Doyon; Elsenberg, *Archiv*, 1887, p. 727; Leviseur, *Jour. Cutan. Dis.*, 1890, p. 482; Handford (with pigmentation), *Brit. Jour. Derm.*, 1894, p. 241; discussion (Petrini, Crocker, Jamieson, Brocq, Unna, Vidal, Schwimmer, Kaposi, Hebra, Jr., Besnier), "Congrès Internat. de Derm. et de Syph.," 1889, *Comptes Rendus*, Paris, 1890, pp. 43 to 80; Jadassohn, *Ueber die Pityriasis Rubra* (*Hebra*), Vienna and Leipzig, 1882, and in *Archiv*, 1891, p. 941, 1892, pp. 85, 271, 462 (an exhaustive histologic and pathologic study); Leloir and Vidal, *Traité des Mal. de la Peau*, 1889; W. G. Smith, *Brit. Jour. Derm.*, 1898, p. 437 (a succinct presentation of the subject, with a report of 2 cases), and discussion (Payne, Galloway, Colcott Fox, Crocker, Mackenzie, Pringle, Leslie Roberts, Whitfield, Malcolm Morris, and others), *ibid.*, pp. 447 to 464; Morrow (fatal in six weeks, with abscess formations), *Jour. Cutan. Dis.*, 1898, p. 541; *ibid.*, 1887, p. 439 (from psoriasis, and with pustular lesions—with discussion); Diehl (following typhoid fever), *ibid.*, p. 222; Coleman, *Dublin Jour. of Med. Sci.*, January, 1898; Pringle, *Brit. Jour. Derm.*, 1899, p. 27; Burnside Foster, *Jour. Cutan. Dis.*, April, 1907, p. 164 (13 cases—various types).

symptoms may or may not continue. The skin is noted to be hyperemic and red, with at first usually slight and sometimes scarcely perceptible inflammatory infiltration; later it may become more pronounced, and occasionally quite marked. After a short period—several days to a week or more—the characteristic exfoliative feature presents, the exfoliation taking place as thin, variously sized flakes or as slightly thickened imbricated scales. As a rule, however, the scales are thin, and usually of a dirty gray or brownish tinge; the underlying skin is smooth, red, and shiny, and later has a yellowish cast. The process thus instituted continues, the formation of new scales going almost hand in hand with exfoliation of the older. There are at times in some cases hyperesthesia of the skin and a feeling of coldness. If the dermatic condition is of an acute type, there may be accompanying febrile action, with evening exacerbation. After a variable time—several weeks to a few months—the process begins to abate, the skin loses its inflammatory aspect, is less red, and the exfoliation is less marked and less rapid. Finally, the symptoms all decline, and the malady comes to an end, complete recovery taking place. In other cases there may be a remission for a short time, and then a fresh exacerbation, after which, or after two or three such remissions, recovery ensues. In other instances the disease continues, either with or without short or long remissions, or short intermissions almost indefinitely. In many of the cases of primary dermatitis exfoliativa recovery has usually ensued after several months, and the patient remains free for a variable time—months, a few years or longer—and then has another attack. In some instances, however, but probably somewhat exceptional, recovery when once established is lasting.

In the persistent cases the patient's health usually begins to suffer, and arthritic symptoms and internal and other complications may arise. In these chronic and severe cases, too, the process often invades the mucous membrane of the mouth, of the nose and conjunctiva, and may also include that of the stomach and bronchial tubes; a cachectic condition may develop. Furuncles and abscesses are sometimes superadded. The hairs and nails are, more especially in severe continuous cases, involved and may be lost, and the skin becomes atrophic, tight, and limits the movements of the joints—**pityriasis rubra** (Hebra). This type is extremely rare.[1]

In cases evolving from psoriasis or eczema these diseases gradually, usually after repeated or long-continued attacks, lose their special characters, the surface, commonly in its whole extent, becomes invaded, and there then presents the ordinary picture of an exfoliating dermatitis, in some instances with slightly more infiltration than usually observed in cases of primary dermatitis exfoliativa.

While the typical disease is almost always erythematous in origin,

[1] E. J. Stout, *Philada. Polyclinic*, Nov. 2, 1895, has reported a case of this type in which there were permanent flexion of the finger-joints, nail involvement, with also some suppurating lymphatic glands. Bowen, *St. Paul Med. Jour.*, Feb., 1900, also recorded a severe and persistent example of the Hebra type; this case since died of gradual exhaustion (see Bowen's paper on the "Four Forms of Generalized Exfoliative Dermatitis (Erythrodermies exfoliantes generalisées, Besnier)," *Jour. Cutan. Dis.*, 1902, p. 548); F. H. Montgomery and Bassoe have also recently (*Jour. Cutan. Dis.*, 1906, p. 298) reported a case with histological and autopsy findings; Gilchrist, *Brit. Med. Jour.*, Oct. 6, 1906, has reported a case followed by peripheral gangrene of the right hand and left foot.

exceptionally cases have been noted in which there was some vesiculation in the early stage. Rarely, too, considerable fluid exudation (Devergie) or a slight serous undermining has been recorded, but such cases doubtless belong more properly to the province of pemphigus foliaceus.

The primary cases, as can be inferred, are of various grades of severity; in rare instances of the markedly acute and hasty type, grave symptoms of a septic character are present, and death ensues in the course of a few weeks. On the other hand, and probably in a majority of the cases, the disease may persist for a long time or often recur without presenting any symptoms of an alarming character, and

FIG. 34.—Dermatitis exfoliativa, showing the close relationship in its mildest phase, as in this case, to erythema scarlatinoides. Patient a working-man aged twenty-five. Four attacks in two years; practically limited to the hands, feet, and immediately adjacent parts of the forearms and legs. Begins with burning sensation, moderate redness, and slight swelling (this last not seen in erythema scarlatinoides), coming on suddenly; these symptoms soon subside, and desquamation, in somewhat thick, lamellar form, and sometimes in mass, as in the illustration, gradually presents. No constitutional symptoms. An attack runs its course in about three weeks. There was a suspicion in this case of drug ingestion (quinin) being the etiologic factor, suggested by its limited localization to the parts named, but an investigation as to the facts of the several attacks did not confirm this.

in some exceptional cases, instead of being extensive, it may be, as already remarked, somewhat limited in extent, occasionally to the hands and feet. Swellings of the superficial lymphatic glands have been noted (Jadassohn) in some instances. In fact, as late analytic papers (Brocq, W. G. Smith) show, the disease presents itself in various types as to extent and severity; the cases varying (Smith) from local forms to the completely generalized, and from the ill-defined to the most typical. More or less pigmentation is noted in the recurrent and chronic cases.

The subjective symptom of itching is present to a variable degree

in almost all cases of dermatitis exfoliativa, sometimes slight, sometimes intense; a feeling of tension and soreness or tenderness are also frequently complained of.

Etiology.—The disease is, as it is ordinarily met with, not contagious, but the infantile and epidemic varieties, which are probably totally distinct morbid entities, and elsewhere separately considered, are doubtless of infectious nature. The apparent etiologic or predisposing factors are varied, and it must be conceded that the essential cause remains practically unknown. Although clinically similar in their chief external symptoms, there are doubtless several processes etiologically considered, some of which may be accepted as of septic and parasitic origin. The malady has been often noted to occur in gouty and rheumatic subjects (Duckworth, Mackenzie, Crocker, and others), and has also been seen frequently in association with tuberculosis (Jadassohn), and in a few instances has been observed to follow excessive alcoholism. Central or peripheral nerve changes, sometimes noted, are suggested as having a causative relationship. On the other hand, in some cases the patients, both preceding and at the time of the attack, have been in fair health. As has been already stated, it sometimes develops from a preexisting psoriasis or squamous eczema. Local irritation from a drug, especially chrysarobin, arnica, mercury, and iodoform, has been known to provoke an outbreak in some instances; and it is probable, too, that the ingestion of certain drugs, notably quinin, is responsible for some of the obscure and acute attacks.

It is, fortunately, a rare disease, and observed most frequently in those between the ages of twenty-five and sixty, and preponderantly in males.

Pathology.—In the ordinary types of dermatitis exfoliativa various findings are recorded (Baxter, Crocker, Vidal, Jadassohn, and others), dependent upon the character, severity, and persistence of the disease—from a purely hyperemic condition, almost or wholly similar to that of erythema scarlatinoides, to that in which considerable inflammatory and atrophic changes occur. There would, indeed, seem to be a very close relationship between the mild acute dermatitis exfoliativa and erythema scarlatinoides.

In the extreme varieties there is a complete obliteration of the papillæ, with variable atrophy of the interpapillary rete prolongations. The glandular structures disappear, in part or wholly, and pigment-granule deposit is noted in the lower epiderm, partly replacing the rete layer. There is also sometimes noted thickening of the blood-vessel walls in the subpapillary plexus, and both the rete and corneous layer may be thickened, the latter irregularly, and exhibiting imperfect keratinization. Tuberculosis of internal organs has been found in a number of cases of the severe—pityriasis rubra (Hebra) type.[1] Myelitis (Jamieson) and peripheral and central inflammatory

[1] Bruunsgaard ("Beitrag zu den tuberkulösen Hauteruptionen. Erythrodermie exfoliativa universalis tuberculosa," *Archiv*, vol. lxvii., 1903, p. 226) reports a fatal case with cutaneous symptoms somewhat similar to the Hebra type, but more inflammatory, in which tubercles were found in the papillary and subpapillary layers of the skin and around the hair follicles; bacilli were found in the lymph glands, and, apparently, it was primarily a tuberculosis of these glands, from which emboli of bacilli were carried to the skin, producing the cutaneous inflammatory symptoms.

PLATE IV.

Dermatitis exfoliativa in a male adult of forty years, of eight months' duration, following upon a moderately extensive psoriasis of ten years' standing. With the exception of some small areas on the legs and a part of the neck, the entire surface, including the face, was involved, with slight infiltration of the skin, and in a continuous state of exfoliation.

nerve changes (Quinquaud and Lancereaux) have been recorded in a few instances.

Diagnosis.—In the beginning of the process in average cases there may be some difficulty, but a few days' observation will usually leave no doubt as to its nature. The exfoliative symptom, ordinarily without systemic symptoms or throat involvement, will serve to differentiate it from scarlet fever and from erythema scarlatinoides. In its early stage, however, in mild cases, confusion with this latter malady is possible, and in such cases, for a time at least, the disease seems to be almost analogous. Erythema scarlatinoides is markedly acute in character, the skin does not show the slightest or perceptible infiltration; there may be constitutional symptoms; and, finally, its course is relatively short, and the exfoliation frequently occurs in large, thin lamellæ and sheets. The absence of blebs as a feature will also be an important point of difference from pemphigus foliaceus. Psoriasis and lichen ruber, which are also dry scaly diseases, are rarely, if ever, universal, the skin is more thickened, and in the former the scaliness is more abundant; the beginning papular character of the latter, and the presence of typical papules here and there at the borders of areas, even when the disease is extensive, are sufficient to prevent error. Psoriasis may, however, as already stated, develop into a true dermatitis exfoliativa, although such termination is rare. In a generalized squamous eczema there will always be found some areas in which the characteristic gummy oozing of that disease is present; or a history of such is obtainable. Moreover, in eczema there is usually considerable thickening and never a tendency to thinning and atrophy.

Prognosis and Treatment.—The prognosis can be inferred from the remarks made in describing the disease. Ordinary idiopathic cases with no constitutional involvement usually recover, although some of these may succumb in future attacks. Cases with septic indications are grave, and end, as a rule, fatally. The cases following on psoriasis and eczema are persistent.

Often the disease seems to have a set course, and to be uninfluenced by treatment. The constitutional treatment aims at removing any possible etiologic factor, improving the tone of the general health, looking after the digestion, and a regulation of the bowel movements. Pilocarpin, carbolic acid, quinin, and arsenic are remedies which have been variously advocated, but the effect is usually doubtful, and their use requires proper caution. Sodium salicylate and arsenic are probably most frequently of benefit. In severe cases special efforts should be made to sustain the strength.

The external treatment is necessary in all cases to relieve the irritation; beyond this its effect is questionable. Strong applications are not only valueless, but are almost invariably damaging. Plain petrolatum, with or without $1\frac{1}{2}$ to 4 grains (0.1 to 0.25) of carbolic acid to the ounce (32.), is usually the most comforting application. In some cases a cooling salve, as cold cream, is more grateful. Linimentum calcis is also of service. The following mild ointment often gives considerable relief:

℞.	Acid. borici,	gr. xv (1.);
	Acid. carbolici,	gr. ij–iv (0.135–0.25);
	Pulv. amyli,	ʒss (2.);
	Petrolati,	℥j (32.).

Bran, gelatin, and starch baths are often of benefit, but should usually be followed by an oily or ointment application. Other mild ointments and lotions, and sometimes dusting-powders, such as prescribed in acute eczema, are also variously employed and prove soothing.

DERMATITIS EXFOLIATIVA EPIDEMICA.

Synonyms.—Epidemic skin disease; Epidemic eczema; Dermatitis epidemica; Savill's disease.

Under the name of epidemic skin disease Savill first described (1891) a disease observed in London institutions presenting essentially the symptoms of dermatitis exfoliativa, with, in some cases, an eczematous aspect.[1] Since then others have observed and reported similar cases (Hutchinson, Lees, Richards, Milner, and others). Unlike dermatitis exfoliativa, however, it was observed to attack a number of individuals simultaneously, or one rapidly after the other, and with fatal issue in 10 to 20 per cent. of the cases. Those of advancing age are its chief subjects, and more commonly males. In this country but a few cases are recorded (Fordyce, Colby and Winfield). The malady begins generally in summer weather, and in most cases without premonitory symptoms. In others anorexia, vomiting, diarrhea, and sore throat were observed. It first appears usually as patchy erythematous or papular, bright or crimson red, efflorescences, and, as a rule, on several regions and with slight itching. Sometimes vesiculation is noted. The legs show less tendency to primary invasion than other parts, the principal first sites being the face, scalp, and arms. Very soon, from the confluence of the beginning and constantly arising new patches, more or less extensive involvement results. In those cases, with vesicular lesions, owing to their rupture, a moist surface is seen at first; it rarely persists, but gives place to scaliness. There is noted some infiltration, and, in all cases, exfoliation rapidly results, and this stage—exfoliating—lasts a variable time—on the average, about five or six weeks. The scales, differing as to size, are rapidly formed and are produced in great quantities. The cervical and postoccipital lymphatic glands are frequently enlarged, and independently of face or scalp eruption. The redness begins to subside, the infiltration still persisting; the skin assumes a shining brownish appearance. Improvement takes place slowly, and in many cases there are several relapses before recovery is complete and permanent. In almost all cases conjunctivitis is observed. The

[1] Literature: Savill, *Brit. Jour. Derm.*, 1892, pp. 35 and 69 (with colored plate and several phototypes); *Brit. Med. Jour.*, Dec. 5, 1891, and Jan. 9, 1892; with discussion in Medical Society of London, *Brit. Med. Jour.*, Dec. 5, 1891, p. 1207; *Jour. Cutan. Dis.*, 1894, pp. 281 and 329; Russell (bacteriology), *Brit. Jour. Derm.*, 1892, p. 106; Fordyce, Soc'y Trans., *Jour. Cutan. Dis.*, 1897, p. 141; Colby and Winfield, *ibid.*, 1898, p. 73; Hutchinson, *Arch. of Surgery*, 1891–92, pp. 146 and 221; Echeverria (histology), *Brit. Jour. Derm.*, 1895, p. 9. A monograph on the disease by Savill, London, 1892, is complete, with a number of illustrations.

hairs and nails fall out, and, although a regrowth takes place, it is slow. Itching, sometimes slight, sometimes intense, is present.

When the disease is completely established, general symptoms of malaise, anorexia, and prostration, and in many albuminuria, are noted; in some instances which are complicated by furuncular development, there is some temperature elevation. Diarrhea is often associated. In unfavorable cases tremor, muscular twitching, labored respiration, intestinal disturbance, pulmonary complication, cardiac weakness, and, in some cases, marasmus, lead to a fatal issue.

Russell and Savill found a diplococcus, in rod-like segments, resembling the staphylococcus, but differing from the latter in the above particular and by the fact that it does not liquefy gelatin. Experimental animal inoculations seem to bear out its pathogenic importance. The food and the milk supply were suspected as being the possible source, but nothing definite could be demonstrated. Anatomically, according to Savill, engorgement of the vessels and extravasation of leukocytes in the corium, serous effusion, etc., were to be noted. Echeverria found "a remarkable and new sort of degeneration of the nuclei of the prickle layer of the epidermis—viz., the peridiaphania of the nuclei."

Treatment consists of mild applications, such as prescribed in acute eczema, but seems to have but little influence in shortening the course of the disease. In a few instances in which the disease began as a small area, painting it over with iodin tincture or collodion aborted it (Crocker).

DERMATITIS EXFOLIATIVA NEONATORUM.[1]

Synonyms.—Ritter's disease; Dermatitis exfoliativa infantum; Keratolysis neonatorum.

Under this name Ritter first (1878) thoroughly described a disease occurring in the new-born in which the cutaneous symptoms were closely similar to those of dermatitis exfoliativa in older patients, with now and then a case presenting some analogy to pemphigus foliaceus. Since then cases have been recorded by other observers (Caspary, Boeck, Elliot, and others), although the disease is a rare one. According to Ritter and others, the disease usually begins between the second and the fifth week; the symptoms vary somewhat, although there is always the essential character, sometimes at the beginning or at other times later, of thin epidermic exfoliation, leaving here and there, or in the grave cases more or less generally, the red exposed rete or corium, and occasionally in parts presenting a distinctly moist surface. In other instances there is displayed a tendency to scattered vesicobullous formation or serous undermining, with exfoliation,

[1] Literature: Ritter, *Central-Zeitung für Kinderheilkunde*, Oct. 1, 1878; *Archiv*, 1879, p. 129; *Archiv für Kinderheilkunde*, 1880, p. 53; Boeck (described as pemphigus foliaceus), *Archiv*, 1878, p. 17; Bohn, in Gerhardt's *Handbuch der Kinderheilkunde*; Caspary, *Archiv*, 1884, p. 122; Elliot, *Amer. Jour. Med. Sci.*, Jan., 1888, p. 1 (a good review of the subject, with references); Dorland, *Philada. Polyclinic*, 1896, p. 385; Escherich, *Verhandlungen der Deutschen dermatolog. Gesellschaft*, V. Congress, 1896, p. 65; Pagliari, *La Pediatra*, Nov., 1897, p. 317—abstract in *Annales*, 1898, p. 820; Winternitz, *Archiv*, 1898, vol. xliv., p. 397; Luithlen, *ibid.*, vol. xlvii., 1899, p. 323; Patek, *Jour. Cutan. Dis.*, 1904, p. 269.

the former being more properly cases of this disease, some of the latter probably related to or examples of pemphigus neonatorum.[1] It frequently begins in one region, often about the chin, and is then followed by general involvement. Buccal, nasal, and conjunctival mucous membranes show invasion, and at the juncture with the integument at the commissures show slight crusting and fissuring. The eruption usually appears without systemic symptoms. In some patients the body-temperature tends below the normal, and marasmic symptoms supervene and death frequently results. On the other hand, after persisting one to three weeks or longer, recovery ensues. Suppurative processes—furunculous and phlegmonous in character—have been noted as sequelæ (Ritter). A single case has come under my observation, in which the malady presented, a week or so after birth, with a reddening of the skin and more or less general exfoliation, with here and there a tendency to slight serous exudation; the temperature was a trifle below the normal; the infant presented a marasmic appearance, but finally, after two or three weeks, recovered. The eruption began in the flexures, especially about the genitocrural region.

The nature of the disease remains still obscure. The process has been variously regarded as a dermatitis of pyemic origin (Ritter); as an epidermolysis (Caspary), with consecutive hyperemia of the cutis; as a peculiar pemphigoid eruption (Behrend, Brocq); as a dermatitis due to a fungus found (Riehl[2]) in one or two instances; and as merely an exaggeration of the physiologic epidermic desquamation noted in the new-born (Kaposi). In one instance Winternitz found the staphylococcus pyogenes aureus and albus in the blood. Its occurrence in institutions, notably in Ritter's cases, suggests that the disease is contagious or infectious. The view sometimes expressed that it is a sequence of some form of intra-uterine exanthem is negatived by those cases in which the eruption has not presented until four or five weeks after birth. The pathologic anatomy has been investigated by Winternitz and Luithlen, but the conditions found are not especially different from the average cases of dermatitis exfoliativa, except that there is usually more serous exudate. The principal conditions noted are: Hyperemia of the skin and other signs of inflammation; dilatation of the vessels; edema, etc.

Prognosis and Treatment.—The prognosis is always grave, a fatality of about 50 per cent. being recorded. In Ritter's 297 cases 150 recovered, 145 died, the remaining 2 were still under observation at the time of his report. The loss of body-heat, the gravity of the attack, marasmus, and secondary septicemia are factors in various cases directly responsible for the fatal issue. Treatment consists in sustaining the strength of the patient by appropriate means, the character of the nourishment receiving special attention; the child should have its natural nourishment—recovery is scarcely to be expected unless this is possible. The maintenance of the body-heat is likewise

[1] Behrend's 7 cases (*Archiv*, 1879, p. 193) and Spencer's 25 cases (*Australas. Med. Gaz.*, Jan. 20, 1899) are, I believe, to be classed among the pemphigoid eruptions, and are distinct from dermatitis exfoliativa neonatorum.

[2] Riehl, cited by Elliot, Morrow's *System*, vol. iii. (Dermatology), p. 321.

of essential importance. For this and other purposes fats or oils should be freely used externally, medicated with 0.5 to 1 per cent. of boric acid or ichthyol, and the patient wrapped in cotton wadding. The crusts at the corners of the mouth, when present, should be frequently anointed with olive or almond oil, and softened and gently removed, as their presence, together with the resulting fissuring, restrains the child from taking sufficient nourishment.

PRURIGO.

Synonyms.—Fr., Strophulus prurigineux ; *Ger.*, Juckblattern.

Definition.—Prurigo is a rare chronic, inflammatory disease, beginning in early life, characterized by discrete, pin-head to small pea-sized, solid, firmly seated, slightly raised, pale-red papules, usually appearing primarily on the tibial surfaces, and accompanied by intense itching and more or less general thickening of the affected skin.

Symptoms.—There are two varieties usually described, prurigo mitis and prurigo ferox (also called prurigo agria), which, however, really represent respectively the mild and severe types of the disease. In many cases there is a preliminary stage of some months in which itchiness and the typical wheals and papules (urticaria papulosa) of urticaria appear from time to time or more or less continuously ; and for some time after the typical lesions of prurigo have appeared, wheals may now and then be seen. The disease proper begins with the appearance of pin-head-sized papules, which may be pale red in color, or even the same color as the skin. They appear almost invariably over the anterior aspects of the legs below the knees, and at first they can scarcely be seen, but can be felt by passing the hand over the surface. Itchiness of the parts usually first attracts attention. Later, from natural growth and from scratching, the lesions are noted to be somewhat larger and pale red or red in color, and some or many covered with minute blood-crusts. They may be in moderate quantity or exceedingly numerous and rather thickly set, but there is no tendency to grouping. At the same time or later lesions present themselves on the extensor surfaces of the forearms, and gradually or rapidly upon other parts. In mild cases the flexor surfaces are scarcely affected, and even in severe type the flexures of the joints, such as the poplitea, axilla, etc., and the palms remain free from papules. In severe cases the eruption may be more or less general, and the face also show some involvement ; the scalp is usually free, but the skin is dry and the hair lusterless. The disease is most marked on the extremities, and more especially on the lower half ; and the upper extremities less severely than the lower. The buttocks and trunk also show decided involvement in severe cases. The skin becomes dry, on the worse parts thickened and hard and rough, and exhibits branny scaliness ; the hairs are rubbed off or broken ; and the perspiration is practically suspended. The color is a pale red to a red. The superficial lymphatic glands, especially the inguinal, show enlargement, sometimes of a pronounced character. From the intense itching, excoriations and long and deep scratch-marks, with resulting slight scars, are produced, and from the long-continued irritation pigmentation results. In extreme, neglected cases it is not uncommon to see impetiginous

and ecthymatous lesions interspersed; distinct eczematous conditions are at times superadded. New crops of papules may appear from time to time, and the subjective symptoms at such periods become still more intense. In some instances (prurigo mitis) the disease is much less pronounced, and consists of scattered, deep-seated papules, chiefly over the extensor surfaces of the limbs, especially the lower; and in these cases the mild aspect continues throughout. In fact, usually the type, as regards severity, is established from the start, although neglect, poor food, and bad hygiene, lead to aggravation. As a rule, the disease is worse during the cold season.

Etiology.—The disease usually has its beginning in the first few years of life. It is by far most common in Austria and Hungary, among the poorer classes, and it is relatively more frequent in the Hebrew race and in males. Mild types are sometimes seen elsewhere. It is extremely rare in this country, and when observed is usually in immigrant subjects, as in the cases reported by Wigglesworth,[1] Campbell,[2] Zeisler,[3] and Taylor.[4] It is, in its milder types, less rare in England. Occasionally chronic papular eczema cases closely resembling the mild varieties are observed. It is not contagious, and heredity does not seem to be a factor. It develops, as a rule, in those in poor general health. Neglect, lack of proper food, and bad hygiene are apparently influential. Climatic conditions may also be in a measure etiologic. The essential cause, whether neurotic, toxemic, or parasitic, is not known; the neurotic view predominates.

Pathology.—The true nature of prurigo remains obscure. There is still much divergent opinion, on reviewing which J. C. White[5] expressed the following conclusion: One cannot go further than accept the existence of a condition of early childhood, allied to pruritus and urticaria in its visible manifestations, and not to be positively distinguished from them in its first stages, often becoming in certain parts of the world a chronic affection due to some inexplicable national cutaneous traits or inherent customs of living, a condition which certainly lacks many of the essential elements of individuality.

The pathologic changes[6] are such as are met with in chronic hyperplasias, such as eczema, and anatomically the process scarcely admits of differentiation. The essential lesion—the papule—which, according to investigation by several pathologists, has its origin in the rete, is of a minute cystic character, and contains a clear fluid and some epithelia; its upper covering is the entire corneous layer, which is undisturbed, except secondarily. It is thought to have some connection with the sweat-gland duct. Apparently there are no changes in the peripheral nerves.

[1] Wigglesworth, *Amer. Jour. Syph. and Derm.*, 1873, p. 1 (patient of American parentage).

[2] Campbell, *Arch. Derm.*, 1878, p. 119 (patient native born but of German parentage).

[3] Zeisler, *Jour. Cutan. Dis.*, 1889, p. 408 (12 cases—only 1 of American parentage, although several born in this country).

[4] Taylor and Van Gieson, *New York Med. Jour.*, vol. liii., 1891, p. 1; Dade, *Jour. Cutan. Dis.*, 1902, p. 569 (also a case, in a child of foreign parentage).

[5] J. C. White, "Prurigo," *Jour. Cutan. Dis.*, 1897, p. 2 (with many cited opinions and literature references).

[6] Van Gieson, in Taylor and van Gieson's paper, *loc. cit.*, gives a good résumé of the histology, with numerous illustrations and references; also Holder, *Trans. Amer. Derm. Assoc. for 1901.*

Diagnosis.—A typical example of prurigo scarcely admits of error: the poor general health, its early beginning, long duration, the dry, harsh, hard, and thickened skin, especially over the extensor surfaces, the freedom of the flexures of the joints, the peculiar, scarcely elevated papules, the intense itching, with the consequent excoriation, and the enlarged inguinal glands, are characteristic. The milder cases possess the same features, but much less marked, and closely resemble papular eczema. It is to be noted that in neglected cases eczematous symptoms are added; but treatment will soon remove these, and the character of the true disease be disclosed. A careless examination might lead to a confusion with a long-continued pediculosis or scabies.

Prognosis and Treatment.—The severe cases are practically hopeless as to permanent relief, although much can be done in every case toward palliation. Under favorable circumstances and the institution of early treatment the milder cases admit of cure, but even in these latter recurrences are often observed. The imported cases in this country usually show, after a time, marked amelioration and even complete disappearance—resulting from the better food and more comfortable and hygienic mode of living.

Both constitutional and local measures are required in the management of the disease. The systemic treatment aims to put the patient in a thoroughly healthy state, with attention to hygiene, and with usually such remedies as cod-liver oil and iron, manganese, and a generous dietary. Carbolic acid, pilocarpin (hypodermically administered), and thyroid extract have their advocates; arsenic seems without influence.

The external treatment, which is of essential importance, consists of frequent warm to hot plain or alkaline baths, tar-baths, baths of potassium sulphid, followed by an oily application. A β-naphthol ointment—in children, of 2 per cent. strength, and in adults, of 5 per cent.—rubbing it in every night, is highly extolled by Kaposi, and is the favorite method in Vienna; every second day a prolonged bath in warm water with naphthol-sulphur soap is taken. The frequent use of sapo viridis, or its tincture, with baths, is also valuable in older subjects, followed by emollient ointments. Strong salicylic acid ointments, from 20 to 60 grains (1.3 to 3.) to the ounce, are also useful in some cases. In cases in which marked eczematous eruption has been added, mild applications are at first demanded.[1]

[1] Under the name of **a papular persistent dermatosis** Johnston, *Jour. Cutan. Dis.*, 1899, p. 49 (with case illustration and histologic cuts) has described an instance of an eruption in a woman aged fifty-two, of ten years' duration, most marked on the extensor surface of the hands and forearms, tibial surfaces, dorsum of the foot, and the face, and which presented, to a slight degree, some of the aspects of prurigo. The eruption consisted of rounded, somewhat hard, rose-red to grayish, pin-head to large pea-sized, itchy papular-looking lesions, some close together, but not grouped, others more or less scattered, beginning somewhat deeply, and only involving the epidermis after considerable length of time. While apparently papules, puncture with a needle and histologic examination showed the eruptive elements to be vesicopapules, a tiny vesicle being contained somewhat deeply in the central apical portion. Histologically, the whole corium was affected by an inflammatory process, a special and peculiar feature consisting of its involvement of the medullated nerve-trunks of the reticular layer; secondarily, there were great increase of the horny layer, and formation near the center of the papule of a vesicle resulting from degeneration of the prickle-cells.

LICHEN PLANUS.

Synonyms.—Lichen ruber planus ; Lichen psoriasis.

Definition.—An inflammatory disease characterized by pin-head to small pea-sized flattened, glistening, crimson or violaceous papules, with often a slight central depression, and often an irregular or angular base ; tending to coalescence and the formation of areas with a roughened or scaly surface.

Symptoms.—The disease, first clearly described by Wilson,[1] is in the larger number of cases somewhat limited, but it may be more

FIG. 35.—Lichen planus of moderate development, in a woman aged twenty-five, and of several months' duration. Practically limited to the arms and mainly on flexor aspects.

or less widely distributed over the entire surface. The favorite sites in the former are about the flexor aspects of the wrists and forearms and the lower part of the leg. The limited form of the disease usually begins insidiously. The lesions at first are discrete, scattered, bright or dark red in appearance, slightly elevated, with a flattened, shining, or glistening top, in the central part of which there is usually a minute depression. The base may be rounded ; but more frequently it is irregularly quadrangular or angular, usually with perpendicular sides ; exceptionally minute stellate projections are noted at the base. In size they are generally a trifle larger than a pin-head. In larger lesions, if present, there may be, more especially after they have existed for some time, a wider depression centrally, resulting in a slightly ringed formation ; or occasionally new lesions spring up contiguous to the border, while the central part flattens down and partially or completely disappears. In occasional instances this ring-like tendency (**annular lichen planus**) in several or more of the lesions or

[1] E. Wilson reported a large number of cases in *Jour. Cutan. Med.*, London, vol. iii., No. 10, 1869.

patches may be quite pronounced.[1] Sometimes several lesions will arrange themselves as a straight or irregular line. Excoriations and scratch-marks are apt to show a development of the efflorescences. Lesions continue to arise, in the average case, close to others, and several or more coalesce, and solid patches of various sizes result; the surface of these is noted to be rough or slightly scaly. The scaliness is generally insignificant or branny, usually quite adherent, but rarely marked. The lesions and areas are now, as a rule, noted to be of a purplish color, which is quite characteristic. Some may disappear, leaving considerable pigmentation, which is slow in fading. In exceptional instances slight atrophy may occur in places.[2] Although some of the lesions and areas may tend to disappear, the eruption is, as a

FIG. 36.—Lichen planus—hypertrophic papules.

[1] In this connection reference may be made to an apparently independent malady, having some points of resemblance to annular lichen planus, lupus erythematosus, and erythema elevatum diutinum, reported by Galloway (*Brit. Jour. Derm.*, 1899, p. 223, with colored plate case illustration and histologic cuts), under the name of "**lichen annularis, a ringed eruption of the extremities.**" The lesion consists of a pale, ivory-like, elevated band showing circinate outlines, and occurring in the neighborhood of the joints of the backs of the hands. The border itself is raised perhaps one or two millimeters above the surrounding skin, and is about three millimeters in breadth. It is smooth, and does not present evidences of increased epithelium nor of papillomatous surface. It is not reddened, but yet has the aspect of a deep-seated infiltration of the cutis. The inclosed skin of the area looked normal, although it had been affected in a similar manner to the part forming the raised border; on close inspection with the lens, however, the inclosed skin is noted to be distinctly altered, the normal wrinkles not being so obvious, and slight signs of atrophy being present. The lesions commenced as small papules or nodules in the center of the areas now affected, and have advanced by peripheral increase, the borders always presenting a peculiarly indurated character. There were no subjective symptoms. It was of three years' duration. According to the histologic examination, the process is an inflammatory one, consisting chiefly of cell infiltration of the type seen in certain chronic inflammatory processes in the cutis, especially the lichen group, the upper part being more especially involved. Other or allied cases in literature are reviewed. Treatment with cod-liver oil and iron internally and a 2 to 10 per cent. salicylic acid ointment externally had, up to the time of the report, brought about almost complete disappearance.

[2] See interesting paper on the variant forms, etc., by Crocker (Lichen Planus: Its Variations, Relations, and Limitations), with discussion, *Brit. Jour. Derm.*, 1900, p. 421; also Engman's report, "Annular Lichen Planus," *Jour. Cutan. Dis.*, May, 1901; Lieberthal, "Lichen Planus Hypertrophicus," *Jour. Amer. Med. Assoc.*, Jan. 11, 1902.

rule, persistent, new efflorescences appearing from time to time. The disease may thus remain upon the affected region, more particularly the lower legs, and continue indefinitely, with but slight variation.

In this region, too, and occasionally elsewhere,—more especially the forearms,—the lesions are sometimes much larger. They are from a small to a large pea in size, with rounded or lenticular base, and flattened or slightly conic in shape, dark red, brownish, or purplish in color, with flattening of the summit or of the entire lesion; the surface somewhat rough and branny or smooth (**lichen obtusus; lichen planus hypertrophicus**). Exceptionally the lesions may be waxy in appearance. They may coalesce and form large areas, as with the smaller papules; the central part of the patches may persist, or it may disappear and show staining and, exceptionally, atrophy. Occasionally the confluent plaques, especially about or near the ankle, are markedly thickened, sometimes quite dark in color, hard, rough, and wart-like—**lichen planus verrucosus.**

The more or less generalized form of the malady may begin as such or develop from the limited form. The lesions usually appear more or less rapidly, are at first rather pale red than deep red; some are waxy and semitranslucent, and conic and rounded in shape, and may or may not have the central depression. Many, and sometimes all, the lesions are, however, similar to those described in the limited form—angular, flat, dark red, and umbilicated. They are apt to appear, first, or most numerously, on the trunk, but the extremities are also invaded, and sometimes markedly. Sooner or later the color becomes dark red or violaceous. There is the same tendency toward close aggregation and coalescence here and there, with the resulting solid patch, a trifle rough and scaly. Exceptionally in some regions the lesions appear close together, forming narrow, bead-like bands (so-called **lichen ruber moniliformis**). This formation is likewise seen in the limited form, and may constitute the major part of the eruption, as in cases reported by Kaposi, Dubreuilh, and G. H. Fox.

The deep-red or violaceous color of the papules is usually most marked on the lower parts of the legs. Single isolated papules are usually free from any attempt at scaliness; exceptionally, however, a minute, thin, filmy scale surmounts it. Minute whitish or grayish points and striæ, and sometimes minute red points, are not infrequently to be seen on the surface of the lesion, more particularly those of larger size, and especially where coalescence has taken place, the presence of which Wickham[1] considers pathognomonic of this disease. On the other hand, the shining or glazed appearance which may be readily seen when the lesions are looked at askant, is usually observable on all discrete lesions. While the eruption may be quite extensive and be distributed in smaller and larger plaques over the entire surface, it is never universal. Even in extreme cases there are always some, and usually many, free areas. It is, as a rule, more or less symmetric, although cases are met with in which the areas of disease may be on one side, and a few instances are on record in which it had a zoster-like distribution. The face is an uncommon site, even when the eruption is abundant. The palms and soles are rarely involved

[1] Wickham, *Annales*, 1895, p. 517.

In rare instances an abortive attempt at summit vesiculation has been recorded; and exceptionally, as in cases recorded by Unna,[1] Kaposi,[2] Leredde,[3] Mackenzie,[4] Hallopeau and Le Sourd,[5] Colcott Fox,[6] Allen,[7] Whitfield,[8] and Engman.[9] It has been quite generally considered that, in some of the cases at least, the vesicular and bullous lesions were probably due to the arsenic so commonly administered in this disease, but in Whitfield's review of 17 collected cases, in 9 of the patients this drug had not been taken.

The mucous membrane of the mouth is noted to be at times the seat of lesions (E. Wilson, Hutchinson, Crocker, and others), and sometimes it begins there primarily, as Thibiérge,[10] Crocker,[11] Petersen,[12] and others have shown. Indeed, Crocker states that he believes that if all cases were carefully examined as to this point it would be found not to be a very rare complication, and that occasionally it might be of diagnostic aid, as it sometimes procedes the skin eruption by some weeks. Hallopeau[13] records a case in which the eruption had been limited to the mouth for some time, without any signs upon the skin.[14]

In this region the disease consists of white or whitish dots or papules, plaques, or streaks, as a rule but slightly raised. It bears a strong resemblance, as Brocq[15] has pointed out, to the appearances produced by cauterization with silver nitrate. It is more commonly observed on the buccal membrane than on the tongue. As a rule, these lesions give rise to no discomfort; occasionally there is a feeling of slight soreness.

The glans penis has likewise been noted to be the seat of lesions, and sometimes before their appearance elsewhere, as recorded by Bulkley[16] and others. The eruption has also been observed (Crocker) on the inside and outside of the vulva. On the glans penis the lesions are either white, when the part is habitually covered by the prepuce, or of the usual color observed elsewhere when the glans is uncovered.

[1] Unna, *Medical Bulletin*, Philada., 1885, p. 145.
[2] Kaposi, *Archiv*, 1892, pp. 340, 342 and 344.
[3] Lerèdde, *Annales*, 1895, p. 637.
[4] Mackenzie, *Brit. Jour. Derm.*, 1899, p. 26.
[5] Hallopeau and Le Sourd, *Jour. mal. cutan.*, Nov., 1899 (vesicles—in palms).
[6] Colcott Fox, *Brit. Jour. Derm.*, 1895, p. 22.
[7] Allen, *Trans. Amer. Derm. Assoc. for 1901; Jour. Cutan. Dis.*, 1902, p. 260.
[8] Whitfield, *Brit. Jour. Derm.*, 1902, p. 161 (with case and histologic illustrations).
[9] Engman, *ibid.*, 1904, p. 207 (with case and histologic illustrations and bibliography).
[10] Thibiérge, "Des lésions de la muquese linguale dans le lichen planus," *Annales*, 1885, p. 65 (this contains a review of published cases).
[11] Crocker, "On affections of the Mucous Membranes in Lichen Ruber vel Planus," *Monatshefte*, vol. i., 1882, p. 161.
[12] Petersen, *St. Petersburg med. Wochenschr.*, 1899, p. 33 (brief case report). See also Touton's paper, "Casuistisches zum Lichen ruber planus der Haut und Schleimhaut," *Berlin. klin. Wochenschr.*, 1886, p. 374 (with references).
[13] Hallopeau, *Annales*, 1896, p. 1307.
[14] Other recent contributions on lichen planus of the mucous membranes are: Mewborn, *Jour. Cutan. Dis.*, 1905, p. 176 (case presentation). Among 10 unusual cases reported by Beltmann (*Archiv.*, vol. lxxv., p. 379) is one in which the only regions involved were the mouth and urethra; Vorner, *Dermatolog. Zeitschr.*, 1906, vol. xiii., p. 107, notes that umbilication may also be observed in these mucous membrane lesions; Dubrenilk ("Histologie du lichen plan des muquenses," *Annales*, 1906, p. 123) states that the lesions of the mucous membranes are histologically essentially the same as those of the skin); Lieberthal, "Lichen planus of the oral mucosa," *Jour. Amer. Med. Assoc.*, Feb. 16, 1907 (2 cases, with illustrations).
[15] Brocq, in *Twentieth Century Practice*, vol. v., p. 309.
[16] Bulkley, *Arch. Derm.*, 1881, p. 135.

The disease in children usually presents the same symptoms as when occurring in adults, but there is a type occurring in infants, described by Crocker[1] and Colcott Fox,[2] in which the eruption (quoting Crocker) comes out acutely in groups, each papule of which is sometimes acuminate at first, but the top seems to die down and a scale comes off, leaving a smooth, shining, angular papule, of a brighter red than usual, though it may get a purplish tint subsequently. Limbs, trunk, or both may be the seat of the eruption. There is considerable itching.

The course of lichen planus is in most cases slow, insidious, and chronic. In some instances, it is true, as already remarked, the outbreak may be extensive and somewhat rapid, but, as a rule, the eruption is slow in development, and in the majority of patients somewhat limited in extent. In many of the limited cases, after reaching a certain point, it may remain practically stationary for a long time, or there is retrogression of some lesions along with the appearance of new papules. Exceptionally, it tends after a time to disappear spontaneously, but, as a rule, it is persistent. There are rarely any general symptoms except in cases of acute outbreaks or exacerbations, and even then but slight and transitory. In more or less generalized cases a marasmic tendency has occasionally been recorded.

The subjective symptoms, consisting of burning and itching, but usually the latter, vary somewhat in different cases and often in the same case. Occasionally the itching is not troublesome or so slight as to give rise to no complaint; generally, however, it is an annoying symptom, and sometimes so intense as to deprive the patient of restful sleep.

Etiology.—The disease is not frequent. It is seen in both sexes, and most commonly during active adult life, being rare in children. It is most frequently observed in those of the neurotic class, after prolonged worry, overwork, anxiety, nervous shock, or exhaustion; and is met with relatively oftener in private than dispensary practice. In fact it would seem, in most cases at least, that the disease is the result of disturbance of the nervous system. This appears to have further support in the fact that it has occasionally been noted to follow nerve distribution and also nerve injuries. It, however, occurs in those apparently well nourished as well as in those showing malnutrition.

Almost all authors of note recognize its frequency among the nervously depressed and exhausted. Duhring[3] holds strongly to this view, stating that, according to his experience, patients are generally found to be suffering from debility arising from improper nourishment, overwork, nervous depression, and similar conditions, and that nervous symptoms are often prominent. I have myself long had under observation 2 cases (women) who have had recurrences when worn out with prolonged winter social exactions.

According to Crocker and Colcott Fox, the infantile cases seem, for the most part, to occur in those whose vitality has been weakened by constitutional taint, such as scrofula, syphilis, and the like.

[1] Crocker, *Diseases of the Skin*, first edit., 1888, p. 215; second edit., 1893, p. 302.

[2] Colcott Fox, "Notes on Lichen Planus in Infants," *Brit. Jour. Derm.*, 1891, p. 201 (7 cases).

[3] Duhring, *Diseases of the Skin*, third edit., 1882, p. 259.

Pathology.—Lichen planus is apparently an inflammatory process, but what the initial exciting pathologic factor is remains as yet unknown. That it is a neuropathic affection seems probable, Colcott Fox suggesting that the first step may be a neuroparalytic hyperemia. The question[1] of its relationship to pityriasis rubra pilaris (lichen ruber) is still an unclosed one, although the large preponderance of opinion considers them two distinct affections. It seems certain, however, that in some cases of extensive lichen planus occasionally papules similar or closely similar to those characterizing pityriasis rubra pilaris (lichen ruber) are observed.[2]

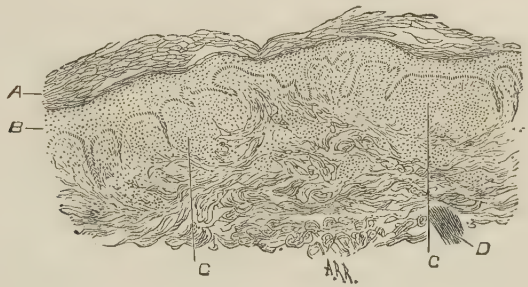

FIG. 37.—Lichen planus—section of two contiguous papules of not very long standing (low magnification): *A*, Corneous layer, thickened slightly; *B*, rete and granular layers, considerably thickened; *C*, *C*, round-cell collection in upper part of the corium and papillæ, some of the latter thus crowded out, others enlarged by the increase in length of the interpapillary rete; *D*, muscle bundle (courtesy of Dr. A. R. Robinson).

The pathologic anatomy has been carefully studied by Robinson, Crocker, Török, Unna, and others. The disease has its seat in the upper part of the corium, and usually around a sweat-duct. The hair-follicles have no determining influence in the situation of the papules. The changes are somewhat different, depending upon the duration and character of the lesion. The rete and corneous layer are noted to be thickened, and the papillæ enlarged, the vessels of the latter showing dilatation. In some recent papules the corneous layer is not thickened and may even be slightly thinned. In the rapid formation of a papule, however, in the acute process, by cell infiltration the rete may be thinned, but if slow, it is found thickened, as above indicated, due doubtless to proliferation of its cells. The central point of the depression usually corresponds to the sweat-duct orifice, the depression resulting from reabsorption and degeneration of the infiltration; the sweat-glands are not affected.

The first characteristic change noted in the epidermis is thought to

[1] See Discussion, *Compt. Rend.*, "Congréss Internat. de Derm. et de Syph.," Paris, 1889.

[2] Kaposi believes that lichen planus, sometimes called the lichen planus of Wilson, is related to the malady described by Hebra as lichen ruber, and to the former he gave the name lichen ruber planus, and to the latter, lichen ruber acuminatus. This view obtained for some years, but was followed by a more or less general reversion, and the acceptance of the opinion that these two so-called types or forms really represented two distinct and separate cutaneous maladies, although a few eminent diagnosticians, as Neumann and Hebra, Jr., as well as several others, have noted cases in which the two coexist. Lichen ruber acuminatus, Kaposi further considers, as is now generally admitted, as identical with pityriasis rubra pilaris.

be an acanthosis, followed by epithelial atrophy, and a hyperkeratosis, intercellular edema, and colloid degeneration of the prickle-cells.

Diagnosis.—The irregular and angular outline, the flattened top, the slight central depression, the glistening or glazed appearance, the dull red or purplish color, the tendency to patch-formation of a slightly rough and scaly surface, with outlying typical papules, together with the history and course and usually itchy character—

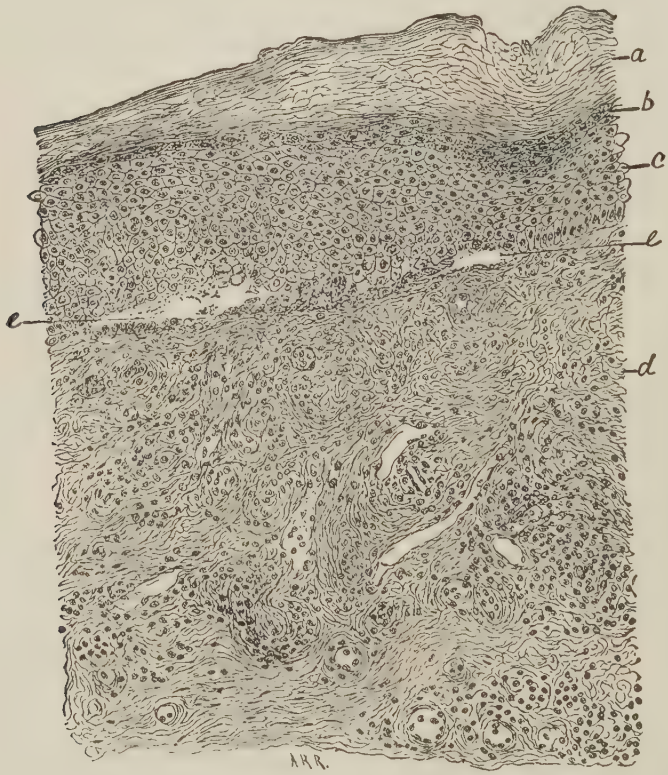

Fig. 38.—Lichen planus—section from a chronic patch (moderately high magnification): *a*, *b*, *c* Show respectively the corneous layer, granular layer, and rete—all considerably thickened; *e*, *e*, microscopic cavities, with serous exudate; *d*, corium, infiltrated with exuded round cells, and with marked increase in the size of the connective-tissue corpuscles (courtesy of Dr. A. R. Robinson).

are features which are peculiar to this disease, and will generally prevent an error in diagnosis. The larger patches look somewhat like psoriasis, but the distribution is different and they are less scaly, of different color, and about the edges are to be found the characteristic papules. A patch of psoriasis is due to peripheral extension, that of lichen planus to accretion of new papules.

While the patches of the disease may resemble squamous eczema, the characters of the papules, always to be found, are essentially different; and in an extensive papular or scaly eczema there is often the presence of a few intermingled vesicles or a history of such or of

oozing; lichen planus is a dry disease throughout, and the lesions are papular and not vesicular; moreover, the papules of eczema are rounded or acuminate.

I have known it to be mistaken for the miliary papular syphiloderm, but in this latter the lesions are usually rounded or conic, and, while tending to aggregate, do not form solid areas, are of a somewhat different color, and almost invariably show some scattered miliary pustules, and often a few larger pustules; moreover, it being an eruption of the active stage of syphilis, there are corroborative signs of that disease to be found.

From lichen ruber the following differences are usually given: the lesions of pityriasis rubra pilaris are round or conic, not shining or glistening, not irregular in outline; are rarely umbilicated; show a scaly film on the summit; are red, and never violaceous, in color; and while the eruption is limited at first, it tends to general involvement. According to Hebra's own description, however, there would seem at times a clinical resemblance in some of the papules of the two affections. Those of pityriasis rubra pilaris are, however, seated about the hair-follicles.

Prognosis.—Its natural course is persistent and often progressive, and shows little tendency to spontaneous recovery. With treatment it can be cured, sometimes in a few months, but oftener a much longer time is required. There is in some cases a disposition to one or more recurrences. The pigmentation finally disappears, but sometimes months elapse before it is entirely gone; occasionally on the legs the discoloration is permanent.

Treatment.—The patient is to have the benefit of good plain food, hygienic living, and, when possible, outdoor life and freedom from mental worry or care. The various tonics and cod-liver oil may be prescribed when indicated. The main remedies in this disease, however, are arsenic, mercury, quinin, and strychnin. Arsenic in many cases has a direct specific influence, given in increasing doses to the point of tolerance, and continued for some time. Biniodid of mercury is also valuable and seems to have a direct action in some instances. These two drugs, and especially the former, are, if no contraindications exist, to be, as a rule, always prescribed, and, along with other indicated remedies, usually lead to recovery. The former is given in the beginning dosage, three times daily, of $2\frac{1}{2}$ or 3 minims (0.165 or 0.2) of Fowler's solution or sodium arseniate solution, or the equivalent of arsenious acid, and gradually increased to 5, 6 (0.33, 0.4), or more; larger doses than 10 minims (0.65) are rarely required, and if no benefit is obtained with this amount, it is not likely to ensue from a greater quantity. Mercury can be given in the form of the corrosive chlorid or the biniodid in the dose of $\frac{1}{32}$ to $\frac{1}{12}$ grain (0.002 to 0.0055). Quinin is also valuable, and should be given in fairly full doses—9 to 15 (0.6 to 1.) grains daily. Strychnin is an excellent tonic in these cases. Constitutional treatment should, as a rule, be continued, in somewhat lessened dosage, one or two months after the eruption has disappeared.

External treatment is of great importance, both for influencing the eruption and for allaying the itching usually present, and in the

limited form of the disease often alone suffices to bring about a cure. In cases of any considerable extent alkaline baths every other day, or in irritable cases bran, gelatin, or starch baths daily, are of service, to be followed on the patches with ointment applications or with lotions. The most efficient application in the general run of cases is liquor carbonis detergens; this is to be applied at first diluted with 10 to 15 parts water, but if no irritation is produced, it may gradually be strengthened, and in some cases can be used pure. It is to be dabbed on thoroughly twice daily, and oftener if the itching demands it. If the skin becomes unpleasantly dry or harsh, its application can occasionally be followed with cold cream; or it may be prescribed in ointment form, 1 or 2 drams (4. to 8.) to an ounce (32.) of simple cerate or a mixture of simple cerate and cold cream. The vegetable tars, especially the oil of cade and oil of birch (oleum rusci), are also excellent in chronic cases, but are stronger than liquor carbonis detergens, and have a more marked and persistent odor; they are best applied in ointment form, 1 to 2 drams (4. to 8.) to the ounce (32.). In acute inflammatory and irritable cases the calamin-zinc-oxid lotion and the plain or carbolized boric acid lotion, act satisfactorily, stronger applications—liquor carbonis detergens—being resorted to later. This calamin-and-zinc-oxid lotion and the other mild lotions used in eczema can also be advised for the disease occurring in infants and children. For thick, hardened, or verrucous areas, a 10 to 20 per cent. salicylic acid rubber plaster or plaster-mull can be used until the thickness is reduced; or paintings with varying strength of caustic potash solutions, beginning with the liquor potassæ, can be used cautiously, washing off immediately afterward, and supplementing with a mild ointment, such as zinc-oxid or diachylon ointment.

When the lesions are close together and patchy, as on the forearms, the galvanic current, of 4 to 10 milliamperes in strength, applied three or four times weekly, has had in some of my cases a material influence; the application should be rapidly labile, except over thickened areas, where the electrodes can be held stationary for one or two minutes. In these cases, too, the static current applied with the roller electrode and the high-frequency current applied with the flat vacuum electrode are also sometimes of service.

Parakeratosis Variegata.—Under this name Unna,[1] in collaboration with Santi and Pollitzer, has described 2 cases, characterized by a more or less generalized red exanthem, but sparing the head, palms, and soles, leaving in some regions—trunk and thighs—small irregular sunken patches of normal skin free, giving the eruption a reticulated or mottled appearance. Over the reddened portion there was a fine lamellar desquamation. The color was deeper on the lower portion of the body, but not uniform, even for the same region, varying from a yellow-red to a blue-red. The affected patches were slightly raised from the surface, their borders sharp, their cuticular areas slightly marked, and their surface beneath the desquamating scales bright and waxy. The larger patches appeared to the touch decidedly infiltrated, like an erythema papulatum, the smaller patches resembling

[1] Unna, Santi, and Pollitzer, *Monatshefte*, vol. x., 1890, p. 404. I have drawn this description in great part verbatim from Pollitzer's abstract in *Brit. Jour. Derm.*, 1890, p. 217.

recent lichen planus papules. There were no subjective symptoms. The affection had lasted in both cases for several years or longer. One of the cases had been sent to Hamburg by Besnier, who had at first regarded the disease as an unusual form of lichen planus universalis, but concluded, after a time, that the affection was one *sui generis*. The histologic examination showed in both cases the changes to be limited to the papillary layer and the epidermis.

In both cases the malady proved resistant to the most energetic chrysarobin treatment, and yielded only to a vigorous course of applications of pyrogallol, during which treatment the poisonous effects of this drug from absorption were prevented by the exhibition internally of large doses of dilute hydrochloric acid.

Under the name **erythrodermie pityriasique en plaques disseminees** Brocq[1] recorded a case of a superficial patchy, slightly scaly eruption, which he was inclined to believe had some features in common with parakeratosis variegata, just referred to, a conclusion with which J. C. White[2] does not agree, a material and essential difference being the entire absence of any papular tendency. The eruption is characterized by scattered, variously sized, scarcely elevated plaques, which are fairly well or quite sharply defined; are of a brownish, pale-rosy, or pale-red color, and with a surface very slightly scaly, the scaliness varying considerably, being extremely slight in White's first case, somewhat more pronounced in his second and third cases, as well as in Brocq's patient, but never excessive or conspicuous. The brownish tint is sometimes the predominant shade, although in Brocq's patient a tawny hue was more noticeable; for the most part, however, the color is pale red or rosy. There is often an ill-defined, marbled, and reticulated appearance of the eruption. The eruption is more or less general, the trunk especially being favored, and sometimes the patches coalesce in places. It is at its worst in winter, and partly or wholly disappears in mild weather. The eruption, as a rule, gives rise to no troublesome subjective symptoms; occasionally there is slight itchiness. Of the several cases reported, one was in a child aged nine, the others were adults, Brocq's case being advanced in years. In another instance in a case recently reported by Ravogli,[3] which, he considers, possesses features which place it with the cases just referred to, the patient was aged three, and the eruption almost universal, but still showing the coalescence from rounded patches of considerable size. This patient had had two

[1] Brocq, *Journal des praticiéns*, 1897, p. 577; and "Parapsoriasis," *Jour. Cutan. Dis.*, 1903, p. 315 (with review and references).

[2] J. C. White, *Jour. Cutan. Dis.*, 1900, p. 536 (with histologic examination by C. J. White). Colcott Fox and Macleod in a recent valuable and exhaustive clinical and histologic contribution, "On a Case of Parakeratosis Variegata," *Jour. Cutan. Dis.*, 1901, p. 424, go over the entire literature of cases which seem to present similar or allied conditions. Méneau, *Jour. mal. cutan.*, May, 1902 (parakeratosis variegata; man aged twenty-one; had existed since aged ten). Graham Little, *Brit. Jour. Derm.*, 1902, p. 218 (erythrodermie pityriasique, case demonstration; girl aged ten). C. J. White, *Jour. Cutan. Dis.*, 1903, p. 153 (1 case, with histologic illustration). Anthony, *Jour. Cutan. Dis.*, 1906, p. 455 (1 case, clinical and histologic, with brief review and bibliography). Török in Mrâcek's *Handbuch*. Riecke, *Archiv*, 1907, vol. lxxxiii., p. 51 (3 cases, lichenoid, with review of reported cases).

[3] Ravogli, *Jour. Amer. Med. Assoc.*, July 13, 1901 (with histologic examination by Heidingsfeld).

previous attacks, and the six other children of the family, according to the parents, had had the same affection in a milder degree when between the ages of four and eight.

These various cases have all much in common, and, according as the one or the other feature is the more pronounced, are, in some of the clinical aspects, suggestive of seborrheic eczema, pityriasis rosea, the early prodromal erythematosquamous eruption of granuloma fungoides, and the disappearing plaques of lichen planus. In a case under my own care (a woman, aged thirty-five, in whom it had lasted several years), the eruption seemed in its general aspects a medley or combination of the appearances of a mild seborrheic eczema and a disappearing lichen planus, the whole having a variegated or marbled aspect.

These and other similar or allied conditions have been grouped by Brocq, under the head of "*parapsoriasis*"; by Crocker, under "*lichen variegatus*"; by Jadassohn, under "*psoriasiform and lichenoid exanthem*"; "*dermatoses psoriasiformes*"; Colcott Fox and Macleod, under "*resistant maculopapular scaly erythrodermias.*"[1]

Brocq divides these cases into three groups: (1) Parapsoriasis guttata (bearing close relationship or resemblance to psoriasis); (2) parapsoriasis lichenoides (intermediate in relationship or resemblance between lichen and psoriasis); (3) parapsoriasis in patches (closely allied and showing resemblance to seborrhœa psoriasiformis (eczema seborrhoicum), the érythrodermies pityriasiques en plaques disseminées). These cases are characterized by (1) an almost complete absence of pruritus; (2) a very slow evolution; (3) a distribution in circumscribed, sharply defined patches, whose dimensions are from 2 to 6 cm. in diameter, which are scattered here and there over the integument; (4) an almost complete absence of infiltration of the derma; (5) a pale redness (pinkish-colored); (6) a fine pityriasic desquamation; (7) an extraordinary resistance to the local applications usually employed in the treatment of psoriasiform or pityriasic seborrhœa; in fact, only yielding slowly and imperfectly to the most energetic applications of pyrogallol.

The *pathologic histology* has been studied by Brocq, Colcott Fox and Macleod, C. J. White, and others. C. J. White found, both in J. C. White's case and his own, the following: (1) Open network formation of the stratum corneum, composed of non-nucleated horny cells; (2) absence of the stratum lucidum; (3) great atrophy, or even total absence, of the stratum granulosum; (4) in places, compression of the rete cells and reduction of the layers composing the stratum spinosum; absence of the palisade layer; and, finally, greatest divergence from the normal directly over the parts of the corium mostly affected; (5) edematous condition of the corium; and (6) reduction in the amount of elastin. Macleod's study[2] of the Colcott Fox-Macleod case and of Perry's case (about the same type as the

[1] Under the name "Xantho-erythrodermia perstans," Crocker, *Brit. Jour. Derm.*, April, 1905, p. 119, reports 10 cases having, as the name signifies, a resemblance, but which he is inclined to consider distinct.

[2] Macleod, *Brit. Jour. Derm.*, 1902, p. 220. Civatte (of Brocq's service) ("note pour servir a l'etude des tuberculides papulo-squameuses; trois cas de tuberculides a forme de parapsoriasis," *Annales*, 1906, p. 209) from his investigations and review believes that parapsoriasis might be an atypical tuberculosis of the skin.

White cases) showed: Dilatation of the subepidermal capillaries; a flattening and edema of the papillary body; an attenuation of the fibrous element; an infiltration of small cells, consisting of small connective-tissue cells, mast-cells, and leukocytes; a thinning of the epidermis; an edema and dilatation of the nuclear spaces; a deficiency in the transitional layers, and an imperfect stratum corneum.

The *treatment* of these cases, as already referred to, is not very satisfactory. The local remedies most efficacious seem to be those commonly employed in psoriasis. In 2 of the cases of xantho-erythrodermia perstans Crocker had good results from 15-grain (1.) doses of salicin three times daily, and the local use of a 10 per cent. vasogen-iodine; salicin seemed to have but little influence in his cases of any duration.

LICHEN SCROFULOSUS.[1]

Synonym.—Lichen scrofulosorum.

Definition.—A chronic, mildly inflammatory disease, usually occurring in scrofulous subjects, characterized by millet-seed-sized, rounded or flattened, reddish or yellowish, more or less grouped, slightly desquamating papules.

In recent years many contributions having in view the grouping together of several cutaneous diseases which are more or less peculiar to scrofulous individuals have been made by Hallopeau (toxi-tuberculides), Darier, Hyde, Boeck (érythèmes tuberculeux), and Johnston[2] (cutaneous paratuberculoses), and others, diseases of which the lesions, while not due directly to the presence of tubercle bacilli, are attributed to their toxins, the organisms having their seat in some other part of the body, either close to the skin or in the deeper organs. The various maladies thus included are lichen scrofulosus, lupus erythematosus, erythema induratum, acne varioliformis (acne necrotica), hidradenitis suppurativa, and a few other affections. That these affections are commonly seen in the tuberculous or those of tuberculous history cannot be doubted, and that, moreover, some present suggestive histologic features. That the explanation advanced (tubercle toxins) is the correct one, requires, I believe, greater substantial evidence, however, before it can be accepted unreservedly. For this reason I have preferred, for the present, to consider these affections separately, and in their customary places, and not under a general class heading. It is true that accumulating facts are almost conclusive as to the tuberculous relationship of lichen scrofulosus, but with the other affections named, the evidence is as yet too scanty to warrant a definite decision.

Symptoms.—This malady is, as a rule, free from subjective symptoms, and insidious in its development, so that it is generally not noted until well-defined patches have formed. The lesions are small, at first scarcely more than a pin-point in size, but which later

[1] Méneau, "Du lichen scrofulosorum," *Jour. mal. cutan.*, 1899, p. 6, gives an admirable account and review of this subject, with bibliography. See also papers and discussion on the same, *Trans. Internat. Derm. Congress*, London, 1896.

[2] J. C. Johnston, "The Cutaneous Paratuberculoses," *Philada. Monthly Med. Jour.*, Feb., 1899, p. 78 (an extremely valuable exposition, with résumé and bibliography).

usually attain that of a pinhead. They almost always arise close together, in irregular bunches or groups, rounded or segmental in configuration; at first bright or dull red, they later assume a livid or brownish tone, and often become fawn-colored or yellowish, which in some instances closely approaches the tint of the normal skin. Not infrequently new lesions arise in the interspaces of the older papules, and between the patches or groups, so that in some cases considerable surface is covered, and if the lesions are yellowish or near the skin hue, the eruption presents some resemblance to goose-flesh (cutis anserina). As a rule, however, the malady is usually represented by but a limited number of patches or areas. The lesions become capped by minute scales, and although they may be close together, never actually coalesce. The older, usually central, papules of the patch often undergo involution, flatten down, and thus results the crescentic or segmental outline often observed; minute yellow stains mark the site of lesions which have disappeared. The eruption is commonly limited to the trunk, especially the lower two-thirds, and more frequently toward the lateral aspects. Less frequently it may also be found upon the arms and legs, and in the latter situation occasionally slight hemorrhagic extravasation may be noted in the lesions, giving them a livid aspect—*lichen lividus.* Exceptionally some of the papules are of a larger size, and may contain centrally a yellowish sebaceous plug, and sometimes several or more are distinctly pustular and acne-like. In rare instances this latter feature is quite pronounced. In occasional cases, more especially in the older patients, there is noted an associated small nodular eczematoid eruption about the scrotum, sometimes a veritable eczema.

The course of the malady is exceedingly chronic, often lasting for years, new lesions and patches arising from time to time, and some gradually disappearing; in other instances the eruption, after a variable time, fading away, and later recurring. While the minute yellow stains usually left by the papules remain for a shorter or longer time, eventually there is not observable a trace of the previous eruption; very exceptionally, however, minute atrophic scars, but rarely more than few in number, are observed. Evidences of scrofula are usually found associated with the eruption.

Etiology.—The disease is extremely rare in this country,[1] less so in France, not uncommon in England,[2] and most frequent throughout Germany, especially Austria. The malady is one of childhood and adolescence, rarely observed under two or three years, and seldom

[1] Bronson, *Archives of Derm.*, 1875, p. 137 (case demonstration); Shepherd, *Canada Med. and Surg. Jour.*, vol. ix., 1880–81, p. 283 (a case); Gottheil, *Jour. Cutan. Dis.*, 1886, p. 133 (with cut and some literature references); Currier, *Jour. Cutan. Dis.*, 1892, p. 403 (case demonstration—doubtful); Hyde, *ibid.*, 1897, p. 453 (a case); Gilchrist, *Johns Hopkins Hosp. Bull.*, 1899, p. 84 (negro child). Professor Duhring (*Diseases of Skin*, third edit., 1882) states that he has not met with a case in this country. My experience, including services at two institutions at which children form a large proportion of the patients, is the same—not a single case has come under my observation.

[2] In England cases have been observed by Tilbury Fox (*Trans. London Clin. Soc'y*, 1879, p. 190 (6 cases, with colored plate); Crocker, *ibid.*, p. 195, and *Diseases of Skin*, second edit. (15 cases); and *Brit. Jour. Derm.*, 1899, p. 38 (case demonstration); Pringle, *Brit. Jour. Derm.*, 1894, p. 218 (case demonstration); Perry, *ibid.*, 1895, p. 156 (case demonstration); Colcott Fox, *ibid.*, p. 153 (case demonstration); Little, *ibid.*, 1900, p. 167 (case demonstration); and others.

above twenty or twenty-five. Sex does not seem to exert much influence, although it is somewhat more common in males, markedly so in Germany. It is a disease of the scrofulous, and the positive evidence at hand, though scant compared to the negative, gives it a place, I believe, among the tuberculoses of the skin, although with one or two, but not absolutely conclusive, exceptions (Jacobi, Wolff)[1] bacilli have not been found in the lesions (Riehl, Darier, Lukasiewicz, Jadassohn, and others). Animal inoculations have failed (Leredde, Jadassohn, Hallopeau, Lafitte, and others) in almost all trials, although in a few instances they have been followed by tuberculosis (Pellizari, Jacobi). In 14 cases out of 16 in which Jadassohn injected tuberculin there was the characteristic reaction. Schweninger and Buzzi saw, apparently as a result of tuberculin injections in a tuberculous subject, lichen scrofulosus develop. The almost invariable association of the malady with evidences of scrofula, such as glandular enlargements, ulcers, caries of the bones, phthisis, and tuberculous family history (Hebra-Kaposi, T. Fox, Duhring, Crocker, Hyde, and almost all others), considered with the other facts just presented, indicate that it is to be considered a tuberculous eruption, the failure to find bacilli leading some observers (Hallopeau, Hyde, Brocq, Johnston, and others) to attribute it to the toxins of the organisms seated at near or remote parts.

Pathology.—The disease has its seat about the pilosebaceous follicles. Anatomic investigations (Kaposi, Sack, Jacobi, Leredde, Unna, and others) show that the papule is made up of an infiltration of lymphoid, epithelioid, and giant-cells, the inflammatory changes beginning first around the vessels, in and about the hair-follicles, sebaceous glands, and about the papillæ surrounding the follicular opening. The cutis beneath the degenerated epidermis undergoes caseous degeneration. Gilchrist[2] states that in his case (a negro) the microscopic sections presented two striking features: (1) Semiglobular-looking masses, situated in the horny layer, and especially around the hair-follicles; (2) marked pathologic changes in the upper portion of the corium beneath these masses, and also about the hair-follicles, especially the deepest portion; the latter was characterized by its tuberculous structure. There is, therefore, in the histologic picture a similarity to the structure of miliary tubercle, and a further support to the belief in the tuberculous character of the disease; Jacobi,[3] Sack,[4] Hallopeau and Darier[5] and Lesselier,[6] from their findings, speak most strongly to this effect.

Diagnosis.—The disease is to be differentiated chiefly from the miliary papular syphilid, keratosis pilaris, and papular eczema. The first is an eruption of the active stage of syphilis, and in addition to the eruption being widely distributed, other symptoms of

[1] Jacobi, *Verhandl. der deutsch. dermatolog. Gesellschaft*, III. Congress, 1891, p. 69 (with histologic plate); Wolff, *ibid.*, VI. Congress, 1899; Haushalter, *Annales*, 1898, p. 455, found bacilli in lesions of 2 cases described by him, but in these cases the lesions were quite large, discrete, disseminated, and also upon the face, and represent more closely cases of disseminated tuberculosis of the skin.

[2] Gilchrist, *Johns Hopkins Hosp. Bull.*, 1899, p. 84.

[3] Jacobi, *loc. cit.*

[4] Sack, *Monatshefte*, vol. xiv., 1892, p. 437.

[5] Hallopeau-Darier, *Annales*, 1892, p. 45.

[6] Lesselier, *ibid.*, 1906, p. 897 (out of 17 cases found in 14 the structure of the tubercle).

this disease can always be found. The usual regions for keratosis pilaris are the limbs, most commonly the thighs, especially the outer surface; there is practically no tendency to form groups or patches. Papular eczema is rarely seen on the trunk alone,—a favorite region for lichen scrofulosus,—and it is decidedly itchy, and frequently some of the lesions are vesicular or papulovesicular. These various characters suffice ordinarily to distinguish these several eruptions from lichen scrofulosus. In this latter the patchy and sluggish features, together with the usual presence of scrofulous symptoms, will also serve to prevent error.

Prognosis and Treatment.—The malady readily responds to treatment; if let alone, it persists an indefinite time. The classic treatment of Hebra, which rapidly cures, consists of cod-liver oil internally and externally; small or moderate doses should be administered. American and English patients would seriously object to oleum morrhuæ as a local application, and experience teaches that mildly stimulating oily applications or ointments will act as effectually. Crocker found that inunctions of plain vaselin, or with 15 drops of the solution of subacetate of lead, or 5 grains (0.35) of thymol to the ounce (32.), were quite as efficient as cod-liver oil applications.

PITYRIASIS RUBRA PILARIS.

Synonyms.—Lichen psoriasis (Hutchinson); Lichen ruber (Hebra); Pityriasis pilaris (Devergie, Richaud); Lichen ruber acuminatus (Kaposi); *Fr.*, Pityriasis rubra pilaire.

Definition.—A rare disease, characterized by grayish, pale-red, or reddish-brown papules, seated at the mouths of the hair-follicles, with minute, somewhat hard or horny, centers, and which in places become confluent and result in thickening and scaliness.

Since the writings on this disease by Devergie,[1] and later Richaud,[2] Besnier,[3] and other French observers, there has been much discussion as to its identity with those cases described by Hebra[4] under the name of "lichen ruber." Kaposi, who was Hebra's assistant as well as son-in-law, and who had seen some of Hebra's cases (although none of the fatal ones) later described the disease under the name of "lichen ruber acuminatus," in order to distinguish it from the lichen planus of Wilson; inasmuch as the French observers considered Kaposi's lichen ruber acuminatus as their pityriasis rubra pilaris, the conclusion would seem inevitable that the latter is identical with Hebra's lichen ruber, although the French do not concede this. A study of the colored plates[5] in existence of these alleged different

[1] Devergie, *Traité pratique des maladies de la peau*, 1857, second edit., p. 454.

[2] Richaud, "Etude sur le pityriasis pilaris," *Thèse de Paris*, 1877.

[3] Besnier, "Observations pour servir a l'histoire clinique du pityriasis rubra pilaris," *Annales*, April, May, and June, 1889 (based upon 28 cases).

[4] Hebra and Kaposi's *Hautkrankheiten*, first edit., 1862, vol. ii., p. 315.

[5] *Barensprung and Hebra's Atlas*, Erlangen, 1865, plates xiv. and xvi.; Hebra's *Atlas*, plate ii., part iii.; *Neuman's Atlas*, plate xli., and *Archiv*, vol. xxiv., 1892, p. 3; Besnier, *Annales*, vol. x., 1889, following p. 388; same in *La Pratique Dermatologique*, vol. iii., with also 2 copies of moulages (Nos. 728 and 972) in Baretta, St. Louis Museum, Paris; *Tilbury Fox's Atlas*, plate xxxix; *Crocker's Atlas*, plate xxxiii.; *Morrow's Atlas*, plate lviii. (copy of Neumann's case); *Taylor's Atlas*, plate liv., and *New York Med. Jour.*, Jan. 5, 1889; and in *G. H. Fox's Atlas*.

In addition to the literature bearing upon the disease in connection with the colored

diseases is, however, confirmatory of their identity. The obscuring facts are: (1) Hebra stated that, "while the entire number of our earlier cases (about 14) died, in no case under our care since—at least three times as many—has such results ensued, but, on the contrary, under treatment (heroic arsenical treatment) a steady progress was made to final and complete recovery"; and (2) Hebra's account[1] of the disease

plates mentioned (especially the articles by Besnier and Taylor) and that specifically referred to in the course of the text, the interested reader, desiring to pursue the subject, can consult the following: Kaposi, *Archiv*, vol. xxi., 1889, p. 743, and vol. xxxi., 1895, p. 1; Neumann, *Archiv*, vol. xxiv., 1892, p. 3; Neisser, *Verhl. d. deutschen Derm. Gesell.*, iv., Cong., p. 495 (with discussion); Discussion, *Trans. Internat. Derm. Cong.*, Paris, 1889; G. H. Fox, *Morrow's System*, vol. iii. (Dermatology), p. 324; Discussion, *N. Y. Derm. Soc'y Jour. Cutan. Dis.*, 1902, p. 572.

[1] The following account is found in Hebra and Kaposi's *Hautkrankheiten*, second edit., vol. i., p. 388:

"**Symptoms.**—If one has the opportunity to observe a beginning or developing lichen ruber, papules of the size of a millet seed will be observed, at first separated from each other, covered with a thin scale, with but very slight itching, and they are therefore but little scratched by the patient, at least not enough to cause them to bleed; and hence black crusts of dried blood, due to scratching, are only exceptionally observed at the summits of the lesions.

"The papules occur in two forms. In one variety they are of a vivid or a brownish-red color, conic, very firm, their summits covered with a white, dry mass of scales, on account of which they are very rough to the touch. If the palm of the hand be passed over them, the sensation to the touch and the sound will be conveyed as if the hand were passing over a grater. In other instances the papules are likewise disseminated, and of the size of millet seeds, but pale red, of a waxy appearance, their surfaces smooth, rounded (not conic), and a minute depression in their center plainly visible.

"The efflorescences in the earlier eruption appear, as a rule, without a definite localization—that is, here and there on the trunk, extremities, more so on the flexor surfaces—so that the disease from the very start shows a generalized character. Occasionally, however, and for some time, the eruption remains confined to the one region, like the legs and the genitocrural region. In the course of time, however, the disease becomes generalized.

"*Clinical Course.*—The described papules retain their size during their entire existence, without manifesting any extension of growth peripherally. The dissemination of the affection is due to the occurrence of new lesions, which appear either irregularly or in rows, close to or adjoining the seat of the earlier lesions, and also on the unaffected skin between the lesions. Thus the papules gradually become more thickly crowded, while the intervening healthy portions of skin become smaller and less numerous. The papules thus become so thickly set that they give rise to variously sized, coalescing red, infiltrated areas, covered with fine scales; at the periphery of the larger plaques the recent papules, although somewhat crowded together, are easily recognized.

"Sometimes the subsequent lesions appear in thick, row-like aggregations, arranged in a somewhat circinate manner around an older papule; the central and longer persisting efflorescences sink down, disappear, and leave a skin, occupied by atrophic depressions, and generally dark pigmented, or showing telangiectases. Plaques thus result, varying in size from that of a lentil to that of a dollar, in which the periphery is made up of one or more wreath-like circles of the above-described waxy, shiny papules, with central depression, while the center is uniformly sunken, darkly pigmented, or occupied by small depressions—like a brooch that is encircled by a chain of pearls.

"In most cases the first variety of distribution is exclusively present, while in rarer cases the other variety; occasionally both varieties are represented in the same individual, in which case the aggregated and circinate plaques are, as a rule, found on the extremities, while the irregular and diffuse lesions generally occupy the trunk. Notwithstanding that a greater part of the lesions run their course with, and some without, atrophy and pigmentation, the repeated recurrences finally predominate, so that in several or more years the whole general surface is largely invaded. The subsequent occurrence of the described lesions on such areas that were previously exempt leads to the involvement of all of the skin, forming a peculiar clinical picture. The skin appears reddened, covered with numerous but thin scales, and thickened, measuring in its transverse diameter more than double that of a normal integument. Every muscular action is rendered difficult, particularly about the joints, as the skin covering the flexor surfaces of these parts is especially involved. The patients can only with great difficulty completely flex or extend

is in some particulars different from the description of pityriasis rubra pilaris as we see it to-day. These two facts led me formerly to consider the two maladies as distinct, and they so appeared in the earlier editions of this book, but a further study and consideration of the subject, as outlined above, have changed my opinion. Hebra's differences in the description of the clinical features can be explained upon the justifiable assumption that it included cases of lichen planus; but we are still left to wonder why, before instituting heroic arsenical treatment, all his cases died, inasmuch as this disease as we see it now is comparatively benign, with no fatal tendency, and, moreover, seems wholly uninfluenced by arsenical treatment.

Cases have been described in America by Taylor,[1] White,[2] Zeisler,[3] Ravogli,[4] Heidingsfeld,[5] and others. The disease seems rarer in England than elsewhere, although an Englishman, Tarral,[6] was the first

the extremities, usually endeavoring to maintain a posture between flexion and extension. The thickening of the skin, however, is especially recognized on the palmar and plantar surfaces, as well as on the toes and fingers: the latter are generally kept separated, and show, in addition to the reddening and infiltration, transverse tears and fissures corresponding to the phalangeal joints. These tears, which are painful, often extend into the corium, giving rise to bleeding, and consequently are covered or surrounded by blood-crusts.

"When there is a general distribution of the lesions, the nails of the fingers and toes are always likewise affected. In some cases the nail substance is thickened from the nail-bed out more than double its usual thickness, is uneven on its surface, very brittle, so that the nails break before they attain their usual length, and are opaque and yellowish; in other cases the nail grows only from the matrix, and as a result the nail substance, as it is not uniformly developed, presents only a thin and fragile horny layer, of a lighter color. The use of the fingers and toes is markedly impeded, both by reason of the dermal infiltration as well as the changes in the nail substance, and in consequence thereof walking and prehension are both rendered more difficult.

"The hair of the head, axillæ, and pubis remains exempt, while the other hairs, on the trunk, are arrested in development, progressing only as far as lanugo hairs.

"*Accompanying Manifestations.*—The first development of the exanthem occurs without any marked local or general prodromal symptoms, without fever or malaise, so that the patients either entirely overlook the eruption or regard it as a 'heat' rash. Nevertheless, many patients suffer during the first outbreaks, and frequently during the later exacerbations, from such violent itching as to keep them from obtaining any sleep whatsoever.

"The generalized eruption is likewise, as a rule, accompanied by unpleasant itching, although this bears no relationship to the extent or severity of the disease, and, furthermore, is less intense than in many other less serious skin diseases—as, for instance, psoriasis, prurigo, eczema; and in no case of lichen ruber do we observe the marked excoriations that are present in the above-named dermatoses. The skin does not, therefore, become the seat of such changes as are observed in other itching diseases of the skin.

"The general condition of the patients in relation to the development of the eruption is variable. In the beginning stages, when but comparatively scanty lesions or infiltrated plaques are present, the general health seems unaffected. Later on the efflorescences increase in numbers, and in the course of years the nutrition is noted to show impairment; and although at this time appetite may be good, and sleep undisturbed, one observes a disappearance of the subcutaneous fat—in short, a perceptible emaciation. When the malady has finally invaded the whole surface, the general nutrition may not even then at first be seriously involved, but in course of time this is noted to be more and more impaired, and the patient merges into a condition of marasmus, in consequence of which a fatal result in most of the cases ensues."

[1] R. W. Taylor, "Lichen Ruber as Observed in America," *New York Med. Jour.*, Jan. 5, 1889 (with a colored plate, several case and histologic cuts—a most admirable and complete paper).

[2] J. C. White, *Jour. Cutan. Dis.*, 1894, p. 468.

[3] Zeisler, *Chicago Med. Record*, vol. xvi., 1899, p. 533.

[4] Ravogli, *Cincinnati Lancet-Clinic*, vol. xlii., 1899, p. 333 (with histologic cuts).

[5] Heidingsfeld, *ibid.*, June 3, 1899 (with histologic cuts).

[6] Tarral, communication to Rayer, *Traité théorique et pratique des maladies de la peau*, Paris, 1835, second edit., vol. ii., p. 158; also quoted by Besnier, *loc. cit.*

PLATE V.

Pityriasis rubra pilaris in a mulatto girl, involving the entire surface. Began when six or seven years old, and gradually extended, reaching generalization when ten years old (at the time photograph was taken). Family free from skin disease, and brothers and sisters, six in all, well and healthy. Under treatment improvement has slowly taken place, so that a year ago, when last seen, then aged sixteen, not more than one-third of the surface remained affected, the eruption then consisting of some large confluent scaly areas and patches of closely crowded discrete follicular papules. The patient's general health has continued good throughout.

one who clearly described a case of the disease, and in late years other cases have been encountered by Hillier, Tilbury Fox, Fagge, Jamieson, West, and Liddell.[1]

Symptoms.—The disease often involves the greater part of the entire surface, or it may remain limited to one or two regions. It usually begins insidiously, and, as a rule, the first manifestations noticed are a scaly condition of the scalp and thickened areas upon the palms and soles. Soon the characteristic follicular, pale-red or brownish papules appear either on the dorsal surface of the fingers and hand, about the abdomen or the extensor surfaces of the extremities, especially the forearms; or they may present more or less synchronously upon all these several regions. In one of the cases under my observation it began on the back of the neck, and for a long time remained limited to this region. They are somewhat hard to the touch, acuminated, and at the central point is seen a small horny formation, usually pierced by a hair, or showing the extremity of a broken hair. The papules only extremely rarely[2] show slight peripheral enlargement, in the manner of a psoriasis papule. While discrete at first, new papules arise and become aggregated, forming confluent areas of variable size, which are noted to be yellowish red or grayish red in color, thickened, rough, dry, and slightly scaly, and with an accentuation of the natural lines of the skin, and sometimes a tendency to fissuring about the joints. These confluent areas bear some resemblance to psoriasis, but the scaliness is more of a branny character, never so flaky or laminated or so pronounced as in psoriasis. Along with these areas the palms and soles are the seat of diffused thickening, and the face, usually beginning at the brow and near the nose, becomes dry, slightly or moderately thickened and scaly, but with no tendency to papular formation. Ectropion of the lower eyelids sometimes ensues. The lesions on the dorsal surfaces of the fingers usually remain discrete, and, as likewise even in cases of considerable scaly development, are quite distinctly pronounced.

The disease on both the scalp and the face is somewhat variable as to degree, from a reddish, slightly scaly condition to that of some thickening and marked scaliness, almost to the extent, on the latter region, of producing a mask to the parts. The hairs of the scalp show but little, if any, involvement. The nails, on the contrary, are often brittle, rough, dull, striated, and they show a tendency to break and crack. The disease is in most cases progressive, but after some months, after reaching a variable extent, it may remain stationary for a time, and then advance again; or there may be periods of slight retrogression and progression. It may be so extensive as to cover in most of or practically the entire surface, in which event a generalized thickened and inelastic condition of the skin is observed, covered with grayish scales, usually moderate in quantity, and dry and

[1] See paper by West., *Brit. Jour. Derm.*, 1895, p. 273 (with case illustrations), and Liddell, *ibid.*, p. 279 (with histologic examination).

[2] Whitfield, *Soc'y Trans. Brit. Jour. Derm.*, 1902, p. 470 and 1904, p. 462, showed such a case—presenting, in fact, at different times or in different areas, some of the features of typical pityriasis rubra pilaris, psoriasis and dermatitis exfoliativa; Thibierge, *La Pratique Dermatologie*, vol. iii., also refer to this possible peripheral enlargement.

harsh to the touch; the natural lines of the skin are considerably exaggerated, and sometimes cracks about the joints occur. In such instances the papular element is scarcely recognizable, although, as remarked, discrete papules are still, as a rule, to be found on the backs of the phalanges. In less extensive cases large grayish plaques, irregularly shaped but commonly oblong, are to be seen on different parts, especially the extremities, with outlying typical papules and with some irregularly scattered over the general surface. In cases of any extent the face, scalp, and hands rarely, if ever, escape. As a rule, there are no subjective symptoms complained of; occasionally, slight itching. The general health remains apparently unaffected.

FIG. 39.—Pityriasis rubra pilaris: *a*, Thickened corneous layer; *b*, hypertrophied rete; *c*, hair-follicle; *d*, cell infiltration about follicle; *e*, corneous plug in mouth of follicle (section from the case herein pictured—section and photomicrograph by Dr. M. B. Hartzell).

Etiology and Pathology.—The disease is rare and the cause is unknown. Neither heredity, sex, nor color seems to have any etiologic significance. It has been observed (Besnier, Hallopeau and Brodier, Rasch) in quite young children, in Rasch's[1] case at the age of two and a half years; indeed, in the majority of cases it has its beginning in childhood or early youth. Of the 5 cases under my observation, 1 was a mulatto girl of ten, in whom it developed when aged six; the others were a woman, aged twenty, a negress aged twenty-five, and two men, aged respectively twenty-five and thirty. They were all apparently in good health, and did not seem to be seriously inconvenienced, although in 3 the disease was almost universal.

[1] Rash, *Dermatolog. Centralblatt*, No. 7, 1899, p. 199.

The pathologic anatomy (Jacquet, Taylor, Ravogli, Heidingsfeld, and others) discloses that the disease is a hyperkeratosis, secondary inflammatory changes resulting. The essential and primary hornification occurs in the epithelial lining of the orifice of the hair-follicle, producing the papule; the projecting horny spine being due to the collected mass of cornified epithelium within the follicle. All the epidermic layers are markedly thickened, more especially the upper corneous part.

The sweat-duct outlets may sometimes show similar, but relatively insignificant, changes. Round-cell infiltration is noted about the hair-follicles and to a less extent in the papillæ. In one of my cases sections, from one of which the herewith illustration was taken, were kindly made by Dr. Hartzell, who reported as follows:

"The epidermis was three or four times thicker than normal, the increase in thickness being most marked in the corneous and prickle-cell layers. The corneous layer, while everywhere thicker than normal, was most markedly increased in and around the mouths of the hair-follicles, in which it formed plugs of considerable size, projecting some distance above the surface and extending well into the follicle. Many of the cells of the rete mucosum showed greatly enlarged nuclei which stained badly, or, in many instances, not at all. The papillæ of the corium were decidedly increased in length, were only slightly wider than normal, and contained a moderate number of small round-cells with a few 'Mastzellen.' Along the entire length of the hair-follicles there was a fairly abundant round-cell infiltration. Neither the sebaceous nor the sweat-glands showed any appreciable alteration."

Diagnosis.—In well-developed cases there is rarely difficulty in the diagnosis; the follicular papules containing a horny projection and broken hair-shaft, and usually to be found even in extensive cases, especially on the dorsal aspects of the fingers, the thickened, harsh, rough, and slightly or moderately scaly skin, the thickened palms and soles, the marked scaliness of the face and scalp, constitute a picture usually quite characteristic. In mild and moderate cases the papular lesions, generally crowded together, with the features described, will be sufficiently distinctive. When more or less general, it may show some similarity to some cases of dermatitis exfoliativa, but in this latter there is rarely material thickening, the skin is redder, and the scaliness more pronounced. It can scarcely be mistaken for psoriasis—in the latter the beginning lesions, their character, and their growth by peripheral extension, instead of by accretion of new papules as in pityriasis rubra pilaris, and the absence usually of palmar and marked facial involvement, are entirely different. The scaly plaques of lichen planus present some features similar to the plaques of this malady, but the dark-red or violaceous tinge of the border and of outlying lesions in the former, and the flattened, frequently umbilicated, characters of the discrete papules, as a rule, always to be found, and the itchiness and almost invariable absence of involvement of face, scalp, and palms, are distinguishing characters.

Prognosis.—The disease is always persistent and rebellious to

treatment. Retrogression, however, may take place, and even complete recovery has been recorded; recurrence often ensues. The 5 cases under my care all improved, but not one was cured; only 1 was under my care a sufficiently long time, however, to expect more than betterment. In this last—the case shown in the illustration—the disease, when the patient was seen several months ago, was still gradually retrogressing.

Treatment.—The treatment of this malady consists essentially in the administration of tonics, when necessary, sudorifics, and externally bran, starch, or alkaline baths, and oils or ointment applications. Exercise, proper food and living, are, of course, of great value. Arsenic has no special value in this disease; but, in view of Hebra's experience as to its remarkable efficiency in continued large doses, it might, in extensive cases, be tentatively tried in steadily increasing dosage.[1] Thyroid extract seemed of slight service in 1 case, but as the external treatment was being carried out at the same time, it was doubtful to which the benefit was due. Little[2] had some effects from it use in 1 instance, beginning with 1½ grains (0.1) and increasing to 3 grains (0.2) three times daily. Jaborandi or pilocarpin will sometimes have a favorable influence by its action on the perspiratory glands. If the nutrition is poor, cod-liver oil is a remedy of considerable value.

The external remedies are about the same as used in psoriasis and in ichthyosis. In cases of decidedly irritable skin, bran or starch baths, daily or three or four times weekly, prove serviceable. Alkaline baths are most frequently to be used, and can be made up with the various alkalies usually employed. Oil or ointment applications should be made once or twice daily, as well as immediately after a bath. An ointment of salicylic acid, from 10 to 60 grains (0.65 to 4.) to the ounce (32.), is one of the most efficient. Weak tar ointments are also at times of service. Markedly thickened and hard areas can be treated by a 10 to 20 per cent. salicylic acid plaster, or this remedy can be applied in collodion, 2 to 10 per cent. strength. Pyrogallol and resorcin salves have been extolled, but the use of the former must be restricted to small areas for fear of absorption. The scalp is to be shampooed frequently with tincture of green soap, and an ointment or oil applied.

PSORIASIS.

Synonyms.—Lepra and Lepra alphos (of old authors); *Fr.*, Psoriasis; *Ger.*, Psoriasis; Schuppenflechte.

Definition.—Psoriasis is a chronic inflammatory disease, characterized by more or less numerous dry, reddish, variously sized, rounded and sharply defined, more or less thickened, patches, covered with white, grayish-white, or mother-of-pearl-colored, imbricated scales, usually abundant in quantity.

Symptoms.—Psoriasis is always a dry scaly-papular eruption—oozing or liquid exudation never occurs, and such other lesions as

[1] Heidingsfeld, *Jour. Cutan. Dis.*, 1906, p. 371, found his 3 cases uninfluenced by this drug in respect to its internal administration and the hypodermic injection of sodium arsenate; but favorably influenced by hypodermic injections of atoxyl, and, to a lesser extent, by cacodylic acid.

[2] Little, *Brit. Jour. Derm.*, 1900, p. 412.

vesicles, pustules, etc., are never observed.[1] It usually begins slowly by the appearance of a variable number, few or many, of scattered pin-point or pin-head-sized, slightly elevated maculopapules or papules, covered with whitish or grayish-white scales, at first thin and epidermic. These lesions increase slowly, and, as a rule, very gradually, in size, and, as they grow peripherally, the scale accumulation becomes more marked and imbricated. During this time new spots are usually appearing. The earliest lesions growing larger, often at different rates of rapidity, together with the appearance of the new scaly papules, soon result in a characteristic clinical picture:

Twenty to a hundred or more patches, varying in size from a pin-head to a silver dollar, are usually present; they are sharply defined against the sound skin, are slightly elevated and thickened or infiltrated, and, if undisturbed, are more or less abundantly covered with whitish, silvery, grayish, or mother-of-pearl-colored scales; at the extreme periphery the red edge of the underlying skin beneath the scales can be seen; from a few or many of the patches the scales have probably been rubbed off by the clothing or intentionally removed, and the bases are then seen to be bright or dark red in color, disclosing the inflammatory nature of the disease. Gently scraping the uncovered surface of a patch, which seems to be coated over with a thin whitish or reddish-white pellicle (Bulkley), with the finger-nail will result in minute abrasions of the vascular papillary layer of the corium, and the appearance of one or several minute drops of blood. The patches are usually scattered irregularly over the general surface, but are commonly more numerous on the extensor surfaces of the arms and legs, especially about the knees and elbows. Several lesions which may have been close together will often have coalesced and a large irregularly shaped patch be formed—always, however, with the edges sharply defined against the sound skin; movement of joints affected may give rise to fissuring. It is possible, too, that in a few patches the central portion may have begun to undergo retrogressive change, and, sunken down, become less scaly or entirely disappear; such patches are then circinate or ring-like.

[1] Some of the more recent literature upon clinical phases:

Analytic and clinical:

Greenough, *Boston Med. and Surg. Jour.*, Sept. 10, 1885; Bulkley, *Maryland Med. Jour.*, Sept. 26 and Oct. 4, 1891; Pye-Smith, *Guy's Hospital Reports*, vol. xxv., 1880–81, p. 233, and vol. xlvi., 1889, p. 419; Nielsen (with full consideration of etiology and pathogeny, and rare atypical clinical types, with numerous literature references), *Monatshefte*, vol. xv., 1892, pp. 317 and 365; also in *New Sydenham Society's Selected Monographs on Dermatology*, 1893, p. 571; Rille (in children, with complete bibliography), *Wien. med. Wochenschr.*, 1895, p. 2098; P. S. Abraham, *Brit. Med. Jour.*, April 14, 1906.

Atypical cases:

Rosenthal, *Archiv, Ergänzungsheft*, i., 1893, p. 79; Waelsch, *Prager med. Wochenschr.*, 1898, p. 73; Deutsch, *Wien. klin. Wochenschr.*, 1898, p. 130; Beyer, *Wien. klin. Wochenschr.*, 1901, p. 824 (with full review of the subject).

Horny formations, with epitheliomatous development: White (J. C.), *Amer. Jour. Med. Sci.*, Jan., 1885; Hebra, Jr., *Monatshefte*, vol. vi., 1887, p. 1; Hartzell (bibliography to date, and especially bearing upon arsenic as the causative factor), *Amer. Jour. Med. Sci.*, Sept., 1899; Schamberg, *Jour. Cutan. Dis.*, 1907, p. 26.

Leukodermic areas: Hallopeau et Gasne, *Bull. de Soc. francaise*, July, 1898; Rille, *Dermatolog. Zeitschrift*, Nov., 1898.

Keloidal formation: Purdon, *Jour. Cutan. Dis.*, 1883, p. 203; Anderson, quoted by Crocker, *Diseases of Skin*, third edit., p. 363.

Such a clinical picture is the one usually seen after the disease has lasted several months or longer. It will be observed that the history of the appearance and growth of one lesion is essentially the history of all. The larger patches cannot arise as such, but are the result of peripheral growth from a beginning small lesion; and as the growth of the lesions may stop at any time and remain stationary for a shorter or longer period, or almost indefinitely, it can readily be understood how the so-called clinical varieties of the disease are produced. For in some instances the lesions, or the most

FIG. 40.—Psoriasis, in a lad aged twelve, of a year's duration, showing small (guttate) lesions, and larger plaques on arms; distribution general.

of them, progress no further than pin-head in size, and then remain stationary, constituting **psoriasis punctata**; in other cases they may stop short after having reached the size of drops—**psoriasis guttata**; in others, as in the descriptive picture above given, the patches develop to the size of coins—**psoriasis nummularis, psoriasis discoidea**—and remain stationary. In other cases, having attained a certain but variable size, more usually small or large coin size, involution changes set in, and the central part of many, or the majority or even more, begins to disappear, and there result a number of patches with clear centers and a surrounding inflammatory scaly band—**psoriasis**

circinata, psoriasis annulata. If it happens that several of the ring-shaped patches are close together and begin to extend again peripherally, at the same time undergoing involution at the inner part of the ring, coalescence takes place, and the coalescing portions disappear, and there is left an eruption of serpentine inflammatory scaly bands—**psoriasis gyrata.** Or if several or more closely situated solid scaly plaques continue to increase in size, they coalesce and form large areas of varying dimensions, sometimes sufficiently large to cover a part or an entire region—**psoriasis diffusa**; when about joints, the mobility of the part is often painful, and fissures, somewhat deep, are often noted. These diffused areas are usually

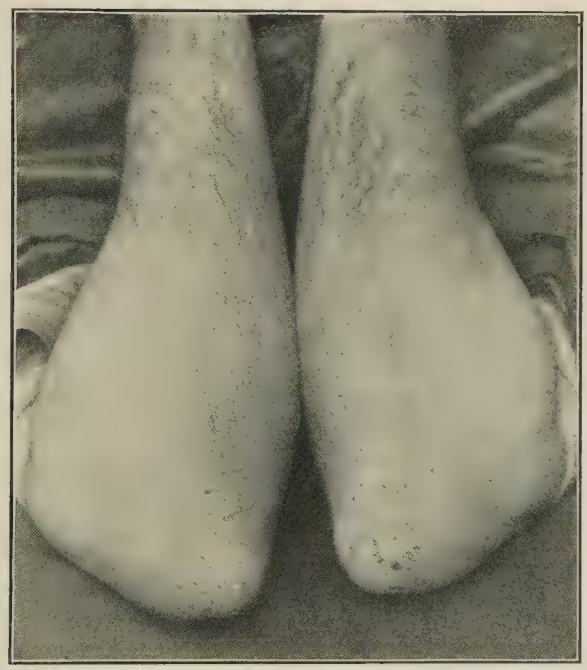

FIG. 41.—Psoriasis in a male adult of several years' duration. Shows a not unusual development on the elbows in slight cases. In this instance the scalp was also involved, but other parts were almost wholly free.

markedly infiltrated and of a somewhat inveterate character, and hence the term sometimes applied—**psoriasis inveterata.** Should, by gradual increase of old patches and the appearance of new lesions in the interspaces, almost the entire surface be one sheet of eruption, the name **psoriasis universalis** is applicable. Fortunately, such extensive covering of the surface is rarely observed.

In extremely exceptional instances (McCall Anderson, Waelsch, Deutsch) there is displayed on some patches a tendency to central heaping of the scales—hence the term **psoriasis rupioides, psoriasis ostreacea**; in some of these cases, however, there is an admixture of fluid (gummy or oily) exudation, indicating an eczematous or at least a seborrheic complication (psoriatic eczema, seborrheic psoria-

sis). When on the scalp, this heaped-up scale accumulation may be quite adherent and almost horny (Gassman). Rarely a tendency in one or several areas to papillary hypertrophy is noted, giving rise to the term **psoriasis verrucosa**; such has been observed on the legs (Kaposi), on the extremities (Waelsch), and on the palmar and dorsal aspects of the hands (Besnier).

While the involution begins frequently at the central part of the patch, and in a very perceptible manner, yet this is by no means always so, for in many cases there is a gradual disappearance, more or less uniformly, of the entire patch; if examined closely, however, many such patches will show that the retrogressive change is slightly more active centrally than peripherally; in others there is no noticeable difference. The first evidences of involution are lessened hyperemia and lessened scale-production.

FIG. 42.—Psoriasis, generalized, of a common clinical type, showing the sharply defined, variously sized, scaly patches (courtesy of Dr. W. Frick).

In many cases of the disease, instead of beginning with a somewhat scattered distribution, the eruption first appears about the extensor surfaces of the knees and elbows, insignificant or moderately well marked, and presenting several or more small areas. It may remain limited to these parts for some months or longer, without any disposition to the appearance of new patches elsewhere; it may disappear during the summer and then reappear the next winter for a few years, before becoming more general. As a rule, after some months on these regions, lesions begin to present on other parts, few or in great numbers, and finally present the picture already described. In other cases, relatively infrequent, the first appearance of the patches is on the scalp, and the malady may last for some months or a year or more so limited, and then gradually or rapidly appear on other parts. While exceptionally the scalp is the sole seat of the eruption for some time, yet, as a rule, in such cases, if the elbows and knees are closely examined, two, three, or more insignificant scaly spots can usually be found, although they may have been so slight as to escape the patient's notice; not infrequently, also, a few small insignificant spots can be found elsewhere on the limbs and trunk.

Instead of appearing in the chronic manner already described,—insidiously, gradually, or with moderate rapidity,—the disease may be acute in respect to the outbreak, and within a few weeks reach extensive development, several hundred or more variously sized patches presenting. In such cases the inflammatory element is usually of a more pronounced type, and, as a rule, the scaliness less marked, occasionally consisting of scarcely more than one or two thin epidermic films. The subjective symptoms of burning and itching may be present to an annoying degree. After a while these cases often lose the acute characters, and then settle down into the ordinary clinical type. In other instances, after reaching rapid, extensive development, involution changes present, and the disease up to a certain degree disappears quite rapidly; the eruption left, of slight or moderate amount, assumes the slow characters of the common clinical cases, and persists more or less indefinitely, with periods of remission or intermission.

FIG. 43.—Psoriasis in a youth of fifteen, of more or less general distribution. Shows scalp involvement, and especially pronounced in mastoid region; few small patches on the face in front of the ear.

It will be noted, therefore, that the disease may first appear on one or two or several regions, and then remain so limited, but, as a rule, only for a variable time, and then present other patches elsewhere; or that it may be from the first more or less scattered, sometimes with a more abundant eruption on certain regions, as about the elbows, knees, and scalp. Occasionally most patches will be found upon the legs, on and below the knees; over the region of the sacrum is also a favorite site, especially for one or two large areas. On the scalp the disease may present scattered patches, or here and there confluent areas; it is not uncommon to find several or more just overstepping the hairy borders of the forehead and mastoid region. There is rarely any hair loss. The face is not often invaded, and, if so, usually with small lesions and to a very slight degree, and these are most commonly found just in front of the ears. The palms and soles usually escape, except in rare instances of more or less extensive and generalized cases; these parts are never the sole seat of the eruption. Exceptionally the palmar lesions, when present, are hard and papular, with but little if any scaliness (Gaucher and Hermery). The backs of the hands often escape; not infrequently lesions may form under and about the nails, and as a result the

latter become brittle or granular, opaque, and sometimes thickened; exceptionally one or more may be cast off, but never permanently.

Psoriasis lesions are noted to form sometimes along the line or at the points of mechanical irritation or slight injury; they are also seen on tattoo marks (Heller), on and about vaccine (Walters, Rohe, Hyde, Augagneur, Mourier, Heller, and others) and other scars (Hallopeau and Gardner), and following the course of scratch-marks. In rare instances, too, the eruption has been, at first at least, somewhat limited, and following peripheral nerve distribution (Thibiérge, Hallopeau and Gasne), and even unilateral, on one arm, starting from a traumatism (Kuznitzky). Psoriasis of the tongue or other mucous membranes really does not exist; lesions, so called, are usually those of leukoplakia buccalis; recently, however, 2 cases in which one or two lesions extended from the skin on to the mucous surface have been recorded (Kuznitzky, Sack).

The eruption may be scanty, moderate in quantity, or exceedingly abundant, and may evolve slowly or rapidly. As to the inflammatory character, that, too, varies considerably in different cases and sometimes in different patches in the same case—from slight and insignificant to that of a marked degree. The base may therefore show practically no inflammatory thickening or this may be pronounced; it may be pale red or bright or dark red in color, and in those of dark, sluggish skin has sometimes a purplish tinge. The characters of the scaliness in a typical case, in which the eruption has been undisturbed, and especially in those of dry skin, are, as a rule, distinctive; the scales are white or grayish white, imbricated, and with a mother-of-pearl luster. In many cases, especially in the working and dispensary classes, however, the color is apt to be a dirty gray. As to the quantity of scales, this is usually abundant, but in some cases much more so than in others. In those who perspire freely, or who have frequent recourse to bathing, the scales, or the greater part, are loosened and rubbed or drop off, so that when the patient is inspected there will present some distinctly scaly spots, some but slightly so, and many entirely free.

In rare instances the scaliness partakes measurably of the nature of a crust, appearing somewhat as if the collected imbricated scales had been glued together with some moist exudation, although such does not in reality in true and typical psoriasis ever occur. Exceptionally, however, in such atypical cases, especially in patches about the lower part of the legs, on removing the scales, the base is noted to be deep or beef red in color, and the surface presents to the touch just a suspicion of moisture. In other cases the scaliness and other features of the disease approach somewhat closely to those of an eczematous eruption. Such examples have been noted by most observers, and several have come under my own care, and indicate that midway cases, or cases presenting some features of both diseases, are, therefore, exceptionally to be met with. Such instances, and doubtless other patchy scaly cases of the psoriatic eruption, in which the scales are somewhat greasy to the touch, sometimes thin and filmy, and with, in some lesions, a slightly moist or greasy base, belong chiefly to the domain of eczema seborrhoicum. As already remarked, some of these

PLATE VI.

Psoriasis of extensive development in a male adult, of years' duration, showing the white silvery character of the scales (courtesy of Dr. J. A. Fordyce).

might very properly be called *psoriatic eczema*, and others, *seborrheic psoriasis*, or psoriasis of a seborrheic type.

The **course** of psoriasis, as may be already inferred, is in all instances essentially chronic, old patches persisting, or some fading away, and new areas developing. Sometimes fluctuations as to the extent and number of patches are noted, and occasionally the disease will partly or entirely disappear, remain in abeyance some months or a year or more, and then actively present again. In some of the milder cases there is a complete, and in almost all cases a partial, disappearance in warm weather. There are some exceptions to this, and in occasional instances the disease is worse at such season. There is never any destructive or atrophic action produced; to this statement, however, must be added the exceptional cases of scarring (Crocker), of keloidal formation (McCall Anderson, Purdon), of leukodermic spots (Hallopeau, Gasne, Rille, Caspary, Löwenheim, Unna), some of which, I believe, however, must be looked upon with suspicion, as probably purely accidental or due to treatment (Besnier). It is true, in some instances, patches will disappear, and leave for a short time a slight pale-red color or discoloration, which quickly fades; exceptionally below the knees more positive staining is noted, which may continue for a variable time. In a few recorded instances in one or two patches verrucous or papillary development has been observed, and later epithelial degenerative changes resulted; and exceptionally warty or horny formations have been noted, which in a few cases assumed epitheliomatous character; but in these instances (Pozzi, Cartaz, Hebra, White, Rosenthal, Hartzell, and others) these conditions were doubtless due, as Hartzell's collected cases would seem to show, to prolonged administration of arsenic, as the drug seems capable of provoking or inaugurating such action. In occasional instances of extensive and severe type the disease, after persisting for some years, during which time it may be more or less variable, finally develops into a temporary or permanent dermatitis exfoliativa or a condition simulating it (Devergie, Gamberini, Besnier, Crocker, Jamieson, and others). Several such cases have come under my own observation, and in 2 of these, as also observed by others, there was associated arthritis deformans; rarely, too, the nails and hair fall out (Besnier).

Subjective symptoms in psoriasis are absent in a large number of cases. In some there is slight itchiness, in others moderate in degree; less frequently it is intense, either at irregular times or continuously, and constituting the most troublesome feature of the disease. In acutely developing cases there may be a sense of soreness and tenderness. The general health does not seem to suffer, except in cases in which the itching is sufficiently intense to interfere with sleep. Digestive disturbances, exhausting mental or physical labor, and similar factors have an aggravating influence upon the eruption; on the other hand, during serious acute systemic disorders, as febrile diseases, the eruption will materially lessen or wholly disappear.

Etiology.—Observation and clinical analysis (Greenough, Pye-Smith, Bulkley, Nielsen, and others) furnish data as to some of the etiologic facts. The disease constitutes 2 to 3 per cent. of all skin cases, varying slightly in different countries; is observed in both

sexes, although occurring somewhat more frequently in males; in all ranks of society, and at almost any age except earliest infancy—although recently cases have been recorded (Kaposi, Crocker, Elliot, Rille, and others) in the first one or two years of life (the youngest case by Rille, aged six days). I have met with an extensive case at the age of three. Its first appearance is, however, exceptional before the age of five, somewhat rare before the age of seven or eight, and most common between the ages of fifteen and thirty, and again relatively infrequent after forty. The disease is, of course, often seen after this period, but usually as a continuation or a reappearance of former outbreaks. While some observers, notably Hebra, believed that it is generally seen in those of apparently good physical condition, my own experience would indicate that it is much more common in those of poor health and enfeebled constitution. Season has usually a very important influence, in almost all cases the eruption improving markedly in the summer, and in many of the lighter cases entirely disappearing, usually to reappear or get worse on the advent of cold weather, especially toward the end of winter.

Inherited rheumatic and gouty tendencies are often of seeming etiologic import (Bourdillon, Gerhardt, Bulkley, Shoemaker, Corlett, Liveing, and others), and when pronounced, often suggest the line of treatment likely to be most successful; in some extreme cases, more particularly those cases developing into dermatitis exfoliativa, and in those recorded as psoriasis rupioides, arthritic symptoms, especially of the character of arthritis deformans, have been associated. Defective kidney elimination, in such instances and in others, is also sometimes an element in those predisposed. Digestive and nutritive disturbances of all kinds are certainly provocative as to recurrences and of probable causative influence. An enfeebled state of the health is also predisposing; in women who are subjects of this disease the eruption is usually worse or recurs during the latter part of pregnancy and during the nursing period. It sometimes follows a severe systemic disease. While it is true that the attacks often occur in those of visibly robust habit, yet a careful investigation will usually disclose that this is more apparent than real; in such patients defective kidney elimination, gouty and rheumatic tendency, digestive disturbances, and in some not infrequently excessive indulgence in alcoholic stimulants, are factors of importance. Intemperate drinking of tea and coffee and excessive use of tobacco are sometimes apparent adjuvant factors. It has no relationship to struma or syphilis, although either condition, by bringing on a depraved state of health, could be of import in provoking an outbreak or recurrence in those predisposed. The ingestion of sodium borate has been credited (Gowers, Liveing) with the production of a psoriatic eruption.

That heredity is seemingly an important factor is well attested by clinical experience (E. Wilson placed it at 30 per cent.), and is a much stronger apparent factor than is generally believed. The fact that the disease is often present but to a mild degree, together with the repugnance felt toward publicity as to skin affections, doubtless frequently keeps the knowledge of its existence even from other members of the family. But in the light of our present knowledge and

changed views of leprosy and tuberculosis one can reasonably ask, I believe, whether its frequency in families is not just as much in favor of communicability—a parasitic cause—as of heredity.

Pathology.—The most probable views entertained as to the nature of the influences which start the histopathologic changes are the parasitic and the neuropathic. There is a growing belief that the disease is parasitic,[1] although as yet there is no uniformity of opinion on this point. It is true Lang believed he had found a fungus, and this, or an apparently similar one, was found by others (Wolff, Eklund, Beissel), but others again (Neisser, Rindfleisch, Majocchi, and others) failed to corroborate Lang, and Ries's exhaustive investigations show that the alleged fungus was an artificial product consisting of eleidin. Other findings—micrococci (Angelucci, De Matei), morococci (Unna), and "minute circular bodies with central dark spots loosely clustered and in dense masses" (Crocker)—are also recorded, but their significance is not established. So far, then, it can be positively stated that no specific organism has as yet been demonstrated. But, on the other hand, the clinical character and behavior of the eruption, as Lang has pointed out, are suggestive of a parasitic origin; and this view receives still further sup-

[1] Literature bearing upon the parasitic view—successful inoculation, fungus findings, apparent or possible communication, and starting from vaccination:

Inoculation: Destot (on himself) (Destot et Augagneur), "Inoculabilité du psoriasis," *Mém. et Compt. rend. de la soc. des scienc. méd. de Lyon*, vol. xxix., 1889, part ii.; *Compt. rend.*, 1890, pp. 131 and 215; and *Province médicale*, June 8, 1889 (referred to in Brocq's letter, *Jour. Cutan. Dis.*, vol. vii., 1889, p. 473); Lassar (on animals), *Berlin. klin. Wochenschr.*, 1885, p. 771; Tommasoli (on animals), quoted by Nielsen, *loc. cit.*

Alleged fungus findings: Lang, *Archiv*, 1878, p. 443; Wolff, *ibid.*, 1884, p. 337; Eklund, *Annales*, 1883, p. 197; Beissel, *Monatshefte*, vol. xv., 1886, p. 385. As stated in the text, Ries's investigations (*Archiv*, vol. xv., 1888, p. 871) not only negative these findings, but show them to have been wrongly interpreted.

Evidence suggestive of apparent contagiousness or communicability: Poor (6 patients with father and mother both affected), *Vierteljahresschr. f. prak. Heilkunde*, Prag, 1878, p. 103, Original-Aufsätze; McCall Anderson (family of father, mother, 2 daughters, and son, mother only free; and an instance where husband exhibited the disease after living some years with an affected wife), *Psoriasis and Lepra*, London, 1865, pp. 12 and 37; Unna (3 children of a family after employment of affected maid), "Congrès périodique international des sciences médicales," *Compte-rendu*, Copenhagen, 1884, vol. iii., Section de Derm. et de Syph. (discussion), p. 115; Hammer (primary attack, father and daughter at same time, in a family where mother and aunt had had the disease for some time), *Mittheilung. aus der med. Klinik zu Wurzburg*, vol. ii., 1886, pp. 404, 405; Nielsen (one instance where mother first affected long after daughter had exhibited the disease), *loc. cit.*, p. 374; Aubert (2 cases where husband had psoriasis and wife developed it later), discussion, Destot et Augagneur, *loc. cit.*, p. 132; Augagneur (2 patients, one with trade eczema, the other with a dermatitis, in hospital, close by psoriasis cases, subsequently showed psoriasis), *ibid.*; Beissel (2 brothers first showed disease while traveling; and 2 cousins apparently contracting it from a grandfather), *Aix-la-Chapelle as a Health Resort*, London, 1892, p. 121; Méneau (psoriasis in girl of eight, followed by psoriasis in scalp of younger sister three years later, who used the same comb), *Journal de médicine de Bordeaux*, Dec. 15, 1895; Cantrell (first in boy aged twelve, several years later in sister, and a year later in the mother; in man aged eighteen, later in mother aged fifty), *Med. Record*, vol. xlix., 1896, p. 627.

After vaccination (usually starting from vaccinated point, and several days or shortly after this operation, and usually in families in which psoriasis had not yet presented); Klamann (1 case), *Jahrbuch für Kinderheilkunde*, vol. xiv., 1879, p. 371; Campbell (1 case—probable), *Arch. Derm.*, 1877, p. 311; Rohé (2 cases), *Jour. Cutan. Dis.*, 1883, p. 11; Piffard (1 case), *ibid.*, p. 119; T. F. Wood (2 cases—sisters; disease previously existed in a brother), *ibid.*, p. 161; Hyde (1 case—referred to in discussion of Rohés cases), *ibid.*, p. 14; Gaskoin (5 cases), "On Psoriasis or Lepra," 1875, p. 49, and appendix; Chambard (1 case), *Annales*, 1895, p. 498; Rioblanc (1 case), *ibid.*, 1895, p. 880.

port in those cases of apparent communication (Unna, Hammer, Aubert, and others), and also in those in which the disease started from vaccination (Klamann, Rohé, Piffard, Wood, Hyde, Chambard, and others); and this seems still further strengthened by the few apparently successful inoculation experiments on animals (Lassar, Tommasoli), and in one instance on man (Destot). The fact, too, that new psoriasis efflorescences are apt to appear at points of abrasion is likewise suggestive, although this may also be used in support of the neurotic view. Upon the whole, I believe it is in the field of pathogenic organisms that the true exciting agent of this disease is to be found, the various factors—age, season, gouty and rheumatic tendencies, debility, etc.—being contributory in preparing the "soil" for successful parasitic invasion.

The other favorite theory of the production of psoriasis is the neuropathic,[1] and it has, indeed, much in its favor. In its support are mentioned the following clinical observations: Relation or association with arthritic disease; heredity; its appearance, and sometimes starting at points of cutaneous irritation; its occurrence, though rare, over peripheral nerve distribution, and its unilateral distribution, already referred to; its occurrence during pregnancy and lactation; the observation of outbreaks, in those predisposed, after emotional attacks (Leloir); the association, though rare, with lessened tactile and thermic sense (Rendu) in the patches; the observation, in some instances, of associated sciatica and pricking sensations in the ends of the fingers and toes (Hebra)—all would seem to point toward a neuropathic origin. The suggestions that it is due to reflected irritation from the skin to the spinal center (Kuznitzky), to purely external mechanical causes (Köbner), that it is an infection (Bernay and Piéry) due to autotoxin poisoning (Tommasoli) and that there is primarily a weakened vascular tone (Unna), or functionally weak nervous centers regulating the nutrition of the skin (Weyl), also bear upon the neuropathic theory, but have as yet but little basis of support.

FIG. 44.—Psoriasis, from a small lesion in early stage, showing considerable hyperplasia of the rete, especially in its interpapillary portion. Blood-vessels of the papillæ are already more or less dilated (courtesy of Dr. A. R. Robinson).

Upon the character of the histologic changes[2] evoked investiga-

[1] Some literature bearing upon neuropathic view: Kuznitzky, *Archiv*, vol. xxxviii., 1897, p. 405; and *Monatshefte*, vol. xxiii., 1896, p. 402; Polotebnoff, *Monatshefte*, Ergänzungsheft i., 1891—an excellent summary of this paper in *Brit. Jour. Derm.*, 1891, p. 328; Bourdillon, "Psoriasis et arthropathies," *Thèse de Paris*, 1888; Leloir, *Annales*, 1887, p. 374; Rendu, *ibid.*, vol. vi., 1874–75, p. 24; Thibiérge, *ibid.*, 1893, p. 1185; Strauss, *Berlin. klin. Wochenschr.*, 1898, p. 617; Hallopeau et Gasne, *Annales*, 1898, p. 690.

[2] Some pertinent literature references: Robinson, *New York Med. Jour.*, July, 1878, vol. xxviii.; Jamieson, *Edinburgh Med. Jour.*, Jan., 1879; Thin, *Brit. Med. Jour.*, Sept. 4, 1880, and July 30, 1881; Crocker, *Treatise on Diseases of the Skin*, 1888, and second edit., 1892; Ries, *Archiv*, vol. xv., 1888, pp. 521, 685, 871 (besides presenting

tions (Wertheim, Neumann, Hebra, Kaposi, Auspitz, Bosellini, Jamieson, Robinson, Thin, Crocker, Unna, Jarisch, Herxheimer, Ries, Kopytowski, and others) are fairly well agreed, although there is a difference of opinion as to whether the process is primarily a hyperplasia of the rete (most strongly supported by Jamieson, Robinson, Thin), with induced secondary inflammatory changes, or whether it originates as an inflammation of the papillary layer. At all events, among the conditions noted are: A hyperplasia of the rete, except directly over the papillæ; the latter are enlarged both laterally and upward; there is a dipping-down of the interpapillary processes, enlargement of the blood-vessels; cell extravasation in the upper corium, especially in the papillary layer and around the hair-follicles,

FIG. 45.—Psoriasis—from a chronic patch—showing marked hyperplasia of the rete extending deeply downward as interpapillary prolongations, thus giving the papillæ increased length. The secondary inflammatory changes in the corium are seen, with enlargement of the blood-vessels (*a*), in the cutis proper as well as the papillæ, and extensive (*b*, *b*) perivascular cell-infiltration (courtesy of Dr. A. R. Robinson).

sweat-gland ducts, and the blood-vessels. Serous exudation, cell exudation, and congestion, together with the enlargement of the papillæ, furnish the thickened and elevated inflammatory base. The rete cells undergo rapid keratinization, giving rise to the enormous increase of the horny layer. Recent investigations (Munro), which, however, lack confirmation, disclose the first step in the formation of

original work, this is a most admirable and critical review of the entire subject of the investigations bearing upon morbid anatomy and pathogeny, with bibliography); Schutz, *Archiv*, vol. xxiv., 1892, p. 739; Munro, *Annales*, 1898, p. 961; Kopytowski, *ibid.*, 1899, p. 765; Bosellini, *Monatshefte*, vol. xxix., 1899, p. 301; Jarisch, *Die Hautkrankheiten*, Vienna, 1900.

a lesion to be a minute erosion of the epidermis, in which are noted collections of leukocytes, producing microscopic miliary abscesses, the subsequent changes being due to the epidermic reaction. Nardecchia has studied the disease in alcoholics, and has found that the usual blood-vessel changes of the latter are made much more pronounced by the psoriatic process.

Diagnosis.—A well-developed example of psoriasis can scarcely be mistaken for any other eruption. The scattered, rounded, sharply defined, variously sized, slightly elevated, scaly plaques, with special preference for the extensor surfaces, particularly the knees and elbows, and not infrequently the presence of patches on the scalp, particularly just overstepping the hair-border on to the forehead and on to the mastoid region; the usually non-involvement or only slight or moderate involvement of the face, and absence of eruption on the palms and soles; the invariably dry nature of the disease, its course and its history, which often includes recurrences; together with the evolution and uniform character of the lesions—all go to make up a picture that is diagnostic. Ill-developed, rapidly developing, and atypical cases may occasionally give rise to difficulty, but such instances are relatively rare. The disease is to be distinguished chiefly from the papulosquamous syphiloderm, eczema, eczema seborrhoicum, seborrhea, lichen planus, pityriasis rosea, and tinea circinata.

The papulosquamous syphiloderm probably bears the closest resemblance. The syphilitic eruption, however, shows no special preference for the extensor surfaces; on the contrary, it is not infrequently more marked on the flexors; patches are usually to be seen upon the face, and frequently on the palms and soles; lesions are also frequent about the anus and genitalia, where they often become abraded, macerated, and moist; they are usually much less scaly, and instead of bright or dark inflammatory redness, have a dull ham or coppery hue: there is distinct infiltration; there are generally several or more characteristic papules to be found, which exhibit no tendency to scale-production; and not infrequently a few scattered pustules; the scales are dirty gray or brownish gray, rarely ever shining, white, and lustrous; the patches usually spring up the size they retain with but little tendency to peripheral extension; they are very rarely larger than a dime, or at the most a silver quarter. Moreover, the disease being a manifestation of the active or secondary stage of syphilis, other concomitant symptoms, such as sore throat, mucous patches, glandular enlargement, rheumatic pains, falling out of the hair, with often the history of the initial lesion, are one, several, or all always present. It will be noted that these various features and characters are materially different from those of psoriasis. Further, the papulosquamous syphiloderm rarely itches, except in the negro, while psoriasis frequently does; in short, the presence of moderate or intense itching would bear conclusively against syphilis; its absence, however, would have no weight, inasmuch as it is not noted in a large proportion of psoriasis cases.

The tuberculosquamous syphilid is a late or tertiary manifestation, which may occasionally show considerable scaliness, but the disease is usually limited to one or two regions, forming one or more

groups of circinate or serpiginous configuration, and generally shows ulcerative tendency and scarring or pigmentation and atrophy. It is rarely located on the favorite psoriasis regions, but is frequently seen on the face.

Squamous eczema can also be confused with psoriasis, but the former never shows such small, rounded, sharply defined patches; but a few areas generally presenting, and these, as a rule, large; it rarely has such scattered distribution; it favors the flexor aspects, and especially the flexures; the individual areas, even when small, usually result from an aggregation of papules, some of which can be often seen at the border; or it arises from a thickened erythematous patch. The history and course of the individual areas are, therefore, different; there is usually a history or the presence of oozing in eczema, especially if the disease is at all extensive; moreover, the hands and face frequently show the disease, regions which are only occasionally or slightly invaded in psoriasis. Eczema is almost always intensely itchy; psoriasis rarely so, and often free from this symptom.

The so-called seborrheic eczema (eczema seborrhoicum) may show greater resemblance than ordinary eczema, inasmuch as it is often patchy in character; the scales are, however, less abundant, greasy, and the base beneath is not infrequently greasy or moist; moreover, seborrheic eczema frequently takes its starting-point from an ordinary seborrhea (dandruff) of the scalp or of the eyebrows, and usually involves the upper part of the body first; the flexures, too, often show the disease, and seborrheic patches with prolongations into the gland-ducts can be sometimes found over the sternum and between the scapulæ; in these latter regions, too, the disease is often primarily ring-like or segmental in shape. The patches in seborrheic eczema may arise the size they retain; those of psoriasis always develop by peripheral extension from a small lesion.

Psoriasis of the scalp, especially when the inflammatory action is slight, may be confounded with seborrhea of that region, but from the average case of the latter it is distinguished by its scattered patch-formation, its often projecting just beyond the hairy border, and by the dry character of its scales and its inflammatory element. Seborrhea is usually diffused over the entire scalp, with little if any tendency to patch-formation. Moreover, in cases of psoriasis of the scalp, in many instances small lesions are often to be found on the elbows and knees.

Lichen planus differs from psoriasis in that the papular lesions are flattened, angular in outline, usually with central depression, and dark red or violaceous in color. The lesions rarely increase in size, and never materially, the scaly patches of the disease resulting from the appearance of new lesions close to the old, finally becoming so crowded as to form solid aggregations or patches; but round about such patches, and usually elsewhere, the typical papule is always to be found. The patches, too, are violaceous or purplish in color, and show much more thickening or infiltration than observed in psoriasis. Moreover, the flexor surfaces of the wrists and forearms and the leg near the ankle are favorite sites, with but little if any disposition

to appear on the extensors of the knees and elbows or upon the scalp.

Pityriasis rosea is a much less inflammatory disease than psoriasis, and the eruption comes out somewhat rapidly, reaching its full development in the course of one to two weeks, and is chiefly limited to the trunk and upper parts of the arms and legs. The extensor surfaces are not especially favored, and the elbows and knees rarely show patches unless the eruption is unusually extensive. The scalp is never involved. Some of the patches tend to become somewhat circinate almost from the beginning. The scaliness is relatively slight, and the eruption is of a duller color, and frequently with a yellowish or salmon tinge. Moreover, the process is an extremely superficial one; and the malady tends to spontaneous disappearance in the course of one to two months.

The annular patches of psoriasis due to the process of involution resemble ringworm to some extent, but the scaliness is much greater, the inflammatory thickening more pronounced. Moreover, such lesions are usually numerous, and there are also found many other patches in which the clearing of the center has not developed. In ringworm seldom more than several patches are seen, and the border is rarely so pronounced, and often is made up of contiguous papules or vesicopapules. Moreover, the history and distribution are wholly different. In obscure cases the microscopic examination of the scrapings could be resorted to, but this is rarely, if ever, necessary.

Lupus erythematosus patches, if carelessly examined, may suggest psoriasis, but the former is seen almost always about the face, and seldom elsewhere, whereas psoriasis patches on the face are rare and seen only in connection with the disease on other parts of the body. The patches of lupus erythematosus are, moreover, entirely different in history and character. Psoriasis can scarcely be confounded with dermatitis exfoliativa, or pityriasis rubra pilaris, as their clinical characters, history, and course are materially different.

Prognosis.—Psoriasis is a disease in which an unqualified opinion as to the future cannot be safely ventured. The prognosis is, as a rule, favorable as to the immediate eruption, and invariably so in the earlier attacks. In fact, almost all attacks can be relieved, some more readily than others, provided the patient persists, but this persistence is, unfortunately, often lacking. Freedom from recurrences, with possibly rare exceptions, is not to be expected. The patient should be clearly informed on this point, as timely measures as soon as the malady again first presents will frequently head off an extensive outbreak. The intervals may be long or short—months or several years or more. In occasional cases, however, the attack is scarcely at end before another appears. Subsequent attacks, especially when well advanced, are less rapidly responsive than the first eruption. As later life is approached, however, the disease often becomes less active, and may entirely disappear. In some patients prolonged, and exceptionally more or less permanent, freedom from the disease is noted. The health is rarely materially affected by the eruption, except in those instances, relatively infrequent, in which itching is

PLATE VII.

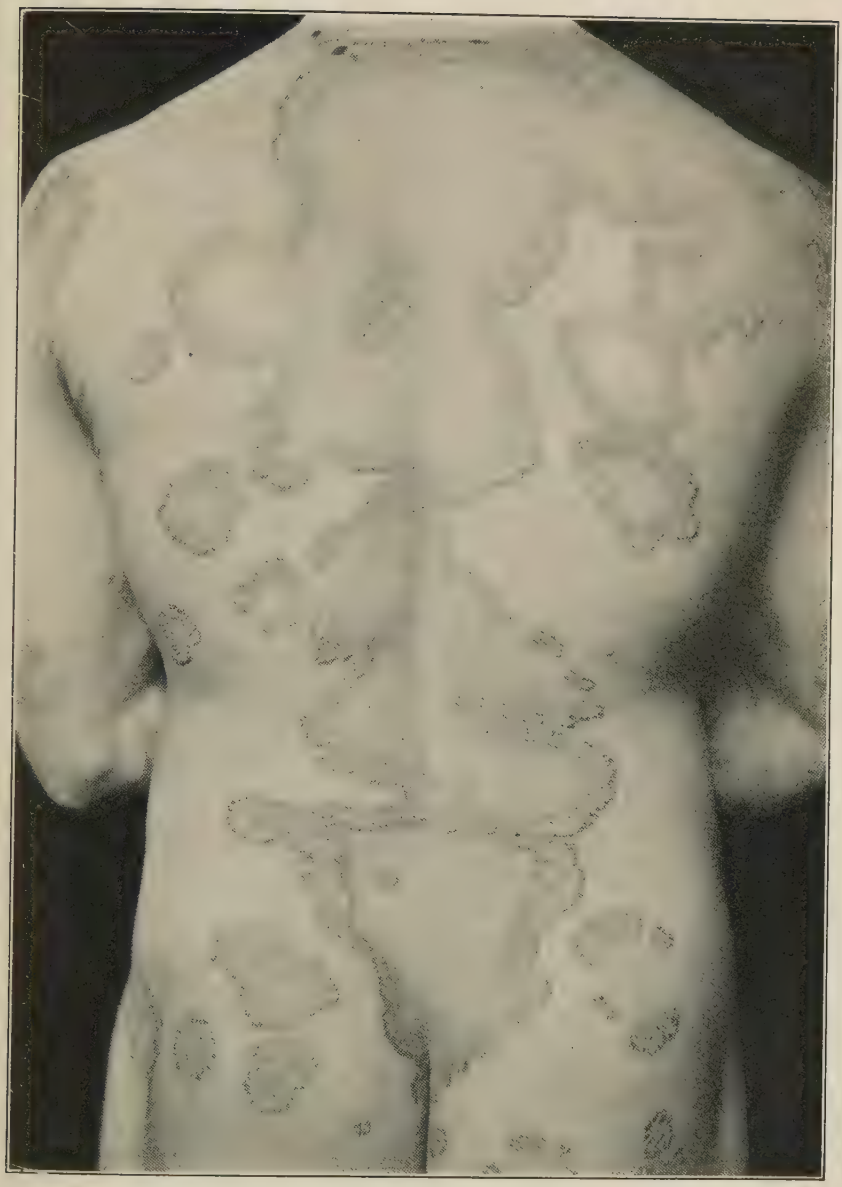

Psoriasis—unusually marked tendency to gyrate and circinate variety on trunk; on the extremities the ordinary scattered, rounded patches. Scales have been partly removed by bathing. Duration, several years; subject, male adult aged thirty.

sufficiently intense to deprive the patient of restful sleep, and thus bring about a condition of nervous and physical debility. In exceptional instances, in severe and oft-recurrent or continuous cases, the disease may finally develop into a true dermatitis exfoliativa, and necessarily assume a more serious aspect.

The cooperation of the patient will often have a material influence in rendering the disease less active and the attacks less frequent; it is a matter of observation that whatever depresses or deranges the equilibrium of the general health will have some weight in bringing on an attack or making the eruption worse, and patients should, therefore, guard against all factors which favor such tendencies.

Treatment.[1]—Whatever plan, both in external and internal treatment, is instituted, it should be continued sufficiently long to judge of its probable effects, unless aggravation is noted to ensue. In most cases a change from one plan to another is often necessary, especially in the more extensive and rebellious cases.

In the systemic treatment of psoriasis, as in almost all of the chronic skin diseases, each individual case must receive careful study, for very often it is noted that the patient is in need of treatment fully as much for himself as for the eruption; all possible etiologic factors should be kept in mind. His diet should be supervised, alcoholic stimulants practically withheld, except in old debilitated subjects; smoking kept within moderate limits or interdicted, and an excess of tea, coffee, and richly seasoned food avoided. In many cases it will not be necessary to interfere with the diet beyond limiting it to easily digested food; in others, especially in those of a plethoric habit, meat should be cut down or for a time prohibited; in still others, in anemic individuals, a rather liberal dietary should be allowed, with a full quantity of meat. The state of the nervous system should be inquired into, and all depressing influences guarded against. In fact, the patient is to be placed in as perfect a state of health as it is possible to attain. Open-air pleasures and sufficient exercise, systematically taken, will, in some individuals, have a material effect in aiding the medicinal treatment. Living as much as possible in the sunlight is beneficial (Hyde and Montgomery)—psoriasis is not common upon exposed parts.

In the constitutional treatment, therefore, in many instances, each

[1] Some literature concerning constitutional treatment: Greve (potassium iodid), *Tidsskrift for praktisk Medicin*, 1881, No. 16, abstract of which is in *Archiv*, 1882, p. 554; Haslund (potassium iodid), *ibid.*, 1887, pp. 677 and 708; Bramwell (thyroid), *Brit. Med. Jour.*, Oct. 28, 1893, p. 934, and *Brit. Jour. Derm.*, 1894, p. 193; G. T. Jackson (thyroid), *Jour. Cutan. Dis.*, 1894, p. 409 (with bibliography); Thibiérge (thyroid), *Annales*, 1895, p. 760; Paschkis and Grosz (iodothyrin) (with report of cases and a critical review of the entire literature of the thyroid treatment, with full bibliography, including also that of potassium iodid), *Wien. klin. Rundschau*, 1896, pp. 609, 629, 646, 664; Passavant (meat diet), *Archiv für Heilkunde*, 1867, p. 251; Crocker (salicin and salicylates), *Lancet*, June 8, 1895, p. 193; Brault (mercurial injections), *Annales*, vol. vi., 1895, p. 676; Mapother (mercurial treatment), *Brit. Med. Jour.*, Jan. 17, 1891; Danlos (cacodylic acid), *Annales*, 1897, pp. 198, 559; Gijselman (sodium cacodylate), *Wien. klin. Wochenschr.*, 1899, p. 363; Rille (sodium cacodylate), *Monatshefte*, vol. xxviii., 1899, p. 140; Murrell (sodium cacodylate) (untoward action, letter communication, *Lancet*, Dec. 29, 1900; Balzer et Griffin (cacodylic acid) (a resulting exfoliative dermatitis), *Annales*. 1897, p. 732.

case must be handled upon its merits, and upon this basis much good can be done, and often without resorting to the several special remedies, which, while of service in removing the eruption, are often detrimental to digestion. If constipation is present, it is to be corrected by suitable laxatives, preferably the salines, and these are especially of service in the acute and rapidly developing disease. Indigestion is to be treated with tonics, digestives, acids, or mild alkalies, as may seem indicated, and the diet regulated accordingly. Neurasthenic conditions are to be modified or removed by the use of tonics, such as strychnin, quinin, iron, and the sedatives, such as lupulin, asafetida, potassium bromid, and ergot, and, if deemed necessary, by general galvanization, faradization, and static electricity. In gouty conditions the alkalies are to be employed, sodium salicylate, potassium bicarbonate, potassium acetate, and liquor potassæ being those most commonly prescribed; potassium iodid in full doses also will act well in some gouty cases. If the general nutrition is below par, —as, for instance, in the attacks of psoriasis occurring or relapsing during pregnancy and lactation,—tonics, and especially cod-liver oil and the hypophosphites, should be advised; the oil, which is often extremely valuable, can be given in doses of a half to one or two teaspoonfuls, either pure, in emulsion, or in capsules, the last method being ordinarily the most pleasant.

In many cases of the disease, however, it will be difficult to discover any material fault in the general health, and dependence is then to be placed on the special remedies alone. Thus there are several drugs that experience has shown to be of special value. These are arsenic, ordinary alkalies, sodium salicylate, salicin, potassium iodid, thyroid, copaiba and turpentine oils, and carbolic acid. Of these, *arsenic* is the most valuable, and the most constant in its effects. Patients are met with, however, who are intolerant to even small doses. In all fresh—first—outbreaks of this disease, if not of an acutely inflammatory character, the judicious administration of this drug will often bring about a surprising improvement in a short time, and rapidly cause an entire disappearance of the eruption. In old-standing cases or in recurrent attacks in those who have had no systematic treatment and who have probably never been regularly treated with the drug, the same favorable effect is often noted. In acutely inflammatory cases or attacks, especially when the disease is rapidly spreading, the drug may do actual harm, in that the inflammatory symptoms are increased and fresh outcroppings stimulated. In recurrent attacks in those who have previously been subjected to arsenical treatment, the drug seems to lack its earlier power for good, even large doses often failing to influence the eruption favorably. It is prescribed in several forms: as Fowler's solution, arseniate of sodium solution, arsenious acid, and sodium cacodylate, the first named most commonly. The dose varies in different individuals, the beginning dose being usually 3 minims (0.2) of the solution of potassium arsenite, or its equivalent of the other preparations, and increasing slowly, if the disease is not being favorably influenced, to 5 minims (0.33) three times daily. In rare instances the dose of 10 minims (0.66) and larger quantity may be safely reached and continued. As a rule, the

dose is increased until its good effect upon the eruption is noted, and then kept at the same dosage, intermitting for a day or two if disturbing symptoms arise, and then beginning again at a slightly smaller dose, and increasing up to the former quantity. The drug should be continued one or two months after the eruption has disappeared, but in somewhat smaller amount. If moderate doses fail to benefit, the chances are that larger doses will prove futile also, or only benefit the eruption temporarily and at the expense of gastric and intestinal disturbance or nervous symptoms traceable to the treatment. The drug, therefore, while often powerful for good if judiciously administered, may, if care is not exercised, be productive of harm. Occasionally its prolonged administration in large dosage produces, in addition to possible digestive and nervous disturbance, a more or less general pigmentation of the skin, which, however, gradually subsides when the drug is discontinued; palmar and plantar epidermic thickening or callosities and wart-like horny formations may also exceptionally result, and the latter may even undergo epithelial degeneration.

The solution of sodium arseniate is, I believe, less apt to disturb the stomach, and seems equally efficacious, and should be prescribed in those of weak digestion in preference to Fowler's solution. Arsenious acid is a convenient form, inasmuch as it can be readily prescribed in pills; the dose should be at the start about $\frac{1}{40}$ to $\frac{1}{30}$ of a grain (0.0016 to 0.0021), and increased to $\frac{1}{20}$ (0.0032), and even, if necessary and there are no contraindications, up to $\frac{1}{10}$ grain (0.0065) or more three times daily. It, as the other arsenical preparations, can be given along with strychnin, quinin, and iron, if indicated. A favorite method of prescribing arsenious acid is as the so-called Asiatic pill, made up of $\frac{1}{20}$ to $\frac{1}{10}$ grain (0.0032–0.0065) arsenious acid and $\frac{1}{2}$ grain (0.033) black pepper, with acacia or licorice root as the excipient. Sodium cacodylate, one of the latest forms of arsenic to be extolled (Jochheim, Danlos, Rille), has shown no advantage over those already named (Gijselman) and it is not as free from danger (Balzer and Griffin, Murrell) as at first alleged; its dose is from $\frac{1}{4}$ to 3 grains (0.015–0.2) three times daily. In occasional instances, as the result of arsenical treatment, pigmentation is noted on the sites of the plaques after their disappearance.

The arsenical preparations are usually administered by the mouth, and this is the most convenient method, but its administration by subcutaneous injection is usually more rapid in its results, but it is a somewhat painful method, and requires great care to avoid abscess formation. The solutions of sodium arseniate, potassium arsenite, and sodium cacodylate are employed. I have occasionally used this method with advantage in obstinate cases, employing Fowler's solution, sterilized, and with $\frac{1}{8}$ grain (0.008) carbolic acid to each dose of 5 minims (0.33), beginning at first with 3 minims (0.2), with 4 or 5 parts water, and increasing gradually, giving a daily injection.

The *alkalies* are usually most promising in cases in which there is an apparent gouty or rheumatic predisposition, but, irrespective of these conditions, in patients of plethoric habit and of apparent robust health, and especially in the markedly inflammatory types and those of acute and rapid development of the disease, the administration of these remedies, especially liquor potassæ (Thomson, Bell, Duhring),

will frequently have a marked influence toward promoting the disappearance of the eruption; it is not appropriate for those of anemic tendency or condition, nor for those of enfeebled health. The dose of liquor potassæ should be, at first, 10 minims (0.65) three times daily, rapidly increasing to 20 or even 30 minims (1.33 to 2.), always being taken largely diluted. In established cases in such patients, even when the eruption is of a decidedly inflammatory aspect, a prescription, such as the following, containing both the potassium arsenite solution and liquor potassæ, can often be used with advantage, and can also be prescribed cautiously in cases in which the development is still active:

℞. Liq. potass. arsenit., fʒij–iij (8.–12.);
Liq. potassæ, fʒiv–fʒj (16.–32.);
Aquæ menth. pip., q. s. ad fʒiij (96.).
Sig.—A teaspoonful in at least a half tumblerful of water after each meal.

Potassium acetate is another alkali, as well as a diuretic, that has gained some reputation, in doses of from 10 to 30 grains (0.65 to 2.) three times daily. Sodium salicylate and salicin (Crocker) are occasionally of decided benefit, and not necessarily limited to those of arthritic tendencies nor to any special class of cases, although more valuable in the arthritic, the former doubtless by its alkaline character. Sodium salicylate is given in dosage from 5 to 20 grains (0.33 to 1.33), and salicin, from 10 to 30 grains (0.65 to 2.), three times daily, beginning with the smaller dose, and, if well borne, increasing. Salicin is less apt to disturb digestion than the sodium salicylate. In place of the latter, ammonium salicylate can be given. Almost all these alkaline remedies are diuretic, and this probably also measurably aids in their favorable action.

Potassium iodid, in doses of from 10 to 120 grains (0.65 to 4.) or more three times a day, has in recent years been extolled (Greve, Boeck, Haslund, Hillebrand) as having a specific effect, which is probably partly, although not wholly, due to its alkaline character. While, in my experience, its favorable action is far from being so constant as claimed for it, it is occasionally of distinct service. The larger doses are, however, usually required, and, of course, while taking such, the patient needs careful supervision.

Oil of turpentine (Crocker), oil of copaiba (Hardy, Simms, McCall Anderson), and similar remedies have likewise acted well in some cases, given in doses of from 10 to 30 minims (0.65 to 2.). They are best given in emulsion, largely diluted, and during their use frequent potations of barley-water or other diluent should be taken to prevent any irritating action upon the kidneys. In several extensive cases under my care the oil of copaiba proved effective in reducing the extent of the disease, but it often fails absolutely. The wine of antimony has also been commended (Malcolm Morris) in cases of an acute type, in the dose of from 5 to 10 minims (0.33 to 0.65) three times daily; it should not be given in those cases in which there is general systemic depression, and its administration should always be carefully watched.

Thyroid feeding several years back was strongly supported (Bramwell) by the report of several brilliant cures, but the experience of others (Thibiérge, Zarubin, Jarisch, Jackson, and others) subsequently has been, upon the whole, unfavorable, and the remedy is now rarely used for this disease. My own observations are in accord with its negative action in most cases, but it has been of service in a few instances in which other plans had failed, so I believe it is entitled to be considered as a reserve remedy for trial in rebellious cases. The dose should be small at first—½ to 1 grain (0.033 to 0.065) of the desiccated gland, and, if necessary and well borne, increasing to 5 grains (0.33) or more three times daily. Its use, however, requires caution, and the remedy should be watched and discontinued if untoward symptoms arise. Iodothyrin, an equivalent preparation, has also been commended (Paschkis and Grosz). I have occasionally seen benefit from Donovan's solution. The subcutaneous injection of mercury has been commended by Brault and Besnier.

Carbolic acid, which had the sanction of Kaposi, has served me in some cases, but it must be administered in full dosage. It is best administered in solution in glycerin and water (1 to 3), each dram (4.) containing two grains (0.13) of chemically pure carbolic acid; beginning with a teaspoonful (given diluted in a third to a half tumblerful of water or more) three times daily, and after a few days, the same dose four times daily, and so gradually up to six times daily; and then, if no improvement, more slowly, adding to each dose till 20 to 30 grains (1.25–2) are given daily. Signs of toxic action should be watched for, but if the drug is pure it is unusual to see any such action. It is contraindicated in those with kidney disease. Tar is another remedy that at one time had some support, and it probably owes its alleged favorable action to its derivative, carbolic acid. Pilocarpin is also of value in some cases.

The various alkaline and sulphur springs, especially the former, are also of service, partly by the fact that change to other scenery, climate, etc., is often of benefit to the patient's general health, but also by the free drinking of the waters and the frequent baths indulged in.

The **external treatment** of psoriasis is demanded in almost every instance. The exceptions are those cases in which the inflammatory symptoms are slight and the patches comparatively few in number, and, for the most part, vary from the size of a pin-head to that of a pea. In such cases a result is very often achieved by the internal treatment, with possibly a warm plain or alkaline bath daily or three or four times weekly. As a rule, however, in moderate and well-marked cases external treatment is essential; and even in instances in which the constitutional management of the case seems to be bringing about a favorable result, external remedies will materially aid in shortening the course of the disease. In fact, in those instances, fortunately not numerous, in which constitutional medication has absolutely no influence, external measures are the sole recourse, and the treatment of psoriasis without such aid would be only too frequently disappointing. The primary object in view is to rid the patches of

the scaliness. In many cases in which the scales are but slightly adherent this is accomplished by the baths to be referred to. In the mild cases it is well to prescribe a daily ordinary bath ; if the scales remain adherent or are only partly removed, the bath may be made alkaline by the addition of sodium carbonate, sodium biborate, or sodium bicarbonate, from 2 to 6 ounces (64. to 192.) to the bath ; a much more efficient alkaline bath in adherent scaly cases is one made with sal ammoniac in the same proportion. The patient remains in this from ten to thirty minutes, and rubs himself dry with a soft towel. If the skin is harsh and dry, or if it becomes so after several days' use of the alkaline baths, an ointment consisting of petrolatum or lard, or equal parts of these, with from 10 to 20 grains (0.65 to 1.33) of salicylic acid to the ounce (32.), is rubbed in after each bath ; if the lesions are small, the ointment is simply rubbed over the affected regions, without reference to the individual spots, and the skin then wiped off. If some of the lesions are large, into these the ointment, or a stronger one, with 20 to 40 grains (1.33 to 2.65) to the ounce (32.), can be rubbed. In many of the milder cases this plan, in conjunction with proper internal treatment, will bring about a disappearance of the eruption. In such instances if there is any eruption upon exposed parts, this same salve can be used, or, preferably, as usually more rapid in effect, an ointment of white precipitate, from 20 to 60 grains (1.33 to 4.) to the ounce (32.) ; this can be rubbed into these patches twice daily.

In the more severe and extensive cases this same plan of bath treatment can be carried out, followed by the general application of the salicylated ointment if necessary, and the application of one of the stronger remedies to be referred to, to the larger patches individually. In fact, in all instances the baths have in view, in addition to some possible therapeutic effect, a removal of the scales, inasmuch as smearing or painting even an active remedy over the scales will have no effect upon the disease. In these more severe and more markedly scaly cases the above baths, with frequent anointing with the salve named, or with a bland oil, as olive or almond oil, will often suffice to remove the scales, but it is sometimes necessary to use sapo viridis along with the baths. Or the Turkish or home cabinet steam or hot-air bath can be used for this purpose, these latter sometimes having a material therapeutic influence as well. In exceptional cases linen rags or cotton soaked in oil can be, during the interim of the baths, kept wrapped around the worst parts and enveloped with waxed paper or other impermeable dressing. In extreme cases of markedly adherent scale accumulation, more especially when the bath plans cannot be conveniently employed, rubber-cloth underwear can be worn for several hours daily, which produces active sweat secretion and consequent softening and maceration. Some skins are readily irritated by it, however ; in others of sluggish integument such treatment alone, if persisted in, will sometimes suffice to remove the disease ; there is less chance of irritation if a thin garment is worn between the rubber and the skin. In cases in which there are but few areas, one or several applications of a 3 to 6 per cent. alcoholic solution of salicylic acid will permit the scales to be easily rubbed off or scraped off with a curet.

With these general preliminary remarks as to the removal of the scales, management of the milder cases, etc., the various more active remedies most commonly employed in the average cases met with, and which have often rendered me more or less satisfactory service, can be individually referred to. Aristol is a mild one, and in irritable cases sometimes valuable, prescribed as a 5 to 10 per cent. ointment or a 10 per cent. etheric solution; if the latter, it is painted on and coated over with a film of collodion, and repeated when it becomes detached. In some instances I have used on the larger patches iodin tincture full strength or diluted with alcohol, depending upon the sensitiveness of the skin; this is painted on as a light coating and rapidly dries; if desired, over this can be painted a coating of collodion. While this treatment is being carried out with these larger areas the general plan already outlined can be continued; the painting is renewed as soon as the film or iodin coating has come off, provided there is no irritation, in which event the repainting is postponed. When the patches show no reaction from the iodin painting and no improvement, two or three coats can be put on at the one time. It sometimes acts satisfactorily.

Tar, in its various forms and varieties, has long been in use as an external remedy in the treatment of psoriasis, and, all things considered, it is an extremely valuable one. In rare instances of extensive application toxic symptoms from absorption have arisen, but these subside rapidly upon withdrawal of the drug. Although I use tar freely in the cases of psoriasis in the skin wards of the Philadelphia Hospital, I have never observed such an accident. Its positive odor makes it somewhat objectionable for every-day practice, but this does not hold as an objection to the coal-tar preparation, and with this latter the odor soon disappears. This preparation, too, will often agree where, from sensitiveness of the skin or idiosyncrasy, the other tar applications irritate. It is much less active, however, than the wood-tars, but in mild and moderate cases it has often proved of benefit. The proprietary preparation is known under the name of liquor carbonis detergens, but an equally good or superior one can be made from the formula given under eczema, and is the one most commonly used by my Philadelphia colleagues and myself. It may be applied as an ointment, 2 drams (8.) to the ounce (32.) of simple cerate, or with lanolin and simple cerate; or it may be rubbed in as a wash, diluted with several parts of water; the pure solution may sometimes be used without producing irritation. Another method of employing this coal-tar solution, which, however, makes a much stronger application, is as a mixture with an equal quantity of Vleminckx's solution (liquor calcis sulphuratæ), another active psoriasis remedy, diluting with from one to several parts of water as may be required; occasionally it may be used pure. When this, or either singly, is used as a wash, a mild ointment should be applied after each application, otherwise the skin tends to become harsh and dry.

The other tar preparations—the vegetable, or wood, tars—may be prescribed in various ways. The most common one is as the official tar ointment, at first weakened with lard or petrolatum—2 parts of tar ointment to 6 parts of the diluent, and if necessary gradually increasing the proportion, sometimes finally using the pure tar oint-

ment; this is the most active probably, but the most offensive as to odor and color. Another form, and that most frequently prescribed, is as the oil of cade (oleum cadinum) or the oil of birch (oleum rusci), 1 or 2 drams (4. to 8.) to the ounce (32.) of lard, petrolatum, or simple cerate. In other cases the tar oil, the oil of cade, or oil of birch, weakened with 1 or 2 parts of alcohol or liquid petrolatum, may be used. The application selected is to be thoroughly rubbed, in small quantity, into the affected areas, the excess wiped off, and a dusting-powder applied. Another mode of employing tar which may occasionally be used with satisfaction is in the form of a paint, 1 dram (4.) of the oil of tar, oil of cade, or oil of birch to the ounce (32.) of collodion. The quantity of oil contained in the formula makes it dry with comparative slowness, but the dressing is efficient in some instances, and remains adherent from one to several days.

Chrysarobin (chrysophanic acid) has an important place in the external treatment (Squire) of this disease. The advantage of this remedy is its rapidity of action. It is adapted to cases in which the patches are comparatively few and large, or to the larger patches in extensive cases. Its disadvantages are that it stains both the garments and the skin, the former permanently, the latter temporarily; it occasionally excites a mild or severe dermatitis in the surrounding skin. The patient should be cautioned against carrying the application to the eyes, as conjunctivitis of varying severity may thus be provoked; it should, therefore, not be employed for patches of psoriasis on the face or the scalp. If carefully used, however, and in the paint or film forms, these untoward effects, except staining, rarely present to an annoying degree. Accidental irritation does not, however, necessarily mean the giving up of this plan of treatment; as soon as it subsides it can be cautiously resumed, and if there is no further irritation, continued.

Chrysarobin is, on the whole, the most powerful local remedy we have in the treatment of psoriasis, and if properly used, frequently removes the eruption. It is to be usually employed as a powdery film or as a paint, the latter being the less active. Its efficacy is sometimes enhanced by the addition of salicylic acid.

In its use as a powdery film (Besnier) the drug is mixed with chloroform, 1 to 2 drams (4. to 8.) to the ounce (32.); or it may be used as a saturated solution, chloroform taking up about 40 grains (2.65) to the ounce (32.). The patches, freed from scaliness, as before applications of all remedies, are freely painted over, giving two or three coatings. The chloroform evaporates and leaves behind a thin layer of the powder; over this, to fix it and keep it in place, are painted a few coatings of flexible collodion or of plain collodion, or a mixture of the two; the plain is apt to be too hard and stiff, the flexible sometimes less adherent. Or liquor gutta-perchæ (traumaticin) can be used for this purpose, as originally advised, but is not, in my judgment, so satisfactory. When the films become detached or considerably cracked or loosened, baths are renewed, the films rubbed or picked off, and a new coating made. As soon as the tendency to scaliness ceases and the skin of the patches becomes pale and normal, the application is discontinued. This is a satisfactory method for large,

stubborn patches. Staining of the surrounding skin follows, but to a much less extent than when a chrysarobin salve is used.

The method of using chrysarobin as a paint is probably the most common one. The drug is prescribed in collodion or in solution of gutta-percha, 48 grains (3.2) or more to the ounce (32.) (Auspitz); the application is rendered somewhat more active by the addition of a proportion of salicylic acid (G. H. Fox), but with this addition it is not, as a rule, so comfortably borne in those with delicate skin. The compound formula with collodion is usually as follows:

℞.	Chrysarobini,	ʒj (4.);
	Acidi salicylici,	gr. x–xx (0.65–1.33);
	Ætheris,	fʒj (4.);
	Olei ricini,	♏v (0.33);
	Collodii,	q. s. ad fʒj (32.).

The ether and oil are sometimes omitted, but this formula is probably more satisfactory. I have also found it more efficient and less apt to stain the clothing when a coating of plain or flexible unmedicated collodion is painted over it.

This mixture is painted on the diseased areas with a camel's-hair brush. It quickly dries into a thin film, which adheres firmly. It usually remains somewhat longer intact than the films formed when the method previously described is employed. The application should be repeated every few days, or as soon as the films become detached; when they begin to crack, they can, as a rule, be readily pulled off. Underlying scales, if any, should first be removed, or as soon as the films are partly detached the baths can be temporarily resumed, until the patches are again free from scaliness, and then the paintings repeated. In another method of applying chrysarobin as a paint a solution or mixture is made with liquor gutta-perchæ, according to the following formula:

℞.	Chrysarobini,	ʒj (4.);
	Acidi salicylici,	gr. x–xx (0.65–1.33);
	Liquor gutta-perchæ,	fʒj (32.).

This makes a thin film which is quite adherent, but does not dry quite so rapidly as when collodion is used as the excipient, and in my experience is less satisfactory. The last two paints give rise to less staining of the surrounding skin than does the powdery film already referred to.

Chrysarobin was originally prescribed as an ointment; this is the most positive but the least agreeable form of application, as it discolors everything with which it comes in contact. It is prescribed ordinarily in the strength of from 40 to 60 grains (2.65 to 4.) to the ounce (32.), either with benzoated lard, with petrolatum, or with equal parts of the two. A small quantity is to be rubbed in vigorously once or twice daily, the excess being wiped off and rice-flour or starch-flour dusted over the part. After a time the tendency to scaliness lessens and finally ceases, the surrounding skin becomes slightly or deeply stained of a mahogany or bronze tint, and the diseased area or patch itself becomes pale and normal. The method

of treatment with chrysarobin ointment is called for in cases presenting obstinate and rebellious patches, and in which the other methods of using this drug have failed. It is also cheaper than the other plans, and for this reason well adapted for hospital practice.

The chrysarobin treatment is to be discontinued as soon as patches to which it has been applied become pale or distinctly whitish, as this usually indicates a disappearance of the disease in such areas; should a tendency to hyperemia or scale-formation present, it is to be resumed.

Pyrogallol (pyrogallic acid) is another remedy (Jarisch) of some value, and one that has been employed for some years in the treatment of the disease. It is not so rapid in its effects as chrysarobin, but it stains the skin less and rarely excites cutaneous inflammation unless used in too great strength; the linen is permanently discolored. It should not be applied to too large a surface at one time, as there is a possibility, as demonstrated by a few recorded cases, of toxic, and even fatal, action from absorption (Besnier, Vidal, Neisser). The drug is commonly employed in the form of an ointment. It is prescribed with benzoated lard or petrolatum, in the strength of from 20 to 60 grains (1.33 to 4.) to the ounce (32.). This is well rubbed into the patches once or twice daily, wiping off the excess and applying over the parts an indifferent dusting-powder.

β-naphthol is another valuable drug (Kaposi) in some cases, but it takes a lower rank than any of the remedies thus far named. It is a clean remedy, and is usually prescribed in the strength of from 20 to 60 grains (1.33 to 4.) to the ounce (32.) of ointment. Very often in working strength it produces considerable burning at the time of application and for some minutes afterward. Resorcin in ointment form, 5 to 10 per cent. strength, is also serviceable in some cases. Gallacetophenone is likewise employed in this disease, in the form of an ointment in the strength of from $\frac{1}{2}$ dram to 1 dram (2. to 4.) to the ounce (32.); so, also, is anthrarobin in the same proportion. Sulphur is only occasionally of service, applied as a 5 to 20 per cent. ointment. As an ointment base for these various remedies lard, or equal parts of petrolatum and lard, or with 10 per cent. of lanolin, can be employed. In those of sensitive skin using the zinc oxid ointment or Lassar's paste as the base, will lessen the irritating effects of the various stronger drugs named.

In psoriasis of the scalp the treatment is somewhat different from that employed when the disease is seated upon other parts. Chrysarobin and pyrogallol are rarely used in psoriasis thus situated, and when employed, always in the form of ointments; the pyrogallol salve is sometimes of distinct service, but should not be used in those with blonde hair, as it stains perceptibly. White precipitate, β-naphthol, and tar are the mainstays in the treatment of the disease here. White precipitate in ointment, 5 to 15 per cent. strength, is the most commonly employed and is usually efficient. Salicylic acid in the form of an ointment, from $\frac{1}{2}$ dram to 1 dram (2. to 4.) to the ounce (32.), is also valuable in some cases. The tarry oils and ointments are sometimes employed, and are most

serviceable applications, especially the vegetable tars, but, owing to their odor, their use can, as a rule, only be insisted upon if the others fail to make an impression; the oil of cade, either pure or weakened with 1 to 3 parts of alcohol, olive oil, or liquid petrolatum, is the most satisfactory. The scaliness is best removed by frequent shampooing with the tincture of sapo viridis.

Affected nails are to be treated with the free use of ointments, of the milder and non-staining class of remedies mentioned, such as β-naphthol, white precipitate, salicylic acid, and sulphur. Tarry ointments are of service here, too, but are disagreeable. The parts should be enveloped in the selected ointment as continuously as circumstances permit. The nails should be kept trimmed, and rough or projecting parts gently ground or scraped down with pumice, file, or knife. An occasional soaking in an alkaline solution of borax or sodium bicarbonate, 1 to 5 grains to the ounce, is often of advantage, the ointment application being reapplied immediately afterward.

Psoriasis spots or patches on exposed parts, more particularly on the face, are best treated with ointments of white precipitate, naphthol, or liquor carbonis detergens, inasmuch as they are cleanly and usually efficient.

For the rather rare acutely developing, markedly irritable cases, the external applications must, in the beginning at least, be of the mildest character possible. Sometimes a bran or gelatin bath, followed by plain cold cream or petrolatum, with or without 3 or 4 grains (0.2 to 0.265) of salicylic acid to the ounce (32.), will furnish relief and answer the demands until the disease has become more sluggish. The salicylic acid paste is one of the safest and most soothing applications. In extreme cases of cutaneous irritability the most comforting application is one consisting of equal parts of lime-water and almond oil, with $\frac{1}{2}$ to 5 grains (0.035 to 0.33 of carbolic acid to the ounce (32.). The calamin-zinc-oxid lotion or liniment is also useful in such instances.

Regarding the several new remedies or modifications of old remedies introduced in recent years, clinical trials do not place them so high as those already in use. Among these may be mentioned pyrogallol monacetate and chrysarobin triacetate, known also respectively as eugallol and eurobin (Kromayer, Bottstein), and oxidized pyrogallol (Unna). These are usually prescribed in ointment form, 2 to 10 per cent. strength; eugallol and eurobin also in chloroform or acetone, the former in 10 to 50 per cent. strength, and the latter 1 to 20 per cent.

Among the new[1] methods, I can speak favorably of the influence of both light baths and the Röntgen rays. The most efficient light is that of the sun, but this is rather unreliable and somewhat impracticable. Next in value, and readily obtainable, is the arc light. Baths of light from numerous incandescent lamps are also of some value, but not so efficient as the arc light. Repeated exposures at intervals of two to four in five days to the Röntgen rays, at a dis-

[1] An interesting paper in this connection is that by Hyde, "The Influence of Light-hunger in the Production of Psoriasis," *Brit. Med. Jour.*, Oct. 6, 1906.

tance of 6 to 12 inches from the tube, have in my experience proved serviceable in removing obstinate areas of the disease; the tube, of a vacuum equal to ½- to 2-inch spark, should be moved from place to place—not being kept more than 3 to 10 minutes in one region. Occasionally, in obstinate places, the time of exposure can be cautiously lengthened, or the distance shortened. Undue risk is not, however, justifiable in a disease of this character, so that *x*-ray treatment is best reserved for large rebellious areas. Like all remedies or methods, however, the light baths or Röntgen rays do not ensure against relapse.

ECZEMA.

Synonyms.—Tetter; Salt rheum; *Fr.*, Eczème; Eczéma; *Ger.*, Eczema; Ekzem; Eczem; Nässende Flechte; Salzfluss.

Definition.—An acute, subacute, or chronic catarrhal inflammatory disease, characterized in the beginning by the appearance of erythema, papules, vesicles, or pustules, or a combination of these lesions, with a variable amount of infiltration and thickening, terminating either in discharge with the formation of crusts or in desquamation, and accompanied by more or less intense itching and a feeling of heat or burning.

Symptoms.—So protean a disease may have almost any beginning form, and often tends to change, especially into consecutive or secondary types—eczema squamosum and eczema rubrum. As a rule, however, when once established, its type or predominant type is apt to remain throughout. It may begin as one or more slightly or marked inflammatory erythematous areas, which soon show slight or moderate scaliness; or, instead of dry erythematous areas, the skin shows inflammatory redness and swelling beset with pin-point-sized vesicles which discharge and form crusts; or the beginning lesions may be small papules, usually aggregated, and often so closely packed that a confluent patch results, later tending to scaliness or vesicular formation. The beginning lesions may also be pustular, or become rapidly so, and dry to crusts. Not infrequently the beginning type may be of a mixed character. These are the several primary types of the disease,—erythematous, papular, vesicular, and pustular,—and all eczema cases begin with the presentation of one or other of these types or a mixture of two or more. The erythematous is usually least likely to show lesions of other types. The papular variety often exhibits vesicles as well, and the latter not infrequently seropurulent or purulent lesions. And when the disease is somewhat extensive in distribution, the several types may sometimes be found on different regions. As clinically met with, a pure type, except the erythematous, and less often the papular, is not frequently observed.

Eczema is eczema, however, whatever its variety, and the various type names should not be allowed to confuse; type name simply signifies the lesion or predominant lesion or condition present, and does not mean necessarily the entire absence of other lesions or conditions; if the predominance is not overwhelming, the type is usually designated mixed. The eruption made up of an intermingling is not infrequent, and sometimes the beginning of the outbreak is of ill-developed char-

acter; thus is explained the terms erythematopapular, erythematosquamous, papulosquamous, vesicopular, vesicopapustular, etc. Although these are sometimes used to designate eruptions of mixed nature, they are more commonly employed to signify that the lesions are of transitional or midway character, as, for instance, the last two terms to signifying that the papules tend to vesiculation, and that the vesicles are not purely serous, but contain some admixture of pus, and so on. Moreover, very often the disease does not continue as

FIG. 46.—Eczema of erythematosquamous variety of several months' duration; deep red color; moderate scaliness; considerable thickening and infiltration, and accentuation of the lines and folds of the skin—this last especially marked about the eyes.

one of the beginning types, but frequently develops into what are known as secondary or consecutive forms. Of these the most common are eczema squamosum or squamous eczema, characterized by moderate or marked scaliness; and eczema rubrum or eczema madidans, characterized by a confluent, reddened, raw-looking, inflamed, weeping surface, with crusting, but which may be at times partly or almost completely dry. These and other types will be referred to in connection with the description of the lesional varieties.

The distribution of eczema may be more or less general, or, as usually the case, it may be limited to one or several regions. No part of the body is exempt. At different ages different regions show the disease much more frequently than others. Thus in infants and young children the face and face and scalp are most usually the seat of the malady; and in some of strumous diathesis there seems

a special disposition for the eczema to be about the orifices of the mouth, ear, nose, and eyes—its assumed association with struma leading some observers to name it, without sufficient foundation, **tuberculous** or **scrofulous eczema.** As active working life is approached and continues, the fingers, hands, and forearms are most commonly affected, and not infrequently the scrotal and anal regions in the male, and the vulva in the female; whereas in older life, past forty or fifty, the disease is seen relatively much more frequently on the lower part of the legs, and also upon the face. In some cases of long-continued eczema of the fingers, and also sometimes in association with the disease elsewhere, the nails are observed to share in the disease; they crack and break easily, are dry and often crumbling. The flexures of the knees, elbows, axillæ, are not infrequent sites for the eruption, and age does not seem to exercise much influence upon the election of these regions, although these are not common situations in infancy and early childhood. This tendency of the disease to affect certain parts, taken together with the age of the patient and the chronicity, is often an important element in diagnosis.

The character of the eruption as regards the activity of the inflammatory process may be of the acute, subacute, or chronic type. These terms are, in eczema, somewhat confusing, inasmuch as acute and chronic are also employed with their usual meaning in connection with the course of the disease as regards duration. Exceptionally eczema is observed to run an acute course, ending in several weeks or a month or two; and in such instances the disease is almost always of a markedly inflammatory or acute grade, and such cases are in the true sense examples of **acute eczema.** As a rule, however, the course of eczema is always chronic, and almost all cases can be classed as **chronic eczema,** but the grade of the process may be acute, subacute, or chronic (sluggish) throughout.

Often the disease is of chronic type and course, with acute or subacute exacerbations; in some cases it may disappear spontaneously for a shorter or longer time, more especially in temperate or mild weather.

The subjective symptoms of eczema are almost always troublesome, consisting of itching, burning, pricking, or stinging, or a mixture of these several sensations; and exceptionally hyperesthesia and pain. Itching is the most common, and is rarely missing; if so, its place is usually taken by one of the other symptoms named. The itching may vary in degree from slight to intense, and it may be constant or frequently intermittent. The rubbing and scratching which it usually provokes either during full consciousness or when asleep often have considerable influence in modifying the type of the disease—an erythematous or papular eczema may be partly changed into a moist oozing form, and the vesicular, by secondary infection, into pustular lesions.

Constitutional disturbances as a part of the disease are never observed except in acute generalized forms and in the acute, markedly inflammatory and edematous eczema of the face, when there may be preceding and accompanying febrile and other symptoms, which, however, soon, as a rule, abate and disappear. On the other hand, an intercurrent febrile disease, such as typhoid, etc., usually leads to a

PLATE VIII.

Eczema.

disappearance of the eczema, which, however, generally recurs as soon as the constitutional malady has run its course.

In occasional cases of eczema complications are met with, such as blebs (rarely), furuncles, impetiginous and ecthymatous pustules, and abscesses; these are purely accidental, and are not a part of the disease process. They are due to accidental infection by pyogenic cocci, the excoriations and the weakened or destroyed horny layer affording favorable opportunities for inoculation. For the most part these lesions are met with in debilitated subjects. Enlargement of the neighboring lymphatic glands is also at times noted, especially in infants and young children, and more particularly with the vesicular and pustular types, usually the latter. In eczema rubrum of the leg, in adults, and especially older patients, varicose veins are often seen in association and are of etiologic importance (**eczema varicosum**); in such cases there is a tendency, due to the same cause, to the development of leg ulcer (ulcus varicosum). Other cutaneous diseases are occasionally encountered in association with eczema or during its course, but such occurrences are purely a matter of coincidence—eczema is in no sense protective against other affections.

Essential Characters.—Before taking up the lesional varieties of the disease, the essential conditions or characters of eczema, in the main to be inferred from what has already been said, may be more distinctly referred to. Exudation is invariable, slight in the exudative congestion of the erythematous type, although it may also in this variety be considerable; more intense and often minutely circumscribed, producing papules, vesicles, and pustules, and serous and seropurulent discharge. There are noted also redness due to hyperemia, thickening and infiltration, and often variable scaliness or crusting. There is distinct tendency to the formation of one or more, often diffused, areas, with irregular and ill-defined borders, the disease shading off almost imperceptibly, as a rule, into the surrounding unaffected skin; often with, especially when about the joints, a disposition to cracking or fissuring of the skin. It will also be observed that fluid exudation on to the surface (**eczema humidum, moist eczema, moist tetter, salt rheum, weeping eczema**), formerly considered a *sine qua non* of the disease, is not always present; the parts are often noted to be dry and scaly (**eczema siccum, dry eczema, dry tetter**). To these various features are added the subjective symptoms, of variable intensity. Several or more of these are always to be found in every case, sometimes comparatively insignificant, sometimes pronounced.

As stated, the primary or elementary varieties are so named from the fact that the eruption is made up of one type of lesion, or that there is an overwhelming preponderance of such. These are also called lesional varieties. These, as well as those of secondary or consecutive types, deserve special description.

Eczema Erythematosum.—The most common site for erythematous eczema is the face, and more especially in middle-aged and old people. It is, however, also not infrequently met with in the flexures, on the back of the neck, hands, and occasionally on other parts, and exceptionally as a generalized eruption. It begins as one

or more small or large, irregularly outlined hyperemic macules or patches, pale or bright red in color, accompanied by more or less itching and burning. At first it may be ill defined and insignificant, but from time to time, and either gradually or rapidly, it tends to spread, and its features to become more pronounced; the redness becomes more conspicuous, the skin somewhat thicker, and shows scaliness, usually branny in character, but sometimes consisting of thin, epidermic, flake-like exfoliation. It may remain as ill-defined patches, or, from enlargement and often the arising of new areas, confluence takes place, and the eruption is then diffused over a part or a whole of a region. The face is often thus involved, although not infrequently it may be more or less limited to the forehead, and sometimes to the region surrounding the eyes.

FIG. 47.—Eczema of erythematosquamous type, in a woman, of a year's duration, involving both legs.

When the disease is fully developed, the skin is observed to be harsh and dry, of a reddish color, frequently with a violaceous and yellowish tinge, and sometimes mottled; the color and inflammatory process becoming less marked toward the healthy surrounding skin, into which the disease merges almost imperceptibly. It is thickened, infiltrated, and slightly scaly, with, at times, here and there, a tendency to the formation of one or more moist or oozing areas, which are usually the result of rubbing and scratching. In consequence of the latter, too, punctate and linear scratch-marks and excoriations may often be seen scattered over the affected region. In most cases, however, the whole area or region remains dry, and continues so throughout, with possibly, at intervals, the appearance of provoked circumscribed oozing, which soon disappears.

The process often varies within slight or moderate limits, becoming at times less pronounced, and at others, especially after exposure to wind or indulgence in rich food or alcoholic stimulants, much aggravated. Exceptionally its course may be acute, the disease after several weeks tending to disappear; in such cases, which are, however, rare, the face is the region generally involved, and the inflammatory process usually begins abruptly and is of an intense character, the

process being somewhat simulative of an erysipelatous outbreak. With few exceptions, however, the course is chronic, although often fluctuating, and sometimes partly abating, and occasionally entirely disappearing, but, as a rule, for a short time only. Even after complete disappearance as the result of treatment or spontaneously, it is exceedingly liable to relapse, probably more strikingly so than is observed with the other varieties of the disease. Very often the scaliness becomes much more pronounced and practically the disease is then representative of the squamous type—eczema squamosum. In rare cases, when involving the face, the eruption surrounding the mouth, and extending outward one or more inches, is erythemato-squamous, with superficial furrows or cracks, sometimes in numbers, converging toward the lips, especially to the angles ; from the effort of the patient to hold the mouth more or less fixed, to prevent fissuring, the orificial opening seems small. Occasionally in patchy erythematous disease about the hands and fingers, the hyperemic element is almost wanting, the eruption consisting of slight thickening, insignificant scaling, and considerable fissuring. In many of these erythematous cases, in fact, the terms erythematosquamous and fissured would be likewise applicable.

In the flexures from friction, and the natural moisture of the parts, the surface frequently is abraded, and a mucoid secretion, often observed in erythema intertrigo, is noted—**eczema mucosum, eczema intertrigo.** This condition is not uncommon at the scrotal, femoral, natal, and interdigital folds, and also under the mammæ. As already stated, however, erythematous eczema, particularly when on the face, is apt to remain as such, for a shorter or longer time, with, in the majority of cases, a tendency to considerable scaliness, and thus evolving into squamous eczema. In a few instances the skin becomes more inflamed, the surface abraded and oozing, and often crusted, and the type known as eczema rubrum is temporarily or more or less permanently established. Papules, vesicles, and pustules, lesions of the other primary types, are rarely seen in the erythematous cases, especially those of limited distribution.

A few words should be said in regard to generalized erythematous eczema (**eczema universale**), as this is the type the generalized disease usually presents. It is rare. It begins rather suddenly, with the appearance of small and large erythematous plaques, which rapidly enlarge, and, together with others that form, soon result in confluence, and practically cover the entire integument, with sometimes here and there small free spaces. Concomitantly with the outbreak, and sometimes for several hours or a day or two preceding, the patient often feels unwell, chilly, and suffers with malaise and slight flushings of heat, with usually slight febrile action developing. Immediately at the time of outbreak, if acute and abrupt, there may be considerable temperature elevation. As a rule, such symptoms, when present, abate as soon as the eruption has developed, but exceptionally chilliness and febrile action, especially the latter, with evening exacerbation, may continue for several days or longer. The eruption presents the usual symptoms of the erythematous type, as observed in the limited form,

the surface being reddish, and soon slightly branny or scaly, with often a tendency to crack about the joints. Almost always, sooner or later, on certain parts of the surface, especially on one or more of the flexures, the moist exudation of eczema is exhibited. Itching is present to a slight or severe degree, as a rule intermittently; probably as troublesome a symptom is burning, and sometimes a feeling of tension. The malady, for most of the surface at least, usually runs an acute course, tending to disappear, sometimes after one or two exacerbations, in several weeks to a few months, but usually leaving behind, however, a more or less persistent involvement of one or several regions, most commonly the lower part of the legs.

Eczema Papulosum.—Papular eczema, **lichen simplex** of former authors, and sometimes called eczema lichenoides and lichen eczematodes, is observed most frequently upon the flexor aspects of the limbs, although it is not uncommon upon the trunk. As with all other forms of the disease, it may be encountered elsewhere, but the face, ears, hands, and fingers seldom show this variety. In my experience, in its purest type it is more common in adults. The eruption may be sparse and limited to a small region, or it may be more or less extensive, involving a greater part of the integument. The lesions appear suddenly or insidiously, usually in numbers, and consist of discrete, aggregated, or closely crowded reddish, pin-head-sized, acuminated, or rounded papules; when in numbers and close together, there is often a good deal of diffused infiltration. The aggregations, especially on the arms, often form rounded or orbicular patches (formerly called lichen circumscriptus).

It is not uncommon, here and there, to find a variable number of lesions so crowded that a solid patch is formed, red, inflammatory, and thickened, with usually several or more outlying discrete papules. These patches sometimes show slight or moderate scaliness. It is not unusual, too, for some of the papules to show slight apex vesiculation (formerly called lichen agrius), and sometimes to develop into vesicles; and often the latter lesions, commonly few or in moderate numbers, are found arising primarily as such along with the much more numerous papules. Occasionally the lesions are distinctly follicular in origin (eczema folliculorum, **follicular eczema**). The papules are persistent, lasting for days or weeks, and if disappearing, replaced by fresh lesions. In fact, often there is a tendency to irregular appearance and disappearance, and also to crop-like exacerbations. Sometimes the papules are minute and punctiform in character; in other cases they are quite large to small pea in size, rather irregularly rounded at the base, and may be slightly flattened on top, and when on the scrotum and lower part of the legs, are likely to be dark red or even violaceous in color, bearing some resemblance to the larger lichen planus papules.

Papular eczema is persistent and obstinate, and usually much more itchy than other types; excoriations, scratch-marks, and small blood-crusts are often observed, bearing evidence of its pruritic character. It often maintains its papular form throughout, but there is frequently a tendency in some to become vesicles, and this tendency is, I think, especially observed in children. In many cases where solid patches

from overcrowding of the lesions have resulted, scaliness becomes a feature, and the disease becomes an example of the papulosquamous or squamous type, although it is common to find discrete papules, especially near the periphery of the scaly area or areas; such areas are not uncommon on the lower part of the legs. When the crowded lesions are overirritated by rubbing and scratching, and especially if there is a tendency to vesiculation, the surface becomes abraded and oozing, and eczema rubrum is evolved.

Eczema Vesiculosum.—The vesicular variety may be regarded as the most typical expression of the disease. It may occur upon any

FIG. 48.—Papular eczema in male adult, of two months' duration, limited to the back.

portion of the surface, but it is most usually seen upon the face of infants and young children (**crusta lactea**, or **milk crust**, of older writers), and in older people upon fingers and hands, neck, and flexor surfaces, especially near the joints. As an acute outbreak it is also observed on the face of adults. It may be limited to one region, or several regions may be stimultaneously affected, or one rapidly after the other. It is rather rare as a wide-spread eruption.

It usually appears somewhat acutely, by the appearance of reddened, more or less diffuse, patches, upon which rapidly develop numerous closely crowded pin-point vesicles, rounded or acuminated, containing clear or slightly opaque fluid, and which tend to become pin-head-sized or slightly larger, and so closely packed that in places

practical coalescence results. In fact, solid sheets of eruption are often thus formed. In some cases the disease is markedly acute, and considerable swelling and edema (eczema œdematosum), occasionally with scanty vesiculation, are present, and when on the face, especially in adults, the attack may at first bear resemblance to erysipelas. The vesicles soon mature and rupture spontaneously, or are broken by rubbing or scratching, and a partly vesicular and partly oozing surface ensues, on which irregular crusting of a yellowish or honeycomb character forms. Beneath this more or less continuous oozing takes place, and in some places new vesicles are formed; or the disease process in the course of days or several weeks may decline, the crusts be cast off, sometimes to be quickly followed by a new abundant crop of vesicles, and the same course be gone through. Later, lesions are apt to be less numerous, and at times, instead of appearing crop-like, they appear irregularly. Scattered papules, vesicopapules, and exceptionally vesicopustules or pustules are frequently to be seen mixed in with the vesicles, or more generally about the borders of the involved areas. In some cases the discharge, after rupture of the first outcropping of vesicles, is so profuse that new vesicles can scarcely be formed, and the surface remains for a time an oozing one, with here and there scattered, imperfect vesiculation. The eruption, when appearing and behaving as described, rarely remains long the vesicular type, but the parts become thickened and infiltrated, the surface oozing and crusted, thus evolving into and constituting eczema rubrum.

In other cases the disease begins insidiously, especially when on the fingers and hands, the lesions being scattered, with a tendency for two, three, or more to form in close proximity; sometimes the contents are absorbed, sometimes—and this most frequently—the lesions rupture or are broken, exude, and dry over with a thin crust, which may fall off spontaneously, leaving healthy skin beneath, or may be pushed off by new vesiculation beneath; or, especially where lesions are crowded together in groups, the underlying part becomes somewhat thick and infiltrated, and for a time—a day or two—the surface, after vesicular rupture, oozes, and constitutes a small patch of eczema rubrum. These small areas are similar to those arising from grouped or coalescent papules with vesicular capping. If lesions are observed in the palms and on the anterior aspect of the fingers, they are often, especially the former, noted to be at first somewhat deep seated, sometimes milky in appearance, and showing slight resemblance to beginning pompholyx lesions. In such cases, too, some of the efflorescences are clearly papular, and at times with a few scattered seropurulent or purulent lesions instead of pure vesicles. In other cases the entire eruption is vesicopapular; the lesions are often readily broken or rubbed off, but they do not present clearly formed or perceptible vesiculation. In other instances, at one time the vesicles predominate, and at another period the papules, so that a precise type designation is not possible. Occasionally the eruption is mixed vesicular and pustular. Exceptionally the vesicular character gradually disappears, leaving infiltrated areas which are persistent and become

scaly, thus going into the squamous form. This termination is, however, exceptional—the usual one, if it takes place, is into eczema rubrum, as already referred to.

The subjective symptoms are troublesome, but rarely so intense as in papular eczema; a feeling of burning and tension is apt to be more predominant than itching, although at times, and in some cases constantly, this latter may be present to an annoying degree. Fissuring, especially at the affected joints, is sometimes in this, as in other types, a feature of the case, but if present at all, is usually slight, and rarely to such an extent as in other varieties. The course of the disease, as can readily be inferred from the foregoing description, is usually chronic, with often acute exacerbations. In exceptional cases, however, the disease is acute both in character and its course.

Eczema Pustulosum.—Pustular eczema, known also under the name of **eczema impetiginosum,** is seen most commonly on the scalp and face, especially in children and young people, and more particularly those who are ill nourished and strumous. In adults it is occasionally seen about the bearded face, and on the thighs and lower part of the legs (**eczema sycosiforme**). The pustular type, is, however, probably the least common of the several varieties; although a pustular eczema of the scalp, especially of the occipital region in girls and women, usually of the dispensary class, due to pediculi, is not infrequent. It is similar, although usually less actively inflammatory, in its symptoms to eczema vesiculosum, with which it is sometimes associated. In fact, there is often an admixture of both types. The lesions are either pustular from the start or develop from preexisting vesicles, as a rule increasing somewhat in size. There is a marked tendency ordinarily to rupturing of the lesions, the discharge drying to thick yellowish, brownish, and sometimes greenish crusts (**eczema crustosum**). On the scalp it is noted exceptionally that the lesions are so numerous and so crowded that considerable epidermic undermining results, and the seropurulent or purulent discharge is so profuse (**eczema ichorosum**) that the denude surface presents. The neighboring lymphatic glands are usually considerably enlarged, especially in young subjects.

In adults there is a tendency for the pustules to be seated in or about the hair-follicles (**eczema folliculorum, eczema sycosiforme, follicular eczema**), to be, in fact, sycosiform, and when on the legs, they are often scattered, although occasionally grouped. Some are distinctly papular in the beginning. In this region, too, they are usually larger than when on the face and scalp, and some approach the size of small impetigo lesions. In extremely rare instances this sycosiform type may involve the entire hairy system, being virtually a sycosis, although with intense itching and other symptoms of eczema.

The course of pustular eczema is chronic, with exacerbations, but not so persistently so as other varieties. The subjective symptoms may be slight, with intermittent attacks of itching of variable degree, or the itching may be almost constant. Soreness and burning are also sometimes complained of.

Eczema Rubrum.—This is a secondary or consecutive type, evolving

from the primary or elementary varieties, as has been already referred to in describing the latter. It is evolved most commonly from the moist lesional types, but on the legs it frequently follows also the erythematous form. It is a common clinical variety, and may be seen on any part of the surface, but is not uncommon about the face and scalp in infants and children, and quite frequent on the legs in middle-aged and old people. It is a weeping or oozing form, but not constantly so, and is chronic and persistent, with, as a rule, but slight variation. Its features are considerable infiltration and thickening, often with swelling, and sometimes with intermittent edema, and with variable degrees of redness—not always bright red, as the name might suggest. The surface is usually oozing, which may be slight or marked, and hence there may be slight or considerable crusting produced from time to time; in the markedly oozing type (**eczema madidans**), of the leg (weeping leg), the surface is commonly free from any general crusting, the surface being, as a rule, raw looking, acutely inflammatory in appearance, with the oozing very diffused over the surface, or in the form of thickly set minute drops. As with all eczematous oozing, it is sticky in character. Often the exudation may lessen, and slight crusting ensue; occasionally in these cases the exudation, though not profuse, may be seropurulent and quite thick, and result in places in the formation of adherent, heaped-up crusting (**eczema crustosum**).

FIG. 49.—Squamous eczema, with tendency in lower part to eczema rubrum.

In other cases the surface is free from any evident discharge, but to the touch the surface is noted to be perceptibly moist or sticky. In other instances, at times, even perceptible moisture is wanting, and the surface presents a reddish, glazed appearance, being deprived of a great part or the entire horny layer. The infiltration, thickening, redness, diffused characters, are, however, common to all, and exceptionally the first two may be so considerable as to suggest mildly or moderately developed elephantiasis. In the cases with marked varicosity (varicose eczema, eczema varicosum), the leg ulcer (ulcus varicosum) is not infrequently associated.

Frequently at the borders of the area, or near by, some elementary lesions are to be observed, showing from which primary type the disease has evolved. The subjective symptoms, especially itching, are usually troublesome.

Eczema Squamosum.—Squamous eczema is a not uncommon secondary or consecutive clinical type, developing most usually, as a chronic form, from the erythematous and closely aggregated papular types. It may, however, evolve from other primary varieties, and all these, as well as eczema rubrum, in fact, go through a slight or moderate scaly stage when declining, or during periods of lessened activity. It may be seen on any part of the surface, but is most frequently observed on the scalp, back of the neck, palms, and the legs. Other forms may also be present, as in all the other varieties—for instance, on the leg, where it often evolves from the papular variety, where the papules are closely crowded, scattered, and aggregated; papules may be near by or more or less remote. It may be present as one large area, or there may be several patches; they are red and scaly, with the border fading gradually into the unaffected skin. Exceptionally the areas are more or less sharply circumscribed, and in rare instances are somewhat numerous; the disease picture seems, in reality, to represent features of both eczema and psoriasis (**eczema psoriasiforme, psoriatic eczema**).

There is usually a good deal of infiltration and thickening, especially when it follows the papular variety. The scaliness is somewhat variable, in some cases considerable, in others slight; and the amount often varies materially from time to time in the same case. This is due partly to frequency of washing, to intermittent or continuous treatment, or entire lack of it, as well as to the activity of the sweat secretion. The scales are dry, thin, or massed and imbricated, in color whitish to brownish yellow; occasionally they seem to partake slightly of the nature of a crust, being somewhat moist or greasy, as if there had been an insignificant admixture of a fluid exudation, often probably oily in character (eczema seborrhoicum, *q. v.*). When about the joints, and not infrequently on the fingers and palm, there is usually a marked tendency to fissuring. Itching is slight or intense, and sometimes variable. This variety of the malady pursues a chronic course, as, in fact, do almost all other forms of eczema.

Eczema Fissum.—This is an important and not uncommon clinical type, known also as **fissured eczema, eczema rimosum,** and **eczema rhagadiforme.** It is especially common about the fingers and hands. The conspicuous symptom is a marked tendency to fissuring or cracking of the skin, and usually deep in character and painful. It is commonly a part of an erythematous or patchy squamous eczema of the parts named, the fissuring constituting the most conspicuous and troublesome symptom. Indeed, sometimes the skin seems scarcely reddened or scaly, merely slightly or moderately thickened, smooth, and dry, and without scaliness; in other, somewhat exceptional, cases the skin, especially at the finger ends, is apparently even thinner than normal, pale, glossy, red, and atrophic in appearance, and inelastic, fissures forming from time to time. The condition known

as **chapping** or **chaps** is an extremely mild example of the fissured variety, although such cases can scarcely be called eczematous; more frequently, indicating a dry and poorly nourished condition of the skin, in subjects eczematously inclined. Eczema fissum is more or less persistent, the tendency to fissuring varying considerably, often according to the state of the weather, frequently disappearing spontaneously in the summer months.

Other clinical or name varieties are to be noted, due to some peculiarity of the disease process or to some developmental tendency. Thus, rarely there is observed a scarcely evident erythematous type, in which the outer epiderm shows superficial cracks, extending only to the rete, the latter being bared, and appearing as pale-red or red lines, often crossing at right angles or irregularly. In some places the epiderm, just at the edges of the cracks, is slightly detached and may turn upward. These thin cuticular filmy scales are quite adherent, except at the borders just mentioned. Occasionally minute, scarcely macroscopically visible vesiculation can be noted. The peculiar appearance is such as would convey the impression that the outer epiderm had been too small for the body, and that the cracking had thus resulted. It bears resemblance also to crackled china. It is rare, usually occurring on the trunk or thighs. It is commonly quite extensive, and is observed in neurotic subjects. Occasional chilliness is not unusual, especially when disrobing. Burning, sometimes associated with hyperesthesia, is probably more complained of than itching. This variety is variously known as **crackled eczema, furrowed eczema**, and **eczema craquele.**

Another type of eczema—**eczema sclerosum**—is occasionally encountered about the legs, especially the region of the ankle, usually developing from the squamous type, particularly that following upon aggregated large papules. The skin is noted to be thickened, infiltrated, hard, and almost horny, and somewhat elevated, and sometimes rather sharply defined. This type is also observed in limited patches on the palms, fingers, and on the soles. In such cases accidental, forcible flexing of a finger-joint near or above which a patch may be situated will cause deep fissuring. Sometimes, on the palms and flexor surface of the fingers and also on the soles, this form of the disease approaches closely to tylosis or callositas, and hence the name, **eczema tyloticum.** Instead of the surface of a sclerous patch, near the ankle, being more or less flattened, it may be rough and uneven, showing papillary hypertrophy, or crowded, wart-like projections —**eczema verrucosum.** In rare instances, usually as a small area, the eruption is moist and papillomatous and frambesiform (Beco, Huber).[1]

The term **parasitic eczema** (**eczema parasiticum**) is a yet somewhat vague term; it is applied, often without sufficient reason, to those cases

[1] J. Beco, "Uncas d'eczéma impetigineux d'apparence frambœsoïde," *Annales de la Societé Medico-Chirurgicale de Liege*, 1894, xxxiii., p. 218; Alfred Huber, "Perifolliculitis suppurativa und frambœsiforme Vegetationen im Anschlusse an Ekzem (with 2 case illustrations), *Archiv*, 1899, vol. xlix., p. 57.

of eczematous aspect in which the disease is patchy and sharply or slightly circumscribed in outline. As a rule, however, the term is not applied to the eczematous irritation produced by such animal parasites as lice, fleas, etc., although it might very well be. The ringworm fungus is known to be capable of producing manifestations in which all the ordinary features of ringworm, except being sharply defined and circumscribed, are absent, the patch or patches in other respects being distinctly eczematous—usually vesicopapular, squamous, or of the eczema rubrum type. Eczema marginatum, to be considered under the head of ringworm, is a typical example. Fungi other than that of ringworm have also been found occasionally in circumscribed eczema areas, but as yet the subject is chaotic, and alleged examples are relatively few. There are such possibilities, however, as the occasional eczematous looking patches due to the ringworm fungus would indicate. Such cases are not, I believe, judged by my own observations, so rare as commonly believed. The designation "parasitic" is also sometimes applied to those cases illustrative of the type

FIG. 50.—Eczema rubrum, of considerable duration, involving face, ears, and neck; showing a good deal of thickening and crusting (courtesy of Dr. M. B. Hartzell).

known as seborrheic eczema (**eczema seborrhoicum**), which is elsewhere described.

Etiology.[1]—Eczema stands first in frequency among skin dis-

[1] Valuable and suggestive papers bearing mainly upon etiology and pathology, some of which also include eczema seborrhoicum: Bronson, "Eczema: Its Pathology and Principles of Treatment," *Jour. Cutan. Dis.*, 1883, p. 129; Unna, "On the Nature and Treatment of Eczema," *Brit. Jour. Derm.*, 1890, p. 231; "Meine bisherigen

eases for which advice is sought. It constitutes, in this country, not less than one-third of all cases; in Europe it is much less frequent, relatively, at least, as other skin diseases uncommon with us are comparatively frequent abroad. It is met with in both sexes and at all ages, although it is probably least observed between the ages of six and fifteen.

In studying the etiology of the disease many factors must be considered. The first which naturally suggests itself is the question of heredity. Eczema can scarcely be said, without much reservation, to be hereditary, for such evidence is lacking in a large proportion of the cases. In many patients, however, there is an inherited tendency, but this alone probably is never responsible, but such individuals, if subjected to other contributory and exciting factors, will often present the disease. Doubtless it would be more correct to state that some individuals are born with irritable and easily excited skin, and therefore this organ is readily susceptible to internal or external pathogenetic stimuli or excitants. It is a well-known fact that certain external irritants will provoke a dermatitis in a large number of those exposed, whereas in most of these it will be simply a passing dermatitis; in others—usually a small minority—it turns out to be a true persistent eczema which has been provoked; what this necessary something is which is present in such individuals and not in others, and not constantly present in many of these, is the unknown quantity in eczema of which we are still ignorant. All that we know is that a great many factors, both constitutional and local, have an influence in calling this "unknown quantity," condition, or "soil," whatever it may be termed, into existence, of which an inherited cutaneous irritability is, in many instances, an important one. It has, moreover, been noted that blonde and florid persons, who are usually apt to have dry and thin skin, belong much more numerously in the "eczema class" than do those of dark hair and complexion; and, as a rule, the disease is much more common in those of an active, nervous temperament than in those of rather sluggish or phlegmatic habit. Sex exercises but little weight, although statistics give the preponderance to males, doubtless due to the fact that men are more subjected to external irritants or causes.

Befunde über den Morococcus," *Monatshefte*, 1899, vol. xxix., p. 106; Bulkley, "On the Causes of Eczema," *Med. Record*, April 4, 1891; Breda, "Das Ekzem und seine Natur," *Archiv*, vol. xxix., 1894, p. 179; Hutchinson, "The Nature of Eczema," *Clinical Journal*, London, vol. vi., 1895, p. 275; Schwimmer, "Ueber die Natur des Ekzems," *Wien. med. Wochenschr.*, No. 30, 34, 1894; Bowen, "Modern Theories and Treatment of Eczema," *Boston Med. and Surg. Jour.*, Oct. 10, 1805; Leredde, "Etiologie et pathologie de l'eczéma," *Presse médicale*, May 8, 1897, and "L'origine parasitaire de l'eczéma," *Annales*, vol. x., 1899, p. 30; *L'eczéma, maladie parasitaire*, Masson & Co., Paris, 1898; Török, "L'eczéma-est-il une maladie parasitaire?" *Annales*, Dec., 1898; Malcolm Morris, "What are we to Understand by Eczema?" *Brit. Jour. Derm.*, 1898, p. 359 (and discussion by Beatty and Colcott Fox); Leslie Roberts, "A Contribution to the Study of Eczema," *Brit. Jour. Derm.*, 1899, pp. 7 and 66; Brocq, "La question des eczémas," *Annales*, Jan., Feb., and Mch., 1900; Sabourand, "Essai critique sur l'etiologie de l'eczéma," *Annales*, April, 1899, p. 305; Galloway and Eyre, "A Study of Certain Staphylococci producing White Cultures found in Eczema," *Brit. Jour. Derm.*, Sept., 1900; Veillon, "Recherches bacteriologiques sur l'eczéma," *Annales*, 1900, p. 683; Fordyce, "The Modern Conception of Eczema," *Jour. Amer. Med. Assoc.*, June 13, 1903, p. 1621; Brocq, *Annales*, 1903, p. 77, and Graham Chambers (etiology and treatment), *Brit. Med. Jour.*, Oct. 6, 1906.

Age has but little, if any, material influence, although the disease is frequent during the first several years of life, relatively uncommon from this time to maturity, and then becoming again frequent.

The possibility of contagiousness is a matter which requires mention, and which has been much discussed, but until recent years there was but one conclusion, and that was negative, without qualification. That is the view still predominantly held to-day, and is in accord with my own experience. There are doubtless fungi and other organisms, among which is the ringworm fungus, that are capable of giving rise to eczematous or eczematous-looking patches, usually those of circumscribed character, and such would naturally be communicable.

The acceptance of the presence of micro-organisms as the essential cause of the disease—a growing belief—would naturally carry with it the possibility of contagiousness, at least under favoring conditions, but as yet the findings are too scanty and lacking in uniformity to warrant such conclusion.[1]

The various etiologic factors of eczema can be conveniently divided into two classes: internal, predisposing, or constitutional, and external or exciting. Either can doubtless act independently of the other, more particularly the external, but in a large number of cases both are necessary.

Constitutional Causes.—These are varied, and include all systemic states or conditions, passing or persistent, which bring about impaired or depressed vitality, and which interfere with proper nutrition, assimilation, and excretion. Experience has taught that gouty and rheumatic subjects are especially liable (Bazin, Garrod, Duckworth, Bulkley, Bird, Mapother, Duhring, Piffard, Whitfield, Watraszewski, and many others) to the disease, and they seem, in some instances, almost interchangeable—gout or rheumatism in the progenitors, the same or eczema in those of the succeeding generation. Uric acid diathesis, or lithemia, being a factor in many cases (**gouty eczema**), defective kidney elimination, in consequence of which the overproduced uric acid is locked up, is an added important element in such patients.

Digestive debility, dyspepsia, and its frequent accompaniment, constipation, must also be given a high place in discussing the causes of the disease—in fact, in my experience stand first in importance, such conditions often bringing on an eczematous attack in those of eczematous tendency, and which responds rapidly as soon as perfect or relatively perfect digestion has been reestablished. Important an etiologic factor as it is in adults, it is even of greater influence in eczema of infants and children. Diet, therefore, may be said to have an important bearing, not only by directly provoking digestive irregularity, but indirectly when food is taken in excessive quantity, by overloading the system with unnecessary supply. Faulty or incomplete metabolism, either directly or by leading to the development of intestinal toxins, is probably an important element in some cases. General debility, from whatever cause, is sometimes the last contributing

[1] For status of this question, see interesting papers and discussion in *Trans. of Section Derm. and Syph.*, XIII. Internat. Med. Congress, Paris, 1900; and also other papers already referred to.

factor necessary to bring on an outbreak. This debility may often be due to assimilative, nutritive, or nervous influence—from overwork, physical or mental, probably more potential when resulting from the latter. The constitutional state designated struma is to be regarded (Trousseau, Sanglé, Hutchinson, Unna, and others)[1] as an important factor in some cases, especially in children.

In some cases it may be of reflex origin (Kroell, Abramitcheff, Kroch, Eddowes, and others). To such factors may be ascribed some instances of eczema seen in association with dentition in infants—the

FIG. 51.—Eczema of crackled variety, in a neurotic old man past sixty, and of several months' duration, involving the surface more or less generally, but more especially the trunk, arms, and thighs. The skin is not thickened—simply of a slightly erythematous character, harsh and dry, with the corneous layer crackled, the fissures superficial, disclosing the red rete.

so-called **tooth rash**, although many of these cases are more likely due to a coexistent digestive disturbance. In children, too, intestinal parasites, doubtless both by reflex impression and direct action on the process of digestion, seem to have at times an etiologic bearing. Likewise, the occasionally observed etiologic agency of an adherent prepuce indicates nerve relationship. The relation of the nervous system to skin nutrition is, indeed, a close one, and nervous shock, hysteria, neurasthenia, and like conditions sometimes have a direct determining influence (Meyer, Tilbury Fox, Schwimmer, Bulkley, Duhring, Morris, Kromayer, and others), and their existence always renders the disease more rebellious. It is probably by the disturbing action on the ner-

[1] Sanglé, "Étude sur l'eczéma scrofuleux," *Thèse de Paris*, 1880, No. 161.

vous system that vaccination in children eczematously inclined occasionally provokes the disease. The presence of eczema should not, as a rule, however, in average cases, be an obstacle to this procedure, for experience teaches, while it is occasionally an exciting and aggravating factor, it likewise sometimes influences the disease favorably.

Among other less active predisposing causes which indicate defective kidney elimination, and which also aid in bringing about a debilitated condition, are to be mentioned albuminuria, diabetes mellitus (eczema diabeticorum), and diabetes insipidus—the dry skin resulting from the last two is probably a factor of importance. Liveing[1] directs attention to the occasional presence of eczema, especially in old people, in those with saccharine urine due usually to overfeeding without compensatory work or exercise and to defective assimilation, and not necessarily indicative of true diabetes mellitus. Functional and organic uterine disorders and nerve injuries (Bowlby, Cavafy, Nikolski, Brouardel, Oulmont and Touchard, and others) have in some cases had etiologic bearing and are additional evidences of the action of the nervous system. This frequent relationship has given rise to the term **neurotic eczema.** Malarial poisoning is also occasionally an important factor.

Eczema certainly seems in some cases to bear relationship to the mucous membranes; thus an association with asthma is now and then met with, the two maladies usually existing, getting worse and improving simultaneously. Exceptionally it has been noted by some observers that an improvement of one was followed by aggravation of the other; such instances have never come under my notice. It is barely possible that the stomachic and intestinal catarrh frequently associated with eczema—probably a catarrhal inflammation of the skin—is in reality the same disease process and due to the same causes; although the fact that the cure or relief of the digestive trouble by treatment addressed to it alone favorably influences the skin eruption, does not seem to support this view; on the contrary, this seems to show more positively merely an etiologic relationship.

External Causes.—In a large number of cases an external factor in the production of the disease cannot be discovered, and probably does not exist. On the other hand, there are cases of eczema which are persistent, owing to the fact that the external exciting cause remains unknown or unsuspected, but which, if finally discovered and removed, brings about rapid recovery. All the agencies capable of bringing on, by their local irritant or weakening action, erythema or dermatitis, referred to under these heads, are also capable, in some persons, of provoking a veritable eczema, especially when long continued or repeatedly acting. In most individuals, as has already been stated, nothing more than a passing erythema or a variable dermatitis is produced, and in many persons the action is, with most of such substances, practically negative; in short, as before referred to, there is an unknown something which makes some people susceptible, while others are uninfluenced, be this heredity, depraved or perverted health, or some inherent or acquired state of the skin itself. Diseased conditions of the skin, such as long-persistent seborrhea and ichthyosis, sometimes lead to the complication or development of an eczema.

[1] Liveing, *Lancet*, 1881, i., p. 411.

Among the more common external causes are to be mentioned excessive use of water and soap, especially strong soaps, dyes and dye-stuffs, chemical irritants, mustard and other medicinal plasters, and drugs; trade articles, such as sugar, flour, tobacco, pastes, polishing materials, and the like. It is a matter, too, of common observation that most of the causes may be acting for a long time without provoking any irritation, when suddenly or gradually some underlying condition supervenes or the resisting power of the skin has been finally overcome (or the weakened skin is no longer able to protect itself against parasitic invasion (?)), and an eczema results. This is seen over and over again with certain occupations (so-called **trade eczemas**, Blaschko, Leloir, Lefebre, Purdon, Lassar, and others[1]), and,

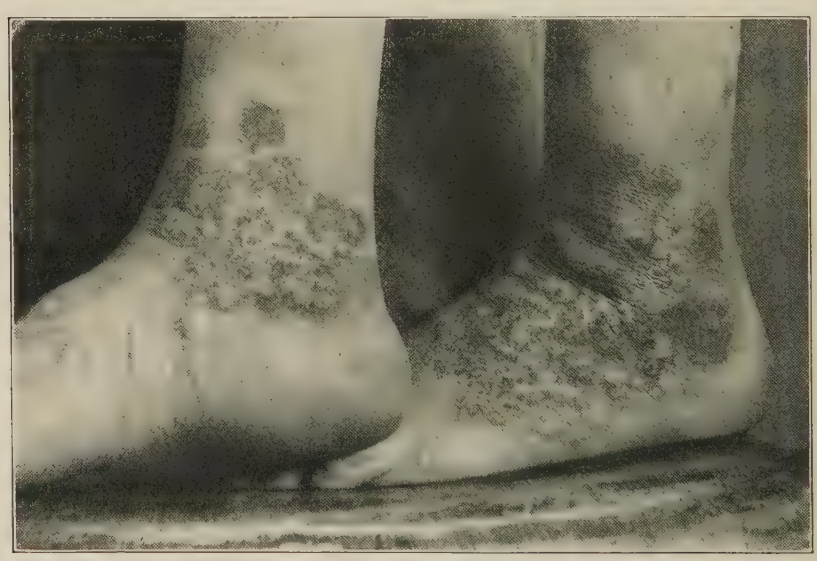

FIG. 52.—Eczema of thickened, sclerous, and verrucous variety, in a man aged about thirty-five, limited to regions shown, and of several years' duration. Deep brownish-red color, with purplish tinge, and bearing some clinical resemblance to hypertrophic lichen planus patches. Previous history of eczema.

as a rule, when this vulnerability is established, it remains more or less permanently. In this class, with eczema of the hands and sometimes the forearms, we find grocers—**grocers' itch** or **eczema**; bakers, from flour and yeast—**bakers' itch** or **eczema**; washerwomen—**washerwomen's eczema**; stonecutters, bricklayers, pasters, bookbinders,

[1] Leloir. "Dermite professionnelle spéciale (eczema des fileurs et varouleurs de lin)," *Annales*, 1885, p. 129; Blaschko, "Die Berufsdermatosen," *Deutsche med. Wochenschr.*, 1889, p. 925; Lefebre, "Eczema of Spinners and Flax-soakers," abstract in *Brit. Jour. Derm.*, vol. i., 1889, p. 140—original paper, *Thèse de Lille*, 1888; Purdon, "Note on the Eczema of Bleachers," *Brit. Jour. Derm.*, 1891, p. 82; Lassar, "Das Ekzem der Chirurgen," *Dermatolog. Zeitschrift*, 1894, i., p. 424; Stillmark, *ibid.*, *St. Petersburg. med. Wochenschr.*, 1894, p. 453; Merzbach, "Ueber Gewerbeczeme," *ibid.*, vol. iii., 1896, p. 161; Hall, "Dermatitis Occurring in the Silver and Electroplating Trades." *Brit. Jour. Derm.*, 1902, p. 121.

printers, dyers, chemists, surgeons (**surgeons' eczema, surgical eczema, nurses' eczema,** from use of antiseptics), etc.

Exposure to extreme cold (Hyde, Corlett),[1] more especially to cold winds, is a not uncommon external factor in some instances, and aggravating in almost all cases. In fact, season often has a considerable influence, the cold wintry windy weather materially adding to the number of patients, whereas as summer weather approaches the disease with many, especially if mild or only moderately developed, disappears entirely. There are exceptions to this, for occasionally the malady is worse in hot weather; this is more especially true of eczema in regions where heat, perspiration, and friction are pronounced, as about the genitalia, anus, axillæ, etc.

Exposure to heat-rays, but probably more especially to the actinic rays, of the sun, is a source in susceptible people, sometimes pro-

FIG. 53.—A distinctly eczematous area of a few months' duration, somewhat rounded and well-defined, which might be truly called "parasitic eczema"; the ringworm fungus was found.

ducing erythema solare, and in others, particularly if repeated, a more persistent irritation, or **eczema solare.** The X-ray is also capable of calling forth an eczema-like process; as a rule, this is an evanescent affair, and scarcely justifies the name of eczema, but exceptionally a persistent eczema results.

Eczema resulting from dye-stuffs, usually anilin dyes, is not only met with as a trade eczema, but not infrequently an eczema of the legs will be due to the irritation from the dye in the socks or stock-

[1] Corlett, "Cold as an Etiologic Factor in Diseases of the Skin, with a Report of 14 Cases" (1 colored plate and 2 half-tone cuts), *Jour. Cutan. Dis.*, 1894, p. 457. The cases eczematous in aspect, Dr. Corlett considers distinct from this disease and suggests the name "dermatitis hiemalis."

ings, and a body eczema is occasionally observed, explainable on a similar basis. The material sometimes put in hat-bands will provoke an eczema of the forehead. Among such possible similar causes are to be sought an explanation of some etiologically obscure cases. To not a few persons the wearing of a rough woolen undergarment next the skin is not permissible on account of the cutaneous irritation excited; this leads to scratching, and the latter to congestion and possibly to an eczema. Mustard and other rubefacient plasters, stimulating liniments, and blisters should be used with considerable caution in those eczematously inclined, for sometimes there results an outbreak which proves persistent and rebellious. Eczema of the genital region in infants is often observed, and the cause is usually to be found in the repeated wetting by the urine, as well as from the irritant action of its products. The eczema of diabetics of these parts, observed more especially in women, has as the immediate exciting cause the irritating diabetic urine.

In speaking of so-called parasitic eczema, it is there stated that at times the ringworm fungus is responsible for what clinically seems to be, and doubtless is, an eczema; it is probable that this and other similar fungi found from time to time by different observers may have a much wider causative influence than is generally supposed. I have met with several instances of persistent eczematous areas, in which the ringworm fungus, or closely similar fungus, was found. Various micro-organisms, as pus-cocci, morococci, and others, have been described, but, as already stated, there has been no conclusive uniformity in the findings, and their presence probably has no etiologic significance beyond, possibly, as with the pus-cocci, a modification or complication of the eczematous picture. The irritation provoked by the various animal parasites, as pediculi and the acari scabiei, together with the resulting irritation produced by scratching, often gives rise here and there to eczematous areas. Other animal parasites, such as bed-bugs, fleas, and the like, in susceptible subjects may also be, exceptionally, etiologic factors.

Among drug irritants, which are also essentially chemical irritants, must be mentioned, in the first place, iodoform. The sometimes untoward action of this drug, more especially when used as a powder, is referred to under dermatitis venenata. It at times not only is responsible for a passing dermatitis, but occasionally it is the starting factor in a most persistent eczema (**iodoform eczema**), and is a drug which should never be employed in individuals eczematously inclined. Another local application, rather frequently employed, capable of exciting the disease, is mercurial ointment (**eczema mercuriale**). These and many other drugs, as already intimated, in certain susceptible individuals produce either an artificial dermatitis, which usually soon passes away, or which evolves into a true persistent eczema—the latter in those who are especially prone to this disease. The same may in such subjects result from so-called rhus poisoning, the dermatitis or eczema proving rebellious.

Pathology.—The investigations of most observers and the clinical evidence point, I believe, pretty conclusively to the catarrhal

nature of the disease—in other words, that it is a catarrhal inflammation of the skin. The acceptance of an inherently weak or debilitated skin from various causes, and the action of varied pathologic epithelial stimuli or irritants (Roberts, Brocq, Fordyce, and others), either from within or without, or from both, best explain the disease process. The grosser parasites, micro-organisms (Unna, Leredde), or their products (Brockhardt, Bender, and Gerlach), thermic, actinic, chemical, toxinic, and other irritating agents, may, therefore, be at times contributory or even distinctly pathogenic in provoking the skin to the reactionary inflammatory process we call eczema. Sabouraud, Török, Jadassohn, Neisser, and others believe the disease

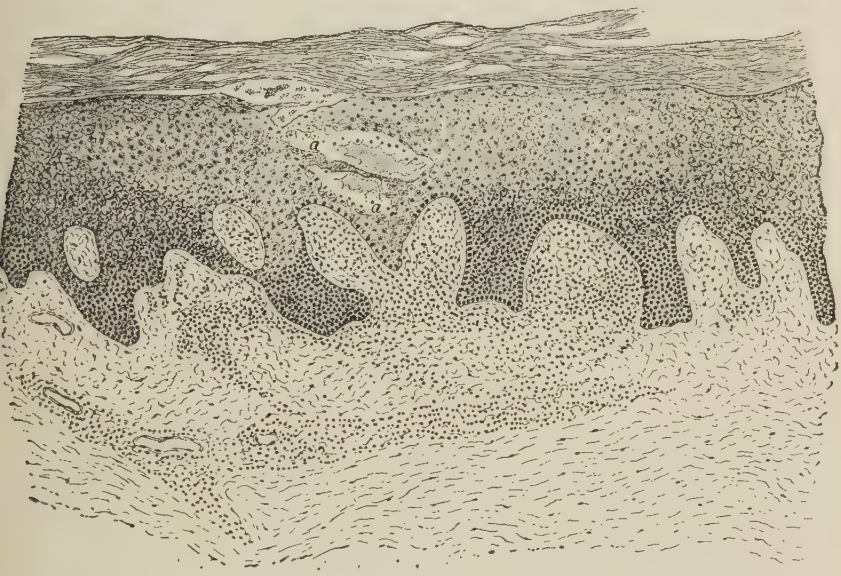

FIG. 54.—Eczema, sluggish, deep-seated, vesicular type, with scattered lesions and somewhat thickened corneous layer, commonly seen on the fingers; section from palmar surface of a finger (low magnification): *a*, *a*, Represents a vesicle in the earliest observable stage; the mucous layer in the lighter part shows molecular changes, and corresponds to the area of inflammation in the papillary layer of the corium below. The papillæ show marked serous exudation, dilated blood-vessels, and invasion of leukocytes (courtesy of Dr. A. R. Robinson).

amicrobic, although admitting that micro-organisms may be, as they undoubtedly are, of import in the evolution or later changes in the morbid process. Unna no longer holds to the specific coccus—the mocrococcus—which is now generally considered to be the staphylococcus epidermalis albus. The symptom of itching might suggest a primary nerve involvement as responsible for the cutaneous phenomena, and nerve changes have occasionally been noted (Colmiatti, Leloir), but it is much more probable that this is wholly secondary. The neurotic or trophoneurotic basis of the pathologic changes has had, however, and still has, many supporters, as referred to when discussing etiology.

The pathologic anatomy[1] of eczema has been considerably studied in recent years (Simon, Hebra, Wedl, Rindfleisch, Kaposi, Riemer, Neumann, Biesiadecki, Robinson, Crocker, Unna, Leloir, Gilchrist, and others). There is a difference of opinion as to whether the earliest changes take place in the epithelium or in the papillary layer, and by such observers that both possibilities are to be admitted. The same difference of opinion exists as to the formation of

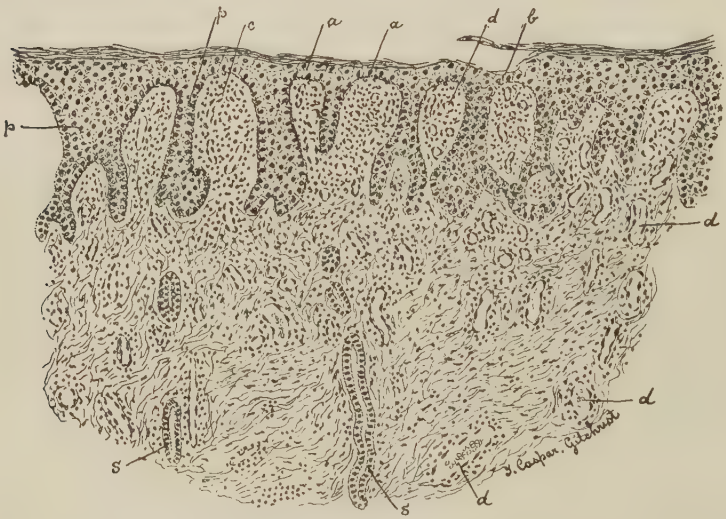

FIG. 55.—Eczema rubrum, weeping variety (low magnification): *p*, *p*, Shows marked hypertrophy of interpapillary processes of the epiderm; *a*, *a*, thinning in some places over the papillæ, but one layer of cells at *b*; *c*, enlarged papillæ; *d*, *d*, *d*, *d*, dilated blood-vessels; *s*, *s*, sweat-ducts, showing no change. In the corium small mononuclear cells present in great number, with increased number of connective-tissue cells (courtesy of Dr. T. C. Gilchrist).

the vesicle, its anatomic seat being the middle or upper layers of the rete; according to investigations, the earliest and most frequent formation of vesicles is within an epithelial cell by alteration, dropsical degeneration, and expansion; and some are formed between the epithelial cells. The pustule is a similarly developed formation, with the addition of leukocytes. The earliest, and possibly histologically

[1] Literature bearing upon pathologic anatomy, more especially consulted in addition to that to which references were previously given: Leloir, "Contribution a l'étudé de la formation des pustules et des vesicules sur la peau et les muqueuses" (with bibliography), *Archives de physiologie*, 1880, vol. vii., p. 307; and "Contribution a l'étude des affections cutanées d'origine trophiques," *ibid.*, 1881, vol. viii., p. 391; "Anatomie pathologique de l'eczéma," *Annales*, 1890, p. 465; Suchard, "Des modifications et de la desparition du stratum granulosum de l'epidermis dans quelques maladies de la peau," *Archives de physiologie*, 1882, vol. ix., p. 205; Gaucher, "Note sur l'anatomie pathologique de l'eczéma," *Annales*, 1881, p. 263; Rindfleisch, *A Manual of Pathologic Histology*, New Sydenham Soc'y Translation, vol. i., 1872, p. 349; Neumann, *Zur Kenntniss der Lymphgefässe der Haut des Menschen und der Säugethiere*, Vienna, 1873, p. 28; text-books, almost all of which present cuts—Tilbury Fox, Neumann, Kaposi, Robinson, Crocker, Jarisch, Unna, (Histopathology), Duhring (*Cutaneous Medicine*, part ii.), Macleod (*Pathology of the Skin*).

characteristic, symptom of eczema is parenchymatous edema of the transitional epithelium; there is, in consequence, a broadening of the prickle layer, and these changes are noted before there is any epithelial growth. The edema is also especially observed in the granular layer, and, as a direct or indirect result, granulation ceases or is retarded, and proper keratinization is interfered with. The serous saturation of the whole epidermis, which in reality occurs, leads sooner or later to variable epithelial growth. Along with these phenomena, or as contended, and probably rightly, by the majority of observers, preceding and causing such, are to be observed a con-

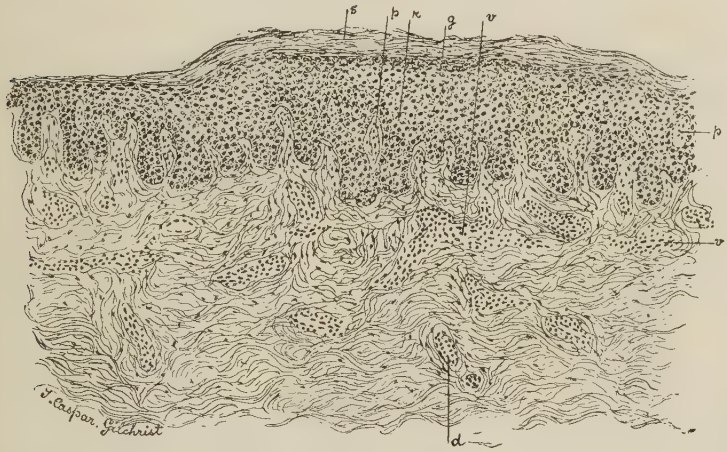

FIG. 56.—Eczema, chronic squamous variety, in a colored woman (low magnification); the inflammatory process involves the epidermis and upper part of the corium, the former, especially the rete (*r*), being much hypertrophied, the lower half of the corium and the glandular structures remaining practically normal: *s*, Scaling corneous layer; *g*, granular layer; *p*, *p*, papillæ, showing but little alteration; *v*, *v*, blood-vessels surrounded by collection of granulation-cells, numerous mast-cells, and pigment-cells; *d*, part of a sweat-duct (courtesy of Dr. T. C. Gilchrist).

gestion and dilatation of the vessels of the papillary layer, with consecutive diapedesis of leukocytes, and serous exudation from the blood-vessels; in consequence the papillæ and adjacent parts of the corium are enlarged, distended, and infiltrated, and in some instances the deeper parts are also involved in the serous exudate. In the latter cases considerable surface swelling is noted in the more chronic disease. As a result of the epithelial proliferation referred to, and also of the serous and cell exudation and connective-tissue cell proliferation, together with dilatation and engorgement of the vessels of the upper corium, considerable thickening and infiltration ensue. In some instances these changes are limited, primarily at least, to the follicles, especially the hair-follicles, and are perifollicular, giving rise to papular elevations. In those cases in which the papillæ are much enlarged and elongated a wart-like or papillomatous aspect is given to the disease. In acute confluent vesicular eczema and in eczema rubrum the edematous exudation is so great and rapid as to destroy and cast off the corneous layer, laying bare the rete.

It will be observed from the above that the process is distinctly an inflammatory one, with the predominance of serous exudation; and is characterized in all cases by hyperemia, serous exudation, and usually also by blood-vessel dilatation, epithelial and connective-tissue cell proliferation, varying in degree according to the intensity and duration of the disease; the rete and papillary layers are especially involved, although in severe and chronic cases the lower part of the corium, and even the subcutaneous tissue, may share in the process. The congestion and exudation lead to increased activity of the epiderm, resulting in scaling. In long-continued chronic eczema, especially of the legs, the changes are still more emphasized, with pigmentation, increased thickening of all parts of the affected integument, and an accentuation of the natural lines and furrows; the papillæ, blood-vessels, and lymphatics are considerably enlarged, and in extreme cases the sebaceous glands, sweat-glands, and hair-follicles suffer obliteration or degeneration, as noted in elephantiasis.

The peculiar gummy or sticky exudation of eczema is made up chiefly of serum and the fluid resulting from dropsical degeneration of the rete cells. It is clear, light yellowish in color, neutral or feebly alkaline in reaction, and deposits flocculent albumin when subjected to the usual tests; this secretion, when dry, gives rise to the yellowish, gummy, or candied-looking glaze or crust often observed in this malady; linen or other material wet with it is stiffened when dry. The darker crusts of the disease are due to the admixture of blood, pus, and dirt.

Diagnosis.—The diagnosis of eczema seems to be a field of great difficulty to students and practitioners, and yet, if the usual features—redness, thickening or infiltration of variable degree, the often mixed character of the eruption, scaling or crusting, and, in many cases fluid exudation of a sticky nature, the tendency to be confluent and to form areas, together with the subjective symptom, itching, and the not uncommon disposition to fissuring—are kept in mind, error need rarely occur. Add to this picture a more or less chronic course, and the above group of symptoms, in readily excluding many other diseases, becomes almost pathognomonic. Cases seen shortly after the outbreak, thus lacking chronicity as a feature, might be more difficult, but as the disease often begins insidiously and slowly, —cases coming on rapidly and running an acute course are somewhat rare,—by far the large majority do not seek medical aid for several weeks after the onset. The value of these various factors is still further strengthened if the favorite locations of eczema are remembered, as the hands, face, scalp, back of the ears, genitalia, flexures, legs, etc. Judged by my own experience, practitioners in venturing upon diagnosis in an untried field usually favor a rare disease rather than a common one—if there is to be any guessing done or jumping at conclusions, it should naturally be in the direction of the greater chances of being right. Eczema is a frequent disease, and a large part of dermatologic practice is made up of its cases, and in that of the general physician it is probably even relatively larger; the specialist's statistics of this disease are apt to be

reduced by the much greater number of cases of rare diseases which naturally gravitate to him. Combining all these diagnostic factors,—symptoms, region, chronicity, frequency,—one is then prepared to say that in children under the age of four or five an itchy inflammatory eruption of the face or scalp of any duration is usually an eczema; the same of an eruption on the hands of a working adult; the same of that on the leg, and to a less extent of that on the face, of the middle aged and old; the same of that about the genitalia and anus of a matured adult; the same of that observed in the various flexures, etc. It is not intended, by any means, that these statements should be taken as absolute, for other diseases do occur on such regions, but relatively so much less frequently that such knowledge has value in reaching a diagnosis.

In the differential diagnosis many diseases must be considered, but of the more common affections the most important and those most likely to be confounded with eczema in private practice are psoriasis and seborrhea, and in public practice the same and scabies, pediculosis, and impetigo contagiosa. The difference between these and eczema will first be pointed out, and then other maladies which may also at times bear resemblance follow in alphabetic order. Among these latter those diseases in which itching is a factor should be more particularly considered in the differentiation, such as pruritus, urticaria, sometimes miliaria, and also the rarer affections, lichen planus and dermatitis herpetiformis.

Psoriasis.—Psoriasis, even though the eruption be scanty, is of more or less general distribution: eczema more likely to be limited to one or two regions; psoriasis patches are variously sized, rounded, and sharply defined: eczema is usually in one or more large, irregular areas, and shades gradually into the surrounding skin; psoriasis favors the extensor surfaces, especially the regions of the knees and elbows: eczema the flexures; psoriasis lesions are uncommon upon the face and hands, and then usually only as a part of a more or less generalized eruption, whereas eczema is frequently seen upon these parts and often only there; psoriasis is probably never limited to a single region, except the scalp, and this rarely: eczema is frequently so limited; the scaliness of eczema is, as a rule, slight: that of psoriasis, more or less abundant; eczema frequently shows, or gives a history of, vesicles or gummy oozing: psoriasis is always dry; psoriasis lesions, when the scales are removed, disclose a reddish, filmy, or membranous-looking surface, which, if scraped, shows minute blood-drops: in squamous eczema the uncovered surface is usually hard, thickened, and rough; psoriasis patches begin as small lesions and increase in size by peripheral extension: scaly eczema patches, which most resemble psoriasis, arise most frequently from overcrowding of papules producing a solid area, and usually characteristic papules are to be found at the periphery; in psoriasis eruption it is not uncommon to find a few ring-shaped patches with clearing center: in eczema this rarely, if ever, occurs. Psoriasis lesions on the palms may resemble closely squamous eczema, but the former malady is never limited to this region, but is seen here, and that rarely, only in conjunction with the characteristic areas on other parts.

Psoriasis of the scalp and squamous eczema of this region have, in appearance, much in common, but the former is here also usually seen as well-defined and always dry scaly patches, and eczema as more or less diffused and sometimes in places moist; psoriasis patches are often noted to overlap the hairy border on to the forehead and mastoid region, and if close together, present a wavy or festooned edge, sharply defined, as elsewhere: eczema, if it oversteps the scalp, generally does so as a diffused eruption, fading gradually into the normal skin, and often presenting, as it approaches the ear, especially behind the ear in the fold, moist exudation; further, while psoriasis may in rare instances be limited to the scalp, in most of the so-called scalp limitation cases usually a few insignificant spots may be seen on the elbows and knees.

In eczema itching is practically invariable: in psoriasis it may or may not be present; its absence would, therefore, throw the balance in favor of psoriasis, while its presence would have but little significance, although, as a rule, even in itchy psoriasis cases, the itching is rarely so intense as in eczema.

Seborrhea.—Seborrhea is sometimes confounded, but in this there is entire absence of infiltration and thickening and of other signs of inflammation common to eczema; moreover, the scales of seborrhea are greasy and oily, rather soft and unctuous to the touch, and when on non-hairy parts, as the nose and breast, occasionally show slight prolongations into the follicles; the underlying skin is usually pale and sluggish-looking, while in eczema, on the other hand, the scales are dry and brittle, and the underlying skin is red, infiltrated, and often rough and hardened; often, too, in eczema a removal of scales or crusts discloses a part of the surface with the characteristic gummy oozing, whereas in seborrhea it is greasy or oily. In seborrhea of the scalp, its most usual situation, if long continued it is often accompanied with falling of the hair: in eczema this is seldom noted. The itching is rarely marked in seborrhea, and sometimes wanting, while in eczema it is more or less constant and troublesome. At times, however, the seborrheic disease has ingrafted upon it, or apparently so, the eczematous process, and thus shows mildly inflammatory symptoms; such cases are described under eczema seborrhoicum, under which the differential points of this latter from ordinary eczema will be given.

Scabies.—The eruption of scabies is in many respects somewhat eczematous, due to parasitic irritation, and in cases of any duration the conditions observed in some parts, especially about the hands, in the neighborhood of the elbow, axillæ, and natal folds, may present distinct eczematous areas. Even in such extreme cases, however, the matter of differential diagnosis is usually readily solved. The distribution of scabies is so characteristic as to be almost pathognomonic. It is not localized to a region or two, as eczema commonly is, but the lesions are usually scattered and discrete, and consist often of a mixture of papules, vesicles, small and large pustules, between the fingers, palms, and dorsum of hands, about the wrists, region of the elbow-joint, axillary folds, nipples in women, lower abdomen, genitalia, and

inner sides of the thighs, and often on the legs and feet—a distribution and eruptive characters wanting in eczema. Moreover, the papules, vesicles, and pustules of eczema are small, acuminated, or rounded, those of scabies somewhat linear, and often markedly so, and many of the lesions, especially the pustular, larger in size. The presence of the burrow, or cuniculus, usually and most commonly to be found on the inner sides of the fingers, and sometimes upon the covering wall of the vesicular and pustular lesions, would be decisive. Moreover, a history of contagion is often attainable in scabies, and frequently two or three members of the family are affected. In extremely mild cases of the malady, kept so by constant bathing, and generally observed in private patients, the lesions are usually ill-defined papules, vesicopapules, and vesicles, and may be few in numbers, but the characteristic distribution is present. Then, too, the face and scalp, except sometimes in infants and very young children, are never involved in scabies, and are commonly so in more or less generalized eczema. The pruritus of scabies is most troublesome at night, and often comparatively absent during the daytime: in eczema this difference is not usually so marked. Scabies cannot remain limited to the region on which it first presents, but is progressive and becomes generally distributed: eczema often is confined to one or two regions, and rarely is found so generally scattered.

Pediculosis.—An eczematoid eruption of a papular, papulopustular, and pustular character, about the scalp, especially posteriorly, and about the pubic region, should always lead to suspicion of pediculi as the cause; the suspicion aroused, it is an easy matter to determine the point by the presence or absence of ova, or nits, on the hair-shafts. This is sufficient, but the pediculi can also usually be found hidden in the deeper meshes of the hair on the scalp, and the crab-louse on or close to the skin, clinging to the hair in the pubic region. In addition to the pubic region, the crab-louse also causes, but infrequently, similar irritation about the axillæ, and sometimes in other regions where there is short hair, as in hairy individuals about the breast, legs, etc. In extremely rare instances also an eczematous irritation of the eyelids and of the eyebrows has been found to be due to the crab-louse on these parts, but here, as in other situations above named, the finding of the nits attached to the hairs will solve the problem. Pediculosis corporis, if of long duration, and especially in the tramp class, gives rise to distinct eczematous irritation, with, however, accentuation on those parts against which the clothing comes in closest contact, as across shoulders, neck, and upper back, around the waist, and down the outer sides of the thighs—a distribution not observed in ordinary eczema. Even if, in many cases, the eruptive lesions and excoriations are scanty, the same distribution is noted, and is usually characteristic. Then, too, parallel linear scratch-marks of some length are more frequently noted in pediculosis corporis than in any other itchy disease. The pediculi are often to be found in the clothing, but unless in great numbers, are usually hidden in the seams, in which places they are to be sought for.

Impetigo Contagiosa.—It is only when impetigo lesions are close

together and coalesce, forming a crusted area, that a resemblance to eczema is shown. Even then the nature of the lesions from which the area resulted, as usually disclosed by the history, and also by the presence of characteristic discrete lesions, will prevent error. The vesicles and pustules of eczema are usually pin-point to pin-head in size, with tendency to spontaneous rupture; those of impetigo are pea- to dime-sized, and exceptionally larger, and tend to dry to crusts without breaking. In the latter disease there is often a history of contagion.

Acne and Acne Rosacea.—Ordinary acne can scarcely be confused with papular or pustular eczema, as in the former disease the lesions are always discrete, larger, and their origin from a plugging up of the sebaceous gland outlet is usually evident. Acne rosacea with a seborrheic element can show a rough resemblance, but here the hyperemia, with no infiltration, often associated acne lesions, and the dilated capillaries, will prevent error—such conditions are not observed in eczema; moreover, acne rosacea is usually limited to the nose and immediate neighborhood: eczema, on the other hand, is apt to be diffused over the face, and never remains limited for any length of time to the rosacea regions.

Dermatitis.—Inflammation of the skin of artificial origin is often similar in symptomatology to that of eczema, and may, indeed, be considered identical, and therefore is to be differentiated chiefly by the acuteness of the attack, history as to the cause, its short course and rapid disappearance. It is also usually limited to the parts subjected to the irritant. In many cases of artificial dermatitis the very violence of the symptoms is suggestive. In rhus poisoning the history of exposure, the part affected, the intensity of the process in many cases, and sometimes the presence of large vesicles and blebs, would ordinarily preclude confusing it with eczema. Rhus plants, however, like other external irritants, may be the exciting factor in eczema, and the violent early symptoms give way to those of the eczematous disease; this result, fortunately, rarely happens except in those with distinct predisposition to the latter malady.

Dermatitis Exfoliativa.—This disease is almost invariably generalized, and, as a rule, shows very little infiltration and thickening, and is usually always dry and with abundant exfoliation; eczema is practically never over the entire surface, but in sheets or areas, and more marked in its favorite places, exhibits a good deal of infiltration and thickening, slight or moderate, and often intermittent, scaliness, and shows often, especially in the flexures, characteristic gummy oozing. Moreover, in many cases of dermatitis exfoliativa there are symptoms of constitutional disturbance, and in eczema such would be exceptional; the subjective symptom of itching is much more marked in eczema, and is usually intense, whereas in cases of dermatitis exfoliativa it may occasionally be troublesome, but is often slight, and sometimes wanting, the feeling being more of burning and tension. There is no doubt, however, that exceptionally extensive eczema, of usually long duration, may, as well as psoriasis, evolve into a true dermatitis exfoliativa.

Dermatitis Herpetiformis.—The cases of dermatitis herpetiformis which could be confused with eczema are rare, and to be found only in those cases in which the vesicular and papular lesions are small; but in this disease the herpetic character of the eruption—the tendency to small groups and the absence of distinct tendency to spontaneous rupture—is different from eczema. Moreover, its variable course, with often change of type or sprinkling of lesions of other types, as blebs, erythematous and bullous rings, and other symptoms common to erythema multiforme, is not observed in eczema.

Erysipelas.—Eczema can be mistaken for this disease only when markedly acute, with considerable edema and swelling, but there are sufficient points of difference. In erysipelas the character of the onset, its method of spread usually from one point, the shining, glazed-looking red surface, and, above all, the well-defined elevated, often as if chopped off, border, frequently the presence of blebs, and the accompanying constitutional disturbance, are different from the symptoms of eczema. In this latter there is rarely febrile action, except at the very beginning of the acute outbreak, and this not always; the eruption often appears simultaneously at several points, with ill-defined borders, its surface is sometimes beset with minute vesicles, which usually break and discharge the characteristic sticky fluid, different from the serum from the broken blebs in erysipelas. The swelling and deep-seated character of the process in erysipelas persist until the disease has reached its acme—usually some days: in eczema the violence of the onset generally abates within twenty-four to forty-eight hours, and then the disease assumes the ordinary features. Eczema is usually intensely itchy, whereas the subjective symptoms in erysipelas are apt to be a feeling of tension, soreness, and burning, rarely itching.

Erythema.—There is, as a rule, no difficulty in distinguishing eczema from the various erythemata. In the milder erythemata—erythema simplex and the other hyperemias—there is absence of distinct inflammation, the process being simply a congestion, though sometimes insignificant, scarcely perceptible exudation, but with the absence of eczema features. Erythema intertrigo, when with a macerated surface, resembles eczema, but the secretion is not, as that of eczema, sticky, nor does it stiffen linen as the latter does; nor is there any infiltration. Still, erythema intertrigo persisting and neglected does sometimes evolve into a true eczema. The lesions of erythema multiforme—papules, tubercles, nodes—are much larger than those of eczema, and with little tendency to become confluent; the erythematous patches are sharply marginate or annular, conditions not observed in eczema. Scaliness is not noted in the erythemata except occasionally, and then only as an almost imperceptible branniness or a thin filmy exfoliation; in eczema scaliness is common and often pronounced. Moreover, the erythemata rarely itch to any degree.

Favus.—This disease, when well defined in its earliest existence, can scarcely be mistaken for eczema, as the yellow, mortar-like, cup-shaped discs are pathognomonic. The scalp is its usual region, and

here, after the disease has lasted for some time and been neglected, and the crusting massed and dirty, it bears some resemblance to squamous eczema, but the hair involvement, as shown by the dead-looking, lusterless hair, the broken hairs, and the irregular, patchy hair loss, is never seen in the latter disease. Moreover, if the crusts are removed, atrophic or scar-like tissue is disclosed, another condition entirely foreign to eczema. In obscure or questionable cases, which, however, are rarely met with, the microscopic examination of the crusts will disclose the fungus if the disease be favus.

Herpes.—Herpes simplex, whether the lesions are about the lips or face or about the genitalia, can scarcely be confused with eczema; herpes presents a grouping of vesicles, often upon a hyperemic base, with little, if any, disposition to spontaneous rupture: eczema vesicles are much smaller, usually closely crowded, and generally over considerable area, with no tendency for special grouping, and, as a rule, soon break and discharge a gummy fluid; the process in herpes is acute in course, disappearing usually in several days or one or two weeks: eczema is almost always persistent; in herpes itching is, as a rule, absent, or so slight as to give rise to no complaint: in eczema it is generally intense and constant. The same reasons, with slower evolution and disappearance of the vesicles, which are also larger, in great measure suffice to prevent confusion between herpes zoster and eczema; moreover, the limitation of zoster to one side of the body or region, its appearance as erythematous and inflammatory patches, surmounted by groups of pin-head- to pea-sized vesicles, and its distribution over the course of a nerve are entirely wanting in eczema. Herpes zoster comes on suddenly and is often preceded and accompanied by neuralgic pain: eczema is never neuralgic, and often insidious in its appearance.

Lichen Planus.—The irregular base, flattened top, with often central depression, and the dark-red or violaceous color and the glistening surface of lichen planus papules usually suffice to distinguish them from the rounded or acuminated, bright-red papules of eczema. The lesions of lichen are, as a rule, slow in appearance and are persistent, and always papules, and, when disappearing, leaving brownish or purplish stains: those of eczema generally present acutely, and are less apt to persist as such, often showing a tendency to vesiculation, and rarely leave discoloration. The solid scaly areas of lichen planus resulting from an overcrowding of the lesions bear resemblance to scaly eczema, especially that evolving from papular eczema, but the lichen plaques are darker red and usually purplish in color and sharply defined: those of eczema bright red, and generally fade off gradually into the surrounding skin; moreover, in lichen planus scattered, characteristic, discrete papules are almost always to be found at the edges of the patch or near by, which would serve for differentiation.

Lupus Erythematosus.—There is a resemblance, on casual inspection, between squamous eczema and this disease; but in lupus erythematosus the sharply defined border, the firmly adherent but less abundant scaliness, and often the evident involvement of the sebaceous glands, as shown by the distended and scaly plugging of

the ducts, and in most cases the tendency to central atrophy of the patch, are sufficient points of difference from the conditions observed in eczema, in which glandular duct involvement, sharp border, and atrophy are wanting. If the scales are removed in lupus erythematosus or are scanty, the patch, pale or deep red in color, is apt to have a dirty-white dotted look, due to the accumulation in the ducts. Moreover, lupus erythematosus is usually a strikingly chronic and slow process, often taking months for the formation of a dime- or quarter-dollar-sized area. The subjective symptoms of lupus erythematosus are slight or absent, whereas in eczema usually troublesome. Ordinary eczema rarely shows the peculiar distribution common with lupus erythematosus—across the nose, and spreading, wing-like, on to the cheeks. When not so distributed, the above differences will, however, be sufficient to distinguish.

Miliaria.—The vesicular variety of miliaria cannot well be mistaken for eczema, as the lesions, though they may be numerous, are discrete and remain so, with no tendency to confluence, and little, if any, to spontaneous rupture, and the contained fluid is not of sticky character, features just the opposite of those observed in vesicular eczema. The papular variety of miliaria possesses greater resemblance, but here the discrete character, the sudden advent, and usually after profuse sweating or heat exposure, distinguish it from papular eczema. Moreover, in vesicular and papular eczema, when the lesions are as crowded as generally observed in miliaria, there are usually underlying inflammatory swelling and perhaps infiltration, conditions not observed in the latter disease either in its papular or vesicular varieties. Besides, eczema itches greatly: miliaria rarely to as great a degree, and is sometimes absent, the subjective symptoms being more a feeling of pricking, tingling, and burning. Miliaria runs a rapid course, and if the cause ceases to act, disappears in several days to one or two weeks: eczema, although it may be acute in coming, is apt to evolve into the chronic and persistent disease.

Pityriasis Rosea.—This malady has some resemblance to mild scaly eczema, but the circinate tendency shown in many of its efflorescences, the numerous patches with but slight disposition to confluence, the superficial character of the process, its rapid appearance, and its limitation, in great measure, to the trunk and upper part of the limbs, the slight degree of itching or its entire absence, and the definite course of the disease, are characters at variance with the features and behavior of eczema. It bears greater resemblance to eczema seborrhoicum, under which it will again be referred to.

Pruritus.—This disease is characterized by simple itching and nothing else, and, therefore, eczema, with its infiltration, vesicles, papules, scaliness, etc., can scarcely ever be confounded with it. There is only one symptom common to both, and that is the itching, and this, as remarked, is the sole symptom in average cases of pruritus. In the latter disease, however, if intense and persistent in character, the constant rubbing and scratching provoked may give rise to follicular papules and some erythematous areas, but these are always in places readily reached by the hands. Moreover, the history of pruritus, with its absence of lesional symptoms, except those as a result of

scratching, etc., will serve to prevent error. Pruritus ani, pruritus scroti, and pruritus vulvæ may, however, from the incessant scratching and rubbing, lead to true eczema.

Ringworm.—The ordinary round patch with the clearing center of ringworm of the non-hairy surface is not met with in eczema. Nor is the method of its spread, beginning usually as a small scaly spot, often soon afterward with a somewhat elevated and scaly or papular or vesicopapular border, and clearing up centrally, leaving slight scaliness or branny furfuraceous desquamation or a smooth surface, ever seen in eczema; this latter never behaves that way. Ringworm of the scalp may suggest a mild scaly eczema, but in the former the evident hair involvement, as shown by the broken-off hairs and hair stumps, and partial hair loss on the patch, and the insignificant scaliness are never found in the latter malady. In the more inflammatory pustular or papulopustular ringworm of this region the appearances simulate eczema, but the hair symptoms, as described, are present and serve to differentiate. Even in obscure disseminated scaly spots of scalp ringworm in which the alopecia and hair invasion are not so obvious, still broken hairs and short small stumps just peeping out from the follicles (black-dot ringworm) suffice to distinguish it from eczema.

Ringworm of the genitocrural, and sometimes axillary, region assumes an eczematous aspect, and has been well called "eczema marginatum," but the sharply defined spreading, often festooned, border, with usually one or several outlying typical ring-like patches, as well as the history of the eczematous-looking area, beginning in similar ring-like manner, are entirely different from ordinary idiopathic eczema. Moreover, in a large majority of ringworm cases a history of contagion is elicited. Nor does ringworm itch, as a rule, nearly so much as eczema, although the last-named type frequently does. In doubtful cases microscopic examination of the scrapings will determine. The differences from ringworm of the bearded region will be considered under the next heading.

Sycosis.—There is a similarity in the eruptions of eczema and sycosis vulgaris, but eczema is not often follicular, and the lesions are often crowded together, forming a solid sheet; it rarely is limited to the hairy parts of the face, but oversteps these regions, and is also often seen elsewhere upon the surface at the same time; the itching is troublesome. In sycosis, on the other hand, the lesions are always follicular and discrete, with each lesion pierced by a hair, and even when crowded, show their follicular character; the eruption is strictly limited to the hairy parts, and the subjective symptoms are rarely complained of. In eczema, moreover, there is at times apt to be the characteristic gummy discharge, whereas this is not observed in sycosis.

In ringworm sycosis (tinea sycosis) of the superficial type the ring patches are characteristic, and serve to differentiate from eczema. In the deep-seated or nodular ringworm sycosis there is usually a history of the disease beginning as a ring-like spot, the hairs are involved, are broken or are loosened and fall out, and there is marked

cutaneous and subcutaneous lumpiness or nodules—symptoms which are entirely lacking in eczema.

Syphilis.—Syphilitic eruptions can rarely be confounded with eczema. The secondary eruptions of syphilis are usually discrete, though more or less generalized in distribution; there is no tendency to the formation of confluent areas; they are darker in color, and more sluggishly inflammatory in appearance, and the color does not always disappear upon pressure, as commonly in eczema; and, in addition, there are other symptoms of syphilis, and often a history or evidence of the initial lesion; moreover, eczema itches, and the syphilodermata do not, excepting sometimes in the miliary papular and papulopustular eruption, and then only, as a rule, in negros. In this latter class, however, itching, usually slight in character, is often complained of in the various syphilodermata, especially the small lesional varieties named. The limited papulotubercular and tuberculopustular area or areas of late syphilis occasionally present a rough resemblance, especially upon the scalp, but the distinct infiltrate, the copper or cutham color, the sluggish character, the segmental and circinate arrangement, and usually evidences of destructive action, as shown by ulceration and scarring, atrophy, and pigmentation, and the absence of itching are quite characteristic of syphilis and wanting in eczema; moreover, the history and the clinical behavior of the two affections are different.

Squamous eczema of the palms and squamous syphiloderm of this region at times resemble each other closely, but the former is more apt to be diffused and often shows equal involvement with the fingers, and in the latter regions occasional vesiculation, usually deep seated; palmar syphiloderm is generally patchy, rather sharply defined, generally wavy or segmental in outline, and often with a distinct circumscribed infiltrate. Fissuring is not, as a rule, a marked feature of syphilis, while it is frequently a pronounced feature in eczema; the syphiloderm is always dry; eczema is noted at times to be moist although this, in the palmar region, is often entirely wanting throughout; in syphilis the eruption is sometimes limited to the one hand: in eczema it is generally in both; palmar syphiloderm is sometimes associated with a similar condition on the soles: eczema rarely. Intense itching would indicate eczema, but comparative lack of it has but little import, inasmuch as in squamous eczema of this region it is occasionally trifling—not complained of, and even denied; entire absence of itching, however, usually means syphilis. Often a history of the latter disease is obtainable. It must be admitted that in exceptionable instances the diagnosis as between these two conditions is difficult, and the course of the disease under treatment is to be noted.

Urticaria.—The ordinary wheals of urticaria will almost invariably serve to distinguish it from eczema, in which such lesions are not observed. Papular urticaria (lichen urticatus), in which, especially in young children, the lesions are small and often excoriated, resembles papular eczema very closely, but in the former they are usually scattered and discrete, whereas those of eczema are commonly on one or two regions, and often show aggregation or solid patches.

The papules of urticaria frequently are noted to be left from pre-existing more or less typical wheals, and not infrequently characteristic wheals, or the history of such, appearing from time to time will aid in the differentiation.

There are some other diseases with which eczema may, if hurriedly examined, be confused, but they are so exceedingly rare, even in the experience of dermatologists, that special differentiation is scarcely called for. These are prurigo, pityriasis rubra pilaris, pemphigus foliaceus, dermatitis repens, and Paget's disease, but they differ materially in appearance, behavior, and course, as the description of those several diseases will show, and under several of which reference will be made to the more important differential points.

Prognosis.—While eczema must, in the larger number of cases, be considered obstinate, yet instances are relatively few in which relief and cure cannot be effected, if proper opportunity is given to reach that end; but this does not necessarily always mean permanency and freedom from future attacks, unless the etiologic factors can be permanently removed or kept in abeyance, for if these come again into play, a recurrence is possible, or, in many cases, even probable, the same as is observed in almost all other diseases under the same circumstances. Eczema never produces tissue destruction and never leaves scars or any other trace except on the legs, where, if of long duration, and especially in older people and those with varicose veins, some pigmentation may remain. Nor has eczema any direct action upon the general health, but in severe, long-continued, intensely itchy cases, from the consequent worry and loss of sleep, the patient may become debilitated and neurasthenic. The prognosis in the individual case depends upon several factors—the locality and extent of the disease, its duration and previous behavior, the removability of the predisposing and exciting causes, the general health, and the attention the patient can or will give to carrying out the treatment. It may be said that acute or sudden attacks yield, as a rule, more readily than those that are developed slowly and insidiously. The moist types are generally also more responsive than the dry forms. Cases in which there is a marked tendency to fissuring are usually obstinate.

Wherever the disease is situated, whatever its type, extent, and duration may be, and whatever the age of the patient, its cure is never attended with evil consequences, nor can its cure be, for the comfort and well-being of the patient, too rapid. The few isolated instances among the hundreds of thousands of eczema cases in which an untoward result has been reported (Gaucher, Brocq, Brooke, Duhring, Hallopeau and Leredde)[1] as possibly due to rapid disappearance or suppression of the cutaneous disease can be more reasonably, I believe, placed to the score of pure coincidence. In-

[1] Brocq, *Jour. de médicine de Paris*, 1889, pp. 680 and 691, and *Brit. Jour. Derm.*, 1889, p. 105; Gaucher, Congrès Internat. de Derm. et de Syph., 1889, *Compt.-Rend.*, p. 538 (refers especially to children); Brooke, *Medical Chronicle* (Manchester), vol. xi., 1889–90, p. 206; Duhring, *Cutaneous Medicine*, part ii., p. 341; Hallopeau et Leredde, *Traité pratique de Dermatologie*, Paris, 1900, p. 357.

deed, instead of such suppression being the cause, it is itself probably the result, of the intercurrent constitutional disease, as it is a matter of not uncommon observation that inflammatory skin affections tend to subside temporarily upon the advent and during the course of a severe, especially febrile, disease. In fact, one can safely say that the secret of the attainment of a rapid suppression of an eczema has yet to be learned, for, unfortunately, the cure is in the vast majority of cases accomplished only after at least several weeks or months of persistent effort.

Eczema of the scalp often responds rapidly if the infiltration is not very pronounced. As a rule, the hair suffers but little; in infants, from the constant rubbing of the back of the head against the pillow, the hair is sometimes rubbed off to a variable extent, but not permanently. On the face, the disease is frequently obstinate, and especially in those whose vocation subjects them to exposure to cold winds and dampness, or to intense heat or to irritating substances. Eczema of the nares and of the lips is somewhat variable as to the time and effort required, some cases yielding readily. Eczema of the hands is often obstinate, occurring as it does most frequently in those of the laboring classes, whose work in itself may be the exciting cause, and which prevents a response to therapeutic measures; in such cases, indeed, unless the occupation can be temporarily suspended, a cure is usually impossible; and in many of these instances resumption of the same work will often induce another attack. Eczema of the nails is, as a rule, obstinate. Eczema of the crurogenital and anal regions is also frequently rebellious, the friction, heat, and moisture of the parts serving to keep up the disease or rendering the applications less efficacious; the same may be said, but less strongly, of the disease in other flexures. On the legs the malady, though severe, commonly yields more or less readily, but occurring in those of advancing years, whose necessities require them to be upon their feet many hours of the day, it is sometimes slow to respond, and occasionally treatment fails absolutely until this predisposing cause is lessened or temporarily suspended. In eczema of the trunk the disease is rarely obstinate; about the nipple and the umbilicus, however, it is often persistent. In acute, more or less generalized eczema it responds, as a rule, somewhat rapidly, but after a certain point is reached the progress is much slower, and in occasional cases the disease persists upon one or two regions, most commonly the legs, for some time after it has been removed from other parts.

Infantile eczema, as a rule, is, more especially if of the face and scalp, its most common situations, quite amenable to treatment, though often slowly so; if in the first year or two of life, in some cases slight recurrences may be expected, but if the patient is aged four or five, the time when such eczemas tend to get well spontaneously, not only will the disease often respond surprisingly well, and to even treatment of an indifferent kind, if not irritating, but the cure usually remains permanent. On other parts the results are finally satisfactory also, but are not so quickly obtained.

Treatment.—The earlier French teaching that eczema was due

to a diathesis, and that treatment was to be chiefly constitutional, and the antithesis in the leading Vienna belief of about the same and later period that the disease was essentially external in character, and required, as a rule, external treatment alone for its removal, have gradually been approaching a middle ground, which English and American physicians have, upon the whole, for a long time maintained—that most cases, for success of any permanency, demand both constitutional and local remedies. This, I believe, experience proves to be the rational view. It is true many cases, some of which—as, for example, trade eczemas—seem to be entirely local in their nature; and in such cases external treatment alone will have satisfactory results. But even in some of these patients underlying or concomitant systemic disorders often impede the progress toward recovery, and if present should be given attention.

Constitutional Treatment.—This does not necessarily always mean medicinal, for often attention to diet and other hygienic considerations are more potent than drugs. While it is not possible to say that certain foods directly induce eczematous conditions, still there are many, through their difficult digestibility or through their influence upon the digestive process, and possibly their absorption before thoroughly in condition for such, which are often factors of some moment. For this reason the diet in eczema cases should always be plain but nutritious, the meals taken at regular times, and in sufficient, but not superfluous, quantity. Such foods as pork, in any form, salted meats, pastries of all kinds, veal, lobsters, crabs, "gamy" fowl, fried dishes, gravies, sauces, cheese, pickles, condiments, fruits, and like articles are to be avoided. Fish in some of the cases is a questionable food, probably due to the fact that much of it on the market at the present day is from "cold storage," and may have undergone change. Oysters in the cold season are permissible, for they are then usually well kept, but in warm, sultry weather they undergo rapid deterioration and seem to develop intestinal toxins, and often aggravate the disease. Excessive tea- or coffee-drinking is to be interdicted; likewise indulgence in beer, wine, and other alcoholic stimulants; the malted liquors especially seem to exert an unfavorable effect. Alcohol tends to produce dilatation of the cutaneous vessels, besides its influence in invoking or emphasizing defective kidney elimination, and is, therefore, even in moderate quantities, especially damaging. To the very old and feeble, accustomed to whisky or brandy, and who apparently need its support, its continued use in moderate quantity should ordinarily be allowed. The excessive use of tobacco should also be prohibited.

An ample dietary is to be found with the meats, beef, mutton, lamb, poultry, and with the ordinary vegetables; potatoes should be taken in moderation. In gouty and rheumatic cases an excessive meat diet should be avoided, but there are some instances of these underlying states that are due rather to the faulty starch digestion than to the meats, usually in those in whom there is distinct digestive weakness, and such patients will often do better with a fairly full meat allowance, together with the less starchy vegetables. In troublesome cases, if of any extent, a rigorous milk diet with an allowance of meat

or eggs once daily will sometimes start the change toward recovery. In the matter of food, individual idiosyncrasies should be considered. In fact, in obstinate and persistent cases a purely meat diet has proved of curative aid in some instances (Squire, McCall Anderson). The same experience has also been noted with a purely vegetable diet (Neusser, Jarisch); the general condition of the patient and his constitutional traits influencing the selection. Another factor, not medicinal, and often of service, is the free drinking of water, not during the meals, but between times; a full glass of water a half hour to an hour before each meal and at other times is often of service in promoting proper elimination through the kidneys. In some patients the water before meals can be taken with greater advantage quite hot. It is the free water-drinking, I believe, along with the regulation of the diet and the ordered exercise, and consequent regular bowel movement, which is the strong element at the different mineral spring resorts, the medicinal ingredients of the water scarcely being in sufficient quantity to be of direct service. Systematic exercise, preferably in the open air, moderate indulgence in calisthenics, living in well sun-lighted rooms, and being as much as possible out-of-doors under the direct influence of the sun's rays, are matters of great value in cases of any extent. The value of light, and especially sunlight, as a therapeutic agent, is not, I believe, as yet given the appreciation it deserves.

The plan of constitutional medicinal treatment, when such is indicated, as it usually is, is to be based upon the indications in the individual case. A careful examination into the patient's general health will usually give the cue to the line of treatment to be adopted. There are no specifics for this disease; arsenic, which was formerly in great vogue, is now known to be only occasionally of service, although it is still greatly used, often to the patient's disadvantage, by the general profession. It should, as a rule, be the last remedy resorted to, rather than the first, as other plans are much more generally successful. This remedy will be referred to again. The aim in all cases is to see that the important emunctories of the body—the intestinal tract and the kidneys—are performing their work; sometimes this is accomplished by attention to hygienic means alone, as already indicated, but often it needs medicinal reinforcement. A proper action, and preferably free action, of the bowels is a most essential desideratum in the management of eczema.

In some cases the constitutional treatment, or, properly speaking, management, need not go beyond the measures just indicated; but in many instances, as noted in discussing etiology, there is disturbance of the digestive apparatus, of which constipation is but a feature. In many of these patients the daily or occasional administration of a laxative, along with an ordinary tonic digestive mixture, associated with mild soothing or slightly stimulating external applications, will soon bring about recovery. As a rule, the various salines, such as Epsom salts, Rochelle salts, sodium phosphate, and the saline aperient mineral waters, are of most service in eczema cases. A frequently used and valuable saline laxative tonic is that known as "mistura ferri acida," the formula for which is as follows:

℞. Magnesii sulphat., ℥j–iss (32.–48.);
Ferri sulphat., gr. iv (0.265);
Ac. sulph. dilut. fʒj (4.);
Aquæ menth. pip., q. s. ad f℥iv (128.).
Sig.—A tablespoonful in a full tumblerful of water about twenty minutes before breakfast.

If not sufficiently active, the dose may be increased somewhat, or a smaller amount can be taken before each meal. In gouty or rheumatic cases the acid should be omitted. Another saline mixture of value, and which can be used as a substitute for Carlsbad salts, and which is in reality more efficient for these cases, is: ℞. Granulated sodium sulphate, ʒx (40.); sodium bicarbonate, ʒiv (16.); sodium chlorid, ʒij (8.); the dose is from one to two teaspoonfuls in a tumblerful of water twenty to thirty minutes before breakfast, or in smaller dosage before each meal. It is to be kept in a closely stoppered, wide-mouthed bottle, as it is hygroscopic. Patients who do not seem to bear salines well can take the following bitter laxative tonic, and which can be given in many cases to advantage: ℞. Sodii salicylat., ʒj–ij (4.–8.); ext. cascaræ sagradæ fl., fʒj–iv (4.–16.); tinct. nucis vomicæ, fʒij–iv (8.–16.); and tinct. cardamom., or tinct. gentian., q. s. ad f℥iij (96.); of this, a teaspoonful in water after each meal. The quantity of cascara should be increased or diminished according to the effects; ordinarily, two to three drams (8.–12.) in such a mixture will be required. In some cases, especially if there is torpid liver action, an occasional laxative dose of calomel, usually 1 to 3 grains two or three times weekly, will not only be a satisfactory laxative, which can be taken for a time, but will sometimes exert a favorable influence upon the disease. Or, instead of taking it in this dosage, the small triturate of $\frac{1}{10}$ of a grain (0.0065) of calomel and 1 or 2 grains (0.065–0.13) of sodium bicarbonate can be given at half or hour intervals until laxative effect is brought on—not more than 10 to 15 tablets, and repeated every few days. Among other satisfactory laxatives to which recourse may be had are the aloin-strychnin-belladonna pills, the compound licorice powder, the plain fluid extract of cascara sagrada.

In some of the eczema cases in which stomachic acidity is a factor sodium bicarbonate, or if there is fermentative tendency, sodium benzoate, 10 to 20 grains three times daily, alone or often associated with advantage with a bitter, will prove of benefit. In other cases hydrochloric acid often acts satisfactorily; as a rule, however, acids are not so desirable in eczema as alkalies. In many instances of digestive debility the various digestive aids, such as pepsin and pancreatin, can be given along with a bitter stomachic. In some of these cases, usually those of stomachic and intestinal indigestion or catarrh, in which diarrheic attacks come on from time to time, laxatives must be used with care; in such patients or at such times bismuth, charcoal, and salol can be administered. In short, in these cases the aim is to remove any existing dyspeptic conditions, to improve the digestive tone, and to meet any special indications as they may arise. In persistent stomachic catarrh occasional lavage of this organ is to be tried.

In another class of patients—the neurasthenic class—invigorating measures of all kinds are to be advised; in some, absolute or relative rest; in others, daily calisthenics and out-door exercise; general massage in suitable cases; and the use of such drug tonics as strychnin, quinin, the hypophosphites, cod-liver oil, and arsenic. It is in this class, and especially when the eruption is extensive, that electricity, in the method of general galvanization, seems to be of service; running a strong current down the spine is also of value. It is probably more particularly in neurotic cases that counterirritation (Crocker)[1] by means of mustard plasters, heat, friction, or wire-brush electrode (Hyde)[2] over the corresponding vasomotor centers occasionally proves of value. It is not advisable, however, in my judgment, to use such counterirritant in instances in which there is still tendency to outcropping of new areas.

In other cases—the gouty and rheumatic—the salicylates, salol, salophen, salicin, sodium bicarbonate, potassium bicarbonate, potassium acetate, the salts of lithium, and exceptionally colchicum, are the most important remedies, along with attention to diet in the lines already indicated. In another class of cases the disease seems to be kept up by a general debilitated state of the system, and in these there is nothing so valuable, if it can be taken and digested, as cod-liver oil. The dose should not be large—from ½ to 2 fluid-drams (2.–8.) will be sufficient; in fact, for its good effects the dose of a dram (4.) need rarely be exceeded, and when so limited, there is less chance of disturbing digestion, and thus necessitate the discarding of a valuable remedy. With this may be administered fairly large doses of strychnin, and in some cases small doses of iron.

There are other classes of patients, etiologically considered, but the several named comprise most of the cases. For instance, malaria, diabetes, and albuminuria may at times be considered active underlying conditions, and then proper treatment of these will aid materially in rendering the external treatment more effective. In some instances, however, it is difficult to assign a cause for the disease, either constitutional or external. Under such circumstances the treatment is entirely empirical, being chiefly conducted on the assumption that an obscure underlying gouty cause is operative, or some slight or unrecognizable assimilative or digestive irregularity. If treatment upon such lines seems futile, there are certain special remedies, variously indorsed, that may be tried experimentally.

Arsenic has long been extolled as having a specific influence in eczema, but it may be safely stated that it is prescribed by specialists for alleged specific effect in only a small percentage of cases. It is often given in small doses as a tonic along with other drugs of the same class, and is especially valuable in patients with underlying anemia, chlorosis, etc. (Hardaway, Morrow, Jarisch, and many others). It may be tried, however, in obscure cases for its specific effect. The drug is a cutaneous stimulant, and should not, therefore, be employed in acutely developing cases, nor, as a rule, in those of

[1] Crocker, *Brit. Med. Jour.*, July 9, 1887, p. 66.
[2] Hyde, *Twentieth Century Practice*, vol. v., "Diseases of the Skin," p. 196.

an acute type, as aggravation will almost certainly follow. Its special field is thought to include those of a sluggish, papular, or squamous type, and in some such instances I have occasionally seen it act most happily, but even in especially indicated cases it often fails to make an impression, and sometimes is detrimental. It should be continued for some weeks unless the disease seems aggravated or the drug causes positive systemic disturbance, usually digestive or neurotic in character. Among other remedies variously extolled may be mentioned viola tricolor (Piffard,[1] Ferguson), oil of copaiba, oil of turpentine (Crocker), tar (McCall Anderson, Duhring), jaborandi or pilocarpin (Simon, Jamieson), ergotin (Lewin, Jarisch), ichthyol (Unna), and wine of antimony or tartrate of antimony (Morris, Jamieson [2]).

Eczema in infants and young children is most frequently attributable to improper feeding, to digestive irregularities, and to constitutional debility. Special attention must, of course, be given to the feeding, and it is to be remembered that in artificially fed infants milk, sterilized or pancreatized, is to constitute the chief and, as a rule, the only food. Not much is to be hoped for permanently in these cases of eczema in infants and children unless the dietary is rigorously supervised. Lime-water added to the milk, a tablespoonful (16.) to the 4 ounces (128.), is sometimes a help. Constipation is to be corrected by the administration of fluid extract of cascara sagrada, gray powder, or castor oil. Of the first, the dose is from 2 to 10 drops (0.133–0.65), given in a little syrup of ginger or orange or other flavoring excipient; the dose of gray powder is from 1 to 2 grains (0.065–0.13) at bedtime every second or third night; castor oil may be given with an equal part of the spiced syrup of rhubarb, in the dose of from one-half to a teaspoonful at bedtime, or three times daily, depending upon the age of the child and the effect produced. Enemata and glycerin suppositories may also be resorted to from time to time. In these little patients a small dose of sodium bicarbonate three times daily will sometimes influence the disease favorably. In fact, in these cases the digestion must be looked after carefully. In many of these infants the nutrition is below the standard, or the patients are of the so-called strumous diathesis. Under such circumstances cod-liver oil is a most admirable remedy, given in emulsion with calcium lactophosphate, or in mixture with an equal part of lime-water; of either of these the dose is from one-half to a teaspoonful three times daily. A mixture which I have often found useful in such cases and in which constipation is present is one composed of cod-liver oil and castor oil in variable proportion, according to the bowel torpidity, and with several drams of spiced syrup of rhubarb to the 3 ounces (96.), to give it flavor. In infantile eczema cases the possibility of the disease being dependent upon or aggravated by reflex irritation is to be borne in mind; the question of an adherent prepuce, an emerging tooth, or intestinal parasites should receive attention.

[1] Piffard, "On Viola Tricolor and its Use in Eczema," *Med. Record*, April 29, 1882; Ferguson, "Viola Tricolor in Chronic Eczema," *Canadian Jour. Med. Sci.*, April, 1882.

[2] Malcolm Morris, *Brit. Med. Jour.*, Sept. 22, 1883, p. 572; Jamieson, *Brit. Jour. Derm.*, 1891, p. 271.

External Treatment.—The external treatment of eczema is of essential importance, and must be resorted to in every instance. In certain cases, as already remarked, external applications alone suffice to bring about a cure. There are certain general principles in the local management of this malady that should be kept well in mind. The affected surface is to be freed from the products of the disease—the crusting and the scaliness. This is best accomplished by means of oily or unctuous applications, supplemented, in suitable cases, from time to time, with washing with soap and warm water. In acute cases, however, and also, as a rule, in those of an acute type, soap and water are rarely admissible; in such instances cleansing can usually be effected by gently wiping with cold cream or petrolatum. Many cases in which there is but a slight degree of scaliness or crusting the remedial treatment alone, especially if consisting in the application of ointments or oils, will serve in itself to remove such products. In those of more marked scaliness or crusting, plain carbolized oil (gr. v–f ℥—0.33–32.) or liquid petrolatum may be used freely, applying it every hour, or flannel cloths soaked in oil can be applied and allowed to remain in contact with the affected surface; after several hours or half a day the parts are then washed with warm water and a mild toilet soap. Or the remedial application may even in such instances in the very beginning be supplemented with the daily washing with soap and water, and as soon as the surface is freed, the latter can be omitted or used at intervals. If the crusting is abundant and adherent, a plain poultice or starch poultice, and preferably made with 2 per cent. boric acid solution, may be used instead of oily applications for the purpose of softening, and be followed by the soap-and-water washing.

After removal of the scaliness or crusting, soap and water are, as a rule, to be used as infrequently as possible in average cases of the acute and subacute types of the disease, as both are irritating in their effect; in instances of marked irritability, or aggravation from such, the parts can be cleansed from time to time with cold cream, vaselin, or almond oil. In certain cases, however, more especially those of chronic sluggish character, the use of soap and water has a therapeutic value.

The selection of the plan of medication and the strength and character of the applications depend chiefly upon the type of inflammatory action. Even in long-continued cases of the disease the type of inflammation is at times persistently acute, although more frequently subacute. On the other hand, some are from the outset sluggish or chronic in character. For a proper conception of the management of eczema, therefore, the degree of inflammatory activity must be considered; it matters not upon what part of the body the disease may be located. In great measure, too, upon the character and type depends the choice of whether lotions, dusting-powders, ointments, oils, or fixed dressings shall be employed. This will be indicated as the various inflammatory grades are considered, but there is no absolute rule. It can, however, upon the whole, be said that lotions with sediments are most useful in the acute and subacute moist types; that clear lotions may be used in such instances, as also in dry types, often with benefit, if ½ to 2 drams (2.–8.) of glycerin

are added to the pint (500.), but, as a rule, more satisfactorily when conjointly with ointments; clear lotions can also be used in erythematous types, sometimes alone, but usually preferably with a supplementary dusting-powder. In thickened, subacute and sluggish cases ointments and fixed dressings (gelatin, etc.) are generally most useful, and especially in the dry forms. Oils are also of value in the latter, but their use is limited.

A substitution of one plan or form of application for another is often necessary, either for the reason that no improvement had followed or in consequence of change of type—from moist to dry—as the result of the treatment first employed. Nor is it always possible to say that a given remedy will be of service, some skins exhibiting marked idiosyncrasy; all changes should be instituted cautiously, and, as a rule, the application tried on a limited area first. It should, moreover, be a dermatologic axiom, and most applicable in eczema, that so long as a selected remedy or plan is benefiting it should be continued.

The methods of applying the remedies are of importance. The clear washes can be simply applied with a soft linen rag or a pledget of absorbent cotton or with an atomizer; those containing sediments dabbed on for several minutes and allowed to dry on, or pieces of linen cloths can be kept constantly applied and freely wet with it from time to time. Lotions are not to be rubbed on. Oily, emulsion-like applications can be applied in the same manner as the sediment lotions. In sluggish cases plain oily applications can be rubbed in, and usually with considerable vigor. Ointments are applied in all types of a moist character, and also in the acute dry type, either by anointing or spread upon lint. The latter is more efficient, but not always practicable. In dry, sluggish, subacute and chronic types they can be rubbed in, using a variable amount of friction, and if increased action is desired, can then be applied as a spread plaster. If at any time the sediment of lotions or the pastes should mass upon the surface and adhere firmly, softening with an oil or cold cream or vaselin will usually suffice for removal.

One of the most troublesome phases of the management of eczema cases is the control of the itching, and often attention must be given, for a time at least, to this point exclusively. Ordinarily the plans of treatment to be considered will hold this symptom within bounds, but occasionally the selected plan must give way to another, or recourse must be had to the special remedies useful in this condition. The addition of carbolic acid, thymol, or hydrocyanic acid to the selected application will usually suffice; in exceptional instances, if relief is not afforded, applications of hot water as hot as can be borne, and more certainly if it contains ½ to 1 grain (0.033–0.065) of sodium bicarbonate to the ounce (32.), will bridge over the pruritic attack. To the pint of lotion carbolic acid can be used in the quantity of ½ to 2 drams (2.–8.); thymol, 8 to 16 grains (0.5–1.); dilute hydrocyanic acid, 1 to 4 drams (4.–16.); and to the ounce of ointment carbolic acid, 2 to 30 grains (0.133–2.); thymol, 1 to 10 grains (0.065–0.65); dilute hydrocyanic acid, 5 to 20 minims (0.35–1.35). Menthol can also be used in ointment, 1 to 10 grains (0.065–0.65) to the

ounce (32.). Of these, carbolic acid is the most valuable. Thymol, in lotion, needs some alcohol and glycerin for its solution.

Unless one is especially skilled in the management of diseases of the skin it is a good plan to begin the treatment of all cases, even though somewhat sluggishly inflammatory, with the remedial applications to be mentioned as appropriate for the acute type; much can frequently be accomplished, and at least the patient's confidence is gained, and then one can, if it seems necessary, go ahead more boldly.

In **acute or actively inflammatory** cases of any variety, and *in almost all cases in which there is scarcely perceptible infiltration and no epidermic thickening*, mild applications alone are well borne. In such the conjoint use of a boric acid lotion, 15 grains (1.) to the ounce (32.), and a mild ointment, such as the zinc oxid, cold cream, or petrolatum, will often give relief; the zinc ointment is probably the most satisfactory. The same may be said of the treatment (White) with lotio nigra, pure or preferably with an equal part of lime-water, in conjunction with such an ointment; if over a large surface, the dilution with lime-water should be greater, to avoid the possibility of mercurial absorption. The lotion is first thoroughly dabbed on for several minutes or longer, and allowed to dry or partly dry; then a small quantity of the selected ointment is gently smeared over; or the ointment may by applied spread upon lint or linen. If the disease is extensive and there is danger of chilling, the surface can be merely moistened with the selected lotion, and then the salve applied immediately; or preferably a small part may be thoroughly gone over at a time, and as soon as anointed another part treated. When the application is repeated, which should be done every several hours, or, at the least, two or three times daily, the parts are first gently wiped off with a piece of soft linen or absorbent cotton; in many of the cases in which the ointment was merely smeared on it has entirely disappeared by the time another application is to be made. I cannot speak too highly of these two plans, nor urge too strongly their value and safety in the beginning management of most cases; it is only in extremely rare instances that either proves irritating. The boric acid lotion is especially valuable, probably by its mild antiseptic property,[1] and is, in my practice, almost indispensable. The use of a compound lotion alone is often beneficial in the erythematous and papular varieties:

℞.	Acid. borici,	ʒij (8.);
	Acid. carbolici,	ʒss (2.);
	Glycerini,	♏x–xxx (0.65–2.);
	Aquæ,	q. s. ad Oss (250.).

This can be used with or without an ointment. Its effect is sometimes enhanced by applying, immediately after it dries, a simple or compound dusting-powder, such as named below. An oily lotion or liniment, soothing in these acute cases, is one composed of equal

[1] See suggestive paper by Klotz, "The Principles of Antisepsis in the Treatment of Eczema," *Jour. Cutan. Dis.*, 1894, p. 99. Only the milder antiseptics are permissible in eczema, the employment of the stronger surgical antiseptics, such as corrosive sublimate solutions, formalin, strong carbolic-acid solutions, etc., are usually aggravating.

parts of lime-water and sweet almond oil, with ½ to 2 grains (0.033–0.13) of carbolic acid or resorcin to the ounce (32.). Or in these same types and also in the vesicular form of the disease the following calamin-and-zinc-oxid lotion may be used:

℞. Calaminæ,
Zinci oxidi, ʒij–iv (8.–16.);
Liquor. calcis, fʒij (64.);
Aquæ, vel solut. ac. boric. satur., q. s. ad Oss (250.).

This is to be dabbed on freely several times daily; it will act more satisfactorily if linen cloths kept wet with it are constantly applied. If the itching is troublesome, to the last lotion may also be added from 15 grains to 1 dram (1.–4.) of carbolic acid, or from 2 to 8 grains (0.13–0.52) of thymol, or from 8 grains to 1 dram (0.52–4.) of resorcin, to 8 ounces (250.). These several last-named drugs may be used alone as lotions, in the strengths indicated, especially in the erythematous and papular varieties. Another mild soothing lotion of benefit in cases of acute type consists of:

℞. Zinci oxidi, ʒij–iv (8.–16.);
Acid. carbolici, gr. xx (1.3);
Mucilag. acaciæ, fʒij (7.5);
Emuls. amygdalæ, fʒij (60.);
Aquæ, q. s. ad fʒviij (250.).

Liquor carbonis detergens,[1] from 1 to 2 drams (4.–8.) to the pint (500.) of water, or in the same proportion added to the several lotions named, is useful in these cases. Ichthyol as a lotion, from 1 to 4 drams (4.–16.) to the pint (500.), also proves of service. Lead-water (liquor plumbi subacetati dilut.) with several or more parts water is likewise a soothing application, sometimes beneficial in the acute types.

With the lotions free from sediments their use with supplementary applications of a dusting-powder after the lotion has dried on, or before completely dry, is often an admirable method, especially in the erythematous and papular types.

Powders are, indeed, frequently used alone in the first few days, in extensive erythematous acute cases of this class, and sometimes give a good deal of relief, and are more especially serviceable when the affection occurs in regions where two surfaces come in contact. They are also occasionally used in the secondary stages of the more acute vesicular disease, for their desiccating influence, especially in cases in

[1] Liquor carbonis detergens is a proprietary coal-tar preparation made by Wright & Co., London; it is essentially a solution of coal-tar in soap-bark tincture. Equally as good, however, and even superior, is one which I can strongly commend, used for many years at the Skin Dispensaries of the University of Pennsylvania, Jefferson Medical College Hospital, Philadelphia Dispensary for Skin Diseases, and Howard Hospital, made as follows: Coal-tar, 4 parts; strong soap-bark tincture, 9 parts; digest for eight days, frequently shaking and stirring, and finally filtering. The soap-bark tincture is made with 1 pound soap-bark to 1 gallon 95 per cent. alcohol, digesting for a week or so. More recently Professor Duhring, *Amer. Jour. Med. Sci.*, May, 1894, has modified this formula, using 1 part coal-tar to 6 parts soap-bark tincture, and suggested the name compound tincture of coal-tar (tinct. picis mineralis comp.); it is, however, weaker than the other formula named.

which ointment applications and lotions are found to be irritating. The powders most commonly employed are zinc oxid, talc, boric acid, lycopodium, starch, magnesium carbonate, rice-flour, zinc oleate, zinc stearate, and bismuth subnitrate. The following is a serviceable and clean combination: ℞. Pulv. ac. borici, gr. xxx (2.); talci, zinci oxidi, āā ℥ss (16.). As a rule, however, it will be found that the conjoint use of a lotion and powder is preferable to the latter alone.

In some cases of the acute inflammatory type ointments are found more comforting, although in the early stages, as a rule, not so frequently so as lotions. They are more especially useful in the dry varieties, and when there is a tendency to desquamation and cracking. Even in most of these instances the preliminary application of a lotion, more particularly the boric acid lotion, seems to be an advantage. Zinc oxid ointment, already referred to, can be used alone, and is extremely valuable, often affording relief; if the parts feel tense and hot, an ointment made of this and an equal part of cold cream can take its place; instead of the zinc oxid constituent, bismuth subnitrate can be at times substituted to advantage. Cold cream itself is, indeed, a valuable salve in these cases, and especially when used conjointly with a lotion. In fact, cooling salves—those containing water—are usually most soothing. For this reason an ointment (Unna) composed of lanolin, 1 part, lard, 2 parts, and rose-water, 3 parts, can often be used as a soothing refrigerant application; or in place of the rose-water lead-water or lime-water can be substituted (Duhring) with advantage, especially in markedly acute types, the latter ingredients adding to its soothing properties. Diachylon ointment, if well and freshly prepared, is also soothing and mildly astringent, but it is difficult to get a good preparation; in the latter event, or if not fresh, irritation often follows its application. Plain petrolatum suits some cases, but disagrees with others, and, as a rule, is not to be used alone in the acute type but as a base or part constituent of a base for incorporation of powdery ingredients it is often permissible and satisfactory. The following I have often used in these cases with benefit:

℞.	Calaminæ,	
	Zinci oxidi,	āā gr. xl (2.65);
	Amyli,	ʒj (4.);
	Ac. salicylici,	gr. iij–x (0.2–0.65);
	Petrolati,	q. s. ad ℥j (32.).

One composed of calamin, ʒj (4.), and ungt. zinci oxidi, ʒvij (28.), is also often valuable. In pustular eczema of the acute type lotions and ointments conjointly used afford the most satisfactory results, and a minute quantity of white precipitate, 1 to 3 grains (0.065–0.2) to the ounce (32.) of ointment, will add to the favorable effects in some instances. Boric acid ointment is also useful in such cases.

Very often, when salves, such as described, will not agree, the so-called pastes (Lassar, Unna, Gründler)[1] can be employed. In

[1] Lassar, "Ueber Salicylpasten," *Monatshefte*, vol. ii., 1883, p. 97; Unna, "Die Pastenbehandlung der entzündlichen Hautkrankheiten, insbesondere des Ekzems," *ibid.*, vol. iii., 1884, p. 38; Gründler, "Ueber Pasten," *ibid.*, vol. vii., 1888, p. 1029; G. W. Wende, "Ointments and Pastes," *Amer. Med. Quarterly*, June, 1899 (an excellent exposition of the subject).

fact, these latter are often the more acceptable, and act satisfactorily. They possess a certain porosity, and while they are protective, they do not entirely block up exudation. The salve mentioned above, containing zinc oxid, calamin, and starch, is somewhat of this nature. The type of this class, is, however, the following (Lassar's paste):

℞.	Zinci oxidi,	
	Amyli,	āā ʒij (8.);
	Petrolati,	ʒiv (16.).

In this is commonly incorporated 3 to 10 grains (0.2–0.65) of salicylic acid. The latter amount is usually added, and when so constituted the paste is generally known as the "salicylic acid paste," "salicylated paste." In fact, when "Lassar's paste" is referred to, this salicylated paste is usually meant. It is a most admirable preparation, not only in the less actively acute types, but in the subacute cases. Another paste which is also satisfactory is one similar to that given: ℞. Zinci oxidi, amyli, ac. borici, āā gr. lxxx (5.33); ac. salicylici, gr. iij–x (0.2–0.65); petrolati, ʒiv (16.). To these, and in fact to the salves already mentioned, in extremely itchy cases, can be added to the ounce (32.) 1 to 3 grains (0.065–0.2) of carbolic acid; a stronger proportion—up to 10 grains (0.65)—is sometimes permissible, especially in the less actively acute cases.

In eczema of a **subacute or moderately inflammatory type**, whether beginning as such or evolving from the acutely inflammatory cases, and in which there is *distinct infiltration* or *epidermic thickening*, it is advisable to begin the treatment with one of the several applications suggested for the acute type. Too much stress cannot be laid upon this point, for often the quickest and most satisfactory results are thus attained. Cautiously, if necessary, as it frequently will be, the various active ingredients named in some of the lotions and ointments—as, for instance, carbolic acid, salicylic acid, etc.—can be added in greater proportion. A lotion containing ½ to 2 ounces (16.–64.) of liquor carbonis detergens to the pint (500.) of water is extremely valuable in many cases, and can be used plain as such, or this tar product can be added to any of the several lotions already named. This is one of the most valuable tar preparations in these cases, and least likely to disagree, but, as with all tarry applications, it should be used cautiously at first, as some skins are intolerant to this drug. The carbolized boric acid lotion referred to may also be prescribed with from 2 to 5 grains (0.13–0.32) of tannic acid to the ounce (32.). Resorcin is also valuable in this type, employed as a lotion of from 3 to 20 grains (0.2–1.33) to the ounce (32.), or as an ointment of from 10 to 40 grains (0.65–2.65) to the ounce (32.). Ichthyol in from a 2 to a 5 per cent. lotion is sometimes valuable. The following is also useful:

℞.	Zinci oxidi,	ʒij (8.);
	Liquor. plumbi subacetatis diluti,	fʒvj (24.);
	Glycerini,	fʒij (8.);
	Infus. picis liquidæ,	q. s. ad f℥iv (128.).

In limited areas, especially of a slightly moist type, painting on a saturated solution of picric acid (Maclennan, Thiéry, Leredde, Radaeli) two or three times daily for three or four days, and then applying emollients, waiting until the film thus formed comes off, is sometimes of service. In these cases, as well as in those of a chronic type, an occasional painting (every five to ten days) with a 1 to 10 per cent. aqueous solution of silver nitrate, or with a 1 to 3 per cent. solution in sweet spirits of niter, proves valuable, more especially in the slightly moist cases.[1]

In this type the results are usually better when a lotion, if employed, is followed by a salve; and an occasional stirring up of the surface with a strong lotion, followed by one of the soothing ointments, sometimes constitutes a good plan. As a general rule, however, soothing remedies are here, as in the acute type, to have first place. Some cases seem to do better on ointments alone. White precipitate can be added to the several already named, in the proportion of 5 to 30 grains (0.33–2.) to the ounce (32.). Calomel, in the same proportion, acts well in many instances, and is the one I most frequently have first recourse to when stronger applications are found necessary:

℞. Hydrargyri ammoniati seu hydrargyri chloridi mitis,	gr. v–xxx (0.33–2.);
Acidi carbolici,	gr. v–x (0.33–0.65);
Ungt. zinci oxidi,	℥j (32.).

If this last ointment is to be rubbed in, as in erythematous and squamous areas, the zinc oxid ointment can sometimes be replaced with advantage by petrolatum, lard, or cold cream. Another formula (Klotz[2]) that is useful, especially as a preparatory measure, in subacute thickened eczema of the hands and extremities, for constant application in the form of a plaster, consists of:

℞. Acidi salicylici,	gr. x–xx (0.65–1.33);
Emplastri plumbi,	ʒiiss (0.10);
Emplastri saponis,	ʒiiss (0.10);
Petrolati,	ʒiij (12.). M.

The same can be said of a 5 per cent. salicylated soap-plaster (Pick).[3] An ointment of alumnol or of aristol, from ½ to 1 dram (2.–4.) to the ounce (32.), and an ointment of acetanilid, from 5 grains to 1 dram (0.33–4.) to the ounce (32.), prove beneficial in some instances. The tarry ointments may be used in these cases, but they should be weak and employed at first cautiously, as they may disagree. The following is mild, and can be often prescribed with great advantage. The first one is the milder and safer for beginning a change in the treatment, and one that can be recommended:

[1] See interesting paper by Dunn, "Nitrate of Silver in Dermatology," *Pennsylvania Med. Jour.*, Jan., 1901.

[2] Klotz, *New York Med. Jour.*, Sept. 17, 1887.

[3] Pick, *Verhandlungen der Deutschen dermat. Gesellschaft*, I. Congress, Vienna, 1889.

℞. Liquor. carbonis deterg., ʒj–ij (4.–8.);
Ungt. zinci oxidi, q. s. ad ℥j (32.). M.

Or

℞. Ungt. picis liquidæ, ʒj–ij (4.–8.);
Ungt. zinci oxidi, q. s. ad ℥j (32.). M.

If the larger quantity of the liquor carbonis detergens is prescribed in the former, the zinc oxid ointment should be partly replaced (about ʒj–ij (4.–8.)) with powdered starch, simple cerate, or lanolin, otherwise the resulting ointment would be too soft. The salicylic acid paste makes a good base for it.

These cases may at times be satisfactorily treated with some of the fixed dressings, especially the salve-mulls and gelatin applications, the medication varying somewhat, usually being zinc oxid, ichthyol, boric acid, small quantities of tar, or resorcin. The salve-mulls [1] (Unna) are especially valuable in irritable cases,—the zinc oxid and the boric acid salve-mulls,—and can be used with safety, both in this type and the acute type cases. They are kept constantly applied, changing once in the twelve or twenty-four hours, according to circumstances. My experience has chiefly been with the two named, although they are made with various other medicaments incorporated.

The gelatin applications (Pick, Unna, Morrow, and others) [2] are most admirable, and constitute a valuable method of treating many cases of the disease, more particularly when upon the lower extremities. They are especially useful in cases of this type of inflammatory action, but they can also be used in some of those of the more acute variety, and are likewise of distinct service in the sluggish cases. There are various formulas given, but the most generally useful are the following—hard preparation: Gelatin, 4 parts; glycerin, 1 part; water, 8 parts (Morrow); soft preparation—and that which I have used most frequently: gelatin, 2 parts; zinc oxid, 1 part; glycerin, 3 parts; water, 4 to 6 parts, and to this preparation is added 2 per cent. of ichthyol, 1 per cent. of carbolic acid, or salicylic acid. That containing zinc oxid and ichthyol is most serviceable; these same ingredients can also be added to the first formula. When needed for use, it is melted over a water-bath (a double farina or oatmeal boiler answers the purpose), and applied with a broad brush of from one to three inches wide. If desired, if the harder preparation is used, it can be allowed to dry on, and then simply dusted over with an indifferent powder. I prefer using the softer gelatin preparation, and then before the gelatin is dry to apply a thin gauze bandage; this adds to the completeness and effectiveness of the dressing. This can

[1] The salve-mulls and also the plaster-mulls to be referred to are made by Beiersdorf, Germany, and imported, through Lehn and Fink, New York. They are somewhat expensive, but have not yet been successfully imitated in this country.

[2] M. Pick, "Die therapeutischen Verwendung arzneihaltiger Gelatine bei Hautkrankheiten," *Monatshefte*, vol. ii., 1883, p. 33; and *Prager med. Wochenschr.*, 1883, No. 6; Unna und Beiersdorf, "Leimglycerin als Konstituens in der Dermatotherapie—Gelatinæ glycerinatæ medicatæ," *Monatshefte*, vol. ii., 1883, p. 37; and *Jour. Cutan. Dis.*, vol. ii., 1884, p. 54 (this paper contains tables of formulas for various drugs with gelatin, glycerin, and water, both for soft and hard preparations); Morrow, "An Improved Method in the Treatment of Certain Forms of Skin Affections," *Med. Record*, Mch. 1, 1884; Eddowes, *Medical Times and Hospital Gazette*, Sept., 1899.

ordinarily be left on three to five days; when its removal is desired, it is softened thoroughly with warm or hot water, after which it readily comes off; a fresh dressing then is applied.

Linimentum exsiccans (Pick[1]), of which tragacanth is the basis, is another dressing which dries on, but it is not comparable to the gelatin application, although it can often be more conveniently used on some situations than the latter. The following is the formula: ℞. Tragacanth, 5 parts; glycerin, 2 parts; boiling water, to make 100 parts; to this is usually added, to preserve it, 2 per cent. of boric acid. It can be variously medicated, that with 5 to 10 per cent. of zinc oxid, and 0.5 to 1 per cent. of carbolic acid, is most commonly used. This dries slowly, and I believe is not so good as one with acacia as the base: ℞. Zinci oxid., 2 parts; glycerin, 1 part; and mucilage of acacia, 5 to 8 parts; the various drugs can also be added to this. Somewhat similar to that of Pick's, but superior, is one made with bassorin (Elliot)[2]: Bassorin, 48 parts; dextrin, 25 parts; glycerin, 10 parts; and water to make 100 parts; it should be prepared cold. Zinc oxid, ichthyol, and other medicaments can be incorporated. These several drying paints are, as a rule, not practicable in hot weather, as the increased perspiration makes them sticky. After the application dries on a powder can be dusted over.

In the management of eczema of **chronic (sluggish) inflammatory type**, in which there are *moderate or pronounced infiltration and epidermic thickening*, the various applications already indicated in the treatment of the acute and subacute types, especially of the latter, can be tried first. In many of these cases, however, these will only bring about slight betterment, and stronger methods must be resorted to. An occasional, or frequent, according to circumstances, vigorous shampooing with sapo viridis, conjointly with the above lines of treatment, will often bring about a favorable result. After the soap-washing the parts should, of course, always be rinsed off with clean water and tapped dry before the remedial applications are made. Stronger remedies are, however, often called for; they are essentially the same as indicated in the above types, but in increased strength. The various lotions, especially of resorcin, can be employed, with several times as much of this ingredient contained therein—5 to 20 grains (0.33–1.33) to the ounce (32.); and it can be followed by a strong salve. The calomel and white precipitate ointments, already suggested, are often of service, containing 40 to 80 grains (2.65–5.33) of the mercurial to the ounce (32.); such ointments should be well rubbed in, but are not applicable to large surfaces for fear of absorption; for the latter reason their application as a spread ointment, except to a small area, is not advisable.

Tarry preparations are most frequently of use in these cases, disagreeing occasionally; they are most satisfactory in the dry sluggish

[1] F. J. Pick, "Ueber die Anwendung eintrocknender Linimente (Linimenta exsiccantia) bei der Behandlung von der Hautkrankheiten," *Archiv*, 1891. p. 633.

[2] Elliot, "Bassorin Paste: A New Base for Dermatological Preparations," *Jour. Cutan. Dis.*, 1891, p. 48; "Bassorin Paste in the Treatment of Skin Diseases," *ibid.*, 1892, p. 184.

types. The mildest of all is the liquor carbonis detergens, already referred to; as a lotion it can usually be employed strong, even up to the pure solution, followed by a salve containing it, as before given, or with the calomel or white precipitate ointment. As a rule, however, the stronger vegetable tars are usually necessary, such as the oil of cade or the official tar ointment. The former can be used with 1 or 3 parts of almond or olive oil, or in ointment with simple cerate, 2 to 3 drams (8.–12.) to the ounce (32.). Sometimes a satisfactory method is to prescribe it with alcohol, 1 to 2 parts, paint over the surface, allow to dry, and then put on a spread salve application of one of the mild salves—the salicylated paste is an eligible one. The official tar ointment should at first be used with 1 to 2 parts lard, and increased in strength if necessary. In favorable cases the infiltration rapidly disappears under the use of these several tar preparations. In limited dry areas, if not too much thickened, the tar, as the oil of cade, can be incorporated with collodion, 1 dram (4.) to the ounce (32.), and painted on two or three times daily for several days, and then under a mild salve dressing allow the film to come up; the painting can then be renewed. If the odor of tar is a serious objection, a strong ointment of resorcin or β-naphthol, or salicylic acid, 30 to 60 or more grains to the ounce, can be employed at times with great advantage, but, like all other remedies, they at times disagree. Painting on iodin tincture, at first weakened with 1 part alcohol, once every few days, is, conjointly with salves, sometimes of service. The gelatin dressing treatment should not be forgotten in these cases, as it is often a valuable method; it can sometimes advantageously be preceded by a shampooing with sapo viridis and hot water, and sometimes by a preliminary painting with pure or weakened liquor carbonis detergens.

Occasionally an ointment of sulphur, 20 to 60 grains (1.35–4.) to the ounce (32.), preferably of the salicylated paste, acts beneficially. A compound ointment sometimes useful in these thickened sluggish cases is the following: ℞. Sulphur. præcip., ʒss–ij (2.–8.); ungt. picis liquidæ, ʒij–iv (8.–16.); petrolati, q. s. ad ℥j (32.). Sulphur must, however, be used with caution, as it frequently disagrees.

Sulphur, in the more sluggish, obstinate cases, is sometimes used in the form of sulphur baths, and these, one every two or three days, can, in some instances, be tried, at least as an adjuvant measure. The bath is made by adding 1 to 4 ounces (32.–128.) of potassium sulphid to the ordinary bath-tub about half full (about 30 gallons), the water being sufficiently warm for the patient to remain in five to fifteen minutes without being chilled. Tar baths are also occasionally resorted to, the affected parts being first scantily or freely painted or rubbed with pix liquida or oil of cade, and the patient then getting in a warm plain bath. Neither of these methods has found use in my practice in late years, as favorable effects were so infrequent and irritation or aggravation not unusual. In some cases, however, a course of baths at the sulphur spring resorts, with the advantages of change of scene, release from care, supervised diet, and out-door life, is serviceable.

Other remedies to which recourse must sometimes be had, when other plans have failed, are ointments of chrysarobin and pyrogallol,

20 to 50 grains (1.33–3.33) to the ounce (32.), but these also must be cautiously employed. In obstinate cases it is sometimes advisable to excite inflammatory action, and then follow with soothing applications. When there is pronounced infiltration of limited extent, which is slow in undergoing absorption, the cautious application, every few days, of the negative electrode of the galvanic battery, using 5 to 20 milliampères, will occasionally give the impetus toward recovery. The static spark is also at times of service in such cases. In some instances the application of a high frequency current by means of the vacuum electrodes, for several minutes or longer, and repeated every few days, has been beneficial and occasionally curative. The same may be said of the action of the Röntgen rays; with cautious exposure of three to ten minutes, with a soft to medium tube, at varying distances of from 3 to 10 inches, repeated at intervals of several days.

In the treatment of the **thickly indurated or sclerosed and verrucous patches** strong applications are, as a rule, necessary to bring about their removal, or such modification that cure is then possible by the various plans already named. For reducing these patches there are several preparations which are of service—chiefly sapo viridis, caustic potash, and salicylic acid. If at all extensive, a compound of equal parts of sapo viridis, tar, and alcohol can be used, rubbing it in twice daily, and allowed to dry on. This can be continued for several days or longer if no reactive irritation sets in, and then the parts soaked in hot water, with 1 or 2 drams (4.–8.) of borax to the quart (1000.), and subsequently thoroughly washed with sapo viridis, rinsed, and dried. The treatment can be resumed and continued in the same way until the infiltration is thinned down and the induration removed, or until irritation is produced, when milder applications can be made. A cleaner method, and more rapid, but requiring greater caution, is the use of a solution of caustic potash, ½ to 2 drams (2.–8.) to the ounce (32.) of water. This is applied carefully, permitted to act a few minutes, washed off, or its further action prevented by application of vinegar or dilute acetic acid, and a mild spread salve put on; this is to be repeated, if necessary, from time to time. A method safer in the hands of those less experienced is the application of a 20 to 25 per cent. salicylic acid rubber plaster, kept constantly applied from one to several days, renewing when it loosens. The upper surface of the hardened tissue will be found softened, and after soaking in hot water, can be rubbed or scraped off, to be followed by renewal of the treatment until the desired end is accomplished. A 4 to 10 per cent. paint of salicylic acid in collodion, painted on twice daily for several days, and then permitted to loosen, and the part soaked and rubbed or scraped as above, and repeated, will finally accomplish the same purpose, but usually more slowly. The imported salicylic acid plastermull (Unna) is also valuable for this purpose. Papoid and boric acid, in equal parts, with enough glycerin and water to make a paste, and spread on overnight, will sometimes have a softening influence on hardened patches. As in other types, treatment by Röntgen rays can be cautiously tried in particularly obstinate cases.

A preparation sometimes useful in these cases as well as in some instances of the chronic sluggish type, is that known as "liquor picis

alkalinus" (Bulkley). It is to be used cautiously, either as a strong solution with 5 or more parts of water, or as an ointment, 1 to 2 drams (4.–8.) to the ounce (32.). As a weaker lotion, ½ to 2 drams (2.–8.) to the pint (500.), it can also be employed in the subacute varieties, often controlling the itching satisfactorily.[1]

REGIONAL AND INFANTILE ECZEMA.

Regional and infantile eczemas are here considered mainly from the standpoint of treatment. They differ in no material respects from the disease, and its types as already described; if there is any modification, it will be referred to. Infantile eczema is usually of the acute and subacute grades, for which the treatment is the same as that for eczema of adults of the same types; mild remedies are, as a rule, however, to be employed, and if the more stimulating applications

FIG. 57.—Eczema of erythematosquamous and squamous variety, with considerable infiltration; of long duration.

are seemingly required to reach a result, they must be used with greater caution. Overfeeding is occasionally a factor, though not so frequently as improper and deficient supply. Bohn[2] places a great deal of stress, and rightly, I believe, upon obesity (Fettsucht) as a factor in infantile eczema in the first and second years, due to the

[1] Liquor picis alkalinus is made of 1 part caustic potash, 2 parts pix liquida, and 5 parts water; the potash is dissolved in the water and gradually added to the tar with rubbing in a mortar.

[2] Bohn, "Eczema," p. 133, in Gerhardt's *Handbuch der Kinderkrankheiten* (Nachtrag), Tübingen, 1883.

character and the often unnecessary quantity of the nourishment given. The influence of digestion as an important etiologic factor in infants,[1] as well as in adults, must be borne in mind, and proper feeding is, therefore, imperative.

In the following remarks on the regional forms but little will be said as to diagnosis, etc., as such matters have already been fully considered, and to which the reader is referred for further information on these points. The generally accepted plan of discussing the external therapeutics of regional eczemas is, indeed, in great measure at least, scarcely necessary if the principles of treatment are kept in mind; for the selection of the remedial applications or plans of treatment is to be based, irrespective of locality involved, almost wholly upon the character and grade of the inflammatory process, remembering that those of the acute type and many of the subacute type require soothing and protective applications, while those of a sluggish infiltrated type usually require stimulating applications. To a slight extent, it is true, region does sometimes influence the first choice of remedy and the method of application, and for such reason a brief consideration of the various regional eczemas can probably be profitably added to the directions already given. Reference will also be made, when deemed necessary, to those remedies most frequently employed in children.

Eczema of the Scalp (Eczema Capitis).—The disease in this region is to be differentiated from seborrhea, psoriasis, pediculosus, favus, and ringworm, chiefly the first two. In the adult the most common variety in this region is the erythematosquamous and squamous, and the inflammation, usually of the subacute and chronic grade. It frequently extends over the forehead and mastoid regions, in the latter often to the back of the ears, presenting, especially in the fold, the moist variety. In its management it is not necessary to sacrifice the hair. If the scale accumulation is considerable, the free use of olive or almond oil or liquid petrolatum, with 1 to 3 grains (0.065–0.2) of resorcin or carbolic acid to the ounce (32.), is, for the first few days, advisable, followed by washing with a mild soap and water. This will generally remove the accumulations, and often a continuance of this plan, especially with a resorcin-containing oil, increasing this ingredient to 5 to 10 grains (0.33–0.65) to the ounce (32.), will lead to marked improvement. After the scales have been removed, washing is repeated only as demanded by cleanliness and scale reaccumulation—on the average, about once every one or two weeks. In irritable cases this can be dispensed with entirely and the parts cleansed by gentle rubbing with the oil. A 2 to 4 per cent. ointment of salicylic acid, with 5 to 20 grains (0.33–1.35) of resorcin to the ounce (32.), is often extremely useful in these cases. In irritable cases in which there is but slight tendency to scale-formation, the application of a boric acid solution followed by a plain salve, such as cold cream or petrolatum, can be used satisfactorily for a time. Later, slightly

[1] Schwartz, "Dermatoses liées aux troubles gastro-intestinaux chez les enfants," *Thèse de Paris*, 1892; A. J. Hall, "An inquiry into the Ætiology of Infantile Eczema." *Brit. Jour. Derm.*, 1905, pp. 161, 203, 241, and 287, gives a full review and discussion of the subject with résumé of the opinions of other writers with conclusions unfavorable to the digestive disturbance theory.

or moderately stimulating ointment applications are demanded, and among these the best are those of liquor carbonis detergens, white precipitate, and calomel, at first weak, later stronger. In thickened, infiltrated, obstinate cases oil of cade, with 1 to 3 parts of olive oil or in ointment, is valuable; but in private practice it is quite frequently found objectionable on account of the penetrating tar odor. β-naphthol ointment, 1 to 3 per cent. strength, can be used as a substitute, and sometimes satisfactorily, but it at times proves irritating. In the stubborn, infiltrated disease sometimes observed on the lower occipital region verging on to the neck, the tar and calomel preparations are satisfactory, but must often be used quite strong.

In infants and children the vesicular and vesicopustular eruptions are not uncommon, and are also occasionally met with in the adult; there is sometimes a good deal of crusting. If present, this is to be removed, in the manner already described above, or if abundant and adherent, as described in the preliminary general remarks concerning external treatment. Salicylic acid ointments are useful in such cases, and also white precipitate and alumnol ointments—of the first, 3 to 10 or more grains (0.2–0.65) and of the latter, 15 to 30 (1.–2.) grains to the ounce (32.). When possible and feasible, the application of the mild boric acid wash can advantageously be used with it. In infants of little hair or when it is short, the zinc oxid ointment and salicylated paste can be employed, but, as a rule, both in children and adults, the powder-containing salves are not practicable for the scalp or other hairy regions. In children and female adults with a pustular eczematous condition of the scalp, especially posteriorly, the possibility of the presence of pediculi being the exciting factor should be borne in mind. Even if these parasites are secondary to the eczema, a cure is not possible unless they are removed.

In irritable types, both in the infants and adults, the temporary use of the mixture of equal parts of almond oil and lime-water with 1 or 2 grains of carbolic acid or resorcin to the ounce (0.065–0.135 to 32.) can be employed temporarily. On the other hand, in extremely obstinate and sluggish cases, a small quantity of precipitated sulphur, 10 to 40 grains to the ounce (0.65–2.65 to 32.), can be added to the tar ointment or other selected ointment.

The best ointment base for the scalp is one of equal parts of petrolatum and cold cream or petrolatum and lard, sometimes with the addition of 10 to 20 per cent. of lanolin; in sluggish cases, and sometimes in other cases, petrolatum can be used alone.

Eczema of the Face (Eczema Faciei).—The disease in adults is to be distinguished from seborrhea, eczema seborrhoicum, dermatitis, acne rosacea, and lupus erythematosus. The most common types are the erythematous and erythematosquamous, but occasionally the papular and, rarely, the pustular, and eczema rubrum, are also met with. An erythematosquamous eczema of the forehead is sometimes observed, in some instances of which the hat-band is the exciting factor. Occasionally the erythematous variety limits itself to the lids and immediate surrounding parts (**eczema palpebrarum**), or more frequently it remains here more obstinately after disappearing from other parts of the face.

The various lines of treatment mentioned under the several inflammatory grade headings are appropriately indicated here. The lotions are especially useful, particularly the boric acid, calamin-and-zinc-oxid lotions, and lotio nigra, the first or third conjointly with a salve, such as cold cream, zinc oxid ointment, calamin-zinc-oxid ointment, and the salicylated paste. For use on these parts white ointments can be given a skin tinge by adding to the ounce several grains or more of calamin, or a sufficient quantity of Armenian bole and umber (Brooke).[1] Ointments can often be employed alone, but the conjoint use of especially boric acid wash is often of added advantage.

FIG. 58.—Eczema of erythematous and squamous variety in the negro.

Cold cream is not only soothing in itself in many of these cases, but it is also a satisfactory base for other remedies. In the acute types the calamin-zinc-oxid lotion is most efficient when applied by means of linen cloths, and kept constantly wet with it; and in very irritable cases, instead of water, the basis of the lotion can be made up of equal parts of lime-water and almond oil. Weak ichthyol lotions, 1 to 10 per cent., are also useful. The liquor carbonis detergens, both as wash and ointment, in the various strengths indicated, is often useful in the erythematous variety, and in the infiltrated cases the stronger tarry ointments may be required, but here, as elsewhere, they should be applied tentatively at first. The bas-

[1] Brooke, "Mittheilung über eine Methode des Färbens von Salben," *Monatshefte*, vol. xi., 1890, p. 62.

sorin, tragacanth, and acacia paints are also useful in some cases. If the patient is obliged to go out, the parts should be covered with a layer of grease to protect from the air and wind; if the application being used is disfiguring, at such times cold cream can be applied.

In infants and young children the vesicopapular, vesicopustular, and eczema rubrum types are most common. It is to be distinguished chiefly from impetigo contagiosa, miliaria, and less frequently dermatitis; it could scarcely be confounded with lupus vulgaris. The mild applications named should be always used in the beginning, and frequently accomplish much, and sometimes lead on to cure; the conjoint treatment with black wash and zinc ointment or boric acid lotion and zinc ointment is often an admirable plan. The salicylated paste, with 3 to 10 grains of carbolic acid to the ounce (0.2–0.65 to ℥j), often acts satisfactorily. In some of the cases, and even when the condition looks quite actively inflammatory, if considerably infiltrated, a tar-zinc-oxid ointment (tar ointment, ʒj (4.), zinc ointment, ʒvij (28.)) brings about improvement, and not infrequently quite rapidly; it should be tried on a small area at first. Later, if the benefit flags, a larger proportion of tar can be added.

An important point in the care of some cases of eczema in infants is the employment of mechanical restraint (White, Hall, Allen)[1] to prevent rubbing and scratching, as by these latter not only is the application rubbed off, but the disease made worse; tying the hands loosely to the lower part of the body or putting on loose mittens will serve to prevent. If these do not suffice, a pillow-case can be pulled over the head, the closed end having had a hole sufficiently large cut in it to permit the head going through; the open end is fastened around the lower part of the body with safety-pins, and while the arms and hands are somewhat free, the latter cannot be readily carried to the face. In markedly itchy cases, both in children and adults, if the remedies prescribed do not give some relief, or if so intense as to prevent sleep, carbolic acid, thymol, or resorcin should be added to the applications named, in the quantity already stated in the general directions for treatment. A short exposure to the Röntgen rays will sometimes relieve the itching temporarily; and in obstinate cases of eczema of these parts repeated exposures at intervals of several days may have a curative influence. It is not, however, a method to be advised in infants and children.

Eczema of the nares or nostrils (**eczema narium**) is sometimes seen in young children as a pustular crusted eruption, often in conjunction with a similar eruption about the corners of the mouth, simulating closely impetigo contagiosa, except that it is chronic and persistent. It is not infrequent also to see a slightly red, crusted condition of the edge of the eyelids. It is most frequently seen in badly nourished strumous subjects. The administration of cod-liver oil is often valuable in these cases. Locally the best applications for the nose and

[1] J. C. White, "Some of the Causes of Infantile Eczema, and the Importance of Mechanical Restraint in its Treatment," *Boston Med. and Surg. Jour.*, vol. cv., 1881, p. 365; H. J. Hall, "A Mechanical Treatment of the Eczema in Young Children," *ibid.*, 1895, vol. cxxxii., p. 59; C. W. Allen, "The Treatment of Eczema in Infants and Children," *New York Med. Jour.*, 1899, vol. lxix., p. 433.

PLATE IX.

Eczema rubrum; child eighteen months old; duration one year; considerable thickening, gummy oozing, and crusting.

corners of the mouth are boric acid ointment, weak ointments (1 to 4) per cent.) of calomel, and white precipitate. For the edges of the lids boric acid lotion, used freely and often, with boric acid ointment or a 1 to 2 per cent. yellow oxid of mercury ointment. The possibility of an eczematous condition of edges of the lids being due to the pediculus pubis is to be remembered, although such instances are rare. In adults eczema of the nasal outlets is treated similarly. In these cases, as also in those in children limited to the nares, a nasal catarrh is often etiologic.

Eczema of the Ears (Eczema Aurium).—In some cases the eczema is limited to the ears, often, more especially in children, to the posterior aspect and particularly in the crease, in which there is frequently a tendency to oozing and fissuring. In this latter region the boric acid lotion and the calamin-zinc-oxid ointment (calamin, ʒj (4.), zinc oxid ointment, ʒvij (28.)), and salicylated paste are usually most efficacious; as the part becomes dry and scaly a small portion of tar, preferably, at first, the liquor carbonis detergens, can be added to one of these ointments, about 5 to 10 per cent. strength. In eczema of the auditory canal the selected ointment should be free from any great proportion of pulverulent substances; one of salicylic acid, from 10 to 20 grains (0.65–1.33) to the ounce (32.), or a 1 to 2 per cent. ointment of white precipitate, calomel, or resorcin, answering the purpose best. It may be gently applied with a piece of linen or small piece of cotton. An occasional cleansing by gently wiping out the canal with almond oil, petrolatum, or cold cream, and from time to time syringing the part with a solution of boric acid containing ½ to 2 grains (0.033–0.133) of borax to the ounce (32.), will be demanded from time to time.

Eczema of the Lips (Eczema Labiorum).—It is not uncommon to see eczema limited to the lips and immediate adjacent parts. In these cases the possibility of the tooth-wash or powder being an etiologic factor (Neisser)[1] should be eliminated. This has been the exciting cause in several of my cases. Ehrmann[2] has found eczema of the lips usually in anemic individuals, the anemia promoting increased salivary secretion, which acts as an irritant. The disease type may be either the vesicopustular or erythematosquamous. It is frequently seen in conjunction with the eruption on other parts of the face; exceptionally it is confined to the upper lip and superjacent skin, and is attended with a good deal of persistent swelling and infiltration. In the latter region a nasal catarrh is sometimes the etiologic factor. A not infrequent feature of lip cases is the tendency to fissuring.

In the moist crusted type the treatment is essentially that described under eczema of the acute and subacute grades—boric acid and resorcin lotions, with boric acid ointment, calamin-zinc-oxid ointment, and weak white precipitate ointments. Later, when dry and the active inflammatory character is reduced, the treatment can, if necessary, be changed to that of the erythematosquamous variety. In this latter,

[1] Neisser, "Kippen-Ekzem und Mundwässer," *Therapeutische Monatshefte*, vol. xii., 1898, p. 79; Galewsky, *Münch. med. Wochen.*, 1906, p. 1360.

[2] Ehrmann, "Zur Aetiologie und Therapie des Mundwinkel- und Lippen-Ekzeme," *Wein. med. Blätter*, vol. xviii., 1895, p. 568.



FIGS. 59, 60, 61. Chronic squamous and fissured eczema of palms and fingers—of various degrees and characters or types.

FIGS. 62, 63, 64.—Chronic squamous and fissured eczema of palms and fingers—of various degrees, characters, or types ; withconsiderable thickening ; last is of seborrheic type.

however, it is well to begin as above, and then, if there is no positive improvement, cautiously go to the tarry applications. The various tragacanth, acacia, and gelatin paints are sometimes of value. Likewise the zinc-oxid and boric-acid salve-mulls. In these cases, too, if persistent, an occasional painting with a 2 to 5 per cent. silver nitrate solution sometimes bring a result, although temporarily disfiguring. Applying a paint of ol. cadini, ʒss–j (2.–4.); collodii, ℥j (32.) (Hardaway), is also an energetic measure that sometimes relieves. The same may be said of frequent painting with benzoin tincture, with 5 to 10 grains (0.33–0.65) of boric acid to the ounce (32.). In using these fixed applications the mouth should be gradually opened to its widest capacity, and the lips then painted; if painted while closed, the dressing soon breaks, and the condition is often aggravated. The Röntgen ray treatment is occasionally beneficial in lip eczema.

Eczema of the Bearded Region (Eczema Barbæ).—In other cases the eruption is more or less confined to the bearded region, and is usually of the papulopustular variety, of varying inflammatory grade. It is rarely limited to the hairy region, but usually extends on to the bordering cheeks, and is often seen also in association with the eruption elsewhere upon the face or body. Many of those cases in which it is said to be confined to the bearded parts are in reality, I believe, cases of sycosis vulgaris. There is, however, sometimes a close relationship. In these patients the beard should be kept closely cropped, and when the inflammation has measurably subsided, shaving is, as a rule, to be advised. The applications are to be, at first at least, of the mildest character, and preferably of lotions and ointments conjointly, and for the various plans advisable the reader is referred to the general directions concerning treatment already given.

Eczema of the Hands (Eczema Manuum).—The hands are extremely common sites for the disease; the types usually observed are the vesicular, the papulovesicular, and the scaly and fissured. Fissures in these cases are quite frequent. The diagnosis is rarely difficult, as almost all itchy eruptions of any chronicity limited to this region, or this and the neighboring forearms, are eczematous. The disease is to be distinguished chiefly from dermatitis venenata, pompholyx, and syphilis. In many of these cases the patient's occupation is the exciting factor, and very often not much can be done in a permanent way unless this is modified or suspended. In domestics who are obliged to have their hands in water a great deal, loose rubber gloves should be worn at such times. In all cases the hands should be protected from cold and wind by the use of gloves.

In the moist types the conjoint use of black wash and zinc oxid ointment is often serviceable; so is the use of a boric acid wash or a resorcin wash, with the supplementary use of an ointment. The wash should be dabbed on thoroughly, allowed to dry in, and then a small quantity of the salve smeared over, or preferably applied spread upon linen or lint. Used in this manner a well-made diachylon ointment is often extremely valuable. The various mild ointments, without the wash, are also beneficial at times. In the moist types, salicylated paste is often an admirable application in this region.

So also is the compound stiff ointment plaster, consisting of equal parts of lead-plaster, soap-plaster, and petrolatum, with 10 grains (0.65) of salicylic acid to the ounce (32.), spread upon linen or lint and closely adapted to the parts; with, if there is much thickening, a larger quantity of salicylic acid—up to 1 dram (4.). In cold weather it is necessary to increase the proportion of petrolatum. While the hands should ordinarily be washed as infrequently as possible, owing to the damaging effects of soap and water, in thickened and infiltrated cases a thorough washing with sapo viridis and hot water nightly or every second or third night, according to circumstances, followed immediately by a mild salve application spread as a plaster, is often of great therapeutic value.

For the dry, thickened types, especially observed on the palmar aspects (**eczema palmarum**), one of the best remedies is salicylic acid, applied as an ointment with petrolatum and benzoated lard as a base, 20 to 80 grains (1.33–5.33) to the ounce (32.); it should be well worked in, and then applied as a spread plaster. Occasionally an addition of 10 to 20 per cent. of lanolin to the base proves of advantage. Calomel and white precipitate ointments, usually strong, are likewise useful. Tarry preparations, in ointment form, are sometimes of distinct service, but their action is doubtful in a given case, and they must be experimentally tried on a small surface at first. When there is marked epidermic thickening, applications of the 10 to 25 per cent. salicylic acid rubber plaster or plaster-mulls is applicable, and, as a rule, soon thin down the parts. The same can sometimes be accomplished by painting on salicylated collodion, 4 to 10 per cent. strength; after thorough washing, two or three coats are painted on for two or three days, twice daily, and then allowed to loosen; it is then repeated, if necessary, continuously or from time to time. For the thickened palmar types Röntgen ray exposures occasionally act admirably.

In chapping, the mildest example of fissured eczema, or at least a condition allied thereto, a weak glycerin lotion or a mild ointment may be rubbed in nightly; the hands should be kept out of water as much as possible, and when washed, rubbed thoroughly dry. A good formula for these cases is: ℞. Tinct. benzoin., ʒss (2.); glycerin, ʒiiss (10.); aquæ dest., ʒv (20.); mix and filter.

In **eczema of the nails** (**eczema unguium**) the nail involvement or changes are usually due to eczema of the periungeal region. The involved nails should be closely filed or cut. The ordinary remedies in the form of ointments can be applied, boric acid, salicylic acid, resorcin, and ichthyol being the best. In obstinate cases painting every few days with a 3 to 10 per cent. aqueous solution of silver nitrate or a saturated solution in sweet spirits of niter is often successful; between the paintings one of the above ointments can be kept applied.

Eczema of the feet (**eczema pedum**) demands no special directions; that on the soles (**eczema plantarum**), in which there is usually marked epidermic thickening, the treatment already outlined for the palms is appropriate; when between the toes, in addition to the milder appli-

cations, the occasional (every 7 to 10 days) painting with a saturated solution of silver nitrate in spiritus ætheris nitrosi, or as a 5 to 10 per cent. aqueous solution, is often especially valuable.

Eczema of the Flexures (Eczema Articulorum; Eczema Intertrigo).—Eczema of these parts is usually either erythematous or vesiculo-papular, sometimes with a resulting maceration of the surfaces, simulating erythema intertrigo, and in others developing into eczema rubrum. A tendency to fissuring is not uncommon. As a rule, the conjoint use of lotions and ointments yields the most rapid results. The boric acid lotion and the zinc oxid ointment, or the salicylic acid paste, should be used at first. The calamin-zinc-oxid lotion often acts well for several days, but it is apt to be too drying unless intermitted and a salve employed for a day or two. It can generally be continued longer if glycerin is added, 5 to 15 minims (0.33–1.) to the ounce (32.). The boric acid and the zinc oxid salve-mulls are extremely serviceable; also, for a time, if any infiltration, the salicylated soap-

FIG. 65.—Eczema of a squamous, thickened, sclerous type, of about a year's duration, in a woman aged fifty. Marked infiltration and callous formation about the heels, with deep, painful fissuring; between some of the toes the eruption was of a mild erythematous type, occasionally moist and oozing. In places there was a strong resemblance to callositas.

plaster. Eczema under the breasts in women is similarly treated. In this region, as well as in others, where parts come in contact, the wearing of flattened thin cheese-cloth bags filled with a dusting-powder is often of great service. Later, if no benefit ensues or as soon as the good effects of mild treatment begin to flag, an ointment containing varying quantities of white precipitate or calomel; or the

zinc oxid ointment, with 1 or 2 drams (4.–8.) of tar ointment to the ounce (32.); and in thickened, infiltrated cases tar ointment itself, weakened at first, often proves of marked advantage.

Eczema of the Breasts (Eczema Mammæ seu Mammarum) and of the Umbilicus (Eczema Umbilici).—Eczema of the nipple and immediate surrounding skin in women is most commonly observed during the nursing period, and may be of the dry or moist type, more frequently the latter. In some subjects the condition is scarcely eczematous, and presents merely fissuring of the nipples, the skin of the same being dry and inelastic. The disease in this region is to be distinguished from Paget's disease (*q. v.*). The mild plans of treatment will be found most serviceable, those designated in the general directions as suitable for the acutely inflammatory type of the disease; ordinarily a nipple-shield should be worn at the time of nursing. In some cases, especially when more or less confined to the nipples, with fissuring, painting the parts with benzoin tincture, compound benzoin tincture, or with collodion will tend to heal the fissures and improve the disease, and, at the same time, measurably afford protection during the act of nursing. In obstinate fissures touching gently with silver nitrate or with the saturated solution of silver nitrate in spiritus ætheris nitrosi can be tried, and often proves effective. In eczema of the umbilicus the same mild measures are usually successful, along with frequent washing with boric acid lotion. In persistent cases the above solution of silver nitrate can be used.

Eczema of the Genital Region (Eczema Genitalium).—The disease about these parts is usually of the erythematous variety, although the erythematopapular and erythematosquamous are not uncommon, and, in fact, any type may exist. It is to be distinguished from eczema marginatum (tinea cruris), pediculosis pubis, and pruritus. Itching is often severe, and a tendency to fissuring is not uncommon. Glycosuria is to be excluded as a factor, especially in women. In males the eruption is often confined to the scrotum, and more especially to those parts coming in contact with the thighs; it may, however, be quite extensive, involving shaft, glans, and neighboring parts of thighs and perineum. In women the labia are usually the seat of the malady, occasionally extending on to the mucous membrane; in some cases there is moist exudation.

The treatment differs in no way from that of the disease elsewhere, but, owing to the heat, friction, and moisture of the parts, the condition is usually extremely rebellious. Lotions of calamin-zinc-oxid, of resorcin, liquor carbonis detergens, boric acid, and ointments of calomel, calamin, the salicylic acid paste, zinc oxid and boric acid salve-mulls, and, later, ointments of tar, may be used. The scrotum should be supported by a suspensory bag as high as possible, so as to keep the surfaces from contact. Sometimes this latter is best accomplished by the use of flat cheese-cloth bags containing dusting-powder, by means of which the parts can be kept separated. In obstinate cases the ointments may be applied spread on lint or linen and kept in place by means of a bandage. In stubborn cases a medicated paint of tincture of benzoin, with a few grains of salicylic acid or 20 to 30 grains (1.33–2.) of boric acid, or ½ to 1 dram (2.–4.) of oil of

cade to the ounce (32.), may be cautiously tried. A frequently successful plan or adjuvant measure is the application, in scant quantity, of a 2 to 5 per cent. solution of silver nitrate in spiritus ætheris nitrosi; it causes variable smarting momentarily. It is repeated about once weekly, and mild salves used in the interval. In women similar measures are employed. In addition to saccharine urine being an occasional cause, irritating vaginal discharges are also sometimes etiologic. In both sexes an occasional cleansing with hot boric acid solution with ½ to 2 grains (0.033–0.133) of borax to the ounce (32.) is necessary; such application, if very hot, will also often allay the itching. Soap and water should be used but seldom.

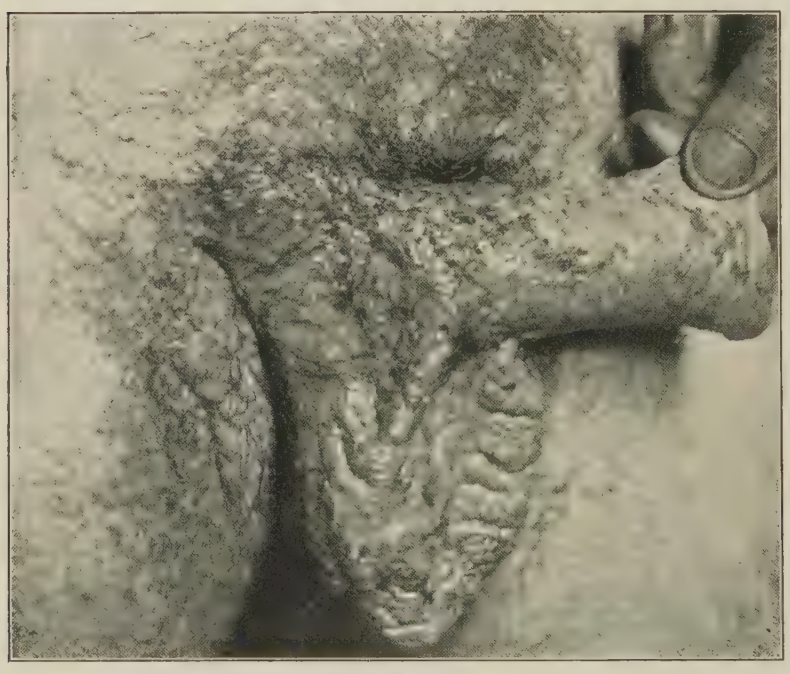

FIG. 66.—Eczema rubrum, of considerable duration, involving scrotum chiefly, together with part of the shaft of the penis and adjacent portion of the thighs; marked thickening and crusting (courtesy of Dr. M. B. Hartzell).

Ezcema of the Anal Region (Eczema Ani).—Eczema of the anus is, as a rule, a most intractable disease, and for evident reasons. It is to be distinguished from pruritus. Seat-worms, hemorrhoids, fissure, and fistula should be eliminated as causes. After each stool the part should be gently cleansed, and the remedial application made. The application should be repeated again at the end of eight or ten hours, without the preliminary washing. If moderately or markedly inflammatory, the various mild lotions and ointments, such as named for eczema of the genitals, should be at first employed; as a rule, however, these cases are sluggishly inflammatory and bear strong remedies. An ointment of liquor carbonis detergens, from 1 to 2 drams

(4.–8.) to the ounce (32.) of simple cerate or prepared suet, is especially useful in some of these cases. Resorcin lotion, followed by a mild ointment, forms also a good plan of treatment. Tar ointment, weakened or of full strength, or a 10 to 20 per cent. ointment of oil of cade, is also valuable in some instances. The oil of cade is often serviceable, too, when used with almond or olive oil. In the application of these preparations the excess can be wiped off, and a dusting-powder used to prevent soiling. In this region very frequently all the various applications will be tried before permanent relief is brought about. For the intense itching sometimes present in eczema of this region applications of water as hot as can be borne may be used, often with prompt relief, and the boric acid solution containing borax, as advised in eczema genitalium, can also often be used here with advantage. Carbolic acid lotions, thymol lotions, and the application of liquid petrolatum, containing from 5 to 20 grains (0.33–1.33) of menthol or from 2 to 5 grains (0.13–0.33) of cocain to the ounce (32.), will allay the itching in some cases, and also exhibit curative effects. The Röntgen-ray treatment is sometimes valuable.

Eczema of the Legs (Eczema Crurum; Eczema Crurale).—The legs are quite commonly the site for eczema in those of middle life and advancing years. The condition is more or less complicated by the fact that the circulation is less active in dependent parts; varicose veins are not infrequently associated, and in some instances may exist for months or years before the eczema (**eczema varicosum**) develops, having in many cases an undoubtedly causative influence. The type of disease most common in this region is eczema rubrum, and not infrequently the erythematosquamous and squamous; on the lower part, in the region of the ankle, often extending on to the foot, the thickened, scaly, sclerous, and verrucous forms are usually observed. There is occasionally noted also a mild, persistent, erythematous type, with but little, if any, tendency to scale-formation, in which here and there, few or in crowded number, minute hemorrhagic puncta are noted; sometimes this purpura-like feature is of more or less diffused character over the affected area or region.[1] The treatment of ordinary eczema rubrum of the leg differs very little from that of other parts. Mild applications should be used at first, such as a boric acid lotion, black wash, or a resorcin lotion, followed by salicylic acid paste, zinc oxid ointment, calamin ointment, or the stiff salicylated plaster-like ointment already referred to. The ointment should be spread upon lint or any suitable material, and applied as a plaster, being closely adapted to the parts. In some cases the free use of the calamin-zinc-oxid lotion will rapidly change the case into a dry type. Occasional washing is necessary, the best plan being to wipe off gently any ointment that may have collected, and to soak the part in a bucket of warm water made alkaline by the addition of from 1 to 4 drams (4.–16.) of borax or sodium bicarbonate; after withdrawing the part it is to be again gently wiped and tapped (not rubbed) dry and the remedial application again made. After the diseased area has lost its moist character the ointment may be made slightly stim-

[1] See interesting paper by Klotz, "Dermatitis Hæmostatica," *Jour. Cutan. Dis.*, 1891, p. 361; and by Schamberg, *Brit. Jour. Derm.*, 1901, p. 1.

ulating by the addition of from 10 to 30 grains (0.65–2.) of white precipitate or calomel to the ounce (32.); later, in addition to its application as a plaster, a small portion of the salve may be gently rubbed into the skin of the affected area; or this latter plan of rubbing in may of itself, in the dry types, be sufficient. Stronger remedies may be gradually used if the improvement flags, and a weak tarry ointment may be eventually employed in many of these cases with great advantage.

In eczema rubrum with much thickening, and when the irritability is not great, vigorous shampooing with hot water and sapo viridis may be practised every few days, even to the extent of producing a good deal of temporary disturbance; then rinsing and drying the part and immediately applying a mild salve spread as a plaster. This plan will occasionally act with surprisingly favorable effect upon the disease. In dry eczemas of the leg ointments containing varying proportions of salicylic acid, tar, calomel, and other stimulating remedies may be rubbed in twice daily; and in these the application of the salve as a plaster is not, as a rule, necessary. A most satisfactory plan of treatment in the majority of cases is that by the gelatin dressing, already described in the general section on the treatment of eczema in discussing the remedies applicable to the subacute variety; this finds its best application when the disease is dry, but it may also be used in the moist type so soon as its moist character has measurably been controlled. The parts should be freed from scales or crusts before applying.

The purely medical treatment of eczema of this part may, especially in those in whom a varicose condition of the veins seems predisposing or causative, be considerably aided by giving support to the leg by means of a properly applied roller-bandage or by a gum stocking. The gelatin dressing referred to does this, and this is one of its advantages. The rubber bandage will prove useful in a few cases, but if applied directly over the parts, it is likely to irritate, so that a thin layer of bandage should be placed next to the skin. In ordinary cases the support to the part need be given only during the day, when the patient is for most of the time in the upright position; during the night it is not necessary, except in markedly varicose conditions. As a rule, however, neither gum stocking nor rubber bandage is so satisfactory during the treatment as the roller bandage; and in my experience the rubber bandage is so often disappointing and even aggravating in its effects that it has been practically discarded. The cotton elastic bandage, however, can satisfactorily take its place.

In eczema of the leg complicated by an ulcer this latter is to be treated in the ordinary manner—"strapping" is, however, as a rule, not permissible; an excellent method in these cases is by the gelatin dressing, leaving an opening over the ulcer, and treating this by the usual applications.

The sclerous, verrucous types are to be treated as already referred to in the general directions.

Generalized or Universal Eczema (Eczema Universale).—This term is usually applied, as has been already stated, to eczema involving the whole or greater part of the surface; it is often more or less acute

in character. Universal eczema, strictly speaking, is, however, rare. The erythematous and mild scaly types are most common; eczema rubrum, more or less generalized, has also been observed; in fact, any type may exist, and in some instances there is only a preponderance of one type, the disease upon different parts presenting different aspects. In these cases the patient is most comfortable in bed, at least until the activity of the inflammation has abated. Lotions and dusting-powders used conjointly are most comforting in dry eczema, while in moist eczema lotions and ointments usually furnish the most relief. There is, however, no set rule for this. The remedies should not be strong. These cases generally do well at first, the disease frequently yielding rapidly, except upon one or more regions, where it is likely to persist for some time. The type (**eczema craquelé**) of more or less generalized eczema sometimes met with, in which there is practically but little, if any, infiltration of the skin, being erythematous and in places minutely vesiculopapular, and tending to crack superficially in irregular squares or blocks, has already been referred to in the description of the varieties. This variety requires the mildest kind of treatment, the salicylic acid paste, plain salicylated petrolatum, 5 grains (0.33) to the ounce (32.), and petrolatum or cold cream, containing 1 or 2 drams (4.–8.) of powdered starch to the ounce (32.), acting most satisfactorily.

Eczema of the Adjoining Mucous Surfaces.[1]—The mucous membrane is rarely, if ever, solely involved, but in conjunction with the neighboring cutaneous surface, as at the nasal orifices, the eyelids, the lips, about the glans penis, the vulvar orifice, and the anus. The membrane becomes inflamed and somewhat thickened, sometimes dryer than normal, and at other times showing a mucopurulent discharge. Crusting, usually insignificant, may at times form, and occasionally there is a slight disposition to crack. Exceptionally the disease is limited to the vermilion of the lips, and is persistent, but this, I believe, belongs to the domain of eczema seborrhoicum and will be again referred to under that head. The benign evanescent plaques sometimes observed on the tongue will be referred to elsewhere.

Its continuity from the disease of the cutaneous surface, from which it usually springs, would suggest a parasitic factor. At times, especially about the nose and mouth, it would almost seem as if it had its commencement on the mucous surface, certainly at least at the mucocutaneous junction. In the treatment of the disease on these parts measures vary somewhat as to locality. That of the nares has already been spoken of, as well as that at the edges of the eyelids. For the glans penis and the inner surface of the vulva as well as, in fact, on all other mucous surfaces, boric acid lotions and 1 to 5 per cent. tannic acid solutions are valuable; and in persistent cases the silver nitrate solutions already referred to several times are to be kept in mind.

[1] Vidal, *Gazette des hôpitaux*, 1880, p. 68; Besnier, *Jour. de med. et de chirurg.*, Dec., 1889; von Sehlen, *Monatshefte*, 1894, xix., p. 15; Hartzell, *Medical News*, 1895, i., p. 460 (with literature references).

ECZEMA SEBORRHOICUM.

Synonyms.—Dermatitis seborrhoica (Crocker, Elliot); Seborrhœa corporis (Duhring; some cases); Pityriasis capitis; Seborrhœa sicca (some cases).

Definition.—A dermatic inflammation of slight or moderate grade, beginning usually primarily upon the scalp, characterized by greasy scaliness, and, especially outside of the scalp region, not infrequently presenting a tendency to segmental or irregular shapes.

This definition of this disease, compared to the more comprehensive one inferentially given by Unna,[1] and which was later accepted by some others, notably Elliot[2] in this country, is a narrow one, and is intended to cover cases which may well be considered to present the combined symptomatology of a mild eczematous inflammation and seborrhea. Along with the majority of my colleagues I believe that most of the papular and moist types which Unna especially would also include are more properly to be placed under eczema. Indeed, I am inclined to share, in part at least, Duhring's opinion[3] that "it often exists as a variable combination of these two diseases, partaking in some cases more of the nature of seborrhea than eczema, as shown by the glandular involvement, the regions affected, and the well-established observation that it often yields readily to the sulphur preparations, so useful in affections of the sebaceous glands." I am far from denying, however, that there exists such disease process; on the contrary, these investigations of both Unna and Elliot, as well as others, leave no doubt on this point, and the clinical picture is frequently enough encountered.

How many of these cases are to be still considered, however, under seborrhea is a problem of some difficulty. I have preferred to retain cases of apparently non-inflammatory character under that head, while those of inflammatory nature are ranged under eczema seborrhoicum. The division line is, however, so ill-defined that many cases could be placed under either one or the other, so that, in a measure, in the description, duplication and repetition must of necessity result. In spite of such, however, this plan for the present seems the best.

Symptoms.—The clinical appearances presented by the disease are somewhat variable according to the region involved, and probably also dependent upon the cutaneous irritability of the individual skin. The special seat of the malady is the scalp. It may consist of mere branny scaliness, with skin practically of the normal color or slightly irritated and reddened (**pityriasis capitis**; some cases of dandruff), or there may be considerable scale-formation, under which the skin is found to be somewhat inflamed and even infiltrated. It sometimes exists in areas of small or large extent, or it may, as it does in some instances, involve the entire scalp, extending over to the ears and on to the forehead. The scales are grayish, or a dirty white color, and

[1] Unna, "Seborrheal Eczema," *Jour. Cutan. Dis.*, 1887, p. 449; and later paper in *Volkmann's klinische Vorträge*, No. 79, Sept., 1893—full abs. translation in *Brit. Jour. Derm.*, 1894, p. 23.

[2] Elliot, *New York Med. Jour.*, vol. liii., 1891, p. 174, and Morrow's *System*, vol. iii. (Dermatology), p. 273.

[3] Duhring, *Cutaneous Medicine*, part ii., p. 323.

greasy or unctuous to the touch. In the mild types—pityriasis capitis—the scales are often rather dry, as likewise is the hair. As a rule, however, although the scaliness varies from almost dry to oily, the hair, if the disease is at all marked, is noted to become oily or greasy and to need frequent washing. There are exceptional cases, however, in which the hair seems dry, lifeless, and lusterless throughout. In those of marked scaliness the hair-shaft, at and near the scalp, is often encircled with thin scales; and in almost all instances there is more or less scaly dust scattered through the hair, readily falling on the shoulders. In persistent cases hair loss, moderate or considerable in extent, is a frequent accompaniment. In extreme types the eczematous aspect is the more pronounced, and there is sometimes serous exudation. The disease is frequently irregularly diffused, and with a gradual lessening toward the borders, which is commonly more noticeable toward the forehead; on the other hand, the edge may be more pronounced, slightly elevated, and gyrate or irregularly segmental, and when red, as such a border usually is, becomes quite conspicuous and disfiguring. Exceptionally scattered over the scalp region, the malady

FIG. 67.—Eczema seborrhoicum, involving sides and angles of the nose, the eyebrows, and, to a slight extent, the chin and other hairy parts of the face. Slight to moderate scaliness of a greasy character, with underlying mildly inflammatory condition. Scalp is also involved.

may present segmental or ring-like patches, slightly inflammatory in character. The disease often remains limited to the scalp, remaining of a mild pityriasis type throughout, with, in some cases, an occasional exacerbation in which the skin becomes acutely inflamed and the scaliness more pronounced, but of a distinctly greasy character. The skin, instead of seeming to be thickened, often has a thin, inelastic appearance. In some cases in which these exacerbations take place the process extends on to the face, partly or completely invading it, and with, at times, areas of moist exudation, presenting, in fact, the appearance of a mildly acute eczema supervening upon a seborrhea.

While the disease frequently confines itself to the scalp and in most instances occurs primarily on this region, it is not uncommon for the region of the side of the nose and the immediate neighboring surface to show scaliness, merely furfuraceous or crusty in character, with a scarcely reddened skin beneath or with the part slightly

FIG. 68.—Eczema seborrhoicum, of more inflammatory type than shown in preceding illustration, involving the whole face and scalp, but especially pronounced about the nose.

hyperemic and even inflamed and somewhat oily; the glandular outlets are frequently enlarged or patulous, and occasionally the overlying scales show projections, extending in the duct openings. In some cases, more particularly in children, the manifestation on the face consists of several or more small, ill-defined, rounded, scurfy patches, especially about the mouth region, sometimes in association with similar lesions on the upper trunk. The eyebrows are also often the seat of furfuraceous or moderate scaliness, and in the male adult the mustache and beard often display the same characters. The ear canal, as well as the ears themselves, may also be the seat of the disease. The scales, especially those about the alæ nasi, are usually quite oily and of a yellowish cast; in fact, this yellowish tinge is often characteristic of this disease not only on this region, but elsewhere on the surface. Instead of the types just described, the disease is sometimes quite inflammatory, and has a decidedly eczematous aspect.

Exceptionally the vermilion border of the lips is involved with other parts, and covered with thin or somewhat thick adherent

PLATE X.

An unusual case of eczema seborrhoicum of a psoriasiform type.

scales or crusts, and it may be attended with a slight or marked tendency to fissuring; there is rarely any puffiness or swelling of the parts, as often observed in eczema of this region. In rare instances the disease is limited to the lips, scarcely extending on to the cutaneous surface, usually with a coexistent eruption of the scalp. In two instances recently under my care[1] it was limited to the vermilion of the lips (cheilitis exfoliativa), neither overstepping the mucous portion of the mouth nor the cutaneous integument, and consisted of persistent and repeated thin exfoliation; there was an associated slight involvement of the scalp in both cases, and in one case transitory mild patches upon the face.

On the breast the disease is frequently limited to one or two irregularly rounded areas over the sternum; it is scaly, with frequently slight elevations, and the skin reddened to a variable degree. On removing the crust, projections are frequently noted extending into the sebaceous gland outlets. It is also not infrequent upon the back, especially between the scapulæ. Instead of only several areas, they may be quite numerous, and may coalesce here and there, and form patches made up of irregular segments and circles or



FIG. 69.—Persistent exfoliation of the lips (eczema seborrhoicum—cheilitis exfoliativa).

festooned areas, often with distinctly inflammatory base, particularly at the periphery. As thus seen upon the chest, it constitutes the so-called seborrhœa corporis (Duhring), the lichen circumscriptus (Willan and Bateman), lichen annulatus (Wilson), lichen gyratus (Biett and Cazenave), and seborrhœa papulosa seu lichenoides (Crocker), seborrhœa figurée (Brocq)—names which convey a fair portrayal of the clinical appearances. The umbilicus is also a not uncommon seat of a dry, scaly, or oily moist form.

The disease on other parts—as, for instance, the genitocrural and axillary regions—varies but slightly from its appearance elsewhere, except that the heat, moisture, and friction of the parts tend to give it more the appearance of ordinary eczema. It frequently begins as small branny, scaly, slightly reddened spots, which often enlarge, and sometimes have somewhat elevated borders, and occasionally with a clearing center. They sometimes coalesce, and then a slightly or moderately inflamed area is presented, with scaly or crusted surface, and usually a rather sharply defined border; the scaliness or crusting being of a yellowish, greasy character, and rarely abundant.

[1] Stelwagon, "A Report of Two Cases of Persistent Exfoliation of the Lips," *Jour. Cutan. Dis.*, June, 1900.

The skin itself, both underlying the patches and immediately adjacent thereto, often is yellowish or has a yellowish tinge. In fact, in these regions there is a resemblance to both erythema or eczema intertrigo and eczema marginatum (tinea trichophytina). On the hands, and also the feet, the disease is usually of a patchy character, sometimes ill defined, at other times quite well marked, and the patches rather sharply circumscribed. Here, as elsewhere, coalescence sometimes occurs and larger irregular areas result; and occasionally vesiculation and serous exudation are noted.

In exceptional instances seborrheic eczema is distinctly psoriasiform in appearance, with scattered, variously sized patches over the general surfaces, usually sparing the extensor surfaces of the elbows and knees—favorite sites for the true psoriasis lesions. In these cases patches are commonly seen in the axillæ, about the genitalia, and in other places where psoriasis lesions are not generally observed. Sometimes they are flat, scaly spots or papules, often disk-like or circinate, with but a slight or moderate amount of scaliness, which is usually of a yellowish tinge, and greasy or unctuous in character. In exceptional instances seborrheic eczema may be quite extensively diffused and involve large surfaces, and be more or less polymorphous. The favorite localities are, however, those already named—



FIG. 70.—Eczema seborrhoicum of the sternal region, a not uncommon site; shows the tendency to irregular, ring-like formation of the patches and scales. The scaliness is slight and of a greasy character; affected surface reddened and mildly inflammatory.

scalp, eyebrows, region of the nose, sternal and interscapular regions, the genitocrural region, and axillæ, and in male adults the hairy parts of the face. In most instances it is upon the upper half of the body. While it begins primarily on the scalp in most cases, and from here tends to spread downward or develop on other regions, in the minority of cases it starts at the eyebrows, axillæ, or the genitocrural region.

As a rule, itching is not a troublesome symptom, and often it is extremely slight, and sometimes entirely wanting. It is noted most frequently with the disease on the scalp, and is not uncommon, when the patient is heated, on the sternal and interscapular regions, and

probably less frequent with the disease in the axillæ and genitocrural parts. It is sometimes entirely absent with the eruption on the hand.

The course of the malady is usually persistent, varying somewhat in severity and extent, and exceptionally with periods of relative quiescence or abatement.

Etiology.—The disease is quite common, especially in its milder types on the scalp. It is met with in both sexes and at all ages, although more frequent between the ages of early youth and thirty or thirty-five years. Systemic disturbances, especially those of the alimentary tract,—indigestion, dilatation of the stomach, constipation,—menstrual disorders, anemia, and general debility are to be considered as favoring factors. Elliot does not place much importance upon constitutional influences; Unna considers them slightly predisposing. My own observations place a good deal of stress upon the systemic condition as an influencing element, especially digestive irregularities; very often, in the milder cases, a variability can be gauged by the state of the alimentary tract. Of probably greater importance are the external factors of lack of care, want of cleanliness, the infrequent use of soap, irritating barber-shop and patent tonic applications to the scalp, and, on the body, the wearing of too heavy woolen underwear. Sweating, especially when retained for a long time in contact with the body, as often observed in winter in the use of thick flannel, is a potent favoring factor in the disease upon the sternal and interscapular regions. It is not improbable that the cautious, and therefore usually imperfect, washing of soiled woolen underwear to prevent shrinking is not without contributory import on covered regions.

FIG. 71.—Eczema seborrhoicum of the scalp of the lightest grade, known commonly as pityriasis capitis. A somewhat hyperplastic, loosely coherent, corneous layer, filling up and causing slight funnel-like dilatation of the follicular opening, and enveloping the hair-shaft at the orifice. Slight inflammatory cell-infiltration in the corium, especially along the hair-follicle (courtesy of Dr. Geo. T. Elliot).

While the disease is met with at all times of the year, it is more common during the "overclad" and indoor season; in summer the outdoor life, the better ventilation, and the more frequent bathing are unfavorable to its production. In a measure the malady is to be

viewed as contagious, and therefore parasitic, and barber-shops, hair-dressing establishments, the combs and brushes in the general toilet-rooms of hotels, etc., are doubtless responsible for its communication in some instances. As is to be inferred from the remarks on the description of the disease, the scalp is the starting-point in most cases, and the disease here has, therefore, an important etiologic bearing upon the development of the eruption on other parts.

Pathology.—The prevailing view of former years that all the conditions observed in this affection were the result of functional disease of the sebaceous glands—a seborrhea—is no longer tenable. Van Harlingen[1] was the first to demonstrate that pityriasis capitis was not a true seborrhea, although his careful work has been lost sight of in the recent excellent and more complete investigations of Unna, Elliot, and others; and Duhring first called attention to the fact that the disease on the chest (his seborrhœa corporis) was associated with, and often followed, the disease upon the scalp, thus foreshadowing the work of other observers, although he did not place the same interpretation upon the clinical facts.

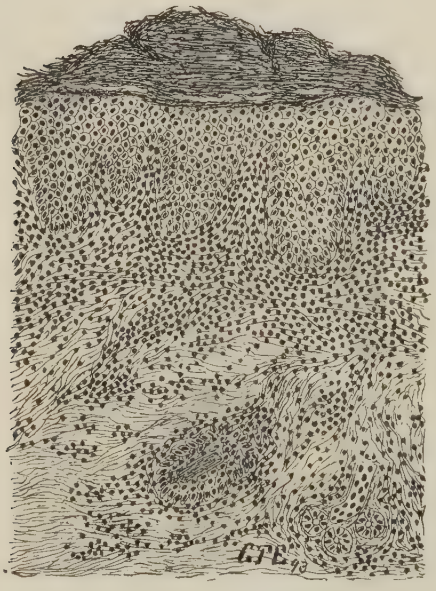

Fig. 72.—Eczema seborrhoicum, section of a small papule in the type commonly known as "seborrhœa corporis." A hyperplastic horny layer and dense inflammatory cell-infiltration in more or less of the entire corium, with slight edema (courtesy of Dr. Geo. T. Elliot).

The essential pathogenic factor of seborrheic eczema must be considered parasitic, and this view is strengthened by the tendency in many cases to assume the circinate, segmental, and spreading forms. Its origin primarily in the scalp in most cases, and its tendency to develop from this region to another, and its infrequent occurrence primarily simultaneously upon several parts, are also suggestive. Unna, and, following him, Leredde, believed that his morococci and the flask bacilli (Malassez's spores) are the parasitic agents. The investigations of Török, Sabouraud,[2] and others threw doubt upon the pathogenic importance of these organisms, and, as Galloway[3] and others have contended, it is more than probable that this coccus—morococcus—is a mere saprophyte. Both Merrill[4] and Whitfield[5] have found a coccus of variable size, arranged

[1] Van Harlingen, "A Contribution to the Pathology of Epithelium," *Amer. Jour. Med. Sci.*, July, 1876; "Pathology of Seborrhea," *Arch. Derm.*, April, 1878.

[2] See literature under eczema.

[3] Galloway, Discussion Harveian Society, *Brit. Med. Jour.*, Feb. 25, 1899.

[4] Merrill, *New York Med. Jour.*, vol. lxv., 1897, p. 322; and vol. lxii., 1895, p. 528.

[5] Whitfield, *Brit. Jour. Derm.*, 1900, p 406.

usually in pairs, and also in groups and short chains, grayish white, and sometimes developing into a yellowish color. Whitfield found it in 12 cases examined by him, but experiments at inoculation on himself were without result. Merrill found constantly diplococci, especially two varieties, one chromogenic and the other non-chromogenic, and states that in a fair proportion of his inoculative experiments he succeeded in producing the disease.

The clinical appearances suggest an inflammation of the skin, usually of a slight or moderate grade,—a mild dermatitis,—and apparently with an associated disturbance of the oil-secreting glands. Unna claims that the coil-glands are those implicated, and to which the oily secretion is due. From his studies he states that there does not exist any hypersecretion of the sebaceous glands which can clinically be called dry seborrhea, due to a deposit upon the surface of firm products from these structures. Seborrheic eczema, in which he includes all forms of seborrhea except seborrhœa oleosa, is due, he believes, to hypersecretion of oil from the sweat-glands, and not

FIG. 73.—Eczema seborrhoicum of the upper part of the back and interscapular region, a not uncommon site; shows the irregular ring tendency and rather sharply defined borders. The scaliness is slight and of a greasy character; affected surface reddened and mildly inflammatory.

the sebaceous glands, together with an inflammation of the skin due to parasitic invasion; the oil secretion permeating the cutaneous tissues, as well as mixing with the surface scales and crusts, and that to this excessive secretion the yellow tinge is to be attributed. His views as to the sole implication of the sweat-glands have not, however, found general acceptance.

The pathologic anatomy has been studied by Unna, Elliot, and others, and with findings, upon the whole, essentially similar. Unna[1] states that four factors are found: (1) Parakeratosis of the epidermis; (2) epithelial proliferation (acanthosis); (3) inflammation of the derma, varying in depth; (4) augmentation of the fatty secretion of the skin, together with increased activity of the coil-glands. The first three are

[1] Quoting from abstract of his paper in *Brit. Jour. Derm.*, 1894, p. 23.

also typical of eczema. The fourth gives the character to the seborrheic disease, but, as already stated, there is difference of opinion as to the source of the fat or oil secretion. In addition he notes an increase in size in the panniculus adiposus; and only after the total disappearance of the hair that the sebaceous glands take part and the sebum accumulates. This last he considers is not an essential part and is only observed in cases of long standing. Elliot[1] has failed to confirm Unna's observation as to fatty infiltration in the tissues or in the sweat-glands; he found disorganization of these glands, but considered this only an evidence of their participation in the inflammatory process, but not necessarily in the line of excessive fat-production.

Diagnosis.—The diagnostic features of eczema seborrhoicum are its almost invariable occurrence primarily upon the scalp, its spread from this region downward, the mildly inflammatory character, the absence of pronounced infiltration, the greasy nature of the scales or crusts, and the tendency, in many cases, to disc-like or segmental configuration, and the relatively moderate amount of itching. The disease is to be distinguished from seborrhea, eczema, pityriasis rosea, ringworm, and psoriasis. The acceptance of eczema seborrhoicum as a distinct entity has almost obliterated seborrhea. But there are still some cases of this latter, in the scalp especially, in which an inflammatory element cannot be detected, and which are, therefore, to be distinguished by the entire absence of inflammatory symptoms and of signs of irritation. The skin is found paler than normal, extremely oily, and often slate-colored, the scaliness being soft and oily. The oily variety of seborrhea, not uncommon on the scalp and nose, is distinguished by the entire lack of scale-formation and freedom from inflammatory signs.

Eczema seborrhoicum is to be differentiated from ordinary eczema by the absence of markedly inflammatory characters, the practical absence of infiltration, its tendency to be somewhat sharply marginate and often segmental or of irregular outline, and by the fact of its first appearance upon the scalp. The scaliness is less abundant and usually of yellowish tinge and greasy-looking to the sight, and unctuous to the touch. In cases of any extent the sternal and interscapular regions rarely escape, parts that are seldom involved in ordinary eczema except in generalized cases. Upon the hands the differentiation is sometimes extremely difficult, but the scurfy or scaly patch-formation here, irregular outlines, and usually the presence of the characteristic disease on other parts will be of aid. In the axillæ and genitocrural regions eczema is rarely ever sharply defined, segmental, or patchy, as generally obtains in eczema seborrhoicum; and the latter's frequent mode of beginning here in ringworm-like patches is unlike eczema. Moreover, seborrheic eczema is on these regions, and also elsewhere, except the scalp, seldom itchy to the extent of being a troublesome symptom, while in eczema it is constantly so.

Pityriasis rosea begins on the trunk almost invariably, comes out more or less acutely in the course of a few days, and presents numerous maculosquamous and papulosquamous patches, tending to spread, and here and there coalesce, rarely involving face, never the scalp, and seldom occurring just over the sternum, as so often observed in eczema

[1] Elliot, *Jour. Cutan. Dis.*, 1893, p. 205 (with several good histologic cuts).

seborrhoicum. The early patches of pityriasis rosea are never segmental, as in seborrheic eczema, and tend more decidedly to developing into spreading rings, and they are not covered with the same greasy or unctuous scales of the latter disease. Its course, after full development, is, as a rule, rapidly toward full recovery, whereas in eczema seborrhoicum this natural tendency to a self-limited duration is not observed. Nevertheless it must be conceded that at times the two conditions present puzzling similarity, which is only positively solved by several days' or one or two weeks' observation.

Ringworm patches, especially in their early stage, and particularly in children about the face, resemble patches of seborrheic

FIG. 74.—Eczema seborrhoicum in a middle-aged man, involving axilla and genitocrural region; of a superficial, marginate, greasy-crusted type. Coexistent scaliness of the scalp of moderate character. Duration, with periods of comparative freedom, a period of twelve years. Is clinically somewhat suggestive of so-called "eczema marginatum" (tinea trichophytina). Recovery after a few months under mild applications.

eczema, but in the former the almost invariable tendency to a complete clearing up of the central portion as it spreads peripherally, and the usually more pronounced and elevated border are generally sufficiently characteristic. From eczema marginatum—ringworm of the genitocrural and axillary regions—the differentiation is not always readily made, but in ringworm the border is usually quite elevated, distinctly marginate, and outside of the confluent areas typical ringworm patches are generally to be found. Moreover, confluent ringworm of these regions is usually more distinctly inflammatory, and the infiltration more marked, than in eczema

seborrhoicum. In all suspected and difficult cases an examination of the scales from the edges will be the crucial test; the ringworm fungus can be found if it be that disease, if the examination be thoroughly and carefully made.

More or less generalized small patchy seborrheic eczema simulates psoriasis at times quite closely, but the favorite regions of psoriasis—the extensor surfaces of the knees and elbows—are rarely invaded in eczema seborrhoicum. Moreover, the patches of this latter disease are rarely so sharply circumscribed as psoriasis patches, and the scales are usually yellowish and greasy, instead of white, silvery, or grayish, and hard and dry, as in psoriasis. In such cases of seborrheic eczema the disease on the scalp rarely shows the same character, but on this region it is more of the nature of a mild or moderate generalized scaliness, and not patchy, as in psoriasis.

Prognosis.—The disease is, as a rule, more readily managed than ordinary eczema, often responding rapidly to treatment. But there is usually a decided tendency to recurrence, which Unna considers to be due to the fact that the parasitic element may remain quiescent in the glandular structures (in his opinion, the coil-glands), and again, favored by some unknown contributory influence, give rise to a recurrence. Elliot believes there is another reinfection. It is more probable that the patient's constitutional condition is an important favoring factor; if in good, strong, vigorous health, with digestion being well performed and the bowels regular, relapses are not apt to occur. The application of a weak resorcin lotion, 2 to 5 per cent. strength, at intervals of several days or a week, and the use of a boric acid or resorcin soap for shampooing and for occasional toilet washing, are advisable in those cases showing a strong tendency to recur. The hair loss which is often observed in connection with the disease on the scalp can generally be replaced by proper management (see alopecia), provided the disease has not been too long continued.

Treatment.—Believing, as I do, that the state of the general health, and especially the condition of digestion, has in many cases an important etiologic bearing, the line of constitutional treatment to be adopted depends upon indications in the individual cases—differing in no respect from the general plan advised in eczema, to which the reader is referred. The bowels should be kept free, and some attention given to diet.

The most important external remedies—and, of course, the external treatment is the essential part of the management of the disease—are sulphur, salicylic acid, and resorcin. Upon the scalp, resorcin, in the form of a lotion made up of 5 to 30 grains (0.33 to 2.), 1 to 2 drams (4.–8.) of alcohol, and water to make an ounce (32.), is one of the most valuable remedies we possess; it may even be used stronger, but in all the stronger proportions some care is necessary at first, as exceptionally irritation is produced. It should be applied once or twice daily. In some instances the lotion is too drying, and is to be supplemented every second or third day by an application of plain petrolatum; or an ointment medicated with 10 to 30 grains (0.7–2.) of resorcin to the ounce (32.) can be employed, either occasionally in

conjunction with the lotion treatment or alone. The objection to resorcin, especially in lotion form, is that in those with gray or decidedly blonde hair, a dirty yellow staining, lasting several weeks or longer, sometimes is noticeable after prolonged use. If employed carefully and in scant quantity, this is not so likely to occur; in such patients, however, other plans are, for this reason, preferable. Sulphur, the precipitated or sublimed, in the form of an ointment, ½ dram to 2 drams (2.–8.) to the ounce, is often curative, but this drug irritates in some cases. On the scalp region, too, salicylic acid, 10 to 40 grains (0.65–2.65) to the ounce of petrolatum, is valuable; and very often a compound salve containing both resorcin and salicylic acid is the best of all. A 0.5 to 2 per cent. solution of salicylic acid in equal parts of alcohol and water is sometimes useful in the scalp disease. Along with the remedial applications occasional washing with soap and water is necessary, the frequency depending upon the rapidity of the scale reaccumulation and the demands of cleanliness. For this purpose a boric acid or a resorcin soap may be used; in sluggish cases the tincture of green soap is permissible, and it can be medicated with 5 to 10 grains (0.33–0.65) of resorcin to the ounce (32.).

Upon non-hairy regions the conjoint use of a lotion, similar but somewhat weaker than those named, along with a salve, usually gives the best result. The ointment for these parts should also be weaker than for the scalp. In these cases sulphur often irritates unless used very weak, 10 to 60 grains (0.65–4.) to the ounce (32.). It frequently acts more satisfactorily and is better borne when prescribed with a paste as:

℞.	Sulphur. præcip.,	gr. xxx–lx (2.–4.);
	Ac. salicylici,	gr. x (0.65);
	Pulv. amyli,	
	Pulv. zinci oxidi,	āā ʒiss (6.);
	Petrolati,	℥iv (16.).

In obstinate patches an occasional application of a 10 to 50 per cent. alcoholic solution of resorcin, as advised by Frickenhaus,[1] is sometimes valuable, but the stronger proportions are to be used cautiously, as aggravation can occur; exfoliation, usually after a few applications, results, and then petrolatum or cold cream can be used for a few days, and, if necessary, the treatment repeated. Occasionally, in obstinate cases of the disease on the face and trunk, an ointment containing chrysarobin, 5 to 30 grains (0.33–2.) to the ounce (32.) of the paste above named, may be used with advantage, for a time at least, and then other treatment of milder character employed. About the face this remedy should, however, be used with great care. In persistent body patches I have frequently employed chrysarobin in collodion, as advised in psoriasis. In some face cases which proved obstinate, I have found, even when seemingly quite inflammatory, the cautious use of the compound lotion of zinc sulphate and potassium sulphuret (see acne), with an occasional application of cold cream, of signal benefit. Short Röntgen-ray exposures (2 to 5

[1] *Monatshefte*, June 1, 1899.

minutes, with a soft to medium tube, at a distance of 8 to 10 inches), at intervals of several days or a week, are a help in obstinate face cases.

In children, as well as in adults of sensitive skin, the applications should be extremely weak at first; the malady is usually most irritable on the face and genitocrural region. The disease upon the lips must also be treated cautiously at first, but in persistent, stubborn cases an occasional application of the strongest remedies becomes necessary; strong silver nitrate, resorcin, and lactic acid solutions are useful here —silver nitrate and resorcin, 2 to 20 per cent. strength, and lactic acid, at first with 10 to 20 parts water; later, if necessary and not too irritating, in stronger proportions; in the interim mild ointments are to be used. In the auditory meatus the resorcin lotion, applied scantily, and supplemented with a weak resorcin salve, constitutes the most successful plan, but the disease here is often obstinate, and frequently requires change of remedies before final success is achieved.

HERPES SIMPLEX.

Synonyms.—Fever blisters; *Fr.*, Herpès vulgaire; *Ger.*, Bläschenflechte.

Definition.—An acute inflammatory affection characterized by the formation of pin-head to small pea-sized vesicles, grouped, and occurring about the face or genitalia.

Symptoms.—The eruption is commonly foreshadowed by a feeling of heat and burning in the part. It generally consists of but one or two groups, which may be small or large; or several or more clusters may present. The vesicles, which are usually seated upon a hyperemic or mildly inflammatory base, are pin-head or slightly larger in size, often crowded close together so that sometimes it may be somewhat difficult to make out their individuality; this is especially so on the lips, but on other parts of the face the lesions, while grouped, are quite clearly discrete. They are distinctly vesicular, with clear contents, subsequently becoming more or less milky, and may exceptionally change to a seropurulent or purulent character. They show no tendency to spontaneous rupture, but should they be broken open, a superficial abrasion or excoriation results, crusts over, the crust subsequently falling off. As a rule, however, they remain unbroken throughout, and gradually dry to thin crusts, of a yellowish or brownish color, which finally drop off and leave no trace. In some cases in which the lesions may be few and the consequent group small and insignificant, the contents may be reabsorbed, and the disease be shortened or aborted. There are, as a rule, no systemic disturbances; never in the cases in which the eruption is upon the genitalia, probably for the reason that it is always scanty; on the face, when the eruption is somewhat extensive, there may be, in severe cases, more or less malaise, pyrexia, and chilliness preceding and accompanying the early part of the outbreak.

Herpes Facialis.—The herpetic clusters—one or several—may be limited to the lips (*herpes labialis*); or appear on the skin near the mouth, chin, under or near the ala of the nose, or on the cheek, or elsewhere on the face. Occasionally the seat of the patch or patches

is the ear, commonly the auricle. When on other parts than the lips or mucous membrane, the eruption is occasionally quite abundant. The skin is hyperemic or slightly inflamed. The malady is also seen in the mouth, and shows two, several, or more, vesicular lesions crowded close together. At first small, the lesions often increase in the course of some hours or one or two days to the size of a small French pea. There is heat or burning and, rarely, itching.

FIG. 75.—Herpes simplex of somewhat extensive development in a girl of ten years, of four days' duration. Outbreak preceded by slight, evanescent febrile action. Characteristic grouping and coalescence; crusting stage already reached on the lips.

After several days, or earlier in slight cases, they begin to dry up, and form a thin crust, which in the course of two or three days drops off. Sometimes one or two of the vesicles are broken and the patch is then excoriated at these points, serum oozes out, which dries to a thin yellowish crust. In some instances, especially on other parts than the lips, the lesions may coalesce and form a small bleb; as a rule, however, this does not take place. Unless irritated, the crust formed drops off in from several to ten days after the disease had first presented. When near or at the angle of the mouth, from the act of opening and shutting the mouth slight fissuring is sometimes noticed, and the constant irritation of the food and saliva may keep the part macerated and sore for one or two weeks or longer. In some instances of considerable eruption slight febrile action precedes. A form of "herpetic fever" has been recorded from time to time, occurring epidemically (Savage, Seaton),[1] usually preceded by a rigor or distinct chill and other symptoms of general disturbance; the outbreak is generally limited to the lips and region of the mouth, in some cases involving also the ears.

Herpes Progenitalis.—Herpes about the glans and prepuce in the male, and the vulva in the female, is also not uncommon. It may consist variously of one or several groups, but it is rarely seen in such abundance as frequently observed on the face. Slight burning and

[1] Savage, *Lancet*, Jan. 20, 1883; *Jour. Cutan. Dis.*, 1883, p. 253; Seaton, *Trans. Clin. Soc.*, London, 1886, p. 26.

itching are usually first noted, rapidly followed by the appearance of a slightly red, and sometimes a little puffy inflamed area, upon which are soon seen several or more minute vesicular points, which slowly increase to the size of a pin-head, sometimes larger. They dry up, or the contents are absorbed; slight crusting ensues, and the disease, under favorable circumstances, in the course of several days or so disappears. Or the lesions may be rubbed or chafed, rupturing taking place, giving rise to one confluent excoriated surface or several excoriated points; and then the duration is usually much longer, inasmuch as the surface is continually irritated by the secretions and probably occasionally by the urine, and resulting in a slight abrasion or even superficial ulceration, which may give rise to confusion with a soft chancre. The eruption may be seated upon the outer prepuce or inner prepuce (herpes præputialis) or the glans in the male; and on the labia minora or labia majora in the female; in the former, too, a patch is sometimes observed further down on the sheath of the organ, and in women just beyond the labia majora.

Etiology and Pathology.—Herpes facialis is often observed in association with other disease, such as colds (cold sores), fevers (herpes febrilis, fever sores), lung disease,[1] malaria,[2] and digestive disturbances. In some individuals an attack of indigestion will lead to an outbreak. Long exposure to the sun, more especially when on the water, is sometimes provocative. An irritable or decayed tooth seems in some instances of recurrent cases the exciting factor.

Herpes progenitalis is believed, in the male subject at least, to be much more common in those who have previously had some venereal disease (Greenough, Diday and Doyon, Fournier, and others),[3] more especially gonorrhea; while this is unquestionably true, doubtless this apparent overwhelming frequency may, in part, be explained by the fact that individuals addicted to sexual indiscretions are readily alarmed by the appearance of any lesion on this part, and thus come more frequently under the eyes of the physician than those who have no reason to be suspicious. A long prepuce predisposes to it, and coitus is also often the exciting factor; in some instances an attack follows each indulgence. Bergh[4] found that in women an outbreak is concomitant with, precedes, or follows menstruation, and that in women it is not a "professional" (prostitute) disease, although Unna's[5] experience does not agree with this. As to relative frequency in the

[1] E. F. Wells, "Pneumonic Fever—its Symptomatology," *Jour. Amer. Med. Assoc.*, May 26, 1894; statistics of his own cases and those of others quoted show that herpes is observed in a large proportion.

[2] Arthur Powell, "Prognostic Value of Herpes in Malarial Fevers," *Brit. Jour. Derm.*, 1897, p. 354. This writer, living in a district (Assam) where malaria is common, the death-rate from which averages 22.6 per 1000 inhabitants, states that "if during an attack of remittent or intermittent fever a patch of herpes broke out on the lips, face, or elsewhere, I always looked on this as a sign that the malarial attack was over. In all my experience I have never met with a case to negative this theory, which I thought was well known and recognized by our profession."

[3] Greenough, "Herpes Progenitales," *Arch. Derm.*, 1881, p. 1; Diday and Doyon, *Les hèrpès genitaux*, Paris, 1886; Fournier, *Gaz. med. de Paris*, 1896, Jan. to May.

[4] Bergh, "Ueber Herpes menstrualis," *Monatshefte*, vol. x., 1890, p. 1 (a complete review with many references).

[5] Unna, "Herpes Progenitalis, Especially in Women," *Jour. Cutan. Dis.*, 1883, p. 321. These papers, together with the last three on the preceding page, all on genital herpes, are full and exhaustive and give many literature references.

two sexes, it is the general opinion that it is much more common in the male, although Unna's and Bergh's statistics do not bear this out, the last named, in fact, believing it more common in women.

Herpes is certainly neurotic. It is possible that it may depend upon reflex irritation of the neighboring sympathetic ganglia, due to local or internal irritation. In fact, the disease is considered by some to be an abortive or irregular zoster, a view scarcely to be accepted. Kopytowski[1] found considerable histologic analogy between herpes progenitalis and zoster.

Ravaut and Darre,[2] from their experimental study of 26 cases (7 men, 19 women) of lumbar puncture in genital herpes, found that all cases accompanied by any nerve symptoms (as well as many without such symptoms) presented some modification in the cephalorachidian fluid—numerous cell elements (lymphocytes); they consider their research is strong evidence that the central nervous system plays an important rôle in genital herpes. A microbic origin has also been suspected in herpes, but, while possible, it does not seem probable.

Diagnosis.—Herpes facialis is, as a rule, readily recognized, especially when on the lip. On neighboring skin there is also rarely any difficulty. It can scarcely be confused with vesicular eczema, as this latter disease is made up of closely crowded small vesicles, which tend to coalesce, but with no tendency to form distinct groups; is slow, as a rule, in its appearance, usually presents some inflammatory thickening, the vesicles are smaller and rupture spontaneously and give rise to gummy exudation. The crusted patch of herpes and that of impetigo often look closely alike, but the scattered patches of impetigo and the history of its appearance and course are distinctive; moreover, impetigo rarely is seen on the lip, herpes commonly.

Herpes of the genitalia presents similar features to that of the face; the presence of several or more small vesicles on a red or inflamed base scarcely permits of error. When abraded and irritated by the moisture or secretions of the part, or cauterized by some overzealous physician, there is sometimes great difficulty to distinguish it from a soft sore and possibly from hard chancre. The absence of glandular enlargement in herpes, or at the most of slight transitory swelling, is a differential point of value. Chancroids are usually multiple, with distinct ulceration. In doubtful cases, when a hurried opinion is necessary, autoinoculation experiments can be made. Ordinarily the beginning induration of a syphilitic chancre will serve to differentiate, together with the history of its appearance. In some instances it must be acknowledged it is not possible to give a definite opinion at once, but the application of the appropriate treatment for herpes will soon heal this disease, whereas much time is necessary for both chancroid or chancre to bring about such result.

Prognosis and Treatment.—The disease, both on face and genitalia, soon subsides, usually in five to ten days, but there is often a distinct tendency to recurrence, more especially in herpes progenitalis. Herpes labialis in fevers, lung disease, etc., is not now thought to be of any prognostic importance.

[1] Kopytowski, *Archiv*, 1904, lxviii., pp. 55 and 387 (clinical and pathologic study of 24 cases of herpes progenitalis).

[2] "Les réactions nerveuses au cours des herpès génitaux," *Annales*, 1904, p. 480.

Ordinary herpes occurring about the lips or other parts of the face rarely requires more than external applications; in persistent and oft-recurring cases, however, the general health of the patient must be looked after, special attention being given to the state of the digestive tract and to possible malarial conditions. Ordinarily the application, several times daily, of spirits of camphor, cologne-water, a lotion of zinc sulphate, from 1 to 5 grains (0.065–0.33) to the ounce (32.) of water or water and alcohol, will be sufficient to bring about a disappearance of the lesions; the first two named, if frequently applied in the earliest stage, will occasionally abort the outbreaks, more particularly the spirits of camphor. Painting over the affected part tincture of benzoin is also useful, and it is especially valuable when the lesions are seated at the mouth angle, showing a tendency to fissuring; the mouth is slowly and carefully opened as widely as possible, and the benzoin tincture painted over two or three times, and allowed to dry, while the mouth remains open; it is repeated two or three times daily. When the crusting stage is reached, ointments, such as cold cream, camphor ice, etc., can be used, the crusts usually separating more quickly under such applications.

Occurring about the genitalia, the treatment is somewhat different. Cleanliness is of the first importance, not only in promoting the disappearance of an attack, but in preventing new outbreaks; the parts should be gently washed two or three times daily. Various powders are useful here, such as boric acid, alone or with from 1 to 5 grains (0.065–0.33) of zinc sulphate to the ounce (32.); or zinc oxid, with or without from 5 to 10 per cent. of calomel. Lotions are also valuable, the most efficient being a saturated solution of boric acid, and one containing from 5 to 10 grains (0.33–0.65) each of calamin and zinc oxid and from ½ to 1 dram (2.–4.) of alcohol in each ounce (32.) of saturated solution of boric acid. A layer of lint or borated cotton should be placed over the part.

In obstinate and recurring genital cases daily applications of the galvanic current will prove of value; the positive electrode is placed over the lower lumbar region, and the negative over the affected part, the current being mild—½ to 2 milliampères. A mustard plaster over the lower spine, daily or every few days, is sometimes useful in this class of cases. The same may be said of the administration of arsenic, both in herpes facialis and herpes progenitalis. In markedly recurrent cases of the latter in the male circumcision is advisable.

HERPES ZOSTER.

Synonyms.—Zona; Zoster; Shingles; Ignis sacer; *Fr.*, Zona; *Ger.*, Gürtelausschlag; Feuergürtel.

Definition.—An acute inflammatory self-limited disease, characterized by the appearance of several or more groups of vesicles on slightly elevated and inflamed areas, of unilateral distribution, and corresponding to the peripheral and intertwining branches of one or two cutaneous nerves.

Symptoms.—In many instances there is more or less neuralgic

pain in the region for one or several days preceding the cutaneous lesions. This may continue through the course of the disease, being continuous or intermittent in character, or it may abate when the eruption is fully out. In other cases the outbreak of the vesicles and neuralgic pains are synchronous. Not infrequently the pain may be so slight as to give rise to no complaint, or sometimes it is entirely absent; this is observed more especially in children (Bohn). In some of the more extensive cases there may be, in the beginning, mild febrile action, chilliness, and a variable degree of malaise. Swelling of the neighboring, and occasionally other, lymphatic glands is frequently, and probably always, noted (Barthélemy,

FIG. 76.—Herpes zoster (dorsopectoralis), left pectoral region, in a youth of sixteen, of about one week's duration. The grouping and cluster tendency are shown; a few lesions in the patch on the side slightly hemorrhagic. There were also a few groups on the same level posteriorly.

Strümpfell, Blaschko, Winfield, Hay, and others).[1] The eruption makes its appearance suddenly, usually as several or more hyperemic or slightly inflammatory patches, upon which are seated usually 10 to 20 papules or vesicopapules, irregularly grouped; these, generally before the case is seen by the physician, soon become clearly defined vesicles, of the size varying from a pin-head to a pea; two or three closely crowded together sometimes become confluent, and form a bean-sized bleb. They show no tendency to spontaneous rupture. New vesicles and patches may come out for several days or longer, although in most cases all the patches are concomi-

[1] Barthélemy, *Annales*, 1891, p. 21, and 1892, p. 168.

tant or are out within forty-eight hours. The disease reaches its full development in five to ten days, and then begins to subside. The contents of the lesion are clear, becoming slightly milky, and rarely puriform; at the end of one to two weeks they have dried to thin, yellowish or brownish crusts, which in several days drop off, leaving red spots, which gradually fade, in most instances no permanent trace remaining. Sometimes, however, there may be a variable amount of scarring left to mark the site of the vesicles. Occasionally the eruption does not go beyond the vesicopapular stage (abortive zoster). In some cases, more especially in old people and in those in a depraved condition of health, the lesions, or some of them, are hemorrhagic (herpes zoster hæmorrhagicus), and contain an admixture of blood and pus; in other exceptional instances there is a slight or marked degree of gangrenous action (herpes zoster gangrænosus),[1] and several such gangrenous vesicles may coalesce, producing areas of ulceration, usually superficial in character, but which may finally result in considerable scarring. In this latter class of cases, especially, there is, as a rule, more or less constitutional disturbance of fever, loss of appetite, nausea, and chilliness, and in rare instances the patient becomes septicemic and succumbs. Exceptionally lymphangitis, furuncles, carbuncles, and phlegmon have been noted as complications (Besnier and Doyon, von Düring).

There is frequently a sense of soreness or burning at the seat of the malady, and exceptionally itching. The neuralgic pain may in some instances continue long after the complete disappearance of the lesions. The eruption may appear upon any portion of the body, following the course of a nerve or of two or more nerves; it is, therefore, always limited in extent, in some cases, however, much more extensive than in others; exceptionally, however, it has been noted to involve a greater part (Wetherill) or the entire half of the trunk (Wilson), several or more nerves being implicated. In slight cases, on the other hand, there may not be more than two or three small groups. With rare exceptions the eruption is unilateral, with, in rare instances, a few lesions seen at a distance from the seat of the disease (Jamieson, Girandeau, Jeanselme, and Leredde). Sometimes one or two groups are seen just beyond or overstepping the median line. Exceptionally it is bilateral (Moers, Bryant, Squire, Stabell, Finny, Elliot, Carpenter, Hallopeau et Barrie, Colcott Fox, and others),[2] and usually on the same plane, but cases have also been observed when the eruption on one side (usually chest or abdomen) was higher or lower than that on the other. These exceptions to the unilateral distribution are, however, extremely rare, many observers, including myself, of large clinical opportunities never having met with a single instance.

[1] Baum, "Herpes Zoster Gangrænosus," *Medicine*, 1895, p. 1 (with colored plate), describes a case, and refers briefly to Kaposi's and other similar instances.

[2] Bilateral zoster cases: Moers, *Deutsches Archiv für klin. Medicine*, vol. iii., 1867, p. 163, and vol. iv., 1868, p. 249; Bryant, *Medical Times and Gazette*, 1865, i., p. 335; Squire, *ibid.*, 1873, i., p. 495; Stabell, *Tijdskrift for prak. Medicin*, No. 13, 1884, abstract in *Archiv*, 1885, p. 316; Finny, *Brit. Med. Jour.*, 1885, p. 67; Elliot (relapsing), *Jour. Cutan. Dis.*, 1888, p. 324; Carpenter, *Brit. Jour. Derm.*, 1892, p. 23; Hallopeau et Barrie, *Annales*, 1892, p. 296; Colcott Fox, *Brit. Jour. Derm.*, 1898, p. 252.

The most common sites for herpes zoster are the thoracic, lumbar, and supra-orbital regions. Various regional names are given to the malady, simply to indicate the locality on which the eruption occurs. The principal of these are zoster capillitii, zoster faciei, zoster ophthalmicus, zoster frontalis, zoster nuchæ, zoster colli (seu cervicalis), zoster brachialis, zoster pectoralis, zoster abdominalis, zoster femoralis, etc.

The general features, behavior, and course of the eruption are the same whatever the region affected. Zoster occurring about the head and face is to be considered more serious in character. In zoster ophthalmicus disastrous consequences sometimes ensue, even to the extent of complete destruction of the eye, pyemia, meningitis,

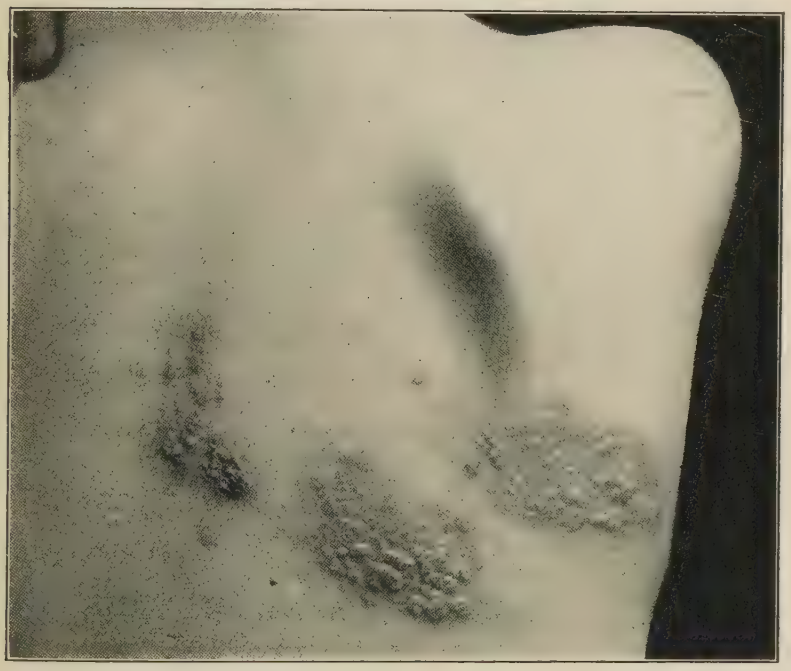

FIG. 77.—Herpes zoster (dorsopectoralis) of right pectoral region, in a male adult, of about five days' duration, showing the erythematous plaques with the numerous vesicles, some coalescent. A few patches also anteriorly (courtesy of Dr. M. B. Hartzell).

and death (Hutchinson, Hybord, Wyss). In the facial variety lesions may be found within the nose and mouth, and exceptionally the eruption is limited to these mucous membranes (Fournier, Ponzin, Lermoyez, and Barozzi). In zoster frontalis the eruption follows the course of the supra-orbital nerve, showing groups over the brow from the eye upward on to the scalp. In facial and inframaxillary zoster there may exceptionally be loss of teeth and even necrosis of the jaw (Paget, Singer). In a few of the head cases persistent anesthesia has been noted (Zeisler), and about the eye and brow scarring is seen most frequently, but not invariably, as has been stated (Thibiérge); the neuralgic pain, preceding, accompanying, and following, is

also apt to be more marked. In zoster brachialis (zoster cervico-brachialis) the eruption is often abundant, and seated upon the neck, shoulder, and upper arm regions, and exceptionally may extend down to the fingers.

The nervous disturbances in zoster are usually sensory, consisting of pain of varying degree, but this is not always present. Motor involvement [1]—paralysis, atrophy—has also been exceptionally noted, and this more especially with zoster of the facial regions (Hunde, Wangler, Lesser, Tryde, Greenough, Strübung, Porzig, Ebstein, Eichorst, Eulenberg, Vernon, Tay, Voight, Besnier, Truffi, and others), but it has also occurred in zoster of the extremities, especially the upper (Schwimmer, Gibney, Broadbent, Joffroy, Weiss, and others), and in connection with truncal zoster; exceptionally hemiplegia, paralysis of bladder, etc., have been noted (Duncan, Davidsohn).

Etiology.[2]—Herpes zoster occurs at all ages and in both sexes. It is probably most frequent between the ages of eight and twenty, and not at all uncommon after forty; it is only exceptionally observed in early infantile life. It is not an uncommon disease, constituting about 1 to 1.5 per cent. of all skin cases. It seems much more frequent during spring and late autumn and winter, and especially during damp, changeable weather. Many causes are given by different observers for the production of this disease; among the most important may be mentioned atmospheric changes, exposure to cold and wet, sudden checking of perspiration, traumatism, peripheral nerve irritation or injuries (Weir Mitchell, Keen, Picaud, Janin, Bulkley, Liveing, Köbner, Touton[3]), pulmonary disease (Leudet, Leroux), intestinal parasites (Duryee), malaria (Colombini, Winfield[4]), carbonic acid gas poisoning (Leudet, Sattler), and the administration of arsenic (Hutchinson, Duckworth, Gerhardt, Crocker, Zeisler, Nielsen, O'Donovan, and many others).[5]

[1] Strübung's paper, "Herpes Zoster und Lähmungen motorischen Nerven," *Deutsches Archiv für klin. Medicin*, vol. xxxvii., 1885, p. 513, refers to most cases published up to that date; Ebstein, "Zur Lehre von den nervösen Störungen beim Herpes Zoster mit besonderer Berücksichtigung der dabei auftretenden Facialslähmungen," *Virchow's Archiv*, vol. cxxxix., 1895, p. 505, also gives review of the subject and literature references.

[2] Clinical analyses bearing upon frequency, etiologic factors, regions involved, etc.: Greenough (255 cases), *Boston Med. and Surg. Jour.*, Oct. 5, 1889—abstract in *Jour. Cutan. Dis.*, 1889, p. 426; Cantrell (193 cases—observed in services of Duhring, Van Harlingen, Stelwagon, and Cantrell), *Philada. Med. Jour.*, March 26, 1898. Of the 62 zoster pectoralis cases in Cantrell's analysis, 58 were in males. Max Joseph, *ibid.*, 1902, vol. x., p. 597; W. Pick, *Prag. med. Wochenschr.*, 1904, p. 219. Among the valuable papers on etiology, of recent date, must be mentioned that by W. G. Hay, *Jour. Cutan. Dis.*, 1898, p. 1 (with good bibliography); Van Harlingen (etiology and nature), *Amer. Jour. Med. Sci.*, 1902, vol. cxxiii., p. 141; Head, Clifford Allbutt's "System of Medicine," vol. viii.; Evans, *Brit. Jour. Derm.*, 1905, p. 198.

[3] Weir Mitchell, *Injuries of the Nerves and their Consequences*, Philadelphia, 1872; Picaud, *Des éruptions cutanées consécutives aux lésions traumatiques*, Paris, 1875.

[4] Winfield's investigations, *New York Med. Jour.*, 1902, vol. lxxvi., p. 191 (33 cases), indicate that 40 per cent. of cases show malarial plasmodia in the blood; the literature is reviewed.

[5] Nielsen, "Ueber das Auftreten von Herpes Zoster während Arsenikbehandlung," *Monatshefte*, vol. xi., 1890, p. 302; abbreviated translation in Sydenham Soc'y's *Selected Monographs on Dermatology*, London, 1893, p. 167. The writer gives 10 cases of his own, and references of other cases. The paper is valuable as proving conclu-

Plate XI.

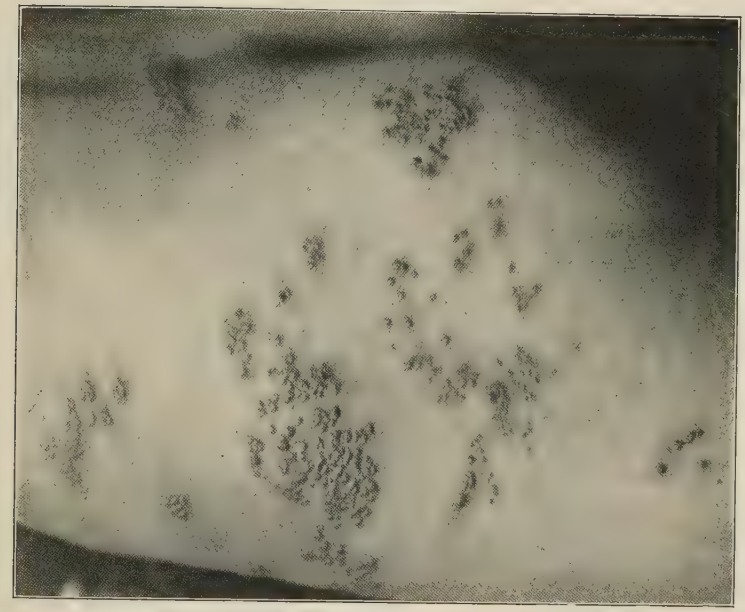

Herpes zoster.

I have myself met with several instances of its arsenical production. It may also doubtless arise from reflex irritation, from functional or organic disease of other organs (Bulkley, Jewell). In

FIG. 78.—Herpes zoster (cervicobrachialis), in a young man aged about twenty-five, involving neck, shoulders, and upper part of the arms, of eight days' duration. The vesicles are small and numerous, some not going beyond the papulovesicular stage, and closely grouped and coalescent; some hemorrhagic.

recent years there has been a growing belief that the disease, sometimes at least, is of infectious origin, which I believe must be accepted as probable.

Pathology.—The pathology of this disease has received considerable study (Bærensprung, Kaposi, Haight, Robinson, Danielssen, Weidner, Wyss, and others). The conclusions, in the main, are that the disease is usually a descending acute neuritis, provoked by various causes, and that the process has its beginning most frequently in the ganglionic system—in the cervical or spinal ganglia—finally reaching the terminal branches with a production of the cutaneous

sively that arsenic can produce zoster; in 557 psoriasis cases taking arsenic, 10 cases of zoster developed, while in 220 cases otherwise treated, zoster was not noted. See also Rasch, "Contributions a l'étude des dermatoses d'origine arsénicale." *Annales*, 1893, p. 150; Méneau, "Dermatoses arsénicales." *ibid.*, 1897, p. 345; Gerhardt, "Ueber bläschenförmige, gruppenweise Hautausschläge nach Arsenvergiftung," *Charité-Annalen*, Berlin, 19. Jahrgang, 1894; Sequeira, *Brit. Jour. Children's Dis.*, April, 1904, records an attack of zoster associated with a generalized bullous eruption, except the face and extremities, from prolonged administration of arsenic; the zoster was in the lumbar region corresponding to Head's first lumbar area on the right side.

phenomena. Investigations (Mackenzie, Head)[1] point to a relationship between the tender areas of visceral disease and the eruptive patches of zoster, the pain fibers of the skin and viscera being in close connection or association.[2] Clinical observation shows that the eruption does not always follow the distribution of one nerve, nor even that of interbranching nerves, and sometimes the eruption lightly overlaps the median line; this is doubtless due, as J. Mackenzie's investigations, and also those of Head and Campbell,[3] show, to some interlocking of nerve-fibers at their origin.[4]

In most cases of zoster the ganglia usually show softening, enlargement, and inflammation, and the nerves are inflamed and thickened. In the traumatic and also in other instances the ganglia are not involved, the peripheral nerves alone being the seat of pathologic changes (Charcot, Weir Mitchell, Pitres and Vaillard, Curschmann and Eisenlohr). It is probable, I think, that future observations and investigations will show that many of the zoster-like eruptions, among which are probably to be placed the recurrent cases, are not examples of true zoster, as already pointedly suggested by Grindon, Hartzell, Duhring, Hay, and others, but that if those due to traumatism and other mechanical irritative causes are eliminated, there will remain the clear-cut typical cases representing a systemic disease of infectious origin. Numerous examples and clinical grounds support this view (Rohé, Erb, Jamieson, Landouzy, Barth, Walther), and it receives further strength from the fact that the disease occasionally is observed in epidemic form (Neligan, Gauthier, Kaposi, Weis, Blaschko).[5] The fact that zoster occurs but once in a lifetime, the

[1] Mackenzie, *Med. Chronicle*, vol. xvi., 1892, p. 293; Head, *Brain*, parts i. and ii., vol. xvi., 1893, p. 129, and (Herpes Zoster) Clifford-Allbutt, *System of Medicine*.

[2] Curtin, "Herpes Zoster and its Relation to Internal Inflammation and Diseases, Especially of the Serous Membranes," *Amer. Jour. Med. Sci.*, cxciii., 1902, p. 264, reports cases having a clinical bearing on this point; 10 cases associated with various diseases, as pleuritis, peritonitis, Bright's disease, appendicitis, and esophageal cancer. In this connection it is interesting to note that Riehl, *Münch. med. Wochenschr.*, 1904, p. 1105, states that in 481 cases of croupous pneumonia in the Munich Hospital in from 30 to 40 per cent. herpes zoster occurred, generally appearing on the third or fourth day, and most commonly in the areas supplied with the second and third divisions of the trigeminus, especially that supplied by the infra-orbital nerve; it had no prognostic significance; and it is scarcely ever encountered in the pneumonia of children and old people; see also paper on similar subject by Howard, *Amer. Jour. Med. Sci.*, vol. cxxv., 1903, p. 256.

[3] Head and Campbell, *The Pathology of Herpes Zoster and its Bearing on Sensory Localization*, *Brain*, 1900, vol. xxiii., p. 333 (with illustrations).

[4] James Mackenzie, "Herpes Zoster and the Limb Plexuses of Nerves," *Jour. of Path. and Bacteriol.*, vol. i., 1893, p. 332.

[5] Some literature bearing upon its infectious and epidemic character: Walther, *Allg. med. Central-Zeitung*, vol. xlvii., 1878, p. 394, an observation of 12 to 15 cases (all students) in three months—no other cases in a period of nine months; in one series especially reported, a student, after having had an attack, moved from his dwelling; another later moving in developed the disease; circumstances requiring this student to leave, the next student taking the same quarters shortly after presented an outbreak. Kaposi, *Wien. med. Wochenschr.*, 1889, pp. 962 and 1002 (an epidemic of 40 cases); Weis, *Archiv*, vol. xxii., 1890, p. 609 (epidemic of 15 cases and some literature references); Erb, *Neurologisches Centralblatt*, vol. i., 1882, p. 529 (2 instances in which mother and daughter developed the disease at about the same time); Pfeiffer. *Die Verbreitung des Herpes Zoster längs der Hautgebiete der Arteries*, Jena, 1889 (based upon 117 cases); also refers to its epidemic and infectious character, and refers to cases; Barth, *Union médicale*, vol. xxxvi., 1883, p. 809; Rohé, *Arch. Derm.*, 1877, p. 318; Landouzy, *Semaine médicale*, Sept., 1883; Hay, *loc. cit.*; Wasielewski, *Herpes Zoster und dessen Einreihung unter die Infections-Krankheiten*, Jena, 1892. Sachs (epidemic in Breslau, 69 cases), *Zeitschr. für Heilk.*, 1904, p. 383.

usually associated adenopathy, and not infrequently observable systemic disturbance, though slight, are, as Hay states, in favor of the infectious character of the disease. Exceptionally, it is true, recurrences have been noted (Kaposi, Behrend, Düring, Nieden, Pernet, Crocker, Hartzell, Grindon, and others),[1] but it is not improbable, as Hartzell intimates, that many such cases are of traumatic origin. It seems, indeed, that anything which may bring about an irritable or inflamed state of the Gasserian ganglion, spinal ganglia, nerve-tract, or peripheral branches may be responsible for the eruption. This requisite nerve irritation may also be produced by pressure of tumors (Eisenlohr and Curschmann). The disease has also been observed to occur in myelitis (Hardy, Weidner), hemiplegia (Duncan, Payne), and in tapes (Westphal, Bernhardt).

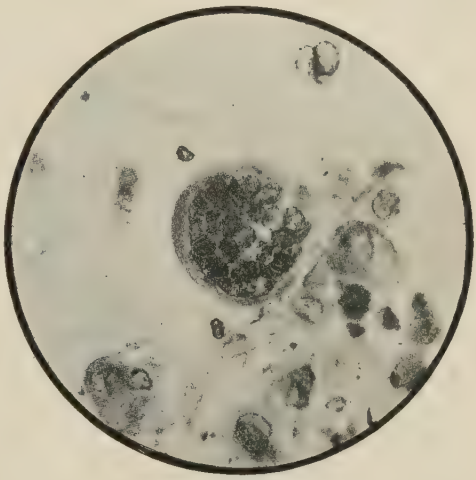

FIG. 79.—Herpes zoster; degenerated epithelial, protozoa-like cells found at the sides and base of vesicle; one resembling a sporocyst (courtesy of Dr. M. B. Hartzell).

The lesions show (Biesiadecki, Haight, Robinson, Lesser, Kopp, Lassar, Hartzell, Gilchrist, Unna) some differences from the vesicles of other diseases. The process begins in the lower rete layer, and apparently in the papillary layer, but the inflammatory involvement of this latter is thought to be secondary. The epithelial cells, through

[1] Grindon, "Recurrent Zoster," *Jour. Cutan. Dis.*, 1895, pp. 191 and 252, gives an admirable analysis of recorded cases—61 in all. It shows that most of such cases cannot be considered as examples of true zoster; a good bibliography is appended. Vörner, "Uber wiederauftretenden Herpes Zoster, im besonderen über Zoster erythematosus und Zoster vegetans," *Münch. med. Wochenschr.*, 1904, p. 1734, reports 3 cases of 3 recurrences in the same region; nervus auricularis magnus; nervus frontalis; zoster buccalis. In one instance the relapses were of erythematosus patches (zoster erythematosus recidivus); and in the case of zoster buccalis in one relapse the lesions were of a vegetating character (zoster vegetans). See also paper, "Du zona récidivant," by Hirtz and Salomon, *Bull. et mém. soc. d. Hôp. de Paris*, 1902, 35, vol. xix., p. 206; and Fabre, "Les recidives du zona," *Bull. Acad. de méd.*, 3d S., vol. xlix., p. 589, and *Bull. méd.*, 1903, vol. xvii., p. 376; Einis, "Ueber Herpes Zoster recidivus," *Allg. med. Centr.-Ztg.*, 1904, vol. lxxiii., p. 313; Duhring believes (*Cutaneous Medicine*, part ii., p. 482) that these anomalous, neurotraumatic cases should be classed distinct from zoster, and suggests the name "dermatitis vesiculosa neurotraumatica," an example of which he recently reported (*Internat. Med. Mag.*, March, 1892). Spitzer, "Ein Fall von recidivirendem Herpes Zoster am Zeigefinger der linken Hand," *Dermatolog. Centralbl.*, 1904, vol. viii., p. 74, reports a case in point—there were 5 recurrences in a year in the district of the musculus radiobrachialis on the index finger, with, at the same time, a tenderness of the forearm, with a distinct hyperæsthesia of the surface corresponding to the ramifications of the radial nerve; tactile, pain, and thermic senses much more intense than on the sound side. Grindon (supplementary paper), *Jour. Missouri State Med. Assoc.*, 1906, No. 8.

colliquation, undergo enlargement,—ballooning (Unna),—and finally, from pressure and traction, assume various shapes. Some of the degenerating cells are thinned or flattened out, and small cavities result; soon these division walls break, and the complete vesicle is produced. The base of the lesion may be a thin layer of the smaller ballooned epithelial cells or the papillæ, which latter may project slightly into the cavity; the roof-wall is formed of the corneous layer, to which may be attached some of the degenerate epithelia. The contents of the lesion consist of serum, epithelial cells, and later some or many pus-corpuscles, and, in the hemorrhagic cases, blood-corpuscles. In more especially these latter cases the upper and sometimes the entire corium undergoes degenerative and destructive action, and ulceration and consequent scarring result. Some of the peculiar epithelial cells found resemble protozoa, but their alleged parasitic character (Pfeiffer) has been disproved, as they have been shown to be degenerated or altered epithelia (Török, Hartzell, and Gilchrist).[1]

Diagnosis.—The usual features of herpes zoster—the frequently prodromal or accompanying neuralgic pain, the grouped vesicles on inflammatory patches following the peripheral distribution of one or two nerves, and exhibiting no tendency to spontaneous rupture, and the limitation to one side of the body—are quite characteristic and render the diagnosis a matter of no difficulty. On the face it might be confounded with an extensive herpes facialis, but in this latter the one-sided distribution of zoster is usually wanting, likewise the neuralgic pain; the distribution on or about the lips, common in herpes facialis, is infrequent in zoster. But it must be confessed that occasional cases are encountered in this region which are somewhat puzzling and which could apparently be placed under either head.

In those instances in which there may be but two or three patches, and in which the lesions are small and abortive, scarcely, if at all, reaching the vesicular stage, a slight resemblance to papular or vesicopapular eczema is noted. Eczema, however, rarely consists of distinct or such sharply defined patches or areas, and is slow in its advent, course, and disappearance, and the subjective symptom of troublesome itching, almost invariable in eczema, is usually wanting in zoster. While abortive zoster is abortive as regards the lesions, it possesses the other features of the disease, as named above. The beginning symptoms—pain and neuralgia—of zoster pectoralis have, sometimes been mistaken for incipient pleurisy, and such error should, therefore, be guarded against.

Prognosis.—This is almost invariably favorable, the symptoms usually disappearing in two to four weeks. In extensive cases, and in those in which new outcroppings present for several days or more, however, the duration is prolonged to one or two months; and in hemorrhagic and ulcerative cases, especially in old people, in whom these types are commonly seen, while the termination is, as a rule, favorable, a fatal ending through exhaustion or septic conditions is possible. In zoster involving the eye the outlook is not always certain, as uselessness or destruction of this organ may ensue, and

[1] Pfeiffer, *Monatshefte*, vol. vi., 1887, p. 589; Török (quoted in Brooke's Hamburg letter), *Brit. Jour. Derm.*, 1890, p. 120; Hartzell, *Jour. Cutan. Dis.*, 1894, p. 369; Gilchrist, *Johns Hopkins Hospital Reports*, vol. i., 1896, p. 365.

exceptionally septic infection, meningitis, and death. The possibility of persistent neuralgia or other sensory and rarely motor disturbances following the eruption is to be kept in view. It is to be said, however, that in a large number of the cases observed the disease is benign, and the patients go about and suffer but little inconvenience.

Treatment.—The mild cases rarely require any constitutional treatment. In those more severe systemic remedies should always be prescribed, the character of the treatment depending, for the most part, upon the indications presented by the individual patient. The chief remedies prescribed, independently of general principles, are those directed toward invigorating the nervous system. Zinc phosphid, $\frac{1}{5}$ grain (0.013) (Thomson, Bulkley) every three or four hours, seems at times to be of service. In other cases large doses of quinin and strychnin will be found to be useful; arsenic is also thought to be of service. Zinc phosphid and quinin prescribed together has seemed to me beneficial and a good routine practice. In cases in which pain is an urgent symptom, it may be necessary to prescribe potassium bromid, chloral, sulfonal, and even morphin; in extreme instances of this character the hypodermic administration of the last-named drug will be demanded. Antipyrin, phenacetin, and acetanilid may also be used for this purpose, and these several drugs, it has been alleged, not only relieve the pain, but may favorably influence the disease. Jarisch speaks well of the conjoint administration of 7 or 8 grains (0.465–0.53) each of antipyrin and sodium salicylate, three or four times daily. Lassar commends highly full doses of sodium salicylate.

External applications are of importance in all except the extremely mild and abortive cases; these latter usually require but little, if any, treatment. The lesions rarely need to be opened. As a rule, the sole object in view in the use of local applications is protection to the parts. This may be accomplished in mild or average cases by the free use of a dusting-powder of equal parts of zinc oxid, boric acid, and talc, over which may be placed a layer of cotton thoroughly drenched with the same powder; this is kept in place by a gauze bandage. This is to be changed daily or every few days, without disturbing the parts unless soiled or offensive, in which event washing with saturated solution of boric acid is advisable; this is, however, rarely required. In mild cases but one or two renewals of the dressing are necessary. A wet dressing of carbolized alcohol (Leloir), 0.5 to 1 per cent. strength, or one to several grains of menthol to the ounce of alcohol, may be used; this is applied on compresses and covered with gutta-percha tissue, and renewed several times daily. In other cases ointments seem to give the most comfort, such as zinc oxid ointment, with 1 or 2 drams (4.–8.) of starch to the ounce (32.), and to which also in painful cases may be added from 5 to 20 grains (0.32–1.3) of opium, or from 15 to 20 grains (1.–1.3) of menthol to each ounce (32.). Such a dressing need be changed but once or, at most, twice daily. Fabre commends, for allaying the pain, painting over the areas a mixed solution of 1 per cent. adrenalin and $2\frac{1}{2}$ per cent. cocain. A valuable method of treatment consists in the application, five to ten minutes daily, or twice daily, of a mild galvanic (constant) current, 1 to 3 milliampères,

the positive electrode being placed as near as possible to the main nerve-supply of the part, and the negative being gently moved to and fro over the diseased area; it favorably influences the pain and seems to modify the course of the disease. For the pain that sometimes follows in the wake of the disease the galvanic current also often gives prompt relief.

HYDROA VACCINIFORME.

Synonyms.—Recurrent summer eruption (Hutchinson); Hydroa puerorum (Unna); Hydroa æstivale.

Definition.—A recurrent, usually vesicular, scarring summer eruption, beginning in early life, almost always in males, and, as a rule, disappearing toward adult age.

This rare disease[1] was first clearly described by Bazin, later by Hutchinson, Handford, Jamieson, Brooke, Crocker, Bowen, White, and others, and while in some of the reported cases there are minor divergences, they all present vesicles, usually pronounced, and with central depression, but sometimes papules with slight vesicular capping, and are followed by slight scarring.

Symptoms.—The eruption is entirely or for the most part on uncovered regions, especially the nose, cheeks, and ears, although exceptionally it may be sparsely scattered over the general surface. It is in almost all cases of vesicular nature, and an outbreak may be preceded by arthritic or other systemic symptoms of slight character. The lesions often begin with a preceding feeling of burning of the part, as discrete or grouped red spots or elevations on which a vesicle or small bulla develops; many show a surrounding red areola. As a rule, subjective symptoms are, however, slight or entirely wanting; rarely there may be some itching. The lesions are variable as to size, from that of a pin-head to a pea; at first with clear contents; later milky and sometimes seropurulent. In a number of the vesicles, and in some cases in most or all of them, there occurs a slight sinking in or umbilication in the central portion, drying here to a thin reddish or blackish crust, while the periphery consists of a surrounding wall of fluid, which may extend slightly, resembling somewhat a small vaccine vesicle, finally crusting. Others dry up evenly and become crusted, and others again may rupture

[1] Literature: Bowen, *Jour. Cutan. Dis.*, 1894, p. 89 (a good review of the subject, histologic examination, with cut; and with literature references to cases of Bazin, Hutchinson, Handford, Jamieson, Berliner, Buri, Broes van Dort, Brooke, Boeck, Crocker; and also a comparison with some of the reported cases of acne necrotica, acne varioliformis); Unna (hydroa puerorum), *Monatshefte*, vol. ix., 1889, p. 108 (questionable cases); Jarisch, *Verhandl. des V. Cong. Deutsch. dermat. Gesell.*, 1895; Colcott Fox, *Brit. Jour. Derm.*, 1894, p. 236; 1897, p. 476; 1898, p. 409; 1899, p. 464; Graham, *Jour. Cutan. Dis.*, 1896, p. 41 (good review of subject); Mibelli, *Giorn. ital.*, 1896, fasc. vi., p. 690 (histologic examination)—abstract in *Annales*, 1897, p. 672; J. C. White, *Jour. Cutan. Dis.*, 1898, p. 514; McCall Anderson (2 brothers), *Brit. Jour. Derm.*, 1898, p. 1; Crocker, *ibid.*, 1900, p. 39; Adamson, "On Cases of Hydroa Æstivale of Mild Type: Their Relationship with Hutchinson's 'Summer Prurigo' and with 'Hydroa Vacciniforme' of Bazin," *Brit. Jour. Derm.*, 1906, p. 125 (5 cases, histologic cut, review, and full bibliography).

accidentally or spontaneously and slowly crust over. Frequently two or three closely grouped lesions coalesce and form a flattened, irregularly outlined, somewhat large bleb. The crusts, which have usually formed in three or four days from the first appearance of the lesions, may be yellowish to a red color; they drop off after a variable period, usually several days or a week or more, disclosing a red, pit-like permanent scar, which in the course of time becomes white.

The process in some spots may halt at the erythematous stage and disappear without trace. The fresh outbreaks may take place almost continuously, or the attack last two to four weeks, to recur again upon moderate or prolonged exposure to sun or wind; or the disease go on indefinitely, at least up to youth or manhood, when the tendency subsides. Numerous scars and, in some cases, a good deal of cicatricial disfigurement of the nose and ears remain as permanent factors, as in cases reported by McCall Anderson and J. C. White.

In some cases (*summer prurigo*), similar or somewhat allied, the eruption may consist of conic papules of a pale-red color, and with, in some, a disposition to minute central vesiculation; in disappearing they, in most instances, leave insignificant scars. Itching is usually a feature, although not always present. It is in many respects similar to the vacciniforme eruption just described, except that the lesions are more distinctly papular, with less tendency to group; and it is apt to be more extensively distributed.

Etiology and Pathology.—The disease is rare, and begins, with few exceptions, in the first several years of life, and is occasionally seen in two members of the same family. It is an eruption in which exposure to the sun and the wind is an important, if not essential, etiologic factor. It is, therefore, as a rule, a disease of the summer, the outbreaks usually disappearing toward cool weather; in some instances, however, attacks occur during the cold season as well. It recurs the following year, and so continues, becoming less active as puberty is approached, and disappearing when adult age is reached. Exceptionally it has been observed to begin later in life, and to continue to a later age. In a few cases (McCall Anderson's) the urine during the outbreak of the efflorescences was noted to be dark wine-colored, and to contain hematoporphyrin. It is seen almost exclusively in boys. It has some features in common with erythema bullosum and dermatitis herpetiformis, and, in some cases, to a slight extent with acne varioliformis.

The pathologic anatomy, studied by Bowen, Mibelli, Adamson, and others, shows that the process is an inflammatory one, beginning in the rete and upper corium, with sometimes distinct edema and cellular infiltration of the papillary layer, resulting in vesicle formation in the rete and subsequent circumscribed necrosis extending deeply in the derma and sometimes into the subcutaneous tissue.

Diagnosis.—Its occurrence solely or most severely in summer, usually in boys and in early life, the distribution, characters, and course of the lesions, with scars usually following, and its repeated recurrence are diagnostic features; scars do not form in erythema bullosum or in dermatitis herpetiformis, besides differing in some of the other characters named.

Prognosis and Treatment.—The patient can usually be made more comfortable by proper measures, and the attacks less active and frequent by avoidance of the sun, heat, and wind, but so far the approach to adult age seems the only factor which stays the disease. As the chemical rays of the sun may be of some causative influence, the wearing of orange or red or dark-colored veils, as has been suggested, can be tried. Treatment is to be mild in character, and is essentially the same as used in other vesicular and bullous diseases.

POMPHOLYX.

Synonyms.—Cheiropompholyx (Hutchinson); Dysidrosis (Tilbury Fox); *Fr.*, Dysidrose.

Definition.—A rare acute inflammatory affection of vesicular and bullous character, limited to the hands and feet, more especially the palmar and plantar aspects.[1]

FIG. 80.—Pompholyx in an adult of forty, of a few weeks' duration; recurrent.

Symptoms.—The most common sites of the disease are the palms and lateral surfaces of the fingers, occasionally extending on to the dorsal surface. Not infrequently the soles of the feet are involved also. Exceptionally it may be limited to the latter region. It is generally symmetric. The eruption is usually foreshadowed by slight burning of the part; soon small, somewhat deep-seated vesicles

[1] Principal literature: Tilbury Fox, *Amer. Jour. of Syph. and Derm.*, vol. iv., 1873, p. 1; Hutchinson, *Illustrations of Clinical Surgery*, vol. i., 1876, p. 49; Robinson, *Arch. Derm.*, 1877, p. 289; Fox and Crocker, *Trans. London Patholog. Soc'y*, vol. xxix, 1878, p. 264; Hoggan (G. and F. E.), *Monatshefte*, 1883, pp. 110 and 148, with full bibliography to date; Unna, *Histopathologie*, p. 176 (based chiefly upon the investigations by Williams and by Santi in Unna's laboratory); Williams, *Brit. Jour. Derm.*, 1891, p. 303; Santi, *Monatshefte*, vol. xv., 1892, p. 93 (with references).

are seen, usually close together, which enlarge, and which in appearance may often be readily likened to boiled sago grains. The parts are reddened, and sometimes swollen. The lesions vary somewhat in size between a pin-head and a large bean. As a rule, new vesicles continue to arise for several days or a few weeks, some of the older small ones becoming milky and disappearing by absorption; or some becoming larger, the contents milky and later purulent. When closely crowded, the result is coalescence, and the formation of large flat blebs or an undermining of the upper skin with serous exudation. The smaller lesions show little if any tendency to spontaneous rupture; the larger blebs are usually accidentally broken, discharge their contents, and disclose the reddened corium or lower rete layer, with no underlying thickening. Gradually the process declines and complete recovery ensues, generally in the course of a few weeks to a few months. All grades of the disease are met with, from that in which

FIG. 81.—Pompholyx, showing vesicle (*e*) formed in the upper two-thirds of the rete (*c*), breaking through the stratum lucidum (*b*), with the covering corneous layer (*a*), between the strata of which are seen lacunæ caused by escaped sweat or from transudation from the papillæ. The vesicle contains at first clear serum, from the underlying papillary blood-vessels, which later, from the invasion of leukocytes, becomes opaque. The papillæ are slightly edematous, and the upper part of the corium (*d*) shows slight inflammatory changes with perivascular cell-infiltration (courtesy of Dr. A. R. Robinson).

the lesions are somewhat scanty, superficial, or deep-seated, to that in which not only the entire palmar aspect of the hands is involved, but a great part of the dorsal surface as well, together with the soles of the feet.

In some instances the eruption will present on one or both the palms but several pin-head to pea-sized lesions, which enlarge slightly, two or three may become confluent, the contents of all in the course of a few days becoming purulent; there is a slight inflammatory areola surrounding the lesions, one or two may be absorbed, or they are broken, especially the larger ones, and the covering exfoliates, the skin soon regaining its normal condition. An abortive type is sometimes observed on the lateral aspects of the fingers.

The subjective symptoms are usually burning and a feeling of tension; itching is rarely a marked feature. There is no constitutional disturbance, although the patient's health, especially in the extensive cases, is noted to be below the normal.

Etiology and Pathology.—The disease is most common in those between advanced adolescence and middle age; it is scarcely seen in children, and not often in old age. It is a somewhat rare disease. It is observed, as a rule, in those whose health is below par, and especially in those lacking nervous strength. In such patients, after one attack, every decided departure from the normal standard, through worry, fatigue, or exhaustion, is apt to be followed by an outbreak, slight or severe in character. It has been noted in many of the patients that the feet and hands sweat freely. It is much more frequent in women.

The tendency of the lesions to group and its usually symmetric character, and its occurrence in neurotic subjects, would properly lead to the belief that the disease is a neurosis. Unna states that he has constantly found in the vesicle sections made in his laboratory by Santi and Williams a bacillus, resembling the tubercle bacillus, but thicker, which he considers the essential pathogenic factor.

Its supposed connection with the sweat-gland gave the name of dysidrosis (Tilbury Fox, Crocker), but later and confirmed investigations (Robinson, Hutchinson, Thin, Unna, Williams, and Santi) show no special association with these structures, but indicate that it is an inflammatory disease in which the lesions take their origin in the rete, the fluid, which is at first pure serum, coming from the papillary blood-vessels, and collecting between the rete cells.[1] The effusion gives rise to degeneration of some of these cells, and the others are gradually pushed asunder to give room for the fluid collection. The upper cells may rupture, and some serum also escape into the corneous layers. The lesions later become purulent from the addition of pus-corpuscles, and contain some fibrin and a large amount of albumin; the contents are never acid. They never contain sweat. The inflammatory changes are slight.

Diagnosis.—The beginning deep-seated lesions, their increase in size, and usually in number, some coalescing and forming blebs, and gradually becoming purulent, together with localization of the eruption, make a pretty clear picture of the malady, and usually render the diagnosis a matter of no difficulty. It is to be distinguished from acute eczema, which, however, it can scarcely be said to resemble greatly; but in this latter disease the lesions are small, are markedly acute, in great numbers, crowded together, with usually considerable inflammatory action and some infiltration; tend to rupture spontaneously, and leave the characteristic oozing surface of eczema; the dorsal surfaces of the hands and fingers are also, as a rule, involved, whereas in pompholyx these parts are rarely affected to a great extent, and frequently not at all. There are, however, mild cases of both disorders, the slight type of pompholyx, with small and scanty lesions, and subacute eczema of limited character which sometimes approach each other in appearance; the boiled-sago-grain character is usually characteristic of pompholyx, but it is not an absolute factor, as some of the deep-seated lesions of eczema on the fingers at times show a similar appearance.

[1] Nestorowsky (*Dermatolog. Zeitsch.*, Mar., 1906, *et seq.*—abs. in *Jour. Cutan. Dis.*, 1906, p. 491), from histologic examination of many specimens, calls this in question—he considers it a disease of the sweat-glands and the vesicles as closely connected with their ducts.

It is also to be distinguished from rhus poison, but the markedly acute and inflammatory character of this latter, and the fact that it usually involves other parts, and a history of exposure, and its course are different from the symptoms of pompholyx.

Prognosis.—The prognosis for the immediate attack of pompholyx is favorable, as the disease subsides spontaneously in the course of several weeks or one or two months; and its duration and course, especially in severe cases, may be modified or shortened by appropriate treatment. As to future freedom, the prospect is uncertain, recurrences at irregular intervals being not infrequent; if a good state of health is maintained and overfatigue and nervous exhaustion guarded against, fresh outbreaks rarely present themselves.

Treatment.—In the management of the disease the condition of health must be looked after, tonics having an invigorating effect upon the nervous tone, and nutrition being especially indicated. Hence quinin, iron, strychnin, arsenic, and cod-liver oil are the remedies commonly prescribed, more especially arsenic in moderate doses and strychnin in tolerably full doses. Cod-liver oil and iron are often extremely useful in debilitated subjects with frequent recurrences. The digestion should receive attention, and constipation be corrected. A mild saline purge in the beginning of an attack is often of service. A generous diet should also be advised.

The external treatment has mainly in view the protection of the parts. Soothing applications such as are employed in acute eczema are the most satisfactory. Strong and stimulating remedies have no place in the treatment of the disease, and aggravation would follow their use. Mention may be made of applications of lead-water and laudanum, boric acid solution, zinc oxid ointment containing a dram (4.) of calamin to the ounce (32.), salicylic acid paste, and diachylon ointment. The last named and the following are useful in those cases in which a distinctly sedative ointment is indicated:

℞.	Menthol.,	gr. ij (0.133);
	Acidi salicylici,	gr. x (0.65);
	Emplastri plumbi,	
	Emplastri saponis,	āā ʒiss (0.6);
	Petrolati,	ʒv (20.). M.

This should be spread thickly upon lint or other suitable material and kept constantly applied as a plaster; or ceratum plumbi subacetatis similarly applied is also of value in such cases. In fact, whatever ointment is prescribed, it should be employed in this manner, the effect being much more decided than is obtained by simply smearing it on. If lotions are used, the parts should be first thoroughly dabbed therewith, and then linen cloths or patent lint wet in the solution applied and kept wet with it. The conjoint use of a lotion and an ointment, first dabbing on the lotion, allowing it to dry on, and then applying the ointment in the manner described, is an efficient method of treatment.

The parts should be gently cleansed once daily with warm water, and every few days by dipping for a few minutes in a basin of warm water with one-fourth to one-half teaspoonful of sodium bicarbonate dissolved therein.

DERMATITIS HERPETIFORMIS.[1]

Synonyms.—Hydroa bulleux (Bazin); Hydroa herpetiforme (Tilbury Fox); Duhring's disease; Dermatitis multiformis (Piffard); Herpes gestationis; Pemphigus pruriginosus; Herpes circinatus bullosus (Wilson); Pemphigus circinatus (Rayer); Herpes phlyctænodes (Gilbert); Pemphigus prurigineux (Chausit, Hardy); Pemphigus composé (Devergie); Dermatite polymorphe, Dermatite herpetiforme (Brocq).

Definition.—Dermatitis herpetiformis is a rare inflammatory disease, with or without slight or grave systemic disturbance, characterized by an eruption of an erythematous, papular, vesicular, pustular, bullous, or mixed type, with a decided tendency toward grouping, accompanied usually by intense itching and burning sensations, with more or less consequent pigmentation, and pursuing a persistent, chronic course with exacerbations.

Symptoms.—The onset and the exacerbations may or may not be preceded for a few days by symptoms of general disturbance, such as malaise, loss of appetite, constipation, chilliness, flushings, and heat sensations, rise of temperature, and often the subjective symptom of itching. During the first several days of the cutaneous outbreak such symptoms may in greater or less degree continue; and in the more severe and extensive types of the disease, especially in the pustular and bullous varieties, the constitutional symptoms may be of a graver character and more or less persistent. Cases in which the general symptoms give rise to anxiety are, however, it must be said, infrequent; and in most instances are entirely wanting or extremely slight.

The eruption may be erythematous, papular, vesicular, bullous, pustular, or mixed; it is never ulcerative. Very rarely purpuric lesions are intermingled or follow in the pigment stains from the vesicles and blebs, and the latter lesions are exceptionally slightly hemorrhagic (Brocq, Tenneson, Hallopeau, Leredde, Perrin). The vesicular variety is the most common. In some cases the same type with which the eruption begins may persist or be preponderant throughout the course of the malady; there is in many, however, a distinct tendency to change from one to another, in some cases completely, in others, partially. The onset of the outbreak may be sudden, or it may be preceded for several days or weeks by slight cutaneous irritation, such as itching, one or several insignificant erythematous patches, groups of vesicles, or urticarial lesions; or the first lesions are all of one variety. When fully developed, the eruption may cover almost the entire surface; or it may be more or less limited in extent, involving a greater part or the

[1] Most of Professor Duhring's papers, establishing a fixed place in classification for this disease, have been republished in *Selected Monographs on Dermatology*, issued by New Sydenham Society, London, 1893, pp. 179–297. A most excellent French exposition of the subject, with numerous literature references and brief recital of most published cases, is that by Brocq, entitled "De la dermatite herpétiforme de Duhring," *Annales*, 1888, pp. 1, 65, 133, 209, 305, 434, and 493. A graphic and succinct description of the disease read by Jamieson before the London Dermatological Society, and the discussion thereon, present the English views of the subject, *Brit. Jour. Derm.*, 1898, pp. 73 and 118. As one of the earliest contributions must be mentioned the suggestive and elaborate paper by Tilbury Fox, "Clinical Study of Hydroa," *Arch. Derm.*, 1880, p. 16 (a posthumous paper, edited, with notes, by Colcott Fox).

PLATE XII.

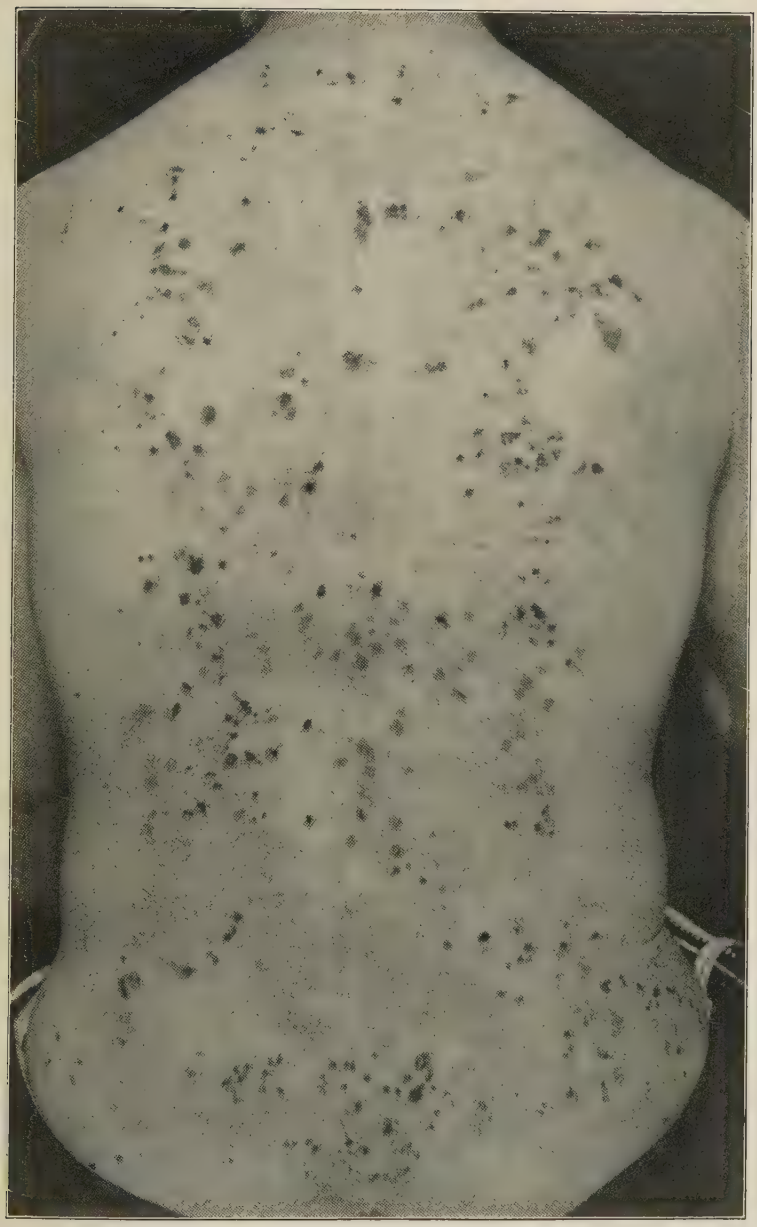

Dermatitis herpetiformis of the vesicular and papulovesicular variety in a male adult aged forty, of about five years' duration; shows the herpetic grouping of the lesions.

entire trunk; or the trunk may be but slightly invaded, and the limbs, especially the legs, bear the brunt. It is, in short, in every way, both as regards violence and extent, variable—slight or severe, limited or extensive. Itching is usually a constant and a most troublesome feature; pigmentation sooner or later is noted in most cases. After several days or weeks of violent activity the disease tends to become, slowly or rapidly, less active, and a period of comparative comfort and freedom of uncertain duration is passed. These remissions or intermissions are irregular and capricious; in some instances scarcely one violent outbreak is in full development when another equally active and extensive follows, and this may continue in rapid succession for several months or longer before a period of comparative or complete quiescence intervenes.

The vesicles, pustules, and blebs, especially the vesicles and blebs, are somewhat peculiar as to shape; they are, or many of them at least, usually of a strikingly irregular outline, oblong, stellate, quadrate, semilunar, or rarely ring-shaped, distended, or flaccid, and when drying are apt to have a puckered appearance. They are herpetic, in that they show little disposition to spontaneous rupture; occur mostly in groups of two, three, or more, and not infrequently are seated upon erythematous or inflammatory skin. Occasionally some of the lesions, especially in the graver cases, contain a slight admixture of blood. They may disappear by absorption, or, if ruptured or broken, leave abrasions which may secrete for a short time and dry up; or they may dry to crusts which fall off, the sites being marked by erythematous spots, which in turn fade or leave behind slight pigmentation. In size the vesicles are rarely smaller than a pin-head, and are usually the size of small peas. The blebs may be almost any dimension from a pea to a hen's egg, and may arise as a single lesion from sound or erythematous or erythematopapular skin, or may have their origin in the confluence of several closely contiguous vesicles or small blebs. Scattered pustules may be large, but more commonly all are small in size, resembling in this respect vesicular lesions; they often begin as pustules, or may have their origin in vesicles. The mucous membrane of the mouth, throat, nose, and eyes is in some instances—more especially the bullous cases—involved, and in exceptional cases the mucous membrane of the trachea and the larger bronchial tubes also.

The erythematous type lesions are similar to those of a generalized erythema multiforme, and it could be very aptly designated a chronic form of that affection, except that at times it is noted to change completely into one of the other varieties; urticarial lesions are now and then interspersed. It is sometimes a beginning type; quite often it appears as a break of short or long duration between active vesicular or bullous outbreaks; and not infrequently it is the type permanently assumed after the violent character of the disease has disappeared.

In children the element of multiformity is often wholly lacking, the eruption being of a vesicular and bullous character without admixture of other types.

Etiology.—The disease is rare, but not so rare as formerly thought. It is met with in both sexes and almost all ages. It is

most frequent during the period of active adult life, although it is exceptionally seen in the very young (one aged three—Pringle; one aged four—Bowen).[1] In some cases there is found nothing of import in the previous or present condition of the patient's health to explain the cutaneous phenomena; in fact, in some the general health seems undisturbed. Still, enough is known to indicate that the disease is essentially neurotic, for in other instances—in a large number, in fact—it manifests itself after severe mental strain, emotion, and nervous shock, as frequently recorded (Tilbury Fox, Duhring, Elliot, Devergie, Crocker, Vidal, Tenneson, Brocq, and others). Its connection with the nervous system is also shown by the cases in which pregnancy is the factor, the malady often disappearing in the interim, of which many examples are on record (Milton, Bulkley, Liveing, W. G. Smith, Duhring, White, Perrin, and others). The possible reflex origin in some instances is shown in the case of a child reported (Roussel) in which phimosis was apparently the factor, a cure resulting after circumcision. Nephritic disease has been associated or recorded as an etiologic factor, as shown by glycosuria (Winfield) and albuminuria (Wickham, Abraham). According to Besnier, there is always scantiness of urine, with diminution of urea and uric acid.[2] Physical or nervous breakdown, exposure to cold, and septicemia have been apparently etiologic in some of my cases. Cases apparently septic in origin have also been reported by others (Sherwell, Kerr, and others). That some septic or otherwise toxic agent is sometimes responsible for dermatitis herpetiformis (or at least a similar or allied condition, showing often a combination of the symptomatology of erythema multiforme, herpes, and pemphigus, and resembling dermatitis herpetiformis), seems shown by the occasional examples following vaccination, as observed by Dyer, Pusey, Bowen, myself, and others.[3] In some instances general debility and debilitating influences may rightly be considered as responsible, in part at least, for a continuance of the disease. On the other hand, striking amelioration has been noted[4] by a physician in his own case during attacks of malarial fever and other intercurrent disorders.

[1] Hallé, *Arch. de méd. d. enfant*, 1904, vol. vii., p. 385, reviews the character, etc., of the disease in children, of which he has seen 5 cases; Bowen, *Jour. Cutan. Dis.*, 1905, p. 79 (Soc'y Trans.), reports 2 cases—in a girl aged four, and a boy aged six; in the discussion several other cases in young children were referred to—in one under three, and in a few instances following vaccination; Meynet and Péhn, *Annales*, 1903, p. 893, in reporting a case in a child, give a résumé of previously reported cases in children, with references; Gottheil, *Arch. Pediat.*, June, 1901, reports 2 cases in children—in one aged nine, beginning when aged four.

[2] Engman, *Jour. Cutan. Dis.*, 1906, p. 216, reports upon the constant presence of indican in the urine, and these amounts seemed to have relationship with the eosinophilia; Loth and Grindon have also noted the presence of indican.

[3] Dyer, *New Orleans Med. and Surg. Jour.*, vol. xxiv., 1896–97, p. 211; Pusey, *Jour. Cutan. Dis.*, 1897, p. 158—the early history of this case was reported by Becker, *Tri-State Med. Jour.*, May, 1893; Bowen, "Six Cases of Bullous Eruption Following Vaccination," *Jour. Cutan. Dis.*, 1901, p. 401 (in children between the ages of five and ten, and appearing within from one to four weeks after vaccination, and lasting for months and years); Stelwagon, "Vaccinal Eruptions," *Jour. Amer. Med. Assoc.*, Nov. 22, 1902; Bowen, *Jour. Cutan. Dis.*, 1904, p. 265, refers to several other cases, and 2 similar cases not following vaccination; and *ibid.*, 1905, p. 381, in a complete paper, "Dermatitis Herpetiformis in Children," reviews these and additional cases in children—15 in all.

[4] "Dermatitis Herpetiformis: A Personal Experience of the Disease," *Brit. Jour. Derm.*, 1877, p. 97, and 1896, p. 282.

PLATE XIII.

Dermatitis herpetiformis; erythematovesicular and pustular varieties in combination. Woman, middle age. Eruption more or less generalized (courtesy of Dr. Louis A. Duhring).

PLATE XIV.

Dermatitis herpetiformis; vesicobullous variety. Irregular bullous lesions, resembling those of erythema multiforme bullosum. Eruption general. Patient, a woman (courtesy of Dr. Louis A. Duhring).

Pathology.[1]—Recent studies (Elliot, Leredde and Perrin, Unna, Gilchrist) indicate that the process, inflammatory in character, has

FIG. 82.—Dermatitis herpetiformis, vesicular variety (× about 35): V_1 and V_2, Show small vesicles; *E*, epidermis unchanged, lifted up by the exudation; *S*, *S*, sweat-gland and duct; *G*, sebaceous gland. The contents of vesicles consist of fibrin, coagulated albumin, polynuclear leukocytes, and, at the bottom, eosinophiles. Glandular structures not involved. Upper half of corium shows acute inflammatory process, with much fibrin (courtesy of Dr. T. C. Gilchrist).

its beginning in the upper corium—in the papillary layer, or in the deep epidermic layers; and the resulting vesicle, forming beneath the epidermis, gradually or quickly enlarges and works upward, the epidermis being secondarily involved. In the corium are noted variable edema, dilatation of the vessels, and cell-masses of usually lymphocytes, occasionally of plasma-cells. Eosinophiles are found both in the corium and epiderm, and are present usually in large numbers in the vesicles and blebs, and also in the blood (Leredde, Brown). In the dilated vessels are to be seen, in addition to the red blood-corpuscles, polynuclear leukocytes; in the larger vessels, eosinophiles in scanty number. The lesions contain a fibrinous network, in the meshes of which are found polynuclear leukocytes in large numbers, some mononuclear and epithelial cells, eosinophile cells, as already stated, and coagulated albumin. The pustules are probably due to an added superficial infection from without. Leredde

[1] Pathologic anatomy: Elliot, *New York Med. Jour.*, 1887, vol. i., p. 449; Leredde et Perrin, *Annales*, 1895, pp. 281 and 452; Gilchrist, *Johns Hopkins Hosp. Reports*, vol. i., 1896, p. 365.

Regarding eosinophilia: Leredde et Perrin, *Annales*, 1895, pp. 281, 369, and 452; Darier, *ibid.*, 1896, p. 842; Leredde, *ibid.*, p. 846, 1899, p. 355, and (also anatomy), *Gazette des Hôpitaux*, March 26, 1898; Funk, *Monatshefte*, 1893, vol. xvii., p. 266; Brown, *Jour. Amer. Med. Assoc.*, Feb. 17, 1900; Bushnell and Williams, *Brit. Jour. Derm.*, 1906, p. 177 (diminished phagocytic power of the eosinophile cells).

strongly believes that the excretion of eosinophile cells by the skin to be an essential part of the cutaneous phenomena, and together with the eosinophile cells in the blood are characteristic of this disease—a view shared, in part at least, by others (Hallopeau, Lafitte, Danlos). It is now known, however, that eosinophile cells are found in lesions of other bullous diseases.

Diagnosis.—At various periods in its course a case of dermatitis herpetiformis may resemble slightly or even strikingly erythema multiforme and pemphigus; and not infrequently, indeed, the clinical picture may be for a time closely similar or even the same as one of these diseases, and without knowledge of its former history and course a mistake could be readily made. Several factors need to be kept in mind in the diagnosis as being more or less distinguishing: Chronicity, with or without remissions or short or long intermissions; multiformity, tendency toward grouping, disposition to change of type, itchiness, with sooner or later slight or marked pigmentation.

It is distinguished from erythema multiforme by the fact that this latter is an acute disease running a course of ten days to several weeks, and is unaccompanied by intense itching; moreover, its distribution is rarely as irregular or general as that of dermatitis herpetiformis. The vesicles and bullæ—herpes iris, erythema bullosum—which are occasionally seen in erythema multiforme have their origin in preexisting erythematous lesions; while this also happens in dermatitis herpetiformis, some of the vesicles and bullæ will be found to arise from apparently healthy skin. In doubtful cases an observation of several days or, at the most, a few weeks, would lead to a correct conclusion.

Pemphigus differs from the bullous type of dermatitis herpetiformis in that the lesions of the former are usually larger and show no special tendency to occur in groups or to assume irregular, angular, or multiform shapes; the pemphigus blebs, moreover, appear, as a rule, from sound skin, and the disease lacks the small vesicles and vesicular groups and occasional small pustules and pustular groups usually found intermingled in the bullous eruption of dermatitis herpetiformis. In pemphigus itching is wanting or slight, whereas in dermatitis herpetiformis it is one of the most troublesome symptoms. The reported cases of "pemphigus pruriginosus" are, doubtless, in many instances at least, examples of dermatitis herpetiformis. Pemphigus with itching as a symptom may be distinguished by the differential points already given, especially when considered in connection with the known capriciousness of type in dermatitis herpetiformis. The constitutional symptoms of pemphigus are often quite marked—much more so, as a rule, than observed in dermatitis herpetiformis.

The characters of dermatitis herpetiformis are so different from urticaria and eczema that a mistake is scarcely possible. In urticaria the lesions are all wheals, there is no tendency to special grouping, and it is usually acute and evanescent; bullous lesions in urticaria are uncommon, and when present, spring from wheals and are associated with other characteristic wheals. In eczema the papules and vesicles are much smaller, and the eruption is rarely generally distributed.

PLATE XV.

Dermatitis herpetiformis (?) sometimes met with in children, and also observed developing after vaccination; neck, axillary, genitocrural, popliteal, and elbow-flexure regions seem favored; vesicobullous and herpes iris type; patient aged eleven; two years' duration, with periods of comparative quiescence.

Prognosis.—As to relief, much, as a rule, may be promised, but as to cure or permanent freedom from outbreaks the prognosis cannot be too cautiously guarded. It is not to be forgotten that dermatitis herpetiformis is a particularly persistent and chronic disease, capricious in its behavior and course, and rebellious to treatment. Permanent recovery is to be considered rather exceptional; there is, however, a tendency in most cases to become less active. Those showing a prevailing tendency to the erythematous form, and the vesicular expression of the disease occurring in connection with pregnancy or the parturient state (herpes gestationis) are the more favorable varieties. The disease in children seems much less rebellious, and recovery is not uncommon. The pustular and bullous types are sometimes of a serious character. A fatal ending is possible in the grave cases, especially in those associated with septicemia. It must be conceded, however, that dermatitis herpetiformis usually persists for years without compromising life, and that in many of the patients the general health, considering the violence of the eruptive phenomena, remains comparatively undisturbed.

Treatment.—Although the etiology of dermatitis herpetiformis is obscure, it is, in most cases at least, to be looked upon as of neurotic nature. The most successful treatment, therefore, is one that keeps in view the avoidance or correction of any factor detrimental or disturbing to the nervous equilibrium, and which also aims to bring about a healthy and more vigorous nervous tone. The mode of living, the diet, the state of the digestion, and the condition of the various internal organs, more especially the liver and kidneys, should be investigated. The diet should be generous, but plain and nutritious; coffee and tea, except in very moderate quantity, should be avoided, likewise all indigestible foods. Alcoholic stimulants are usually damaging. Occasionally a purely milk diet, or with meat once daily, has a favorable influence. Upon the whole, constitutional treatment is based upon general principles. Irrespective, however, of what may be indicated by suspected etiologic conditions, three remedies need special mention—arsenic, quinin, and strychnin in moderately full or large doses. Arsenic, according to my own observation and those of others (Jamieson, Roberts, Mackenzie), stands first in value; in small doses, it is often valuable as a tonic, but in some instances, especially of the vesicular and bullous types, pushed to the point of tolerance, it will be found of distinct service; after it fails to do further good, it can be stopped, and then later resumed. In other cases it seems to do harm. In persons of depressed general nutrition cod-liver oil is a remedy of value. Alkalies and diuretics are sometimes of service. Phenacetin (Morris, Pringle) or acetanilid will occasionally favorably influence the itching. In severe cases narcotics are necessary to procure sleep, but are to be avoided if possible. A saline purge often has a favorable influence in mitigating the severity of an attack; the bowels should always be kept free. General galvanization and static insulation are measures which may be of service.

Regarding the external treatment, it will be found that, as a rule, lotions of an antipruritic character will give the most relief. Blebs, if

present, should be opened and evacuated. In some cases weak alkaline and bran and gelatin baths are comforting. Liquor carbonis detergens, 1 or 2 teaspoonfuls to a small teacupful of water, will often be serviceable for controlling the pruritus; if well borne, and if the weaker strengths afford no relief, this preparation may be used in stronger proportion, often up to the pure solution. Ichthyol, in an aqueous lotion, from 2 to 10 per cent. in strength, is also of value. Resorcin, from a 1 to a 5 per cent. solution; carbolic acid, from 1 to 3 drams (4.–12.) to the pint (500.) of water, with boric acid to saturation; liquor picis alkalinus, from 1 to 3 drams (4.–12.) to the pint (500.) of water, applied cautiously—are all of value in some cases and at different times in the same case. These may be often advantageously supplemented by bland dusting-powders or by the mild ointments, such as that of zinc oxid, cold cream, and the petroleum ointments, plain or carbolized or with from 1 to 10 grains (0.065–0.65) of menthol to the ounce (32.). At times the washes are not well borne; then the ointments already named and the other mild ointments used in eczema may be employed alone with greater benefit. An ointment of value is one made up of from 1 to 2 drams (4.–8.) of liquor carbonis detergens to the ounce (32.) of simple cerate. Sulphur ointment in the vesicular and vesicobullous and pustular varieties of the disease, rubbing it in vigorously so as to break down the lesions, is sometimes serviceable (Duhring, Mackenzie), but it is a strong application, and must be tried cautiously. Lassar commends tar baths and tar-and-sulphur ointment as of considerable curative value.

PEMPHIGUS.

Synonyms.—Fr., Pemphigus; *Ger.*, Pemphigus; Blasenausschlag.

Definition.—Pemphigus is an acute or chronic bullous disease, characterized by the formation of scanty or numerous irregularly scattered, variously sized, rounded or oval blebs, arising from apparently normal or moderately reddened skin, and which may or may not be accompanied by mild or severe constitutional disturbance.

Numerous so-called varieties of this rare and as yet obscure disease have been described, based chiefly upon the duration, age of the patient, and the clinical characters and behavior of the eruption. The division is in many respects purely arbitrary. The whole subject of pemphigus is, in fact, at present chaotic, and it is a matter of difficulty even to the trained dermatologist to know what to include and what not to include under this head. Many of the cases formerly considered in this class, and still so considered by some German writers, have been gathered together to form the group constituting the dermatitis herpetiformis of Duhring.[1]

The presence of a bleb or blebs does not, however, as often considered by many physicians, constitute a pemphigus, as such lesions

[1] Recent papers on the classification of bullous diseases by Bowen and by Bronson, with discussion, are to be found in the *Trans. Amer. Derm. Assoc.* for 1905, and *Jour. Cutan. Dis.*, 1906, pp. 110–127, and by Corlett, *ibid.*, 1906, p. 464 (an analysis of 65 bullous cases).

are often seen as an accidental or unusual manifestation in other diseases, such, for example, in urticaria (urticaria bullosa), erythema multiforme (erythema bullosum), dermatitis herpetiformis, just referred to, pompholyx, dermatitis venenata, leprosy, and some others. On the contrary, pemphigus is a malady in which the lesions consist, primarily at least, of distinct watery rounded blebs, of more or less general distribution, without ring or other peculiar formation or special tendency to group, and appearing irregularly or in successive crops, and, as a rule, running a chronic course, with exacerbations. The subjective symptoms usually consist of tenderness, soreness, and burning, and less frequently itching.

The varieties of pemphigus can be described under the heads of pemphigus acutus, pemphigus chronicus, pemphigus foliaceus, and pemphigus vegetans. The terms "benignus," "malignus," "gangrænosus," "hæmorrhagicus," etc., sometimes added to pemphigus, are self-explanatory.

Symptoms.—Pemphigus Acutus.[1]—Acute pemphigus includes all those cases in which the course is more or less limited, and the termination, within several weeks or a few months, in recovery or death. Its occurrence has been denied, but occasional observations, now considerable in number (Damon, Rayer, Cazenave, Neumann, Allen, Payne, Behrend, Shillitoe, Roach, Van Harlingen, and others), leave no doubt as to its existence. It is, however, rare, and seen for the most part in children of early age, although it is also exceptionally seen in the adult. It is occasionally observed (Hardy) in young girls between the period of puberty and full sexual maturity with menstrual difficulties (so-called pemphigus virginum). In its clear type (**blister fever, febris bullosa, pemphigus febrilis**) the eruption usually comes out suddenly, with premonitory symptoms of malaise, slight or severe febrile action, chilliness or rigors, and other evidence of mild or grave systemic disturbance. The lesions are variously sized from that of a pea to that of a pigeon's egg or

[1] Some literature on acute pemphigus: Pernet and Bulloch, "Acute Pemphigus: A Contribution to the Etiology of the Bullous Eruptions," *Brit. Jour. Derm.*, 1896, pp. 157 and 205. This admirable paper refers to the various acute types, especially to that in adults due to infection from animals or their products. The subject is presented in its clinical, etiologic, bacteriologic, and histopathologic aspects—with numerous literature references. The reader is referred to this paper for many references made in my own text, especially as to bacteriologic findings. Hadley and Bulloch, *Lancet*, May 6, 1899 (fatal case in butcher, starting in finger injury); Ravogli, *Cincinnati Lancet-Clinic*, April 27, 1889, p. 481; Schamberg, *Annals of Gynecology and Pediatry*, Feb., 1901, p. 321 (fatal case, apparently due to vaccination); Whipham, *Lancet*, 1896, i., p. 1219 (2 cases; arsenical treatment, 1 death, 1 recovery; with some bacteriologic experiments by S. R. Wells); Robinson, *Manual of Dermatology*, p. 234; Rose, *Montreal Med. Jour.*, Jan., 1899, p. 50 (in the course of a fatal case of alcoholic delirium). Caie, *Brit. Med. Jour.*, 1903, vol. i., p. 308, a case of acute malignant pemphigus, ending fatally in 12 days; the patient, a male adult, worked among cattle, and shortly before the eruption had pricked his hand while washing sheep. Howe, "Cases of Bullous Dermatitis Following Vaccination," *Jour. Cutan. Dis.*, 1903, p. 254 (with several case illustrations; a series of 10 cases, all, except 1, occurring in those recently vaccinated; 6 of these cases died). Bowen, "Acute Infectious Pemphigus in a Butcher, During an Epizootic of Foot and Mouth Disease, with a Consideration of the Possible Relationship of the Two Affections," *Jour. Cutan. Dis.*, 1904, p. 253 (reviews the subject of acute pemphigus, especially as to its possible origin from animal sources, and gives a résumé of reported cases, with references). Saundby, *Lancet*, Oct. 1, 1904, reports a case of acute pemphigus in a butcher's apprentice.

larger, are generally quite abundant, and irregularly distributed over the surface; they are distended or somewhat flattened, come out at one time or in rapid succession or in distinct crops, and, as a rule, arise from skin showing no preliminary change; sometimes, however, from a slightly hyperemic surface. Some are usually surrounded by a narrow red halo. Generally clear at first, they often become milky and opaque, sometimes hemorrhagic, and exceptionally gangrenous. In other instances the eruption is unaccompanied by pronounced constitutional involvement, and in others the febrile action and other systemic symptoms of varied nature continue for the first week or two, until subsidence of the cutaneous phenomena sets in; in such instances complete recovery usually takes place in several weeks to one or two months.

In some of the febrile cases grave symptoms present or continue

FIG. 83.—Pemphigus in a negress aged thirty-one, of two months' duration, showing the fresh, tense, and older flaccid blebs on upper arm; eruption general. Irregular febrile disturbance, but otherwise patient's health seemed good.

to increase in severity, the throat and mouth show serious involvement, the blebs become flaccid and puriform, and exceptionally the underlying surface, gangrenous (Lenhartz), and death follows in one to several weeks. In some instances the disease, after the more acute outbreaks have subsided, gradually becomes less active, the lesions are less numerous, and it goes into the chronic form.

The blebs disappear, sometimes partly by absorption, with desiccation and crusting, or sometimes purely by desiccation and crusting, with or without previous accidental or spontaneous rupture; when the crust falls off, slight temporary redness or staining is noted, but there is no permanent trace left.

The acute type is usually observed as isolated cases, but it has, or a disease simulating it, been observed (Colrat, Köhler, Bernstein, and others) to occur in epidemic form (**pemphigus epidemicus, pemphigus**

contagiosus); in some instances with but slight constitutional symptoms or entirely free from such, and in others moderately active and occasionally severe. These doubtless are similar to the contagious or infectious cases observed in the newborn—pemphigus neonatorum—to be referred to. It is highly probable that many of the reported epidemic and contagious cases are examples of impetigo contagiosa and bullous varicella. The benign pemphigus contagiosus described by Manson as quite common in the tropics is probably a variety of impetigo contagiosa; it is usually diffused in children, but in adults chiefly about the axillary and genito-crural regions, and in the latter sometimes developing into "dhobie itch."

Pemphigus Acutus Neonatorum[1] (Pemphigus neonatorum; Pemphigus neonatorum contagiosus; Pemphigus epidemicus; Pemphigus contagiosus).—The cases usually included under this subheading of acute pemphigus are believed to represent a distinct pemphigus type, and are those observed a few days after birth, many of which run

[1] Literature bearing upon pemphigus neonatorum, pemphigus epidemicus, and pemphigus contagiosus: Staub, "Ueber den Pemphigus der neugeborenen und der Wöcherinnen," *Bericht des II. Internat. Dermatolog. Congress*, 1892, p. 699; Strelitz, "Bacteriologische Untersuchungen über den Pemphigus neonatorum," *Archiv für Kinderheilkunde*, vol. xi., 1890, p. 7; and vol. xv., 1893, p. 101; Peter, "Zur Aetiologie des Pemphigus neonatorum," *Berlin. klin. Wochenschr.*, 1896, p. 124 (in infant suckled by septicemic mother); Zechmeister, "Ueber Pemphigus neonatorum," *Münchener med. Wochenschr.*, 1887, p. 737—abs. in *Archiv*, 1888, p. 271 (in 76 births under charge of one midwife 28 cases developed, of which 6 were fatal); Wichmann, "Epidemie von Pemphigus Contagiosus," *Tidsskrift für praktisk Medicin*, 1887, No. 21—abs. in *Archiv*, 1888, p. 423 (in the new-born; 23 cases, of which 3 died—all the children born under the care of the same midwife); Jükovsky, "Pemphigus neonatorum," *Vratch*, No. 15, 1891, p. 357—abs. in *Brit. Jour. Derm.*, 1891, p. 368 (12 infants, of which 4 died—all born under care of same midwife); Kilham, "An Epidemic of Pemphigus Neonatorum," *Amer. Jour. of Obstet.*, 1889, p. 1039 (12 cases, all mild; bacteriologic examination negative); Homolle, "Epidemic of Acute Pemphigus in the New-born," *Gazette Hebdom.*, Nov. 13, 1874—abs. in *Arch. Derm.*, 1875, p. 154 (among 79 births but few escaped; the disease was mild, but 1 case ending fatally; inoculation experiments negative); Corlett, *Indiana Med. Jour.*, Nov., 1893, p. 158; Moldenhauer, "Ein Beitrag zur Lehre vom Pemphigus acutus," *Archiv für Gynäkol.*, vol. vi., 1874, p. 369 (101 cases observed in a period of about a year—mild, and distribution, character, and behavior indicate that they were cases of impetigo contagiosa); Klemm, "Zur Kenntniss des Pemphigus contagiosus," *Deutsches Archiv für klin. Medicin*, vol. ix., 1871, p. 199 (28 cases are reported, and a study of which leaves but little doubt that they were examples of impetigo contagiosa); Faber, "Ueber den acuten contagiösen Pemphigus," *Monatshefte*, vol. x., 1890, p. 253 (an analytic paper of reported cases, indicating the probability that many were impetigo contagiosa); Greer, "Puerperal Septicemia and Pemphigus Neonatorum," *Brit. Med. Jour.*, 1894, i., p. 1241; Holt, "Pemphigus Neonatorum" (1 case associated with general infection with staphylococcus pyogenes; death), *N. Y. Med. Jour.*, 1898, i., p. 175; Solbrig, "Pemphigus neonatorum," *Zeitschrift für Med.-Beamte*, vol. xiii., 1900, p. 41; Kœhler, "Ueber die Diagnose und Pathogenese akuter Blasenbildung der Haut nebst kasuistischem Beitrag zur 'Febris bullosa'" (small epidemic of 7 cases, 1 of which died), *Deutsches Archiv für klin. Medicin*, 1899, vol. lxii., p. 579; Bernstein, "Ein Beitrag zur Kenntniss des Pemphigus neonatorum acutus" (5 cases, infants and adult; somewhat suggestive of impetigo contagiosa, although the reporter excludes this, and experimental inoculations were negative), *Monatshefte*, vol. xxviii., 1899, p. 19; Bloch, "Pemphigus neonatorum," *Archiv für Kinderheilk.*, vol. xxviii., 1900, p. 61 (an observation of 20 cases, some fatal; clinical, anatomic, and bacteriologic aspects are presented); Knocker, "Pemphigus neonatorum" (2 cases, mild in type; had been delivered and looked after by the same nurse), *Brit. Jour. Derm.*, 1898, p. 195; Beck, "Aetiologie des Pemphigus neonatorum" (1 case—death; cocci, usually paired, found in lesions and blood)—abs. in *Monatshefte*, 1899, vol. xxviii., p. 410; Windisch, "Pemphigus Contagiosus Tropicus," *Jour. Amer. Med. Assoc.*, vol. xxxiv., 1900, p. 77; Munro, "Pemphigus Contagiosus (tropicus)," *Brit. Med. Jour.*, Apr. 29, 1899, p. 1021; Finlay, "Pemphigus Contagiosus Tropicus," *Austral. Med. Gaz.*, 1898, p. 114; Brosin, "Pem-

a rapid, mild course. It is probable that almost all, as Richter's analytic study seems to indicate, could be viewed as a variant type of bullous impetigo contagiosa. Bloch distinguishes two forms, the grave type, which sometimes resembles pemphigus foliaceus and Ritter's disease, and a mild or benign form. The mild type, of which a number of instances have been recorded (Olshausen and Mekus, Ravogli, Corlett, Kilham, Padosa, Crocker, Knocker, and others), is usually entirely free from systemic disturbance, is of acute onset, apparently contagious and infectious, and is seen in the newborn, usually in the first several days of life. The lesions are, as a rule, not very numerous, and while they may be seated upon any part, are observed most frequently or abundantly about the lower trunk and thighs. The eruption may, however, be quite extensive and of general distribution. A favorable termination is reached in the course of a few weeks.

On the other hand, cases are reported (Tilbury Fox, Staub, Peter, Greer, Moldenhauer, Klemm, Brosin, and others) of severe and grave characters. The eruption may be somewhat sparse or abundant, and there is accompanying febrile action as observed in ordinary acute pemphigus cases already described, with septic symptoms; or there may be practically absence of fever, and yet the cases terminate fatally (Brosin).

Pemphigus Chronicus.—Under chronic pemphigus belong most of the cases usually met with, and to which the name of pemphigus vulgaris is also applicable. It is, like other varieties, rare, and especially in this country. Its chief distinction from the others is that the blebs continue to appear incessantly, the skin being, as a rule, never free. On the other hand, there may be shorter or longer intervals of comparative or complete freedom. The lesions appear irregularly, one or several at a time, or there are distinct crop-like exacerbations, the blebs appearing in numbers. Probably most commonly they make their appearance in numbers for several days or more; these subside, crust over, and disappear, during which time and for a few weeks or longer scattered lesions, in scanty number, arise, and then another moderate or extensive outbreak manifests itself, and so the malady continues indefinitely. The mouth and throat in occasional cases are also noted to exhibit the eruption, and exceptionally the disease may have its beginning in these parts. In rare instances the conjunctivæ (pemphigus conjunctivæ) are also invaded, and some-

phigusübertragungen im Wirkungskreise einzelner Hebammen" (2 epidemics; in a total of 64 confinements 18 cases, 7 of which died), *Zeitschrift für Geburtshülfe und Gynäkologie*, 1899, vol. xl., p. 418; P. Richter, "Ueber Pemphigus neonatorum," *Dermatolog. Zeitschr.*, vol. viii., 1901, Nos. 5 and 6, reviews most thoroughly the whole subject (over 100 pages, with 20 pages of references); he concludes that the dermatitis exfoliativa neonatorum of Ritter, is a variety, and that pemphigus neonatorum also bears a relation to impetigo contagiosa, the characters of the newborn skin being responsible for the clinical differences; it is due to the presence of a staphylococcus of a doubtful nature, with a group, more malignant, infected with streptococci or mixed staphylococci and streptococci. G. J. Maguire, "Acute Contagious Pemphigus in the Newborn," *Brit. Jour. Derm.*, 1903, p. 427 (indicative of its identity or allied nature to bullous impetigo contagiosa); Adamson, "Pemphigus Neonatorum in the Light of Recent Research," *ibid.*, p. 447 (conclusion as to its being an infantile form of impetigo contagiosa); Crary, "A Case of Acute Septic Pemphigus," *Jour. Cutan. Dis.*, 1906, p. 14 (with review and bibliog.).

times accompanied by shrinking of the parts (von Graefe, Morris and Roberts, Fuchs, and others).[1] The blebs are usually well distended, pea- to small egg-sized, scattered, or often close together, several occasionally coalescing, although there is but little tendency to grouping. A slight admixture of blood is sometimes noted, and in exceptional cases this may be quite decided (**pemphigus hæmorrhagicus**). An individual lesion, as in the other varieties, runs its course, and crusts over in several days to two weeks. No permanent trace is left by the eruption, but on areas frequently covered with recurrent lesions slight pigmentation may show itself. In the mild cases there are no constitutional symptoms; in others chilliness and febrile action preceding or accompanying the original outbreak, subsiding and again presenting at the time of the exacerbations; in still others of the more extensive type the systemic disturbance is more or less continuous. The subjective symptoms of burning, soreness, and itching (**pemphigus pruriginosus**) may be present in variable degree; itching is rarely troublesome and often absent. The disease may finally end in recovery or terminate fatally, its course being usually long and indeterminate.

Pemphigus Foliaceus.[2]—This variety, which is extremely rare, may assume its peculiar features from the start or it may develop from an acute or chronic pemphigus of the ordinary character; in other instances it has begun as a superficial generalized cutaneous edema (Quinquaud), as a scaly greasy surface (Besnier), as a dermatitis her-

[1] Morris and Roberts, "Pemphigus of the Skin and Mucous Membrane of the Mouth, Associated with 'Essential Shrinking' and Pemphigus of the Conjunctivæ," *Brit. Jour. Derm.*, 1889, p. 176, and *Monatshefte*, vol. viii., 1889, p. 437 (a report of a case, with colored plate, and a tabulation and references of 28 previously reported cases). Meneau, *Jour. mal. Cutan.*, Jan., 1905, gives an extensive review of different forms of pemphigus as involving the mucous membrane, especially of the conjunctiva, nose, mouth, throat, and larynx (with complete bibliography). Cocks, *Jour Amer. Med. Assoc.*, Nov. 24. 1906, p. 1736, records a fatal case in which the eruption was limited to the mucous membranes.

[2] Literature of pemphigus foliaceus: Nikolsky, "Contribution a la question du pemphigus foliacé de Cazenave," *Thèse de doctorat*, Kieff, 1896 (refers cases of Cazenave, Plieninger, Bazin, Guibout, Meyer, Munro and Swarts, Sormani, Besnier (2 cases), Hallopeau and Fournier (3 cases), Petrini (3 cases), Regensburger, and Dumesnil de Rochemont —17 cases in all); Lausac, "Du pemphigus foliacé mixte primitif," *Thèse de doctorat*, Toulouse, 1898 (reports 1 case and refers to 28 cases previously observed by others—brief abs. of his own case and conclusions in *Annales*, 1898, p. 1040; Biddle, "Pemphigus foliaceus or Dermatitis herpetiformis," *Jour. Cutan. Dis.*, 1897, p. 203; Sherwell (1 case, with photo), *Arch. Derm.*, 1877, p. 97, and (same case—recovery and relapse) *Jour. Cutan. Dis.*, 1889, p. 453; Graham (1 case), *Canadian Jour. Med. Sci.*, June, 1879; Hardaway (1 case), *Jour. Cutan. Dis.*, 1890, p. 22; Munro and Swarts's case (*ibid.*, 1891, pp. 332 and 423), already named in Nikolsky's paper, seems to partake of the nature of both pemphigus foliaceus and pemphigus vegetans; Klotz (1 case), *Amer. Jour. Med. Sci.*, Dec., 1891; Nasarow (1 case), *Dermatolog. Zeitschr.*, vol. vi., 1899, p. 719; Nazaroff (1 case), *Roussky Archiev Patologgi*, Feb., 1900—abs. in *Brit. Jour. Derm.*, 1900, p. 258; Hellier (1 case—infant (pemphigus neonatorum?), *Brit. Jour. Derm.*, 1899, p. 18; Savine (1 case), *Jour. de méd. mil. russe*, July, 1897; abs. in *Annales*, 1898, p. 597; Hallopeau et Constensoux (1 case with associated osteomalacia), *Annales*, 1898, p. 979; Lindstroem (3 cases), *ibid.*, 1898, p. 1026; Leredde, "Étude sur le pemphigus foliacé de Cazenave," *ibid.*, 1899, p. 601 (a study of pathology and pathologic anatomy, with some literature references); Fabry, *Archiv*, June, 1904, p. 183 (1 case, beginning with redness and scaling, showing at first a suggestive resemblance to pityriasis rosea and eczema marginatum, subsequently developing into pemphigus foliaceus); Brousse and Bruc, *Annales*, 1905, p. 853 (1 case; began with an erythematous eruption, intense general itching, followed by bleb formation, which became generalized, and in a month had developed into the exfoliative type; autopsy report and 1 clinical and 1 histologic illustration).

petiformis (Hallopeau and Fournier). It is characterized by the formation of blebs so rapidly and so quickly repeated that the distended bulla is not seen. It is flat and but slightly raised, and is scarcely dried to a crust before another flaccid lesion forms beneath. Or the blebs appear, but instead of being distended and elevated, are flaccid and flat, become purulent, break or are accidentally ruptured, and then a gradual undermining of the surrounding epidermis is noted. The eruption is usually abundant and generally distributed, and may, indeed, involve almost the entire surface. In the latter instances a picture is presented of extremely flaccid, scarcely elevated, seropurulent or purulent variously sized blebs, with the fluid bulging them out at the most dependent portion; ruptured lesions with a serous or seropurulent undermining of the immediate surrounding epidermis; thin crusts with rapidly forming exudation beneath, and large red, raw, oozing surfaces where the crusts have been removed or rubbed off, and where the exudation is so rapid that a new crust cannot form. Exceptionally the surface remains, temporarily at least, almost dry, the condition resembling dermatitis exfoliativa. Fissuring occurs, especially about the joints, and there is a pervading foul odor about the patient. In extreme cases the nails and hair are brittle and sometimes shed, the eyes are sore-looking, the conjunctivæ may become involved, the mucous membranes share in the disease, and with increasing gravity of the constitutional symptoms, and, in a majority of the cases, the patient finally succumbs from exhaustion, pyemia, or from some intercurrent disease. Exceptionally there are long intervals of freedom (Sherwell). The malady is rare, but there has been a gradual addition to the number of reported cases since the disease was first described (Cazenave, 1850); in this country but several cases have been observed (Sherwell, Graham, Hardaway, Klotz, Munro and Swarts).

Pemphigus Vegetans.[1]—This variety, also called erythema bullosum

[1] Literature of pemphigus vegetans: Crocker, "Pemphigus vegetans (Neumann)," *Brit. Med. Jour.*, Mch. 16, 1889, and *London Med.-Chirur. Soc'y Trans.*, vol. lxxii., 1889, p. 233 (a bibliography of cases to date is given); Mapother (1 case), *ibid.* (referred to in the discussion); Müller, *Monatshefte*, vol. xi., 1890, p. 427 (2 cases, with 2 plates presenting 4 histologic cuts; a brief review of 22 other cases from literature, with references, are given); Hyde (1 case), *Jour. Cutan. Dis.*, vol. ix., 1891, pp. 412 and 459; Lowe, *Lancet*, May 23, 1891; Haslund, *Hospitalstidende*, 1891 (quoted by Crocker); Herxheimer (3 cases, "Festschrift der Städtischen Krankenhauses in Frankfurt A. M.," *Archiv*, vol. xxxvi., 1896, p. 141; Köbner (2 cases), *Deutsches Archiv für klin. Medicin*, vol. liii., and vol. lvii., abstracts in *Annales*, 1894, p. 890, and 1897, p. 816; Luithlen, "Pemphigus vulgaris et vegetans," *Archiv*, vol. xl., 1897, p. 682; Tommasoli, *Archiv*, vol. xliv., 1898, p. 325; Neumann, *Wien. klin. Rundschau*, 1900, No. 1, p. 1; Pini, *Giorn. ital.*, 1898, p. 354 (chemical experimental researches)—brief abs. in *Annales*, 1899, p. 505; Phillipson, et Fileti (1 case), *Giorn. ital.*, 1896, p. 354; Ludwig (1 case), *Deutsch. med. Wochenschr.*, 1897, p. 267; Mracek (1 case), abs. in *Annales*, 1898, p. 919; Duhring (1 case), *Cutaneous Medicine*, part ii., p. 456; Zumbusch, "Ueber Zwei Fälle von Pemphigus Vegetans mit Entwicklung von Tumoren," *Archiv*, vol. lxxiii., p. 121, 1904 (mild course with pedunculated papillomatous growths in 1 case; large areas of papillomatous development in 1 case on forearms, leg, and soles of feet. (Dermatitis vegetans (?)); Jamieson and Welsh, *Brit. Jour. Derm.*, 1902, p. 287, and Dyce Duckworth, *ibid.*, 1903, p. 26, and 1904, p. 245 (histologic report by Little, *ibid.*, p. 138), each reports an extensive case—both fatal; Hamburger and Rubel, *Johns Hopkins Hosp. Bull.*, April, 1903, p. 63, report a fatal case, and review the literature; Zumbusch, *Archiv.*, vol. xxliii., 1905 (2 cases with development of tumors, 2 colored plates); Ormsby and Bassoe (an acute fatal case with autopsy), *Jour. Cutan. Dis.*, 1905. p. 294; Ravogli, *ibid.*, 1906, p. 311; Winfield, *ibid.*, 1907, pp. 17 and 71 (with illustration), reports a fatal case with autopsy, and gives a brief analytical review of reported cases with references.

vegetans (Unna), is the rarest of all, and was first described (Neumann) in 1886; since then other cases have been reported (Crocker, Hyde, Haslund, Hutchinson, Riehl, Duhring, and others). The earliest manifestations are usually to be seen in the mouth, throat, or lips, and consist of whitish or reddish plaques; soon the ordinary blebs appear on the integument, and these may at first maintain the character of ordinary pemphigus, but after a while, instead of going through the crusting and disappearance, as usually noted, vesicles or blebs form around a crust; the base of such a patch becomes inflamed, often edematous, covered with a viscid, offensive secretion, and finally exhibits papillomatous or condyloma-like vegetations. Several such plaques become confluent and form large areas. This peculiar development is seen most commonly about warm and moist surfaces in close contact, as about the genital, anal, and axillary regions. With increasing constitutional symptoms which are usually present from the beginning, the disease, with rare exceptions, finally ends fatally. In favorable

FIG. 84.—Dermatitis vegetans (courtesy of Dr. M. B. Hartzell).

cases the process gradually declines; these seem to be chiefly those in which the eruption was scanty and mainly about the mouth (Hutchinson). The malady is sometimes variable in its course, and occasionally presents here and there distinct blebs in which the vegetating tendency is not displayed. Exceptionally there is observed a combination of its own peculiar manifestations with the symptoms of pemphigus foliaceus. There is usually temperature elevation, somewhat variable, it is true, determined by the extent and gravity

of the disease; it is usually more marked at periods of exacerbation of the cutaneous phenomena. On the other hand, the body-heat is noted at times to be below normal.

A malady variously thought to be a modification, or subvariety, of pemphigus vegetans are usually encountered, or as an entirely distinct disease is that described first by Hallopeau,[1] as pyodermatitis vegetans (pyodermite végétante), and subsequently by Hartzell, Jamieson, Fordyce, and Gottheil under the name of **dermatitis vegetans.**[2] Later Wende[3] and Degroat reported 2 cases in children, and briefly reviewed 5 others (2 adults, 3 children) previously recorded, in which the same peculiar vegetations developed upon an eczematous basis.

The cases of Hallopeau, Hartzell, and Jamieson in many respects showed close clinical similarity to pemphigus vegetans (just described), but the serious constitutional element was lacking, and the first eruptive features were, predominantly at least, those of vesicles, vesicopustules, and pustules, and not infrequently grouped as in dermatitis herpetiformis. The vegetating plaques were amenable to antiseptic applications, leaving behind some pigmentation, which finally completely, or almost completely, disappeared. Hallopeau long maintained the individuality of the disease and its non-identity with either pemphigus vegetans or dermatitis herpetiformis; its relationship to the latter being asserted in a report by Wickham,[4] of a case presenting similar vegetating formations, under the name of "Un cas rare de dermatite herpetiforme de Duhring; variété pustuleuse et végétante," and this belief supported in the discussion by Vidal, Besnier, and Brocq. Although this case may be probably accepted as an example of dermatitis vegetans, it showed, as Hartzell states, "that his own case and those of Hallopeau and Wickham, in which there were no blebs, but the eruption distinctly pustular, or vesico-pustular, with a marked tendency to occur in groups, and, in some instances preceded by erythematous patches, to be much more closely allied to dermatitis herpetiformis than to pemphigus"—an opinion which Fordyce and Gottheil believe is also supported by their case. That there are cases, however, in which such features, as well as erythematous rings and gyrate patterns are conjoined with bleb-formation, is shown by the example recorded by Ormerod,[5] concerning which there was some difference of opinion as to its proper place—pemphigus vegetans or dermatitis vegetans, Crocker viewing it as the latter. It is to be said that Hallopeau, receding from his earlier stand, has recently placed the malady as a variety of pemphigus vegetans. Jamieson strongly maintains its in-

[1] Hallopeau, *Archiv*, vol. xliii., 1898, p. 289, and vol. xlv., p. 323, and *Annales*, vol. ix., 1898, p. 969, and also in his treatise (Hallopeau and Leredde), *Dermatologie*, 1900, under Pemphigus Vegetans, or Maladie de Neumann.

[2] Hartzell, *Jour. Cutan. Dis.*, 1901, p. 465 (with illustration of genital region, and histologic cut); Jamieson, *Brit. Med. Jour.*, 1902, p. 407 (with illustration of hand and histologic cuts). Fordyce and Gottheil, *Jour. Cutan. Dis.*, 1906, p. 543 (with case and histologic illustration, review, and bibliography).

[3] Wende and Degroat, "Vegetating Dermatitis Developing during the Course of Infantile Eczema," *Jour. Cutan. Dis.*, 1902, p. 58 (with illustration of face and histologic cuts). Corlett, *Brit. Med. Jour.*, Oct. 6, 1906, has reported a somewhat similar case but developing upon a bromide-like papulo-pustular eruption.

[4] Wickham, *Annales*, 1891, p. 1005.

[5] Ormerod, *Brit. Jour. Derm.*, 1903, p. 26 (case demonstration).

dividuality. The cases reviewed and reported by Wende and Degroat go to show that somewhat similar vegetations, probably from some added infective agent, can also arise on the vesicular, pustular, or oozing surface of such a mild disease as eczema, and seem to point to the possibility that this peculiar vegetative tendency is not necessarily characteristic of any particular malady, but may be simply an accidental or added feature to the several diseases named. Pusey,[1] whose 2 cases of "vegetating dermatoses" are closely similar to those of Hallopeau, Wickham, Hartzell, Jamieson, and Fordyce and Gottheil, and yet apparently arising upon an eczematous basis, also takes this view of the malady. As already intimated, cleanliness and antiseptic applications are usually efficacious in its treatment.

Etiology.—Pemphigus is, fortunately, extremely rare, and much more so in this country than in Europe. It is met with in both sexes, with probably a slight preponderance in females; it is more frequent in infants and children than in adults. The causes are obscure. It is not due to syphilis, although this latter does give rise to a pemphigoid eruption, but one entirely different in its characters, course, and behavior. It is not hereditary; the cases of hereditary tendency to bullous development upon the slightest local irritation belong to epidermolysis bullosa (*q. v.*). It is probable that the several so-called varieties are due to different causes, or at the least the ingrafting of an accidental factor upon the same disease process. Acute pemphigus sometimes has its origin in a septic wound (Pernet and Bulloch, Hadley and Bulloch); from, in infants, a disease of the navel and from puerperal processes in the mother (Staub, Peter, Greer). Pernet and Bulloch's studies, as well as such cases as that reported by Bowen, point strongly toward animals or their products as a frequent source; this may, too, explain the cases following vaccination occasionally, as, for instance, Howe's cases. Bowen calls attention to the similarity of some cases of "foot and mouth disease" in cattle and man to acute pemphigus. Johnston[2] believes we have evidence of the existence of an autotoxic factor in the production of pemphigus and other bullous diseases, a view which, it seems to me, has much in its favor. Other factors which seem to be of moment in the production of the disease are chills (Schwimmer, Crocker), nervous influences, such as peripheral nerve injuries (Mitchell, Morehouse and Keen, Mougeot, Leloir), diseases of central nervous system (Charcot, Balmer, Leloir, Kopp, Schwimmer, Brissaud, and others), degenerative changes in the peripheral nerves and nerve-centers (Déjerine, Quinquaud, Jarisch, Mott and Sangster, and others), functional nervous disturbance, and hysteria—pemphigus hystericus[3] (Kaposi, Hardy, Jarisch, Duhring, and others). Against these evidences must, however, be quoted the observation (Kaposi and Weiss) that in 9 fatal cases, in only 1 was there structural nerve alteration—diffuse sclerosis of cord.

[1] Pusey, *Jour. Cutan. Dis.*, 1906, p. 555 (with case illustrations).

[2] Johnston, *Brit. Med. Jour.*, Oct. 6, 1906.

[3] C. J. White, "Recurrent, Progressive, Bullous Dermatitis in a Hysterical Subject," *Jour. Cutan. Dis.*, 1903, p. 415, reports a curious case of bullous lesions, the outbreak beginning usually on an extremity, and then extending upward, with periods of freedom, and later involvement of other parts (4 other somewhat similar cases in literature are briefly described, with references to these and other papers on allied subjects).

That the derangement, functional or organic, of the nervous system is of etiologic importance is borne out by the cases reported by the writers just referred to, and by the experience of almost all others who have to do with this disease. Whether the action is a direct one or merely contributory to a successful parasitic invasion or infection is an unsolved question. At all events, whatever the rôle of the nervous system may be in the chronic variety, there can scarcely be a doubt that an important etiologic factor in many of the acute cases, and especially those in infants and young children, particularly those of epidemic and contagious character, is to be found in micro-organisms. Such findings have been recorded by a number of observers (Almquist, Escherich, Peter, Luithlen, Gibier, Demme, Sahli, Claessen, Whipham, Holt, Beck, and others), but there has not been sufficient uniformity to warrant positive conclusions, although the majority of observers found, in pemphigus neonatorum,[1] staphylococcus aureus and albus; and some were able to produce the disease by inoculation from lesions (Moldenhauer, Koch, Vidal), and also by inoculation from cultures (Almquist, Strelitz). A diplococcus has been found by several observers in acute pemphigus (Demme, Claessen, Bulloch, Whipham, Beck). Investigations by others in both these directions have, however, not met with the same positive results. The acute cases resulting from septic infection already referred to point likewise to micro-organisms as a cause. The microbic view is also supported by the series of cases of pemphigus neonatorum occurring in infants cared for by the same widwife, an observation repeatedly made (Corlett, Knocker, and several others). It is probable that most of these are examples of bullous impetigo contagiosa, as instances of transference to older members of the family, etc., have occurred, and in whom the lesions are essentially those of this latter disease, a view which is held by most observers (Pontoppidan, Faber, Crocker, Duhring, and many others). Another view of the etiology of pemphigus formerly held was that the malady is due to defective kidney elimination, and occasional acute cases are noted to follow or be associated with organic kidney disease. Urine examinations in most instances, however, disclose nothing. As in other bullous diseases, eosinophilia has been noted (Leredde), and a diminution of the red blood-corpuscles observed (Hallopeau and Leredde, Nikolski).

Pemphigus, especially the acute form, has also been observed to follow rheumatic fever, the exanthemata, diphtheria, and other acute systemic disorders.

Pemphigus vegetans[2] seems, as noted by Hutchinson, Danlos, Brocq, and others, much more common with those who live in the country—2 cases that came under my observation were from country districts.

Pathology.—In connection with pemphigus lesions on the skin organic changes have been noted, as already remarked, in other structures, more especially the nervous system in its various parts, centrally

[1] Both Whitfield (*Brit. Jour. Derm.*, 1903, p. 221) and Macleod (*Brit. Med. Jour.*, 1903, p. 1278) obtained pure cultures of a streptococcus.

[2] Stanziale, *Annales*, 1904, p. 15, found in a case of pemphigus vegetans a diplobacillus (probably identical with the small diplococcus of Waelsch), and a pseudo-diphtheritic bacillus. The latter, he thought, played a rôle in the production of the vegetating lesions. Hamburger and Rubel, *loc. cit.*, also isolated a pseudo-diphtheritic bacillus.

to peripherally,[1] the liver and kidneys have also exhibited disease in some cases. To a great extent, or at least in many instances, the cutaneous manifestations must be considered but a part of a systemic process or infection. This belief is supported by the findings of micro-organisms referred to in etiology.

Pathologic anatomy[2] discloses (Robinson, Crocker, Luithlen, Unna, Gilchrist, Jarisch, and others) that the local changes in the cutaneous lesions are slightly varied, dependent, doubtless, upon the degree of inflammatory action and the stage of formation, although the bleb is more superficial than obtains in herpes. The roof-wall is the upper horny layer, and the base the rete; but in some instances the inside of the roof shows a layer of rete cells, and in others the corium is the floor of the lesion. The bleb is doubtless due to a sudden effusion from the vessels of the corium, probably following paralysis and dilatation of the vessels.[3] In the early stage of its formation, in most lesions, inflammatory signs are slight; in others they are present, usually but to a moderate degree. The papillæ are edematous; dilatation of the vessels, emigration of polynuclear leukocytes, and a variable amount of serous infiltration of the tissues are noted. In pemphigus vegetans are found (Neumann, Riehl, Kaposi, Unna) marked hypertrophy of the papillæ and pronounced proliferation of the rete, with outgrowth of the same; enlargement of the superficial blood-vessels and edema of the upper layers of the corium.

The contents of the lesions are neutral or alkaline in reaction and composed of serum, to which are added later pus-cells, epithelial cells, and fat; ammonia has been found in it, as well as in the urine; phosphorus has also been found and thought to be due to nerve disintegration. An increase of eosinophile cells has, as already stated, in some instances been noted both in the bullæ and in the blood, but as yet no significance can be assigned to this increase, as it is observed in vesicles and bullæ of other maladies and even in those of artificial origin.

Diagnosis.—The disease is to be distinguished from erythema

[1] Jamieson and Welsh, *loc. cit.*, found in a well-marked case of pemphigus vegetans distinct degenerative changes of a special character in the nerve-cells of the spinal cord, and to a less pronounced extent of the sympathetic ganglia, and the cerebral cortex; consisting "of an evidently slowly progressive rarefaction of the chromophile bodies of the protoplasm, more especially in the perinuclear zone, formation of minute vacuoles in the altered portion of the protoplasm, swelling of the cell-body, disintegration of the nucleus, and, finally, destruction of the whole element."

[2] Jarisch, "Zur Anatomie und Pathogenese der Pemphigusblasen," *Archiv*, vol. xliii., 1898, p. 341; Robinson, section, drawing, and description in Duhring's *Cutaneous Medicine*, part ii.; Gilchrist, *ibid.*; Kromayer, *Dermatologische Zeitschrift*, vol. iv., 1897; Kreibich, *Archiv*, 1899, vol. l., pp. 299, 375; Luithlen (Pemphigus vulg. et veg.), *Archiv*, vol. xl., 1897, p. 682, and (Pemphigus neonatorum) *Wien. klin. Wochenschr.*, 1899, p. 69.

[3] According to Weidenfeld's investigations ("Beiträge zur Klinik und Pathogenese des Pemphigus," Vienna, 1904, a monograph based on 18 cases: 9 pemphigus vulgaris, 4 pemphigus serpiginosus, 5 pemphigus foliaceus, and 1 pemphigus vegetans), he found that in some cases of pemphigus, pressure would always provoke a bleb, in other cases pressure had absolutely no influence, while in a third group it was variable—sometimes pressure producing a bleb and sometimes not. In the stages of improvement none could be provoked, but as soon as the general condition (eruption, etc.) showed increase and aggravation, blebs could again be provoked by pressure. The author explains this upon the assumption of a variation or disappearance and reappearance of some noxious material having a damaging influence on the circulatory system.

bullosum, urticaria bullosa, impetigo contagiosa, dermatitis herpetiformis, and the bullous syphiloderm.

In erythema bullosum the blebs are a part of an eruption (erythema multiforme) in which other characteristic features are usually present; even when all the lesions are bullous there is likely to be a circinate or ring-like configuration with some, and the eruption is generally limited to, or more abundant on, certain regions, as the hands and forearms—erythema bullosum never has a general distribution. Moreover, the blebs frequently spring from erythematous or inflammatory skin, and the disease runs a rapid course without, as a rule, any persistent or marked systemic symptoms.

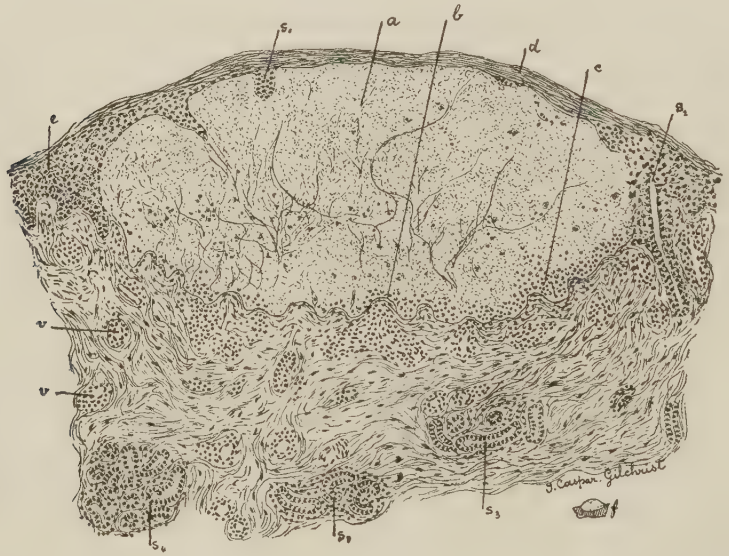

FIG. 85.—Pemphigus—a beginning bleb (*a*) between corium and the epidermis, the bared papillæ (*b*) forming the base; acute inflammatory changes in the papillary layer of the corium, with marked serous exudation, particularly about the vessels; reticular part of the corium and the sweat-glands (s, s_3, s_4, s_5) are practically normal, except where the sweat-ducts (s_1, s_2) are involved in the bleb-formation: *d*, corneous layer; *e*, rete; *v*, *v*, blood-vessels; *c*, cell masses at base; *f*, about the natural size of bleb examined (courtesy of Dr. T. Caspar Gilchrist).

The bullous syphiloderm is usually observed in infants in the first few days or weeks of life; and the lesions are often seen on the palms and soles, parts not commonly involved in pemphigus. Moreover, the syphilitic blebs soon become puriform, form thick crusts, and under which, as a rule, ulceration is noted. In syphilis of this type other characteristic symptoms are always to be found. Pemphigus vegetans bears strong resemblance to the vegetating syphiloderm; in this latter, however, the disease remains more or less limited to the genital region and around the anus, with but little disposition to spread extensively, as is observed in pemphigus. Moreover, in syphilis a positive destructive tendency is sometimes noted, and there is absence of any tendency to bleb-formation, usually seen at some

stage of pemphigus vegetans. The clinical history, the presence or absence of other syphilitic lesions or symptoms, must sometimes be utilized. In pemphigus, too, slight or severe constitutional involvement is usually noted. Pemphigus foliaceus and dermatitis exfoliativa are sometimes confounded, but the dry character in the latter and the absence of mouth involvement and any tendency to bleb-formation are different from what are observed in pemphigus.

Eczema rubrum and pemphigus foliaceus have, in a general way, some resemblance, but the former is never universal, and, indeed, rarely extensive; the crusting of the former is usually less pronounced, the crusts being in small flakes, whereas in pemphigus they are often of considerable size; moreover, blebs are not seen in eczema, and the characters of the general symptoms observed in pemphigus are wanting.

It is scarcely possible to confound the blebs occasionally noted in scabies with pemphigus; in the former there is never present more than a scant number, and the other eruptive lesions, together with the distribution and history, are entirely different from the picture of pemphigus. The differentiation from bullous urticaria, impetigo contagiosa, and dermatitis herpetiformis will be found discussed under those diseases.

Prognosis.—Too much caution cannot be exercised in expressing a positive opinion as to the final outcome. As to acute pemphigus, the character of the outbreak, whether attended by active constitutional symptoms, the behavior of the lesions (whether serous, purulent, hemorrhagic, or gangrenous), the extent of the eruption, the previous and present health of the patient—all have a bearing. Those cases in which more or less grave systemic disturbance presents, and those, usually the same class, in which the lesions become rapidly purulent or are hemorrhagic or gangrenous, are almost always fatal. Involvement of the mucous surfaces is of unfavorable significance.[1] Even slight systemic disturbance, especially chills, has a serious import. The vegetating and foliaceous varieties rarely recover, but they may be of months' or years' duration. The septic types, arising from a wound, are grave. Almost all cases unattended by temperature elevation or other constitutional symptoms get well, although the possibility of changing to a severe type is to be kept in mind. In short, the prognosis for the milder cases is usually favorable; for the extensive and grave eruptions, serious. The prospect in children is much better than in adults.

In chronic cases the same features bear upon the ultimate prognosis: persistence and chronicity are the rule, and relapses are not uncommon.

Treatment.—The treatment includes both constitutional and local remedies. The systemic treatment, which is of essential importance in the grave acute and in the chronic varieties, is, upon the whole, to be based upon general principles, any possible etiologic

[1] According to Weidenfeld, "Beiträge zur Klinik und Pathogenese des Pemphigus," Vienna, 1904, those cases of pemphigus in which the malady begins in the mouth are the gravest.

factor being corrected, modified, or removed, the general health built up, and the digestive tract looked after. In fact a careful study of the whole economy should be made. The patient should have the benefit of good hygienic conditions. There are, however, certain remedies which have acquired deservedly more or less reputation of exerting a specific influence. First in importance is arsenic (Hutchinson, Morris, and others), given in safe but increasing doses up to the point of tolerance. The drug has in some cases a controlling influence, and it is sometimes curative; its use should be persisted in, as it is usually after long administration that its beneficial effects are to be expected; it should also be continued in small doses for some time after the disease has disappeared. Strychnin and large doses of quinin are likewise useful in some instances. These three remedies, arsenic, quinin, and strychnin, probably the most valuable in this malady, can advantageously be prescribed conjointly. Iron in full doses, cod-liver oil, and linseed meal (Sherwell) are also of service in some cases. Opium, especially in the vegetating form (Hutchinson), pilocarpin, and atropin (Crocker), have exceptionally proved of advantage. Change of scene and climate is of distinct value in some instances. The dietary should be generous, but of a plain and substantial character.

Externally applications of a soothing nature are the most grateful. It is a good rule to open and evacuate the blebs as soon as they form, immediately applying one of the local remedies. The various lotions employed in the acute type of eczema, especially those containing sediments, are valuable, and should be applied freely by dabbing on or by compresses; or, instead of lotions, the several dusting-powders named, particularly those containing boric acid. In painful and extensive cases linimentum calcis is grateful. Sometimes ointments, such as the zinc oxid ointment, an ointment containing 1 dram (4.) of calamin to the ounce (32.), a mild salicylic acid ointment, from 10 to 20 grains (0.65–1.3) to the ounce (32.), and salicylated paste are comforting. In cases in which the disease is more or less general, bran baths, starch baths, gelatin baths, and occasionally an alkaline bath, followed by the application of an ointment, will prove acceptable. In the most severe types the continuous bath (Hebra) is to be employed. In cases in which itching is a more or less prominent symptom carbolic acid may be added to the lotions or ointments employed; or the other applications employed to relieve itching, as mentioned in the treatment of eczema, may be resorted to. In pemphigus occurring in infants and young persons the same general plan of treatment is to be followed.

EPIDERMOLYSIS BULLOSA.

Synonyms.—Epidermolysis bullosa hereditaria; Acantholysis bullosa.

This is a rare affection, described (Goldschneider, Köbner, Blumer, Valentine, Elliot, Hallopeau, Beatty, Bowen, and others) in recent years, characterized by the formation of vesicles and blebs on any part subjected to slight rubbing, knocks, or irritation. It is usually

hereditary,[1] the same condition, as a rule, having existed in one or more previous generations. It generally makes its first appearance in early infancy or childhood, and the tendency persists indefinitely.

The lesions consist of small and large bullæ, exceptionally partly hemorrhagic, arising especially on parts of the surface subjected to friction from the wearing apparel, collar, wristband, etc., as on various parts of the body; or from slight knocks or pressure, as on the hands,

FIG. 86.—Epidermolysis bullosa, showing blebs, mostly broken, on those parts most subject to pressure and slight traumatism, as about the ankle, tibial surface, knees, and dorsal surface of the fingers (courtesy of Dr. J. C. Johnston).

from the use of implements, over the joints, etc. They are also observed in the mouth in some cases. The skin remains free if not subjected to such influences. In some instances the susceptibility is less marked than in others. As a rule, the blebs disappear without trace; exceptionally some pigmentation and slight scarring result. In a case under my observation the neck and upper back, wrists, and hands

[1] Bettman, *Dermatolog. Zeitschr.*, vol. x., 1903, p. 561, abstract in *Brit. Jour. Derm.*, 1904, p. 198, gives a striking example of hereditary transmission. His cases were a father and two daughters, with this family history: First known case was a daughter (1 of 13 children); of her 10 children, 2 were affected; 1 of these affected was married, and of her 14 children, 2 were affected; of these 1 (female) had 5 children, of whom 4 were affected; the other of the two (a male) had 2 children, both of whom were affected. Valentin, *Archiv*, 1906, vol. lxxviii., p. 87 also records a somewhat similar instance of heredity; also Engman and Mook, *Jour. Cutan. Dis.*, 1906, p. 55 (in 1 of their 4 cases).

exhibited almost continuous bleb-formation, the hand lesions resulting from work (drawing and designing). This tendency was especially noted at the finger-ends, and finally led to some atrophy and nail-loss. The patient is now twenty, and the condition has existed since birth. In some instances a similar atrophy of the finger-ends, associated with alopecia (G. W. Wende and others)[1] has also been observed.

The general health is not involved. In some cases there is an association of milium-like cysts (Augagneur, Beatty, Bowen, Bukovsky).[2]

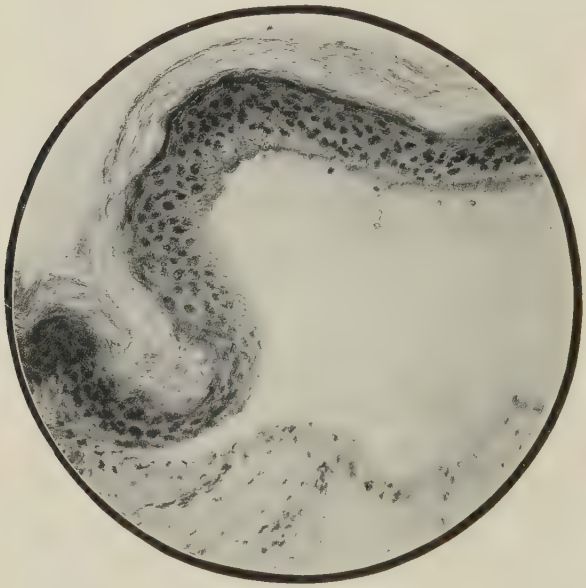

FIG. 87.—Epidermolysis bullosa: section of a portion of a bulla, showing the degeneration of the basic portion of the rete (courtesy of Dr. Geo. T. Elliot; photomicrograph by Dr. J. A. Fordyce).

The nature of the disease is obscure. The mild traumatism, if it can be so called, excites rapid exudation from the dermal vessels into the rete, separating this latter, and giving rise to blebs. Elliot's investigations lead to the conclusion that epidermolysis bullosa is not a disease in the strict sense of the term, but a cutaneous condition;

[1] G. W. Wende (1 case), *Jour. Cutan. Dis.*, 1902, p. 537 (with references and illustrations), and (1 case), *ibid.*, 1904, p. 14 (with illustration); Pernet, *Brit. Jour. Derm.*, 1904, p. 225 (nails, both of fingers and toes, were non-existent). Colcott Fox, *Brit. Jour. Derm.*, 1905, p. 223 (case, with progressive deformations). Sichel, *ibid.*, p. 307 (case presentation; with deformations and cicatricial alopecia); Savill, *ibid.*, p. 460 (case presentations; 2 brothers). Petrini-Galatz, *Annales*, 1906, p. 766 (2 cases, congenital and dystrophic; histologic; with many references). Williams, *Brit. Jour. Derm.*, Jan., 1907, p. 10, (evidences of antenatal development).

[2] For complete clinical survey and résumé of the disease see Wallace Beatty's paper, *Brit. Jour. Derm.*, 1897, p. 301; Bowen's paper, *Jour. Cutan. Dis.*, 1898, p. 254, and for the histopathologic aspects, Elliot's paper, *Trans. Amer. Derm. Assoc. for 1899.* H. L. Smith, *Maryland Med. Jour.*, April, 1901, reports a case in a negro, with notes on the blood and vesicle cells by T. R. Brown, who found both local and general eosinophilia. This paper also gives a summary of the literature. Bukovsky's (*Archiv*, 1903, vol. lxvii., p. 163) investigation of these bodies showed (as also demonstrated by others) a histologic connection with the sweat-ducts—retentive cysts of the ducts, their outlets becoming blocked by the healing of the bullæ. Engman and Mook's investigations confirm this.

the individual is born with a congenital irritability of the vascular supply of the skin, which responds to every irritation, and in consequence the basal portion of the rete is kept bathed in a more or less serous transudation, inducing degenerative changes; greater or repeated irritation causes greater exudation, detaching the loosely fastened rete, and the bleb is thus formed. Engman and Mook found the elastic tissue absent.

Treatment has no influence in modifying or lessening this tendency. As much as possible pressure and friction should be guarded against.

DERMATITIS REPENS.[1]

Definition.—Dermatitis repens is a spreading dermatitis starting from an injury, extending by a serous undermining of the epiderm, and usually occurring upon the upper extremities.

Symptoms.—The disease, first described by Crocker, may begin shortly after an injury, or immediately after a surgical operation, or even after complete healing has taken place. It begins, as a rule, by redness and serous exudation; the skin breaks at this point, and the exudation continues to be produced at the periphery and gradually undermines the epidermis, in this manner extending and covering considerable area. Or the disease appears first by the development of one, several, or more vesicles or small blebs, which become confluent, and followed by gradual peripheral undermining. Exceptionally the first lesions are papular. When established, a picture is presented of a red, raw-looking, usually oozing surface, with an elevated, confluent, spreading, vesicular wall, which invades the adjoining skin, and presents toward the red weeping surface which has just been passed over a raised irregular rim of partially detached or loosened epidermis. As the disease spreads the oldest part becomes dry and heals, the epidermal covering being thin and atrophic in appearance. Occasionally the traversed part, while red, soon becomes dry; and then there presents the spreading peripheral serous wall with the ragged epidermic edge, under this latter a red oozing surface, and beyond, on the old part, a dry or but slightly moist, red surface. In some instances the border portion may show some crust-formation. Exceptionally the malady may spread with a superficial elevated vesicular wall, and, as it extends, the older part collapses and dries, resulting in a somewhat scaly surface.

The disease may invade a considerable area; it may start at a

[1] Literature: Crocker, *Diseases of the Skin*, London, 1888, p. 128, and *Trans. Internat. Cong. Derm. and Syph.*, in Vienna, 1892; Garden, in Crocker's paper in the *Transactions;* Nepveu, *Brit. Med. Jour.*, 1886, ii., p. 1194 (Paris correspondence); Stowers, *Brit. Jour. Derm.*, 1896, p. 1; Fréche (Eruption trophonéurotique des extrémités rappelant la dermatitis repens), *Annales*, 1897, p. 491; Hardaway, *American Text-book of Genito-Urinary Diseases, Syphilis, and Diseases of the Skin*, p. 877, briefly refers to a case; Hyde and Montgomery, *Diseases of the Skin*, seventh edit., p. 434, briefly refers to 3 cases in speaking of treatment; Hallopeau, *Annales*, 1897, pp. 473 and 1277, under the name of "Acrodermatites continués," gives notes of a few cases with some points in common with dermatitis repens, but which he considers entirely distinct from the latter —he also considers the cases by Stowers and by Freche as similar to his own, and not identical with the disease as described by Crocker; Audry, "Les phlycténoses récidivantes des extremités," *ibid*, 1901, p. 913 (2 cases, with a résumé of previously published cases); Hartzell, "Dermatitis Repens," *Jour. Amer. Med. Assoc.*, Dec. 20, 1902, p. 1581 (1 case, with a review of recorded cases).

finger and traverse the entire arm, and even extend on to the trunk. Moderate cases may not involve more than a greater part of the hand and the lower part of the forearm. In fact, it may not extend beyond a small area—as, for instance, over a finger or a finger and small part of the hand. It is generally slow in its progress, but exceptionally, as in the case pictured, quite rapid, covering the surface shown in a period of about one week. There seems but little, if any, tendency to spontaneous cure. It is usually seen starting on the finger or some part of the hand, and rarely elsewhere.

A closely similar and, doubtless, allied condition is **acrodermatitis perstans** (*acrodermatites continués* of the French), in which the eruption is more of a vesicular and pustular nature, the first lesions being vesicles or pustules. Beginning usually on one finger, it may remain localized for some time, gradually, by the development of fresh foci, involving other fingers, the nail regions, and parts of the hand. Other regions of the body may show a secondary erythemato-squamous eruption.

FIG. 88.—Dermatitis repens in a middle-aged woman, of about a week's duration, beginning at a cut shown on the thumb, and followed by progressive serous epidermic undermining extending down the fingers, across the hand, and up the wrist.

Etiology.—An injury, usually slight in character, such as a cut or a burn, appears to be the starting-point of the disease, probably from a peripheral neuritis. It would seem to me that the malady is due to parasitic invasion, the break of continuity affording opportunity for inoculation. Or a peripheral neuritis may be the causative agent. It is possible that both factors may, as Crocker states, be etiologic, the neuritis primary, and parasitic invasion secondary.

Diagnosis.—The disease somewhat resembles eczema rubrum; but its origin from an injury, method of spread, the elevated vesicular

or bullous spreading wall, usually with the loosened or projecting rim of epidermis, and the red, oozing, and sometimes atrophic-looking surface will prevent any confusion. Those cases beginning in a group of several vesicles or bullæ may at first slightly suggest pompholyx.

Treatment.—The undermined and loose skin should be first cut away. The few cases which have been under my own care were cured by applications of a saturated solution of boric acid containing 2 or 5 grains (0.13–0.33) of resorcin to the ounce (32.); bathing the parts with this morning and night, and while the surface is still wet with it, covering over thickly with powdered boric acid, and enveloping in a loose, light dressing. Should there be considerable oozing, sufficient to lead to adherence of the enveloping dressing, then the under part of this latter, in contact with the powder, can be slightly greased with petrolatum. Once daily the affected area should be gently washed clean with warm water.

Crocker cured one case by keeping the part constantly wrapped up with linen cloths wet with lead lactate lotion; one with painting on a 10 per cent. permanganate of potassium solution three times daily until a crust is formed. Hardaway had success with an ointment of a dram (4.) of aristol to an ounce (32.) of unguentum vaselini plumbicum. Applications of a saturated solution of pyoktanin blue and a solution of sodium hyposulphite have also been commended.

Hartzell found applications of formalin—1 dram to an ounce of glycerin (4. : 32.)—to the spreading edges, followed by Brooke's paste (see treatment of cutaneous tuberculosis), efficacious.

Hallopeau and Gastou[1] had results in 1 case (acrodermatite suppurative continué), which promised complete success, from *x*-ray treatment.

THE IMPETIGOS.

In olden times the term impetigo, as well as impetigo simplex, impetigo sparsa (Willan, Bateman, Wilson, Hillairet), was applied to various pustular inflammations of the skin. From this ill-defined classification many authors gradually accepted two divisions of this group: one under the name of impetigo or impetigo simplex, and the other under the name of impetigo contagiosa (Tilbury Fox[2]); under the former were included most accidental pustular lesions seen in connection with parasitic diseases, especially pediculosis, and those occasionally occurring in connection with eczema and other inflammatory dermatoses, and this variety was for a long while thought to be non-contagious. While most authors considered this type more of an accidental lesion than a distinct morbid entity, others, and in our own country notably, Duhring[3] and Robinson[4] contended that there was a special disease of which the rounded,

[1] Hallopeau and Gastou, *Annales*, 1904, p. 1021.

[2] Tilbury Fox, *Brit. Med. Jour.*, 1864, pp. 467, 495, 553, and 607; and *Jour. Cutan. Med.*, Oct., 1869, p. 231; *Treatise on Diseases of the Skin*, third edit., p. 227.

[3] Duhring, *Diseases of the Skin*, third edit., p. 293; part ii., *Cutaneous Medicine*, p. 422.

[4] Robinson, *Manual of Dermatology*, p. 280.

semiglobular pustule, practically non-contagious, and occurring in children, and presenting a variable number of lesions, did exist. Under the other heading—impetigo contagiosa—authors have been accustomed to place those cases of vesicular and seropurulent and purulent lesions seen chiefly upon the face of children, usually running a definite limited course, and which clinical observation had pointed out had very decided contagious properties. Later, chiefly since the experiments of Bockhart,[1] all these various pustular lesions have been thought to represent the same morbid process resulting from inoculation by pyogenic cocci. This acceptation would attribute the somewhat varied clinical pictures to the fact of different environment, different "soil," and different virulence of the infecting germ. For clinical purposes and for treatment this view, while in the light of more recent research not wholly scientifically exact as to the pathogenic organisms, appeared to be the most satisfactory. Since this view became the prevailing one, however, clinical and experimental studies by Unna,[2] Sabouraud,[3] and others,[4] seem to show various types of impetigo due to different micro-organisms. Unna would have us believe that there are, in reality, several distinct diseases: impetigo vulgaris (impetigo contagiosa, of Tilbury Fox and others), impetigo staphylogenes (impetigo of Bockhart and Duhring), and impetigo circinata and impetigo streptogenes. Sabouraud's clean-cut investigations led him to conclude that there are two separate maladies, one due to the streptococcus and the other to the staphylococcus, the former causing the impetigo contagiosa of Tilbury Fox and others, and the latter the impetigo of Bockhart. It will be seen that while the question of impetigo is still in an unsettled condition, much has been done, and is being done, to add to its elucidation.

The facts as now known seem to indicate that there are several types of impetigo, sometimes doubtless mixed in character, the slightly varied clinical differences of which, for practical purposes, may be ignored, inasmuch as for all the treatment is always the same. All forms are contagious, the impetigo of Bockhart being the least so. As Tilbury Fox's impetigo contagiosa is that most commonly observed, they will be here considered under that heading.

[1] Bockhart, *Monatshefte*, 1887, p. 450.

[2] Unna and Schwenter-Trachsler, "Impetigo Vulgaris," *Monatshefte*, vol. xxviii., pp. 229, 281, 333, and 385 (an elaborate and experimental paper reviewing the whole subject and literature of impetigo).

[3] Sabouraud, "Etude clinique et bacteriologique de l'impetigo," *Annales*, 1900, pp. 62 and 320 (a complete and elaborate investigation of the subject, with important literature references and a number of cuts).

[4] Other important recent literature: Wickham, *Union médicale*, Feb., 1892, Nos. 16 to 23, and *Brit. Jour. Derm.*, 1892, p. 202; Balzer and Griffon (bacteriologic; streptococci found in every instance), *La Presse méd.*, 1897, No. 89; Dubreuilh, "De la nature de l'impetigo et de l'eczèma impetigineux," *Annales*, 1890, p. 289. Also valuable papers bearing upon the rôle of pus-producing organisms in skin diseases in *Trans. Amer. Derm. Assoc. for 1899*, by Elliot (p. 75) and Gilchrist (p. 87) and (of staphylococcus) C. J. White, *Med. Com. Mass. Med. Soc'ty*, 1899, p. 157.

IMPETIGO CONTAGIOSA.

Synonyms and Varieties.—Porrigo contagiosa; Impetigo parasitica; Impetigo vulgaris (Unna); Impetigo simplex; Impetigo sparsa; Impetigo streptogenes; Impetigo staphylogenes; Impetigo circinata; Impetigo figurata

Definition.—Impetigo contagiosa is an acute, contagious, inflammatory disease, characterized by the formation of discrete, superficial, flattened, rounded, or oval vesicles or blebs, often becoming seropurulent, and drying to thin yellowish crusts.

Exceptionally the beginning lesions are small pustules, and which may dry to thicker crusts. And occasional types of a circinate or even serpiginous configuration are noted.

Symptoms.—In a typical case of impetigo contagiosa of the common form of the disease several vesicopapules, vesicles, or vesicopustules make their appearance simultaneously or in rapid succession upon the face, face and scalp, or face and fingers, or upon all these various parts. At first small, they tend to increase in size, becoming decidedly flattened, with, in some cases, in some of the lesions, a slight relative depression of the central part, as compared to the extending peripheral portion; there may even be distinct umbilication. They are superficial, and, as a rule, are without conspicuous areola and without distinctly inflammatory base. They attain the diameter of a pea or a dime, and when close together, as often noted when about the mouth and chin, coalesce and form one or more large, irregular patches. The contents at first are often purely serous, later becoming milky or seropurulent or even purulent. If a vesicopustule or bleb is broken, a reddish, moist, abraded-looking surface is exposed, secreting a thin watery or puriform liquid, and looking not unlike a superficial burn or abrasion. Several days after the appearance of the lesions they begin to dry to thin, granular, yellow or yellowish, wafer-like crusts, which are but slightly adherent, and later on, when the edges have commenced to loosen, have the appearance of being imperfectly pasted on. Fresh lesions may appear singly or in crops from day to day, but finally, in the course of several days or a weeks, new ones cease to form and the malady gradually ends. The crusts soon drop off, leaving behind reddish spots which rapidly fade

FIG. 89.—Impetigo contagiosa in a girl of ten years, of one week's duration, crusting stage already reached; on chin and nose lesions have coalesced.

away. Itching may or may not be present. The whole course of the disease, as a rule, occupies ten days to a few weeks.

Exceptionally, in addition to the eruption upon the skin, a few lesions show themselves upon the conjunctival, nasal, or oral mucous membrane. A not unusual site for a vesicopustule is around a finger-nail, where it is somewhat suggestive of a superficial paronychia. Excoriations, scratch-marks, or abrasions, if present, soon become, through autoinoculation, the seat of characteristic lesions. As a rule, there is no constitutional disturbance, but when the eruption is extensive, as it is more apt to be in the epidemic form of the disease, it is preceded by light febrile action and malaise.

FIG. 90.—Impetigo contagiosa, with small lesions, in a girl of fourteen years, and of six days' duration.

All observers have recognized the existence of anomalous types.[1] In some of these the eruption consists of but two, three, or several ill-defined lesions about the nose and mouth, with possibly one or two upon the fingers. In others, again, the eruption is more or less scattered over face, hands, limbs, and to a less extent upon the trunk. In some instances, of more or less general distribution, the lesions, instead of being flat, consist of pea- to nut-sized blebs, flaccid or tense; and when occurring in an epidemic manner among infants and young children the malady simulates, according to the predominant size of the lesions, varicella or pemphigus (**impetigo contagiosa bullosa**). Doubtless many of the reported cases of contagious pemphigus and acute pemphigus in children are examples of this variety (impetigo streptogenes ?).

[1] Foster, "Herpes Contagiosus Varioliformis," *Arch. Derm.*, 1875, p. 97; Corlett, "Impetigo: Its Clinical Forms and Present Status, including Ecthyma and the so-called Pemphigus Contagiosus," *Cleveland Jour. Med.*, vol. iii., 1898, p. 513; Allen (general—bullous), *Trans. Amer. Derm. Assoc. for 1896;* Elliot (general—bullous), *Jour. Cutan. Dis.*, 1894, p. 194; Anthony (various forms), *ibid.*, 1898, p. 218; Stelwagon (various forms), *Phila. Med. Times*, Sept. 22, 1883; Engman, "Impetigo Contagiosa and its Bacteriology," *Jour. Cutan. Dis.*, 1901, p. 180 (with review and bibliography); Grindon (bullous), *ibid.*, p. 188.

In occasional cases they may present segmental or ring-like or serpiginous configuration (**impetigo circinata, impetigo figurata**).[1] In rare instances, instead of vesicles or blebs, many of the lesions are pustular, and especially those upon the legs, ecthymatous, with a markedly inflammatory base and areola. Exceptionally, as in the variety described by Duhring[2] as **impetigo simplex** (**impetigo staphylogenes**), the vesicular stage of the disease seems to be wanting, the lesions appearing as pure rounded globular pustules, with little or no tendency to flattening; and which, in some cases, may, instead of developing into ordinary matured impetigo lesions, lead to deeper invasion by the organisms and to boil-formation. As Bockhart has shown in this type, the lesion is usually follicular. It is seen not infrequently about hairy regions, as the nape of the neck, about the ankles and other general-surface regions in hairy individuals; and in those cases in which the lesions are close together and almost coalescent could be clinically well described as a **pyogenic dermatitis** (**dermatitis pyogenica, pyodermia, pyodermatitis, pyodermitis**).

FIG. 91.—Impetigo contagiosa of slight development and showing a circinate patch; of six days' duration, in a youth of eighteen. Crusting stage already reached.

In exceptional instances the common sites for the eruption may be exempt, the lesions appearing in unusual regions as on the buttocks or legs.[3]

It is infrequent in adults, and when seen, consists usually of a few abortive lesions on the face or hands; in some cases, however, it presents numerous discrete and closely crowded pea to dime-sized or slightly larger, lesions about the bearded region and the neck; and which quite frequently show a distinct tendency to ring-like development; the serous and sero-purulent formation is often quite

[1] See remarkable case by Schamberg, *Jour. Cutan. Dis.*, 1896, p. 169 (with illustrations).

[2] Duhring (a report of 2 typical examples), *Amer. Jour. Med. Sci.*, Oct., 1888; also Leslie Roberts (1 case), *Brit. Jour. Derm.*, 1895, p. 142.

[3] In 103 cases observed at the Philadelphia Dispensary for Skin Diseases the site was as follows: Face, 49; face and hands, 12; face and limbs, 6; face and scalp, 5; face, scalp, and hands, 5; face, hands, and other parts, 4; face and trunk, 3; face and buttocks, 3; face and feet, 1; legs, 3; trunk and legs, 2; trunk and limbs, 1; hands and neck, 1; hands and buttocks, 1; scalp, 1; buttocks, 1; limbs, 1; distribution more or less general, 4.

scanty, and in such cases the lesions may show considerable resemblance to ringworm patches. This more extensive variety is met with in the male adult and is commonly contracted in barber-shops.

According to Unna,[1] the chief differences between the common type observed (his impetigo vulgaris—impetigo contagiosa of T. Fox) and impetigo circinata, impetigo staphylogenes, and impetigo streptogenes are: in impetigo circinata there are no thick crusts, but scales containing more horny cells than serum, and the lesions spread at the borders, forming discoid and gyrate figures, clearing in the central portions. In impetigo staphylogenes (of Bockhart) the lesions are small pustules with an areola, and are discrete for some time before coalescing, and lead to the formation of comparatively small and thin crusts; the lesions do not remain long as impetigines, but the staphylococcus, by invading the hair-follicles, leads to folliculitis, furuncles, whitlows, etc. Impetigo streptogenes lesions commence with serous exudation, giving rise to flaccid bullæ, generally large in size, and with grayish-yellow, turbid contents.

FIG. 92.—Impetigo contagiosa in a child of three, and of five days' duration. Lesions scattered, and more of the nature of the type of "impetigo simplex" described by Duhring.

If the experience of other observers is at all similar to mine, there are instances met with in which the characters of these several types are found in the same case; Sabouraud's investigations demonstrate the possible admixture of two types, primarily to invasion of streptococci, secondarily to staphylococci.

Etiology.—The disease is contagious in all its forms, inoculable and autoinoculable. From its occasionally occurring in epidemics it would almost seem as though the malady might in some instances be infectious. It is observed commonly in the lower ranks of life, although it is not infrequently seen among the wealthier classes. It is chiefly a disease of infancy and early childhood, being most common between the ages of two and ten. In men, occurring about the bearded region, it is usually contracted in barber-shops. Epidemics have also been noted to occur among youths and adults through interchange of apparel or the use of common or insufficiently cleansed towels, as with football players (*football impetigo*) in schools, and among bathers (*bath-house impetigo*)

[1] Quoting from the abstract of his paper (*loc. cit.*) in *Brit. Jour. Derm.*, 1899, p. 332.

at the shore. A relationship to vaccination[1] has been noted in some instances, but the same relationship may be said to exist, I believe, to other suppurative processes or lesions. It is also seen in association with pediculosis and scabies; the minute punctures made by the parasites and the excoriations produced by scratching furnishing opportunity for the necessary inoculation.[2]

Pathology.—It is known that the disease is due to pus-cocci, staphylococcus aureus, streptococcus, and possibly the staphylococcus albus. As intimated in the preliminary remarks, other cocci are

FIG 93.—Impetigo contagiosa of the male adult, of bearded region and of about a week's duration, showing discrete and confluent lesions; usually contracted in barber-shops and presenting lesions more especially on bearded parts of the face and neck, and which are quite frequently ring-like in character (courtesy of Dr. J. F. Schamberg).

doubtless also etiologic; and it has been alleged by Unna that the various forms have each a specific coccus, but this needs further confirmation. Exceptionally the ringworm or other fungus will provoke somewhat similar lesions (Kaposi, Piffard, Colcott Fox, Geber).

[1] Stelwagon, "Impetigo Contagiosa: Its Individuality and Nature," *Medical News*, Aug. 29, 1883 (out of 88 cases, in 6 only did it follow vaccination; others have, however, observed this association in larger proportion. This paper contains most literature references to date).

[2] See paper by Klotz on "The Infected Scratch and its Relations to Impetigo and Ecthyma," *Jour. Cutan. Dis.*, 1896, p. 46.

Crocker[1] was the first to demonstrate clearly that the disease was due to a coccus, and the investigations by Unna and Sabouraud, if carefully examined, appear, in fact, to corroborate the correctness of these earlier findings as the cause of some cases of the disease. In some instances—those in which the eruption is epidemic and more or less general in its distribution, and, more especially, the bullous type, with slight constitutional disturbance—the disease certainly bears resemblance to such eruptive fevers as varicella; it is difficult, it is true, to reconcile such examples with the numerous simple cases of undoubted pus-inoculation lesions occurring about the nose, mouth, and hands.

The lesion is formed (Robinson, Unna, Gilchrist, and others) between the rete and horny layer, this latter being the roof-wall; there is a surrounding mild inflammation. The underlying upper part of the corium displays acute inflammatory action, with the usual features. The lesion contains polynuclear leukocytes in large number, some round mononuclear cells, a few detached epithelial cells, small quantity of fibrin, and a large quantity of coagulated albumin (serum), and, especially in the central portion of the lesion, a large number of the staphylococcus pyogenes aureus, often streptococci, as well as sometimes other cocci.

Diagnosis.—Impetigo contagiosa is to be differentiated from pustular eczema, ecthyma, varicella, and pemphigus. The patches formed by coalescence bear, it is true, a rough resemblance to pustular eczema; but this latter is accompanied with other symptoms of eczema, such as more or less infiltration and thickening of the involved skin, with intense itching. Moreover, in impetigo contagiosa discrete lesions are always to be found, and these differ from the individual pustules of eczema in greater size, in the absence of a tendency to rupture, and their course.

Impetigo contagiosa differs from ecthyma by the absence of the inflammatory base and areola. The distribution is also unlike the eruption in the latter malady, being ordinarily upon the face and hands or face and several other parts, while that of ecthyma is commonly seated upon the legs. Moreover, impetigo contagiosa is essentially a disease of childhood, whereas ecthyma is usually observed in adults. In the former, too, the process is superficial and the crusts are thin; in the latter, deep-seated, and the crusts are thick.

The lesions of varicella are uniform and smaller, rarely larger than split peas, and more or less disseminated, with no tendency to patch-formation and with insignificant crusting. In those rare cases of impetigo contagiosa resembling pemphigus the disease must be studied in its entirety, and sometimes for several days before it is possible to be positive as to diagnosis. Pemphigus is exceedingly rare. In true pemphigus the lesions spring from the sound skin usually as blebs of some size from the start, whereas in impetigo contagiosa they are small in the beginning and grow in size by peripheral extension. The eruption of pemphigus has no parts of predilection, and, moreover, is generally accompanied by symptoms of constitutional disturbance. In impetigo contagiosa some of the characteristic

[1] Crocker, *Lancet*, 1881, vol. i., p. 82.

lesions are usually present, or frequently another member of the family will present the typical disease.

Prognosis.—The effect of treatment is, as a rule, prompt; indeed, impetigo contagiosa in most instances tends to spontaneous disappearance in ten days to a few weeks; but in exceptional cases, more especially in those in which itching is present to a sufficient degree to lead to scratching, the excoriations thus made become inoculated, and in this manner the disease, unless actively treated, may persist for one or two months. A pediculosis capitis is also at times a causative factor in prolonged cases.

Treatment.—Treatment consists in the destruction of the autoinoculable properties of the crusts and contents of the lesions. The crusts should be removed by warm water and soap washing, fresh or distended lesions being first opened. An ointment of 10 to 20 (0.65–1.35) grains of ammoniated mercury to the ounce (32.) of cold cream or petrolatum should then be gently but thoroughly rubbed into the secreting base of the lesions two or three times daily. When the crusts are quite adherent and fail to come off with ordinary washing, the salve just named should be applied over the patch, and the washing and such anointing repeated two or three times daily until the crusts come away, after which the ointment should be rubbed into the secreting base. In many of these latter cases, indeed, partial or complete healing will be found to have taken place beneath the crusts. In some instances Lassar's paste with the addition of the white precipitate or 20 to 30 grains (1.33–2.) of sulphur to the ounce (32.) is more satisfactory. Any mildly antiseptic ointment will, however, be found curative.

In markedly itchy cases, in which the disease tends to continue from inoculation of the scratch-marks thus provoked, a lotion of the saturated solution of boric acid, with 5 grains (0.33) of either carbolic acid or resorcin, or both, to the ounce (32.), should, as a preventive measure, be applied two or three times daily to the affected parts generally. Ordinarily in all extensive cases this lotion can be advised along with the salve as a routine measure. For lesions occurring on the conjunctiva a plain boric acid lotion, 10 grains (0.65) to the ounce (32.), may be dropped in the eye once or twice daily.

In those cases of more or less general distribution, in which mild febrile action is present, in this respect resembling slightly the eruptive fevers, a laxative should be given and the patient kept at comparative rest for a day or two; in other respects the treatment is the same.

ECTHYMA.

Definition.—Ecthyma is characterized by the appearance of one or several or more discrete, finger-nail-sized, flat, usually markedly inflammatory pustules.

Symptoms.—The eruption is seen commonly upon the legs, sometimes upon the shoulders and upper back and the forearms, but rarely elsewhere. The lesions begin as small, usually pea-sized pustules, without a prepapular or prevesicular stage. They increase somewhat in size, and when fully matured attain about the area of a small,

or sometimes a large, finger-nail. They are slightly elevated, flattened, and have a markedly inflammatory base and areola, with usually considerable infiltration and induration of the underlying tissue. In color they are at first yellowish, but soon become, from the admixture of blood, reddish or brownish. They gradually, in the course of several days to several weeks, dry to brownish or blackish crusts, beneath which will be found, in the earlier stages of this process, superficial excoriation. If a maturing pustule is pricked or accidentally ruptured, the fracture may close by drying of the exuded pus and the lesion fills up again. The individual pustules usually last ten days to a few weeks; but new lesions may continue to appear from day to day or week to week for a period of several months or longer. As a rule, not more than five or ten are present at any one time. Occasionally, however, they are more numerous, small and less deep, and may be limited to one or both legs below the knees. More or less persistent pigmentation, and, in some instances, superficial scarring may remain to mark the site of the pustules. The subjective symptoms are never marked, and rarely consist of more than slight pain and tenderness; itching is occasionally complained of, but is never severe.

Etiology.—Ecthyma is distinctly a disease of the lower walks of life, and occurs in those debilitated from any cause whatsoever. It is therefore more commonly seen in poor-houses, prisons, and in the slum districts. Improper food, living under bad hygienic conditions, are predisposing. Its common subject is the adult tramp or the low-class tenement lodger. It is not uncommon, according to Hallopeau, in those working in sugar-refineries. It occurs infrequently in children. The exciting cause of the disease must be considered, from the standpoint of our present knowledge, to be a specific micro-organism. The malady is mildly contagious. Nor can it be doubted that the slight breaks in the continuity of the cutaneous tissues produced by scratching and by vermin—the bites of lice and bedbugs—in those whose other conditions and surroundings predispose, are in many cases potential factors in the production of the disease. It is to be borne in mind also that exceptionally the ingestion of certain drugs, as iodids and bromids, may produce somewhat similar lesions.

Pathology.—The disease is allied to impetigo, and by many is considered identical. Experiments with direct inoculations (Vidal, McCormick) and cultures, it is alleged, always produce the same affection; further confirmation is, however, needed on this point. Various investigators (Mathieu and Netter, Wickham, Thibièrge, Unna, and others) have found a streptococcus in the lesion. Studies (Leloir, Unna) of the pathologic anatomy show that the process begins as an inflammation in the lower epidermal layers, fibrinous centrally and edematous peripherally, and which invades the derma superficially or deeply; minute, intercellular cavities form, which melt together and are filled with a fibrinous and purulent fluid. The fluid cavity involves the upper corium and exceptionally the entire corium. The pus, which is inoculable and autoinoculable, usually contains staphylococci and streptococci.

Diagnosis.—Ecthyma is to be differentiated from the impetigos (*q. v.*) and the large, flat, pustular syphiloderm.

The flat pustules of syphilis are ordinarily sluggish, much less inflammatory, and usually lacking the extensive, hard, and bright-red base and areola of ecthyma; moreover, the ulceration of the syphilitic lesion is deeper and more sharply cut, and the secretion is thicker, drying to greenish or greenish-brown crusts, which are more bulky and inclined to be heaped up like an oyster shell. The flat pustular syphiloderm is also of more extensive distribution, frequently with other syphilitic lesions intermingled, and almost invariably accompanied with other symptoms of syphilis.

Prognosis and Treatment.—Ecthyma is rapidly amenable to treatment. It is to be kept in view that the affection occurs, as a rule, only in those in a depraved state of health and those who have been exposed to bad hygienic conditions, and these possible factors should be met with proper measures and tonics.

Cleanliness is necessary, and frequent washings, with the use of the ordinary toilet soap, or alkaline baths, are to be advised; these, together with remedial unguent applications, soon remove the crusts. If they are firmly adherent, and if the process appears to go deeply, water dressings or starch poultices can be used temporarily, but in ordinary cases this is not necessary, and the crusts may be permitted to become detached gradually, healing taking place beneath. Applications are to be made twice daily, and applied spread on lint or any suitable material. The local treatment is similar to that employed in impetigo contagiosa.

IMPETIGO HERPETIFORMIS.[1]

Definition.—An extremely rare disease, occurring in women almost exclusively, and usually while in the puerperal state, characterized by the appearance of numerous isolated and closely crowded miliary pustules, with a decided tendency to the formation of circular groups or patches, and preceded and accompanied by grave systemic disturbance, and usually ending fatally.

Symptoms.—The eruption is chiefly upon the genitocrural region, inner and flexor aspects of the thighs, and the anterior surface of the trunk, although other parts of the body may also share in the disease. It consists of minute pustules, grouped or arranged in circles, tending to crowd together into patches; they crust over and new lesions and circular groups appear at the periphery, the crusts being of a yellowish, greenish, or brownish color. In this manner the eruption spreads, the patches coalesce, and large areas are thus involved. The surface beneath the crusts is red and moist

[1] Literature: Hebra, *Wien. med. Wochenschr.*, No. 48, 1872 (translation in *Amer. Jour. Syph. and Derm.*, 1873, p. 156); *Lancet*, Mch. 23, 1872; and colored plates in *Atlas der Hautkrankheiten*, H. ix., Taf. ix. and x., 1876; Kaposi, *Archiv*, 1887, p. 273 (based upon 13 cases; 4 colored plates); Dubreuilh, *Annales*, April, 1892 (a report of a new case and an analytic review of all authentic previously reported cases, almost all of which were observed in Germany and Austria). Since this date the following cases have been recorded: Glaevecke, *Arch. für Gyn.*, Bd. ccxi., H. 1, p. 18—abs. in *Jour. Cutan. Dis.*, 1897, p. 146 (recovery; histologic examination); Hartzell, *Jour. Cutan. Dis.*, 1897, p. 507 (in a woman aged eighty-four); Whitehouse, *ibid.*, 1898, p. 169 (in a male).

looking, not unlike that of a weeping eczema. The circular grouping and spreading are more or less characteristic, but in some of the cases reported the lesions were disseminated and in irregular clusters. The pustules come out in crops, and the malady goes from bad to worse, so that a great part or almost the entire surface may become invaded. The mucous membranes of the mouth, nose, and throat may also show involvement. The crusts fall off as the case progresses, new epidermis forms, or the surface continues to have the moist eczematous aspects. In some instances patches similar to those of pemphigus vegetans are observed. In a few of the cases, too, the eruption was polymorphous, these being midway in their cutaneous symptoms between this affection and dermatitis herpetiformis. While the disease is, as a rule, continuous, there may be intermissions of partial or complete quiescence. Along with the cutaneous outbreaks there is grave constitutional disturbance, which persists, increases in severity, and, with but few exceptions, finally, from exhaustion or some intercurrent organic disease, the patient succumbs.

Etiology and Pathology.—The disease is obscure. It is closely allied to dermatitis herpetiformis and to pemphigus, cases of apparently mixed symptomatology having been reported by Heitzmann,[1] Zeisler,[2] Fordyce,[3] and others. Excepting the 3 cases in males observed by Kaposi, Dubreuilh, and Whitehouse, all of the cases so far reported, about 20 in number, were in women, and with but few exceptions in women in the pregnant state. The pathologic anatomy (T. Du Mesnil and Marx, Dubreuilh, Glaevecke) shows dilatation of the blood- and lymph-vessels, with swollen endothelium and encompassed with embryonic cells. The interpapillary processes of the epidermis are widened and prolonged, there is an abundance of round-cell infiltration in the derma obscuring its structure, and which in the pustular area completely obliterates the line of demarcation between the pars papillaris and the rete layer. Contrary to Du Mesnil, Dubreuilh finds that the smallest pustules are deepest seated. Several micro-organisms have been found, but on this point no conclusion is yet warranted. The disease is evidently an infection, and in some cases its septicemic nature seemed evident. In autopsies nephritis and pulmonary tuberculosis have been noted in some instances.

Diagnosis.—Its clinical features, its occurrence in women, and generally when in the parturient state, are usually sufficiently characteristic to distinguish it from pemphigus, more especially pemphigus vegetans, and from dermatitis herpetiformis; midway cases between it and the latter disease are, however, likely to give rise to difficulty, which a few weeks' observation will usually solve.

Prognosis and Treatment.—Not much hope can be held out to the patient, as the disease is usually fatal. With but relatively few exceptions all have died, some after weeks, some after months, of suffering. Treatment is to be based upon general principles, and the plans advised in pemphigus and dermatitis herpetiformis seem indi-

[1] Heitzmann, *Arch. Derm.*, 1878, p. 37. [2] Zeisler, *Monatshefte*, 1887, p. 950.
[3] Fordyce, *Jour. Cutan. Dis.*, 1897, p. 495 (with colored plate and several histologic cuts).

cated. Abortion should be induced. The cases which recovered were, as a part of the treatment, kept in the continuous water-bath.

FURUNCULUS.

Synonyms.—Furuncle ; Boil ; *Fr.*, Furoncle ; Clou ; *Ger.*, Furunkel ; Blutschwär.

Definition.—Furunculus, or boil, is an acute, deep-seated, inflammatory, circumscribed, rounded or more or less acuminated, firm, painful formation, usually terminating in central suppuration and necrosis.

Symptoms.—A boil usually begins in one of two ways. There may appear a small painful induration in the skin or subcutaneous tissue, over which the skin presents a rounded or imperfectly defined reddish spot; it increases in size, and the surrounding induration and swelling become more pronounced, and project more or less above the surface of the circumjacent skin. After several days, when well advanced, it appears as a pea- to a cherry-sized, circumscribed, reddish, rounded elevation, with more or less surrounding hyperemia and swelling, and is painful and tender; it gradually begins to soften, and ends, in the course of several days to one or two weeks, in the formation of a central slough and suppuration. The central overlying skin is finally involved, which becomes somewhat pointed, thin, and yellowish, disclosing the pus beneath. This central point soon breaks, the opening enlarges, and there are discharged more or less pus and a small, grayish-yellow or greenish-white pultaceous mass, the so-called "core"; the pain immediately abates, the inflammation quickly subsides, the swelling and redness disappear, the hollow cavity fills up with granulation tissue, and healing rapidly takes place, leaving behind for a week or more a reddish spot, with slight scar-formation, which, in some instances, may be so slight as later to be scarcely perceptible.

Or instead of a painful cutaneous or subcutaneous nodule, the lesion first presents as a minute superficial pustule, usually pierced by a hair; gradually the surrounding and underlying parts become red and slightly indurated and swollen, and the small pustule dries, and then the lesion gradually assumes, to a great extent, the characters of an ordinary boil, and goes through the stages described. Or the small pustule breaks and discharges; it dries over, and then the induration, redness, and swelling ensue. Gradually this points, presents a yellowish summit, and the course is the same as above detailed. Exceptionally the opened apex may dry over once or twice, the boil fill up again before the core is discharged.

There may be one, several, or more present, and usually in close proximity, although in some cases they may be widely separated. If the lesion is a large one, or if several form simultaneously, there may be slight sympathetic constitutional disturbance. The neighboring lymphatic glands may show some enlargement.

At times a boil shows very little, if any, tendency to point or break down, or to form a distinct core, constituting the so-called *blind boil.* This may disappear in its early stage, or may continue

and finally go on forming a soft boggy pea- to cherry-sized elevation, which eventually breaks and discharges, and then gradually heals up as in the ordinary form.

Usually, when the one or several lesions which have formed simultaneously or one after another disappear, the whole process is ended. In other cases there is a constant recurrence of one or several lesions, in the same localities, or on different regions, and this sometimes continues for weeks and months, constituting that condition termed *furunculosis*.

While boils may appear on any part of the body, certain regions, such as the back of the neck, the axilla, buttock, forearms, and legs are its most common sites, and most frequently the first named.

Etiology.—Two factors are to be considered necessary in this disease, essential and predisposing. The essential factor, and the immediate exciting cause, is the entrance into a hair-follicle or sebaceous gland-duct, or possibly a sweat-gland, of a special micro-organism. The frequently observed close proximity of boils is indicative of external cause and autoinoculability. The contributing influences are various, but may be, in brief, any depraved state of the general health. Albuminuria, diabetes mellitus, disorders of the digestive organs, gouty and rheumatic diatheses, living in close and badly ventilated rooms or in damp and musty places, and, doubtless, other factors may be of influence in bringing about a condition of the skin favorable to successful inoculation. Too much warmth, with its consequent sweating, and friction are also of importance in bringing the skin itself into a favorable state for implantation and multiplication of pyogenic organisms. Thus boils are quite frequently a part of a persistent miliaria in dirty and overclad children or even adults; and especially common about the nape of the neck and axilla, parts subjected to rubbing and chafing. Workmen in paraffin oils and petroleum and tar products often present furuncles and subcutaneous abscesses. The administration of certain drugs, notably potassium iodid, may be in some instances an important etiologic factor; lesions so produced are not infrequently seen in those taking "blood purifiers," many of which contain this drug.

All ages and both sexes are liable, but the formation is more common between the ages of twenty and forty, and in males.

Pathology.—A boil is an inflammatory formation having its starting-point in a sebaceous gland, hair-follicle, or possibly a sweat-gland (see hydradenitis suppurativa), the exciting factor being the staphylococcus pyogenes aureus. Both Bockhart[1] and Garré[2] have experimentally produced furuncular lesions on themselves by rubbing in pure cultures of this organism; the former, a pure mixed culture of the staphylococcus aureus and albus, the latter of the aureus alone. Its pathogenic importance has been demonstrated by Pasteur, Sabouraud, Unna, Wickham, and others.[3] It is not improbable, however, that boils may also be produced by other pus-producing organisms. The core or central slough of a boil is composed of pus and the

[1] Bockhart, *Monatshefte*, 1887, p. 450.
[2] Garré, *Fortschritte der Medicin*, 1885, p. 165.
[3] See literature under impetigo, and also p. 84.

glandular and perifollicular tissue in which it had its origin. The intense zone of inflammatory deposit around the center, by shutting off the vascular supply, results, along with the liquefying action of the cocci and leukocytes, in the breaking down of the central portion and the production of the core mass.

Diagnosis.—A boil is so well known that usually even a layman can make the diagnosis. In the earliest stage of those which begin as a superficial pustular point around a hair it might be readily, and probably properly, looked upon as a simple impetigo lesion; the later phases of surrounding and underlying inflammation, with the gradual pointing and discharge, are quite characteristic. A furuncle is, in fact, to be distinguished chiefly from a carbuncle, and the main distinguishing point is that a furuncle is a single formation and has but one point of suppuration and opening, whereas a carbuncle is a large, flattened, intensely painful formation usually accompanied with considerable or severe constitutional disturbance, and has, moreover, several or more points of suppuration.

Prognosis.—An average boil usually runs its course in from one to two weeks, and even when several or more are present in the same locality, a favorable issue in many cases soon results. In some of these latter instances, however, and in those in which there are scattered boils appearing from time to time (furunculosis), a favorable result is not so rapidly reached, although complete freedom will sooner or later be established. The possibility of a serious underlying factor, such as diabetes, living in a damp, unhygienic atmosphere, etc., must be considered.

Treatment.—Remembering that boils are doubtless due to the predisposing factors of a weakened organism, a local disturbance of the skin, and the presence of the specific causative microbe will suggest the plans of treatment.

The constitutional treatment depends, in a measure, upon the patient's general condition, and what may seem to be the etiologic factor. A generous dietary is to be allowed. In cases of numerous and recurrent boils, the urine should always be examined. Irrespective of any such disease as diabetes, albuminuria, and the like, the most successful plan of treatment consists in the administration of tonics, especially iron, cod-liver oil, strychnin, and similar remedies. Occasional laxatives are of value. The digestion should be considered, and if disordered, the necessary treatment instituted. Recently fresh brewer's yeast, a teaspoonful to a tablespoonful, three times daily, has been again brought forward as a valuable remedy by Brocq,[1] Gordon,[2] Turner,[3] and others.[4] Purdon[5] speaks favorably of lactophosphate of lime, and Duhring of sodium hyposulphite. Wright and a few others have recently reported good results in furunculosis, from injections of antistaphylococcic serum or "vaccine," the dose and frequency to be regulated by the opsonic index of the blood (see "Opsonins," p. 108).

[1] Brocq, *La Presse méd.*, 1899, p. 45 (with review of past literature).
[2] Gordon, *Philada. Med. Jour.*, April 1, 1899.
[3] Turner, *Therapeutic Gazette*, Mch. 15, 1899.
[4] Aragon and Coutourieux, *Bull. méd.*, July 5, 1899.
[5] Purdon, *Dublin Jour. Med. Sci.*, Feb., 1898.

The local management of the disease is of importance, and its success depends upon thoroughness. Absolute cleanliness is essential, and for this purpose frequent washings, at least once daily, with soap and water should be enjoined; and in multiple or recurrent cases the tincture of green soap may be used for this purpose, with 5 or 10 grains (0.33–0.65) of resorcin to the ounce (32.). The beginning formation may sometimes be aborted by the injection of a few drops of a 5 per cent. solution of carbolic acid into the lesion, or frequent painting of the overlying skin with the same solution; touching with nitrate of silver and other similar plans have also been variously recommended. I have rarely had recourse to these methods in recent years, as they are, as a rule, without result. An ointment or aqueous solution of ichthyol, 25 per cent. strength, kept constantly applied, will succeed sometimes. It forms a good method of treatment of the lesion; when pointing has ensued, an incision and expression of the contents and its reapplication will hasten the final disappearance. While most boils will pass through their various stages and disappear satisfactorily without incision, this latter hastens the process. After incision and expression of the contents a good plan is to cleanse the cavity with hydrogen dioxid or the carbolic acid solution. Poultices are, as a rule, not to be employed. While they do relieve the pain and hasten maturation, I am convinced that the warmth and moisture favor the inoculation of nearby points. In addition to the ichthyol ointment and the soap-and-water washings, an application of an antiseptic lotion to the boil or boils and the entire affected region, night and morning, is a measure of considerable value in the management of the disease and the prevention of new lesions. Such a lotion is the following: ℞. Resorcin, gr. xv–xxx (1.–2.); acidi borici, ʒiss (6.); alcoholis, f℥j (32.); aquæ dest., f℥v (160.).

When the lesions are small, superficial, and close together, as not uncommon upon the back of the neck, and occasionally on the lower part of the leg, the free use of this lotion after thoroughly cleansing the parts with the tincture of green soap and water, and while still wet with it putting on a thick layer of boric acid powder and covering with a light dressing will often act satisfactorily; this is to be done once or twice daily. When, too, the lesions are on the neck region, it is possible that the scalp, especially the hair of the lower occipital region, may be the harboring place of the micro-organisms and give rise to recurrence; and the patient is, therefore, directed to wash this latter region thoroughly once daily, and the entire scalp at least twice weekly. The same is to be advised when the disease is on other parts, where the hair is in abundance, as in or about the axilla, genitalia, and anal region. With this plan of management—frequent washings and the general application of the above lotion and powder, and, in the larger and the maturing lesions, ichthyol salve application, incision when necessary, along with the indicated constitutional treatment—most of the recurrent cases, in these regions, yield comparatively rapidly. In especially rebellious cases phototherapy can be resorted to with hope of success, subjecting the part to repeated close exposure to a strong arc light.

CARBUNCULUS.

Synonyms.—Carbuncle; Anthrax; Anthrax simplex; Anthrax benigna; *Fr.*, Carboncle; *Ger.*, Carbunkel; Brandschwär; Kohlenbeule.

Definition.—A carbuncle is an acute, usually egg- to palm-sized, more or less circumscribed, flattened, phlegmonous inflammation of the skin and subcutaneous tissue, terminating in a slough which usually finds exit at several or more points.

Symptoms.—The first indications of the formation of a carbuncle consist in some local tenderness and subcutaneous induration, along with symptoms of constitutional disturbance, such as chilliness and malaise and febrile action, which, if the disease is situated about the face, or if involving an extensive area, and especially if the patient is asthenic, may be of a severe character. Locally the induration becomes more pronounced, is somewhat flat, and consists of a firm dense infiltration of the deeper skin and subcutaneous tissue, with the overlying skin of a reddish tinge. It spreads laterally, and finally involves an area of several or more inches in diameter. It projects slightly above the surface, and extends deeply, is tense looking and of a dark-red color, which extends for some distance beyond the hardened area. After a variable time, usually some days, suppuration and softening take place, the skin at several or more points shows a tendency to thinning and discloses the yellowish-red pus beneath. These gradually open and give exit to a sanious pus. The many openings give the surface a cribriform appearance. Sloughing is noted at these openings, which slowly or rapidly become larger; the inclosed pus and necrotic tissue are gradually cast off, the cavities are filled with healthy granulations, and healing begins to take place. Or in other cases, as soon as the skin has broken through at several or many places, a sloughing of the whole mass ensues, which later falls out, and leaves a large and rather deep-cut ulcer, which gradually undergoes the reparative process and heals. Or, after reaching its acme, the whole mass may slough without previous opening. The necrotic process usually stops at the subcutaneous fascia, but in exceptional instances (Weber, Monnier) it goes much more deeply. The formation is painful, often of a dull and lancinating character. The disease area may, in extreme cases, involve a whole region. Especially in the latter cases, the constitutional symptoms are of a grave character. In some instances, particularly in the aged, septic poisoning ensues, and the patient gradually or rapidly succumbs. Instead of beginning as a subcutaneous induration a carbuncle may, as also observed in boils, begin as a superficial pustule, and may, in such instances, in its early stage, be apparently furuncular.

There is usually but one lesion present. The favorite sites are the nape of the neck and the upper part of the back. It is most common in middle age and advancing years, and most frequent in men. Several weeks or one or two months may elapse before recovery is complete.

Etiology.—The etiology of carbuncle is to be considered as essentially the same as that of furuncle; ill health from any cause, a depression of the vital forces, diabetes, and other constitutional diseases being predisposing. Added to the predisposing factor or factors

is the essential one of microbic invasion, the organism believed to be the same as in boil, and doubtless always the staphylococcus pyogenes aureus, although it is possible that other pus-organisms may at times be etiologic. There may be an invasion at many points in this malady, which results in the production of a lesion seemingly made up of a number of closely aggregated necrotic centers.

Pathology.—The pathology of this lesion is closely similar or analogous to that of a furuncle. The inflammation starts simultaneously from numerous points from the hair-follicles, sebaceous, and possibly sometimes also the sweat-glands, the inflammatory centers break down, and the pus finds its way to the surface; finally the process ends in gangrene of a part or of the whole area. It is not improbable in this, as well as in furuncle, that the vascular supply is shut off from both beneath and laterally by the intense inflammatory deposit, with resulting necrosis. The pyogenic micro-organisms are present in abundance in the tissues. Investigations have shown that the inflammation may also start deeply down from some point or points in the subcutaneous tissue. The pus forms, spreads laterally along the line of least resistance, the overlying skin becomes necrotic, and the pus finds its way to the surface along the line of the columnæ adiposæ and along the hair-follicles and erector pili muscles (Warren).[1] According to Winiwarter,[2] there is primarily tissue necrosis, with suppuration and fibrinous coagulation, and early thrombosis of the vessels.

Diagnosis.—Carbuncle differs from furuncle by its flatness, more extensive area, and its multiple points of necrosis and suppuration, and by the presence, usually, of constitutional disturbance of moderate or severe character. Erysipelas and phlegmona diffusa may also at times, more especially in the beginning, bear some resemblance. Conglomerate pustular perifolliculitis, a rare disease, involves a smaller area, is relatively superficial, and without systemic symptoms.

Prognosis.—Carbuncle is always a serious malady, and is not infrequently fatal in old people and those debilitated by disease or who have a grave underlying condition of ill health. About the face and head the outlook is still more serious. Septic poisoning is always a possibility; death from thrombosis or embolus has also occurred. Except in such instances as named, however, full recovery is to be expected.

Treatment.—The treatment of carbuncle comes usually under the care of the surgeon. Abortive treatment, by keeping the surface soaked in a strong antiseptic solution, usually 5 to 10 per cent. carbolic acid lotion, may exceptionally, in the very beginning, when the formation begins superficially, prove successful; likewise the application of ichthyol, pure or with two or three parts water. Mild cases, and even severe cases, are often successfully treated, as first advocated by Verneuil, by free injection of carbolic acid in glycerin or oil, 10 per cent. strength, at several or more points in the lesion; over this can be placed a thick covering of a 25 per cent. ointment of ichthyol, using equal parts of lanolin and zinc oxid ointment or spermaceti

[1] Warren, *Boston Med. and Surg. Jour.*, April 17, 1877; *Columnæ adiposæ, with their Pathological Significance in Carbuncles*, etc., Cambridge, Mass., 1881.

[2] Winiwarter, "Furunkel und Carbunkel, *Chirurgische Krankheiten der Haut*, Stuttgart, 1892.

as a base. When the growth has broken down at a number of points, the pus and detritus may be partially drawn out by means of a cupping-glass, and the carbolized oil or glycerin injected into the cavities thus made, and over this the same dressing as above; or the cavities or openings can with advantage be first thoroughly washed out with hydrogen dioxid. The slough usually comes away in the course of several days or a week or so, and healing gradually ensues. Others (Woods, Taylor, Manley)[1] prefer a saturated solution of pure carbolic acid as less likely to be followed by absorption. Operative treatment has long been the favorite method; deep crucial incisions have long been in general use, and still have their advocates; and, more recently, crucial incision, supplemented by complete extirpation of diseased tissue by curet or knife (Riedel, Schleich, Parker).[2] In rapidly sloughing cases thorough curetting and the superimposing of an antiseptic dressing are advisable; ichthyol also serves well for this purpose.

The constitutional treatment of carbuncle consists in supporting the patient's strength with the administration of alcoholic stimulants, ammonium carbonate, strychnin, quinin, and iron. Wright's plan of opsonic treatment with antistaphylococcic vaccine might be worth a trial in extreme cases (see "Opsonins," p. 108).

PHLEGMONA DIFFUSA.

Synonym.—Phlegmonous cellulitis.

Phlegmona diffusa is a somewhat rare, more or less extensive inflammation of the cutaneous and subcutaneous tissues, which is similar to or closely allied to cellulitis and to erysipelas. It is of a rather ill-defined character, presenting a conglomerate symptomatology of deep erysipelas and later of extensive flat carbuncle. There are often prodromal symptoms akin to those observed in erysipelas: feeling of malaise, followed by a decided chill or by repeated rigors, with subsequent febrile action. There is usually sharp or dull pain at the site of the disease. It begins, as a rule, as a hard infiltration or lumpiness somewhat deeply seated, and is attended by a good deal of swelling and edema, which may involve considerable area. In the course of five to ten days some softening is observed, and the indurated swollen area gives place to bogginess and fluctuation. Or before this stage is so clearly reached there may be retrogression and a gradual disappearance of the swelling. In other cases a melting away or necrosis takes place. The purulent matter may burrow its way into surrounding tissues, involving these in the process; or there may be a gradual working toward the surface, and one or more openings may present, and discharge pus and the necrotic tissue. In favorable cases the disease then gradually declines. In severe and grave instances septic poisoning may ensue, the patient rapidly succumbing or sinking gradually from exhaustion. In these severe forms the constitutional symptoms continue from the very beginning. In favorable cases as soon as there is cessation of pus-formation,

[1] Woods, *Toledo Med. and Surg. Jour.*, 1880, p. 446; Taylor, *Austral. Med. Gaz.*, 1881–82, p. 34; Manley, *Med. Record*, June 18, 1898.

[2] Schleich, *Methode der Wundheilung*, Berlin, 1899; Riedel, *Deutsche med. Wochenschr.*, 1891, p. 845; Parker, *Brit. Med. Jour.*, Nov. 26, 1898, p. 1604.

febrile action, as a rule, ceases, and the patient gradually recovers. Depending upon the amount of surface necrosis, the scarring may be slight or extensive.

The malady is of a somewhat obscure nature. It is, as judged by kindred diseases, due to a micro-organism. It may be the ordinary pus coccus, with some unknown favoring conditions added. It is really a phlegmonous cellulitis, and is probably to be regarded, as suggested by some writers, as a deep form of erysipelas. It is similar or closely allied (Hyde and Montgomery) to the gangrène foudroyante of the French and to the acute purulent edema of English authors. Unna's investigations would indicate that the process is due to infection by the erysipelas coccus and pyogenic staphylococcus.

The disease varies in severity from comparatively mild form to a rapidly fatal variety. With cases of mild or moderate severity in healthy and vigorous subjects the result is almost invariably favorable; and even in some of the more extensive cases in such individuals the outlook is not hopeless. It is always to be considered, however, a dangerous affection. Constitutional treatment is to be of supporting character, as in erysipelas; local measures are essentially surgical, consisting of incision, thorough drainage, and the free use of antiseptics.

DISSECTION WOUNDS.

Several of the diseases described elsewhere in this book, such as erysipelas, impetiginous lesions from pyogenic cocci and the like, and various kinds of irritation from the chemicals employed in preserving or embalming, usually of an eczematous character and belonging to dermatitis venenata, are sometimes observed in those having to do with dead bodies; but the usual manifestations to which this title of dissection wounds is given are postmortem pustule and anatomic tubercle. As the latter is admittedly tuberculous, it will be elsewhere considered.

Postmortem pustule results from inoculation of some unknown virus from cadavers in the dissecting room or from postmortems; rarely it is seen in butchers and others who have to do with dead animals. There is a presupposed abrasion or break of continuity in the skin, often demonstrable, but occasionally scarcely recognizable, through which the poison enters. The lesion first presents itself shortly after exposure, as an itchy red spot, which soon develops into a vesicopustule or pustule having a slightly or markedly inflammatory base. It gradually dries, or, from breakage of the crust, the contents find exit; the crust closes over again, or the process goes on and it fills up again, usually becoming somewhat larger. This may continue slowly and repeat itself a number of times if uncared for, or it may finally dry up and disappear spontaneously. If the crust is removed, a superficial ulcer is disclosed. The formation is more or less painful and usually dull red in color, and not infrequently attended with swelling of the surrounding parts; occasionally red streaks extend along the line of the lymphatics. Exceptionally the region may present an erysipelatous aspect. In some cases slight or severe constitutional disturbance is present. In other instances the local lesion may remain insignifi-

cant, but is followed by some swelling and general septic symptoms of more or less gravity. The essential (bacterial) cause of the disease is not known.

Treatment consists in opening the pustule, removing the crust, cleansing with hydrogen dioxid, and the use of wet antiseptic corrosive sublimate dressings; or a powder of iodol or a powder of 3 parts boric acid and 1 part acetanilid can be freely applied. If any virulence is displayed, the base of the lesion should be previously cauterized and the subsequent treatment be as above. Constitutional treatment is rarely called for, and its character would depend upon indications.

EQUINIA.

Synonyms.—Glanders; Farcy; Malleus; *Fr.*, Morve; Farcin; *Ger.*, Rotz; Rotzkrankheit.

Definition.—An inoculable acute or chronic disease of malignant type, derived from the horse, mule, or ass, and characterized by grave constitutional symptoms, inflammations of the nasal and respiratory passages, and a vesicopustular, papulopustular, or deep-seated tubercular or nodular ulcerative eruption.

Symptoms.—The site of the inoculation may be on exposed parts through any break or lesion of the skin, or it may gain access through the mucous membrane of the eye, nose, mouth, or respiratory tract. Its port of entrance is not always ascertainable. A few days to several weeks after inoculation general symptoms of malaise, fever, rheumatic pains, and possibly chills or chilliness are noted. The local symptoms at the point of inoculation are somewhat varied. The spot may heal up and break down again, a decided phlegmonous inflammation may show itself, or a small inflammatory, dark-red papulopustule arises and may break down into an unhealthy-looking ulcer, which tends to spread. Inoculation of the mucous membrane of the eye or nose may lead to destruction of the part, which usually not only extends deeply into the soft tissue, but may involve the bony structure. Along with the symptoms at the site of the inoculation and the advent of systemic disturbance, or somewhat later, the general surface, or parts of it, as well as the mucous membranes, becomes the seat of somewhat flattened vesicopustules, small or large nodules which break down and form ill-conditioned, foul ulcers, which increase in size and may involve considerable tissue. Large nodules (so-called farcy buds) may appear deep down in the tissues, in the lymph-glands, and the lymphatic channels may be thickened. Some may melt down and give rise to abscesses and extensive destruction. The mucous membranes may also show lesions of similar but smaller character, more especially the mucous membrane of the nose, the latter being affected in a large number of cases. These are apt to undergo the same destructive changes as those upon the skin. There is at first a good deal of mucoid or catarrhal discharge from the nose, somewhat viscid, which may later be mixed with pus and blood. In some instances the brunt of the manifestations is upon the mucous membranes, not only of the parts named, but also of the intestinal tract. The constitutional symptoms may vary, but in the acute cases the febrile action is

usually continuous and becomes more marked, the symptoms of general sepsis are added, and the patient succumbs.

The chronic cases differ often considerably from the acute. The lesions may be scanty in number, develop and undergo changes less rapidly, and the accompanying constitutional disturbance is less marked. The characters of the acute type may supervene, and the patient rapidly die. The duration of the chronic disease may be months or longer. Death usually results from marasmus or renal complication (Besnier). If recovery takes place, the ulcers gradually heal and other symptoms abate. Exceptionally apparent recovery is noted (Hallopeau), which may last a year or more, followed finally by recrudescence and death.

Etiology and Pathology.—The disease is rarely seen in this country. It is usually contracted from horses, and is seen chiefly in those who have to do with these animals. Its transmissibility from man to man has also been noticed in some instances. The direct cause is the glanders bacillus (bacillus mallei), similar but smaller than the tubercle bacillus, and found in all lesions, the blood and other tissues (Schütz and Löffler, Bouchard, Capitan, Charrin). The lesions are made up of round-celled granulation tissue, which, as in all the granulomata, is unstable and breaks down readily.

Diagnosis.—The diagnosis is not always easy in the earliest period, but after the cutaneous manifestations, nasal discharge, and mucous membrane lesions have presented, the picture is sufficiently characteristic. In the earliest stage it has been mistaken for rheumatism and typhoid fever. The chronic disease may bear some resemblance to tuberculosis and syphilis. Now that the cause is known, in suspected cases microscopic examination should be made for the bacillus, staining with methylene-blue; or inoculation experiments may be made.

Prognosis and Treatment.—Acute cases almost invariably end fatally within six weeks, and some early in the attack, and even before the skin-lesions appear; the chronic disease is fatal in about half the cases.

Treatment is purely empirical, the strength being supported, and the lesions treated surgically and antiseptically. It is possible that the toxins—mallein—of the bacilli may prove of service; in one case (Bonome)[1] subcutaneous injections had a very favorable influence.

PUSTULA MALIGNA.

Synonyms.—Anthrax; Anthrax maligna; Malignant pustule; Splenic fever; Carbuncle; *Fr.*, Charbon; Pustule maligne; *Ger.*, Milzbrand; Milzbrandcarbunkel.

Definition.—Malignant pustule is a furuncle- or carbuncle-like gangrenous lesion resulting from inoculation with the bacillus anthracis, and usually accompanied with constitutional symptoms of more or less gravity.

The general infective disease (splenic fever) in which the bacillus gains access through other channels than that of the skin will not be considered.

Symptoms.—The lesion, almost always single, is seen commonly

[1] Bonome, *Deutsche med. Wochenschr.*, 1894, p. 703.

on exposed parts, usually the hand or the face, and, according to Korányi,[1] who has given a good deal of study to this disease, has an incubation period of from one to three days. The disease begins with slight burning and itching at the point of inoculation, and the appearance of a slight reddish papular elevation, which grows larger. These symptoms are, in fact, similar to those frequently observed after an insect-bite. In the course of a few hours or a day or so, or more rapidly in some instances, a vesicle or bleb forms on the summit, the contents of which may quickly become bloody or purulent, and intense inflammatory infiltration ensues, which may involve considerable area. It soon ruptures, showing a depression, in and around which is disclosed a blackish eschar, which may increase in extent. The surrounding induration and swelling become more marked and extensive. Around about the central depression and eschar, on the swollen and inflammatory base, groups or a chain of vesicles form, and the surrounding tissue may become still more swollen, tense, and infiltrated. The near-by glands and lymphatics are affected. The central gangrenous or escharotic area may enlarge, grave symptoms and complications of general infection supervene, and death result; or the process halts, and the gangrenous area is cast off, leaving a cavity, as in carbuncle, and the reparative process begins. As a rule, general infection in man follows only in a minority of cases.

Instead of the symptoms here outlined, inoculation may be followed by intense edema and swelling of livid color, which soon involves a large area, with surface bleb-formation and gangrenous destruction at several or more points, with usually rapid systemic infection and death, within a few days to one or two weeks.

Etiology and Pathology.—The cause of the malady is the bacillus anthracis, discovered by Pollender, which is conveyed to man from infected animals, directly or through the mediation of flies or other insects; or from the hides, hair, etc., of animals that have died of the disease. The last method seems most common. In animals it is usually observed in the herbivora, being uncommon in the carnivora. In man the disease is met with in those who have to do with cattle, and those who have to work in their products, such as slaughterers, tanners, wool-sorters, etc. Ravenel[2] reports an outbreak in which as many as 12 men and 60 head of cattle died of the disease near tanneries (in Pennsylvania) in the course of a year; the men were operatives at the tanneries, while the cattle were on pastures watered by the streams carrying off the refuse from these tanneries. Goldschmidt[3] and Merkel[4] have reported cases occurring among the employees

[1] Korányi, "Der Milzbrand," Wien, 1897, in Nothnagel's *Specielle Pathologie und Therapie*, vol. v., 1, Wien, 1900. This contribution is a complete and exhaustive exposition of the subject, with full bibliography and several cuts, a few of which are colored.

[2] Ravenel, "Anthrax—The Influence of Tanneries in Spreading the Disease," *Philada. Med. Jour.*, April 22, 1899 (with experiments as to the effects of tanning solutions on the germs in the spore stage).

[3] Goldschmidt, *Verhandl. der Gesellsch. der Naturforschen und Aerzte*, Nürnberg, 1893 (Leipzig, 1894), p. 428.

[4] Merkel, *ibid.*, p. 432; Jopson and Ghriskey, *Trans. Philada. Patholog. Soc'y for 1899* (Dec. 14 meeting), also report a case in a morocco worker, and give a brief review of the subject, with some references.

See also De Langenhagen, "Relation de plusieurs cas de pustule maligne chez l'homme coexistant avec une épizootie charbonneuse," *Annales*, 1899, p. 705.

of brush factories. The disease, for obvious reasons, is most commonly seen in male adults.

Inflammatory reaction of the most intense character, as described, is found following the inoculation of this germ. The usual signs of such process are to be found, and in the advanced lesion are closely similar to carbuncle. According to Korányi, Unna, Ziegler, and others, the process is essentially a serofibrinous inflammation, leading rapidly to necrosis, the microscopic appearances varying according to the stage at which the lesion is examined. Unna[1] found in a fresh anthrax nodule of the lip covered with vesicles that the development of the bacillus had taken place in the form of a flat area at the level of and around the subpapillary vascular net, and penetrating into the papillary body above and the epidermis; in this region the whole cutis is swollen, and the bacilli lie so closely that their number must be reckoned by thousands; there were found a marked dilatation of the blood-vessels and a severe interstitial edema of the skin and hypoderm, the escaped lymph in many places formed into fibrinous nets. The bacillus is rod-shaped, and multiplies rapidly; in the body it multiplies by fission; in culture the rods may develop into filaments, undergoing segmentation and producing spores. These retain their vitality for a long time.

Diagnosis.—The appearance and subsequent rupture of the vesicle or bleb, the central depression and eschar, the rapidly developed ring of vesicles or blebs around this necrotic center, with the surrounding induration and swelling, make up a typical picture which is scarcely mistakable. In its very earliest stage it might be mistaken for a beginning boil or carbuncle, but the above features would serve as differential points. Poisoned wounds and facial chancre are also to be excluded. The latter is relatively indolent, with no gangrenous tendency and with no febrile constitutional symptoms. Occupation of the patient may give a clue. In doubtful or suspicious cases a microscopic examination for the bacillus should be made immediately. Some of the liquid from the pustule can be dried on the cover-glass or slide or piece of glass, stained, and examined. A simple staining fluid may be easily improvised by dissolving a piece of anilin blue pencil in water; the bacilli are so large that they may be easily seen with an ordinary high-power lens (D. W. Montgomery).

Prognosis.—The disease is always of serious import, but with an early diagnosis and prompt treatment most cases of malignant pustule recover. The cases in which intense and extensive edema follows inoculation, without much initial change at the point of inoculation, are usually fatal, as active measures of treatment cannot be so well and satisfactorily carried out. In any case if there is grave systemic involvement, showing that the bacillus and the ptomains or other septic material have gained access to the general circulation, the outlook is involved in doubt. The mortality seems variable in the groups of cases observed, apparently indicating that there may be some difference in the virulence of the bacillus at different times or from surrounding conditions. Thus in Goldschmidt's

[1] Unna, *Histopathology*, p. 456.

cases, 30 in number, there were only 3 deaths; in Müller's[1] 13 cases not a single fatality; on the other hand, according to the statistics of Nasarow,[2] among 180 cases 17 per cent. died.

Treatment.—The consensus of experience indicates that the best plan is excision of the entire diseased area, going well beyond the border, done under antiseptic precaution to prevent reinfection; subsequently the ordinary treatment of open wounds, antiseptics being freely employed, such as weak corrosive sublimate solutions. The injection of iodin tincture or 5 per cent. solutions of carbolic acid at five or six points around the border has proved successful, repeated after several hours if the process is unchecked. Such injections, with free incisions and the application of pure or dilute carbolic acid, have been employed in the markedly edematous cases. Carbolic acid poisoning must be watched for. On the other hand, Müller had good results in his cases by a purely expectant treatment.

Constitutional treatment should be with sodium sulphite or hyposulphite, and quinin in large doses, and alcoholic stimulants and ammonium carbonate as supporting measures if indicated, and other appropriate remedies as special conditions may demand.

ERYSIPELAS.[3]

Synonyms.—St. Anthony's fire; *Fr.*, La rose; Feu sacré; Érysipèle; *Ger.*, Rothlauf; Rose; Hautrose; Wundrose.

Definition.—Erysipelas may be defined as a specific inflammation of the skin and subcutaneous tissue, most commonly of the face, characterized by shining redness, swelling, edema, heat, and a tendency, in some cases, to vesicular and bleb-formation, and accompanied by more or less febrile disturbance.

Symptoms.—Cases of moderate severity are usually preceded for several hours to one or two days by prodromic symptoms of con-

[1] Kurt Müller, "Der Aeussere Milzbrand der Menschen," *Deutsche med. Wochenschr.*, 1894, pp. 515 and 534.

[2] Quoted from Jarisch, *Die Hautkrankheiten*, Wien, 1900, p. 466.

[3] Some pertinent literature: General: Hutchinson, *Archives of Surgery*, vol. v., 1894, p. 300; vol. viii., 1897, p. 1; Allen, *Medical News*, 1899, i., p. 426; Kaposi (report of investigating committee of erysipelas in General Hospital, Vienna, 1882-84), *Wien. med. Wochenschr.*, 1887, Nos. 30 to 35, and full résumé in *Archiv*, vol. xx., 1888, p. 250.

Etiology and pathology: Fehleisen, *Die Aetiologie des Erysipelas*, Berlin, 1883; Pawlowsky (concerning specificity of streptococcus, with some experiments as to the action of certain drugs upon it), *Berlin. klin. Wochenschr.*, 1888, p. 255; Leroy (showing persistent vitality of streptococcus), *La Gazette Médicale de Montreal*, January, 1890; Pfahler (cases apparently due to other coccus), *Philada. Med. Jour.*, January 13, 1900; Guarnieri (autopsy showing general streptococcic infection), *Archivio per le scienze*, 1887, No. 2—abs. in *Annales*, 1888, p. 249; Denucé, *Etude sur la pathogenie et l'anatomie pathol. de l'erysipèle* (showing general infection), Paris, 1885.

Treatment—Antistreptococcic serum: Marmorek, *Compt. Rend. Soc. de Biol.*, 1895, p. 230, and *Annales de l'Institut Pasteur*, 1895; André, *Archives de Med. et de Pharmacie militaires*, 1898, p. 340; Cotton, *Boston Med. and Surg. Jour.*, 1899, i., p. 105; Bristow, *New York Med. Soc'y's Trans.*, 1899, p. 382; Baum, *Medicine*, 1899, p. 23. These four papers are all valuable as showing the present status of this remedy, and give literature references; Cotton gives full bibliography.

Ichthyol: Unna, *Aerztl. Vereinsblatt für Deutschland*, 1885, No. 158; Fessler, *Klinische-experimentelle Studien über Chirurgische Infectionskrankheiten* (clinical and experimental evidence of action of ichthyol), Munich, 1891; Jamieson, *Brit. Med. Jour.*, Aug. 6, 1898.

stitutional disturbance, such as malaise, chilliness, nausea, and sometimes vomiting; a decided rigor or feeling of chilliness, with ensuing febrile action, is rapidly followed by the appearance of the cutaneous eruption. This latter may develop rapidly, soon involving an area the size of a palm or larger, or its evolution is more gradual. It frequently begins at one point, usually where there has been a break in the continuity of the skin; an area of a dime to dollar size is first noticed, elevated, swollen, red, and shining, with a glazed appearance; there is a feeling of burning, often some tenderness, and sometimes a variable degree of itching. The border is sharply defined, elevated, and bright red, usually scarlet red; it spreads gradually or rapidly by peripheral extension, and in some cases there may arise new points of infection near by, spread and merge into each other. In the course of several days to a week the disease has usually reached its acme, and may then cover a great part of the face or the entire region. On the face it often stops at the edge of the hair or beard. The parts are elevated, much swollen, and somewhat tense, with the peculiar shining dark-red surface; or there may be the formation of vesicles and blebs, which in some cases may subsequently become purulent; exceptionally the part may be partially undermined with serous effusion. In other instances the deeper parts are involved seriously, and some sloughing may ensue. Hutchinson has observed cases in which the characteristics of erysipelatous inflammation are not always present together; the florid congestion may exceptionally be lacking, the edematous swelling practically constituting the disease, and to which the term "white erysipelas" could be well applied.

When the erysipelas involves a limb or part of the body other than the face, there may be some extension in the form of streaks along the line of the lymphatics. The constitutional symptoms are of various grades from slight to grave, with the temperature elevated one to several or more degrees above the normal, according to the extent and severity of the disease. The temperature is highest toward night; a marked exacerbation usually signifies renewed activity or a new area of disease. Occasionally the temperature is subnormal. In severe cases delirium or stupor may be present, and grave complications of other organs sometimes occur, probably due to toxin poisoning or to general streptococcic invasion.

After remaining a few days stationary, the process begins to subside, the swelling becomes less pronounced, the redness goes into a brownish red, and later yellowish and yellowish-white shade, the constitutional symptoms abate, and the disease at the end of ten days to a few weeks is practically at end. Desquamation ensues, slight or marked, according to the severity of the process. When there has been pronounced vesicular or bullous development, these dry into crusts, which finally fall off, leaving behind temporarily a reddish surface, which gradually fades.

In some instances as the disease spreads at the periphery the older part clears permanently or again lights up. Or the disease may appear at a site close by or somewhat distant from the original point of infection. Thus the case may go on for several weeks or longer,

constituting that variety known under the name of **erysipelas ambulans**, or **erysipelas migrans.** This rare recurrent ambulant type is sometimes designated chronic erysipelas, although this term is also often given erroneously by laymen, and occasionally by practitioners, to cases of chronic eczema.

While the face is the most common site of erysipelas, and the one of chief interest to the dermatologist, other parts are also not infrequently the seat of the disease; in the latter instances usually starting from some injury or succeeding a surgical operation. That on the face may extend over the entire scalp and may even push into the mouth and throat and nose, or exceptionally may have its starting-point in the latter regions, and may, indeed, in rare instances be limited to these and neighboring mucous membranes (Arnott, Mosny, Porter). In the extreme examples of this class the head, face, ears, lips, and mouth are much swollen, and the patient disfigured beyond recognition. In a large majority of the cases observed by dermatologists in skin dispensaries the disease is of a somewhat slight and limited character; usually starting at some point of the face, or not infrequently at or just within the nasal orifice, it may involve only an area of a few inches, lasting two or three days and then rapidly beginning to subside, with or without desquamation. The constitutional symptoms in such walking cases are mild, sometimes scarcely noticeable, but there may be temperature elevation for a few days of one to three degrees and yet the patient persist in going about his employment.

Etiology.—The disease is both contagious and infectious, at times to a marked degree, at other times apparently scarcely at all. There are probably three causes operative in erysipelas—essential, contributory, and predisposing. The essential cause is now believed to be a specific streptococcus, the streptococcus of Fehleisen. That the essential cause may consist of varieties of micro-organisms other than this streptococcus is not beyond dispute; in 8 cases investigated at the Philadelphia Hospital presenting all the symptoms of erysipelas a special diplococcus was noted differing from the streptococcus of Fehleisen (Pfahler), and Hajek has found that the disease may be caused by the pyogenic organisms. The contributing cause, as an abrasion, prick, or slight injury, a lesion of continuity of the skin, may doubtless be almost considered essential, although it is not always demonstrable. Infection may, indeed, take place through the mucous membrane of the mouth, throat, or of the nose, possibly through a break or abrasion, or from some pent-up pus-collection. A not uncommon point of infection in dermatologic experience is a sycosiform inflammation just inside the nostril orifice. Frequently this latter produces but a small erythematous and moderately swollen area, starting at the nose and extending slightly toward the eye and cheek, which in many instances can scarcely be called true erysipelas; in others, however, a distinct erysipelatous area arises, and in others again a typical, somewhat extensive, development of the disease ensues. Ulcers, excoriations, abrasions, a nasolabial fissure, ear-piercing, injuries of various kinds, may all be instrumental in the development of the disease.

As predisposing causes may be mentioned a poor condition of the health, general debility, alcoholism, or failing health from organic disease; in fact, anything which depresses or weakens the vital forces and lessens the resisting power of the organism. Age seems to be in a measure of etiologic import, the disease being much more common in those between twenty to forty and rather unusual in the young or old.

Anders,[1] from a study of his tabulation of 2010 collated cases, extending over a period of twenty years, shows that seasonable influences must be counted in considering the etiology of the disease. August gave the fewest cases, and from then there is a gradual monthly increase until April is reached, which gives the largest number, and then follows a rapid decrease. One-half of the cases occurred in February, March, April, and May, April giving sixteen (15.9) per cent. It was further found that a low barometer and mean relative humidity invariably correspond with the annual period in which the greatest proportion of cases occur and the highest mean relative humidity with the months affording the fewest attacks.

Pathology.—Unna's investigations show that the typical erysipelatous inflammation of the cutis is purely of a serofibrinous nature, which may result in necrosis, the specific germ being the sole pathogenic factor. One attack of the disease does not protect against other attacks; on the contrary, it becomes a predisposing factor of some import. Doubtless this may be due to the fact that some of the micro-organisms may remain in the integument (Besnier, Hutchinson, Allen, and others). Maclachlan[2] believes, from his observations, that succeeding attacks become milder and milder.

There is nothing strikingly peculiar in the histologic findings. The disease is really an infectious dermatitis, involving the integument and deeper parts. There is a variable amount of serous exudation into the skin and subcutaneous tissues, some deposit of fibrin and swelling of the connective-tissue fibers, and enlargement of the blood-vessels and lymphatics. In hairy regions the serous exudation involves the follicles and hair-sheath, and may result in extensive or complete hair fall. The corium is invaded, in severe cases, by the streptococci, especially the lymph-spaces, and this invasion may extend down into the subcutaneous tissue. Unna finds that in every case the hypoderm swarms with cocci. In rare instances general invasion has been observed—streptococci being found in various organs (Guarnieri, Denucé, Lukowsky). Metschnikoff found an inverse proportion between the collection of leukocytes and the proliferation of cocci in the skin, which he viewed as a warfare between these two powers. The serous exudation may be so rapid, especially in points or places, that vesiculation or bleb-formation ensues. Repeated attacks are apt to leave a permanent thickening of the skin, especially when on the legs.

Diagnosis.—The diagnosis of erysipelas is rarely attended with difficulty, especially when it occurs upon the face and after surgical

[1] J. M. Anders, "Seasonable Influence in Erysipelas, with Statistics," *Trans. Amer. Climatol. Assoc.*, vol. x., 1893–94, p. 43.

[2] Maclachlan, *Edinburgh Med. Jour.*, Aug., 1899.

injuries. The important diagnostic points are the character of the onset, the shining redness, the swelling, the sharply defined elevated border, and the accompanying constitutional disturbance. The diseases which at times resemble it, especially in its beginning, are phlegmona diffusa, erythemata, acute eczema, and dermatitis. Those most likely to give difficulty are the latter two. Dermatitis from poison-ivy or from some drugs, such as iodoform, may at first present a somewhat similar appearance, but this lacks the sharply defined border, is usually free from any constitutional disturbance, and may start simultaneously from several points. Acute eczema also lacks the sharp elevated border, rarely develops from a single point, and is attended by marked itching, and, except in infants and young children, is seldom accompanied by any pronounced systemic disturbance. In fact, erysipelas is so distinct a malady that it ordinarily admits of ready diagnosis, and is rarely to be confused with other disease, except with anomalous examples of the several affections mentioned. In doubtful cases several hours' or a day's observation is usually sufficient to solve the difficulty.

The slight and limited erysipelatous swelling consequent upon a chronic folliculitis of the nasal fossa, while it may develop into true erysipelas, can scarcely be invariably looked upon as of such nature, but rather an erythema due to pus-absorption.

Prognosis.—Erysipelas is, under proper management, not often a fatal disease, a factor which is not sufficiently taken into consideration when estimating particular claims made for the various remedies usually employed, all of which belong in the class of antiseptics, and therefore appropriate for the treatment. Extensive and especially the deep-seated cases, with grave systemic disturbance and high fever, and those of distinctly septic type, are to be looked upon as of possible fatal ending. Erysipelas which invades the entire scalp is also to be considered dangerous. Arising after severe injuries or operations, it is also to be viewed as of possible serious portent, occurring, as it does, in one probably already debilitated and with lessened resisting power. In alcoholics and those with nephritic disease the prognosis is also of greater gravity. On the other hand, the mild and moderate cases, which make up the largest number, usually run a somewhat rapid favorable course. Depending upon the extent and severity of the disease, its course is run in from one to several weeks. In those instances in which there is a continual cropping out of new areas the duration may be somewhat prolonged, but, except in severe cases, more than a month's continuance could be considered rather uncommon. Loss of hair is usually replaced.

Treatment.—The constitutional treatment of erysipelas consists in the administration of remedies of a tonic, stimulating character, plain but nourishing food,—chiefly milk in severe cases,—and the use of drugs with alleged specific properties. In this latter class tincture of the chlorid of iron and quinin are those, especially the first, which have the greatest support. As routine practice it is well to advise both these remedies, the former in doses of 15 to 40 minims (1.–2.65), the latter, 2 to 3 grains (0.13–0.2), along with moderate doses of strychnin, three to five times daily, according to the severity of the attack. Other remedies for special conditions or complications

will suggest themselves. In great depression alcoholic stimulants and ammonium carbonate are of value. Favorable results in grave cases from a few injections of antistreptococcic serum—about 10 c.c. at an injection—have been reported (Marmorek, Cotton, Robinson, André, Bristow, Baum, and others).

After all, the external treatment is probably of greatest importance, especially if the accepted theory of the cause of the disease is considered. In most of the cases it alone would suffice. Many remedies have been variously advised, but they may all be included under the head of mild antiseptics. Along with the remedial applications the larger vesicles and the blebs should be opened from time to time. When involving the scalp, cutting the hair is an advantage, and in severe cases should always be done. A simple and strongly advised application is a 1 per cent. lotion of carbolic acid, made with equal parts of water and alcohol (White). Ichthyol as an ointment or aqueous solution of 10 to 25 per cent. strength has probably, at the present time, the greatest number of supporters (Unna, Nussbaum, Jamieson, Allen, Elliot, and others), and to the value of which I can warmly subscribe. The lotion is applied similarly to the above; the ointment spread upon patent lint or other fabric, and applied as a plaster, changing one to three times daily, according to the condition. The ointment is more grateful to some patients, and more suitable for those cases in which, especially in the later stage, there is crust-formation. The base of the ointment can be petrolatum, or equal parts of lanolin and cold cream, stiffened, if necessary, with wax or spermaceti. These several plans have afforded me good results in all the cases met with, although in most of the patients the disease was of a mild grade.

The extension of the process can seemingly be sometimes prevented by painting over the bordering skin an inch-wide band of a strong solution of silver nitrate or of iodin tincture.

The milder cases of surgical erysipelas can also be treated satisfactorily with the above remedies, but for the treatment of the more severe cases of this class the reader is referred to works on surgery.

There are many other remedies and methods, such as sodium salicylate solution (1 : 20) compresses (Besnier, Hallopeau), 1 per cent. picric acid solution, kept constantly applied (Cavelli, Tassi), and frequent local baths of 95 per cent. alcohol (Behrend). Pawlowsky's laboratory experiments show that this last rapidly destroys the streptococcus.

ERYSIPELOID.[1]

Synonyms.—Erythema migrans; Erythema serpens (Morrant Baker).

This affection, first clearly described by Morrant Baker, and later studied clinically and bacteriologically by Rosenbach, is rare,

[1] Literature: Morrant Baker (under the name "Erythema serpens"; based upon 16 cases, with colored plate), *St. Bartholomew's Hospital Reports*, vol. ix., 1873, p. 198; Rosenbach, *Verhandl. der Deutschen Gesellschaft für Chirurgie*, vol. xvi., 1887, p. 76 of part ii.; Elliot, *Jour. Cutan. Dis.*, 1888, p. 12. Tilbury Fox, under the title "Erythema of the Hands from Dyes" (*Brit. Med. Jour.*, 1870, p. 132), described 2 cases which seem to be examples of this disease, one in a patient who handled kid shoes, and the other in a clothing dealer.

and clinically bears a slight resemblance to erysipelas, lacking the constitutional and the more violent local symptoms of the latter. It is observed in those who handle putrid or spoilt meats and fish, such as butchers, fish-dealers, poultry-dealers, and cooks, and occasionally with those who handle animal products. For obvious reasons it is almost invariably seen on the fingers and hands, although Elliot refers to a case in which the disease was conveyed from the hands to the toes by scratching. It is, as a rule, observed to follow some slight traumatism or break in the continuity of the skin, the disease starting from this point. It consists, at first, of a dull red or purplish spot or zone, scarcely elevated, which tends to spread; as it spreads the first part involved usually clears up. If infection takes place at several points, many zone-like erythematous areas may merge into each other, presenting then an eruption of a festooned character. The advancing border of the erythema is sharply defined against the surrounding skin, and is slightly elevated, and commonly purplish red or even livid in color. Sometimes some swelling and puffiness are noted. There may be itching and burning, and these symptoms are sometimes marked. Its progress is slow, and it rarely involves much area, remaining limited to a finger or small part of the hand. Subsiding, the color changes to a yellowish, and finally disappears. There is no scaliness.

The disease is, according to Rosenbach, due to a micro-organism which is found in dead or decomposing animal matter, and probably of the family of cladothrix, from cultures of which the malady has been experimentally produced. Gilchrist[1] found no organisms. Experiments with smears were negative, and atttempts to produce the disease by experimental inoculation were likewise negative. He believes that the disease is probably produced by a special ferment. In almost all of his cases the disease had followed crab-bites. It is to be distinguished from erysipelas and ringworm, but the absence of the more inflammatory and the constitutional symptoms of the former and the elevated and often vesicopapular and subsequent scaly border of ringworm will serve to differentiate. It could scarcely be confounded with dermatitis repens or erythema multiforme; in the former there is serous undermining, the upper epidermis separating from the rete, and in the latter the eruption presents other symptoms and is usually extensive.

The disease tends to spontaneous disappearance in from one to several weeks, but its course may be influenced by treatment, which is usually rapidly successful, as the nature of the affection would indicate. Treatment consists of antiseptic dressings, of which those employed in erysipelas are the most satisfactory, especially the ichthyol applications.

[1] Gilchrist, *New York Med. Rec.*, 1896, vol. xlix., p. 783, and *Jour. Cutan. Dis.*, 1904, p. 507 (erysipeloid, with a record of 329 cases, of which 323 were caused by crab-bites or lesions produced by crabs), reviews the literature, with references.

SPHACELODERMA.

Synonyms.—Dermatitis gangrænosa; Erythema gangrænosum; Spontaneous gangrene of the skin.

Sphaceloderma, or dermatitis gangrænosa, is a term applied to various cases of cutaneous disease in which gangrene is the essential and constant feature. The predisposing causes are doubtless many and diverse. There is a constitutional factor, such as neurasthenia, hysteria, diabetes, sepsis, systemic infection, and central nervous disease and the like. In addition there is, in all probability, a local microbic element. The condition is a rather rare one, and the size, behavior, character, extent, and distribution of the lesions vary somewhat in the different instances. The propriety of considering the several varieties under separate heads is, in my judgment, a questionable one, as there is, doubtless, a close analogy, especially as to the infantile type, adult type, and diabetic type, the underlying factor being diverse, but the essential local factor probably identical.

DERMATITIS GANGRAENOSA INFANTUM.[1]

Synonyms.—Varicella gangrænosa (Hutchinson); Pemphigus gangrænosus; Multiple cachectic gangrene; Infantile gangrenous ecthyma; Multiple disseminated gangrene of the skin in infants; Rupia escharotica; *Fr.*, Ecthyma térébrant; Ecthyma infantile gangréneux; *Ger.*, Ecthyma gangrænosum.

Definition.—Dermatitis gangrænosa infantum may be defined as a gangrenous eruption observed in children and infants, arising spontaneously or following other vesicular or pustular eruptions, more especially varicella and vaccinia.

Symptoms.—A large number of the cases of this rare disease, first clearly described by Hutchinson, and later by Crocker and others, have followed varicella. The vesicles, instead of drying up and disappearing in the usual manner, become crusted centrally, often with a pustular border, and surrounded with an inflammatory areola. Ulceration begins beneath the crust and may also take place peripherally, resulting in a grayish or grayish-black eschar. Closely contiguous lesions may become confluent and form an irregular ulcer of some size and depth. After a variable time these eschars begin to separate, showing shallow or deep-seated ulcers, finally drop off, and leave behind a rounded or oval shallow pea- to dime-sized or

[1] Literature: Hutchinson, "On Gangrenous Eruptions in Connection with Vaccination and Chicken-pox," *London Med.-Chirurg. Soc'y Trans.*, 1882, p. 1, with plate (this writer also refers to it briefly in *Rare Diseases of the Skin*, p. 235); Stokes, "A Case of Vaccinia Gangrænosa," *Dublin Jour. Med. Sci.*, June, 1880; Howard, "A Case of Gangrenous Varicella," *Brit. Med. Jour.*, May 12, 1883, p. 904; Atkinson, *Amer. Jour. Med. Sci.*, Jan., 1884; Crocker, "Multiple Gangrene of the Skin in Infants and Its Causes," *London Med.-Chirurg. Soc'y Trans.*, 1887, p. 397 (full account of his own cases and a review of others); Baudouin et Wickham, "Ecthyma térébrant des enfants," *Annales*, Dec., 1888 (with bacteriologic examination); Elliot, "Dermatitis Gangrænosa Infantum," *Med. Record*, May 16, 1891, p. 862; Ehlers, "Deux cas d'ecthyma térébrant des Enfants," *Annales*, 1891, p. 793; Hitschmann, Fritz, und Kreibich, "Pathogenese des Bacillus pyocyaneus und zur Aetiologie des Ecthyma Gangrænosum," *Wien. klin. Wochenschr.*, 1897, No. 50, and "Ein weiterer Beitrag zur Aetiologie des Ecthyma Gangrænosum," *Archiv*, 1899, vol. l., p. 81; Marshall (1 case), *Pediatrics*, Feb., 1898; Lipes, "Dermatitis Gangrænosa Infantum," *Albany Med. Annals*, Jan., 1900, p. 1.

larger superficial scar. As is to be expected, these escharotic lesions are most numerous in those regions upon which the varicellar eruption is most abundant. The disease has also been known to follow vaccinia, in which instances it takes its starting-point in the neighborhood of the vaccine pustule. Cases which arise spontaneously, without preceding exanthem, usually are seen first about the buttocks, and commonly appear as small papulopustules. The malady varies considerably in severity and gravity. In some the lesions are almost bullous, sometimes, especially in the grave cases, hemorrhagic. In others the eruption is comparatively mild and scanty. New lesions may appear from day to day for a few weeks or longer.

The constitutional symptoms, as a rule, bear relation to the cutaneous features. There may be high fever, vomiting, diarrhea, cardiac and pulmonary complications, and even septicemia. On the other hand, in mild examples, the systemic disturbance is not marked.

Etiology and Pathology.—The disease is rare, and is seen usually in debilitated and anemic infants and young children. It is observed in those under the age of three, most commonly in the first year, and more frequently in females. Tuberculosis and syphilis have both been alleged as possible causes, but an examination of the literature of the subject and my own scant observations would give but little credence to these factors. While it probably follows in most instances varicella, yet a number of cases have been observed which arose independently. It is doubtless due to some micro-organism, although there has been as yet no uniformity in the findings; Baudouin and Wickham found in a case examined by them the streptococcus pyogenes, but were not convinced of its pathogenetic importance. The bacillus pyocyaneus has considerable support (Ehlers, Hitschmann, Kreibich, and others). Some of these cases are classified by some writers under ecthyma.

Diagnosis and Prognosis.—The appearance of small vesicopustular or pustular lesions leading to crusting and tissue destruction in infants and young children leaves but little chance for an error in diagnosis. Syphilis should be excluded.

In very young infants, and especially those in which the lesions are numerous, with considerable destruction, the outlook is unfavorable. The advent of general septic symptoms, too, must be regarded as of serious import. On the other hand, many cases recover, even some of apparently very serious nature.

Treatment.—The constitutional treatment is to be tonic and stimulating, with abundant proper nourishment. The various remedies to be advised will depend upon circumstances; in short, the treatment is symptomatic and expectant. Sodium salicylate, opium, and zinc sulphocarbolate have each been commended.

As the disease is doubtless infective, the local management is to be of an antiseptic character. A 5 to 10 per cent. ichthyol ointment or lotion, a saturated solution of boric acid with 2 or 3 grains (0.133–0.2) of resorcin to the ounce (32.), washings with corrosive sublimate solution, about 1 : 2000, are all satisfactory. Aristol or boric acid powder, with 10 to 20 grains (0.65–1.33) of acetanilid to the ounce (32.), may be used to dust over the ulcerations.

MULTIPLE GANGRENE OF THE SKIN IN ADULTS.

This term is employed to include several similar manifestations of cutaneous gangrene, not dependent upon an underlying diabetes, which have been variously described under the name of **spontaneous gangrene of the skin, disseminated gangrene, hysteric gangrene, gangrenous zoster, and dermatitis gangrænosa.**[1]

Doubtless some of the instances of gangrene in hysteric girls and women are of artificial origin,[2] but, as Van Harlingen[3] and others have more recently intimated, this can by no means be said of all, and probably of only a small proportion. Audry[4] makes the suggestion that in some of these cases it may be due to the iodids or bromids administered. The lesions may be few or numerous, usually the former, and, as a rule, begin with an erythematous spot (**erythema gangrænosum**) which soon becomes gangrenous, without any intermediate stage, or there may be slight vesiculation or serous exudation under the epiderm.

In other instances of multiple gangrene the first appearance of the lesions is somewhat urticarial. While the areas are usually few in number at one time, new spots continue to arise, and in this manner the process may persist for some time. Some lesions tend to spread peripherally. As a rule, in the large majority of cases at least, there are no grave constitutional symptoms, and in some the constitutional involvement seems almost or wholly wanting.

Multiple gangrene is commonly seen in girls and women, but it is also observed in children;[5] cases in men are rare, but have been reported. The disease has, in a large number of instances, been noted to follow accidents, more especially a burn. It has also been noted to follow systemic disease, such as typhoid fever,[6] scarlet fever, measles, malaria,[7] etc. In a few instances it appeared to be closely similar or identical with dermatitis gangrænosa infantum.

The causes are doubtless varied, but a fair presumption is that two factors are necessary: a weakened resisting power in the skin, due to a general neurosis or a trophoneurotic disturbance, and a local infective agent. A bacillus has been found by Rooter, Waelsch, and Hart-

[1] Rona, *Archiv*, vol. lxxv., 1905, p. 25, has recorded 5 cases in hysteric individuals, similar to the herpes zoster gangrænosus hystericus of Kaposi, and in all of which he believed the lesions were self-inflicted.

[2] Riecke (4 cases of artificial origin), *Wien. klin. Wochenschr.*, 1899, No. 14.

[3] Van Harlingen, "The Hysterical Neuroses of the Skin," *Amer. Jour. Med. Sci.*, July, 1897 (a most admirable paper, with a comprehensive review of the subject and a wealth of references, to which the reader is referred for the literature of the disease); Balzer and Michaux (in hysteric girl), *Annales*, 1898, p. 53; Corlett (girl of fifteen, apparently free from hysteric tendencies), *Jour. Cutan. Dis.*, 1897, p. 551; Wende (2 cases, girls, aged seventeen and eighteen, of hysterotraumatic origin), *ibid.*, 1900, p. 548 (with pertinent literature references).

[4] Audry (disseminated—due to iodid), *Jour. mal. cutan.*, Feb., 1898.

[5] Zuppinger, "Ueber Spontangangrän im Kindesalter," *Wien. klin. Wochenschr.*, 1899, No. 13 (child five years old, extensive, following pneumonia; the writer gives a recapitulation of cases of spontaneous gangrene in children; usually follows typhoid, typhus, influenza, measles, tuberculosis, etc.; many having the character of Raynaud's disease).

[6] Stahl, "Gangrenous Dermatitis Complicating Typhoid Fever," *Amer. Jour. Med. Sci.*, 1900, vol. cxix., p. 251 (in returning soldiers; 10 cases out of 144 patients).

[7] Osler (following malaria, simulating Raynaud's disease), *Johns Hopkins Hosp. Bull.*, Feb., 1900.

zell. In Hartzell's[1] case it was present in numbers; in the early stage of a patch-formation it was quite superficially seated.

Prognosis and Treatment.—Recovery takes place sooner or later, although the malady may be persistent and long continued; in children the outlook is more grave. Constitutional treatment is essentially based upon what may appear to be the underlying cause. If neurotic in character, appropriate treatment should be instituted. In those cases lacking any demonstrable cause such remedies as arsenic, iron, cod-liver oil, and the like are most frequently to be employed. Local treatment is purely antiseptic and sometimes surgical. In Hartzell's case it was found that thoroughly removing the gangrenous tissue, especially about the edges, and enveloping with antiseptic applications, would prevent its further extension.

DIABETIC GANGRENE.

Diabetic gangrene is a term applied to those cases of cutaneous gangrene which are directly or indirectly due to the presence of diabetes, of which many examples have been recorded (Kaposi, Rosenblatt, and others).[2]

Symptoms.—Diabetic gangrene may show itself spontaneously without previous injury to the affected skin, or it may arise at the seat of a slight traumatism, or even at the seat of the skin affections, so common in such subjects.

In those cases arising spontaneously there may be prodromal symptoms of loss of sensation, neuralgic pain, and coldness of the part, and sometimes intermittent flushing or lividity of the area. Gradual death of the integument may ensue, the part first becoming dark colored, or there is at first the appearance of vesicles or blebs. The destruction may extend into the subcutaneous tissue, and it also tends to spread laterally. One, several, or more patches may be present, and in some cases the areas are arranged somewhat symmetrically.

In other cases of diabetic gangrene starting from traumatism the part either rapidly goes into a state of gangrene, which may be dry or moist, but usually the latter, and tends to spread and involve the deeper tissues; or the traumatism may first be followed by inflammatory action, which later becomes gangrenous. In this variety those parts liable to injuries or knocks, such as the legs and hands, are most commonly the seat of the malady, especially the former.

The patches in diabetic gangrene are rounded, irregular, or even serpiginous. Constitutional disturbance may or may not be present in the beginning; symptoms of septic character usually finally supervene.

Etiology and Pathology.—Considering the number of cases of diabetes, diabetic gangrene must be considered extremely rare. Three factors are doubtless contributory or essential in its production: The

[1] Hartzell, "Infectious Multiple Gangrene of the Skin," *Amer. Jour. Med. Sci.*, July, 1898 (with some references). S. W. Wende and Bentz, "Infectious Dermatitis Gangrænosa," (fatal case), *Jour. Cutan. Dis.*, 1906, p. 445, found streptococci, staphylococci, diplococci, and bacilli in the bullæ and gangrenous lesions of the skin during life, and in the internal organs at the autopsy.

[2] Kaposi, "Hauterkrankung bei Diabetikern," *Wien. med. Wochensch.*, 1884, Nos. 1, 2, 3, and 4; C. W. Allen, *Med. News*, Oct. 24, 1896. See also paper by Morrow, "The Cutaneous Manifestations of Diabetes," *Med. Record*, April 11, 1896. Other references will be found under general etiology.

abnormal impregnation of the tissues and blood with sugar, making the former favorable soil for microbic development; lessened resisting power, superinduced by the diabetes; and microbic infection, probably taking place through some break in the continuity of the skin. Gussenbauer[1] inclines to the belief that the gangrene is not so much due to the sugar in the tissues, as to the loss of resisting power and to the bad effects following infective processes in such individuals. The spontaneous form is possibly purely trophic in origin, but in these cases an unnoticed insignificant injury or break in the skin may have preceded. Morrow states that it mainly occurs in the old and obese, is usually of the moist type, and that the blood-vessels are found to be pervious. Wallace[2] found the arteries in 23 out of 24 cases decidedly atheromatous, the patients averaging sixty-three years; and that the disease was relatively more frequent in males.

Prognosis and Treatment.—The disease is a grave complication or accident in the course of a serious disease, and the outlook is rendered less favorable. The gangrene is apt to extend, and new areas may arise. The patient may finally die from septic poisoning. Exceptionally cases do recover, however, particularly those of spontaneous origin.

The diabetes itself must be carefully treated, both by dietetic and medicinal means. The gangrenous spots or areas are to be managed upon general principles, with applications of antiseptics until the slough separates; or, better still, as soon as the slough has formed it may be removed by curetting, if necessary, and the parts treated antiseptically. Gussenbauer points out that the best plan consists in thorough surgical removal of the diseased tissue. Wallace believes the best treatment is removal of the limb early, before sepsis has caused great depression.

SYMMETRIC GANGRENE.

Synonyms.—Local asphyxia; Raynaud's disease; *Fr.*, Asphyxie locale des extrémités; *Ger.*, Raynaud'sche Krankheit.

Definition.—An affection, usually of the extremities, of probably trophic nature, characterized by local ischemia and asphyxia, which usually terminate in the gangrene of the skin and underlying tissue.

While considerable irregular information was known as regards this affection, Raynaud's[3] description was the first well-defined presentation; his contributions, with those of Barlow and others, have given a clear portrayal of its clinical symptoms and behavior.

Symptoms.—The extremities, such as fingers and toes, the ears, nose, and occasional other parts may be the seat of the disease. On the ears and nose, however, the gangrenous stage is rarely reached.[4] It is, generally, symmetric. The first symptoms[5] are, as a rule, cold-

[1] *Wien. med. Blatt*, Feb. 2, 1899.

[2] C. S. Wallace, *Lancet*, Dec. 23, 1899 (a record of 26 cases observed in a period of eleven years in St. Thomas's Hospital, London).

[3] Raynaud, "De l'asphyxie locale et de la gangrène symétrique des extrémités," *Thèse de Paris*, 1862. Also paper by same writer, *Arch. Gén. de Méd.*, vol. i., 1874. pp. 5 and 189. English translation in New Syd. Soc'y publication, *Selected Monographs*, 1888, by Barlow, with valuable additional notes.

[4] Fordyce, *Jour. Cutan. Dis.*, 1896, p. 87, records a case in which the ear-tips alone were affected and gangrenous.

[5] Bronson, "A Case of Symmetrical Gangrene," *Jour. Cutan. Dis.*, 1903, p. 456 (with case illustration), describes a peculiar case in which not only was the so-called

ness and paleness of the parts—local ischemia; pain and numbness may or may not have preceded. Sooner or later the second stage is reached, that of local asphyxia, in which the parts become dark red, livid, and bluish, and sometimes swollen, with not infrequently tenderness and shooting pains. There may be, in either of these periods, a repeated retrogression and reappearance for some time, and occasionally it does not progress beyond the second stage. Finally, however, the condition usually eventuates in gangrene, generally of a dry character; there may be formation of vesicles or bullæ along the edge of the gangrenous margin. Or, instead of gangrenous changes, the part affected, especially if the fingers or toes, may gradually become atrophic, withered, and indurated.

In many cases the process goes on until it reaches the beginning of the third stage, that of persistent lividity, of bluish or bluish-black color, and may remain in this state an indefinite time. Or in some instances complete resolution may take place, to be followed by recurrent attacks.

On fingers or toes the gangrene may involve considerable area. It may be of a dry and mummified character, and gradually drop off; or it may be cast off by underlying inflammatory and suppurative action; or, instead of dry gangrene, it is of the moist character, with some purulent infiltration of the subjacent tissue. The resulting ulcers heal slowly.

Etiology and Pathology.—The causes may be varied; in fact, it is questionable whether Raynaud's disease is a distinct entity or merely a symptom of many underlying affections. It has been ascribed to many agencies: cold, exposure, general disturbance of nutrition, a sequence or associated condition of severe systemic fever or disease, nephritic disorders, and to various neuroses. In some instances malarial fever seemed of etiologic bearing (Rey, Mourson, Fischer, Calmette and Leloir, and others);[1] Osler,[2] in 9 cases observed by him, was not able to confirm this in a single instance. An arteritis of syphilitic origin, probably beginning peripherally, is, doubtless, as Jacoby[3] has strongly pointed out, responsible for some cases reported as examples of Raynaud's disease. It is doubtless in most instances in all probability of purely neurotic origin—a vasomotor nutritive disturbance.

There is, first, a contraction of the arterioles and capillaries (Raynaud), which explains the first stage; this is followed by dilatation and paralysis of the vessels, giving rise to the livid or blue color. It is alleged by Weiss, however, that these later changes are due to a contraction of the veins. At all events the local disturbance is a circulatory one, and this may be due to peripheral or central causes.

local syncope entirely lacking, but the usual situations were spared, the malady involving symmetrical areas on the legs and ankles and clinically characterized by recurrent attacks of pain and inflammation, exactly symmetrical, together with the development of a necrotic process; the author viewing the case as a possible transitional form between Raynaud's disease and erythromelalgia.

[1] Calmette, *Gaz. médicale*, 1876, No. 44; Leloir, *Twentieth Century Practice*, vol. v., Dis. of Skin, p. 807.

[2] Osler, *Johns Hopkins Hosp. Bull.*, Feb., 1900.

[3] Jacoby, "A Contribution to the Diagnosis of Raynaud's Disease." *New York Med. Jour.*, Feb. 7, 1891 (with a good bibliography); see also paper (3 cases) by H. H. Morton, *Jour. Cutan. Dis.*, 1894, p. 249.

According to Leloir, its most common subjects are between the ages of fifteen and thirty-five, and four-fifths of them are females.

Diagnosis and Prognosis.—The symmetric character of the disease and the sites affected, together with its course, are sufficiently characteristic.

The outlook for permanent recovery is not very favorable. Sometimes recovery takes place after one attack. As a rule, however, and even in seemingly favorable cases, there are likely to be recurrences, or one part after another may become involved. If it is possible to recognize the etiologic factor, and this be susceptible of removal, a permanent cure may result. In unfavorable cases, septic infection may gradually ensue.

Treatment.—The recognition of the underlying causative factor is all-important for a result. Treatment is, therefore, somewhat different in different cases, although in the most it is probably empiric. As a rule, invigorating treatment, especially directed toward the nervous system, and a full generous diet and attention to hygiene will have an influence. Remedies having an action upon the peripheral circulation, such as amyl nitrite and nitroglycerin, and others have been advocated but are of questionable value. Inhalations of oxygen have also been advised. A method of treatment commended by Raynaud, which in some instances seems to be of decided service, is that by the galvanic current with the positive pole applied at the fifth cervical vertebra and the negative over the last lumbar vertebra or over the sacrum; the current should be moderately strong, and continued for five to ten minutes daily. The negative electrode, with weaker current, can also be applied to the affected region. Application of the faradic current to the parts should also be employed from time to time.

In the earlier stages cold application, frictions with stimulating liniments, and massage are of service. Later the local treatment is essentially antiseptic and surgical.

DERMATITIS CALORICA.

Definition.—This term includes cases of dermatitis of varying grade, due to the action of heat or cold. The condition may be so slight as to be simply an erythema or congestion—erythema caloricum; or, if the cause has been extreme, death of the part may result. Two forms are described: that due to excessive heat—dermatitis ambustionis, or burns—and that due to excessive cold (extreme absence of heat)—dermatitis congelationis, or frost-bites.

DERMATITIS AMBUSTIONIS.

Symptoms.—Burns may vary from a slight redness, as, for example, that produced by exposure to the sun's rays—erythema solare, eczema solare—to that in which rapid destruction or necrosis ensues. They are, according to their severity, usually divided into three degrees: In that of the first degree (dermatitis ambustionis erythematosa) there is simply redness, accompanied with more or less heat of the affected part, and at times with slight swelling; in that of the second degree (dermatitis ambustionis bullosa), to the above symptoms are

added vesiculation and the formation of bullæ, due to considerable serous exudation, and along with these there may be greater swelling, and the part may even have an erysipelatous aspect. In both of these grades the subjective symptoms of heat and burning are present; in those of the second degree, more or less tenderness and actual pain. In the third grade (dermatitis ambustionis escharotica) of burns, to the characters already named, are added those of escharotic action, involving superficially or deeply according to the intensity and duration of the exposure. In the more severe instances, and even in the milder cases of any extent, there are usually constitutional symptoms of considerable violence. In fact, if the burn is severe or very extensive, the patient may suffer profoundly from shock, from which, in the most extreme cases, he does not rally. In serious burns, especially those of escharotic character, various and grave complications of the internal organs may occur; or the patient may suffer from the drain of the suppurative action which ensues. In favorable instances of the severe type the slough is gradually cast off and repair takes place; or, after tissue repair, there may remain considerable surface which fails to skin over.

Prognosis and Treatment.—Burns of the first and second degrees almost invariably make rapid recovery, unless extensive; the latter are always serious, and may be rapidly fatal from shock. The cause of death has been variously suggested as due to induced changes in the red blood-corpuscles (Wertheim, Lesser, and others) or to the development of toxins or ptomains (Lustgarten, Spiegel, and others). The prognosis in those of the third degree depends upon the extent of the destruction. In all grades the extremes of life are the most dangerous periods.

In severe cases constitutional measures of supporting character are made necessary by the general condition of the patient. Stimulants, and sometimes narcotics also, are required. The local treatment depends, in part at least, upon the degree of inflammation or destruction, and whether it be limited or extensive. If of a mild degree, the application of sodium bicarbonate as a powder, covering the parts thoroughly, is often sufficient; or it may be applied in solution, from 3 to 5 grains (0.2–0.33) or more to the ounce (32.), enveloping the part with linen cloths kept constantly wet with it. The application of cold-water compresses, or compresses wet with boric acid solution, will also be of value. Dilute lead-water is often very grateful and satisfactory, and can be used when the surface is not large. In those cases with vesicles and bullæ, these should be carefully punctured, the contents gently pressed out, and the dressings, such as above, applied. In those involving extensive surface relief is often obtained by the well-known linimentum calcis (Carron oil); if the area is not too large, this can be made more effective in painful cases by the addition of a small amount of carbolic acid, ½ to 5 grains (0.033–0.33) to the ounce (32.). Many of the soothing applications advised in the acute types of eczema will also give relief in the majority of the milder burns. If very extensive, especially when there is profound shock, the continuous immersion of the patient in a warm bath affords great comfort and relief. In recent years a 1 per cent. solution of picric acid has been extolled (Thiery, Debacq,

Power, Dakhyle, and others), especially in the first and second grades; it is applied in the form of compresses, but should not be applied over a large surface for fear of absorption. In suppurative surfaces attention should be given to cleanliness and frequent change of applications. The graver, escharotic cases belong properly to the surgeon. In some of these skin-grafting will be eventually necessary.

DERMATITIS CONGELATIONIS.

Symptoms.—Various grades of dermatitis from exposure to cold are met with, varying from a simple hyperemia to that of deep tissue necrosis. As in burns, it is usual to give a somewhat arbitrary division into three degrees. In the first the part is noted to be hyperemic, sometimes of a dark or dusky hue; in this type there sometimes results weakening of the circulation of the part, and the congestion persists, or is readily provoked upon exposure to cold or to moderate heat. This condition—*chilblains*—is often persistent and gives rise to a good deal of burning and itching when the part becomes warm. In frost-bites of the second degree there may be a bright red or livid skin, with more or less serous exudation, usually in the form of vesicles and blebs, although there is sometimes a serous undermining of the entire epiderm. In the third degree the part is at first noted to be pale, stiff, and even brittle; if not severe or if it may not have been long exposed, gradual reddening takes place and the circulation is reestablished, the surface presenting moderate or marked vesiculation and bleb-formation, with some underlying superficial ulceration; or complete normality may be restored. Or the part may go immediately into a state of necrosis or gangrene, a line of demarcation gradually forming. As in dermatitis from exposure to heat, there may be constitutional disturbances, if the part involved is very extensive, and especially if the case is of the third degree. Even in limited areas of this last grade there may develop some fever later, and possibly septicemic symptoms may supervene as the part is cast off and undergoes suppurative action. If the exposure has been prolonged and involves a greater portion or the entire surface, the patient fails to rally.

Prognosis and Treatment.—The prognosis is usually favorable, both for the patient and for the part involved, if exposure has not been too prolonged and the region involved not too large. Extensive cases, however, and particularly if the resulting damage is of the third degree, are always of serious import. The patient's general condition may demand the free use of stimulants to overcome any shock and to support the strength.

The local treatment of established chilblain has been considered under erythema caloricum. If the case is seen immediately after exposure, the parts are to be brought back to the normal temperature by first rubbing gently with snow or by applications of cold water, gradually replacing these with water of higher degree until the normal temperature is reached; soothing lotions or ointments may then be applied for a short time.

If the action is of the second degree, the same preliminary measures of gradually bringing the part back to the normal tem-

perature are to be adopted. Subsequently the vesicles and blebs are to be carefully opened, and soothing remedies employed, such as are used in diseases with similar lesions. Weak ointments of salicylic acid, from 10 to 20 grains (0.65–1.33) to the ounce (32.) of zinc oxid ointment, or with the addition of 5 or 10 grains (0.33–0.65) of carbolic acid to the ounce (32.); or boric acid ointment, or one with 5 to 10 per cent. ichthyol, will usually be all that is required. Wet dressings, the same as referred to in burns, sometimes prove more grateful. Cases of the third degree, especially the more extensive forms, properly belong to the domain of surgery. In limited areas the treatment is the same as in the other varieties. Proper antiseptic precautions should be taken.

DERMATITIS TRAUMATICA.

Under this head are comprised all those cases of cutaneous disturbance or inflammation due to traumatic agencies, such as friction, contusions, abrasions, excoriations, surgical operations, animal parasites, continued scratching, and the like. The amount of disturbance depends upon the character of the cause and the duration of its action or its repetition. Very often this does not go beyond simple erythema (erythema traumaticum). When the action has been prolonged, a variable degree of thickening of the skin and pigmentation may result. Infection from without may be added to the ordinary symptoms of traumatic break in the continuity of the derma, and give rise to complications.

The various other examples of this variety of dermatitis scarcely need special mention. The irritation and inflammation sometimes due to tight-fitting garments, bandages, to constant pressure (bed-sores), etc., are additional illustrations. The mild traumatic dermatitis which the various implements of trade produce in those of sensitive skin unaccustomed to their use is well known; nature, by gradually producing a thickening or callousness of the parts pressed upon, protects from further damage.

The management of dermatitis traumatica consists simply in withdrawal or modification of the causative factor, and, if necessary, the application of soothing lotions or ointments, such as referred to in erythema traumaticum; in bed-sores soap-plaster, or equal parts of soap-plaster and petrolatum, with or without 1 to 5 per cent. of ichthyol to the ounce, is of advantage.

DERMATITIS VENENATA.

Definition and Causes.—Under the head of dermatitis venenata are included all those inflammatory conditions of the skin due to contact with or to the action of caustics, chemical irritants, drugs, plants, and other deleterious substances. These agents are for the most part essentially chemical. The substances which may be responsible for dermatic inflammation are almost innumerable. Many of them are more or less irritating to all skins, some are harmless or practically so to a large number, while in others again the action is so exceptional as to be due to some peculiar idiosyncrasy. Among

the most common are the various irritant drugs, as arnica, mustard, cantharides, mercurials, iodoform, iodin, carbolic acid, oil of turpentine, dye-stuffs, petroleum products, tar compounds, alkalies, and acid and many others; among irritating articles of wearing apparel and every-day use irritant to some individuals may be mentioned strong soaps, anilin and coralline dyes, especially in socks and veils, many of the quack stimulating oils for rheumatism, etc. Among the trade causes may be mentioned the constant handling of sugars, flour, polishing material, pastes, tobacco, and similar substances.

Plants also furnish a somewhat prolific source of dermatic inflammation. As with almost all other substances, certain plants are more frequently causative, while some others may only occasionally bring about such action, and by far the large majority are wholly devoid of irritating properties. Idiosyncrasy plays an important part. The various plants which may provoke such irritation in susceptible subjects are at least sixty or seventy. The most common and best known of this group are the rhus plants. These furnish,

FIG. 94.—Dermatitis venenata from exposure to *poison-ivy*, following shortly after exposure; vesicular and bullous lesions; not an uncommon type; hands and forearms involved; a few days' duration.

in season, our clinics with a large number of examples of dermatitis venenata of varying grade. The several plants of the rhus species are somewhat common in different parts of our country, and some are more poisonous than others. These plants are: rhus toxicodendron, a climbing plant (poison-ivy), and as an independent shrub or small tree (poison oak); rhus venenata, a shrub or small tree rarely exceeding the height of fifteen or sixteen feet, also known as poison dogwood, poison sumac, and poison elder; rhus diversiloba, and rhus pumila, the former a climbing and the latter a creeping shrub, both of rather limited distribution; and rhus vernix, from which the varnish for Chinese lacquer work is made.

The various other plants[1] which are sometimes provocative are too

[1] For further information on this and other points the reader is referred to the monograph on *Dermatitis Venenata* by Dr. James C. White, Boston, 1887; and to Dr. P. A. Morrow's work on *Drug Eruptions*, New York, 1887, and "Dermatitis Venenata—A Supplemental List," by Dr. James C. White, *Jour. Cutan. Dis.*, 1903, p. 441 (with references). Evans, *Brit. Jour. Derm.*, 1905, p. 447, refers to several cases occurring in workers on teak wood.

numerous to mention individually, and, moreover, are much less frequently causative. Among the best known are urtica doica (nettle), primula obconica (primrose), mucuna pruriens (cowhage), polygonum punctatum (smartweed), podophyllum, balsamum Gileadense (balm of Gilead), nerium oleander (oleander), and ruta (rue).[1]

Symptoms.—The symptoms of dermatitis venenata are varied, depending upon the individual susceptibility and upon the character and duration of contact of the irritating substance. All degrees are met with, from that of simple irritation to that of gangrenous action. Intermediate degrees of papulation, vesiculation, erysipelatous and edematous swelling, and the formations of bullæ are all encountered; and, in rare instances, superficial destruction and ulceration.

In almost all cases the dermatitis runs a somewhat acute course and terminates spontaneously in recovery, and, except in the rare and extreme instances of suppurative and destructive action, without trace or scar. In subjects eczematously inclined the artificial dermatitis may develop into a true eczema, more especially after two or three attacks, or from persistent action of the irritant. The subjective symptoms of burning and itching are somewhat variable; they may be extremely troublesome or very slight, and even wanting.

FIG. 95.—Dermatitis venenata from exposure to poison ivy; the hands, forearms, and face involved, with numerous vesicles and blebs.

Some of the cases due to the more common causes may be referred to. That irritation is produced by many drugs is well known. Even the constant use of the various antiseptics in susceptible individuals tends eventually to bring about a variable dermatitis, essen-

[1] E. Hoffmann, *Münch. med. Wochenschr.*, No. 44, 1904, in addition to referring to the dermatitis produced by the primrose, states that, among other plants, he has seen cases due to the chrysanthemum, fresh squill-root, and arbor vitæ. Primrose dermatitis is quite frequently observed in England and the United States, a number of such cases having come under my observation in the past few years.

tially an eczema, usually slight, but sometimes persistent. This is not infrequently encountered in surgeons and nurses (surgeons' eczema; nurses' eczema), especially after a series of prolonged operations, during which the hands have been more or less constantly in contact with corrosive sublimate, carbolic acid or formaldehyd solutions; the repeated use of strong soap, such as sapo viridis or the tincture of green soap, used in washing the hands, is also often a factor. A mild degree of dermatitis is sometimes encountered in patients from the use of antiseptics and antiseptic gauzes and other dressings. In many of these instances there is, of course, a pronounced individual idiosyncrasy.

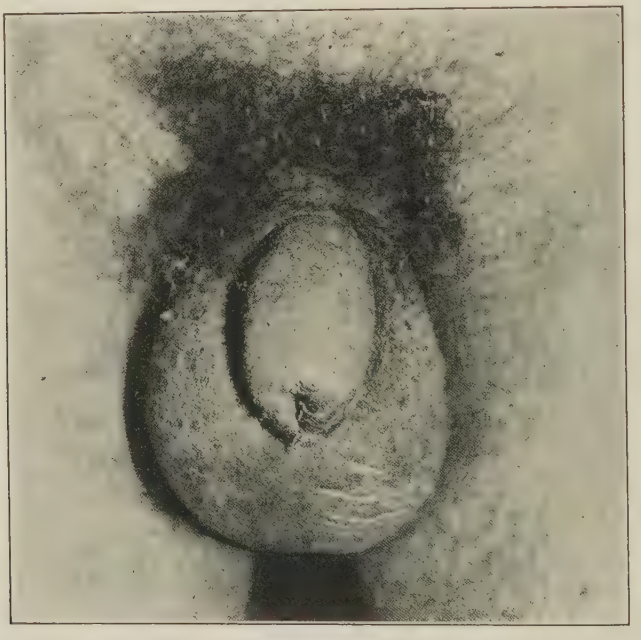

FIG. 96.—Dermatitis venenata from exposure to *poison-ivy*. Marked edematous swelling of the scrotum and penis; also slight involvement of face and hands; two days' duration, developing ten or twelve hours after exposure.

Iodoform (iodoform dermatitis, iodoform eczema), more especially when used in powder form, is a not infrequent source of such irritation (Neisser, Taylor, Watkins, and many others). The use of this drug is responsible for occasional inflammatory action, which may be quite positive, and sometimes long continued. The character of the inflammation varies from that of erythematous to vesicular and bullous; often it is of an apparently eczematous character. It usually starts at the seat of the dressing, and may continue to be so limited; often, however, it spreads from this point and involves the immediate neighborhood, and may even extend to other regions. I have met with several cases of rebellious eczema which had their start in the local use of this drug. It may, moreover, through absorption, also be provocative of more or

less general cutaneous manifestations of varied character, and if extensive or severe, with associated, temporarily at least, systemic disturbance (see dermatitis medicamentosa).

The popular use of arnica tincture has also been the cause of some cases of violent dermatitis (Cartier, Bauvais, Mouillot, Bowles, Dale, and others), which may extend much beyond the part to which it is applied, and present as an erythematous, erysipelatous, vesicular, bullous, and even gangrenous inflammation; and in some cases there may be severe constitutional symptoms accompanying. Occasionally other drugs[1] will provoke, in certain subjects, a variable degree of dermatic inflammation, among which may be mentioned tincture of iodin, chrysarobin, blue ointment and other mercurial ointments, tar preparations, and pyrogallol. The symptoms vary with these, usually being of mild character—erythematous, erythemato-squamous, and vesicular; pyrogallol may exceptionally lead to superficial destruction.

The dermatitis observed is those working in trades is usually, when coming under observation, of distinctly eczematous nature; for instance, the so-called bakers' itch, grocers' itch, the irritation seen in book-pasters, polishers, etc.; the dermatitis produced by some of these factors may occasionally be acute in type, but, as a rule, it is gradual, and in the latter resulting in a veritable eczema.

The cases of dermatitis venenata most frequently met with are, however, those in which the action has been due to exposure to the rhus plants (**rhus poisoning, ivy poisoning**). Some persons are entirely immune; some, but slightly susceptible; others, quite vulnerable, while not a few can scarcely go near the plants without an attack. In some instances a gradual immunity seems to be established, more especially as the patient grows older, but this is rather exceptional than the rule. The irritation may be almost immediate, but it generally follows some hours or a day or so after exposure. The hands, forearms, sometimes face, and not infrequently the genitalia and anal region, are favorite localities. It presents either an erythematous rash, with more or less swelling, or may have a pronounced erysipelatous aspect; sometimes the affected regions are studded over with vesicles, or in some cases with both vesicles and bullæ. In others again the blebs may be confluent and the integument in places more or less denuded, and presenting a weeping red surface; occasionally there is also pus-formation. The first parts usually attacked are, for obvious reasons, the hands or face, to which it may remain limited, or other regions may later become involved, either as the effect of the same exposure or as a result of the irritant being conveyed by the hands. It would seem possible, too, that the irritant might be conveyed by a person himself immune to one susceptible. If the disease is caused by the oily constituent of the plant known as toxicodendrol, there is explanation why, in the early part of the attack, it may be autoinoculable, and also be even conveyed from one person to another; this latter accident is, however, extremely rare. In extensive and markedly inflammatory cases there may at first be some constitutional disturbance.

[1] Orthoform, as well as many other drugs, commonly thought to be innocuous, will occasionally provoke irritation and even severe dermatitis: Dubreuilh, "Des Éruptions orthoformiques," *La presse médicale*, No. 40, May 18, 1901 (with bibliography).

The dermatitis produced by these plants usually subsides in mild forms in the course of several days to a week; in the more pronounced cases it may last for several weeks to a few months, and, as already stated, it may gradually run into a persistent eczema. A spontaneous recurrence of the irritation for several successive seasons has been alleged, but this is doubtless due to the fact of reexposure, although often such patients may not be aware of it.

Diagnosis.—It may occasionally be difficult to reach, at first, a positive diagnosis as between some cases of dermatitis venenata and eczema. A history of the onset, occupation, and exposure will be of aid. Rhus poisoning frequently begins between the fingers, is usually markedly acute in character, with a good deal of swelling, with often large vesicles and blebs, these latter being rarely seen in eczema; in fact, the acuteness, rather violent characters, and the distribution of the eruption, together with a history of possible exposure, make up a picture ordinarily conclusive.

Prognosis and Treatment.—The prognosis has already been in part referred to. The various types of dermatitis usually subside spontaneously after the removal of the cause, requiring more or less time according to the degree of inflammatory action present.

Treatment is essentially that of other inflammatory diseases of like clinical character, notably that of eczema of the acute type. Rhus poisoning has had innumerable remedies brought forward, but those advancing them fail to keep in view the natural tendency of the disease to spontaneous, and, in many instances, usually rapid, disappearance. In fact, many slight cases will get rapidly well of themselves, many others with simple applications; others are more rebellious and yield slowly. The essential treatment consists in the employment of mild soothing and slightly astringent applications. As a rule, one of the best plans is, as in acute eczema, the conjoint use of black wash with an equal part of lime-water, followed by the plain zinc oxid ointment; or a boric acid lotion, 2 to 3 per cent. strength, followed by the zinc ointment. The calamin-zinc-oxid lotion, frequently applied, is also an admirable application; or, better still, linen cloths kept constantly wet with it, may be continuously applied. Weak alkaline lotions of borax, sodium carbonate, or ammonium muriate, of the strength of 1 (0.065) to 2 (0.13) or 3 (0.2) grains to the ounce (32.), are useful, especially in the milder erythematous types. Weak solutions of sodium hyposulphite, 1 to 10 grains (0.065–0.65) to the ounce (32.), are also of value. A lotion of the fluid extract of grindelia robusta, 1 to 2 drams (4.–8.) to about 4 ounces (128.) of water, and continuously applied (Duhring); a lotion of zinc sulphate, ½ to 2 grains (0.033–0.13) to the ounce (32.), with 2 to 5 grains (0.13–0.33) of carbolic acid, will likewise often prove useful. The larger vesicles and the blebs should be punctured and the contents pressed out. Once every one or two days the parts should be gently bathed with warm water, tapped dry, and the treatment immediately resumed; occasionally the washing can be done with a weak alkaline lotion. The various mild ointments may also be employed, either alone, or preferably conjointly with a lotion as already suggested. An ointment of calamin, 1 dram (4.), to the ounce (32.) of zinc ointment is often effective.

X-RAY DERMATITIS.

Synonyms.—X-ray burn ; Röntgen-ray dermatitis or burn.

The "Röntgen ray" discovery has added much to the resources of medicine, especially in a diagnostic way, and to some extent therapeutically, but as now known it is not the harmless agent it was at first thought.

Its deleterious effects upon the integument, and sometimes subcutaneous tissues, and exceptionally extending to the bone, are now matters of record, and have led to its more careful employment, although in spite of all precautions, probably from some extreme susceptibility of the skin in certain subjects, an occasional case of cutaneous injury still continues to be reported from time to time.

The first signs of cutaneous disturbance sometimes do not present for several days or longer after exposure. The mildest phase of the X-ray action is a peculiar reddish flush or erythema, resembling somewhat closely sunburn, and which in the course of several days or a few weeks gradually disappears. In other instances of seemingly similar mild type the flush continues for a longer period, and not infrequently there is an extremely slight feeling of local discomfort, such as a sensation of warmth, burning, or itching. A continuance of exposures, and occasionally after only a few exposures, this flush is succeeded by a varying number of brown to black freckles, and a slight general pigmentation of the skin. These conditions may persist for several weeks, and in extreme cases much longer; exceptionally an insignificant growth of down and telangiectases are added. On the other hand, accidental exposure of a hairy region will exceptionally, even though of comparatively short duration, cause falling of the hair—followed, sooner or later, by regrowth. In other cases the erythema is rapidly succeeded by a superficial, ill-defined vesiculation, and with or without an associated trifling swelling or puffiness. These are usually much more persistent, and may be attended with the ordinary subjective symptoms of irritation. In some instances a slight dry branny or insignificant, or sometimes lamellar, scaliness or exfoliation follows the erythema, appearing several days or later, or first showing itself as the redness is fading away. In those whose hands are constantly exposed to the ray, as with those making frequent use of it professionally, a mild erythematosquamous condition of these parts not infrequently develops, and is more or less persistent, and is succeeded by variable pigmentation, wrinkling and other atrophic changes in the skin. Brittleness and thinning of the nails are also often noted. When such exposures have been long continued these changes persist for several months to several years, or more, after the operator has given up *x*-ray work; in fact, in some instances the hands never fully recover their normal condition, and in a few cases keratoses are superadded, which may develop into carcinoma.[1] The possibility of these atrophic changes are to be kept in mind in the employment of *x*-ray treatment for the benign dermatoses, such as acne, for in a few in-

[1] Johnston, *Phila. Med. Jour.*, Feb. 1, 1902. Macleod (*Brit. Jour. Derm.*, 1906, p. 104), reports an epithelioma developing on an *x*-ray scar in a case of lupus vulgaris.

stances a thinning, atrophic, and freckle, or other pigmentary and old-age changes (wrinkling, atrophic spots, telangiectases, etc.)[1] have been noted. Two such cases have come under my own observation.

A far more serious state of affairs is occasionally, but fortunately infrequently, noted, in which the erythematous flush, sometimes with subsequent vesicular development, is followed by a dry, leathery,

FIG. 97.—The hand of an *x*-ray operator, showing the atrophic condition of the nails and skin; the latter is dry, slightly scaly, with pigmentation, thinning, and wrinkling.

superficial or deep slough or ulcer. The ulcer is, as a rule, shallow, sluggish-looking, with a slightly or moderately hyperemic or inflammatory border, and covered with a rather adherent grayish, often tough and leathery crust or membrane; it is persistent, with but little if any tendency to spontaneous reparative change, and the accompanying pain is often excruciating, as in cases observed by Orelmann,[2] Cassidy,[3] and others.

[1] Freund and Oppenheim, "Über bleibende Hautveränderungen nach Röntgen Verstrahlung," *Wien. klin. Wochenschr.*, 1904, No. 12.
[2] Orelmann, *Wien. med. Wochenschr.*, 1809, No. 39.
[3] Cassidy, *Med. Record*, Feb. 3, 1900 (with illustrations).

Etiology and Pathology.—There is much divergence of opinion as to the exact etiologic factor in the production of *x*-ray burns. Gilchrist[1] and others have suggested that it might be due to the entrance of minute particles of the conducting metal used; others (Leonard,[2] Oudin, Barthélemy and Darier,[3] and others) that the current, and not the rays, is responsible; the latter believing, as now generally accepted, that too short a distance of the tube and a current of high intensity are the dangerous factors. Tuttle[4] suggested that

FIG. 98.—*X*-ray dermatitis of mild degree, showing an erythematosquamous condition, and also diffused and freckle-like pigmentation (case of acne—cured—skin regained its normal state in several weeks).

the exposure to the X-ray generated by the static machine was apparently not productive of injury, but this is refuted by Cassidy's extreme case (*loc. cit.*) and probably by others. The light-ray itself does not seem to me to have been given full consideration as the possible causative or influencing factor. The pathology of the malady is not clearly understood, although many observers believe that the cutaneous disturbances are not primary, ascribable to local action on the cells of the derma, but that they are rather of a trophoneurotic nature, due to neuritis; and this, according to Oudin, Barthélemy, and Darier (*loc. cit.*), is not a peripheral neuritis connected with the dermic nerve terminals, but is probably at first central, during the period which might be called that of the incubation of the phenomena, to become subsequently centrifugal and to manifest itself by distinct alterations of nutrition.[5] Behrend[6] is of the opinion that the integumentary

[1] Gilchrist, *Johns Hopkins Hosp. Bull.*, Feb., 1897 (with an illustration and review of published cases, with bibliography).

[2] Leonard, *New York Med. Jour.*, July 2, 1898.

[3] Oudin, Barthélemy and Darier, *La France Médicale*, 1898, No. 12 (a valuable conjoint paper, based upon its use in 400 cases, detailing the various accidents and discussing the pathology); Zarubin, *Monatshefte*, 1899, vol. xxviii., p. 489, also gives a valuable résumé and bibliography.

[4] Tuttle, Soc's Trans., *Philada. Med. Jour.*, Feb. 26, 1898.

[5] Quoted from review of the subject in *Progressive Medicine*, Sept., 1899.

[6] Behrend, *Berlin. klin. Wochenschr.*, June 6, 1898.

changes—scaliness, vesiculation, falling of the nails and hair—are due to the serous exudation induced in the cutaneous tissue.

FIG. 99.—*X*-ray dermatitis of considerable severity; shows the importance of protecting the lips in sensitive subjects, or when the exposure is somewhat prolonged.

Macleod,[1] after reviewing the investigations of others, gives the following tentative propositions as fairly representative of the present state of our knowledge of the subject: (*a*) That the *x*-rays in small

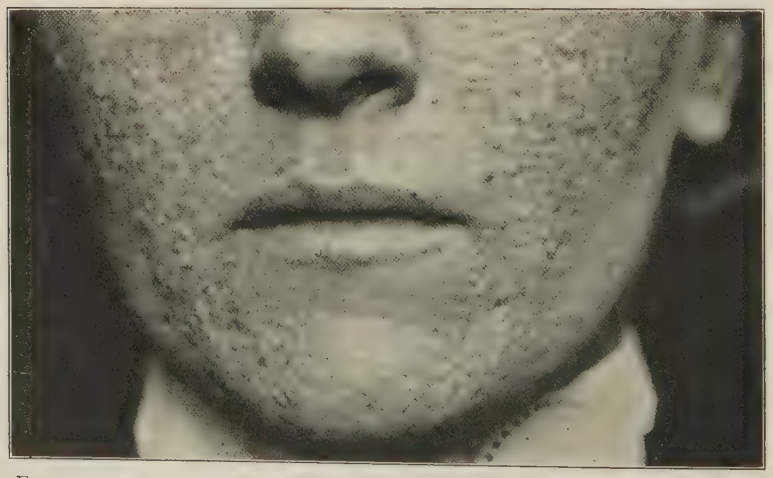

FIG. 100.—Atrophic spots, somewhat depressed, coarseness of the skin, pigmentation, and telangiectases, developing several months after *x*-ray exposures had been discontinued; there was also considerable "old-age wrinkling," but this has largely disappeared.

doses have a stimulating effect on the elements of the healthy skin; (*b*) that in large doses, by long exposures, close proximity of the tube to the skin, on the employment of soft tubes, the rays are capa-

[1] Macleod, *Brit. Jour. Derm.*, 1903, p. 365 (with brief review and reference to the works of Oudin, Barthélemy and Darier, Schiff, Freund, Doutrelepont, Beck, Pernet, Scholtz, Skinner, Norman Walker and Gardiner, and others).

ble of devitalizing the tissue elements, interfering with the process of reproduction, and causing their degeneration; and that this power is the result of a direct specific action of the rays; (*c*) that the more highly differentiated structures, such as the hair follicles, glands, nails, and blood-vessels, are more readily and severely affected by the rays than the less-differentiated epidermal cells or the fibrous stroma of the corium; (*d*) that pathologically altered cells, whether of epiblastic or mesoblastic origin, are far less resistant to the rays than healthy cells, and are devitalized with small doses of the rays, and that this destructive action on diseased elements may be taking place while the healthy elements in the neighborhood, instead of having their vitality inhibited, may be stimulated to a process of repair; (*e*) that the action of the rays is cumulative, and that when the cellular degeneration reaches a certain degree the toxic products of the breaking-down cells are capable of setting up an inflammatory reaction, which is a secondary phenomenon; (*f*) that this inflammatory reaction is peculiar in that it occurs in a tissue the vitality of whose various elements has already been impaired by the action of the rays, and in that it is associated with greater destructive changes than those produced by the actinic rays, and is apt to lead to ulceration and necrosis, and is liable to be followed by an imperfect process of repair.

Treatment.—The best treatment of X-ray burns is, so to speak, their prevention. The dangers of too long and too frequent exposure, too close proximity, and a high current intensity are, so far as possible, to be avoided. Leonard, Oudin, Barthélemy and Darier, and others have advised the interposition of grounded thin or perforated sheets of conducting material, which permits penetration of the rays, but such a plan has not been generally followed. In the "raying" or treatment of limited areas it is, however, advisable to protect the surrounding parts by a thin sheet of lead. The mild and moderate forms of X-ray dermatitis require the ordinary palliative applications employed in the acute types of eczema (*q. v.*) and in dermatitis from other causes. Soothing applications are usually sufficient to bring the irritation to a more rapid disappearance. The X-ray ulcers in most instances are obstinate, and the most satisfactory plan in refractory cases is to curet and, if necessary, skin-graft. In such patients, where operation, for the time at least, is not feasible, the local applications are to be the mildest possible; ointments containing cocain, opiates, menthol, acetanilid, for the control of the intense pain, are to be variously tried. In a case under my own care at the Howard Hospital almost all applications intensified the painfulness, and the only ointment giving relief was one containing 1 or 2 drams (4.–8.) of orthoform to the ounce (32.). No progress was made in this case toward healing, and a year or so later the area was curetted and skin grafted by my colleague, Dr. C. H. Frazier, and recovery finally resulted.

DERMATITIS FACTITIA.

Synonym.—Feigned eruptions ; Dermatitis artefacta.

By this term is meant an eruption of artificial origin, usually limited in extent, and purposely produced with the object of gaining sympathy or for malingering, and of which many cases are now on record (Startin, Fagge, Lavgier, Mattei, Mackintosh, Van Harlingen, Colcott Fox, and others).[1]

Symptoms.—The lesions may be of an erythematous, vesicular, bullous, or ulcerative nature. They are rarely numerous, as a rule, one or several patches being present. The individual spots are usually small, but exceptionally may cover considerable area. The most common lesion met with is probably the small erythematous area, with

FIG. 101.—Dermatitis factitia—note the unusually uniform and regular character and arrangement of the lesions.

slight crusting, usually somewhat longer than wide, and at times distinctly linear, resulting from persistent friction, as in a case of my own,[2] or from the application of some mild irritant. Blebs are also not an uncommon manifestation. Occasionally the lesions are shallow ulcers. In fact, almost all varieties of dermatic lesions capable

[1] Van Harlingen and Stout, Morrow's *System*, vol. iii. (Dermatology), p. 364, give a brief but good résumé, with some references. Consult also Lavgier. "Maladies simulées," *Dict. de Med. et de Chir. Pratiques;* Rasch, *Dermat. Centralblatt*, Aug., 1899, p. 322, relates a case of vesicobullous and gangrenous character and refers to several others; F. J. Shepherd (4 cases), *Jour. Cutan. Dis.*, 1897, p. 544.

[2] Stelwagon, *Arch. Derm.*, 1882, p. 236.

of being produced by the ordinary means at hand, such as acids, strong alkalies, and other chemicals, heat, friction, or other traumatic agencies. Acids and cantharides are frequently employed, and are apt to give rise to patches with somewhat irregular edges, due to careless or unskilful application. The lesions, for obvious reasons, make their appearance suddenly, and apparently during the night or at other time when the patient is unlikely to be seen or disturbed. They are, moreover, usually seated on parts readily reached by the hands—not infrequently are on the one side of the body. The most common sites are the anterior or lateral aspects of the legs and arms; occasionally the face and the trunk.

The lesions are scarcely gone before new ones make their appearance suddenly near by or elsewhere upon the surface; or the original spot or patches may be kept purposely in a constant state of irritation. Thus the affair may continue almost indefinitely until the patient is weary of the annoyance or the special object desired is attained or despaired of. They have an artificial look, are usually sharply defined, and do not correspond to either the appearance or distribution of ordinary cutaneous diseases. Doubtless some of the cases of superficial gangrene (erythema gangrænosum, dermatitis gangrænosa, neurotic excoriations) have their origin in such manner. The subjects of these various manifestations are, for the most part, hysteric women, but they are also met with, for the purpose of malingering, in criminals and mendicants, in soldiers, sailors, and others desiring to be relieved of work or their duties.

The diagnosis is sometimes fraught with difficulty, but attention to the features, behavior, and persistence and repetition of the eruption will usually arouse suspicion, and the patient can be kept under secret surveillance. An irregular outline and the presence of staining at the borders from the chemical used are suggestive. A fixed dressing to the parts involved will result in prompt cure, and if new lesions appear, they will, of necessity, be on other situations. Too often, unfortunately, a statement of the correct diagnosis to the family of the patient will be received not only with incredulity, but often with dismissal.

Treatment of the lesions depends upon their characters and is essentially that of the forms of dermatitis to which they may belong.

DERMATITIS MEDICAMENTOSA.[1]

Synonyms.—Medicinal eruptions; Drug eruptions; *Fr.*, Eruptions médicamenteuses; *Ger.*, Arznei-exantheme.

[1] General literature: Behrend, "Zur allg. Diagnostik der Arzneiausschläge," *Berlin. klin. Wochenschr.*, 1879, p. 714; Van Harlingen, "Medicinal Eruptions," *Arch. Derm.*, 1880, p. 337; Morrow's *Drug Eruptions*, 1887, and the same publication with additional notes and references by Colcott Fox, in *Selected Monograph on Dermatology*, Sydenham Soc'y publication, 1893; Brooke "On Behrend's Division of Drug Rashes into Specific and Dynamic Groups," *Brit. Jour. Derm.*, 1890, p. 313; Colcott Fox, "Contribution to the Study of Drug Eruptions" (especially bearing upon the question of placing eruptions due to external action of certain drugs in the same category with the universal eruptions following internal use), *ibid.*, p. 327; Stowers, "Drug Eruptions —Their Nature and Varieties," *ibid.*, 1898, p. 289 (with discussions thereon by Payne, Galloway, Crocker, and others, adding personal observations); Caspary, "Zur Lehre von der Arznei-exanthemen," *Archiv*, vol. xxvi., 1894, p. 11; Jadassohn, "Zur Kenntniss den medicamentösen Dermatosen," *Verhandl. der Deutschen dermatolog. Gesell-*

Definition.—Dermatitis medicamentosa is a term used to designate all those congestive, inflammatory, and other conditions of the skin due to the ingestion or absorption of drugs.

It might well be considered also to include those cases of dermatitis due to their external application, but the disturbance called forth by this latter use of them is due to their direct irritant properties, and should therefore, I believe, be classed under the head of dermatitis venenata.

Symptoms.—The symptomatology of drug eruptions is essentially the symptomatology of the various erythematous, exudative, and inflammatory diseases. Thus all the various skin-lesions are encountered in different cases, such as erythema, papules, vesicles, pustules, tubercles, blebs, purpura, and even gangrene. The carbuncular or anthracoid eruption and papillomatous nodules or plaques produced by iodin and bromin compounds are, however, somewhat peculiar, and will be referred to later when discussing each drug. In most instances there is more or less uniformity in the type of lesion in the same individual from a particular drug, but not infrequently an eruption of a mixed type may result, such as, for example, the various symptoms of erythema multiforme.

Medicinal eruptions are apt to make their appearance somewhat suddenly, after one or two doses, or with some drugs only after continued use. They are usually highly colored. Upon withdrawal of the drug they, with but few exceptions, as rapidly disappear. Sometimes, however, the eruptive phenomena may continue for some time after the drug has been stopped, as has occasionally been observed with bromids, and less frequently with the iodids, especially in children. And in exceptional instances it has been noted that the first appearance of the rash has not presented until the drug had been withdrawn. Exceptionally, too, the eruption produced may go through the various stages of the idiopathic malady which it simulates. In generalized eruptions, especially of the erythematous, morbilliform, and scarlatiniform types, there may be a variable degree of constitutional disturbance.

Etiology.—In the large majority of cases the eruption called forth is due to some peculiar idiosyncrasy of the individual to that particular drug, and while the same drug produces most frequently, as a general rule, the same type of eruption in other susceptible individuals, this is by no means always the case. On the other hand, certain few drugs, such, for example, as the iodids and bromids, give rise so often to pustular or acne-like lesions that such effect may really be considered its normal or physiologic action. Many of the more severe types of medicinal eruption are due to the fact that the medicine is continued after the milder manifestation has shown itself or has been administered in large dosage; on the other hand, occasionally profound cutaneous disturbance results from an exceedingly small quantity.

schaft, V. Congress, 1895; Hudson, "Some Cases of Drug Eruptions, *Atlanta Med. and Surg. Jour.*, April, 1898; Ryall, "Dermatitis Medicamentosa," *Med. Record*, Dec. 24, 1894. These several papers, especially those of Van Harlingen, Morrow, and Colcott Fox, are replete with references and refer to cases to date. Pernet, "Drug Eruptives," *Brit. Med. Jour.*, May 16, 1903.

Women and children seem to present drug idiosyncrasy most frequently, and those of light complexion more commonly than brunettes. Probably, too, those of a weakened state of health and a neurotic temperament are more susceptible than others. Defective kidney elimination is certainly a factor of importance. While this peculiar idiosyncrasy to a drug usually persists, it may in some persons entirely disappear; and in others small initial doses with a very gradual increase will sometimes prevent the manifestation.

As illustrating an extreme of drug idiosyncrasy, I have had under my observation [1] a man who, upon taking an ordinary dose of quinin, was attacked with an erythematous scarlatinoid eruption, of itchy character, with some exudation, and which took several weeks to run through its course, ending with desquamation. Several years subsequently he went into a drug store and took a "calisaya soda-water tonic," with the same eruption as a result. A few years later his family physician gave him some pills, each containing, among other ingredients, $\frac{1}{16}$-grain dose of quinin, of which he took only three, with the development and course of the cutaneous outbreak as before.

Pathology.—How are drug eruptions produced? This is an interesting question, and as yet not conclusively settled. Three principal theories of their action have been advanced: (1) That of skin elimination, the drug acting as an irritant as it passes through the cutaneous tissues or glands; (2) increased skin elimination due to defective condition of the ordinary eliminative organs, more particularly the kidneys; (3) the neurotic theory. The first seems plausible, but it is lacking in proof; in fact, while it may seemingly be true with a few drugs, the weight of investigations made proves it, upon the whole, untenable. In its support it is claimed (Adamkiewitz, Guttmann, Giovannini) that the drug—investigations with the iodin and bromin preparations—was found in the sebaceous glands. This, however, as Jarisch remarks, proves nothing unless found in greater relative quantity than in other tissues. These findings, however, have been negatived by investigations in the same direction (Pellizzari, Ducrez, Veiel), and also by the histologic examinations (Thin, De Amicis, Colcott Fox, Harris, and others), which show the first changes to be in the papillary layer, and not necessarily, except secondarily, in or about the glands. The view (Behrend) that the presence of the drug generates some toxin or irritant material in the blood to which the eruptive phenomena are due has gained no support, but Engman and Mook's [2] investigation, while not directly in support of this, yet are somewhat confirmatory of such a hypothesis. These investigations show that in iodermia and bromodermia the drug circulates in the body tissues and which under certain conditions acts as a toxin causing at points of past or present local disturbance (such as comedones, acne lesions, seborrheic lesions, scars, traumata, scratches, etc.) all the symptoms of an inflammation, this inflamma-

[1] Stelwagon, "An Extraordinary Case of Quinin Susceptibility," *Jour. Cutan. Dis.*, 1902, p. 13.

[2] Engman and Mook, "A Contribution to the Histopathology and the Theory of Drug Eruption," *Jour. Cutan. Dis.*, 1906, p. 502, with histologic cuts (study based upon iodin and bromin eruptions).

tion not differing essentially from that produced by other toxic agents; the process consisting primarily of inflammatory changes about the vessels. As to the second view, it is known, it is true, that the worst forms of the iodid eruption—carbuncular (anthracoid), bullous; nodular lesions—are seen commonly in those with heart and kidney disease; but beyond this scanty knowledge as to the possible causative influence of defective renal elimination, there is no clinical evidence in its favor. The neurotic theory (Morrow), while somewhat difficult of explanation, still has had considerable support; the action being either purely reflex, analogous to *urticaria ab ingestis*, or due to the influence of the drug upon the vasomotor centers or on the peripheral nerves.

Diagnosis.—The diagnosis of medicinal eruptions is sometimes difficult, but the suddenness of an outbreak should always excite suspicion and inquiry be made. Particularly is this so with eruptions of the nature of an exanthem. I have little doubt that many of the so-called second attacks of the various exanthemata have been instances of drug rashes. Medicinal eruptions seem often more violent in character than the eruptions they simulate. As a rule, except in some of the cases of generalized erythematous rashes, the constitutional symptoms are rarely marked in dermatitis medicamentosa, and are not infrequently wanting. The withdrawal of any suspected drug and one or two days' observation will generally clear up the matter.

Treatment.—A medicinal eruption is usually to be treated externally in the same way as the eruption which it may simulate. The carbuncular or anthracoid lesions do not need, as a rule, any operative interference; soothing applications are generally sufficient. Withdrawal of the drug is the first step, and frequently, in the milder cases at least, nothing else is required. In others alkaline diuretics and free drinking of water should be prescribed. In graver cases supporting treatment is required.

With certain drugs, as, for instance, the iodid and bromids, the coadministration of Fowler's solution (Crocker and others), potassium bitartrate, and the maintenance of intestinal antisepsis (Féré, Echeverria, Gowers, Duhring) have seemed at times to have an inhibitory action, more especially with the pustular eruptions produced by these drugs. In fact it is probable the administration of a diuretic along with the drug would, in some instances at least, exercise a preventive influence. Briquet and Lyon's[1] observations show that the sodium iodid gives rise less frequently than the potassium salt to cutaneous manifestations, and my own experience is in accord with this.

The subject of dermatitis medicamentosa is of sufficient importance to warrant a summary of the eruptive types provoked by different drugs and a brief consideration of the possible eruptions which each individual drug may produce.

The following is the summary of the forms of eruption which may

[1] Lyon, "L'Iodisme," *Gazette des Hôpitaux*, July 8, 1899—a full abstract in *Jour. mal. cutan.*, 1899, p. 556.

follow ingestion or absorption. Many of these drugs are capable of giving rise to several types in different individuals or even in the same individual; many are only rarely causative; others, such, for example, as the bromids, iodids, quinin, copaiba, coal-tar derivatives, and others, are somewhat frequently etiologic. To a certain extent the dividing-line between some of the types here given is purely arbitrary and somewhat ill-defined; for example, erythematopapular and polymorphous are closely similar, but in the latter are placed those more particularly simulative of erythema multiforme. Doubtless many more drugs will eventually be included in this list.

Bullous.—Aconite, anacardium, antipyrin, boric acid, chloral, bromin, copaiba, quinin compounds, copaiba and cubebs, copaiba, iodin compounds, iodoform, mercury, opium (?), phosphoric acid, and salicylates.

Carbuncular (Anthracoid).—Arsenic, chloral, iodin and bromin compounds, and opium.

Cyanotic.—Acetanilid, potassium chlorate.

Eczematous.—Boric acid, belladonna, carbolic acid, opium and morphin, sodium borate.

Erysipelatous.—Arsenic, belladonna, conium, digitalis, ipecac, quinin, and stramonium.

Erythematous.—Acetanilid, antipyrin, arsenic, alcohol, antitoxin, belladonna, benzoic acid, boric acid, bromin compounds, capsicum, carbolic acid, chinolin, chloral, chloralamid, cantharides, chloroform, castor oil, conium, copaiba, copaiba and cubebs, cubebs, dulcamara, exalgin, iodin compounds, iodoform, guaiacum, gurjun oil, hydrocyanic acid, hyoscyamus, lead acetate, mercury, opium, pilocarpin, piper methysticum, phenacetin, phosphoric acid, potassium chlorate, quinin, salicylates, sodium benzoate, santonin, sodium borate, stramonium, sulphonal, tannic acid, tar, oil of turpentine, tuberculin, and veratrum viride.

Erythematopapular.—Acetanilid, antipyrin, benzoic acid, copaiba, digitalis, gurjun oil, iodin compounds, iodoform, phenacetin, silver nitrate, and potassium chlorate.

Epitheliomatous.—Arsenic (secondarily to keratoses).

Furuncular.—Antipyrin, arsenic, bromin compounds, calx sulphurata, chloral, condurango, ergot, mercury, and opiates.

Gangrenous.—Arsenic, belladonna, ergot, iodin compounds, quinin, salicylates.

Herpetic.—Arsenic, belladonna, iodin compounds, mercury, and salicylates.

Keratotic.—Arsenic.

Morbilliform.—Antipyrin, antitoxin, belladonna, copaiba and cubebs, boric acid, opium, sodium borate, sulphonal, tar, turpentine, and tuberculin.

Nodular.—Iodin and bromin compounds.

Papillomatous.—Iodin and bromin compounds.

Papular.—Arsenic, boric acid, bromin compounds, cantharides, chloral, conium, copaiba and cubebs, cubebs, digitalis, iodin compounds, jaborandi, oil of turpentine, mercury, terebene, and opium.

Papulovesicular.—Capsicum.

Pigmentary.—Arsenic, silver nitrate, and antipyrin.

Pruritus (Without Eruption).—Opium, chloral, copaiba, strychnin.

Purpuric (Including Petechial).—Antipyrin, antitoxin, arsenic, benzoic acid, calx sulphurata, chloral, chloroform, copaiba, copaiba and cubebs, ergot, hyoscyamus, iodoform, iodin compounds, lead acetate, mercury, phosphoric acid, potassium chlorate, oil of sandalwood, quinin, salicylates, stramonium, and sulphonal.

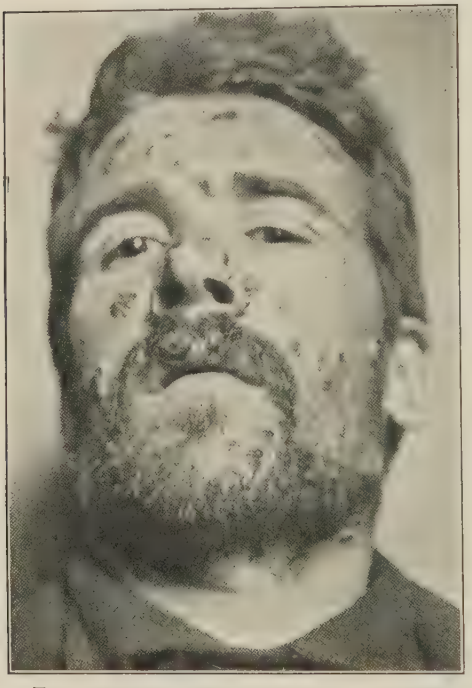

FIG. 102.—Dermatitis medicamentosa of pustulo-bullous type, following ingestion of *potassium iodid*. Principally upon the face, with some pustular lesions on the neck and shoulders. Subsided upon withdrawal of the drug, and brought out again by experimental readministration.

Polymorphous (Resembling Erythema Multiforme).—Antipyrin, antitoxin, sodium benzoate, copaiba and cubebs, iodin compounds, iodoform, boric acid, chloral, exalgin, coal-tar derivatives, opium, potassium chlorate.

Psoriasiform.—Sodium borate and tuberculin.

Pustular.—Aconite, antipyrin, arsenic, bromin compounds, calx sulphurata, condurango, antimony, hyoscyamus, iodin compounds, ergot, mercury, nitric acid, cod-liver oil, opium, tanacetum, oil of turpentine, salicylates, and veratrum viride.

Papulopustular.—Bromin and iodin compounds.

Scarlatiniform.—Antipyrin, antitoxin, belladonna, chloral, copaiba and cubebs, copaiba, digitalis, hyoscyamus, mercury, nux vomica, opiates, oil of turpentine, pilocarpin, rhubarb, quinin, strychnin, sulphonal, salicylates, stramonium, tuberculin, and viburnum prunifolium.

Ulcerative.—Arsenic (secondarily to keratoses), bromin compounds, chloral, iodin compounds, and mercury.

Urticarial.—Alcohol, antimony, anacardium, antipyrin, antitoxin, arsenic, bromin compounds, benzoic acid, chloral, copaiba, copaiba and cubebs, digitalis, dulcamara, hydrocyanic acid, guarana, hyoscyamus, iodin compounds, opium, mercury, pilocarpin, phenacetin, pimpinella, quinin, salicylates, salol, santoninum, oil of turpentine, sodium benzoate, tannin, tar, and valerian.

Vesicopustular.—Antimony, antipyrin.

Vesicular.—Aconite, anacardium, antimony, antipyrin, arsenic, bromin compounds, cannabis indica, calx sulphurata, chloral, copaiba and cubebs, copaiba, cod-liver oil, ergot, iodin compounds, iodoform,

nux vomica, oil of turpentine, opium, quinin, salicylates, and sodium santonate.

Hair Loss.—Boric acid and thallium acetate.

A study of the literature of the various drug eruptions, together with personal observation of many cases, gives the following data, briefly stated:

Aconite.—Not common; usually vesicular, exceptionally bullous, and pustular.

Acetanilid.—Occasional; erythematous, and erythematopapular; not infrequently cyanosis, especially of lips, face, and extremities.

Alcohol.—Rare; erythematous, and urticarial, of generalized distribution.

Anacardium.—Rare; urticarial, vesicular, and bullous.

Antimony—Tartar Emetic.—Uncommon; urticarial, and vesicopustular.

Antipyrin.[1]—Not uncommon; usually morbilliform, occasionally erythematopapular, polymorphous, scarlatiniform, and urticarial; there may be considerable sweating, variable pruritus, and desquamation may follow; trunk, flexures, and occasionally face are the most common sites; mouth, hands, and feet may also share in the eruption; exceptionally vesicopustular, bullous, furuncular, and purpuric. The erythematopapular may leave behind redness and pigmentation for several weeks. Exceptional blackness of the skin of the penis ("verge noire" of the French) has developed, usually taking a long time to disappear.

In some instances a tolerance is soon established, and the eruption may fade while patient still continues to take the drug.

Antitoxin.[2]—Rather frequent; simple erythema, scarlatiniform, morbilliform, urticarial, and polymorphous. The morbilliform and the scarlatiniform may or may not be followed by desquamation. There may be prodromic symptoms, or the outbreak may be sudden, with considerable temperature elevation, and pain and swelling about the joints. The rash may appear shortly after the injection is administered, or not until several or more days later. The subjective symptom of itching is variable in the different cases. The eruption lasts usually from several days to a week or more. Exceptionally petechiæ are observed.

[1] Apolant, "Die Antipyrinexantheme," *Archiv*, vol. xlvi., 1898, p. 345 (a thorough exposition of the subject, with brief résumé of the most important type-cases, and with a bibliography of 265 references to date); Fournier (3 cases "Verge noire"), *Annales*, 1899, p. 371; Wechselmann, *Deutsche med. Wochenschr.*, 1898, No. 21, p. 335, and *Archiv*, vol. l., 1899, p. 23; Deas (bullous), *Brit. Jour. Derm.*, 1899, p. 194; Barthélemy et Rellay (bullous), *Annales*, 1899, p. 478; Mibelli, *Giorn. ital.*, 1897, fasc. 5 and 6, pp. 575 and 697—abs. in *Annales*, 1898, p. 590.

[2] Dubreuilh, *Annales*, 1895, p. 891; Hartung, *Jahrbuch für Kinderheilkunde*, Bd. xliii., 1897, p. 72—full abs. in *Archiv*, 1900, vol. lii., p. 411 (in 375 cases, in 20 was local irritation, and in 68 general eruption); Schulze, "Die Serumexantheme bei Diphtherie," Inaug. Dis., Berlin, 1898—brief abs. in *Archiv*, vol. lii., 1900, p. 315 (out of 704 cases, 144 showed eruption; of these, 29 per cent. urticarial, 31.9 per cent. scarlatinoid, 11.1 per cent. morbilliform, 20 per cent. indeterminate, and remainder not noted); Berg, *Med. Record*, June 18, 1898, p. 865; Bauer (abstract with discussion), *Monatshefte*, 1899, p. 450; Rawlings, *St. Bartholomew's Hosp. Jour.*, Dec., 1898, p. 40; Washbourn, *Guy's Hosp. Gaz.*, Aug. 19, 1899; Malherbe, *Jour. Mal. Cutan.*, 1904, p. 499, ("verge noire").

Arsenic.[1]—Somewhat rare; almost every form of cutaneous eruption has resulted from the internal use of this drug—erythematous, papular, vesicular, urticarial, pustular, petechial, erysipelatous, herpetic, furuncular, carbuncular, pigmentary, keratotic, ulcerative, and gangrenous. The genital region, especially the scrotum, is the usual site of the ulcerative, edematous, and gangrenous manifestation. Herpes zoster has been observed in a number of instances to follow its administration (see herpes zoster). The long-continued use of the drug, as in

FIG. 103.—Keratosis (palms and soles) from the long-continued administration of arsenic. (Another illustration showing the development of epithelioma, apparently upon an arsenical keratosis, will be found under epithelioma.)

psoriasis and chorea, is sometimes followed by extensive pigmentation, especially about the trunk. As a rule, it eventually disappears sooner or later after the drug has been discontinued. Thickening of the horny part of the skin of the palms and soles, and over the elbows and knuckles, especially of the hands and feet, is occasionally noted in long-continued administration. The horny formations may

[1] Menéau, "Les dermatoses arsenicales," *Annales*, 1897, p. 345 (full paper and bibliography of 124 references); Brouardel, "Étude sur l'Arsenicisme," *Thèse de Paris*, Feb. 17, 1897 (an exhaustive paper); Moreira, "Arsenical Affections of the Skin," *Brit. Jour. Derm.*, 1895, p. 378 (8 cases—various types); Rasch, "Contribution a l'étude des dermatoses d'origine arsenicale" (2 cases, 1 zoster and 1 bullous, and partial review of the general literature of arsenical eruptions), *Annales*, 1893, p. 150.

Zoster eruption: Gerhardt, *Charité-Annalen*, Berlin, 1894; Nielsen, *Monatshefte*, vol. xi., 1890, p. 302 (10 cases, with literature references to others); Bettmann, *Archiv*, vol. li., 1900, p. 203 (1 case and bibliography); see also under herpes zoster for additional references.

Keratosis (palms and soles): Pringle, *Brit. Jour. Derm.*, 1891, p. 390; S. Mackenzie (also general cutaneous pigmentation), *ibid.*, 1896, p. 137; Colcott Fox, *ibid.*, 1893, p. 51; Hardaway, *ibid.*, p. 304; Payne, *ibid.*, 1895, p. 249; Hamburger (also cutaneous pigmentation), *Bull. Johns Hopkins Hosp.*, Apr., 1900, p. 87; Boeck, *Monatshefte*, vol. xvii., 1893, p. 184; Mibelli, *Lo Sperimentale*, 1898, Heft iv.; Lang, *Annales*, 1898, p. 480; Ullmann, *ibid.*, p. 481; Arning, *Verhandlungen der Deutsch. Dermatol. Gesellschaft*, V. Congress, 1894, p. 581.

Keratosis with epitheliomatous development: Hutchinson, J. C. White, Hebra, Jr., Hartzell, Schamberg, and others—see under psoriasis for references.

Pigmentation: Pringle, *Brit. Jour. Derm.*, 1895, p. 52; Schlesinger, *Wien. klin. Wochenschr.*, 1895, p. 779; Smetana, *Wien. med. Wochenschr.*, 1897, p. 903; Audry, *Annales*, 1896, p. 1415; Müller, *Archiv*, 1893, vol. xxv., p. 165; see also under psoriasis.

undergo epitheliomatous degeneration (referred to under psoriasis and epithelioma), and in a few instances death has finally resulted.

Belladonna—Atropin.—Not infrequent, especially in children; scarlatinous type most usual; patchy erythematous areas or flushings occasional. The eruptions are, as a rule, upon suspending the drug, of short duration. Exceptionally erythema and gangrene of scrotum have been observed. Itching is sometimes troublesome.

Bromin Compounds.[1]—Quite common. An acne-like papulopustular and pustular, about the regions of the face and shoulders and back most frequently; although the lesions are usually discrete, several or more may tend to group and become in places confluent, forming a sluggish, conglomerate patch studded with pustular points, and bearing slight resemblance to a superficial carbuncle. The eruption may be in some instances more or less generally distributed.

FIG. 104.—Dermatitis medicamentosa in a young child, from the ingestion of *potassium bromid;* the lesions of a pustulopapillomatous character, and of somewhat general distribution, but most numerous and marked on the face and lower extremities (courtesy of Dr. G. T. Jackson).

Occasionally erythematous, vesicular, papular, urticarial, furuncular, and carbuncular eruptions are observed to follow its administration. Exceptionally an eruption somewhat similar to erythema nodosum is encountered. Bullous development is rarely observed.

[1] Crustaceous and papillomatous eruptions: Jackson (2 cases (1 child)), *Jour. Cutan. Dis.*, 1895, p. 462; Elliot (2 cases—infants), *Trans. Amer. Derm. Assoc. for 1895;* Panichi, *Giorn. ital.*, 1897, fasc. 5, p. 559—abs. in *Annales*, 1898, p. 395; Malherbe (vegetative and ulcerative), *La Presse médicale*, May 24, 1899, p. 243; Hallopeau et Trastour (suppurating plaques), *Annales*, 1900, p. 883; Feulard, "Bromisme Cutanée," *ibid.*, 1891, p. 531; Pini (Bromoderma nodosum fungoides), *Archiv*, vol. lii., 1900, p. 164, with 4 plates—3 histologic—and some literature references; Colcott Fox, *Brit. Jour. Derm.*, 1892, p. 287; see also paper by Van Harlingen, *loc. cit.;* Hall (confluent pustular, child, with illustration), *Quarterly Med. Jour.*, Nov., 1902, p. 138; Myers, *Jour. Cutan. Dis.*, 1904, p. 231 (with illustration); Hallopeau and Vielliard (gangrenous), *Annales*, 1904, p. 442; Parkes Weber (granuloma-like or mycotic type case demonstration), *Brit. Jour. Derm.*, 1905, p. 63. Pasini, "Sur la pathogenie des eruptions bromiques (with review and bibliography), *Annales*, 1906, p. 1 (papulopustular, discrete, and confluent).

A rather rare manifestation, occurring especially in children and adolescents, consists of one or several or more red or purplish-red elevated, papillomatous, or condylomaform areas, sometimes crusted, and sometimes presenting numerous points of pustulation; there may also be, in parts of such lesions, superficial ulceration, but rarely of marked character. Such formations are usually of sluggish appearance, and while they may be numerous and of general distribution, there may be but one or two plaques present, occupying an area of several square inches. In the latter the lower part of the leg is the most common site; in the extensive form, legs, arms, and region of face are favorite situations.

Bromin eruptions may ensue after a few and small doses, but more commonly after the drug has been given for a few weeks or longer and after large doses. Bromin eruptions have been seen in infants suckled by a mother taking the drug, and when even herself free from any manifestation.

Contrary to observation concerning most drugs, the eruptive disposition from bromids may persist, especially in children, for several weeks after the drug has been discontinued. The plaque or condylomaform type is usually slow in disappearing.

Benzoic Acid and Sodium Benzoate.—Uncommon; from benzoic acid, erythematous, erythematopapular, and urticarial, the last most usual. After sodium benzoate, erythematous, polymorphous, and urticarial, with or without furfuraceous desquamation.

Boric Acid and Sodium Borate.[1]—Rare; from *boric acid* erythematous, papular, and bullous. An inflammatory scaly eruption, eczematous in character, quite marked on scalp, face, and neck, with more or less complete loss of hair, has resulted in a few instances after long-continued dosage; condition subsided after discontinuance and hair grew in again. From *sodium borate*, rare, erythematous, morbilliform, eczematous, and psoriasiform eruptions, the last after prolonged administration.

Calx Sulphurata.—Not common; usually furuncular and pustular, rarely vesicular, and exceptionally petechial.

Cannabis Indica.—Exceptional; vesicular, more or less general, with accompanying pruritus.

Cantharides.—Rare; erythematous, and papular.

Capsicum.—Rare; erythematous, and papulovesicular.

Chinolin.—Not infrequent; erythematous; observed in 6 out of 20 fever patients to whom this drug was given.

Chloral.—Not uncommon; scarlatinous most frequent and usually accompanied with febrile action, congestion of buccal and conjunctival mucous membranes, and followed by desquamation. Occasionally urticarial, papular, and vesicular, and exceptionally bullous, furuncular, carbuncular, petechial, and ulcerative; and in children, ulcers of the tongue and cornea.

Chloralamid.—Exceptional; punctate erythematous, with vesicles, and with redness of nasal and oral membranes, coryza, febrile action, and subsequent desquamation.

[1] Wild (boric acid and sodium borate), *Lancet*, 7, 1899, p. 23, with review of literature; Fordyce (boric acid), *Jour. Cutan. Dis.*, 1895, p. 499; Gowers (sodium borate), *Lancet*, Oct. 24, 1884; Evans (boric acid), *Brit. Med. Jour.*, Jan. 28, 1899.

Chloroform.—Not infrequent; erythematous, punctate, or blotchy; exceptionally purpuric.

Cod-liver Oil.—Rare; vesicular and acneiform.

Condurango.—Rare; acneiform and furuncular.

Conium.—Uncommon; erythematous, papular, and erysipelatous.

Copaiba and Cubebs.—Not infrequent; usually erythematous, scarlatinous, morbilliform, or polymorphous; rarely vesicular, papular, bullous, urticarial, and petechial. There may be considerable pruritus.

Copaiba.—Not infrequent; most of the rashes observed from the conjoint administration of copaiba and cubebs are due to this drug; scarlatiniform, urticarial, erythematous; rarely, vesicular, petechial, and bullous.

Cubebs.—Rather unusual; erythematous and small papular.

Digitalis.—Exceptional; scarlatiniform, papular, erythematopapular, urticarial, and erysipelatous (of face).

Dulcamara.—Rare; erythematous, urticarial, and erythematosquamous.

Ergot.—Rare, and usually only after prolonged administration. Vesicular, petechial, pustular, furuncular, and gangrenous; this last on the extremities and usually circumscribed.

Guarana.—Rare; urticarial.

Guaiacum.—Exceptional; miliary erythematous.

Gurjun Oil.—Rare; erythematous and erythematopapular.

Hyoscyamus.—Occasional; most commonly erythematous and urticarial, with edema, exceptionally scarlatiniform, pustular, and purpuric.

Iodin and its Compounds (Usually the Iodid Salts).[1]—Common; usually the papulopustular and pustular—iodid acne, so called. This is generally seen on face, shoulders, and back, although it may be more or less scattered; appears after one or more weeks' administration, and exceptionally after a few doses. Occasionally, in places, two or more lesions may become confluent, as in the bromid eruption, and give rise to a papillomatous, condylomaform, carbuncular, crustaceous, or rupial area; they are somewhat persistent, disappearing but slowly upon discontinuance of the drug.

Exceptionally the iodids may provoke a multiform or polymorphous eruption closely simulating erythema multiforme and sometimes erythema nodosum. Urticarial eruptions are also observed; likewise vesicular, bullous, and purpuric, although these latter only rarely.

[1] Recent literature of the more severe forms of iodid eruption: Hyde, *Arch. Derm.*, 1879, p. 333 (bullous types; with bibliography to date and analytic table), and *Jour. Cutan. Dis.*, 1886, p. 253 (with references); Morrow, *ibid.*, pp., 97 and 136; Norman Walker (vegetating, condylomatous type), *Lancet*, May 12, 1892, with literature references to other cases; Fordyce (nodular 1, rupia-like 2), *Jour. Cutan. Dis.*, 1895, p. 496; Cannet et Barasch (pustulonodular, fungoidal—death), *Arch. Gén. de Médicine*, Oct., 1896, p. 424; Malherbe (ulcerative), *La Presse médicale*, May 24, 1899, p. 243; Neumann (nodular-ulcerative, skin and mucous membrane of stomach—fatal case, uremic patient), *Archiv*, vol. xlviii., 1899, p. 324, with colored plates of face and stomach lesions; Milian (purpuric), *La Presse médicale*, Sept. 20, 1899, p. 193; Audry (disseminated gangrene), *Annales*, 1897, p. 1095; O. Rosenthal (tuberous and fungoidal, illustrations), *Archiv*, 1901, vol. lvii., p. 3; Hallopeau and Lebret (purpuric, bullous, and sclerous), *Annales*, 1903, pp. 826 and 925.

The bullous may be accompanied with considerable erysipelatous redness and swelling, and with more or less profound constitutional disturbance; such lesions may be numerous, sometimes con-

FIG. 105.—Dermatitis medicamentosa of a bullous type, from the ingestion of *potassium iodid*, in a woman aged fifty. Face, neck, forearms, and hands involved, and the seat of considerable edematous swelling and variously sized blebs. In some parts blebs became confluent, broke, and uncovered a superficially excoriated surface, as shown in cut. Recovery without any scarring or other trace. Patient had a weak heart.

fluent, and are most commonly seen on the face, hands, and arms. Ulcerations beneath the lesions are sometimes observed. The bullous and more severe types of iodin eruptions are usually seen in those with kidney and heart disease. The bullous and purpuric iodin eruptions are exceptionally of grave import, and in extreme cases a fatal issue, while not to be expected, occasionally results.

As in bromid eruptions, the eruptive tendency may persist for some time after the drug is discontinued, more especially in children, and rarely it does not appear until after the cessation of the drug. Iodid eruption has been sometimes seen in nursing infants to whose mothers the drug was being administered. Investigations (Briquet, Lyon) tend to show that the sodium salt is least apt to give rise to eruption. This agrees with my experience.

Iodoform.[1]—Uncommon; in addition to the dermatitis and eczematoid eruptions produced directly by the local action of this drug, referred to under the head of dermatitis venenata, cutaneous manifestations exceptionally follow its absorption, and may be erythematous, erythematopapular, and polymorphous, vesicular, bullous, and petechial. Serious constitutional symptoms can also result; delirium, nephritis, and death have been observed.

Ipecacuanha.—Exceptional; circumscribed erysipelatous patches of more or less general distribution.

Jaborandi and Pilocarpin.—Rare; erythematous, miliary, papular, and urticarial. Active diaphoresis.

[1] Colcott Fox, *Brit. Jour. Derm.*, 1890, p. 327; Taylor, *N. Y. Med. Jour.*, Oct. 1, 1887; Cutler, *Boston Med. and Surg. Jour.*, 1886, vol. cxv., p. 73; Etienne et Pilon, "Revue méd. de L'Est," June 1, 1895, p. 339, abs. in *Annales*, 1896, p. 417.

Mercury.—Not common; erythematous, scarlatiniform, papular, pustular, herpetic, bullous, purpuric, furuncular, and ulcerative. Almost all, more especially the severe forms, usually resulting from overdosing, and are scarcely observed at the present day.

Castor Oil.—Rare; erythematous, with pruritus.

Opium—Morphin.—Not uncommon; erythematous, of scarlatiniform, morbilliform, and polymorphous types, usually with intense itching; desquamation may follow; less frequently urticarial, and exceptionally vesicular, bullous, pustular, furuncular, and carbuncular.

Piper Methysticum.—Kava-kava, the fermented juice of this plant, gives rise to erythematosquamous, exfoliative dermatitis.

Phenacetin.—Not common; erythematous, erythematopapular, and urticarial.

Phosphoric Acid—Phosphorus.—Rare; bullous and purpuric.

Pimpinella.—Exceptional; urticarial.

Lead—Carbonate and Acetate.—Rare; erythematous and purpuric.

Potassium Chlorate.—Exceptional; erythematopapular, polymorphous; cyanotic.

Quinin,[1] **Cinchona.**—Occasional; erythematous, scarlatiniform, with or without desquamation, most commonly; less frequently urticarial, purpuric, vesicular, bullous, erysipelatous, and gangrenous (especially of scrotum). In the scarlatiniform and sometimes in other types of general distribution there may be considerable constitutional disturbance, with marked febrile action, etc. In the desquamating cases this may be branny, lamellar, or come off in sheets or from the hands as a partial or complete casting. Idiosyncrasy, and not dosage, is the all-important factor. Itching is frequently present, sometimes to an annoying degree.

In doubtful cases of sudden scarlatiniform and similar eruptions quinin should always be eliminated as a possible etiologic factor.

Rhubarb.—Exceptional; scarlatiniform desquamative erythema.

Salicylic Acid—Salicylates.—Not common; usually erythematous, scarlatiniform, and urticarial, with or without desquamation; rarely vesicular, bullous, purpuric, and even gangrenous.

Salol has exceptionally also been responsible for urticarial eruptions.

Salipyrin has been credited with producing edema and loss of tissue.

Santonin and Sodium Santonate.—Exceptional; from santonin, generalized urticarial with desquamation and edema; from sodium santonate, vesicular.

[1] Morrow, *New York Med. Jour.*, March, 1880 (an analysis of 60 cases—in 38, erythematous, of scarlatiniform or morbilliform type; in 12, urticarial, usually with edema or puffiness of the face; in others papular, vesicular, or petechial); Haralamb (erythema bullosum), *Annales*, Dec., 1895, p. 1048; Johnston (bullous; with literature references to several other cases), *Jour. Cutan. Dis.*, 1896, p. 266; Allen (acquired idiosyncrasy), *Med. Record*, vol. xlvii., 1895, p. 97; Heard (generalized erythematous, with desquamation—from ⅛-grain dose), "Trans. Acad. Med. of Pittsburg," *Philada. Med. Jour.*, Oct. 28, 1899; Simpson, *ibid.* (similar generalized case, with general desquamation, including the nails); Chomatianos (erythematovesicular and erythematobullous, hands and penis), *La Grece médicale*, 1899, No. 4—abs. in *Amer. Jour. Med. Sci.*, Aug., 1899, p. 231; D. W. Montgomery (purpuric—acquired idiosyncrasy), *Boston Med. and Surg. Jour.*, vol. cxxxvii., 1897, p. 646.

Silver Nitrate.—Slate-colored and grayish-black pigmentation or discoloration after prolonged use; exceptionally erythematopapular eruption.

Stramonium.—Not common; usually erythematous and scarlatiniform; rarely erysipelatous and purpuric.

Strychnin—Nux Vomica.—Rare; scarlatiniform, and miliaria, with pruritus.

Sulphonal.—Occasional; most commonly erythematous and scarlatiniform, with desquamation and accompanying pruritus; rarely morbilliform and purpuric.

Tanacetum.—Exceptional; varioliform.

Tannin.—Rare; erythematous and urticarial.

Tar.—Rare; erythematous, morbilliform, and urticarial.

Thallium Acetate.[1]—More or less complete alopecia.

Tuberculin.—Not common; erythematous, scarlatiniform, and morbilliform, with or without subsequent desquamation; exceptionally, psoriasiform.

Turpentine, Terebene.—Occasional; erythematous, scarlatiniform, and morbilliform; exceptionally vesicular and papular, urticarial, and pustular. *Terebene*, papular, with pruritus.

Valerian.—Exceptional; urticarial.

Veratrum Viride.—Rare; erythematous, and pustular.

Viburnum Prunifolium.—Exceptional; scarlatiniform, with subsequent desquamation.

THE EXANTHEMATA.

In many works on diseases of the skin the various eruptive fevers, generally classed under the term exanthemata, are accorded no space. Inasmuch, however, as their cutaneous features are always so prominent a factor, and their differentiation from other eruptive maladies so often demanded, they can, I believe, be viewed, as regards their consideration, as on the border-line between general medicine and dermatology, and therefore not an unnecessary addition in works on the latter branch. They are here presented in sufficient detail to be of value, although not in all their aspects so fully considered as in standard general medical treatises.

The several diseases in this group present certain common characteristics: they are of a specific infectious nature, with variable febrile and other constitutional symptoms, of self-limited course, usually occurring in epidemic manner, and for the most part diseases of childhood. Their skin manifestations differ slightly or materially both as to seat and intensity, as well as to lesional formation. One attack, as a rule, confers immunity from further infection. While micro-organisms are beyond reasonable doubt the active agents in these several affections, as yet it can scarcely be said that the specific microbes have been discovered, considerable diversity existing so far as to the alleged findings.

[1] Jeanselme, *Annales*, 1898, p. 999; Huchard, *Bull. de Acad. de Méd.*, March 17, 1898; Vassaux, *Thèse de Paris*, July 12, 1898—abs. in *Annales*, 1898, p. 813 (was valuable in sweating of phthisis, but in 34 cases, hair loss occurred in 8).

SCARLATINA.

(W. M. Welch.)

Synonyms.—Scarlet fever; *Fr.*, Scarlatine; *Ger.*, Scharlachfieber; *Ital.*, Febbre scarlatina.

Definition.—An acute infectious disease characterized by fever, angina of variable intensity, a diffuse punctiform rash appearing on the second day, and ending by a desquamation more or less copious.

Symptoms.—In studying the symptomatology of scarlet fever it is found most convenient to divide the disease into three stages—namely, the stage of invasion, the eruptive stage, and the stage of desquamation. The stage of invasion is usually sudden in its onset. It is seldom ushered in by a chill or chilly sensations, but in young children convulsions are not uncommon. Along with some indisposition, sore throat and vomiting are usually the earliest symptoms. The temperature rises rapidly, often reaching, in the course of a few hours, 102° to 104° F. The skin is hot and dry, the tongue furred, the face flushed, there is intense thirst, and the patient is restless. Taken together, the symptoms indicate the beginning of an acute illness, the nature of which, however, is not revealed until the rash appears, which is usually on the second day.

It is very common, indeed, for the **eruption** to appear within the first twenty-four hours of illness, and in normal cases it is rarely delayed longer than the second day. Almost always it is seen first on the trunk, the skin being slightly reddened on the chest and abdomen, frequently in the region of the groins. The redness rapidly increases, and on the evening of the second day it may be distinctly seen on all parts of the trunk and extremities. The face frequently escapes entirely. The cheeks may be more or less flushed, while the lips and alæ of the nose very often appear preternaturally pale. Pressure removes the redness momentarily. By drawing one's fingers quickly over the rash the momentary pallor that is produced will be quickly replaced by the redness, but presently the pale lines return again and persist for a minute or longer. The rash may vary very greatly in its distribution and intensity. Sometimes it is so scanty as scarcely to be recognized, or it may be seen in ill-defined patches, or it may be general and so intense as to suggest the existence of acute dermatitis. In well-marked cases the efflorescence covers all parts of the body, with perhaps the exception of the face, and on passing the fingers over the skin it may appear smooth, but there is in most cases a sensation of minute elevations, which are due to prominence of some of the hair-follicles similar to the condition known as cutis anserina. This condition may be so marked on some parts of the body as to present a papular appearance and thus give rise to a suspicion of measles, especially when there is normal skin intervening.

While the rash presents the general characteristics of a diffuse efflorescence, yet on close inspection it is found to be made up of innumerable puncta of more intense redness, with intervening erythema of duller hue. This gives to the rash a somewhat variegated appearance, being at the same time diffuse and punctiform. The color of the rash is often described as scarlet, but if it be compared at the

bedside with a piece of scarlet flannel, a wide difference will be observed, even when the rash presents its brightest appearance. It is difficult to describe the color exactly, but it may be said to be a dull red rather than a bright red. When the rash begins to fade, it presents a dusky or brownish-red color. It may disappear entirely in two or three days, but it frequently remains as long as six or eight days, and sometimes even longer. In a rash of extreme intensity minute hemorrhagic puncta may be seen, which generally disappear entirely on pressure. In such cases, as well as in many milder ones, innumerable miliary vesicles appear at the height of the eruption. These are much more frequent than is generally supposed, being often overlooked on account of their small size. They are, as the name implies, the size of a millet seed, conic in shape, and contain the merest speck of milky fluid. They are more frequently seen on regions of the skin in which the eruption is most intense, as upon the mons veneris and anterior axillary folds, yet they are by no means infrequently present on the abdomen and chest. A magnifying glass will often bring them into view, when they cannot be seen by the unaided eye. In certain atypical cases the rash may be so indistinct that its true nature cannot be recognized; or, indeed, it may be absent altogether. The only local manifestation of the disease in such cases is a slight soreness of the throat. It not infrequently happens during the prevalence of scarlet fever in a family that one member will be affected by a sore throat, more or less severe, without any eruption on the skin. Under such circumstances the diagnosis is made of "scarlatina sine eruptione," which diagnosis is sometimes confirmed later by the occurrence of sequelæ.

One of the earliest symptoms, as has already been mentioned, is **soreness of the throat.** At first only slight redness may be seen in the fauces, causing deglutition to be somewhat painful, and this condition often increases *pari passu* with the development of the cutaneous rash. In mild cases the throat symptoms may be moderate throughout the attack, or even absent. But in severe cases the fauces are often intensely inflamed and present an appearance comparable to the rash on the skin. The soft palate particularly is of a vivid red color and shows punctiform elevations. The tonsils are swollen and become partially covered with yellowish-white exudation. The mucous membrane involvement frequently extends to the nares, causing an irritating discharge from the nose. The tongue at first is red at the tip, and covered with yellowish fur. About the time the rash is developing on the skin the papillæ on the tongue become prominent and often project through the coating, thus giving the appearance described as "strawberry tongue." In three or four days the coating disappears entirely, leaving the tongue red and raw looking, with its papillæ very prominent, when the strawberry appearance is even more suggestive. In certain cases of scarlet fever the throat affection is so severe as to constitute an exceedingly prominent feature of the disease. The name applied to these cases is "scarlatina anginosa." The tonsils are greatly swollen and covered with membranous exudate. Deglutition is very painful and sometimes almost impossible without regurgitation through the nos-

trils. The tissues of the throat, particularly the soft palate, may undergo necrosis and slough away in good part. The breath is fetid, and constitutional depression profound. The glands of the neck in such cases are always swollen, and there may occur extensive abscesses in this region; so extensive, indeed, as to destroy a large area of skin and the underlying connective tissue, leaving the muscles and large blood-vessels exposed. In these extreme cases death is liable to result either from toxemia or exhaustion.

The **fever,** which is marked from the beginning, does not diminish, but rather increases after the appearance of the eruption. As a rule, the temperature ranges high. In the average case the axillary temperature is from 102° to 104° during the progress of the rash. In mild cases it may not rise above 102°, even when the rash is intensely marked. But in severe cases the temperature not infrequently reaches 105°, and may even exceed this. Hyperpyrexia sometimes occurs just before death, when the thermometer may register as high as 108° or 109°. The pyrexia in this disease, as in most other febrile affections, is characterized by morning remissions and evening exacerbations. When the rash begins to fade, the temperature declines, falling usually by lysis. Should it continue high, some complication probably exists. During the pyrexia the skin, of course, is hot and dry. The pulse is always rapid. This symptom is perhaps more uniformly marked in scarlatina than in any other infectious fever. In children the pulse ranges from 120 to 160. The number of respirations are usually increased proportionately to the height of the fever. It is only in exceptional cases that the stomach continues irritable after the initial vomiting. Anorexia, however, continues throughout the eruptive stage, and thirst is usually intense. The bowels are not necessarily disturbed. Nervous symptoms, such as headache and slight muttering in the sleep, commonly appear with the initial fever; and during the progress of the disease, especially when the temperature ranges high, there may be restlessness, jactitation, and insomnia, or even active delirium. Slight albuminuria is present in a certain proportion of cases during the eruptive stage, but its presence at this time does not necessarily denote renal disease. This may occur at a later stage as a complication or sequela and will be considered presently.

The lymphatic glands are involved in a large proportion of cases of scarlet fever. They may be found swollen in the submaxillary region at an early stage of the disease. According to Schamberg's[1] investigation, the inguinal glands are invariably enlarged, and those in the submaxillary, cervical, and axillary regions are also very commonly enlarged. The glandular intumescence usually bears some proportion to the toxemic condition. Suppuration of the glands of the neck not infrequently occurs; but those located in other parts of the body rarely suppurate. This process, however, does not usually take place until the rash has disappeared. An acute phlegmonous inflammation involving the glands and connective tissue of the neck may occur and prove very destructive to the parts, and consequently fatal to the patient.

[1] Schamberg, *Annals of Gynecology and Pediatry*, Dec., 1899.

In epidemics of scarlet fever some cases are sure to develop into a **malignant type** of the disease. The tendency to the occurrence of this type varies in different epidemics. The disease may be marked with unusual severity from the beginning, presenting such symptoms as high temperature, excessive irritability of the stomach, extreme restlessness and delirium, or even convulsions. The delirium may be followed by partial coma, a rapid and feeble pulse, intense fever, and disturbed respirations. Death sometimes occurs within the first forty-eight hours of the disease as a result of the intensity of the poison. The disease but rarely assumes the hemorrhagic form, which is recognized by the livid hue of the rash, the presence of petechiæ or purpuric spots, and by epistaxis and hematuria. From this variety recovery is rare, and the struggle usually short.

When the rash of scarlet fever begins to fade, the skin assumes a dusky or brownish hue, is dry and slightly rough, and begins to show signs of shedding its upper layer. This process is known as **desquamation.** In severe cases it usually begins before the rash has entirely disappeared, being first seen on the neck and gradually extending to other parts of the body. Quite frequently it is noticed first at the summits of the miliary vesicles and spreads from each of these points by centrifugal expansion. In its degree and extent it always bears a very distinct relation to the diffuseness and intensity of the rash. When the latter has been intense, the desquamative process is very copious, the epidermis being shed in flakes and scales. On the hands and feet, where the horny layer of the skin is thicker, casts resembling gloves and slippers are sometimes exfoliated. The finger-nails may be shed, but the hair rarely falls out. When the rash has been extremely mild, the desquamation is sometimes furfuraceous in character, and it may be even so slight as to be scarcely perceptible; but it is rarely entirely absent, except perhaps in cases of scarlatina sine eruptione. It has been known to occur more than once in the same case. I am able to cite one instance in which both the rash and desquamation recurred twice. The time required for completion of the process, counting from the beginning of illness until all parts of the body, including the palms of the hands and soles of the feet, are perfectly smooth, is from six to eight weeks, and sometimes longer.

Certain **complications** are liable to occur, and of these otitis media is perhaps one of the most common. It most frequently appears during the second week of illness. The earliest symptom is pain in the ear, and this is soon followed by a purulent discharge from the external meatus. Partial or complete deafness may result, although the majority of cases recover without impairment of hearing. In some cases there is suppuration in the mastoid cells, and even such serious results as meningitis, thrombosis, or abscess of the brain. A mild form of arthritis, commonly called rheumatoid pains, often appears during the subsidence of the fever. Abscesses of the neck are of frequent occurrence. Endocarditis, pericarditis, or myocarditis is not uncommon. Pneumonia or pleurisy occurs occasionally during convalescence. The latter is sometimes associated with acute nephritis and a general dropsical condition, and the effusion which takes place in the pleural cavity is often purulent. Affections of the eye

sometimes occur, but only rarely are they serious. I recently saw a case of temporary blindness, doubtless caused by nephritis; also two cases of exophthalmos from infiltration of the cellular tissue of the orbit. Both of the latter were albuminuric, and death resulted. I have also seen several cases of sloughing of the soft palate, the trouble beginning as a perforating ulcer.

Albuminuria is not infrequent. It may be met with at an early stage of the disease as the result of malignancy or intensity of the fever, but far more frequently does it occur from the fourteenth to the twenty-first day as the result of postscarlatinal nephritis. One of the earliest symptoms of this condition is extreme pallor, with puffiness about the face. Whether or not this symptom is noticed it is advisable to examine the urine frequently during the second, third, or even the fourth week of illness. The presence of albumin in the urine does not always depend upon the severity of the scarlatinal attack. Indeed, very severe forms of nephritis not infrequently follow extremely mild attacks of scarlet fever. The quantity of albumin present may vary greatly in different cases. It may be so scanty as scarcely to be found, or so abundant that almost the entire column of urine in the test-tube solidifies by boiling. The amount of urine secreted is usually diminished. In very severe cases there may be almost complete anuria, and the small quantity that is secreted is usually dark, often bloody, and contains, besides albumin, tube-casts. The scanty elimination of urea may cause constant vomiting and repeated convulsions, and death may result, with all the symptoms of acute uremia. In cases somewhat less severe there is a puffy appearance of the face, especially about the eyelids, and often general edema. The urine is scanty, sometimes bloody or smoky in appearance, and contains tube-casts. The dropsy increases, effusion into the serous cavities may occur, and the child, after suffering for several days, may die from effusion into the pleura, edema of the lungs, or uremic poisoning; or death may result suddenly from hydropericardium. Fortunately, in most cases very much can be done by prompt and judicious treatment for relief of the threatening symptoms of this complication.

Scarlet fever is sometimes complicated with diphtheria. It has been found, by systematically culturing all cases admitted to the Municipal Hospital, Philadelphia, that the Klebs-Löffler bacilli are present in from 10 to 15 per cent. Not infrequently, however, these organisms are found in cases presenting no clinical evidence of diphtheria.

Etiology and Pathology.—The cause of scarlet fever is undoubtedly a specific infection, and is transmitted by persons suffering from the disease or by means of infected clothing, bedding, and the like. All persons are not equally susceptible to the disease. Many are naturally immune, while others are exceedingly vulnerable to the infection. **Age** is of considerable importance as a predisposing factor. The disease is far more common among children, and especially among those under ten years. Adults are not exempt. The reason why they suffer less frequently is not wholly because most of them had undergone the disease in childhood. There is no doubt that the susceptibility which is present at an early age often entirely

disappears as the individual develops into adult life. It is advisable, therefore, to keep a child away from the infection as long as possible. Moreover, statistics show that the younger the child, the greater the danger. Neither sex nor race exerts any predisposing influence. The same may be said of season, although some writers believe the disease is apt to prevail with greater intensity during fall and winter. It often occurs sporadically from time to time, or it may assume an epidemic prevalence. Epidemics differ greatly in severity without any known cause.

Scarlet fever is infectious at all stages, but most highly so during the period of desquamation. While the poison is undoubtedly given off with the breath and the exhalations and secretions from the body of a patient, it seems to be most intense in the exfoliated particles of the skin. At any rate, this has long been considered one of the most active agencies in the spread of the disease. Even at a very late stage, when desquamation has apparently finished, the patient may communicate the infection. This has occurred not infrequently after the patient had been isolated for nine or ten weeks, and when the skin had become perfectly smooth. The infecting principle may reside for a long time in the discharges from the ears and nares when they are affected. Many authorities believe that the isolation period should continue for twelve or thirteen weeks, or even longer when such complications as just mentioned exist. Indeed, it is impossible to state exactly the number of weeks that should elapse before freedom from infection by a patient can be guaranteed. The infecting agent is very subtle, and not only readily adheres to material substances, but may retain its morbific power for a long time, especially in clothing tightly rolled up and packed away. It is quite possible for physicians, nurses, and others to convey the contagium. Several instances are recorded of its having been communicated by milk. It is generally believed that the puerperal state renders the individual peculiarly susceptible to the scarlatinal virus; but while the puerperal woman may suffer from scarlet fever, it is not improbable that septicemia accompanied by a rash is sometimes mistaken for that disease. The same explanation may hold good in many cases of so-called "surgical scarlet fever."

Nothing is positively known of the infecting agent of scarlet fever, though it is believed to be a specific germ. Streptococci are found in the throat, skin, and other parts of the body, and the streptococcus pyogenes in the discharge from the ears. Class, of Chicago, claims to have cultivated a diplococcus from the throat, blood, and scales in 300 successive cases of scarlet fever, and he believes this to be the specific cause of the disease. It must be said, however, that this claim needs further confirmation before it can be accepted. The period of incubation is somewhat variable in different cases, though it is invariably much shorter than in the other acute exanthemata. The disease has been known to occur within a few hours after exposure; and as many as nine days have elapsed before symptoms developed. The more common period is from two to five days. One attack usually confers permanent immunity, although there are well-authenticated instances of the disease having recurred once, or even twice.

This disease presents but few anatomic changes postmortem. Except in the hemorrhagic form, the skin-lesions disappear after death. Inflammation of the fauces, tonsillitis, and enlargement of the lymphatic glands, or lymphadenitis, are about the only pathologic conditions constantly met with. Of course, any complication that may have existed will present its own peculiar morbid appearance. When death results from postscarlatinal nephritis, marked renal changes will be found.

Diagnosis.—Except in atypical cases, the diagnosis of scarlet fever is not difficult if attention be given to the following clinical points: The disease begins abruptly, usually with vomiting, slight soreness of the throat, and rise of temperature. In twenty-four hours or less the rash appears on the neck, chest, and abdomen, being rather fine at first, but rapidly increases in intensity and spreads to all parts of the cutaneous surface except the face, which often escapes. When fully formed, it is diffuse and punctiform in character. With the appearance of the rash the fever increases, the tongue becomes furred, red at its tip and edges, and the pulse is rapid. The lymphatic glands, especially those of the groins, are almost always enlarged. The rash is quite invariably followed by desquamation. Of the few diseases which may be confounded with scarlet fever, only three are deemed worthy of consideration: measles, erythema scarlatinoides, and septicemia. Measles may be differentiated by the longer stage of invasion, and which is characterized by catarrhal symptoms; by the rash first appearing on the face and extending to the trunk and extremities; by the macular character of the rash and its so-called crescentic arrangement; by the comparative absence of sore throat, and by the branny character of the desquamation. Erythema scarlatinoides may be distinguished by the uniform distribution of the efflorescence instead of the punctiform character; by the longer duration of the efflorescence and its tendency to recur; by the absence of marked throat symptoms; and sometimes, also, by shedding the hair and the nails, as well as the epidermis. The rash of septicemia is sometimes quite similar to that of scarlet fever. But in this affection a history of sepsis is almost always obtainable, the temperature usually shows greater variation, the "strawberry tongue" is wanting, and there is no desquamation.

Drug-rashes are sometimes mistaken for scarlet fever. These are usually transitory and rarely generalized. They are not associated with fever, nor with the train of symptoms peculiar to scarlet fever. The rash caused by belladonna, and less frequently that by quinin, gives perhaps the best simulation.

It must be admitted, however, that in every epidemic there occur atypical cases about which there is much doubt as to the diagnosis. This doubt may sometimes be dispelled by the occurrence of nephritis or subsequent well-marked cases of scarlet fever in the family.

Prognosis.—In forecasting the final result in any case it is necessary to take into consideration the character of the epidemic, the severity of the symptoms, the age of the patient, and the nature of the sequelæ, if any. Epidemics differ very greatly in severity: some are mild and others malignant. In private practice among the better

class the death-rate is usually not so high as in the hospitals, where a larger proportion of the cases is apt to be severe. In the latter the death-rate may range from 5 to 10 per cent. in mild epidemics, and as high as 20 per cent. and over in severe ones. The unfavorable symptoms are persistently high temperature and vomiting, great restlessness and delirium, severe involvement of the throat, the occurrence of petechiæ and hemorrhages, and a livid rash.

Age is an important factor to be considered. But few infants under one year recover if the attack be at all severe. The disease is, in fact, especially to be dreaded in children under five years. Nephritis occurring as a complication is, in the majority of cases, quite amenable to treatment. But if such symptoms as suppression of the urine, convulsions, and coma occur, the prognosis becomes grave.

Treatment.—The prophylaxis of scarlet fever can be accomplished only by perfect isolation of the patient and attendants, by thorough and prompt disinfection of every infected article, and by preventing the dissemination of the epidermal scales. After convalescence is completely established and desquamation ended, the patient should have an antiseptic bath and be provided with clean clothing before being permitted to mingle with other persons.

In caring for mild cases hygienic treatment alone will often suffice. A suitable temperature should be constantly maintained in the room, and ventilation should be thorough, without exposing the patient to currents of air. A light diet and cooling drinks are to be preferred as long as the temperature is above normal. There is no article of diet preferable to milk, as this is least irritating to the kidneys. In view of the fact that nephritis is liable to occur as a complication or sequela attention should be given not only to the kidneys, but to the skin. A tepid bath once or twice daily will tend to maintain the functions of the skin, and thus lessen the liability to renal affection. After subsidence of the fever the diet may be more liberal, avoiding, however, too large a quantity of nitrogenous food. During desquamation occasional bathing with warm water should be continued, and it is advisable to rub the patient every day with an unguent or oil containing some antiseptic. After the temperature has continued normal for a week or ten days the patient may be allowed to get out of bed if properly clothed. But for three or four weeks at least great care should be taken to prevent exposure to cold.

In severe cases we are powerless to do more than treat symptoms as they arise. The febrile invasion may call for a febrifuge mixture, such as liquor ammoniæ acetatis and a little spiritus ætheris nitrosi, slightly sweetened with syrup. When the temperature reaches 103° F., sponging with tepid water is serviceable. The temperature will more certainly be reduced by using equal parts of alcohol and water. In sthenic cases cool water may be used either for sponging or bathing. A cold pack in such cases, or a warm pack when the circulation is feeble, will often reduce the temperature considerably, allay delirium and restlessness, and secure for the patient a few hours of refreshing sleep. An ice-cap constantly applied is also of great service. Some one of the medicinal antipyretics, repeated in suitable

doses, may act advantageously in some cases; but, upon the whole, they are not so safe and reliable as hydrotherapy. For the extreme pruritus of the skin usually present during the eruptive stage there is nothing that affords more prompt relief than rubbing the patient with cacao-butter.

In mild cases the throat symptoms do not require any special attention; but when severe, the fauces, and even the nares, if affected, should be cleansed with a weak antiseptic solution. Peroxid of hydrogen properly diluted is very useful for this purpose. It may be used by means of an atomizer. A warm normal salt solution is less irritating and equally useful as a cleansing agent for the nares. Ice may be applied to the neck when there is much swelling. When the inflammation extends through the Eustachian tubes to the middle ear, the pain often becomes distressing. As a palliative measure the ears may be syringed with water as warm as can be borne. The tympanum should be frequently inspected, and as soon as any bulging is noticed it should be carefully punctured. In the vast majority of cases, however, the tympanum ruptures spontaneously. The purulent discharge should be frequently washed from the ears by the injection of tepid water and soap or an antiseptic solution.

The nephritis should receive prompt attention. As soon as albumin is discovered in the urine the patient, if up and dressed, should be put back to bed immediately and kept in an equable temperature of 70° to 72° F. The use of highly nitrogenous food, and even preparations of iron, should be suspended. The diet should be restricted to milk; water may be given freely. The quantity of urine voided in twenty-four hours should be noted, and the urine should be examined at frequent intervals both chemically and microscopically. It is well to commence treatment by placing over the region of the kidneys a warm poultice composed of fifteen parts of flaxseed meal and one part of ground mustard. If there be diminished secretion of urine, a non-stimulating diuretic may be given. I know of no formula more useful in this condition than infusion of digitalis with acetate of potassium. Calomel and saline cathartics are also useful. In severe cases small doses of pilocarpin are recommended by some authors, but this drug often proves very depressing to children. When the secretion of urine is nearly suppressed or scanty, great benefit may often be derived from a hot pack or a hot-air bath. Either of these measures usually causes very free sweating, and in obstinate cases should be repeated twice daily, especially when good results are noticed. When convulsions occur, hydrate of chloral may be given. If they are persistent, the inhalation of chloroform may prove serviceable.

A certain degree of anemia is apt to follow the severe forms of scarlet fever, and especially when complicated by nephritis. For this condition the ferruginous preparations are indicated. Basham's mixture is highly recommended by many authors.

RUBEOLA—MEASLES.

(W. M. Welch.)

Synonyms.—Morbilli; *Fr.*, Rougeole; *Ger.*, Masern; *Ital.*, Rosolia.

Definition.—An acute, highly contagious disease, characterized by fever, marked catarrhal symptoms of the respiratory tract and the occurrence of a macular rash about the fourth day of illness, without any abatement of the earlier symptoms.

Symptoms.—The disease usually begins as a common cold. At first a feverish condition is noticed, and there may be slight shivering, but rarely a decided chill. Sneezing and coryza are often the earliest symptoms observed, and soon become very pronounced. There is slight running at the nose, and the eyes are irritable, reddened, and watery. More or less intolerance to light is noticed. Examination of the mouth and throat will show a furred tongue and hyperemia of the fauces. Toward the end of the initial stage a distinct punctiform rash may be seen on the mucous membrane of the mouth, with the exception of the tongue. On the buccal mucous membrane opposite the molar teeth may also be seen in most cases minute bluish-white specks at the summits of small red spots. These are known as Koplik's spots.

Subacute laryngitis is commonly present. This is denoted by hoarseness and a troublesome cough, which is dry, sonorous, and distressing. The hyperemia may extend lower down in the respiratory tract and give rise to symptoms of bronchitis. With these local catarrhal affections, which may vary greatly in severity in different cases, there is usually proportionate pyrexia, the axillary temperature varying from 101° to 104° F. The appetite is impaired or lost. There is often headache, always debility or lassitude, and sometimes nausea and vomiting. Epistaxis is not uncommon. Convulsions may be seen in children, but are not of frequent occurrence. Spasm of the glottis or false croup sometimes occurs in young children.

The average duration of the initial stage is about four days. It may be as short as two or three days, but more frequently it is as long as five or six days, and sometimes even longer.

The **eruption** first appears on the face and neck. On the neck, behind the angle of the jaw, it often assumes its distinctive character earlier than anywhere else. It appears as small red spots which increase in number and size, spreading over the face first and rapidly extending to the trunk and extremities. The redness now entirely disappears on pressure. The eruption is macular in character, sometimes becoming somewhat papular on some parts of the body, but never presenting to the touch the shotty sensation peculiar to variola. When fully developed, the eruption arranges itself into irregular outlines which are commonly described as crescentic in shape, with here and there normal skin intervening. At this stage the face is slightly swollen and the lymphatic glands of the neck may become somewhat enlarged and sensitive, though the latter symptom is not so prominent as in scarlet fever. The curvilinear or peculiar shaped character of the eruption is usually found best marked on the chest,

abdomen, and back. The eruption reaches its fullest development on the face on the second day, and on the trunk on the third day, when it begins to recede on the face. On the fourth day it is still seen on the trunk and extremities, but presents a faded appearance. After the eruption disappears there remain for several days innumerable yellowish-brown spots, giving to the skin a distinctly mottled appearance.

The **fever and catarrhal symptoms**, so prominent in the initial stage, do not abate with the appearance of the eruption. On the contrary, the fever not infrequently is highest after the eruption appears, reaching often 104° to 105° F. on the first and second days. On the third or fourth day of this stage, when the eruption is fading, the temperature falls rapidly to normal, and the catarrhal symptoms also become markedly mitigated. The fall is usually by crisis; when by lysis it is probably because of the persistence of the catarrhal symptoms.

After the rash has entirely disappeared a slight desquamation occurs in the form of fine furfuraceous scales, often so fine as to be scarcely noticeable. It is certainly not to be compared to the coarse desquamation in scarlet fever. In the absence of complications all symptoms now rapidly disappear, and convalescence is established.

The description given applies to typical measles, but it is well known that in epidemics atypical cases are common. Sometimes the disease is so mild and thought to be so trivial that the family physician is not sent for. Every patient, however, should be confined to bed. The stage of invasion may be abnormally short, lasting only thirty-six or forty-eight hours, and marked by mild symptoms; or, on the other hand, it may be prolonged to five or six days and attended by severe and painful catarrhal symptoms and extreme systemic depression. The eruption also may be abnormal either in its mildness or intensity. The macules may be very scanty, or even quite abundant, and disappear with remarkable rapidity; or they may be so copious as to constitute a general efflorescence, quite like the redness of erysipelas. A high temperature and an adynamic condition are common in the latter form of the disease. The severest and most dangerous type of measles is the hemorrhagic. Fortunately, these cases are not common in family practice. They are met with occasionally in crowded institutions, in military camps, and in bad hygienic environments. In this type of the disease the early symptoms are severe, and the eruption never develops properly. The spots at the beginning are livid, and soon become petechial. Hemorrhages occur from the nose and often from the mucous membrane of other parts. There is profound systemic depression, and death is apt to occur early from disorganization of the blood.

In measles **complications** are not infrequent, especially in certain epidemics. Those most commonly met with are inflammations of the respiratory tract. Bronchitis and bronchopneumonia are most frequent and most dangerous, especially in infancy and early childhood. These affections more often occur during the decline of the eruption. Lobar pneumonia may occur, but is less frequent and not so dangerous. Phthisis pulmonalis sometimes follows an attack of

measles. Laryngitis of mild form is not at all uncommon, and may give rise to symptoms of spasmodic croup. In severe and fatal epidemics diphtheric laryngitis or membranous croup not infrequently occurs, requiring for its relief intubation or tracheotomy. Recovery from this complication is very uncertain. Catarrhal inflammation of the middle ear is seen sometimes, but not so frequently as in scarlet fever. The mild conjunctivitis commonly present may develop into the purulent form; so also it may become chronic and persist as a sequel. Likewise iritis, blepharitis, keratitis, and some other eye affections occasionally develop as sequels.

Complications located in the mouth and intestinal tract are sometimes met with. Aphthæ and ulcerative stomatitis are not uncommon. Gangrenous stomatitis or cancrum oris may occur. The form known as noma usually progresses rapidly to a fatal termination. Intestinal catarrh causing troublesome diarrhea occurs not infrequently, and it may lead to enterocolitis, especially in very young children or debilitated subjects.

Etiology and Pathology.—The infectious nature of measles is most probably due to a peculiar micro-organism, but none has yet been conclusively demonstrated. The disease prevails in all countries and all climates wherever the infection is introduced. It is one of the most highly contagious of the communicable diseases, and but few enjoy natural immunity. It is most common in childhood, but it also occurs in adults who have not had the disease at an earlier period of life. Age, *per se*, exerts no influence, except that infants at the breast, under six months, very frequently escape an attack when amply exposed. It has, however, occurred in infants less than a month old. Sex likewise exerts no influence. The infection is exhaled with the breath from a patient, and is also given off with the secretions, particularly those from the nose. It may be communicated by infected clothing, but not so readily as is the case in some other infectious diseases.

Measles shows a decided tendency to prevail in epidemics, and in large cities these often occur in cycles of two or three years. The disease may prevail at any season of the year, but is rather more common during the winter and spring months. It may occur oftener than once in the same individual. Some claim to have had as many as three or even four attacks; but it is not improbable that rötheln is sometimes mistaken for measles. The rule is that one attack confers immunity against subsequent attacks.

The disease is infectious at all stages. It is most infectious during the catarrhal and eruptive stages, and least so during the desquamative stage. It is said to have been communicated during the period of incubation. This period, or the interval between the reception of the infecting principle into the system and the occurrence of symptoms, is subject to some variation. It may be as short as seven and as long as eighteen days. The usual period, however, is about twelve days.

The pathology of measles is very simple. Apart from the cutaneous manifestations nothing abnormal is seen except when complications arise. The skin-lesions consist of an acute hyperemia with a

tendency to slight cellular infiltration around the blood-vessels of the corium, more particularly those which surround the hair, sebaceous and sudoriparous follicles. There is commonly catarrhal inflammation of the mucous membrane of the larynx, and occasionally small areas of ulceration. A catarrhal condition is sometimes seen extending to the lining of the trachea and bronchi. In the vast majority of fatal cases there is found capillary bronchitis or bronchopneumonia. Lobar pneumonia is less frequently seen. The bronchial glands are said to be invariably swollen. When death occurs at a very late stage of the disease, tuberculous deposits are not infrequently found. The mucous membrane of the intestinal tract sometimes shows evidence of catarrhal inflammation. Peyer's patches are often involved, being intensely hyperemic and much swollen.

Diagnosis.—In the diagnosis of measles it is important to bear in mind the symptoms of the two principal stages of the disease. Usually it is quite impossible to fully recognize its presence during the first or initial stage. But if to such symptoms as persistent sneezing, watery eyes, slight discharge from the nares, a hoarse, rasping cough, and rise of temperature there can be added a history of exposure, the diagnosis of measles may be made with a reasonable degree of certainty. Such a history, however, can but rarely be obtained in isolated cases, and hence the diagnosis in the majority of cases cannot positively be made until the rash appears. It is important to remember that the rash often appears first on the mucous membrane of the mouth and fauces. The presence of Koplik's spots may help one to arrive at an early diagnosis; but these are sometimes absent.

The distinguishing feature of the disease is the rash, which appears after a catarrhal stage of about four days. It is first seen on the face, and rapidly spreads over the entire body. The spots are red, macular in character, and show a tendency, when fully developed, to arrange themselves into irregular shapes, with traces of normal skin intervening, giving to the eruption curvilinear or crescentic outlines. The eruption is distinguished from that of small-pox in that it is macular instead of papular, and that it never develops into vesicles nor pustules. The disease with which measles is more likely to be confounded is scarlet fever. In the latter affection the initial stage is short, usually not longer than twenty-four hours, and the rash first appears upon the trunk, rapidly spreading to all parts of the body with the exception of the face, which is often not perceptibly involved. It differs from the rash of measles in that it is diffuse and punctiform in character. The exclusion of rötheln is at times most difficult. This affection may be differentiated by the absence of prodromal symptoms, or, if present, by their shorter duration and by the milder fever. The rash may be discrete or confluent, but it seldom assumes the so-called crescentic arrangement. Drug-rashes may be excluded by the absence of fever and catarrh of the respiratory tract.

Prognosis.—By most physicians measles is regarded as quite an innocent malady, yet by consulting the mortality bills of the large cities of every country it is found to rank high as a cause of death, especially during the last few years. Osler says: "Among the erup-

tive fevers it ranks third in the death-rate." It is a question, however, whether it has not lately been more fatal in many parts of the world than scarlatina, or even variola. In uncomplicated cases the death-rate is not high; but in certain epidemics catarrhal inflammation of the respiratory organs frequently occurs and is directly responsible for the largest number of deaths. In pulmonary complications, therefore, the prognosis should always be guarded. From hemorrhagic or "black" measles recovery is rare. In the adynamic type of the disease patients are likely to be overwhelmed by the poison and die from toxemia. When measles is associated with or immediately follows some other infectious disease, like scarlatina or diphtheria, the symptoms often become very serious. The development of membranous croup is always of grave import. Should tuberculosis follow as a sequel, death is liable to occur sooner or later.

Treatment.—When measles has broken out in a family or an institution for children, very little can be done to prevent its spread. The effort, however, should be made by isolating the affected child. In private dwellings the uppermost room should be selected as the sick chamber, and all communication therewith cut off. Attention should be given to ventilation and disinfection. But in spite of the very best efforts the object frequently will not be attained. After infection has taken place nothing can be done to prevent the attack; but when symptoms appear, an effort should be made to conduct the case to a favorable termination. The patient should be confined to bed in a carefully ventilated room in which the temperature is maintained at about 70° F. The bed-clothing should be neither too heavy nor too light, but suited to the comfort of the patient. Cooling drinks and a suitable diet should be allowed. The foolish notion of the laity that heavy clothing and hot drinks are required to bring out the eruption should be discouraged. There are, however, cases in which the eruption is very tardy in making its appearance; such cases may be benefited by a warm bath and hot drinks.

When the fever ranges high, it may be modified by careful sponging, beginning with tepid water and gradually reducing its temperature. Internally cold water may be allowed quite freely to assuage the extreme thirst. To older children and adults may be given cold acidulated drinks, like lemonade. With the object of allaying the cough as well as modifying the fever a mild sedative mixture containing citrate of potassium, sweet spirits of niter, syrup of ipecacuanha, and syrup of tolu may be given in suitable doses frequently repeated. A little paregoric may be added when the cough is distressing. In ordinary cases no additional treatment is required, but when the temperature of the patient is persistently high, and nervous symptoms develop, besides the cool bath, such antipyretics as antipyrin, phenacetin, and the like may be given in carefully regulated doses so as to reduce the temperature moderately without causing the depressing effect of these drugs. The bromids are always indicated when the nervous symptoms are pronounced.

In order to relieve the photophobia and lessen the congestion of the conjunctivæ bright light should be excluded from the room, and a few drops of boric acid solution (gr. xv (1.) to ℥j (32.)) instilled into

the eyes several times daily. If the eyelids adhere during sleep, a little vaselin may be applied to their edges.

The hemorrhagic and ataxic or adynamic types of the disease require tranquilizing and supporting measures. If epistaxis be troublesome, it will need attention. Indeed, all complications, such as capillary bronchitis, bronchopneumonia, lobar pneumonia, and membranous croup, should receive the treatment best adapted to each of these affections occurring under other circumstances.

Great care should be exercised during convalescence to secure perfect restoration to health. It is commonly believed that "catching cold" at this period may lead to serious lung trouble. In view of the fact that convalescents from measles are peculiarly vulnerable to the infection of tuberculosis, it is advisable to guard against the occurrence of pulmonary catarrh or exposure to a tuberculous subject.

RÖTHELN.

Synonyms.—Rubella; German measles; Epidemic roseola; Hybrid measles; French measles; *Fr.*, Roséola épidémique.

Definition.—Rubella, or rötheln, is a mild, contagious, eruptive disease, with a slight febrile action, and usually of but several days' duration.

Symptoms.—The period of incubation is somewhat variable, usually, however, from one to three weeks; with a stage of invasion, frequently but a few hours, scarcely ever exceeding one or two days, and characterized by slight malaise, enlargement of the cervical glands, and less frequently the other lymphatic glands, generally insignificant febrile action, and sometimes with headache and pains in the extremities. Exceptionally there may be some symptoms of nervous character. Very often, however, constitutional disturbance, which is rarely marked, is entirely or apparently wanting, and the first recognizable sign of the malady is the rash. This may first present upon any part, but much more commonly on the upper half of the body, and frequently on the face and scalp, and extends rapidly downward. Sometimes along with the rash slight catarrhal symptoms are also noted, as mild coryza, injection of the conjunctiva, with lacrimation and slight redness and soreness of the fauces. The eruption usually consists of more or less rounded rosy spots, varying in size from a pinhead to that of a lentil, and which are made up of closely set points, with trifling but scarcely recognizable elevation, being macular or maculopapular in character. The color rarely gets beyond a pale red, never violaceous. Sometimes the tint extends as a faint halo just a little beyond the border of the actual lesion. The spots may be somewhat disseminated or more or less crowded, the eruption seldom covering more than half the surface; it not only spreads rapidly, but as it spreads the first spots are frequently already disappearing. The rash rarely lasts more than a few days from beginning to the end. Desquamation is unusual, and when observed, is commonly of an almost imperceptible branny character. The general symptoms, if present, are scarcely ever pronounced, the temperature only occasionally going beyond 100° F., and very often it is normal

throughout. In exceptional instances relapse occurs, either immediately or after several days, but not later than two weeks (Emminghaus).[1] The eruption is not always a clearly distinctive one, as it may resemble both measles and scarlet fever; as Crozer Griffith[2] states, "the eruption is maculopapular, pin-head- to split-pea-size, pale-rose, multiform, usually discrete, sometimes grouped as in measles, sometimes confluent as in scarlatina." It undoubtedly more frequently bears decided resemblance to measles, and in considering the points of difference, Atkinson truly says that there is no feature of either affection that may not be sometimes observed in the other, whether it belong to the incubative, invasion, eruptive, or desquamative stages.

The most common subjects of the disease are children, it being most frequent between the ages of five and fifteen; adults are only rarely affected. The disease is not thought to recur, one attack giving immunity. It is usually epidemic in character, seldom presenting sporadically, so that reported sporadic cases must be looked upon with considerable doubt, as the possibilities of an erroneous diagnosis are naturally great. The danger of contagion is believed to be greatest during the eruptive period.

Diagnosis.—The malady is to be distinguished from measles, scarlet fever, and the medicinal erythemata. The mildness of the disease, its short period of invasion, often entirely absent; the rapid development and disappearance of the rash, the slight angina and conjunctival injection; and, as a rule, the absence of a tendency to crescent shape or to scarlatinous confluence; the slight or lacking febrile action, the enlarged cervical glands; and the usually almost imperceptible, often absent, character of the desquamation, are the distinguishing features. The importance of the glandular enlargement referred to has been emphasized by many writers, and while taken together with other factors is of great value, is not to be given too much weight, as Atkinson, Crozer Griffith, and others have called attention to the fact that it is very often observed in measles also.[3] In typical examples of the malady there is seldom any difficulty in reaching a correct diagnosis, but in atypical cases it is only by a careful consideration of the points of difference in these several febrile eruptive diseases, sometimes supplemented by one or two days' observation, that error can be avoided. From the medicinal rashes there is rarely much trouble in distinguishing it, as these are usually more pronounced, the eruptions more vivid or dark red, with the absence of the other symptoms of rötheln, as well as a history of drug ingestion.

Prognosis and Treatment.—The malady is, as a rule, a trivial affair, and is over in the course of several days or a week or so, and there are not, as often observed in measles and scarlet fever, any

[1] Quoted by Atkinson, *Amer. Jour. Med. Sci.*, Jan., 1887, in an excellent paper on the disease, giving its history, with numerous references. Relapses were also noted in a few instances by Harrison, *Brit. Jour. Derm.*, 1892, p. 112, and also by other writers.

[2] Crozer Griffith (a report of 150 cases), *Med. Record*, July 2 and 9, 1887 (with full bibliography).

[3] Crozer Griffith, "The Differential Diagnosis of Rubeola and Rubella, with Especial Reference to the Enlargement of the Glands of the Neck," *University Med. Mag.*, Philada., June, 1892.

sequelæ. It is true, as in any other disease, complications may arise in this, doubtless independently of the malady itself, and the outcome would then depend upon the nature of the complication, a few deaths having been reported in consequence of such accident. The treatment is purely expectant, and generally none is required. The patient should be kept housed, and if there is febrile action, in bed, and with a plain diet.

VARICELLA.

Synonyms.—Chicken-pox; Water-pox; Variolæ spuriæ; *Fr.*, Variolette; *Ger.*, Spitzblattern.

Definition.—A contagious febrile systemic affection of benign type, occurring chiefly in children, and characterized by an eruption of discrete, scattered, superficially seated, thin-walled, usually small-pea-sized vesicles.

It seems strange that even at this late date there should still exist physicians who look upon small-pox and chicken-pox as identical. This was the teaching of the Vienna school under Hebra, and this view is still maintained by Kaposi, but it need scarcely be said that those holding this opinion to-day are extremely few and isolated, and that even a suggestion of such an association to American and English minds is received with complete incredulity, and opposed by all extended clinical observation and experience and the facts evolved by the effect of vaccination.

Symptoms.—The eruption may be the first evidence recognizable by the patient, appearing without appreciable systemic disturbance. On the other hand, there may be for several hours or one or two days premonitory symptoms of slight malaise, chilliness, and mild febrile action, which in average cases are scarcely sufficiently well marked to elicit more than passing attention. Exceptionally however, in extremely susceptible children and in cases in which the eruption is extensive, the prodromal disturbance may be relatively severe. The eruption makes its appearance slowly, as a rule, and never all at once, presenting usually first upon the trunk and head, more especially the scalp. If seen in their earliest formation, or if the development of the later lesions is watched, the first stage is, as a rule, noted to be a small hyperemic spot, in the center of which a minute, elevated, vesicopapule or vesicle appears, pin-point to pin-head in size, rapidly growing to small pea-sized, the pinkish or reddish peripheral portion of the macule or spot usually measurably or completely subsiding during the vesicular evolution. New lesions continue in an ill-defined, crop-like manner or irregularly, several or more at a time for twenty-four to forty-eight hours, and sometimes slightly longer.

The eruption, when sufficiently developed,—usually in from several hours to a day after it begins,—is noted to consist of scattered vesicles of scanty or abundant or variable number, and in various stages of formation; usually some clearly defined, rounded, translucent, small or large pea-sized vesicles, with practically no areola, some

with a small areolar band; others with minute beginning vesicular lesions presenting at the central point of small pinkish or reddish spots or macules. In short, various stages of the lesional formation can usually be seen, although in some instances many are fairly well rounded and mature pea-sized vesicles, many of which stand out from the skin without surrounding band of redness; others are somewhat irregularly shaped. In some of the vesicles the walls are somewhat flaccid, always thin, often ruptured accidentally. In larger lesions, and especially if of slow formation, while the enlargement from a pin-head-sized vesicle into that of a pea-sized is taking place by peripheral extension, the central part has already begun to dry, and is, compared to the fresher peripheral portion, depressed. Umbilication, therefore, while not a common feature as thus described, is not infrequent in several or more marked or maturing lesions.

As a rule, the individual lesions reach full development in several hours to one or two days, by which time desiccation has already set in, drying to thin, film-like crusts. The contents, at first clear, soon become milky, and later may be slightly puriform. This latter probably results usually from accidental irritation or inoculation; it is chiefly in such lesions, particularly when scratched and made more inflammatory and sometimes impetiginous, that slight scarring results. This is uncommon, however, and when occurring is usually in some lesions on the face. Subjective symptoms are rarely complained of, but occasionally there is itching, and in extensive cases, some tenderness. The eruption is commonly scanty, and chiefly seated upon the trunk, more numerous usually upon the back; the scalp also generally shows some vesicles, but the face and extremities relatively few. Sometimes they are also observed on the adjoining mucous surfaces, more especially in the mouth and throat; the covering is soon broken or rubbed off, and superficial abrasions result. Exceptionally the eruption may be quite extensive, but with no tendency to confluence, grouping, or bunching; in such instances the constitutional disturbance, generally slight, usually continues until the height of the malady is reached. The process is, as a rule, ended, and the crusts fallen off in from seven to twelve days after the inception of the disease.

Exceptionally the vesicles are somewhat large, exceeding the size of small or medium-sized peas; or such pemphigoid development is noticed to follow the ordinary sized lesions, developing from the latter or arising independently. In such rare instances, as doubtless in the 4 cases reported by Pye-Smith,[1] it seems probable that the bleb eruption is not necessarily a part of the varicella, but is due to some accidental and subsequent infection. The seriousness of this development or complication would also support this belief. To accidental infection is also to be attributed that condition known as varicella gangrænosa (*q. v.*), in which gangrenous development, in rare instances, follows upon varicellous and other eruptive lesions.

Etiology and Pathology.—The malady is contagious, and, according to Hutchinson and LeGendre, it is inoculable, although

[1] Pye-Smith, "Four Cases of Bullous Varicella," *Brit. Jour. Derm.*, 1897, p. 148.

Smith[1] failed to produce it in his experimental attempts. One attack is usually protective—it is rarely observed twice in the same individual. Nor does an attack protect against small-pox, as would be the fact were the two diseases at all related.[2] It has been alleged that it occurs most frequently immediately before, during, and after small-pox epidemics, but this will not bear the test of investigation. The period of incubation doubtless varies somewhat from ten to seventeen or eighteen days—Smith's observations indicate between fifteen and seventeen days. Young children are its usual subjects. In an analysis by Baader (quoted by Smith, *loc. cit.*) of 584 cases, 382 occurred between the ages of one and five, 191 between six and ten, 7 between eleven and fifteen, 2 between sixteen and twenty, and 2 between twenty-one and forty. I have observed an instance of its occurrence in a man past sixty. The most common age is about three.

The pathologic changes are superficial, rarely extending below the middle layers of the rete, in this respect differing from variola, in which the process is most pronounced in the lowest layers and the papillary body. The vesicle cavity is, in the earliest stages at least, divided by septa, as in the latter disease, but, according to Unna,[3] in varicella the septa join on the covering wall, whereas in the small-pox lesion at the center of the base. The cavity proper occupies only the upper part of the much widened prickle layer. Fibrinoid degeneration of the epithelium takes place, and to which process Unna gives the name of "reticulating colliquation," in view of the most frequently recognizable stage of the fibrinous reticulum.

Diagnosis.—The diagnostic points in varicella are the absence or lightness of the systemic disturbance, the distribution of the eruption, usually most pronounced on trunk, and often on scalp, the superficial nature of the lesion, its thin, easily ruptured wall, and the irregular, crop-like appearance of the eruption. The disease with which it is most likely to be confounded is small-pox, more especially in the earlier stage. Morrow[4] states that in an analysis of 38 cases of error reported to the New York Health Board at a certain period for small-pox, 17 were cases of chicken-pox. It is true that urticaria bullosa, impetigo contagiosa, and a few other diseases have occasionally been confounded with varicella, but such mistakes are usually the result of hasty and imperfect examination, and readily avoidable, as the features of these several affections (*q. v.*) are sufficiently distinctive.

The disease differs from variola in many particulars, although the differences are much less recognizable when it concerns mild cases of small-pox or varioloid and severe cases of chicken-pox. The most important differential points in my judgment are the distribu-

[1] J. Lewis Smith, *Diseases of Children*, 1896 edition, p. 326.

[2] See a suggestive and, for the patient, extremely unfortunate, exemplification of this fact reported by Dyer "On the Differential Diagnosis of Varicella and Variola," *New Orleans Med. and Surg. Jour.*, Jan., 1896. The patient, according to Dyer's opinion, presented varicella, but was placed in the small-pox hospital by the municipal authorities, who considered the case variola; the patient made the usual course of average varicella and was discharged; a few days subsequently he presented small-pox of confluent form, was again taken to the hospital where he had contracted the disease, and died.

[3] Unna, *Histopathology*, p. 635.

[4] Morrow, "On the Diagnosis of Small-pox," *Jour. Cutan. Dis.*, 1886, p. 72.

tion, the manner of appearance, the character of the lesion and its thin covering or wall, and the nature of the constitutional symptoms. In chicken-pox the trunk presents the most lesions, and the face, hands, and extremities are comparatively, or in some cases wholly, free; whereas in variola the hands and face and extremities are generally most markedly involved. In chicken-pox the eruption rarely, if ever, comes out at once, but there are irregular or crop-like outbreaks for two or three days, although the largest number appear with the first outbreak; the lesions are, therefore, to be found in all stages of evolution. They begin as hyperemic spots from the center of which a vesicle develops, or they begin as vesicles; the beginning spot or lesion is never hard or shotty. In small-pox, on the contrary, the lesions usually appear at one time or within several hours or a day, and their evolution and course are, therefore, uniform, although naturally some lesions may be larger than others; they are distinctly hard and shotty in the beginning. The lesions of varicella are discrete and usually scattered, with no tendency to close grouping, bunching, or confluence. In variola closely set grouping or crowding together and confluence are quite common. The lesion of varicella is relatively rapid, often beginning to crust over in a few days, whereas that of variola is slow and much longer in its course. The character of the lesions in the two diseases is often strikingly different. The varicella vesicle is extremely superficial, thin-walled, translucent, often of irregular or irregularly rounded shape, and easily broken, accidentally or intentionally; whereas that of variola is deep-seated, often markedly globular; the covering is thick and tough, with little if any tendency to break, even if roughly handled, and with a yellowish cast, but not translucent, owing to the thickness of the walls. Umbilication is not an essential feature of varicella, and is generally seen only in few lesions, and these the larger and usually the relatively slow-developing vesicles, and it frequently results from a beginning desiccation of the central or earliest formed part; the lesions rarely become pustular; as a rule, only slightly cloudy or milky, and are not distinctly multilocular. In variola a sinking-in of the central part is a common feature of all cases and all lesions, and is observed long before the actual desiccating stage has been reached, being in fact a part of the advanced vesicular stage, the lesions becoming globular as they develop into pustules, and again slightly umbilicated as desiccation takes place; the lesions all become purulent, and are, except in the very latest stage, clearly multilocular. Scarring is the rule in variola, and rare in varicella, and then usually due to accidental irritation. The constitutional disturbance in varicella is slight or wanting, except in the extensive cases, and the eruption is often the first evidence of the malady. Even in severe cases it usually subsides rapidly after the eruption has appeared or reached full development, and does not reappear; in variola, on the other hand, there are almost always distinct prodromal symptoms for several days—headache, backache, general rheumatic pains, some gastric uneasiness, and febrile action, especially developing with the eruption, upon the full appearance of which it partially subsides, to become marked again when the pustular stage approaches.

Prognosis and Treatment.—The disease is benign and runs a quick, favorable course, recovery ensuing in one to two weeks. Rare instances of fatal ending are in all probability purely accidental, and due to some complication wholly independent of the varicella exanthem. Treatment is purely hygienic and expectant. As a matter of precaution, the patient should be kept housed, and if the eruption is at all extensive, in bed. A mild antiseptic dusting-powder, such as boric acid, can be used to lessen the chances of accidental infection. For the same reason scratching should be cautioned against, and if there is sufficient irritation or itching present to lead to this, a saturated solution of boric acid with ½ dram (2.) of carbolic acid to the pint (500.) can be used.

VARIOLA.

(W. M. Welch.)

Synonyms.—Small-pox ; *Fr.*, Petite-vérole ; *Ger.*, Blättern or Pocken ; *Ital.*, Vajuolo.

Definition.—Small-pox is an acute infectious disease characterized by an initial fever of about three days' duration, succeeded by an eruption passing through the stages of papule, vesicle, and pustule, ending in incrustation, and leaving pits or scars ; the fever either intermitting or remitting in the papular, and increasing in the pustular, stage.

Symptoms.—The period of incubation of small-pox is seldom less than eight days or more than fourteen, commonly from ten to twelve days. The symptoms constituting the initial stage, or **stage of invasion**, are usually ushered in suddenly and often with considerable violence. Among the earlier symptoms is a distinct chill, which may be mild or severe, and which is immediately followed by rise of temperature. The thermometer often registers 103° or 104° F. on the first day, and may be a little higher on the succeeding days. The pulse and respirations keep apace with the febrile movement. Prostration is often extreme. Vertigo on assuming the erect position is a frequent symptom. At this time vomiting and epigastric tenderness are commonly observed. Headache usually begins at the onset of the disease, and continues until the appearance of the eruption. It may be excruciating, and, when the fever is high, accompanied by delirium. Convulsions are very common in children, and at times there may be coma. Pain in the lumbar and sacral regions comes on early, and, like the headache, subsides at the beginning of the eruptive stage. This symptom is not invariably present, although it occurs in over one-half of the patients. In hemorrhagic cases the backache is often violent. A peculiar prodromal rash, varying in frequency in different epidemics, often makes its appearance on the second day, and disappears within forty-eight hours. It is stated by some authors to be scarlatiniform in character, but in my experience it has more often resembled measles, and has been designated "roseola variolosa." I have observed this rash more frequently in varioloid than in severe cases of variola.

The **eruption** usually appears upon the third day of illness,

manifesting itself first upon the face, particularly about the forehead, temple, and mouth, and then rapidly appearing upon the scalp, neck, ears, forearms, and hands. In the course of twenty-four hours the body and lower extremities become involved. The eruption continues to increase for two or three days before its definite limit is reached. The lesions consist at first of minute red points, which in the course of twenty-four hours develop into elevated papules with characteristic shot-like induration. On the third day of the eruption many of the lesions will be found to contain a little clear serum, and by the fourth or the fifth day all the papules will have been converted into vesicles with cloudy or milky contents. These continue to enlarge, attaining their maximum size about the seventh or the eighth day. Many of the vesicles will be seen to have the central depression or umbilication, which is a feature of diagnostic value.

FIG. 106.—Well-marked discrete small-pox on ninth day, showing lesions in the stage of beginning crust-formation (courtesy of Dr. J. F. Schamberg).

The **stage of suppuration** usually commences about the sixth day, when the contents of the vesicles are yellowish and decidedly puriform. In the process of development the pustules lose their umbilication and become large and globular. The reddish areola, which at first surrounded the lesions, acquires greater breadth and a more intense hue. Where the pustules are thickly set, as upon the face, great swelling and intumescence take place, so distorting the patient's features as to render him completely unrecognizable. The eyelids are frequently so edematous as to preclude the possibility of their being opened. The lips, nose, and ears are greatly tumefied, and the

PLATE XVI.

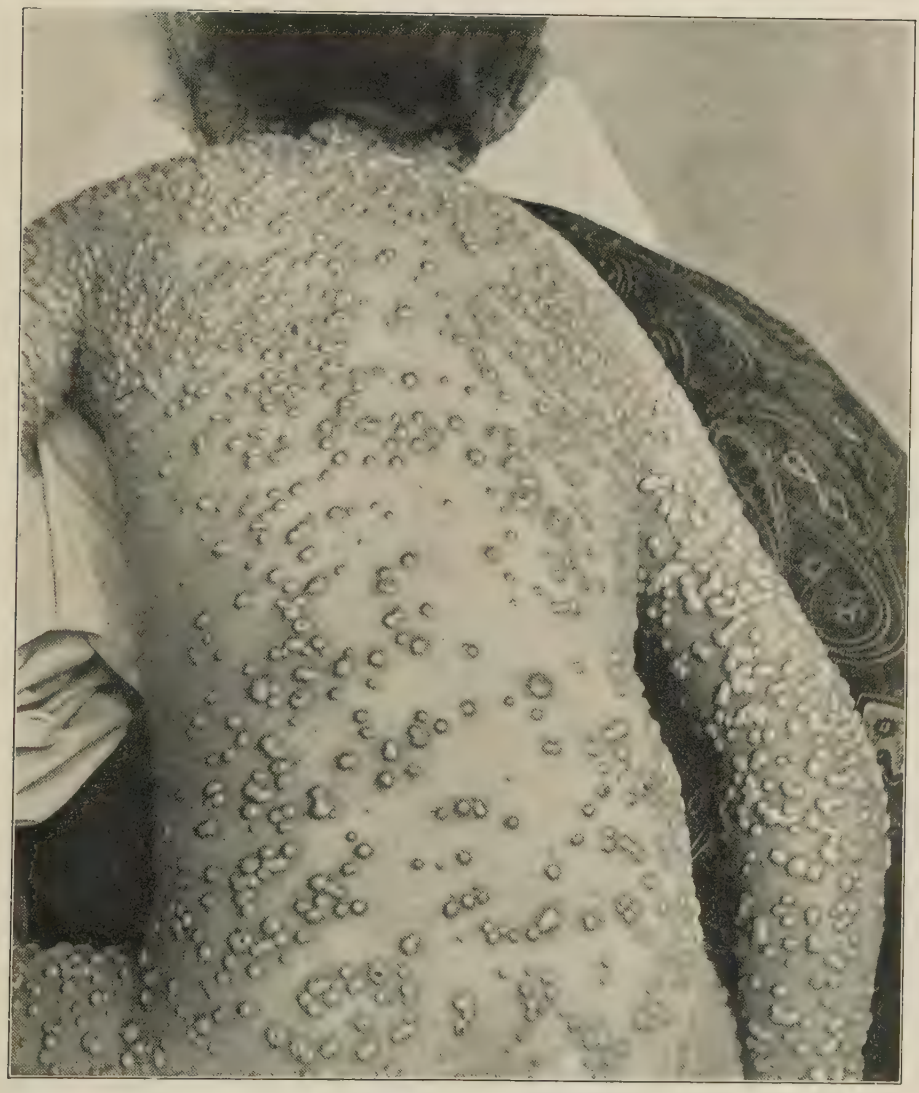

Variola—an extensive case showing numerous lesions on trunk as well as face and extremities (courtesy of Dr. G. W. Wende).

scalp is swollen and painful. The mucous membranes are also attacked, the lesions manifesting themselves upon the lips, buccal and nasal mucous membrane, tongue, pharynx, and at times the larynx.

Upon the appearance of the eruption, or, more commonly, on the second or the third day thereafter, the temperature falls, the headache, backache, vertigo, vomiting, etc., cease, and the patient believes himself on the road to convalescence. The subsidence of these symptoms, however, except in mild cases, is only temporary, for upon the commencement of the stage of suppuration the temperature again begins to rise and continues high until the decline of the suppurative fever. The height of the fever is proportionate to the extent of the eruption, the temperature varying from 102° F. in mild cases to 104° or 105° F. in confluent small-pox. Headache, restlessness, and delirium are common during this stage, the patient at times sinking into the typhoidal state.

During the **stage of desiccation,** which begins about the eleventh or twelfth day, the tumefaction subsides, and the normal contour of the features is gradually restored. The contents of the pustules dry into crusts, which process is often accompanied by intense itching. The crust-formation begins in the center of the pustules, leading to a secondary umbilication. In regular cases of variola vera the shedding of the scabs requires a period of three to four weeks, making the entire duration of the disease about five or six weeks. After the scabs have fallen the skin presents a red, spotted appearance, and is disfigured by scars or pits. These are deepest on the face, particularly about the end and alæ of the nose. The hair is often lost, but thorough restoration usually follows.

The clinical history of small-pox is not complete without reference to other forms and varieties of the disease. The above description relates more particularly to cases in which the eruption is either discrete or semiconfluent. The grades of small-pox cover a wide field of variation, from an eruption consisting of but a few small pustules, scarcely sufficient to identify the disease, to an eruption completely covering the entire cutaneous surface. During the past few years there has appeared in this country an epidemic of small-pox so unprecedentedly and uniformly mild as to constitute an unwritten chapter in the history of the disease. Its benignancy can be best estimated when it is stated that the mortality-rate among many thousand vaccinated and unvaccinated cases throughout the United States during the first three months of 1901 was not much over 1 per cent. The clinical picture is that of mild varioloid, despite the absence of any such modifying influence as commonly exists in this form of the disease. Therefore a brief description of varioloid will suffice to portray also this unusually mild form of small-pox.

The prodromal symptoms of **varioloid** may be severe or mild; in the latter case it being possible to prophesy a sparse eruption. The duration of the initial stage is more variable than in variola vera, varying from twenty-four hours to five days. The eruption of varioloid differs from that of variola only in that it is milder in its course and shorter in duration. The lesions may be limited to a

very few on the face, or they may be semiconfluent. In the milder forms the lesions may become abortive at an early period; in the severe forms the evolution of the lesions may not differ from unmodified small-pox. The cutaneous involvement is often superficial, being limited to the upper layers of the skin. As a result, we have a shorter eruptive course, earlier desiccation, more rapid shedding of the scabs, and fewer and less disfiguring scars. Occasionally the lesions develop into large, solid papules, conic in form, with vesicular summits. On shedding of the crusts, instead of pits, tuberculated or warty-looking excrescences are left. These, however, flatten down and disappear in the course of time. Secondary fever is either absent or trivial in character.

FIG. 107.—Variola—moderate case (courtesy of Dr. G. W. Wende).

The eruption of **confluent variola** is usually preceded by severe prodromes, such as high fever, intense headache and backache, vomiting, etc. The temperature does not descend as low on the appearance of the eruption as in milder cases, nor does the remission continue so long. On account of the extensive involvement of the skin, redness and swelling begin early, the former as early as the second day. Many of the thickly set papules coalesce, and in the formation of vesicles the confluence is so great as often to cover almost the whole cutaneous surface. The confluent pustules are usually flat, and sometimes present a milky or pasty appearance. At the height of the eruption the patient is unrecognizably disfigured. The mucous membranes of the nose, mouth, pharynx, and larynx are often intensely involved. The soft palate, tonsils, and tongue may become greatly swollen, and edema of the glottis may lead to a fatal termination. Upon rupture of the pustules and decomposition of the contents the stench often becomes unbearable. Secondary fever is usually very high, and death frequently occurs at this period from septicemia and exhaustion. When recovery takes place, convales-

cence is long and tedious, and apt to be interrupted by the occurrence of boils and abscesses.

The names **petechial, purpuric,** and **hemorrhagic variola** are applied to the different phases presented by malignant small-pox. A petechial rash is sometimes seen at the close of the initial stage, about the time the true eruption appears or should appear. This is quickly followed by the purpuric or hemorrhagic lesions, which lead rapidly to a fatal termination. At other times petechiæ and ecchymoses appear between the papules or vesicles, the latter often filling up with a sanguinopurulent fluid. **Variola purpurica** is the most malignant form of the hemorrhagic type. At the end of the initial stage, which is particularly characterized by intense backache and excessive prostration, a diffuse scarlatinoid efflorescence appears on various parts of the trunk and extremities. This gradually assumes a dark-red or purplish coloration, which does not disappear on pressure. In addition, petechiæ, vibices, and ecchymoses occur. The face soon becomes involved, presenting a swollen and puffy appearance. Indistinct sanguinolent vesicles, blackish or leaden-gray in color, may be seen in various localities. As the disease progresses, the skin becomes almost black or a deep indigo color. Hemorrhages occur from the various mucous membranes. Death is the almost inevitable termination. In the form designated **variola hæmorrhagica pustulosa** the vesicles, instead of filling with purulent material, contain a bloody fluid. This condition of the vesicles may be limited to certain localities or may be generalized, with petechiæ and ecchymoses interspersed. Hemorrhages occur from the nose, mouth, and intestinal and urinary tracts. This form runs a somewhat longer course than purpura variolosa, but is almost as certain to end fatally.

Among the common **complications** and sequelæ of small-pox may be mentioned erysipelas, boils, abscesses, and disease of the eyeball, middle ear, respiratory tract, and joints. Erysipelas occasionally comes on during desiccation, and is apt particularly to involve the face. Pneumonia sometimes occurs. Furuncles and abscesses are extremely common. But few patients pass through a well-marked attack of small-pox without suffering from boils during the later stage of the disease. Gangrene of the skin, especially of the scrotum, is a complication which usually leads to a fatal termination.

Etiology and Pathology.—Few would deny at the present day that the exciting cause of small-pox is the introduction into the system of a specific micro-organism. At this writing, however, it would appear unwise to pin one's faith to any particular parasite thus far discovered. Streptococci, spore-bearing bacilli, and protozoa have each in turn been invoked by various observers as the *causa causans* of variola. While recent investigations would seem to strengthen Pfeiffer's protozoan theory, the bacteriology of small-pox must be said to be still *sub judice*. The staphylococcus aureus and other pyogenic organisms are uniformly present in the pustules. The malady is undoubtedly contagious in all stages characterized by symptoms. The disease is least transmissible during the initial stage, and most highly so during the suppurative and early period

of the desiccative stages. The body may transmit the contagium even after death.

The earliest and most important anatomic changes in small-pox are seen in the epidermis. According to Unna, the chief pathologic changes noted are as follows: The poisoned epithelium in the upper prickle-cell layer of the rete mucosum softens and becomes edematous from swelling of the protoplasm within the epithelial cells, while a fibrinoid degeneration of albuminoid bodies set free from the cells takes place. Owing to the slow advance of colliquation or softening of the prickle cells, other epithelial cells of the mucous layer are compressed into trabeculæ or septa, perpendicular in the center of the pock, and directed somewhat outward at the periphery. The younger epithelial cells of the lower rete meanwhile assume the form of hollow spheres or balloons. Unna describes the fibrinoid degeneration of the epithelium in small-pox as presenting two forms—reticulating colliquation (or softening), which predominates at the periphery of the pock, and ballooning colliquation, which is well marked in the center. The umbilication is due partly to reticulating colliquation and partly to edematous swelling of the epithelial cells, which occurs chiefly at the periphery. The center, owing to the lesser grade of swelling, simply remains behind. Other observers believe umbilication to be due to the holding down of the center of the vesicle by a sweat-duct or hair-follicle.

There is, of course, at the beginning of the eruption a hyperemia produced by engorgement of the papillary blood-vessels. This is followed by a serous exudation into the surrounding tissues, accompanied by moderate cell-infiltration. Owing to swelling and proliferation of the rete cells, the Malpighian layer of the skin becomes hypertrophied in circumscribed areas, thus producing the prominence of the papules. When the vesicles and pustules are formed, the papillary layer of the corium is flattened by downward pressure. As long as the integrity of this layer is preserved, no scarring or pitting results. When the eruption is severe and deep, however, the papillary layer of the true skin is unable to resist the inflammatory process, and the papillæ undergo necrotic degeneration and form part of the pustular débris. The restoration of this loss of tissue in the corium can take place only through connective-tissue growth, and consequently a scar remains.

The liver, kidneys, spleen, and heart muscle undergo important pathologic changes, which are, however, scarcely peculiar to small-pox. In hemorrhagic small-pox large or small extravasations of blood may be found in the various organs and tissues.

Diagnosis.—In the initial period of the disease great assistance may be gained by determining the presence or absence of vaccine marks and their number and character. Furthermore, by ascertaining whether or not small-pox is prevalent, and whether the patient has been exposed to the disease. During the eruptive stage variola may be confounded with varicella, pustular syphiloderm, impetigo contagiosa, drug-rashes, etc.

The onset of varicella is very different from that of variola. There is usually no distinct febrile stage preceding the eruption. It is true

PLATE XVII.

Variola on the seventh day, showing the usual preponderance of lesions on the face, hands, and wrists (courtesy of Dr. J. F. Schamberg).

that in many cases of extremely modified small-pox no reliable history of an initial stage can be obtained, so that in such cases the diagnosis must be made from the appearance and behavior of the exanthem alone. It is important to bear in mind the following facts: that the lesions of varicella make their appearance as distinct vesicles containing perfectly clear serum; that they are usually seen first on parts of the body covered with clothing, and especially on the back, where they are apt to be most abundant; that they make their appearance in successive crops, and may be seen in every stage of development; that they vary very greatly in size; that they are unilocular and have an epidermal covering so delicate as to be readily broken by the finger-nail; that they are rather soft and velvety to the touch; that many of them enlarge to a considerable circumference by peripheral expansion, while others are as small as millet seeds; that they are not umbilicated except by desiccation beginning in their centers; that they run their course to the formation of crusts in two to four days; that the crusts are thin, brown, and friable, and when they have fallen off, red instead of pigmented spots remain; and that but few of the lesions are followed by permanent scars. The exanthem of small-pox, on the other hand, begins in the form of papules which are firm and dense to the touch, feeling somewhat like grains of sand buried in the skin; that they usually appear first on the face and then on other parts of the body; that the papules slowly develop into vesicles with milky or turbid contents; that the vesicles in well-marked cases are umbilicated; that they are multilocular and have an epidermal covering so dense as not to be easily broken by the finger-nail; that the eruption prefers the exposed parts of the body, such as the face, hands, and arms, being often only sparsely seen on the trunk; that the vesicles are usually quite uniform in size; that they change into pustules; that the eruption requires in severe cases twelve or more days to pass through its various stages, while in extremely mild cases not more than five or six days are required; that the crusts which form are thick and very dark, and when they have fallen off, there remain pigmented spots and more or less pitting.

Despite the above differentiation, it must be admitted that small-pox may occur in a form so atypical as to make the differential diagnosis a matter of great difficulty. In such cases the patient should be isolated and carefully watched for a few days, when the nature of the disease will, as a rule, be easily determined.

The lesions of the pustular syphiloderm frequently resemble very closely those of small-pox. The difficulty of diagnosis is often increased from the fact that the eruption in syphilis is not infrequently preceded by fever and various aches and pains, and that the lesions begin as papules and end in pustules. Instead of appearing all at once, the eruption of syphilis usually comes out in successive crops. Pustular syphiloderm, however, may be distinguished by the milder constitutional symptoms during the initial stage; by appearance of the lesions in successive crops; by the formation, at the summits of the papules, of small vesicles which later become pustular; by the large indurated base of each vesicle; by the absence of typical umbilication; by the tendency to ulceration of some of the lesions;

by the slower course of the eruption, and by concomitant symptoms of syphilis and a history of infection. In doubtful cases a few days' observation of the patient will usually suffice to determine the question.

Impetigo contagiosa has been confounded at times with the mild variola of recent years. It may be easily differentiated by the absence of fever, by the usual limitation of the lesions to the face and hands, by the fact that they are primarily vesicular or bullous, rapidly becoming pustular and drying into flat, ocher-colored crusts, and by the extreme superficiality of the process.

Prognosis.—Unmodified small-pox is an exceedingly fatal disease, the death-rate varying in different epidemics from 15 to 60 per cent. Vaccination has enormously reduced the mortality-rate. Age is an important factor in prognosis. Small-pox is exceedingly fatal in the very young and in those of advanced years. It is rare for an infant under one year to survive an attack of variola vera. The disease is also very fatal in children between one and five years. On the contrary, from five to fifteen years the chances of recovery are rather better than in adult life. A mild initial stage permits a prognostication of a moderate or sparse eruption. Excruciating backache should excite suspicion of the hemorrhagic form. The occurrence of the prodromal roseola is rather of good portent, often preceding, as it does, a modified eruption. In estimating the danger in small-pox there is no better guide than the amount and character of the eruption.

Treatment.—Vaccination is by far the most important measure in the prevention of small-pox. Isolation of the patient during the entire infective period, and subsequent disinfection of the sick-room and of all articles with which the patient has come into contact will do much to limit the spread of the disease. The isolation of the patient should continue until all the scabs have fallen off and the skin has become quite smooth.

There are no known remedies which have any modifying influence upon the course of the disease after symptoms have once manifested themselves. During the first few days of the incubation period the employment of vaccination will often modify to a considerable extent the course of the disease. The degree of protection exerted by vaccination is proportionate to the length of time that its development precedes the variolous outbreak. Humanized virus is more rapid and surer than the bovine lymph, and should be employed when possible under such circumstances. Glycerinated lymph, which is now used extensively, is also very reliable, and should be preferred next to the humanized virus.

After the onset of the initial stage nothing can be done to stay the progress of the disease. The treatment is then directed toward the amelioration of the symptoms. The patient should be placed in a well-ventilated room of the temperature of 68° to 70° F. A light diet and cooling drinks are most appropriate during the initial febrile stage. As the fever is usually high, febrifuge mixtures containing citrate of potassium or acetate of ammonium, with spirits of nitrous ether, tincture of aconite, and the like, may be advantageously given. Phenacetin in 2- or 3-grain (0.13–0.2) doses for an adult will often be

serviceable. Nothing is more efficacious in moderating high temperature than frequent sponging with cool water. The ice-bag and cold compresses may also be used. For the relief of the severe headache the bromids, caffein, phenacetin, or one of the other coal-tar anodynes may be employed. For convulsions in children warm baths, one of the bromids, and chloral by the mouth or rectum may be given. Insomnia or restlessness should be combated by the bromids, chloral, Dover's powder, or morphin. The latter may be given hypodermically. Many remedies have been suggested to abort the pustules and thus prevent pitting, but none of them has stood the test of experience. The exclusion of daylight from the room, or the substitution of red light by means of red window-panes or curtains has been heralded as a means of preventing the suppurative stage of the disease. In view of the abandonment of these measures many years ago such statements should be received with some reservation.

As the eruption progresses to the vesicular stage there is always considerable burning and itching of the skin. When there is much swelling and the burning pain is severe, nothing gives quite so much relief as the frequent application of compresses wrung out in cold water or the use of iced cloths. Some patients, however, prefer hot applications. For the relief of the distressing symptoms produced by the lesions in the mouth and throat mouth-washes or gargles of such drugs as potassium chlorate, boric acid, tincture of myrrh, glycerol of tannin, and the like, may be employed. Great relief is often obtained from allowing pellets of ice to dissolve in the mouth. Spraying with weak solutions of cocain is of value in severe dysphasia. An effort should be made to prevent eye complications by frequent instillations into the conjunctival sac of a saturated solution of boric acid. At the same time the eyes should be kept scrupulously clean.

To allay the intolerable itching and to correct the offensive odor from the exuding pus local antiseptic applications should be frequently employed. Among these may be mentioned solution of boric acid (1 : 20), carbolic acid (1 : 100), bichlorid of mercury (1 : 2000), or a 5 per cent. solution of Labarraque's fluid. Nothing is more convenient, and upon the whole more serviceable, than equal parts of olive oil and lime-water containing a little carbolic acid or oil of eucalyptus. A 15 or 20 per cent. aristol ointment is also highly recommended.

During the suppurative stage the chief indications are to mitigate the secondary fever and to support the vital powers. Cool sponging and the use of phenacetin and quinin in small doses are of use in fulfilling the first-named indication. When maturation of the pustules begins, the patient should receive a liberal amount of nutrients and stimulants. An adult patient suffering from a severe form of variola should take during twenty-four hours two to three quarts of milk, two or three eggs, and six to twelve ounces of whisky, preferably given as milk-punch or egg-nog. Beaf-tea, nutritious broths, and wine may be employed when milk and whisky cannot possibly be taken in sufficient quantity. Strychnin, digitalis, and carbonate of ammonium are serviceable in cases of threatened cardiac failure. Tonics are useful during convalescence.

VACCINAL ERUPTIONS.

Synonym.—Vaccination rashes.

It is beyond the scope of this volume to go into the method and details of vaccination more than briefly, and chiefly as to the cutaneous aspect of the resulting lesions, and the sometimes engendered or provoked more or less generalized eruptions. **Vaccinia**, or cow-pox, is a well-known affection among certain animals, but more especially the cow, and while never occurring spontaneously in the human subject, its artificial production in the latter by inoculation, as strenuously pointed out by Jenner, affords a protection against variola.

The operation of **vaccination** is sufficiently well known to need no comment.[1] For the first few days nothing special is observed: possibly a little congestion or irritation from the procedure. After the lapse of forty-eight hours or thereabouts a minute papule is noticed at the point or points of inoculation, which in the course of two or three days more has developed into a vesicle. Where several or more have simultaneously arisen at contiguous points of the inoculation spot these usually merge, and the subsequent course is, as a rule, the same as when there is but one inoculation point, although in some instances the resulting larger vesicle shows its compound nature. When several inoculation points are, as the result of intention or accident, at some distance apart, each develops and usually goes through the regulation course, although sometimes one undergoes full development and the others partial. The vesicle enlarges peripherally, and in from five to seven days after the operation is a somewhat distended, well-formed pea- to finger-nail-sized, translucent vesicle, frequently with a perceptible or well-marked tendency to central depression or umbilication. At this stage, in successful, and usually especially pronounced in instances of first vaccination, there is a well-defined wide encircling red or pinkish-red areola, with some inflammatory infiltration or hardness. At this time—in sixth to the eighth day—constitutional symptoms of variable degree present: slight temperature elevation, accelerated pulse, general malaise, often some gastro-intestinal uneasiness, and the axillary or neighboring lymphatic glands are somewhat enlarged and tender. The lesion is usually exquisitely sensitive, and slight or intense itchiness may, at this time, be complained of. The vesicular contents now become cloudy, and by the ninth or tenth day desiccation gradually sets in, the inflammatory areola begins to fade, and the general symptoms subside, the lesion then finally, by the thirteenth to the fifteenth day, presenting as a dime- to silver-quarter-sized yellowish or reddish-

[1] Hutchins, *Jour. Amer. Med. Assoc.*, Apr. 23, 1898, advises a simple, ingenious, painless method, especially valuable in children, in whom even the suggestion of a trifling scarification often meets with opposition. The part to be vaccinated is first cleansed, and a small piece of cotton is wet with liquor potassæ and laid on the spot for two or three minutes; it is then removed, and the soapy mixture thus formed, with the epidermis and skin secretion, wiped off, and the place gently rubbed with a piece of damp cotton; the epidermis softened by the liquor potassæ comes readily away, and an excellent bloodless absorbent spot is thus made, on which the vaccine is placed and let dry on in the usual way.

brown crust, with an encircling narrow line of redness, which latter slowly disappears; and usually in a little less than three weeks from the date of vaccination the crust has fallen off, disclosing a pinkish or reddish scar which slowly becomes whitish and shows minute pits or depressions—the sites of the primary points of inoculation. Exceptionally, generally in those cases in which healing has been accidentally delayed, a keloidal tendency has been noted, but usually of slight development.

All cases are not regular in their development and course: in some the vesicle develops early, in others it is retarded. Cases vary considerably in intensity, in some, probably from accidental complication or inoculation or individual peculiarity of the tissues, the zone of redness presents a decidedly erysipelatous aspect, and may involve a greater part of or the entire region. In fact, so severe may this erysipelatous-looking inflammation be that it may assume a phlegmonous character and some sloughing of the vaccinated spot occur, with associated lymphangitis and marked swelling of the neighboring glands. The constitutional symptoms may also be correspondingly severe. In other instances new vaccinal lesions develop in the neighborhood of the vaccinated spot, and even to some extent beyond, and while these may be simply a part of the disease vaccinia, it is much more probable that they are the result of accidental inoculation in consequence of carrying the virus from the vaccine lesion by means of the nails or fingers. General vaccinia has, however, it is stated, been observed, although the possibility of a coincident impetigo contagiosa might afford an explanation of many such instances. In some cases of vaccination, usually unsuccessful, after a partial formation of the vaccine vesicle it is ruptured, and granulation tissue of a raspberry- or strawberry-like character develops, and sometimes, if untreated, will persist for weeks without showing the slightest tendency to spontaneous disappearance.[1] In some such instances there has apparently been an accidental, but usually harmless, inoculation of an adventitious organism or material, and which probably has taken place subsequently to the vaccine inoculation. It may be that in some of these cases the tubercle bacillus is implanted upon an unfavorable soil and fails to gain proper nutritional support, and disappears on the institution of almost any astringent or antiseptic application.

Malcolm Morris, in his excellent presentation of the subject, has divided the vaccinal rashes[2] into two classes: (1) Eruptions due

[1] This peculiar strawberry-like growth is probably somewhat akin to a usually smaller but similar formation, known as **granuloma pyogenicum** (*botryomycosis* of French writers), described first by Poncet and Dor, and since by Chambon, Sabrazés, and Laubie, Brault, Faber, Hartzell (*Jour. Cutan. Dis.*, 1904, p. 520, with case illustrating histologic cut and brief review), and others. It may be briefly described as a somewhat rare, small pea- to nut-sized, usually pedicled, fungating proud-flesh-like formation, most commonly met with on the fingers or other parts of the hand. It is essentially a granulation tissue tumor, with pus cocci present, and which are probably of pathogenic influence. The French observers thought it identical with a similar-looking growth (botryomycosis) observed in bovines and other animals. It is sometimes persistent and rebellious to ordinary measures; curetting and mild cauterization of the base (Hartzell) usually prove efficacious.

[2] The reader desirous of pursuing the subject is referred to Behrend's paper (read before Dermatologic Section of International Medical Congress, London, Aug., 1881), *Arch. Derm.*, 1881, p. 383 (translated by Alexander); Morrow, *Jour. Cutan. Dis.*,

to pure vaccine inoculation, and (2) eruptions due to mixed inoculation, which Frank has slightly enlarged and modified, and which, with few immaterial changes, embody my own views and present clearly the eruptive complications: some not uncommon, others extremely rare, and some questionable. It is true that to some extent these divisions are more or less arbitrary, and there is difficulty in placing some affections as respects the exact etiologic local or general relationship, and hard-and-fast lines cannot always be drawn; but the scheme is about as satisfactory as can be made under present conditions, and gives a fairly clear presentation of the subject.

1. Due to vaccine virus.	Local.	Local erythema. Dermatitis. Local vaccinia. Adenitis.
	Systemic.	More or less generalized erythema (erythema vaccinicum, roseola vaccinica). Urticaria. Erythema multiforme. Vaccinia (generalized vaccinia). Purpura.
2. Due to mixed inoculation introduced at time of vaccination or subsequently.	Local.	Impetigo contagiosa. Furunculosis. Cellulitis. Erysipelas. Gangrene. Tuberculosis cutis.
	Systemic.	Gangrene. Pyemia. Syphilis. Leprosy. Tuberculosis.
3. Sequelæ of vaccination.		Eczema. Urticaria. Pemphigus. Psoriasis. Furunculosis.

The most frequent and usually evanescent and harmless of these are the localized or general erythema, urticaria, erythema multiforme, a regional, vaccinia-like eruption (often probably impetigo contagiosa), impetigo contagiosa, and a pseudo-erysipelatous or erysipelatous inflammation, or other accidental dermatitis. A neighboring adenitis, as already referred to, is usual to a moderate degree, but sometimes is extremely developed. Local or generalized erythema, erythema multiforme, and urticaria may present at any time between the date of vaccination and the crusting period; erythema

1883, p. 166, with references; Malcolm Morris's paper, with discussion (read before Dermatologic Section, British Medical Association, Birmingham, Eng., July, 1890), *Brit. Med. Jour.*, Nov. 29, 1890—abs. of paper in *Brit. Jour. Derm.*, 1891, p. 26; also Frank's paper, *Jour. Cutan. Dis.*, 1895, p. 142; and Dyer's, *New Orleans Med. and Surg. Jour.*, Feb., 1896; Colcott Fox, *Brit. Med. Jour.*, July 5, 1902; Towle, *Boston Med. and Surg. Jour.*, Sept. 4, 1902; Stelwagon, *Jour. Amer. Med. Assoc.*, Nov. 22, 1902; Pernet, *Lancet*, Jan. 10, 1903; Corlett, *Jour. Cutan. Dis.*, 1904, p. 495 (with illustrations and references to recent papers). See also under pemphigus and dermatitis herpetiformis.

multiforme and urticaria, especially the latter, even to a later period. Behrend called attention to the fact that there seem to be two periods for the occurrence of vaccinal eruptions—in the first three days, or not until the eighth or ninth. While true in the main, there are many exceptions. They present no special peculiarities from the ordinary types of these maladies, but are usually of shorter duration. In erythema multiforme the erythematous and erythematopapular manifestations are most common, but the vesicular and bullous lesions may also occur. The various other cutaneous complications are rare. Eczema developing from the inoculation site or elsewhere occasionally follows, but probably only in those with a clear eczematous tendency; and exceptionally the disappearance of an existing chronic eczema is promoted by the vaccinal operation (see eczema).[1] Psoriasis has in rare instances taken its start at the point of inoculation, or has made its first appearance closely following this procedure, as already referred to under that disease; in all probability vaccination has no etiologic relationship except as possibly its action as a local or general excitant or its disturbing influence upon the nervous system. Indeed, in this as in many other instances of eruption occurring during or immediately subsequent to vaccination it is more than probable that they are purely coincidental and in no way connected with or due to this operation. The layman and, flagrantly, the anti-vaccinationist, and sometimes, too, the physician, are too prone to consider all such eruptions as effects; in short, it should be clearly understood that cutaneous outbreaks occurring at such time are not necessarily vaccinal, although it is true many of them are.

Most of the pemphigoid eruptions encountered, usually following one to several weeks after the operation, have doubtless been examples of bullous impetigo contagiosa. Exceptionally, however, pemphigus or pemphigoid lesions have been observed[2] A few instances of seeming relationship have come to my notice, and of serious character; bovine virus was used. In this connection the observations and study of the etiology of acute pemphigus by Pernet and Bulloch[3] are of great interest (see pemphigus). In their report and analysis of cases, in a number the subjects were found to be butchers, and the disease to have originated from a small wound resulting from their occupation; further, in one case a pemphigoid eruption seemingly followed inoculation from a similar eruption on the teats of a cow. Others are also mentioned where the disease occurred in those having to do with animals or animal products, and instances of the existence of pemphigoid eruptions in animals are referred to. These facts have suggested the possibility that the rare cases of pemphigus, usually of grave character, exceptionally observed developing after vaccination, may thus be explained.

[1] Great care should be exercised, however, as to vaccination in moist, raw, oozing cases of eczema; as in a few instances, in young children, more or less general inoculation of such surfaces has followed. One such case was shown at the Internat. Derm. Congress in Berlin, Sept., 1904.

[2] See a recent interesting paper by Bowen, "Six Cases of Bullous Dermatitis Following Vaccination, and Resembling Dermatitis Herpetiformis," *Jour. Cutan. Dis.*, 1901, p. 401; and Howe, "Cases of Bullous Dermatitis Following Vaccination," *ibid.*, 1903, p. 254.

[3] Pernet and Bulloch, *Brit. Jour. Derm.*, 1896, pp. 157 and 205.

Irrespective of the usual transitory rashes, it has been believed, ever since the operation of vaccination has been advocated, that the process is not without danger as to the inoculation of other more serious diseases. There can be no question that pure virus of bovine origin should be employed, and that with this, as with any operative procedure, care, caution, and cleanliness are essential prerequisites to safety, and with proper observance of which the operation is an absolutely harmless and safe one. With careless operators, impure virus, and more especially uncleanly patients, the accidental inoculation of tuberculosis, leprosy, syphilis, and other affections becomes a possibility. It is doubtless true that in most of the serious sequences of vaccination that neither the operator nor virus is at fault, but that the damaging infection takes place later as a result of carelessness, negligence, or uncleanliness on the part of those vaccinated. The possibility of inoculation of tuberculosis has been questioned, but suggestive cases are on record where localized tuberculosis cutis (*q. v.*) has developed at the point of vaccination, and that much being admitted, general infection might likewise be produced.[1] As to the accidental inoculation of leprosy, there has long been a belief that such has often occurred (Beaven Rake), but authentic examples are rare. Daubler's[2] 2 cases seem to show this possibility, and doubtless other instances might be found upon investigation. Added to this is the fact that bacilli lepræ have been found in the vaccine lymph taken from a leper (Arning).[3] Examples of syphilis inoculation through vaccination are rarely observed at the present day, and then only through gross carelessness or through pure accident unconnected with the procedure itself; but that it was, while not frequent, occasionally observed formerly is attested by the observations of Hutchinson, Fournier, R. W. Taylor, and others.

Vaccinal eruptions cannot always be prevented, referring especially to those that arise through the vaccine virus itself, but such are practically harmless and short-lived, and rarely give rise to trouble. Even taking into consideration the occasional accidental mixed infections, which also with rare exceptions are not of serious import, such cases weigh as nothing compared to the benefit bestowed upon mankind by the operation. With proper care, however, on the part of the caretakers of the cattle from which the virus is derived, rigorous inspection of the animals, and extreme precaution in the collection and preservation of the vaccine, added to caution and cleanliness on

[1] A case under my own observation, of development of lupus at the site of vaccination, and immediately following the same, and which is referred to in discussing that disease, is one in point. This patient and two others were vaccinated from the same crust; the reactionary symptoms in all were severe, in two quickly followed by mixed general symptoms of what seemed, as described to me, of mixed septicemic and tuberculous character, followed by death; and in my patient, at that time a robust young female child, followed by the development of lupus, which had persisted and extended when I saw her ten or twelve years later. The history of the cases was given me by a physician, the brother of my patient, but owing to the years which had elapsed and the nature of the accident, further details could not be obtained, and there naturally remains an element of doubt about the true character of the condition which carried off the other patients.

[2] Daubler, "Ueber Lepra und deren Kontagiosität," *Monatshefte*, Feb. 1, 1889, p. 123.

[3] Arning, *Jour. Lepr. Inves. Com.*, No. 2, Feb., 1891, p. 131, quoted by Dyer (*loc. cit.*).

the part of physician and patient, before, at the time, and subsequently to the operation until complete healing has taken place, the occurrence of serious accidents would practically be placed beyond the bounds of possibility. Human virus should, of course, never be employed. Morris, among other recommendations for the prevention of vaccinal eruptions and accidents, urges that strict antiseptic and protective treatment should be carried out immediately after the vesicles have developed, and, further, that the cases should be seen by the vaccinator until the wounds have healed.

But little need be said about the treatment of the various erythematous, urticarial, and other ordinary rashes occasionally observed, as it is in these the same as in these eruptions occurring independently of the operation. The rare serious cases, too, are likewise managed on the same principles laid down elsewhere for the particular eruption presenting.

CLASS III.—HEMORRHAGES.

PURPURA.

Synonyms.—Hæmorrhœa petechialis; *Fr.*, Hémorragies cutanées; *Ger.*, Blutfleckenkrankheit.

Definition.—A hemorrhagic affection characterized by the appearance of variously sized, usually non-elevated, smooth, reddish or purplish spots or patches, not disappearing upon pressure, and generally accompanied by systemic disturbance of slight or severe nature.

Various grades of the disease are encountered, from mild and insignificant to profoundly grave, both as to the cutaneous lesions and the constitutional symptoms. It is customary, for the sake of convenience, to divide the cases into three classes or varieties, denoting respectively the mild, moderate, and severe grades: purpura simplex, purpura rheumatica, and purpura hæmorrhagica. This division is, however, to a great extent a purely arbitrary one, as merging cases are not uncommon. Insignificant cutaneous lesions are sometimes seen in association with more or less severe constitutional disturbance, and in rare instances the integumentary hemorrhage may be quite profound and the systemic involvement relatively slight. Nevertheless it is not improbable that the various grades may have a different or mixed etiology.

The lesions are variously designated, according to size, etc., petechiæ, vibices, ecchymoses, and ecchymomata. Petechiæ are the spots usually seen in the mild type, and are generally rounded or ovalish in form, and from a pin-point to a dime in size; vibices may be described as simply hemorrhagic streaks, of varying length from a small fraction of an inch to an inch or more; ecchymoses are the larger, non-elevated lesions, and may be rounded or irregularly shaped; an ecchymoma (also called hematoma) is large in size, similar to the last, but the extravasation of blood has been sufficiently great to produce slight or pronounced elevations or tumors.

Symptoms.—The essential symptom in purpura is the cutaneous hemorrhage—hemorrhage into the integumentary tissues, and which does not disappear upon pressure. The lesions thus produced are pin-head, pea- to bean-sized or larger, appear suddenly, and are noted to be of a bright-red or purplish-red color. Their brightness gradually fades, the color usually changing to a bluish, bluish-green, bluish- or greenish-yellow, dirty yellowish, yellowish-white, and finally disappearing. In the smaller lesions these changes are scarcely perceptible, the spots becoming fainter and then fading away; in the large ecchymotic lesions the various changing tints are quite pronounced, resembling in many respects the changes observed following a bruise. As a rule, the lesions are not visibly elevated, but in extreme cases in which there may be considerable effusion, slightly raised flat, tumor-like formations result. The most common sites are the lower extremities, and especially from the middle of the thighs

downward, although the upper part, and also the forearms, not infrequently share in the distribution. In other cases, and especially of the more severe type, the lesions may be seen over the trunk, and rarely upon the face as well. Exceptionally the trunk is the seat of most of the spots or patches.

As a rule, there are no subjective symptoms in uncomplicated cases, although occasionally slight soreness is complained of, and less frequently mild itching. In some instances other skin-lesions, such as those of urticaria and erythema multiforme, are associated, to be referred to later. Other accidental and general symptoms will be referred to under the particular varieties or subdivisions.

Purpura Simplex.—This, the mild grade of the disease, is rarely accompanied by any systemic disturbance, in some cases possibly slight malaise, loss of appetite, etc. It usually manifests itself quite suddenly, the spots appearing in numbers, pin-point- to pea- or bean-sized, bright or dark red in color, and most frequently limited to the lower extremities, although it is not uncommon to see lesions on the forearms as well. In other cases their appearance is gradual, coming out in distinct, crop-like exacerbations. Once its acme is reached, they begin in most cases gradually to fade, and at the end of a few weeks or longer have entirely disappeared. It is not unusual, however, for new lesions to appear either irregularly or in crops at irregular intervals for several weeks to several months; and in exceptional instances the tendency may persist for one, two, three, or more years. In a case of a young girl under my care the eruption persisted in this manner, with irregular, but usually short, periods of quiescence, for five years, and was still appearing when the patient withdrew from my observation several years ago; there were no subjective or general symptoms, and the child, aged about twelve, was apparently in good health. Such extremely prolonged cases are rare, but cases lasting in this irregular manner for a year or two are not, I believe, so uncommon as is generally thought.[1]

In rare instances the lesions may be circinate, with clear center, as in a case reported by Duhring[2] and one by myself;[3] the eruption in my case was chiefly limited to the trunk. Subjective symptoms are scarcely ever noted; in some instances, however, there is an urticarial element, and it is noted that the hemorrhagic spots, here and there, become the seat of wheals—**purpura urticans**; most of these cases are, however, examples of urticaria, with hemorrhagic tendency in the lesions. Very exceptionally there may be associated some irregularly scattered but scanty efflorescences of erythema multiforme; these are, however, rare—much more so than in cases of purpura rheumatica.

A variety (purpura senilis) of apparently an entirely different and innocent nature is observed in people of advancing years, although

[1] Meachen, *Brit. Jour. Derm.*, 1903, p. 459, showed a somewhat similar case before the Derm. Soc'y of Great Britain and Ireland, a girl of eighteen, who had been continuously subject to the malady, with varying intensity, for four years, her generel health being good; Osler, *Jour. Cutan. Dis.*, 1903, p. 297 (with colored plate), reports a case of "Chronic Purpuric Erythema," lasting eight years, with pigmentation of the skin and enlargement of the liver and spleen; patient died of pernicious malaria.

[2] Duhring, *Med. and Surg. Reporter*, Aug. 3, 1878.

[3] Stelwagon, *Jour. Cutan. Dis.*, 1887, p. 370 (with illustration).

occasionally also in younger individuals; purpuric spots appear on the legs, usually about the ankles and on the leg just above, which last a variable time, sometimes almost indefinitely, and leave behind pigment stains. New spots continue to reappear at irregular intervals. This condition seems to be of purely local nature, and is usually observed in association with sluggish circulation and often with varicose veins.

Purpura rheumatica or **arthritic purpura** presents itself in several varieties. The most common, and in fact the usual one, is that with cutaneous lesions, as in purpura simplex, with the addition of rheumatic pains and sometimes swellings about the joints. There is generally slight passing, sometimes more or less prolonged, febrile action, and the outbreak is often ushered in with the other usual symptoms of constitutional disturbance. Its behavior and course, although more severe, are practically like average cases of purpura simplex.

Another variety of the rheumatic form is that known as **peliosis rheumatica,** or **Schönlein's disease.** It is rare. In its most marked expression it may be said to be made up of a combination of symptoms—those of rheumatism, purpura, and erythema multiforme, often with here and there considerable edematous swelling. Occasional urticarial lesions are also associated, and exceptionally some of the efflorescences may become vesicular or bullous. The disease frequently begins with symptoms of sore throat. In one case observed by me there was marked edematous swelling of the legs, with both purpuric patches and ecchymoses, and pronounced rheumatic symptoms of the main joints, together with hemorrhagic lesions and swellings of the lips and throat. Such extreme examples have been well termed *febrile purpuric edema.* The constitutional symptoms are often alarming, the temperature elevated, the urine often diminished, and occasionally endocarditis and pericarditis, and in rare instances, as in 2 cases observed by Osler,[1] necrosis and sloughing of a portion of the uvula. In the single example of this severe type under my care recovery took place. Osler states, in fact, that cases usually do well, and that a fatal result is rare. Recurrence is noted, in some instances, at yearly intervals for several years—in this respect corresponding to erythema multiforme.

Somewhat similar to peliosis rheumatica is that known as **Henoch's purpura,** observed principally in children, in which, however, the erythema multiforme aspect is more pronounced, and the purpuric character, as to the integument, less conspicuous; edematous swelling is also often noted, suggestive of a combination of purpura and angioneurotic edema, as in the cases reported by Bowen[2] and others. In addition there are gastric and intestinal symptoms and hemorrhages from the mucous membranes. Osler[3] states its characters to be: (1) Relapses

[1] Osler, *Practice of Medicine*, third edit., p. 815.

[2] Bowen, "The Association of Purpura and Acute Circumscribed Edema," *Jour. Cutan. Dis.*, 1892, p. 434 (report of 2 cases and references to allied literature).

[3] Osler, *loc. cit.*, p. 816, and (interesting paper, reporting 11 cases—3 deaths) in *Amer. Jour. Med. Sci.*, Dec., 1895, p. 816; see also valuable contribution by S. Mackenzie (on the relationship of purpura rheumatica and erythema multiforme), *Brit. Jour. Derm.*, 1896, p. 116; and Weber (case report with remarks on the visceral complications of purpura), *Brit. Jour. Derm.*, 1900, p. 77.

PLATE XVIII.

Purpura.

or recurrences extending over several years; (2) cutaneous lesions, which are those of erythema multiforme rather than of simple purpura; (3) gastro-intestinal crises—pain, vomiting, and diarrhea; (4) joint pains or swelling, often trifling; (5) hemorrhages from the mucous membranes. A variable amount of albumin is usually found in the urine, while in the most aggravated cases there were all the symptoms of acute hemorrhagic nephritis. He further states that any one or two of these symptoms may be absent; the intestinal crises, with enlargement of the spleen, may be present and recur for months before the true nature of the trouble becomes manifest. In 61 cases collected, of which 11 are reported by Osler, there were 13 deaths. In these are included the large number collected by Dusch and Hoche.[1] Apparently the dermatologist rarely gets sight of these peculiar cases, which, according to this writer, are more common than generally thought.

Purpura hæmorrhagica (also known as **morbus maculosus Werlhoffii** and **land scurvy**) may begin as a simple purpura without preceding constitutional disturbance or with mild systemic symptoms, the integumental lesions being small, scanty, or numerous; and there may subsequently develop the characteristic symptoms of this type of purpura, such as more or less grave constitutional involvement, hemorrhages from the mucous membranes, and also considerable hemorrhagic effusion into the skin, producing large areas or tumor-like ecchymoses (ecchymomata). On the other hand, the disease may begin suddenly, with severe systemic disturbance, and assume its serious characters from the start. Purpuric patches are usually noted upon the mucous membrane of the mouth and throat. The cutaneous lesions in this variety may appear anywhere, beginning either on the extremities or trunk. In many cases, although the symptoms are somewhat alarming, recovery after several weeks or a few months finally results. Extreme cases are met with in which there is a combination of profound cutaneous disturbance, and hemorrhages from the mouth, stomach and intestinal symptoms, with general symptoms of collapse and a rapidly fatal ending—**purpura fulminans.**

Etiology.—The disease is not uncommon, and is met with in both sexes and at all ages, being most frequent between the ages of ten and forty. Its subjects, as regards the state of the general health, vary from those in seemingly good condition to those profoundly cachectic. No one cause can, in the state of our present knowledge, be set down as essential in all cases. Various factors seem capable of bringing on that unknown condition which results in hemorrhagic effusion. It is known that the ingestion of certain drugs (see dermatitis medicamentosa), notably potassium iodid, salicylates, and chloral, have provoked it. Malarial poison is not infrequently to be assigned as an important factor, as in cases reported by Tyrrell[2] and others.[3] Syers,[4] who has had ample opportunities

[1] Dusch and Hoche, *Festschrift Eduard Henoch*, Berlin, 1890, p. 379.

[2] Tyrrell, *Pacific Med. and Surg. Jour.*, June, 1876.

[3] Engmann, "Paludides, with the Histopathology of a Case of Malarial Purpura," *Jour. Cutan. Dis.*, 1903, p. 489 (with references).

[4] Syers, *Lancet*, Feb. 12, 1898.

of observing the disease in children, is inclined to consider it somewhat allied to scorbutus and due in many cases to poor, unhygienic life conditions and insufficient or poor food. It is likewise sometimes seen in the course of or following grave systemic disease,[1] more especially profound anemia, scorbutus, hemophilia, variola, pyemia, typhus, syphilis, grip, nephritis, etc. Rheumatism has long been discussed as etiologic, but the rheumatic symptoms in this disease are doubtless merely a part of a symptom-complex due to some unrecognized cause. It has also been observed along with gonorrheal rheumatism, in which the latter could scarcely be considered the exciting factor. Doubtless in some of the gonorrheal cases the purpuric manifestation has been the result of drug administration; copaiba has been known to produce it. Nervous disorders, both of a functional and organic character, visceral diseases, and other similar factors have all seemed to be of etiologic import in some instances, the eruption occurring in association with hysteria, myelitis, locomotor ataxia, etc. It is probable that circulatory disturbance, especially when associated with debility or cachexia, may likewise be occasionally responsible.

Micro-organisms have been also looked upon as causative, at least in the more grave cases, and have been found by Martin de Gimard,[2] Letzerich,[3] Hanot and Luzet,[4] Kolb,[5] Burch,[6] Howard,[7] and others, but there is a great deal of diversity in the findings, and in some instances, as in the case of Mossé and Iversenc,[8] several bacterial forms are to be found, which may, as they suggest, mean that the primitive infection opens the door to secondary infection. The bacillus described by Kolb, Letzerich, and Burch and some others, however, seems to be closely similar or identical. Most of these investigations have been with hemorrhagic or grave types. Martin de Gimard, Letzerich, and Kolb all succeeded, in experimental inoculations in animals from pure cultures, in producing the malady. Microbic infection is, therefore, doubtless the causative factor in some of the grave cases; and it is not impossible that the initial sore throat often noted indicates the port of entrance.

Summarizing, I agree with Johnson,[9] who, from a careful study, believes that the causative factors may be divided, in general, into

[1] Among recent cases may be mentioned that by Colcott Fox, London Clin. Soc'y, *Lancet*, June 3, 1899 (developing toward the end of Bright's disease); Poynton, *ibid.*, Oct. 28, 1899 (with pernicious acute rheumatism); Frankenhäuser, *St. Petersburger med. Wochenschr.*, 1899, No. 4, and Glendenning, *Philada. Med. Jour.*, vol. iii., p. 968, May 6, 1899 (following the grip); Londe, abs. in *Jour. mal. cutan.*, 1899, p. 770 (at the decline of typhoid fever); see also interesting and suggestive paper (with references) by Graham Little, "Cases of Purpura Ending Fatally, Associated with Hemorrhage into the Suprarenal Capsules," *Brit. Med. Jour.*, 1901, p. 445.

[2] Jules L. A. Martin de Gimard, *Du Purpura hemorrhagique primitif*, Paris, 1888.

[3] Letzerich, *Untersuchungen über die Aetilogie und die Kenntniss des Purpura hæmorrhagica*, Leipzig, 1889.

[4] Hanot and Luzet, *Arch. de méd. exper.*, ii., No. 6, 1890.

[5] Kolb. *Arbeiten aus der Kaiserlichen Gesundheitsamte*, vii., 1891, p. 60 (with references, and 4 plates, presenting 13 cuts of bacillus cultures and inoculated animal tissue sections).

[6] Burch, *Medical News*, vol. lxxiv., p. 427, 1899.

[7] Howard, *Jour. Exper. Med.*, vol. iv., 1899, No. 2.

[8] Mossé and Iversenc, *Jour. mal. cutan.*, Nov., 1898.

[9] Johnson, *N. Y. Med. Jour.*, Oct. 7, 1899.

several classes—vasomotor, toxic, and infectious; and some of those of toxic origin, probably as Breton's[1] observations lead him to conclude, arise from an autointoxication starting from the intestinal tract. There seems, too, an affinity or connection between certain cases of erythema multiforme and some cases of purpura rheumatica, and Osler is inclined to include with these angioneurotic edema and urticaria, and suggests the possibility of as yet an unknown poison, possibly the result of faulty metabolism, which, according to individual and dosage, may provoke one or the other of these several manifestations.

Pathology.—While it is customary to designate almost all cases with hemorrhagic cutaneous lesions purpura, it is, nevertheless, beyond question that this manifestation is simply a symptom of probably widely diverse conditions.[2] It is difficult to reconcile the mild, insignificant cases with those examples, apparently infectious in origin, and rapidly fatal, except upon such assumption. It is probable, too, that cases differ somewhat as to the pathology of the lesion, whether the toxic agent or the pathogenetic factor, whatever it is, acts primarily upon the nervous centers, peripheral nerves, on the blood itself, or on the vessel-walls. There may be simple transudation of blood coloring-matter, or the blood may find exit through a rupture of the vessel-wall or by diapedesis; the second method is probably the most usual. According to Hebra, in the first formation of the lesion there is slight accompanying hyperemia, which soon disappears, and Kromayer[3] states that since his attention was called to this point he has found, from careful observation, that there is a prodromal hyperemic spot, sometimes slightly elevated, which immediately precedes the hemorrhage. Excepting these two, I believe no one else refers to it or has confirmed it. Inasmuch as in most instances the lesions are on dependent parts, blood stasis is doubtless a contributing factor; thus, in a case recorded by Bruce and Galloway,[4] a man aged twenty-nine, the purpuric spots on the legs gradually vanished after rest in bed, the eruption recurring as soon as the patient was allowed to get up. Or there may be sudden obstruction of the vessel, due to thrombosis or embolism, and in some of the grave, and doubtless infectious, cases, the obstruction may consist of accumulation of micro-organisms, as Cheyne, Letzerich, Martin de Gimard, and others have found. Most investigations have been with hemorrhagic cases. Martin de Gimard[5] ascribes the disease conjointly to a mechanical obstruction of the vessels and to inflammation of the vessel-walls from the presence of colonies of micrococci, rupture occurring spontaneously or as a result of movements on the part of the patient. I have noted the

[1] Breton, *Jour. des practiciens*, 1899, No. 3.

[2] Török, "Les Purpuras," *Jour. mal. cutan.*, April, 1903, forcibly contends that all purpuras have a similar origin—some infective or toxic or autotoxic agent acting upon the vascular walls and reaching the parts affected by the blood-stream; these agents may be various, and can produce the same clinical and histopathologic picture; clinical differences are merely of degree; the differences in histopathologic findings by various investigations are assumed to be due to accidental conditions.

[3] Kromayer, *Allgemeine Dermatologie*, Berlin, 1896, p. 77.

[4] Bruce and Galloway, *Brit. Jour. Derm.*, 1898, p. 6.

[5] Martin de Gimard (*loc. cit.*), cited by D. J. M. Miller, *Medical News*, Aug. 8, 1891, who reports a fatal case—I have not been able to see the original.

effect of this latter in many cases; while the patient remains at relative or complete rest there is but little disposition to the appearance of new lesions, but if at all active, an exacerbation is immediately noted; this is probably an element also in such cases as that of Bruce and Galloway, just referred to. Letzerich, from his investigations, was led to conclude that the bacilli or their products exerted a chemical influence on the albumin of the blood, changing it into a gelatinous substance, which produces disturbance of circulation leading to extravasations. The blood changes have, however, been found to be somewhat varied by different observers and in different cases. In grave types there is usually great diminution in the red corpuscles; in 2 fatal cases recently reported by Dziehiszek[1] and by Cureton[2] this was especially noticeable; in the latter's case three days before death numbering 1,680,000 and rapidly going down to 310,000.

Anatomically (Robinson), the effusion has its seat in the corium, especially the papillæ, and sometimes in the subcutaneous tissue as well; the involved blood-vessels are usually dilated and filled with red blood-corpuscles.

Diagnosis.—But little difficulty, as a rule, need be experienced in the recognition of so well marked a symptomatology which most cases present. The lesions are not inflammatory, are purely hemorrhagic, and do not disappear under pressure. In rare instances, it is true, the border-line between purpura and erythema multiforme is closely approached, but in uncomplicated purpura there are no erythematous lesions. In fact, the disease to be differentiated is scurvy. In this latter, however, the condition is observed usually in one deprived of all vegetable food and fruits, and is generally preceded or accompanied by softening and sponginess of the gums, which bleed easily, and often loosening of the teeth; moreover, the hemorrhagic lesions are, as a rule, limited to the legs in almost all cases, and most frequently about the ankles, with often some brawny swelling of the parts and a tendency to break down into ulcerations. The lesions which are produced by flea-bites are often, after a day or two, of slight purpuric character, but their origin is usually recognized, and in the beginning they are encircled by a slight erythematous halo, and they are not, moreover, usually seen in numbers, nor do they appear in crops.

Prognosis.—While it is generally believed that various types of purpura are of diverse nature and etiology, nevertheless cases which appear as mild in character after a time become, in some instances, quite serious. The prognosis should always be expressed with a certain amount of caution, although it can be said that almost all those of mild or moderate character terminate favorably. As to the length of time for such to come to pass, however, no definite statements can be given. Most cases end in three to six or eight weeks; others, even though mild in type, may persist with remission for some months. Those presenting alarming symptoms, especially those of the type purpura hæmorrhagica, must always be considered grave,

[1] Dziehiszek, *Gazette Lekarska*, 1898, vol. xviii., p. 648—abs. in *Jour. Cutan. Dis.*, 1898, p. 502.

[2] Cureton, *Lancet*, Feb. 25, 1899.

and a fatal ending often occurs, sometimes in several days or a week. In cachectic patients the outlook is always less favorable. Hyde and Montgomery[1] state that in a case under their care a purpuric eruption was the first evidence of hemophilia, which subsequently showed itself.

Treatment.—Except in the mildest types the patient should be kept at absolute rest, and preferably in bed, in the horizontal position, or with the legs on a higher, slightly inclined plane; and in more severe cases light compression, as with the roller bandage, may also be used, as advised by Besnier. In the graver forms occasional disinfection of the throat and mouth (possible port of entrance of the disease) is advisable. Outside of the use of several special remedies, treatment depends upon the possible etiologic factor. Quinin is to be given, and in full doses, where malaria is suspected. The special remedies which have been extolled from time to time are iron, especially the tincture of the muriate, ergot, oil of turpentine, oil of Canada erigeron, aromatic sulphuric acid, and silver nitrate. Poulet[2] was especially favorable to silver nitrate, in dosage of about $\frac{1}{6}$ grain (0.0108) two or three times daily, and records recoveries from its use in what appeared to be grave cases; he believes its favorable action due to its modifying influence on the capillary circulation through an impression on the vasomotor nerves. Crocker strongly indorses oil of turpentine, both internally and by inhalation. Recently Wright[3] has advised a trial of calcium chlorid in 15- to 30-grain (1.–2.) doses three times daily, basing its possible value upon its service in urticaria and hemophilia, etc., in which lessened blood coagulability had seemed, from his investigations, to be the direct etiologic factor. The remedy should not be given, however, for more than several days, as its continued use finally diminishes the coagulability. In suspected cases, probably rare, of syphilitic etiology, the proper treatment should be instituted; in a recent case by Kornreich,[4] of moderate but persistent type, which showed no improvement under ordinary remedies, rapid recovery ensued upon the administration of potassium iodid and mercury. Frick[5] commends antirheumatic remedies, stating that such treatment had succeeded in cases rebellious to other plans, and he is inclined to believe that this is suggestive of a common or allied cause for these affections. The most valuable remedies in my experience have been quinin, iron, and ergot, the last in grave forms by subcutaneous injection. It is possible, in these alarming cases, the injection of artificial serum might be of service; Boulloche[6] had success in a case of fulminating type, in which this seemed to be the therapeutic agent in promoting rapid recovery—an injection of 120 c.c. was used. MacGowan[7] highly commends full doses of adrenalin chlorid.

[1] Hyde and Montgomery, *Diseases of the Skin*, seventh edit., p. 485.

[2] Poulet, *Bull. gén. de thérapeutique*, May 3, 1889—abs. in *Jour. Cutan. Dis.*, 1889, p. 331.

[3] Wright, "On the Treatment of the Hemorrhages and Urticarias which are associated with Deficient Blood-coagulability," *Lancet*, Jan. 18, 1896, p. 153; also papers in *Brit. Jour. Derm.*, 1896, p. 82; and (on calcium salts) *Brit. Med. Jour.*, Dec. 19, 1891.

[4] Kornreich, *Med. Record*, Feb. 26, 1898.

[5] Frick, "Purpura Rheumatica," *Kansas City Med. Index*, 1896, p. 159.

[6] Boulloche, *Bull. et mém. de la soc. méd. d. hôp. de Paris*, vol. xvi., 1899, p. 809.

[7] MacGowan, "The Use of Adrenalin Chlorid in Hemorrhages and Angioneurotic Diseases of the Skin," *Jour. Cutan. Dis.*, 1905, p. 72.

External treatment is rarely called for. Duhring, in the graver types, thinks well of ice applied frequently to the parts. If there is any itchiness, very occasionally noted, the ordinary antipruritic lotion of carbolic acid can be prescribed.

Purpura Scorbutica (Synonyms: Scurvy; Sea scurvy; Scorbutus). —In its cutaneous symptoms scurvy is closely similar to purpura, and by some writers is considered of allied nature. In the general characters and features, however, the diseases are more or less dissimilar. Scurvy is due to long-continued deprivation of proper food, especially fruits and vegetables, and its development is also favored by other bad hygienic conditions. Its subjects are usually sailors or others taking long voyages, although it is occasionally observed in those on land, and both Starr and Crozer Griffith, as well as others, have also noted it in improperly or insufficiently fed infants and young children. A peculiar constitutional state is developed, characterized by emaciation, general febrile and asthenic symptoms, sometimes with also swelling of one or more joints, and a moderately or markedly swollen, turgid and spongy and even gangrenous condition of the gums; and concomitantly, or sooner or later, by the appearance, usually upon the lower portion of the legs only, of dark colored hemorrhagic patches or blotches. Sometimes, instead of more or less diffused discoloration, it may consist of a variable number of small or moderately large spots, in close proximity or crowded together; or these will be seen in the neighborhood of or just outlying large or confluent plaques. In fact, the cutaneous lesions may, as to size and ordinary characters, be essentially similar to the petechiæ, ecchymoses, and ecchymomata of purpura, and these several grades of hemorrhagic lesion may exist at the same time; but they never have the bright-red color of the latter malady, but are usually dark sluggish red from the beginning, and generally of a dull purplish hue. While its common and often sole seat is about the ankle and the immediately adjacent part, it sometimes is also seen higher up, and occasionally on other parts as well. The skin of the affected region often becomes swollen, brawny, and slightly scaly, and not infrequently breaks down and ulcerates. The tumid gums in well-marked cases show a more or less irregular or fungoidal surface, give off an offensive secretion, and bleed readily. Indeed, in advanced cases hemorrhages from the various mucous surfaces, slight or grave, may also take place. Under unfavorable conditions, in those instances in which the same bad hygienic surroundings and the ingestion of improper food are continued, death finally results.

While scurvy can be said to be closely allied to purpura, it clinically differs somewhat from the latter, mainly by the asthenic and emaciated general condition and the peculiar puffy, spongy state of the gums, as well as by the diffused character of the cutaneous manifestation and its usual limitation to the ankle region or lower part of the legs. Moreover, unlike many cases of purpura, scurvy is, as a rule, readily remediable, and usually rapidly so, although in some instances recovery is tedious.

The **treatment** consists in giving the patient the advantage of

hygienic living, proper food, with an abundance of vegetables. Lemon- or lime-juice has always enjoyed a reputation in the management of this malady, and deservedly, as it is especially valuable, and is to be taken freely. In some cases tonics are also required, such as the ferruginous preparations, quinin, strychnin, and, in weak digestion, the ordinary stomachic bitters, such as gentian. In grave cases stimulants are sometimes needed. The tumid, spongy, and possibly ulcerated condition of the gums often demands treatment, and of great service is frequent rinsing of the mouth with water, first tepid, later moderately cool. In addition astringent and antiseptic mouth-washes are to be employed, such as a weak solution of potassium chlorate, 2 or 3 grains (0.135–0.2) to the ounce (32.), with 5 or 10 minims (0.35–0.65) of tincture of myrrh.[1] A boric acid lotion with a little tincture of myrrh is also useful. The skin condition in most cases requires but little if any treatment, but if extensive, a roller bandage to give support to the parts may be used. If brawny and scaly, a mild ointment can also be applied, and if ulcerations have resulted, they are to be treated upon general principles—cleanliness, mild antiseptic lotions, and ointments, with the roller bandage support.

[1] Coplans (*Jour. Trop. Med.*, 1904, p. 98), who from observations of the disease in South Africa, believes the disease of bacterial rather than of dietary origin, places the greatest stress upon rigorous and frequent mouth antisepsis, and believes that cases seen early can be cured by this treatment alone.

CLASS IV.—HYPERTROPHIES.

LENTIGO.

Synonyms.—Freckles; Ephelides; *Fr.*, Lentilles; Taches de rousseur; Éphélide lentiforme solaire; *Ger.*, Sommersprossen; Linsenflecken.

Definition.—Freckles are yellowish, brown, or blackish pigmentary, circumscribed, cutaneous macules, varying in size from a pin-head to that of a pea or larger, and appearing, for the most part, and often exclusively, on exposed regions, as the face and hands.

Symptoms.—This affection is, as well known, characterized by pigmentary spots, which are round or irregular in contour, and vary in size from a pin-head to a pea, and in color from yellow to yellowish-brown or black. Their most usual color is a yellowish-brown. The affection is of frequent occurrence, and not only shows, as stated, great variation in degree of development, both as to size and color, but also as to number. In some cases there may be only a few scattered macules, in others exist in greater or less profusion, and, indeed, a large area, as the face, or some parts of it, may be thickly studded with them. They are usually met with only on exposed parts, such as the face, especially on nose and cheeks, neck, and dorsal surfaces of the hands, but they may also exist on covered regions of the body, more particularly the upper part of the back. Crocker mentions a case of a young woman, in whom they first appeared, and in some profusion, on the thighs, and later on the front part of the trunk, and only finally, after several years, a few on the face. Duhring has seen several instances in which they were also to be seen on the buttocks and penis. Exceptionally, as in Robinson's case, the lesions may be in great part or wholly limited to one part of the face. While they are observed almost at any time of life, they are, however, rarely met with before the fourth year, and are most common between the ages of ten and twenty. Their appearance may be slow and insidious, or may be somewhat rapid, as quite frequently observed after continued sun exposure. In fact, they usually appear first on the approach or during the summer season, and always fade away more or less as the cool weather comes on, often completely, reappearing or becoming more numerous and darker upon the return of sunny weather. Beyond the disfigurement they cause they do not give rise to any trouble, as there are no subjective symptoms.

Lentigo occurs also as an early symptom of that rare affection of the skin known as xeroderma pigmentosum, and is, moreover, observed in atrophia cutis senilis (old age of the skin); in the latter they sometimes become, after a time, seborrheic, covered with thin greasy scale, and later may undergo slight degenerative change either directly or after first becoming somewhat warty and elevated (seborrheic wart). According to Crocker's observation, they are occasionally observed following eczema in those advanced in years.

Etiology and Pathology.—The affection is common to both

sexes and to all ages, but, as already remarked, is generally seen in its greatest development during adolescence, the disposition to its appearance becoming less marked as age advances. Those of light complexion, and especially those with red hair, are its most common subjects, and in whom it usually reaches its greatest development. On the other hand, it is also seen in brunettes, and even mulattos are not wholly exempt, although the blemish is naturally much less conspicuous in those of dark complexion. Exposure to the sun or sunlight is a potent factor, and often the only recognizable cause. This does not, however, explain the lesions upon covered parts. Heat of any source, however, and winds are also etiologic. For obvious reasons, therefore, freckles are more common in the summer, and during cold weather they fade somewhat or disappear entirely, to reappear as soon as the exciting cause again becomes operative.

Their occurrence on protected parts of the body, sometimes appearing and remaining even in cool weather, would indicate that there may be also other causes than those named, and of which we have no cognizance; such freckles are sometimes spoken of as "cold freckles." An inherited tendency is generally to be noted. Congenital freckles, occasionally reported, are more probably of the nature of pigmentary nævi, although the latter are, in reality, in their slightest development a similar formation, except, as a rule, the pigmentary disturbance involves the upper part of the corium as well.

Freckles consist of a circumscribed amount of pigment in the rete mucosum—merely, in fact, a localized increase of the normal pigment, differing from chloasma only in the size and shape of the pigmentation.

Treatment.—The management of this affection is practically the same as for chloasma, and ordinarily just about as unsatisfactory. Like the latter, in many instances freckles may be readily, though often only temporarily, removed by treatment; in others, while this effect may be accomplished, the blemishes prove somewhat rebellious, although their removal is possible in all cases. Unfortunately, however, in the vast majority of cases they soon make their reappearance. Treatment instituted on the approach of autumn is sometimes rapidly effective, and there may be no return until the following summer.

The various applications employed have in view the removal of the corneous epidermis and upper rete cells, and, with these, the contained pigmented spots. It is to be remarked, however, that all drugs which exert such action are not therapeutically efficient, for some, as mustard, cantharides, and others, will often cause a deposit of pigment. The most efficient and most generally used remedy for this purpose is mercuric chlorid, and this is the active ingredient in most patent freckle and complexion lotions. This is applied as a lotion, in the strength of from ½ to 4 grains (0.035–0.26) to the ounce (32.) of water or alcohol and water; this should be dabbed on two or three times daily, and a mild degree of furfuraceous desquamation brought about. A compound lotion, consisting of mercuric chlorid from 4 to 8 grains (0.26–0.52), 2 drams (8.) of tincture of benzoin, from 20 to 40 grains (1.33–2.65) of zinc sulphate, and

equal parts of alcohol and water to make up 4 ounces (128.), acts more satisfactorily. Hydrogen peroxid solution, full strength or weakened, will sometimes lessen the discoloration, and occasionally promote their disappearance. Lactic acid, diluted with from 6 to 20 parts of water and applied freely and often, will sometimes prove satisfactory, caution being exercised at first that too vigorous action does not result, for with some skins this drug occasionally acts with unexpected energy; or the stronger applications may be made to the spots themselves. An ointment of 1 dram (4.) each of bismuth subnitrate and white precipitate to the ounce (32.) of cold cream, lard, or petrolatum is effective in some cases. When patients can give themselves up to the treatment, a 10 to 25 per cent. salicylic acid plaster applied to the entire face, worn constantly, and replaced when it loosens, for five to ten days will usually produce active exfoliation and a disappearance of the pigment. Such a plaster is rendered still more active with the addition of 5 to 20 per cent. of resorcin. The so-called peeling paste (see acne) acts in like manner. This energetic plan, which is the one adopted at some of the "toilet parlors," usually provokes, however, a variable degree of dermatitis, sometimes mild, sometimes quite severe, which takes several days or more to subside, and for which mild soothing lotions or ointments are to be used. It should not, therefore, be employed except very cautiously in those of irritable skin.

Electrolysis may be tried when the spots are few in number, pricking the epidermis superficially, and using a mild current ($\frac{1}{2}$ to 2 milliampères), scarcely more than one or two seconds to each freckle, in order that there may be no possibility of scars.

CHLOASMA.

Synonyms.—Moth patches or spots; Liver spots; *Fr.*, Chloasme; Panne hépatique; Tache hépatique; Chaleur du foie; *Ger.*, Pigmentflecken; Leberflecken.

Definition.—Chloasma is the term applied to increased pigmentation of the skin, occurring as variously sized and shaped, yellowish, brownish, or blackish patches, or as more or less diffused discoloration.

Symptoms.—More commonly chloasma appears as ill-defined, somewhat rounded patches; less frequently as a diffuse discoloration. Its appearance is rapid or slow, although usually insidious and gradual, and unattended by any subjective symptoms, the sole symptom consisting in the deposit of more or less additional pigment, without textural change. There is, therefore, no elevation, and the surface of the skin remains smooth, although in some of the localized forms, especially on the face, there may be a slight coexisting oily seborrhea. The patches are rarely numerous, one, several, or more being present, and generally shade off gradually into the surrounding normal skin; sometimes coalescing and forming one or more large irregular and ill-defined areas. The face is the usual site for the common or patchy variety, although it may also be found occasionally on the trunk and other parts, but is then, as a rule, the

result of some external agency. The diffused discoloration may occupy a portion of the body, or more or less of the entire surface. In these latter instances the discoloration is always deeper in those parts which are normally darker, such as about the eyes, neck, axillæ, genitocrural region, and about the nipple. The color is yellowish or brownish, and may even be blackish; when the last, the malady is more commonly designated by the practically synonymous term, **melasma** or **melanoderma.** Depending upon the etiologic factors, whether external or internal, chloasma cases are usually grouped in two classes—idiopathic and symptomatic.

Idiopathic chloasma (chloasma idiopathicum) includes all those cases in which the pigmentary increase is due to local or external agents, such as the sun's rays, sinapisms, blisters, continued cutaneous hyperemia, or irritation due to pressure, friction, scratching, parasites, and like causes. The increased discoloration following continued exposure to the sun or diffused bright light is the result of the action of the chemical rays, and may also occur in prolonged exposure to strong electric light, although to a relatively slight extent. The heat itself has also an influence, although a minor action when compared to chemical rays; it will, however, when long continued and repeated, bring about some increase of depth in the skin tint, as observed in those whose occupation demands close proximity to the fire, as stokers, etc. The chloasma thus variously produced is sometimes also designated **chloasma caloricum.** The first stage, usually, of such is slight erythema or hyperemia. In this connection the pigmentation resulting from repeated exposure to the X-ray may also be mentioned, following after erythema, which it often produces; the discoloration is usually slight, and doubtless the effect of both the light and the current, although in what manner the latter is causative, if it is so, is not known. The discoloration resulting from the application of sinapisms and blisters, and from certain drugs, known also under the name of **chloasma toxicum**, is an occasional occurrence, and sometimes it is quite persistent, as in an instance which came under my own observation in a young, fashionable woman who had had a mustard plaster applied over the sternal region, deep pigmentation developing as the redness subsided, and lasting for months as a sharply defined area, the exact shape and size of the plaster, making the wearing of décolletté gowns impossible. It remains at the site of the application, although Dubreuilh[1] reports a case in which, apparently as a result of a mild spreading dermatitis produced, it extended considerably beyond.

The increased discoloration due to pressure and friction, as well as other traumatic agents (chloasma traumaticum), is exemplified in those regions against which a truss is in constant contact. To the same cause is doubtless to be attributed the slight darkening of the skin of the neck region noticeable in some individuals. Of especial dermatologic interest is the pigmentation resulting from prolonged hyperemia and irritation, as that observed in consequence of the scratching induced by chronic irritation of the skin, particularly in long-continued pruritus, dermatitis herpetiformis, and pediculosis cor-

[1] Dubreuilh, *Annales*, 1891, p. 76.

poris, as well as other lasting, itchy, cutaneous diseases constituting the pityriasis nigra of Willan. Syphilitic eruptions may, as is well known, also leave some pigmentary stain.

In pediculosis it becomes, after long continuance of this malady, often extremely pronounced—so much so that, exceptionally, there is a strong suggestion of Addison's disease; one such instance came under my notice at the Philadelphia (Charity) Hospital, the patient having been sent by the admitting physician to the medical ward under the belief that it was the latter affection. Similar extreme examples have been reported by Greenhow.[1] In pediculosis the pigmentation is most marked, as is to be expected, on those situations where the irritation is greatest, as across the shoulders and upper part of the back, around the waist, over the sacrum, etc. (see pediculosis). It is, in moderately marked cases, somewhat spotty, with also some small, somewhat whitened, atrophic or scar-like spots intermingled, the latter the sites where the skin has been deeply gouged out by the nails in scratching. Other parasites in addition to lice and the itch-mites can also bring about pigmentation or pseudo-pigmentary changes, as in a few rare instances from the demodex folliculorum (*q. v.*) and from the microsporon furfur (see tinea versicolor), microsporon minutissimum (see erythrasma), which will be referred to in the proper place.

Symptomatic chloasma (chloasma symptomaticum) is the more important variety, and includes all forms of pigment deposit which occur as a consequence of various organic and systemic diseases, as the pigmentation, for example, observed in association with tuberculosis, secondary syphilis, sarcoma, cancer, malaria, Addison's disease, Graves's disease, and functional and organic affections of the utero-ovarian system. With the exception of the pigmentation observed in the last named, the most common cause of symptomatic chloasma, it is usually more or less diffused. The hyperpigmentation bordering the white depigmented patches in vitiligo and that of the pigmentary syphiloderm are considered under these diseases, and need not, therefore, be discussed here. Moreover, the discoloration of these various cachectic maladies (chloasma cachecticorum) named is too well known to need special description, although to the practised eye there is often considerable difference in depth and shading in the several affections. In tuberculosis, in its greatest development, it is somewhat on the tint of the color in Addison's disease, although much less pronounced, and sometimes extremely slight.[2] The peculiar sallow or earthy color of the early stages of secondary syphilis, most marked on, and sometimes practically limited to, the face, is often sufficiently distinct to be of some corroborative value in otherwise doubtful cases. A somewhat similar tint is frequently seen in sarcoma and also in cancer, but usually with a trifling lemon-yellow coloring. In malaria there is generally a sallow color, with a brownish tint, while in mor-

[1] Greenhow, "Vagabond's Discoloration Simulating the Bronzed Skin of Addison's Disease," *Trans. London Clin. Soc'y*, vol. ix., 1876, p. 44.

[2] W. G. Smith, *Brit. Jour. Derm.*, 1892, p. 386, describes an extreme case; also Andrewes, "Two Cases of Tuberculosis with Unusual Pigmentation of the Skin and Deposit in the Suprarenals," *St. Barthol. Hosp. Rep.*, vol. xxvii., 1891, p. 109 (with remarks).

bus Addisoni it is of a somewhat slaty, bronzed hue. In Graves's disease there is also sometimes observed a brownish-yellow pigmentation, either in freckle-like spots, patchy, or, in rarer instances, as a more or less diffused discoloration, of which examples are cited by Drummond,[1] Mackenzie,[2] Nicol,[3] and others.

Chloasma Uterinum.—The most important form, however, in the symptomatic class is that due to disturbances, either functional or organic in character, of the utero-ovarian system, known under the name of chloasma uterinum. It appears upon the face and is usually limited to this part, the forehead being the favorite site, although occasionally this whole region shares in the discoloration, forming

FIG. 108.—Chloasma in a light mulatto woman aged thirty, of several months' duration; a rather sharply defined area on the central portion of the forehead, some under the eyes, small patches on cheeks, and a long patch on upper lip. There was utero-ovarian disturbance, with irregular menstruation.

almost a "mask." In some instances patches appear also on the breast, abdomen, and other parts. It presents sometimes as fairly well-defined patches of yellowish-brown pigmentation, but much more commonly the plaques or areas are ill defined, and the dividing-line between the normal and pigmented skin is difficult of recognition. The pigmentation is more intense in brunettes. The skin is smooth;

[1] Drummond, "Clinical Lecture on Some of the Symptoms of Graves's Disease," *Brit. Med. Jour.*, 1887, i., p. 1027.

[2] Hector Mackenzie, "Clinical Lecture on Graves's Disease," *Lancet*, 1890, vol. ii., pp. 545 and 601 (many interesting cases with pigmentation; numerous references).

[3] Nicol, *Brit. Jour. Derm.*, 1900, p. 56 (more or less general); see also Dore's paper, "Cutaneous Affection Occurring in the Course of Graves's Disease," *ibid.*, p. 353.

occasionally a mild degree of seborrhea coexists, in which event the surface may be either oily or furfuraceously scaly, usually the former, depending, however, upon the variety of seborrhea. It is seen in those between the ages of twenty-five and fifty; rarely in those younger, and seldom after the climacteric. It is most commonly observed during pregnancy (*chloasma gravidarum*), but may also occur in connection with any functional or organic disease of the utero-ovarian apparatus. There is during the pregnant state, as is known, a physiologic tendency to a pronounced increase of pigmentation, but more especially in certain situations, as along the linea alba and about the nipples. Kaposi[1] reports a curious case of a woman in whom increased pigmentation of a large mole on her neck was the earliest sign—in the first month—of pregnancy. In some instances this pigmentary tendency is not only seen in the face, especially the forehead, but also the neck, and occasionally it is extensive or almost universal, as in the cases referred to by McLane,[2] Wilson,[3] Murphy,[4] Crocker,[5] Swayne,[6] and others. It more usually appears in the early or middle period, and may deepen in shade as pregnancy becomes advanced, disappearing, as a rule, after confinement. In McLane's case it appeared during the eighth month; in Swayne's, at the beginning of the last three months, and in this instance had so occurred in three successive pregnancies. In Crocker's patient the color increased with each pregnancy. As already remarked, however, various other conditions may also occasion it, such as ovarian irritation, dysmenorrhea, etc.[7]

Etiology and Pathology.—The causes which have in the main already been necessarily mentioned in speaking of the varieties are, it is seen, numerous and of different nature. Most cases coming under observation are those with patches on the face, and having some disturbance of the utero-ovarian apparatus as the etiologic factor. In addition to this and the other causes named may also be mentioned anemia and chlorosis, chronic indigestion, neurasthenia, nervous shocks, and similar agencies. Sex has a very decided influence. The malady is rare in the male; occasionally, however, pigmentation of the face is observed, and sometimes discoloration, more or less patchy, is seen about the crural and perineal region. As already stated, persistent hyperemia, as in chronic eczema of the legs,

[1] Kaposi, *Trans. Berlin. Internat. Cong.*, 1890, vol. iv., Abth. xiii., p. 98. The papers by Caspary, Kaposi, Ehrmann, and Jarisch on the subject, "Die Pathogenese der Pigmentirungen und Entfärbungen der Haut," contained therein, give a clear presentation of the subject.

[2] McLane, "Extraordinary Pigmentation of the Skin in Pregnancy," *Amer. Jour. Obstet.*, 1878, vol. xi., p. 792 (chiefly on neck, back, and thighs, patient profoundly anemic).

[3] Wilson, *Lectures on Dermatology*, London, 1878, p. 24 (more or less general).

[4] Murphy, "Chloasma Uterinum," *Obstetrical Gazette*, vol. ii., 1879–80, p. 294 (general).

[5] Crocker, *Diseases of the Skin*, second edit., p. 439 (chiefly face and neck).

[6] Swayne, quoted by Tilbury Fox, *Diseases of the Skin*, second Amer. edit., p. 402, and also by Crocker, *loc. cit.* (face, arms, hand, and legs—spotty).

[7] See valuable paper by Champneys, "Pigmentation of the Face and Other Parts, Especially in Women," *St. Barth. Hosp. Rep.*, vol. xv., 1879, p. 233 (with review of the subject and report of 8 cases).

especially when associated with varicose veins, will often leave more or less permanent pigmentation. Discoloration is also, as known, observed as a result or part of some other maladies, as lichen planus, pigmented sarcoma, xeroderma pigmentosum, lepra, scleroderma, urticaria pigmentosa, etc. The staining of jaundice and the yellowish color from the ingestion of picric acid, as well as the discoloration produced by the external use of certain drugs, such as chrysarobin, need not be specially referred to, the causative factors being usually self-evident. The chloasma following prolonged administration of arsenic is referred to elsewhere (see dermatitis medicamentosa). Argyria, tattooing, and gun-powder stains are discussed later on.

The pathologic process of chloasma is, for the most part, merely an accentuation or increase in the physiologic pigment function.[1] It is apparently under the control of the nervous system. Some observations, as in Andrewes's cases,[2] suggest investigation as to the possibility of disease of the suprarenal glands being occasionally of influence. Gueneau de Mussy[3] believed that any irritation or lesion of the nerves, or affiliated nerves, which supplied the suprarenal capsules, from whatever part of the abdomen, will have an influence on increase of pigmentation. Anatomically the sole change consists of an increased deposit of pigment having its seat wholly or principally in the mucous layer of the epidermis. The malady, in fact, is pathologically similar to freckles, except in the latter there is an extremely circumscribed deposit, while in chloasma it is patchy or diffused. In some instances pigment is also found more deeply, as Demiéville[4] and others since have observed. In some instances, as in those following chronic diseases of the skin, the pigmentation is due, in great part at least, to the coloring-matter of the extravasated blood. In discolorations due to stains, as in jaundice, for instance, the color extends deeply.

Diagnosis.—The general pigmentary cases give no difficulty, nor does, ordinarily, chloasma uterinum, the discolorations of which are usually confined to the face. The diseases with which the latter is most likely to be confounded are tinea versicolor, vitiligo, and chromidrosis. In tinea versicolor the discoloration is rarely seen on the face, and then in connection with extensive eruption on the trunk, and, moreover, even then it only exceptionally gets higher than the lower edge of the chin. The distribution and the extent are, therefore, usually alone sufficient for the differentiation; but in addition to

[1] See "pigment" of the skin and the extremely valuable contributions by Ehrmann, "Untersuchungen über die Physiologie und Pathologie des Hautpigmentes," *Archiv*, 1885, p. 507, and 1886, p. 57 (a classic paper, with references and 11 colored histologic cuts), and also his still more elaborate paper, "Das Melanotische Pigment," etc., *Bibliotheca Medica*, Abth. D. ii., H. vi., 1896, with 12 colored plates containing many cuts (Fisher and Co., Cassel); also "Das Pigment der Haut," by Unna, *Monatshefte*, 1889, vol. viii., p. 366 (with review and references); also Piersol's paper, "Development of Pigment within the Epidermis," *University Magazine*, 1890, p. 571 (with cuts and references).

[2] Andrewes, *loc. cit.*

[3] Gueneau de Mussy, *Revue Méd.*, Feb., 1879, quoted by Murphy, *loc. cit.*

[4] Demiéville, "Ueber Pigmentflecke der Haut," *Virchow's Archiv*, vol. lxxxi., 1880, p. 333 (based chiefly upon a study of lentigo, with 3 histologic cuts and references).

this the patches of chloasma are smooth, the skin otherwise unchanged, whereas in tinea versicolor there is more or less furfuraceous scaliness, and the surface can readily be scraped off with the finger-nail, and with it the discoloration, as the latter is due to the causative fungus, which is rarely seated more deeply than the superficial horny layer. The microscope could, of course, be resorted to if necessary, but such a contingency could rarely happen. Vitiligo, as is known, consists of depigmented or whitened spots or patches with surrounding increased pigmentation, totally different from chloasma, and this can readily be recognized unless hastily and carelessly examined; but the possibility of mistake is in the fact that the white areas may be considered the normal color, in which event the surrounding pigmentation would be misinterpreted. The patch of chloasma always has, however, somewhat rounded, convex borders, whereas in the pigmentation of vitiligo inclosing a more or less rounded area of white skin the border, of one side at least, would be just reversed—concave.

In chromidrosis (*q. v.*) the discoloration is in the exuded secretion, and it can be washed or rubbed off, although sometimes with considerable difficulty, but usually readily with ether or chloroform; the moist or oily condition of the surface, moreover, is unusual in chloasma, and when rubbed, the exudation taken up by the rubbing finger shows the discoloration also. In view of the observations of DeAmicis, Majocchi, and Dubreuilh, indicating that exceptionally pigmentation results from the presence of a profusion of the parasite, demodex folliculorum (*q. v.*), this factor should not be lost sight of, especially in those instances seemingly obscure etiologically. Nor is the possibility in obscure cases of the discoloration being due to some drug or other stain medicinally or intentionally employed to be forgotten, which, if such suspicion is aroused, can, as a rule, readily be determined. It is to be remembered, also, that the continued administration of arsenic sometimes produces a more or less general pigmentation.

Prognosis.—Chloasma uterinum is usually persistent and rebellious, generally disappearing as the cause—pregnancy or other disturbance of the generative organs—subsides. In persistent cases, in which no evident factor seems present, ovarian irritation or some disease of the uterus is to be suspected, and such possibility substantiated or disproved by gynecologic examination. Cases depending upon anemia, chlorosis, and similar removable agencies are usually of favorable outcome. It is true, without disappearance of the underlying cause, the discoloration can generally be removed by local applications, but the effect is, as a rule, only temporary. The remediability of the more or less generalized pigmentation of tuberculosis, cancer, etc., is dependent upon the prognosis of the disease in question. The pigmentation consequent upon irritation and inflammatory diseases usually subsides sooner or later after discontinuance of the cause, but in some cases some months or a year or more may elapse before it has entirely disappeared; that from chronic eczema of the leg, if in people of advanced years, is usually permanent, though it

becomes somewhat less marked. That following syphilitic eruptions is rarely persistent.

Treatment.—Chloasma requires for its removal a careful study of the exciting and predisposing causes. The digestion, the tone of the general health, and the utero-ovarian organs should receive attention as possible factors. If anemia or chlorosis is present, the proper measures should be accordingly instituted. In fact, the constitutional treatment is to be prescribed upon general principles, as there are no specific remedies. As in some instances it is difficult or impossible to discover any faulty condition of the general system, in such reliance must be placed upon local treatment; and, in fact, this latter is to be employed in all cases, although, unless a removal of the exciting or predisposing cause is possible or has ceased to persist, the relief furnished is commonly but temporary.

The cases applying for treatment are usually those in which the face is the site of the blemish,—other cases being relatively rare,—and for the most part these are examples of chloasma uterinum. The external treatment has in view a two-fold action—a removal of the epidermic corneous layer and upper rete cells, and with these the pigmentation contained therein, and a stimulation of the absorbents. Occasionally the action must also take in the lower rete cells. The external treatment is, in fact, similar to that employed in the removal of freckles, to which the reader is referred for the method of application of the remedies—corrosive sublimate, lactic acid, hydrogen peroxid, the ointment of bismuth subnitrate and white precipitate, and the peeling pastes .As a rule, however, in chloasma the stronger applications are necessary, and sometimes actual blistering is required. It should be noted, moreover, that certain remedies which produce active exfoliation or blistering, instead of removing the pigment, may tend to increase it, such as, for instance, mustard and cantharides, and these are to be avoided. The application selected should be employed in the weaker strength at first, in order to test the sensitiveness of the skin; it is to be made several times daily when possible, and as soon as branny exfoliation begins to show itself or active irritation supervenes, it should be discontinued until such symptoms have subsided. When the temporary disfigurement is not objected to, treatment can be more energetic, pushing it to the point of more decided exfoliation, after which a mild soothing salve, such as cold cream, can be applied for a day or two until the surface is smooth again, and then, if pigment still remains, as it commonly does, although usually less marked, active treatment is resumed, and so on until it is entirely removed; or if the selected remedy is unsuccessful, then changing to another. Hydrogen peroxid acts more through its bleaching property, and occasionally satisfactorily without pushing it in greater strength to the point of producing a mild exfoliative dermatitis.

My own experience would indicate that the most valuable applications are, in the order named, corrosive sublimate solution, lactic acid, salicylic acid, the peeling pastes, and hydrogen peroxid.

Argyria is the term applied to the discoloration which follows the prolonged administration of silver nitrate, a rare occurrence at the present day, but not infrequent at the period when this drug was the chief remedy in the treatment of epilepsy. It has also been stated to follow the repeated applications to the throat, and Crocker (*loc. cit.*) "met with a case in which the blueness did not develop for many years after the topical application had ceased to be made." This scarcely accords with Krahmer's statement (quoted by Crocker), that 450 grains is the smallest quantity which has produced it. It is not improbable, however, that a much smaller quantity may produce it, as in an instance observed by Neumann[1] in the case of a physician, who for gastric ulcer was in the habit of injecting into his stomach daily, through an esophageal tube, two or three syringefuls of a solution containing 24 grains (1.5) of silver nitrate to 3 ounces (96.) of water, and in whom, after the twelfth injection, according to the patient's statement, the discoloration began to appear. In the instance reported by Riemer,[2] the first sign appeared after about 280 grains had been taken. According to Branson, confirmed by Pepper,[3] the earliest indication of the development of the discoloration is the occurrence of a dark-blue line on the edges of the gums, very similar to that produced by lead, but somewhat darker. The color of the skin resulting, as well known, is of a bluish-gray or slate color, and when once established, is permanent. It is general over the surface and also on the adjoining mucous membranes, but is most pronounced on those parts exposed to the light, as the face and hands. The hair and nails also share in the discoloration, the hair having a faint reddish tinge. According to the investigations of Riemer and Neumann,[4] the pigment is found in the form of reduced silver, and in all parts of the skin except the rete cells and the glandular epithelium, and also in the subcutaneous connective tissue. The greatest deposition is just below the rete, in the uppermost papillary layers of the corium, where it appears as a sharply defined blackish border, and it is also abundant in the membranæ propriæ of the sweat-glands. A deposit is likewise found in the internal organs, with the exception (quoting Lesser)[5] of the central nervous system.

When the discoloration is once established, it is permanent, although Neumann[6] records an instance in which there occurred some lessening of the intensity in the course of several years; and Yandell[7] reported 2 such patients (epileptics) who contracted syphilis, for which the administration of potassium iodid was conjoined with mercurial vapor-baths, and during which treatment there was gradual disappearance of the discoloration—in one completely, in the other

[1] Neumann, "Ueber Argyria," *Medicinische Jahrbücher*, 1877, p. 369 (with résumé, several histologic cuts, and references).

[2] Riemer, *Archiv der Heilkunde*, 1875, pp. 296 and 385.

[3] Branson, Pepper, cited in *United States Dispensatory*.

[4] Neumann, *Lehrbuch der Hautkrankheiten*.

[5] Lesser, *Ziemssen's Handbook of Skin Diseases*, p. 455.

[6] Neumann, *Medicinische Jahrbücher*, 1877, p. 382, also cited by Lesser, *Ziemssen's Handbook of Skin Diseases*, p. 455.

[7] Yandell, *Amer. Practitioner*, 1872, vol. v., p. 329.

practically so. Others, however, who have since tried this plan have not been so fortunate.

Tattoo-marks.—Tattooing, or the mechanical introduction of pigments into the skin, is a well-known process. The coloring-matter used consists of carbon, cinnabar, carmin, and indigo, and when once thoroughly imbedded, is permanent. The chief interest dermatologically lies in the attempts at successful removal, an end exceedingly difficult, and without excision or destructive action almost, if not wholly, impossible of attainment. Various methods have been extolled from time to time, having usually as a basis the production of a reactive destructive inflammation which results in crusting, the crust dropping off, and in successful instances the pigment cast off with it, leaving a superficial or pronounced scar, according to the particular plan employed. The French methods, which seem to have the most support, excepting excision or cauterization, are the plans advocated by Brault[1] and by Variot,[2] with neither of which I have had any personal experience. Brault's method consists, after thorough cleansing of the surface, of tattooing in of a solution of 30 parts of zinc chlorid in 40 parts of water; mild inflammatory reaction ensues, but usually slight, a crust forms, and after some days falls off, leaving a scar; a repetition is sometimes necessary. Variot's plan is first to put on the mark a concentrated solution of tannin, which is then tattooed in, making punctures close together: he then rubs the silver nitrate stick firmly over the surface, allows it to remain for several minutes, and then wipes it off. There is a slight inflammatory reaction, occasionally trifling suppuration; the part blackens, a superficial crust or eschar forms, which in one or two weeks drops off, leaving an insignificant scar which becomes scarcely noticeable.

In recent years Ohmann-Dumesnil,[3] Nelson,[4] and Skillern[5] have reported success in their removal by tattooing in, after first rendering the surface aseptic, of glycerol of papoid spread upon the surface, using a bunch of needles, and driving in firmly, but not to be driven so deeply as to draw more than the least quantity of blood; the part is gone over several times, and then covered with two or three layers of gauze, previously soaked in the solvent, and over this, adhesive plaster; this is removed after a few days; a slight crust forms, and when this falls off, "all traces of the tattoo-mark will usually be gone." If any should still remain, the process is to be repeated, which "for the best result is generally necessary." Others,[6] including myself, have not, however, been successful with this method. It is possible that the explanation of this may be that it is successful only in those in which certain pigments had been employed. Later greater suc-

[1] Brault, *Annales*, 1895, p. 33.
[2] Variot, *Compt.-Rend. Soc. de Biol.*, 1888, p. 636.
[3] Ohmann-Dumesnil, *New York Med. Jour.*, 1893, vol. lvii., p. 544, and *St. Louis Med. and Surg. Jour.* (tattoo-marks and powder-stains), vol. lxxviii., 1900, p. 65.
[4] Nelson, *New York Med. Jour.*, 1894, vol. lix., p. 272 (chiefly as to powder-stains).
[5] Skillern, *Philada. Med. Jour.*, vol. i., 1898, p. 1166.
[6] Cantrell and Stout, Bangs and Hardaway's *Amer. Text-book*, p. 949.

cess has been claimed in the use of caroid, instead of papoid, as the solvent.[1]

The methods which I have chiefly employed are those of electrolysis, the cutaneous trephine, and excision. Electrolysis is successful only with small spots. The needle is introduced, as a rule, from the edge, slantingly toward the center—as if to undermine it; the whole border is thus gone around, the punctures being about one-eighth inch apart. The strength of current varies from 1 to 4 or 5 milliampères, and with each introduction allowed to act from one-half to one minute or a trifle longer. It is in reality a destructive method, reaction taking place, a thin eschar or crust forming, and finally cast off, leaving a superficial scar. If any remains, that part

FIG. 109.—Cutaneous punch or trephine.

is to be gone over again. The cutaneous trephine or punch can be used in two ways: if the spot is very small, it can be "punched," and the projecting disc cut off, and a slightly larger disc of healthy skin made by a larger trephine transplanted; if the area is greater, then a small or moderate sized punch can be used on several parts of its surface, the discs cut off, and the denuded places dressed with an antiseptic powder, such as 1 part of acetanilid and 7 parts of boric acid. After these have healed, new places can be treated in the same manner until it is entirely removed. With care and trouble transplantation could also be practised in such larger areas. When the mark is on soft yielding parts, excision is a good plan, the skin at the edges being dissected under and drawn together. In the light of the favorable reports on the methods of Brault and Variot I should feel disposed to try them, especially in cases objecting to the use of the trephine. Hansen,[2] who has tried most of the various plans in use, considers these two as the surest and as leaving the smoothest scars.

Powder-stains are practically similar to tattoo-marks. If the case comes under observation shortly after the accident, many of the marks can be picked out. Later this same plan may prove of service, but much better is the method of removal by a cutaneous trephine of extremely small caliber, as originally suggested by Watson[3] and subsequently brought into more general use through the paper by Keyes.[4] The punch is placed over the powder speck and given a slight rotary motion, pressing firmly, but not going down to

[1] Ohmann-Dumesnil, "The Removal of Tattoo-marks and Powder-stains," *St. Louis Med. and Surg. Jour.*, vol. lxxviii., Oct. 1900.

[2] Hansen, *Hospitalstidende*, vol. xl., No. 45, 1897; brief abs. in *Archiv*, 1899, vol. xlix., p. 430.

[3] Watson, "Discotome," *Med. Record*, vol. xiv., 1878, p. 78; and "Gunpowder Disfigurements," *St. Louis Med. and Surg. Jour.*, vol. xxxv., 1876, p. 145.

[4] Keyes, "The Cutaneous Punch," *Jour. Cutan. Dis.*, 1887, p. 99; Busch, *Berlin. klin. Wochenschr.*, xxi., 1884, p. 306, originally suggested similar, but larger, trephine for the removal of small growths.

unnecessary depth; the little disc of skin tends to jut out, can be snipped off, and the minute cavity filled with powdered subsulphate of iron or with a paste of tincture of benzoin and boric acid, or with the compound powder of boric acid and acetanilid mentioned under tattoo-marks. With care and skill, not cutting too deeply, the little scars left become practically unnoticeable. More recently the application of hydrogen dioxid has received favorable comment, Crile,[1] Rhoads,[2] and Clark[3] reporting satisfactory and rapid results. It is applied in full strength, freely and often, and if not irritating, it can be kept constantly applied on lint, wetting this from time to time. Crile used a "concentrated solution," which was applied until a white zone had appeared around and under the grains, and until bubbling, which was also produced, had fairly ceased, after which they may be readily removed with a pointed instrument. Clark used a solution of 1 part glycerin and 3 parts hydrogen dioxid, and applied freely, on lint if not irritating, and the stains disappeared. In addition to these several methods the tattooing in of the glycerol of papoid or caroid has also been commended, employed as in tattoo-marks.

NAEVUS PIGMENTOSUS.

Synonyms.—Pigmentary mole; Mole; Mother's mark; *Fr.*, Nævus pigmentaire; Tache pigmentaire; *Ger.*, Pigmentnævus; Fleckenmal; Pigmentmal; Linsenmal.

Definition.—Nævus pigmentosus, or mole, may be defined as a circumscribed increase in the pigment of the skin, usually associated with hypertrophy of one or all the cutaneous structures, especially of the connective tissue and hair.

Symptoms.—Moles are of various kinds and degrees,[4] and according to the predominance of one or other feature are divided into the several varieties, nævus spilus, nævus pilosus, nævus verrucosus, and nævus lipomatodes.

Nævus spilus is the simple pigmented smooth spot, consisting of a pea- to bean-sized or much larger area, usually deeply colored from a light brown to a black, and scarcely, if at all, elevated. Sometimes, however, there is slight connective-tissue increase with this, and when so, the patch is slightly raised above the surrounding surface. One, several, or more may be present. The face, neck, and back are favorite situations. **Nævus pilosus** is the hairy mole, which, in addition to the features of the common smooth nævus, just described, presents an abnormal growth of hair, slight or excessive, light in color or deeply pigmented, and usually coarse and of considerable length. There is often added a somewhat irregular surface and a variable connective-tissue hypertrophy. They may be single or multiple, and may occur upon any part of the body, and while ordinarily not larger than a bean, may be of much greater area, and in extreme instances cover a portion of or a complete region.

[1] Crile, *Cleveland Med. Gazette*, vol. xii., 1896–97, p. 183.
[2] J. N. Rhoads, "Powder-Stains," *American Medicine*, vol. i., 1901, p. 16.
[3] Clark, *ibid.*, June 1, 1901, p. 384.
[4] The different forms are discussed in full, with bibliography, by Möller, *Archiv*, 1902, vol. lxii., pp. 55 and 371, and Riecke, *ibid.*, 1903, vol. lxv., p. 65.

Nævus verrucosus, as the name signifies, is the mammillated or warty pigmented nævus, with a rough, sometimes hard, sometimes soft, irregular surface, and usually with variable, but often considerable, increase of all the skin tissues, and with, often, marked hypertrophy of the papillæ, this last feature giving rise to the furrowed and uneven surface. There may be but slight development in the hair of the part, but, as a rule, there is considerable growth. The **nævus lipomatodes** is the type in which there is an excessive fat and connective-tissue hypertrophy,[1] producing sometimes formations of considerable dimensions and elevation, being soft and loose in texture, or somewhat verrucous and hard, with or without hair hypertrophy. The surface is either smooth or irregular and warty, and sometimes the growth shows loosely or closely packed folds and deep furrows, occasionally having a mollusciform aspect. As already stated, the more common or ordinary moles are found most frequently upon the face, neck, and upper part of the trunk, although they may occur upon any part of the surface. The extensive hairy, verrucous, and lipomatous moles sometimes cover a considerable area, in extreme cases a great part of the trunk, and especially the lower trunk and the ischiofemoral regions are partially or completely enveloped.[2]

FIG. 110.—Nævus pigmentosus, congenital and of extensive distribution; except the large irregular and clefted area on the back, they are nearly all small, smooth, and flat; here and there, especially on those of the right shoulder and buttock, a growth of hair. A slight secretion from the clefts of the large growth and of an offensive odor. This growth has spread slightly during past few years, with the suggestion of possible malignant change. Patient a Swede, aged twenty one (courtesy of Dr. Burnside Foster).

While there is in most cases no special distribution or configuration, in exceptional instances of apparently the same disease the lesions are arranged in narrow bands, sometimes zosteriform, as in

[1] Jackson reports a good case, with illustration, in *Jour. Cutan. Dis.*, 1895, p. 66.

[2] Remarkable cases, with illustrations, have been recorded in recent years by Michelson, *Ziemssen's Handbook of Skin Diseases*, p. 405; Hyde, *Jour. Cutan. Dis.*, 1885, p. 193 (with references to other cases); Joseph, *Lehrbuch der Hautkrankheiten*, third edit., p. 181; Lesser (Baerensprung's case), *Lehrbuch der Hautkrankheiten*, tenth edit., pp. 234 and 235; Burnside Foster, *Jour. Cutan. Dis.*, 1899, p. 132 (concerning the case herein illustrated).

DeAmicis's and Hyde's cases. These cases, usually limited to one side of the body, have a peculiar form which has been described under the various names of **linear nævus**, nævus unius lateralis,

FIG. 111.—Linear nævus.

nævus nervosus, nævus lichenoïde, ichthyosis linearis neuropathica, papilloma lineare, papilloma neuropathicum unilaterale, etc.[2] Cases

[1] A full list of the numerous names under which this peculiar form has been described is given in D. W. Montgomery's paper, "The Cause of the Streaks in Nævus Linearis," *Jour. Cutan. Dis.*, 1901, p. 455 (with report of a case, with illustration).

Among the various case reports and contributions on this subject (linear nævus), several with references and résumé of other cases, may be mentioned: Hyde, "Rare Form of Congenital, Multiple, and Monolateral Pigmentary Nævus, Having the Disposition of Zoster Corporis," *Chicago Med. Jour. and Exam.*, 1877, vol. xxxv., p. 377; S. Mackenzie, "On Neuropathic Papillomata," *Illust. Med. News*, vol. i., 1888, p. 123 (several cases with illustrations); Spietschka, "Ueber Sogenannte Nerven Nævi," *Archiv*, 1894, vol. xxvii., p. 27 (report of 3 cases, with illustrations, review of the subject, and references); Werner and Jadassohn, "Zur Kenntniss der 'systematisirten Nævi,'" *ibid.*, vol. xxxiii., 1895, p. 341; and Jadassohn (second paper), "Bemerkungen zur Histologie die systematisirten Nævi," *ibid.*, p. 355, and Jadassohn (third paper), "Zum Localisation der systematisirten Nævi," *ibid.*, p. 373 (3 extremely valuable papers and report of 9 cases, case illustrations, histologic cuts, and full résumé of the disease, with bibliography).

vary to a slight degree, but only in minor details, more especially as to extent, location, and width of the band-like strips. The characters of the formation vary somewhat, however, in different cases, in most probably corresponding to a somewhat hard nævus, with some accumulation of the horny layer, giving it slight scaliness, and of a light or dark brownish color; or it may consist of contiguous and distinctly small papillary growths. In other cases the component lesions may be comparatively smooth and soft, with variable pigmentation. Occasionally, as in the 3 cases, apparently of this disease and of closely similar nature, reported by Thibiérge,[1] Selhorst,[2] and DaCosta,[3] there is associated a comedo-like plugging of the sebaceous ducts. In some cases, as in Morrow's, there is some itching.

Etiology and Pathology.—Moles are seen in both sexes, and are usually congenital, sometimes being small and insignificant at birth, and undergoing variable development later. Duhring and some others believe that many of the flat, smooth, pigmentary nævi without hair, which are seen so commonly upon the trunk, are not congenital, but appear subsequently. Duhring states that they "are almost invariably acquired during the life of the individual." There is no doubt of this in some instances according to my own observations, although it is possible, as has been suggested, that there may have been previously small insignificant, unnoticed lesions from which their development may have sprung. That a nævus may sometimes undergo variable extension is a matter of observation, but much more commonly, however, the only change in many instances is increase in the growth of hair.

Pathologically, an ordinary pigmented nævus is similar to a freckle, except that it is larger, and with usually, but not always, a variable, though often slight, connective-tissue hypertrophy, and commonly with the pigment extending more deeply. The conditions in the other forms vary: there may be hypertrophy of all parts of the cutaneous structures, or a predominance of one or more over other components.

Among other important papers: Hallopeau and Weil, *Nævi systématisés métamériques*, 1897, p. 483 (with some references); Morrow, "Linear Nævus, with Remarks on its Nature and Nomenclature (2 cases)," *N. Y. Med. Jour.*, 1898, vol. lxvii., p. 1 (with 2 colored plates); Ransom, "An Unusual Case of Nævus Unius Lateris," *Jour. Cutan. Dis.*, 1896, p. 141 (with case illustration, and histologic cut by Fordyce); Philippson, "Ichthyosis cornea (hystrix) partialis, etc.," *Monatshefte*, 1890, vol. xi., p. 337 (2 cases and 5 similar cases from literature—critically discussed; illustrations); Cutler, "Ichthyosis Linearis Neuropathica," *Jour. Cutan. Dis.*, 1890, p. 139 (case demonstration); Peterson, "Ichthyosis Linearis Neuropathica," *ibid.*, p. 57 (with illustration and some literature references); Müller, "Ein Fall von Nævus verrucosus unius lateris," *Archiv*, 1892, vol. xxiv., p. 21 (with 2 illustrations); Colcott Fox, *Brit. Jour. Derm.*, 1897, p. 446 (case demonstration). Heidingsfeld, *Jour. Amer. Med. Assoc.*, Aug. 27, 1904 (3 cases, with review and references). Hodara, *Jour. Mal. Cutan.*, 1905 p. 61 (histologic, with review and bibliography); Adamson (histologic), *Brit. Jour. Derm.*, 1906, p. 235.

[1] Thibiérge, "Nævus acnéique unilatéral en bandes et en plaques," *Annales*, 1896, p. 1298 (case demonstration).

[2] Selhorst, "Nævus Acneiformis Unilateralis," *Brit. Jour. Derm.*, 1896, p. 419 (with case illustration).

[3] Mendes DaCosta, "A Case of Sebaceous Nævi"—abs. in *Brit. Jour. Derm.*, 1897, p. 207; original paper in *Nederlandsch Tijdschrift voor Geneeskunde*, Deel 1, No. 7, 1897.

Their origin is somewhat obscure. Unna, speaking jointly of angiomatous and pigmentary nævi, believes that they have a hereditary basis or have their foundations laid in embryonic life, and become evident at different periods later, developing slowly. This practically corresponds to Kaposi's view, that they are the result of an embryonic impulse in one or more of the tissues, which continues beyond the usual normal limit. The cells of which a mole is chiefly composed have generally been thought by pathologists, following Virchow's view, to be of connective-tissue or endothelial origin, and their endothelial origin has recently been maintained by Johnston,[1] but Unna, Gilchrist, Whitfield,[2] and others have, in following out the histogenesis of these growths, reached the conclusion that they are not of dermal, but of epidermal, origin. W. S. Fox,[3] while largely sharing this latter opinion, believes, from his investigations, there is also a rare variety of soft moles whose cells are probably derived from the mesoblast.

The position of linear nævus is somewhat problematic. Unna considers that provisionally they might remain with the proliferative tumors. Histologically, however, in the main, the characters are similar to those of the other forms of nævi presenting like clinical features. Both Petersen[4] and Elliot[5] found adenomatous involvement of the sweat-glands; the latter, however, believing this finding to be an entirely secondary and accidental one.

The origin of this peculiar nævus formation and distribution has been the subject of much discussion. D. W. Montgomery's study of the literature shows that the various theories advanced are: (1) The streaks or bands follow the course of the cutaneous nerves; (2) run along what are called Voight's lines; (3) follow the lines of cleavage of the skin; (4) follow the course of the blood-vessels; (5) run in the metameres or segments of the body; (6) lie along the embryonic sutures and follow the trend of growth of the tissues. The last, according to this writer, more nearly explains the curious band distribution. Balzer and Alquier,[6] in a recent study, conclude that the readiest explanation is upon the basis of the Voight's lines, and that

[1] Johnston, "Melanoma, *Jour. Cutan. Dis.*, Jan. and Feb., 1905. (An elaborate paper with numerous histologic cuts (two colored) and complete bibliography to date). Among others of the important recent papers on the pigmented moles are those of Fick (included in Johnston's bibliography), and Sachs, *Archiv*, 1903, vol. lxvi., p. 101 (with bibliography), and Migliorini, *ibid.*, 1904, vol. lxx., p. 413.

[2] Gilchrist, *Trans. Amer. Derm. Assoc. for 1898*, p. 30. Whitfield, *Brit. Jour. Derm.*, 1900, p. 268 (with bibliography and histologic cuts).

[3] W. S. Fox, "Researches into the Origin and Structure of Moles and their Relation to Malignancy," *Brit. Jour. Derm.*, 1906, pp. 1, 47, and 83 (with review and bibliography). Ziegler's investigations ("Beiträge zur pathologischen Anatomie und zur allgemeinen Pathologie," vol. 39, 1906), show that in some instances the growth takes its origin from the covering epithelium ("Deckepithelium"), and not from the nævus cells themselves.

[4] Petersen, "Ein Fall von multiplen Knäueldrüsengeschwülsten unter dem Bilde eines Nævus verrucosus lateris," *Archiv*, 1892, vol. xxiv., p. 919.

[5] Elliot, "Adeno-cystoma Intracanaliculaire Occurring in a Nævus Unius Lateris," *Jour. Cutan. Dis.*, 1893, p. 168 (with histologic cuts).

[6] Balzer and Alquier, "Les dermatoses linéares;—Étude clinique et pathogénique," *Arch. gén. de Med.*, 1901, vol. clxxxvii., p. 717 (19 illustrations).

the occasional divergence probably depends upon embryonic malformation.

Prognosis.—Pigmentary nævi are permanent,[1] but, as a rule, when once established, do not tend to grow larger, although in many, even of the ordinary, moles, later in life there is a disposition sometimes noticed toward increased growth of the down or hair of the patch. Beyond the disfigurement, however, the blemish is a benign one, unless constantly irritated, under the influence of which, especially in advancing years, degenerative changes set in and a malignant character is occasionally noted. In a relatively few instances, it is true, apparently without known irritation or traumatism, a nævus has been the starting-point of more or less general malignant growths (see also sarcoma), as noted by several observers, among whom, most recently, Green,[2] Gilchrist,[3] and Waelsch.[4]

Treatment.—There are several methods of removing moles—by electrolysis, caustics, and excision. Soft, pigmented fleshy moles, those which have a peculiar tendency to lead to degeneration and general carcinomatous (or sarcomatous) invasion, should be freely excised, going well beyond the limits of the growth. In the ordinary surface non-hairy moles application of the "electric needle" to several or more points, and but superficially inserted, not going more deeply than the upper part of the corium, will sometimes remove the blemish, especially after several repetitions, without leaving much of a scar, and occasionally with scarcely any trace. A more positive way is to insert the needle just beneath the lesions, below the epidermis, along its length, parallel to the surface, several such parallel insertions usually being necessary, and sometimes others running in the transverse direction; the scar may be slight, although if skilfully done often scarcely perceptible. With hairy moles the hairs should be removed first by the ordinary electrolytic method, and in some cases, when this is done, the pigment will have almost completely disappeared, although, as a rule, supplementary treatment, as just described, will be necessary. The elevated and verrucous growths, if not too large, can also be treated in like manner, the hairs, if present, being first removed; subsequently going over the surface with the needle, inserting perpendicularly the required depth, and making the punctures one-eighth to one-fourth of an inch apart; or if time is plenty and a good cosmetic result, as regards scarring, is especially desired, the punctures can be made further apart, and at a later time—a few days—the operation again done in the interspaces, and so repeated. If the case is at all extensive, this method is tedious, but much can

[1] Spitzer, *Dermatolog. Zeitschr.*, 1905, p. 24, describes a case of verrucous nævus which underwent spontaneous involution, and also refers to a similar one reported by Lassar.

[2] Ledham Green, "Ueber Nævi pigmentosi und deren Beziehung zum Melanosarcom," *Virchow's Archiv*, vol. cxxxiv., 1893, p. 331.

[3] Gilchrist, "Are Malignant Growths Arising from Pigmented Moles of a Carcinomatous or Sarcomatous Nature," etc., *loc. cit.* (with histologic cuts and bibliography).

[4] Waelsch, "Ueber die ausweichen Nævus entstandenen bösartigen Geschwülste," *Archiv*, 1899, vol. xlix., p. 249 (with histologic cuts and bibliography).

be accomplished in the way of a good result.[1] The strength of current employed varies, according to the character and nature of the growth, from one-half, in the superficial, freckle-like lesions, to several or more milliampères in the thicker and hypertrophic varieties. Dade and Trimble[2] warmly endorse the use of liquid air in the removal of hairy moles.

The superficial moles can frequently be satisfactorily removed by mild caustics carefully and scantily used, such as trichloracetic acid, glacial acetic acid, and nitric acid, applied by stippling or by a thin coating to the surface; the deeper growths by the same caustics more energetically and repeatedly applied. In the latter, however, if the caustic method is adopted, Brault's plan of removing tattoo-marks (*q. v.*) or the galvanocautery is more rapid; but in such cases, however, if beyond the effective action of electrolysis or moderate use of caustics, excision is usually preferable. Circumscribed growths can be readily excised and the skin brought together, so that only a slight linear scar remains. In the superficial forms, when not too large, shaving off, as in the manner of procuring skin-grafts, the upper surface containing the pigment, will sometimes give excellent results, a method used very frequently by my colleague, Professor Hearn, of the Jefferson Medical College Hospital. Linear nævus can in some instances be successfully treated by the various methods described, but ordinarily the readiest plan is that by excision. Ransom, in his case, after trying many methods, found that the most satisfactory procedure consisted in picking the skin up between the thumb and fingers, snipping off the top of the ridge thus made by flat-pointed scissors, the cut being superficial and extending not quite through the skin proper.

ACANTHOSIS NIGRICANS.

Under this title Pollitzer[3] and Janovsky[4] reported and described minutely, in 1890, each a case of an obscure and a practically unknown or unrecognized grave malady characterized in the main by more or less general pigmentation, associated with, especially on certain regions, the development of verrucous nævus-like growths. It seems, however, that a case with apparently similar symptomatology had previously been recorded by Crocker[5] in 1881. Since the report by Pollitzer and Janovsky other examples of the disease have been noted by various observers, among whom are Darier,[6] Hallopeau,[7]

[1] See report of a successful case, with illustration, by G. H. Fox, *Jour. Cutan. Dis.*, 1893, p. 166.

[2] Trimble, *Med. Record*, July 8, 1905.

[3] Pollitzer, *Internat. Atlas Rare Skin Diseases*, 1890, plate x. (female, aged sixty-two).

[4] Janovsky, *ibid.*, plate xi. (male, aged forty-two).

[5] Crocker, "General Bronzing without Constitutional Symptoms," *London Clinical Soc'y Trans.*, vol. xiv., 1881, p. 152 (with histology—male, aged twenty-two), and second case, *Brit. Jour. Derm.*, 1899, p. 116 (case demonstration—male, aged fifty).

[6] Darier, "Dystrophie papillaire et pigmentaire," *Bull. Soc. Derm. et Syph.*, 1893, p. 421, and *Annales*, 1893, p. 865 (female, aged thirty-four), and *ibid.*, 1895, p. 97 (male, aged thirty).

[7] Hallopeau, Jeanselme, and Meslay, *ibid.*, 1893, p. 876 (female, aged seventy-two), anp Hallopeau, *ibid.*, 1896, p. 737 (doubtful case).

Morris,[1] Kuznitzky,[2] Neumann,[3] Spietschka,[4] Boeck,[5] Roberts,[6] Dyer,[7] and several others,[8] so that now the detailed description of more than 20 cases is on record.

The onset of the malady is slow or rapid. The pigmentation varies somewhat in intensity in different cases, being a sallow yellowish, such as observed in some instances of cancerous cachexia, in others, a bronze tint, and in still others various shades of a darkish or dirty brown. It is more or less general, but usually more pronounced about the flexures and other sites of the papillomatous growths. Concomitantly with pigmentary changes or following it papillary hypertrophy is noted, which to a great extent goes into distinct verrucous elevations. The verrucosity is often limited to or most developed on certain parts, especially the axillary, genitocrural, anal, and abdominal regions. The neck, face, lips, and mouth are also favorite situations, and to a variable extent share in the papillomatous development. The skin, in places at least, and especially on those parts most affected, often presents accentuation of the natural lines, in some instances amounting to superficial furrowing, and is hypertrophied. Palmar and plantar keratosis is commonly present, and partial or complete loss of hair, especially of the hair of the scalp and eyebrows, and dystrophic nail-changes are quite frequently noted. In the region of the flexures the warty growths are often so numerous and crowded that practical coalescence ensues, resulting in the formation of masses of a papillomatous and vegetating aspect. These, like the skin, vary in intensity of pigmentation from a grayish yellow to almost black, and are usually seen in all stages of growth—some minute, others distinctly verrucous. Scaliness is not a usual feature. Darier has noted also the development of nævi, freckle-like spots, and seborrheic warts; and in a few instances epitheliomatous degeneration in some of the lesions has been observed. The lesions on the mucous membrane, especially the mouth, are not present in every instance, but more or less involvement is the rule; they consist of furrows, discrete or crowded papillomatous formations,

[1] Malcolm Morris, *London Med.-Chirurg. Soc'y Trans.*, vol. lxxvii., 1894, p. 305 (female, aged thirty-five).

[2] Kuznitzky, *Archiv*, 1896, vol. xxxv., p. 3 (with a colored illustration and histologic cuts—female, aged forty-one).

[3] Neumann (case demonstration), *ibid.*, 1896, vol. xxxiv., p. 145 (female, aged seventeen—case demonstration).

[4] Spietschka, *Archiv*, 1898, vol. xliv., p. 247 (3 cases—2 females, aged fifteen and twenty; male, forty-four—with histologic review).

[5] Boeck, *Norsk. Mag. f. Laegev.*, No. 3, 1897—abs. in *Jour. Cutan. Dis.*, 1897, p. 588 (female, aged fifty-two).

[6] Roberts, "Melanosis Accompanied by Moderate Acanthosis" (acanthosis nigricans?) (male, aged fifty-eight), *Brit. Jour. Derm.*, 1897, p. 184 (histologic cut).

[7] Dyer, "A Case of Keratosis Nigricans," *New Orleans Med. and Surg. Jour.*, 1898, vol. li., p. 201 (male, aged seventeen).

[8] Burmeister, *Archiv*, 1899, vol. xlvii., p. 343 (reports a case—male, aged thirty-six—and gives a résumé and analysis of 19 reported cases); Couillaud's paper, "Dystrophie papillaire et pigmentaire; ses relations avec la carcinose abdominale," *Thèse de Paris*, 1896, and *Gaz. des Hôpitaux*, 1897, p. 413, gives a review of the subject and literature to date. An abstract review of the cases and papers by Boeck, Couillaud, Roberts, Kuznitzky, Rasch, Collan, in *Jour. Cutan. Dis.*, 1897, p. 588, and those by Barsky, Dyer, and Spietschka, in same journal, 1899, p. 97; Rille, *Wien. med. Wochenschr.*, 1897, p. 1019, and Gaucher, *Medical Week*, 1897, p. 411, give good descriptive accounts; M. Hodara, *Monatshefte*, 1905, vol. xl., p. 629 (following a breast cancer).

which may be sessile or slightly pedunculated, or the mucous surface may be more or less granular-looking.

The course of the malady is slow or somewhat rapid, with some exceptions cases ending, after some months or several years, fatally. A cancerous cachexia is commonly developed, and in the majority of instances sooner or later carcinomatous disease of one of the abdominal organs is recognized—usually the stomach, but occasionally it is the uterus, and in exceptional cases it is more or less general, sometimes secondarily to cancer of the breast.

Etiology and Pathology.—The cause of the disease is not definitely known, but the frequent association of carcinoma would appear to make it, in the majority of cases at least, dependent upon the latter malady.[1] It may occur at almost any age beyond childhood. According to Burmeister's analysis of this point, in 14 cases 1 case was observed under the age of twenty years; 1 between twenty and thirty; 3 between thirty and forty; 5 between forty and fifty; 2 between fifty and sixty; 1 between sixty and seventy; and 1 between seventy and eighty. As to sex, women seem slightly more prone to it, according to Burmeister's analysis furnishing 60 per cent. of the cases. Couillaud, whose valuable contribution was prepared under the supervision of Darier, comes to the following conclusions:[2] "The disease is a syndrome dependent upon abdominal carcinosis and characterized—(I) from a clinical view-point by: (1) a papillary hypertrophy and a cutaneous pigmentation having an essentially regional character; (2) a papillary hypertrophy of the mucous membrane; (3) a dystrophy of the hair and nails; (4) absence of desquamation; (5) existence of a cachexia; (II) from a pathologic standpoint, by carcinomatous degeneration of the abdominal organs; (III) histologically, by lesions of hypertrophy and pigmentation in the rete and corium." Histologic examinations show that the horny layer is thickened, the rete cells, more especially the prickle-cells, enlarged, the corium infiltrated and exhibiting some mast-cells; and both rete and corium filled to a variable degree with pigment granules, irregularly distributed or in masses, partly intracellular and partly extracellular.

Prognosis and Treatment.—When no carcinomatous disease is present, the course of the malady is slow and its outcome uncertain; when, as in most cases, however, there is underlying carcinoma, a fatal result is but a matter of months or a few years. Treatment, unfortunately, is purely expectant, with scarcely a possibility of influencing the course of the disease. Boeck thought that in his case life was prolonged by the administration of suprarenal extract.

CLAVUS.

Synonyms.—Corn; *Fr.*, Cor; Tylosis gompheux; Oeil de perdrix; *Ger.*, Leichdorn; Hühnerauge.

Definition.—Clavus, or corn, is a small, circumscribed, conic, deep-seated, horny formation or callosity, usually seated about the

[1] See Couillaud's and Burmeister's papers, *loc. cit.*, on this point.
[2] Quoted from abstract in *Jour. Cutan. Dis.*, *loc. cit.*

toes, with the small end of the growth pressing down upon the corium.

A corn resembles a callosity, the epidermis being thickened, polished, and horny. It differs, however, from callosity in being smaller and circumscribed, averaging a pea in size, and in being provided with a central prolongation or horny peg, shaped like the head of a nail, known as the core. The base of the corn is directed upward and the apex downward, the latter by its pressure on the nerve-filaments giving rise to pain. Two varieties of clavus are recognized—the hard and the soft. The former is the common one, and generally occurs on the dorsal surface of the toes or on the plantar aspect of the foot; although they may, however, appear on any other part which is subjected to pressure or friction long continued. One, several, or more may be present. A soft corn is generally seen between the toes; it is depressed in the center, and of a grayish color, and, owing to the constant heat and moisture of the parts, it becomes soft. Not infrequently, when improperly treated, corns are the starting-point of erysipelas and suppuration, and even ulceration may occur. From accidental causes or as the result of constant pressure or from some unknown factor a corn exceptionally becomes the seat of inflammatory and suppurative action which may be more or less persistent—*suppurating corn.* They are prone to become quite sensitive during climatic changes, and are usually at all times painful when pressed upon, and sometimes spontaneously so. On the sole of the foot, when well developed, they may give rise to considerable discomfort, making locomotion or standing painful.

Etiology and Pathology.—A corn results from pressure with counterpressure and friction, attributable generally to tight or badly fitting shoes. It appears, however, that apparently similar formations may occur spontaneously independently of pressure, as in the cases of Davies-Colley, quoted by Crocker, in which the palms and plantar surfaces of a Hindoo were the seat of numerous clavi. Primarily the growth is, as in callositas, an attempt to protect a part pressed upon, but its subsequent peculiar development is difficult to understand. It consists of a circumscribed hyperplasia of the epidermis, of conic shape, with the base external, variously elevated, and with the apex directed downward and pressing upon the papillæ. It is, in fact, a peculiarly shaped callosity, the central portion and apex being dense and horny, forming the so-called core. The corium beneath the down-pressing apex is thinned, and the papillæ are usually atrophied, although occasionally hypertrophied. There is, Robinson states, more or less hypertrophy of the papillæ at the circumference. Unna noted "well-preserved condition of the sweat-glands, and even those glands whose pores disappear in the core do not atrophy." Minute hemorrhages frequently occur beneath the thickened epidermis, due to rupture of capillary vessels of the papillæ. Structurally, the growth is made up of closely packed epidermic cells arranged in concentric layers.

Treatment.—Removal of the cause and the wearing of properly fitting shoes are a *sine qua non* of successful treatment. In fact, if pressure is removed, corns will in most instances disappear sponta-

neously. In an affection so common, the plans of treatment recommended, as is to be expected, are almost innumerable. A simple and popular method of treatment consists in shaving off, after a preliminary hot-water soaking, the surface portion by means of a razor or sharp knife, and then applying a ring of felt wadding or like material having an adhesive side, to be found in the shops, over the region of the corn, with the hollow part directly over the site of the core. This should be worn for some time—usually several weeks—thus relieving the growth of all pressure and friction; and if well carried out, this plan quite frequently will bring a good result. Another method is to pare off, as before, the thickened broad surface, and then carefully to dissect out the core; in some instances, after thorough soaking and surface removal, this can be extracted with the forceps. Chiropodists have become quite expert in their removal, often dissecting them out without previous softening, and with scarcely any pain and rarely any bleeding. In manipulations of this character it is absolutely imperative that the instruments employed should be aseptic, as unpleasant complications or consequences have occasionally been noted. In some cases touching the base of the cavity left by the removal of the corn with a droplet of a solution of caustic potash will prevent a return; but the application must be made with care, and with a solution of not more than 5 per cent. strength, and its action almost immediately neutralized with vinegar or dilute acetic acid.

A safe and conservative plan, sometimes successful, consists in the repeated application of a solution of salicylic acid in collodion, for which the common formula is: Salicylic acid, gr. xxx–xl (2.–2.65); ext. cannabis indica, gr. x (0.65); collodion and flexible collodion, āā ʒij (8.).—M. This is to be painted on the corn night and morning for several days, at the end of which time the parts are soaked in hot water, and the horny mass, or a greater part of it, will, as a rule, come readily away with a little rubbing or scraping. If it is then at all tender, treatment is to be discontinued for a few days, and the paintings resumed. Several repetitions are usually necessary. After apparent relief the wearing of a ring-pad, as already referred to, for a few weeks, is to be advised. Salicylic acid has the peculiar property, especially when so applied, and also in the form of a plaster, of softening and removing the horny layer of the epidermis, and this drug is the active principle in most of the advertised corn-cures. The various caustics are also occasionally employed, but their use requires care and caution. Of the milder caustics, lactic acid may sometimes be applied, in minute quantity, with benefit, weakened or full strength.

In soft corns the same mild plans mentioned may also be employed. Nitrate of silver is useful in these cases, the outer surface first being removed by salicylic acid or weak solution of caustic potash. The essential measure is the prevention of friction and maceration by keeping the toes slightly separated with a piece of soft lint or absorbent cotton, changing frequently. When extremely sensitive, dilute lead-water is a soothing application.

CALLOSITAS.

Synonyms.—Tyloma ; Tylosis ; Keratoma ; Callus ; Callosity ; *Fr.*, Durillon ; *Ger.*, Verhärtung.

Definition.—Callositas is a hard, horny, thickened epidermic patch, due to hyperplasia of the stratum corneum, and occurring for the most part on the hands and feet.

Symptoms.—Callosities are acquired formations. They consist of small or large patches of yellowish, grayish, or brownish, hard, horny, slight or excessive epidermic accumulations, which are generally seen on parts subjected to pressure or friction. Hardening and slight thickening are also sometimes caused by chemical irritants. The palms, soles, fingers, and toes are favorite locations. They are somewhat elevated, are quite thick, especially at the central portion, less so at the edge, and gradually merging into the sound, unaffected skin ; they are very hard, dry, and horn-like and occasionally brittle. The natural surface lines of the affected part are obliterated, the patches generally being smooth. When the thickening is markedly developed, it interferes with delicacy of touch, and may impair the finer movements somewhat. As callosities are usually the effort of nature to protect underlying parts constantly rubbed or pressed upon, they are necessarily very frequently observed on the hands of mechanics, as tinsmiths, blacksmiths, carpenters, shoemakers, tailors, workers in metals, etc. They are also not infrequently seen on the fingers of zither-players, violinists, and harpists. About the soles and sides of the feet they most commonly occur in those whose occupation requires constant walking or standing, and more especially if roughly and heavily made or tight shoes are worn. The ball of the great toe and lateral surface of the little toe and the heel are favorite locations. They are also observed in those who go barefooted. Long-continued pressure kept up by surgical appliances for the correction of some deformity or the wearing of a truss may bring about callosities in the parts pressed upon. Callous thickening over the ischial tuberosities are usually formed in those who sit much upon hard chairs or benches. They are also thought to arise spontaneously at times, but such cases are mostly examples of inherited and usually symmetric callosities—keratosis palmaris et plantaris (*q. v.*). As a rule, inflammatory symptoms do not make their appearance in these growths, although occasionally, from accidental injury, the subjacent corium may become inflamed and suppurates, and the thickened mass be cast off.[1] They usually disappear spontaneously when pressure and other external irritation which may have produced them are removed. A variable callous condition or horny thickening is, as well known, sometimes observed in several of the chronic cutaneous diseases, as in some forms of eczema, in ichthyosis, lichen planus, psoriasis, and a few other maladies, but in such it is merely a part of the pathologic process ; sometimes,

[1] Morrison, *Jour. Cutan. Dis.*, 1886, p. 5, reported a curious case in a negro, a fireman for ten years on a steamer, in whom the friction of the handle of the shovel and the exposure to intense heat brought about markedly thickened layered callosities under which later suppuration, ulceration, and necrosis developed.

however, the callous development remains after the disease has disappeared. Palmar and plantar keratoses are also not infrequently the result of prolonged arsenical administration (see dermatitis medicamentosa). Anatomically, the growths consist of thickened upper epidermic layers; the deeper underlying strata of the epidermis and corium remain, as a rule, except when involved by accidental inflammatory action, unaffected.

Treatment.—Quite frequently treatment is not required, as the accumulation may be a naturally formed protective against the constant pressure and friction incident to the patient's occupation. Occasionally, however, the formation is excessive and unsightly, and gives rise to discomfort. In such instances and in others in which removal or at least thinning down is deemed advisable, this object can be accomplished in several ways. The callus can be softened in hot water containing one-half to an ounce (16.–32.) of an alkaline carbonate, such as sodium carbonate or bicarbonate, potassium carbonate, or sodium borate, to the gallon. The parts can also be softened by poultices. After a soaking of some minutes the outer surface is sufficiently softened to be readily pared down, and this may be repeated until the thickening is sufficiently reduced. The same result can be obtained by painting on a solution of caustic potash—in mild cases, the liquor potassæ, in hard and much thickened areas a solution several times stronger; care should be exercised with the latter. Several such paintings can be made within a few minutes of one another, and then the softened part scraped or shaved away. According to circumstance it can again be repeated immediately, or if any irritation has been produced, a day or two later. Lactic acid, weakened or full strength, will also soften such epidermic accumulations. Another satisfactory method is by the continuous application of a 10 to 25 per cent. salicylic acid rubber plaster or plaster-mull for several days or a week; on removal it is followed by hot-water soaking, and the mass can, in great part, at least, be rubbed or scraped away. The action of the plaster may have been sufficient to permit the rubbing or scraping away of the callus without the supplementary soaking. According to the degree of thickening this application may need to be repeated once or several times. The salicylic acid collodion paint, often used in clavus (*q. v.*), can be employed in place of the plaster, but is generally not so efficient, although it is not so inconvenient. In moderate cases enveloping the parts at night with a compound salicylated soap-plaster, advised in some cases of eczema, will usually keep the thickened accumulation from getting stiff, hard, and inelastic. In persistent cases the Röntgen ray treatment can be tried.

KERATOSIS PALMARIS ET PLANTARIS.

Synonyms.—Tylosis palmæ et plantæ; Ichthyosis palmaris et plantaris; Keratoma; Keratoma palmare et plantare hæreditarium; Symmetric keratodermia; *Fr.*, Kératodermie plantaire et palmaire.

Definition.—Hypertrophy of the corneous layer of the palms and soles, usually of a more or less horny and plate-like character.

Symptoms.—The features of this somewhat uncommon malady, to which the contributions of Unna[1] and Hyde[2] first directed special attention, are in their essential character analogous to those of callositas, but the hardening and thickening arise spontaneously without necessarily having any external factor, such as pressure, friction, etc., as in the latter malady, and is, furthermore, symmetric, and usually on palms and soles. Moreover, it is, as a rule, congenital or a hereditary condition. The degree f development varies somewhat both as to thickness and uniformity. In the typical cases the whole palmar and plantar regions are the seat of a thickened, usually smooth, hardened, and sometimes seemingly translucent, yellowish, brownish-yellow, or yellowish-gray calloused epidermic plate. It is of a hard, leathery consistence, not infrequently being almost horny in character. While it is commonly limited to the palmar and plantar aspects, occasionally it extends somewhat beyond on to the side, and exceptionally slightly on to the dorsal surface. Much more frequently, however, the only parts calloused over, in addition to the usual sites, are several or more of the knuckles. It is common to find the nails more or less affected, and tilted slightly or moderately upward by the collection of hardened and thickened epidermis under their free borders. At the edge of the plate-like thickening there is generally a narrow pinkish or reddish halo or zone, apparently passive in character, and not due, as a rule, to inflammation, this latter, with few anomalous exceptions, being observed only as an occasional accidental factor. In some instances there is associated hyperidrosis of the parts, in which event the epidermic mass is not so hard or horny, and although still tough, may have a slightly sodden character.

The condition is a persistent one, although in some cases, from time to time, there is a partial or almost complete casting off of the hardened plate, and a variable intermission of at least comparative freedom. While the surface is usually smooth or not conspicuously rough, sometimes it is somewhat irregular, and in occasional instances it has a slightly worm-eaten appearance. The thickness of the plate varies, averaging almost $\frac{1}{8}$ of an inch, and sometimes much more over parts subjected to pressure. The conditions are practically the same on both palms and soles, although on the latter the hollow of the foot usually escapes completely or is but relatively slightly affected. There are variations, however, from the malady as described, and it may not involve the entire parts uniformly. Brocq[3] has described a case in which the calloused formation was of a more or less band-like character and of a longitudinal direction, running along and corresponding to the middle of the anterior aspect of the fingers. In other instances the chief thickening is over the joint prominences. In some, moreover, the keratosis consists, primarily at least, of small

[1] Unna, "Ueber das Keratoma palmare et plantare hereditarium," *Archiv*, 1883, p. 231 (2 cases, with illustration).

[2] Hyde, "Observations in Three Cases of Symmetrical Hand and Foot Disease," *Med. News*, vol. li., 1887, p. 416 (3 cases, bibliography). The subject is well gone over in the papers and discussion in *Trans. of Third Internat. Dermatolog. Congress*, London, 1896. The clinical appearances of the malady are well shown in the plate in Mracek's *Hand-Atlas of Skin Diseases* and also in the colored illustration in Crocker's paper, "Tylosis Palmæ et Plantæ," in *Brit. Jour. Derm.*, 1891, p. 169.

[3] Brocq, *Traitement des Maladies de la Peau*, second edit., p. 378.

rounded or conic callosities, with but slight or moderate thickening of the intervening skin. A case somewhat similar to the last, with a slight erythematous or inflammatory halo or zone surrounding the callosities, has been noted by Besnier.[1] Brooke[2] has also called attention to a peculiar erythematous condition (erythema keratodes of palms and soles), seemingly allied to the malady under consideration, but in which there was some underlying erythema, giving the slightly thickened epidermis an orange-gray color and a quite pronounced inflammatory halo; the inflammation was of a mild or moderate grade, although the outer edges were somewhat swollen and tense and hot to the touch. There was, in addition, erythematous horny papules over the joints on the dorsal surface of the fingers. The malady was less marked on the soles. It responded to treatment, but was prone to recur.

There are no subjective symptoms—occasionally slight tenderness around the edges and over the joints. There is interference with free mobility of the parts, and sometimes fissures are to be seen, and these are usually quite painful. Exceptionally, from accidental irritation or as a result of occupation, an eczematous element may be superadded. Ordinarily, however, the condition, beyond its unsightliness and inconvenience, gives rise to no trouble. Hyde[3] mentions that in these patients "the pulse is sometimes exceedingly slow, running in adults from 50 to 55 beats a minute, without other manifest impairment of the general health."

Etiology and Pathology.—Beyond the fact of the malady being congenital and often hereditary, but little is known as to its causes. Exceptionally it has been acquired. A history of its occurrence in two or more generations is sometimes obtainable (Thost, Unna, Date, Crocker, Sherwell, Heuss, Neumann, Pendred),[4] and not infrequently two or more members of the same generation, as in several reported by those just named. It has also been stated that it tends to affect only one sex in the family, but this is not borne out by an analysis of the cases. In some instances pressure and friction have seemed to be exciting, or at all events aggravating, causes. The malady is not, however, to be confounded with the keratosis, often of

[1] Besnier, "Keratodermia symmetrica erythematosa," *Internat. Atlas Rare Skin Diseases*, 1889, plate v.

[2] Brooke, *Brit. Jour. Derm.*, 1891, p. 335, with colored plate; also "Notes on Some Keratoses of the Palms and Soles," *ibid.*, p. 19; Dubreuilh, *ibid.*, 1892, p. 185, reports a somewhat similar case.

[3] Hyde, Morrow's *System*, vol. iii. (Dermatology), p. 405.

[4] Thost, *Ueber erbliche Ichthyosis palmaris et plantaris*, Heidelberg, 1880, quoted by Unna (4 generations); Unna, *loc. cit.* (1 case, 2 and 1 case, 3 generations); Date, "Hereditary Ichthyosis," *Brit. Med. Jour.*, 1887, ii., p. 718 (5 generations; brief note); Crocker, *loc. cit.* (one instance 5, and another 2, generations); Sherwell, *Jour. Cutan. Dis.*, 1898, p. 451 (case demonstration—2 generations); Heuss, "Keratoma palmare et plantare hereditarium," *Monatshefte*, 1896, vol. xxii., p. 405 (3 generations); Neumann, "Ueber Keratoma hereditarium," *Archiv*, 1898, vol. xlii., p. 163 (7 plates, 2 generations); Pendred, *Brit. Med. Jour.*, 1898, i., p. 1132 (3 members of family; disease appeared in unbroken succession—5 generations—for at least one hundred and fifty years in the same family, principally through the female line); Vörner (*Archiv*, 1901, vol. lvi., p. 1, with bibliography), Pasini (*Giorn. ital.*, 1902, vol. xxxvii., p. 318, with bibliography), Decroo (*Jour. d. sci. med. de Lille*, July 4, 1903—abs. in *Brit. Jour. Derm.*, 1903, p. 377), and Böhn (*Dermatolog. Centralbl.*, 1904, March, p. 162) also report instances of the malady through several generations.

similar general aspect, such as the callosities resulting from occupation and that noted in connection with eczema, pityriasis rubra pilaris, and other chronic diseases; nor that due to the continued ingestion of arsenic (see dermatitis medicamentosa), although this latter might readily be considered as an acquired or accidental example of the same malady due to a definite etiologic factor. It is not improbable that there are several distinct varieties, as indicated by the unusual types referred to, and that the etiologic factors are somewhat varied. Besnier divides the cases into four classes: (1) The ordinary symmetric congenital and hereditary form; (2) the symmetric keratodermia developing in childhood, of an erythematous and irritable character, and probably connected with some neurosis; (3) symmetric keratodermia, especially of the feet, developing primarily in isolate foci, and probably of central origin; (4) accidental keratodermias, distinct from ordinary callositas, occurring at any age, and provoked by some unusual occupation or work.

While the malady may be seen in any station of life, it is usually observed in the poorer and working-classes. It is met with in both sexes. The condition, or an analogous affection, seems to be endemic on the island of Meleda, off the coast of Dalmatia, and is known as the "mal de Meleda"; Hovorka,[1] viewing it originally as a form of leprosy, subsequently (Hovorka and Ehlers)[2] retracted this opinion. Professor Neumann, who visited the island and examined several cases (*loc. cit.*), also dissented from this view. He found that it was not leprosy, but a disease similarly or closely allied to symmetric keratodermia. In the cases there, however, the thickening was not limited to the hands and feet alone, but the lower leg and lower forearms and the patellar region also were involved. Neumann believes it belongs to the category of the hereditary anomalies of the skin.

Pathologically, the disease is closely related to callositas, and about the same histologic characters are disclosed, the chief and constant factor being the thickening and hardening of the corneous layer.

Diagnosis.—The symmetric character of the disease, its usual involvement of all extremities, the absence of inflammatory symptoms, the frequent association of hyperidrosis of the parts, and the common history of its existence since birth and of hereditary tendency will generally serve to prevent its confusion with thickened squamous eczema, ordinary callosities, and the thickening occasionally seen in connection with other maladies. The possibility of a similar or closely similar condition being due to the prolonged ingestion of arsenic is not to be overlooked, nor that such keratosis, after once thoroughly established, is sometimes persistent.

Prognosis and Treatment.—The condition is irremediable as to permanent relief, but treatment can do much to keep the malady in abeyance. But little, if anything, is to be expected from general treatment, although Brocq advises large doses of sodium arseniate; and in the symmetric erythematous keratodermia the same drug, together with the bromids, and the application of revulsives to the nape of the neck. Brooke thought the internal administration of

[1] Hovorka, "Ueber einen bisher unbekannten endemischen Lepraherd in Dalmatien," *Archiv*, 1896, vol. xxxiv., p. 51.

[2] Hovorka and Ehlers, "Mal de Meleda," *Archiv*, 1897, vol. xl., p. 251.

ichthyol, 3-minim doses (0.2), in association with local treatment, of curative value. Klotz[1] believed in one case benefit derived from the internal use of pilocarpin. The important and usually only treatment which has any effect consists in external applications, and the most valuable of all are those in which salicylic acid is the active constituent, the treatment being the same, in fact, as advised in ordinary callositas (*q. v.*). A strong salicylic acid plaster seems, in my experience, the best method of its application—15 to 25 per cent. strength. A 10 to 20 per cent. salicylated soap-plaster, as advised by Klotz, is also valuable. Soft-soap (sapo viridis) cataplasms and hot-water soakings may also be used to soften and remove the hardened accumulation; or instead of sapo viridis, caustic potash solution, 10 to 30 per cent. strength, can be cautiously employed. In a few instances frequently repeated close exposures to the Röntgen rays have been followed by a disappearance of the thickening.

KERATOSIS SENILIS.

Old age of the skin, or atrophia senilis (*q. v.*), is characterized by various changes: sometimes more or less thinning of the derma, freckle-like and larger pigmentary spots, seborrheic warts (*q. v.*), greasy crusted or scaly patches, usually pea- to bean-sized or larger, and somewhat hard, generally small, thickened epidermic patches. This last formation is the ordinary type of lesion to which the name of keratosis senilis is commonly applied, but in reality it is often applied to the last two. The greasy crusted or scaly spots begin, as a rule, by a slight pigmentation, and this may remain as such, or after a time it is noted to be greasy to the sight and touch. Later it becomes irregularly covered with a thin, scarcely noticeable, scaly coating, which can easily be rubbed off. Gradually the scaliness increases in thickness, and sometimes in area, is dirty gray or brownish gray in color, and often quite adherent; and when removed, the surface is moist or oily, and after a time an atrophic thinning is observed. It may remain almost indefinitely as such, the scaly crust being rubbed, washed, or cast off from time to time, and gradually renewed. In many instances, however, the process advances, and the degenerative thinning is followed by superficial abrasion, and sometimes with scarcely noticeable papillary prominences, and now, when the crust is at all forcibly or harshly removed, slight bleeding—one or two droplets—may occasionally be observed. The discharge from the abrasion, or perhaps now superficial ulceration, together with the oiliness of the immediately surrounding border, gives rise to a slightly thicker crust. From such a **degenerative seborrheic patch** often results a beginning superficial epithelioma or rodent ulcer. In other instances the sebaceous scaliness may be more of the nature of a somewhat horny concretion, and limited to one or several contiguous gland-ducts, finally presenting sometimes an ill-defined, warty-looking aspect. This coating or formation is apt to be more adherent, and not so readily dislodged, partaking of the nature of both a keratosis and a degenerative seborrhea. After a time atrophy may take place, or the base, especially the peripheral

[1] Klotz, *Jour. Cutan. Dis.*, 1899, p. 373 (society discussion).

portion, shows slight abrasion or ulceration, and practically the same stage is reached as above indicated.

In the true keratosis senilis the earliest manifestation is frequently a slight discoloration, and over which, after a while, the horny layer of the epidermis becomes harder, and thickens somewhat, forming a roughness or scaliness. To the finger it now feels rough, harsh, and hard or quite horny, not greasy, as a rule, as in the degenerative seborrheic patch. The spot becomes slightly or moderately elevated, grading off into the surrounding integument, or being somewhat sharply defined. It now consists of a hardened or horny elevated spot, with trifling dry harsh adherent scaliness, and appearing as if the tissue thickening involved both the upper corium and epidermis. The surface in some instances is uneven and wart-like, and the color

FIG. 112.—Keratosis senilis, scurfy and scaly spots and patches, with degenerative changes, on the cheek, tending to become epithelimatous; small epithelioma on neck, developed from a similar spot.

is usually dirty or yellowish gray or blackish gray, and occasionally quite dark. In area it varies from that of a pea to a half-inch or so in diameter. It may remain more or less indefinitely as such, or atrophic changes begin to present, which gradually lead to epithelial degeneration, abrasion, ulceration—in short, to the development of an epitheliomatous lesion. As with the degenerative seborrheic patch, one, several, or many may be present.

The usual site of these formations is the face, but the back of the hand is also a quite frequent situation. As a rule, they are observed in those past the age of sixty, but to this there are many exceptions, old age changes in the skin often presenting as early as the age of forty and sometimes earlier, even though the patient be yet in other respects possessed of the attributes of vigor and active adult life.

They are, as White[1] points out, much less likely to develop upon persons who have kept their cuticle and sebaceous glands in proper order through life by sufficient use of soap than in those who have been more or less negligent in this respect. There is, however, in some individuals a peculiar proneness to these degenerative formations.

Prognosis.—Ordinarily in their earlier development, both as to the degenerative seborrheic spots and the keratoses, if properly looked after, their further formation or progress can be prevented by proper measures. Their chief significance is the possibility or probability of undergoing epithelial degeneration and development into epithelioma, not at all an uncommon result when neglected, although, for the most part, usually into but slowly progressing and comparatively benign lesions, which, however, sometimes become transformed into an epithelioma of more malignant character.

Treatment.—In their earliest appearance the use of a simple mild ointment, such as cold cream or vaselin, rubbed in gently at night, and washed off with soap and water in the morning, will often suffice to remove the blemish, or, at all events, stay its progress. If of more positive character, the ointment can be rubbed in after the morning washing as well. When there is considerable hardness, the continuous application of the ointment over night as a spread plaster is more efficient. The addition of salicylic acid, in the proportion of 1 to 4 or 5 per cent., is to be made when the condition is obstinate or more advanced. In the latter event an ointment composed of 5 to 20 grains (0.33–1.33) each of salicylic acid and sulphur to the half-ounce (16.) of ointment base,—vaselin or equal parts of vaselin and lard or cold cream,—and gently rubbed in at night after a preliminary soap-and-water washing, will be found of greater value, and often curative. I have found these two drugs especially valuable in these conditions; D. W. Montgomery[2] and likewise others have had similar experience. In the treatment of the degenerative seborrheic spots it is not necessary to go beyond the treatment indicated, unless epithelial changes with ulceration have already set in, in which case the management becomes that of superficial epithelioma (*q. v.*).

The advanced, and sometimes the slight, true keratosis senilis, in which there is a good deal of horny hardness or wart-like development, will usually require more energetic measures. If rebellious to the means already suggested, a strong salicylic acid ointment, 5 to 15 per cent. strength, can be applied as a plaster over night for one to several nights, a mild salve application being made in the daytime. This remedy is still more active, and this effect is sometimes necessary, when applied in the form of a 10 to 25 per cent. plaster-mull, or in collodion, in 5 to 15 per cent. proportion. Two or three such applications will often suffice to remove the thickening, and subsequently the mild salicylic acid salve, with or without the addition of

[1] J. C. White, "The Old Age of the Skin," *Boston Med. and Surg. Jour.*, vol. cvii., 1882, p. 484. This and other forms of keratosis will also be found more or less exhaustively dealt with in the paper by Dubreuilh, "Des Hyperkeratoses circonscrites," *Annales*, 1896, p. 1158 (with review of the subject and references); and especially as regards their significance as precanervous affections, by Hartzell, *Jour. Cutan. Dis.*, 1903, p. 393 (with 3 histologic cuts and bibliography).

[2] D. W. Montgomery, "A Contribution to the Treatment of Senile Patches," *Philada. Med. Jour.*, 1898, vol. i., p. 211.

sulphur, can be used. Sometimes, however, their complete removal without cauterizing or operative methods is not possible, but, as a rule, their further progress can usually be stayed. If obstinate, the strong salicylic acid plaster or collodion applications should not be continued indefinitely, as possible irritation and degenerative changes might be promoted. If unyielding as to complete obliteration, if stationary, nothing further need be done; but should the patient desire removal or should epitheliomatous changes have presented, then one of the various plans for superficial epitheliomata can be resorted to, or Röntgen ray exposures can be tentatively tried. For the treatment of seborrheic warts and other senile cutaneous changes the reader is directed to the articles on warts and atrophia senilis.

KERATOSIS PILARIS.

Synonyms.—Pityriasis pilaris; Lichen pilaris; *Fr.*, Keratose pilaire; Xérodermie pilaire (Besnier).

Definition.—Keratosis pilaris is a hypertrophic affection characterized by the formation of pin-head-sized or slightly larger conic epidermic elevations seated about the apertures of the hair-follicles, and most commonly presenting on the outer anterolateral and posterolateral aspects of the thighs and arms.

Symptoms.—In this disease conic, sometimes slightly acuminate or flattened, papules, the size of a pin-head, and of a whitish, grayish, or dark-gray color, and consisting of epithelial cells and sebaceous matter, are situated at the outlets of the hair-follicles, from which they project. Not infrequently the lesions are somewhat larger, and quite elevated; exceptionally the color is blackish. They are discrete, numerous, do not form patches or distinct aggregations, but, although closely set, are more or less evenly distributed over the affected regions. They are usually located on the extensor and outer surfaces of the thighs and arms, and sometimes also on the trunk, and in rare instances show a more or less general distribution. On close inspection the papules are seen to be pierced by a hair, which is either lanugo-like in character or broken off at the apex of the papule, when it is seen as a dark point in the center of the lesion, or is coiled within the papule. They are somewhat hard, harsh, and dry, and the apex slightly scaly, and to the hand passed over the part feel like the surface of a nutmeg-grater. If the accumulation falls out or is rubbed or picked out, a small depression marks the site temporarily, occupying the opening of the hair-follicle. Sometimes the enveloping basal follicular outlet is somewhat reddened and elevated, and the papule then noted to be of a slightly inflammatory character.

The intervening skin between the papules is generally dry and harsh to the touch, sometimes with a trifling furfuraceous scaliness. On the neighboring regions it may, and usually does, present a perfectly healthy appearance, although not infrequently the skin over most of the surface is also found harsh and dry, and suggestive of a mild ichthyosis, which malady, in fact, occasionally may be associated. In rare instances in a few of the lesions there may be an accidental pus-

tular capping. There are, indeed, considerable variations in extent and development. In its milder forms it is not uncommon, and often it is so slight as almost to escape notice. In the latter instances it bears rough resemblance to goose-flesh. Quite often it is limited to the thighs alone. In other cases the lesions are very pronounced and may be distributed over a considerable part of the surface. It is rare, however, to find the eruption on the flexor aspects. Its development is insidious and slow, and occurs during the cool or cold season; warm weather gives rise to free action of the sweat- and sebaceous glands, the skin is kept soft, supple, and moist, and the dryness and epidermic papules cannot readily be produced. Subjective symptoms are usually absent, although occasionally moderate or even considerable itching is complained of.

Etiology and Pathology.—The affection is more common during early adult life, although it may be met with at any age, excepting possibly earliest infancy. It is most frequently observed, moreover, during the winter months, and usually in those who have naturally rather dry skin and who are unaccustomed to frequent bathing. In some individuals, however, there is a greater tendency to development exhibited, and sometimes in spite of moderately frequent washing, so that there is probably another etiologic element —doubtless a hereditary predisposition to a dry skin. It has been considered by some observers to occur much more frequently in those of a cachectic or scrofulous tendency, but apparently it is just as common in those of vigorous and robust nature. Those who naturally have somewhat active perspiratory secretion are rarely affected. Its greatest development is observed in ichthyosis, of which disease it is a pathologic part.

Anatomically the malady essentially consists of a hyperkeratinization of the upper part of the pilosebaceous follicular outlet, and the papular elevation results from the formation of this superabundant or accumulated epidermic horny mass, which projects beyond the orifice. To this, in some instances, slight basal congestion is added secondarily, and probably purely as the result of the irritation produced by this collection or possibly for some unknown pathologic reason; and in occasional cases, instead of such trifling basal congestion, there is distinct, though usually extremely slight, inflammatory infiltration. In extreme instances of these latter types there is some suggestion of the same pathologic process as in pityriasis rubra pilaris, and it is not impossible that some of the cases of keratosis pilaris occasionally referred to as of peculiar distribution and of excessive horny development, and otherwise anomalous, are on the border-line between these two maladies. It is probably in such instances only that the superficial perifollicular cell-infiltration is found (Crocker, Unna, Giovannini, and others). The congestive and inflammatory elements, when present, give the lesions a somewhat different aspect, and doubtless, chiefly based upon these factors, Brocq[1] divides the cases into several forms—keratosis pilaris alba, keratosis pilaris rubra, and two intermediate divisions. In the extreme cases of the latter—the inflam-

[1] Brocq, "Notes pour servir a l'histoire de la kératose pilaire," *Annales*, 1890, pp. 25, 97, and 222 (a complete exposition and review of the subject with many references).

matory type—slight atrophy or scarring may exceptionally result. Mibelli, Unna, and a few others do not consider the lesion of this malady and the apparently similar one of ichthyosis as pathologically identical. According to Giovannini,[1] Mibelli,[2] and Lemoine,[3] there are also, at least in some cases, atrophic changes in the sebaceous glands, which may, in fact, entirely disappear; the first named, moreover, found atrophy of the hair-papilla.

Diagnosis.—The character of the eruption, its persistently discrete lesions, with no attempt at grouping or to the formation of coalescent solid patches, and its common localization will serve to prevent error. It is to be distinguished chiefly from goose-flesh (cutis anserina), the miliary-papular syphiloderm, and lichen scrofulosus. In goose-flesh the elevations, due to sudden chilling or excitement, are evanescent, not rough, harsh, and scaly, and subside rapidly as suddenly as they came upon the surface being warmed, being rarely present more than a few minutes. The dull ham, brownish-red colored papules in the miliary-papular syphilid have a more general distribution, are distinctly infiltrated, and therefore firmer to the touch, and tend to aggregation and groups; the slight scaliness is a late phase. There will be found also other symptoms of syphilis. In lichen scrofulosus—a rare disease—the eruption is usually limited, and occurs in distinct, more or less rounded groups or patches, and most commonly upon the trunk, especially the abdomen, the extensor aspects of the extremities rarely being involved; the lesions are firmer and less scaly. In pityriasis rubra pilaris the scaly condition of the scalp and the horny thickening of the palms, as well as the plaque and confluent tendency and distribution, are totally different from the eruption of keratosis pilaris. It can scarcely be confused with eczema or lichen planus, both itchy inflammatory diseases of different character, behavior, and distribution.

Treatment.—The common clinical type yields readily, the condition often being removed in the course of a few weeks, and wholly as the result of external treatment. In some rare instances, more especially, however, the inflammatory type, the end is not so soon reached. In such cases, particularly in ill-nourished individuals, cod-liver oil, arsenic, and iron are sometimes to be advised. Rarely, however, are more than external measures required, and these consist ordinarily of frequent local or general baths, plain warm baths, with the use of an ordinary toilet soap or sapo viridis. In other cases the baths should be alkaline, using for this purpose from 1 to 6 ounces (32.–192.) of sodium carbonate, sodium borate, or sodium bicarbonate to about 30 gallons (120. l.) of water; in others, in addition to the baths, supplementary applications of a mild salicylated ointment, from 10 to 30 grains (0.65–2.) to the ounce (32.) of petrolatum or lard and lanolin, will be found necessary. In fact, the management is practically the same as employed in the milder cases of

[1] Giovannini, "Contributione allo studio istologico della cheratosi pilare," *Lo Sperimentale*, 1895, p. 661—abs. in *Brit. Jour. Derm.*, 1896, p. 151.

[2] Mibelli, "Zur Aetiologie und die Varietäten der Keratosen," *Monatshefte*, 1897, vol. xxiv., pp. 345 and 415 (with numerous references).

[3] Lemoine, "De l'ichthyose ansérine des scrofuleux," *Annales*, 1882, p. 275.

ichthyosis. In some individuals, however, frequent bathing must be subsequently followed to prevent its recurrence.

Crocker describes[1] another somewhat similar malady in some of its aspects, but which is slightly inflammatory, often patchy, and occurs on almost any region. To this rare affection, which is scarcely described by other authors, he limits the name **lichen pilaris,** the common synonym of keratosis pilaris, to be in conformity with other lichens which are of an inflammatory nature. Never having met with a case, I draw from his description, and for the most part *verbatim.* It may develop acutely or subacutely in crops, and consists of papules about the size of a pin-head, red, conic, and containing in its center a horny spine projecting about $\frac{1}{16}$ of an inch; this epidermic plug can be picked out, leaving a depression in the papule. After some duration the papule loses its redness and becomes the color of the normal skin. The papules are densely crowded into patches, often large and irregular in outline, symmetrically distributed, sometimes in a few, sometimes in many, regions. The favorite sites are the back of the neck, the buttocks, over the trochanters, the abdomen, the back of the thighs, the popliteal spaces, and the extensor surfaces of the arms. The hands, feet, face, and upper part of the chest are, according to Crocker's observations, not attacked. There is a tendency, in cases in which the eruption is not dense, to form roundish groups, with some scattered papules between. The eruption comes out in crops, sometimes a patch appearing over night, gradually increasing in extent for a week; after this the lesions grow paler, but beyond this the eruption usually persists without change more or less indefinitely. The cause is unknown. It occurs chiefly in children, and in Crocker's experience more frequently in boys. In a few instances it was associated with lichen planus and with lichen scrofulosus. It bears resemblance to keratosis pilaris and to pityriasis rubra pilaris. Alkaline baths with friction, and in the inflammatory stage supplemented by a mild grease or oil; or, if sluggish, with weak tincture of green soap, containing a dram (4.) of oil of cade to the ounce (32.), prove successful. The constitutional treatment is according to indications: cod-liver oil, iron, and other tonic measures are most frequently called for.

[1] Crocker, *Diseases of the Skin*, third edit., p. 452; Adamson, "Lichen Pilaris, seu Spinulosus," *Brit. Jour. Derm.*, Feb. and March, 1905 (with case illustration and histologic cuts), has recently given a full account and review of the disease, and the literature. As examples of lichen spinulosus to be found in French literature, he quotes the following: (1) possibly the acné cornée of Hardy; (2) certainly the acné cornée of Guibout and of Leloir and Vidal; (3) the case of acné cornée en aires of Hallopeau, possibly his 3 cases of acné cornée in adults; (4) Barbe's cases of kératose folliculaire (type de Brooke); (5) Audry's cases of kératose pilaire engainante; and in Italy (6) Giovannini's case of acne cornea. Histologically the lesions show that the pathologic process is essentially a hypekeratosis of the follicle; perifollicular inflammation is absent or, at any rate, very little marked. Lewandowsky, *Archiv*, 1905, vol. lxxiii., p. 343 (with histologic cuts), who describes a German case, believes it an inflammation of the follicle with a secondary parakeratosis; Bowen, *Jour. Cutan. Dis.*, 1906, p. 416 (report of a case; youth aged nineteen).

KERATOSIS FOLLICULARIS.

Synonyms.—Ichthyosis follicularis; Darier's disease; Psorospermosis; Psorospermose folliculaire végétante; Acné sébacée cornée; Ichthyosis sebacea cornea (E. Wilson).

This rare disease, of which but about 24 examples have been recorded, was first clearly described, and almost simultaneously, in 1889, by Darier[1] and Thibault in France, and by J. C. White[2] in our own country. Since then Boeck, Lustgarten, De Amicis, Bowen,[3] and others have reported cases.

The disease has been frequently noted to appear first upon the head and face. In the beginning the lesions do not vary much in color from that of the normal skin; they look not unlike those of keratosis pilaris, and may have, especially later, when more pronounced and increased in size, the appearance of greasy-looking papules, or dry, firm, brownish papular elevations, semiglobular in shape, and varying in size from a small to a large pin-head. They are at first discrete, and sparsely or thickly set. When closely examined, most of the lesions—those of any size—are observed to contain in the center a hardened or fatty-looking mass or plug. The disease extends slowly, and gradually invades other parts; finally, usually after several years or longer, it becomes more or less generalized, being, as a rule, most abundant and showing greatest development about the face, scalp, the chest anteriorly, the loins, genitocrural regions, and the extremities. Bowen has recently reported a case, however, in which it was limited to the head and hands. On the scalp there is usually a thick, seborrheic-looking coating, but no special hair loss. When at all developed or advanced, the lesions are noted to have grown larger, and in some places may become confluent, and present an irregular, papillomatous, or nutmeg-grater-like surface, with sometimes a fissured appearance or even distinct

[1] Darier and Thibault (2 cases), *Thèse de Paris*, 1889; *Annales*, July, 1889.

[2] J. C. White, *Jour. Cutan. Dis.*, 1889, p. 201 (1 case), and 1890, p. 13 (1 case), with, in each case, a histologic examination by Bowen. Morrow's case, published under this name (*Jour. Cutan. Dis.*, 1886, p. 257), seems histologically different from those now accepted as representing this malady, and more accords with the conditions found in keratosis follicularis contagiosa (Brooke).

[3] Bowen, *Jour. Cutan. Dis.*, 1896, p. 209, reports a case and gives a review of the subject; literature references are made to the other published cases by Boeck (5), Buzzi and Miethke, Bulkley and Lustgarten, Schwimmer, De Amicis, Schweninger and Buzzi, Pawloff (2), Fabry, Mourek, and Jarisch. It is upon this paper and that by White that the account of the disease here given is based—to some extent the same word description.

Since this date additional cases have been recorded by Hallopeau, *Annales*, 1896, p. 737, and pathologic anatomy of the same by Darier, *ibid.*, p. 742; Savill (case demonstration), *Brit. Jour. Derm.*, 1896, p. 229; Bowen (limited to head and hands), *Annales*, 1898, p. 6; Graham Little (case demonstration), *Brit. Jour. Derm.*, 1901, p. 51 and (histologic report) p. 98; Ehrmann, abstract in *Brit. Jour. Derm.*, 1902, p. 41; Ormerod and Macleod, *ibid.*, 1904, p. 32 (with histologic cuts, review, and complete bibliography); Lieberthal, *Jour. Amer. Med. Assoc.*, July 23, 1904, (good effects from *x*-ray treatment); Audrey and Dalous, *Jour. Mal. Cutan.*, 1904, vol. xvi., p. 801 (a woman aged forty-four, and of twelve years' duration; urine examination showed a diminution of sulphur); Sequeira, *Brit. Jour. Derm.*, 1905, p. 266 (case demonstration—woman aged forty-six, of eight years' duration); Malinowski, *Monatshefte*, 1906, vol. xliii., p. 209 (girl aged seventeen, began in first year; review with bibliography, and 4 histologic illustrations); Mook, *St. Louis Courier of Med.*, March, 1906 (good effects from *x*-ray treatment).

fissuring. They are noted to be of various sizes, some of them bearing resemblance to keratosis pilaris, some larger and containing the firm or fatty central concretion, and others—a smaller number—rounded or flattened, dull red to dark brown in color, and exhibiting no central opening, bearing a slight resemblance to lichen planus papules. Others, again, especially in the advanced stage, are quite hard and horn-like, of dark-gray or dark-brown color, hemispheric or conic, and projecting well above the surface. In places, if the

FIG. 113.—Keratosis follicularis. (The two cuts of this disease are of the same case).

disease is at all extensive, elevated areas are formed by confluence of the lesions, presenting uneven surfaces, covered by thick, yellowish or brownish, flattened, horny concretions. Less frequently are noted elongated horny masses, from $\frac{1}{4}$ to $\frac{1}{3}$ of an inch in diameter, and from $\frac{1}{8}$ to $\frac{1}{2}$ of an inch in height, of irregular outline, with blunt, truncated apices, yellowish in color, of dense consistence, and compactly crowded. They can be removed with difficulty, and then show bases of corresponding area, considerably elevated above the general surface, and hyperemic and moist. On some of these areas are found scattered smaller or larger crateriform openings, distended follicular openings, filled with firm concretions; occasionally some of

these underlying openings show ulceration, and the whole area is the seat of a mucopurulent discharge.

Close inspection shows that the greater part of the lesions are grouped about the follicular orifices—in other words, that the disease is essentially a follicular one, at least in its beginning; in some places, however, where the lesions are confluent and form the papillomatous, irregular, elevated areas, it can be seen that the process has invaded the interfollicular structures also. The subjective symptoms are variable—sometimes intense itching; in other cases, no troublesome features. The general health remains comparatively undisturbed. A rather weak mental condition has been noted in some cases. The skin is usually noted to be of an offensive odor—more particularly in extensive cases, and in those in which excoriations have been produced by scratching; the odor is more or less characteristic of decomposing epithelium (White) or sebaceous matter.

Etiology.—The age at which the affection begins seems to vary somewhat; in the larger number of cases, however, it occurred before the sixteenth year, and in several instances in infancy. Of the 24 patients, 15 were males and 9 females. The question of heredity and contagiousness has been considered; Boeck had 3 cases in one family, White's patients were father and daughter, and Ehrmann had a patient whose father had the same malady; with these exceptions, however, no other support for either of these possibilities is available. Darier believed he had discovered the cause in peculiar, coccidia-like bodies in the lesions, and hence suggested the name psorospermosis. This view obtained some credence and was seemingly supported by Wickham's investigations. Both observers thought them of etiologic significance not only in this disease, but also in molluscum contagiosum, Paget's disease, etc. In later studies, however, by Bowen, Buzzi, Miethke, Piffard, Boeck, and Darier himself these bodies were demonstrated to be due to cell transformation, and not psorosperms, as originally believed.

Pathology.—Darier's psorosperm theory of the origin of the disease having been abandoned, the view advanced by White and Bowen, and corroborated since by others, that the affection is evidently in all its phases a keratosis or modified cornification of the epithelial layers having its seat in the mouths of the pilosebaceous ducts, has been generally accepted. Bowen, who has had the opportunity of studying both of White's cases, 2 of his own, and also sections from Lustgarten's case, confirms Darier's conclusion as to the follicular character of the malady, although admitting that the process is not confined wholly to them, but is found also in their neighborhood. Boeck, on the contrary, cannot agree, from his investigations, that the lesions are in great part confined to the follicles. Ormerod and Macleod, from a study of their case and a review of the subject, conclude, that "it is a type of dyskeratosis associated with a peculiar cellular degeneration, which may affect any portion of the epidermis, and is frequently located at the upper third of the pilosebaceous follicle or the opening of the sweat ducts." The very

smallest lesions are histologically scarcely distinguishable from the papules of keratosis pilaris, although there are even then traces of the perverted process of cornification which characterizes the disease. The "corps ronds" and the "grains" described by Darier are interesting features. The former, which were thought to be psorosperms, as already remarked under etiology, are now known to be transformed cells; they are found especially in the deeper and middle rete layers, and at the base of the horny or greasy mass, and probably are, as Bowen states, epidermal cells that are enlarged and swollen, and made up of a nucleus, with usually a clear or hyaline protoplasm around it. The "grains" are probably cells from the bottom of the dilated, funnel-shaped openings below the follicle plugs, which have become cornified without passing through

FIG. 114.—Keratosis follicularis.

the keratohyalin stage. They are rounded, and somewhat polygonal, shrunken bodies, homogeneous, and with feebly differentiated nucleus.

As to be inferred, the anatomic changes in the disease are essentially epidermic—a parakeratosis as well as a hyperkeratosis. In addition to the evidences of keratosis there is at the periphery of the lesions a marked increase in the pigment in the normal rete cells. The corium presents but few changes of any significance—some enlargement of the papillæ at the sides of the lesions, and a moderate round-celled infiltration about the vessels.

Diagnosis.—In advanced stages the disease can scarcely be confounded with other dermatoses. In the earliest beginning the malady bears resemblance to keratosis pilaris, but its presence on unusual locations for this latter affection is a point of difference. Some of the lesions, especially those on the trunk, may also, early in the disease,

suggest lichen planus, but an inspection of the eruption, as a whole, would prevent error. At certain stages or in certain lesions the soft central plug will call to mind molluscum contagiosum; but this latter never has so wide a distribution, and its pearly-looking characters, and the contained mass with the so-called "molluscum bodies" are points of difference. Moreover, the opening of molluscum contagiosum lesions is small, that of keratosis follicularis is, when emptied, crateriform. In can scarcely be mistaken for pityriasis rubra pilaris or for ordinary cases of ichthyosis.

Prognosis and Treatment.—The disease is persistent, and usually slowly progressive, with periods of greater or less activity. The general health does not seem to be compromised, although toward advanced life one would expect to find beginning degenerative epithelial changes. No cure has been reported, but much can be done by treatment to render the disease less disgusting and disfiguring, and possibly to somewhat restrain its course. Frequent alkaline baths, as given in psoriasis, and the employment of stimulating and keratolytic applications, such as salicylic acid, resorcin, and sulphur ointments, are of decided benefit. Pyrogallol can also be used in ointment form, but only to limited areas at a time. Lieberthal's case and Mook's case showed improvement from *x*-ray treatment, and in a case now under my own care there has been also considerable change for the better.

Keratosis Follicularis Contagiosa.—Under this name Brooke[1] described a rare affection, apparently of contagious nature, occurring in children, and sporadically in adults, and characterized by an abnormal cornification. The first change in the affected parts consists of a slight, but visible, thickening of the horny layer, with an accentuation of the cutaneous furrows, and a yellowish to yellowish-black discoloration. Upon these areas are gradually noted several or more black points, later resembling comedo plugs, seated at the follicular outlets, and of which one or more develop into papular elevations from which project horny, straight or bent, spike-like formations of variable length. The regions usually invaded are the neck, trunk, extensor aspects of the extremities, and, less commonly, the face and flexor surfaces. The hyperkeratosis, according to Brooke and Unna, is not limited to the follicles alone, but extends superficially in their neighborhood and also slightly into the sweat-pores. Unna states that two main groups of changes are to be noted: (1) simple appearances of retention and (2) formation of horny plugs at the seat of the follicles. It is a dry, non-fatty affection. The process consists essentially of a hyperplasia of the epithelial cells. It is not improbable, as Unna suggests, that the more localized forms of so-called *acne sebacée cornée* of the French also represent this malady. This writer would include Morrow's case of keratosis follicularis in the same category, the histologic examination (Robinson) giving support to this opinion. The malady responds readily to simple softening and alkaline applications.

[1] Brooke, *International Atlas*, 1892, part vii., plate xxii.

PLATE XIX.

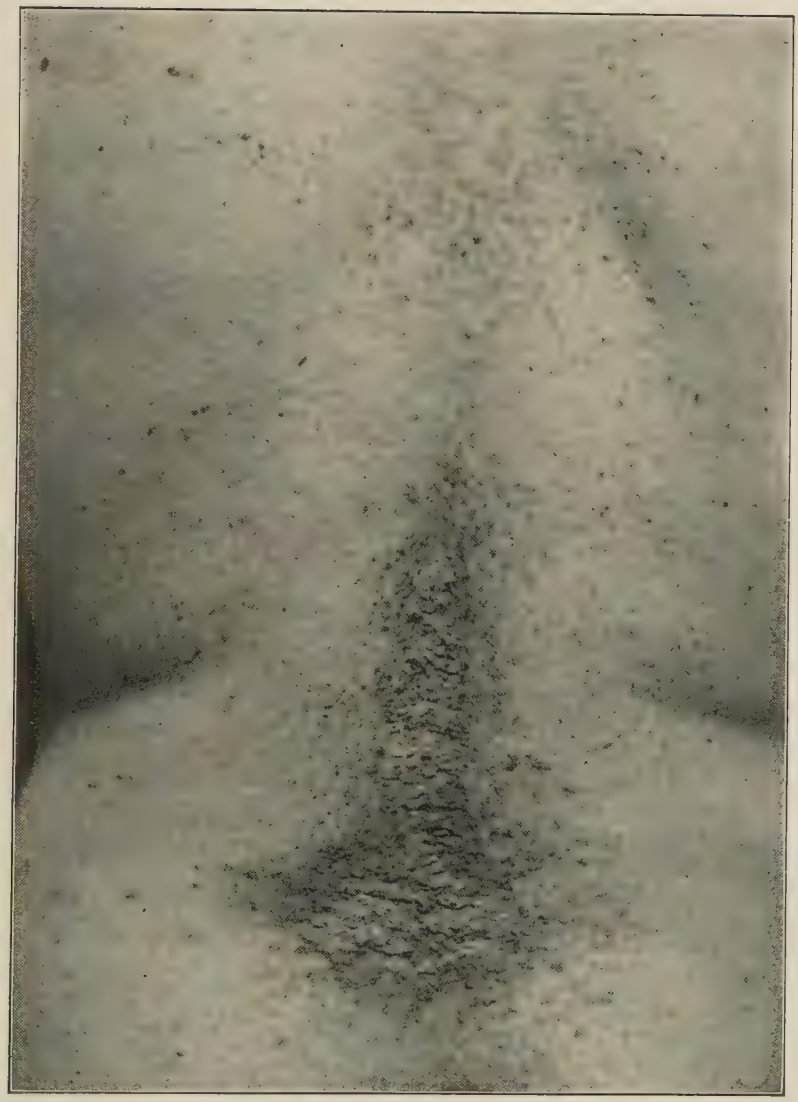

Keratosis follicularis in a male adult aged forty; of many years' duration. Some improvement under *x*-ray treatment.

VERRUCA.

Synonyms.—Wart; *Fr.*, Verrue; *Ger.*, Warze.

Definition.—Verruca, or wart, is a small, but somewhat variously sized, circumscribed epidermal and papillary growth, which may be soft or hard, and rounded, flat, acuminated, or filiform.

According to the shape and predominance of one of the several characters it is convenient to divide these formations into several clinical varieties: verruca vulgaris, verruca digitata, verruca plana, verruca filiformis, and verruca acuminata.

Verruca Vulgaris.—This is the common wart so frequently seen, and occurring mostly upon the hands. It is somewhat variable as to size, averaging that of a pea, and having a broad base. It is generally hard or horny, somewhat rounded or slightly flattened, elevated, and circumscribed. It is, as a rule, of slow and gradual growth, and at first is smooth and covered with slightly thickened epidermis, but later the smoothness usually disappears to a variable extent, and the surface becomes, partly in consequence of the hypertrophy of the papillæ, but chiefly of the rete proliferation, rough and irregular, with minute elevations. Sometimes the projections are sufficiently pronounced as to give it a slightly papillomatous appearance, and to give some cause for the name "papilloma," which has occasionally been used.[1] In its earliest formation the color may be that of the normal skin, but later it is grayish, with a slight or decided yellowish or brownish tinge; exceptionally it is almost black. On the average there are several present, but there may be but one, or they may be present in numbers. Not uncommonly one lesion appears,—the so-called "mother wart" (the verrue mére of Vidal),[2]—attains full growth, and several others or more gradually present, and usually close to the first or not far distant. Sometimes several are in such proximity that coalescence ensues, and a wart of relatively considerable size results. There are no subjective symptoms—no itching,[3] but, as with any other growths if irritated, they may become slightly painful when knocked.

While the fingers and hands are the usual sites of these lesions,

[1] The term "papilloma" was formerly used with a somewhat indefinite meaning and indiscriminate application, not only to warts, but to all growths with projecting excrescences or vegetations, which were then erroneously thought to be exclusively due to papillary hypertrophy, and hence the name. Observation has shown that this feature is only an accidental or occasional development, and, moreover, observed in various and often totally diverse diseases, and is, therefore, not descriptive of any special disease entity. For these reasons it is no longer to be considered a scientific term, and has been practically dropped, and given place to the employment of the proper disease title in each instance, with, to designate this particular clinical feature, the addition of the descriptive adjective papillomatous, or its equivalent, papillary, vegetating, verrucous, etc.—as, for example, the papillomatous or vegetating syphiloderm (syphiloderma papillomatosa seu vegetans), papillary or papillomatous epithelioma, lupus verrucosus, etc.

[2] Vidal, "Verrue mére—verrues filles," cited by Gémy, *Annales*, 1889, p. 94.

[3] Corlett, *Jour. Cutan. Dis.*, 1896, p. 301 (with illustration), reports a case of somewhat doubtful nature in which numerous lesions of a warty character were on the legs, and in which there was a good deal of itching.

they are also occasionally found upon other parts, and Dubreuilh[1] and other writers[2] have called attention to the fact that they are sometimes observed on the feet, especially the soles (**verruca plantaris, papilloma of the sole**), where at times, from friction and pressure, the covering and surrounding horny layer are much thickened, smooth, and hard, forming a "wart-containing callosity," so that they are usually mistaken for corns; upon shaving off the surface the wart-like character is disclosed, and in such operation bleeding is very readily produced. This plantar wart is not an infrequent one in my experience, and is usually painful and troublesome.[3] The scalp may also be the seat of the common wart, although in this region the digitate variety is the usual one. Exceptionally the growths are found on the vermilion of the lips—on both lips in a case observed by Elliot.[4] In Gémy's[5] case not only were the lesions present in great numbers, but the legs were the principal seat.

Verruca plana, or the flat wart, is a name more especially used for those pea- to finger-nail-sized growths, usually but slightly or moderately elevated, and observed most commonly on the back and face of middle-aged and elderly people, although they may also occasionally be seen in this form in younger individuals. In older people, however, they are usually of a darker color, and not infrequently after a time become slightly papillomatous and covered with a rough, dark, often blackish, somewhat greasy scale, constituting the formations also variously known as keratosis pigmentosa, verruca senilis, seborrheic wart (verruca seborrhœica), quite frequently seen associated with other degenerative changes in the skin (see old age of the skin). There is sometimes slight or moderate itching. They possess a close analogy at times to dark, slightly elevated moles, and could be often clinically well described by the term "warty mole." There may be one, several, or more present, and usually scattered. In some instances, sooner or later, there is a tendency to development into epithelioma.

Under verruca plana can also be most conveniently considered a totally different variety of warts, both as to the age of those affected and their clinical characters, known as **verruca plana juvenilis,** and which has attracted notice in more recent years through the contributions of Thin,[6] Darier,[7] Besnier,[8] Herxheimer and Marx,[9] and others

[1] Dubreuilh, "De la verrue plantaire," *Annales*, 1895, p. 441; also review of this paper by Bowen, *Boston Med. and Surg. Jour.*, vol. cxxxv., 1896, p. 262.

[2] Eddowes, "Warts on the Feet," *Brit. Jour. Derm.*, 1896, p. 195; also "Corns, True and So-Called," *Brit. Med. Jour.*, Dec. 21, 1895. D. W. Montgomery, *Jour. Amer. Med. Assoc.*, July 11, 1903.

[3] Hardaway and Allison, *Jour. Cutan. Dis.*, 1906, p. 127, express the opinion that these growths, as well as callosities, and hyperidrosis of this part are more common in those having malpositions of the feet, especially flat-foot and Morton's foot.

[4] Elliot, *Jour. Cutan. Dis.*, 1889, p. 306 (case demonstration).

[5] Gémy, "Verrues confluentes des deux jambes," *Annales*, 1889, p. 94.

[6] Thin, "An Unusual Case of Warty Growths on the Face," *London Med.-Chir. Soc'y Trans.*, vol. lxiv., 1881, p. 283 (with case illustration (colored plate) and two histologic cuts).

[7] Darier, "Verrues planes juveniles de la face," *Annales*, 1888, p. 617.

[8] Besnier-Doyon, French translation of Kaposi's work; also *Annales*, 1889, pp. 22 and 200 (in discussion).

[9] Herxheimer and Marx, "Zur Kenntniss der Verrucæ planæ juveniles," *Münchener med. Wochenschr.*, 1894, p. 591 (a report of 29 cases, with review of subject and references).

Their sole feature possessed in common with the ordinary verruca plana just described is the flat character, in other respects being wholly dissimilar. They are somewhat peculiar, lichen-planus-looking warts, with roundish, squarish, or polygonal base, with a flat and smooth surface, rarely larger than a small French pea, and usually much smaller, and generally seated upon the face, where they may exist in moderate or great number. Occasionally in some lesions a scarcely perceptible central depression can be detected. They are normal skin color or grayish or brownish; are discrete or aggregated, and when several or more are close together, coalescence sometimes takes place, resulting in a small, irregular shaped, occasionally somewhat linear, patch. Their elevation is usually slight, with some lesions scarcely appreciable. While all are almost always perfectly flat, occasionally a few will show, especially in their earliest existence,

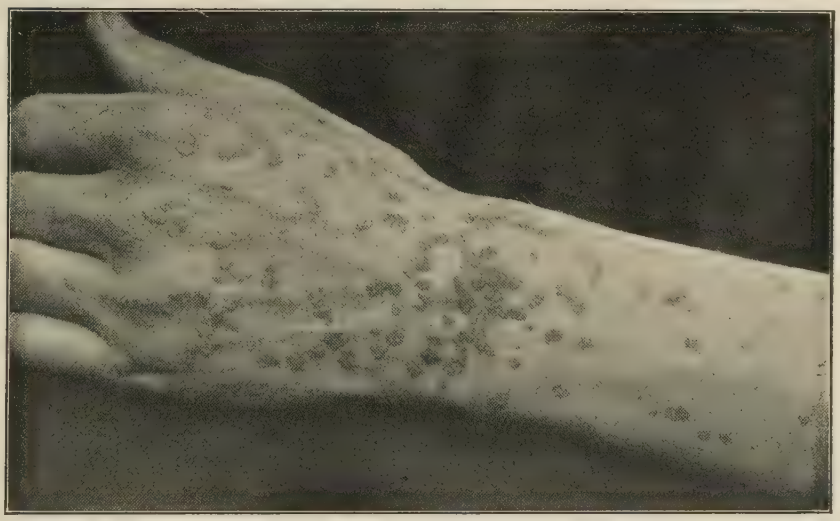

FIG. 115.—Verruca of the juvenile flat variety in a young adult was also on face and forehead. There were some lesions, however, showing a tendency to develop into the verruca vulgaris type.

a slightly rounded top. The chin, lower part of the cheeks, and the forehead, more particularly, as a rule, toward the temporal region and the hair border, are the favorite situations. They are seen in children, frequently in those quite young, but are also observed in youth and early adult age. They are generally slow and insidious in their coming, and are persistent, lasting often for months and years, but unattended by subjective symptoms.

Verruca Digitata.—This is a variety of wart more commonly observed upon the scalp, and which is characterized by clefts or digitations extending sometimes nearly or quite down to the base. This feature may involve the whole body of the growth, but it

is always most marked at the peripheral portion. The wart may arise as such, being practically of this nature almost from the start, or it may appear at first as an ordinary wart, but as it grows, the epidermic covering seems to extend down between the projecting and enlarging papillæ, while the latter grow upward, and clefting results. When the digitations do not extend completely to the base, the lower part, or neck, is sometimes relatively much smaller or apparently constricted, and the growth has then a pedunculated appearance, the upper cleft part tending to spread out some. The surface is hard and horny, the lower portion somewhat soft. If at all forcibly disturbed, they are apt to bleed—much more readily than common warts. In size they vary from that of a small pea to a dime, and are elevated from one to several lines. Their color is usually that of other warts. But one or several may be present; quite frequently somewhat aggregated, sometimes sufficiently so to form a coalescent group.

Verucca Filiformis.—This is a thread-like growth, most commonly seated about the neck, face, and eyelids. It is of varying length, from that of a line to $\frac{1}{4}$ of an inch or longer, and from scarcely more than a thick thread to a line in diameter, apparently depending upon whether one or several papillæ are hypertrophied. It is, as a rule, soft to the touch, and quite flexible, with a narrowed conic or pointed end. It occurs more frequently as a single formation, although occasionally several are to be seen scattered or more or less closely grouped.

Verucca Acuminata (Synonyms: Condyloma acuminata; Venereal wart; Moist wart; Pointed wart; Pointed condyloma; Condyloma acuminatum; Fig-wart; Cauliflower excrescence; *Fr.*, Végétation dermique; *Ger.*, Spitzencondylom; Spitzenwarze; Venerische Papillome; Venerische Warze; Feigwarze).—This variety usually occurs on the mucous and mucocutaneous surfaces of the genital and anal regions, although also sometimes on the adjoining integument and in the flexures and on other parts.[1] As they usually result from irritating discharges, they are most common on the genitalia and genitocrural regions, and in association with venereal diseases. The formations are either single or multiple, scanty or abundant, pointed, tufted, club-shaped, and sessile or pedunculated. They have a bright pinkish or reddish color, sometimes with a purplish tone. In some cases they have the general features and color of a cock's-comb. In other instances instead of projecting vegetations they have more the appearance of thick hypertrophic and superabundant granulation tissue. In the mildest examples they consist of one or more groups or bunches of acuminated, pinkish or reddish, raspberry-like elevations. In extreme cases the warts make up irregular, cauliflower-like masses which cover the entire region and project to considerable elevation. According to the region, they may be somewhat dry or moist; and if

[1] Heidingsfeld (Condyloma Acuminata Linguæ), *Jour. Cutan. Dis.*, 1901, p. 226 (with histologic cuts), reports an instance in which, in addition to lesions on the labia majora, there were some similar warts on the tongue; and also reviews the subject of extragenital verruca acuminata (with references).

the latter, the secretion, which results from maceration due to the natural heat and friction of the parts, is usually abundant, of a yellowish color and puriform, and develops, from rapid decomposition, an offensive and penetrating odor. As the excrescences bleed easily, the secretion is sometimes tinged with blood. In some cases the discharge dries and forms thickish, reddish-yellow or brownish crusts, sometimes tough and almost horny, beneath which the partly pent-up secretion undergoes rapid decomposition.

Their most common starting-points in the male are on the glans and in the sulcus and from the inner side of the prepuce; and in the female in about the clitoris, inner side of the labia, and from the vagina. The anus may also be the site, and the condition may remain so limited, but more commonly it appears here secondarily to the eruption on the genitalia, especially in women. It may exceptionally also present upon other regions, as about the axillæ, umbilicus, mouth, and between the toes. On integumentary sites where there is not much or no friction or excessive natural sweat secretion they are much drier, occasionally free from discharge, and their color, at first at least, is not materially different from the normal skin, but later becomes purplish and reddish. Their development is commonly quite rapid, although sometimes, after attaining variable dimensions, they may remain more or less stationary. In many cases, however, there is a disposition to increase and extend, as the secretion is auto-inoculable. The malady is, in fact, contagious. If undisturbed, there is usually no tendency to spontaneous disappearance.

Etiology.—Warts are more common in childhood, in adolescents, and in early adult life. There is a more or less general tacit acceptance of mild contagiousness, and of the correctness of which I feel pretty well convinced. Observations in many instances of suggestive cases of auto-inoculation support such a view. The quite frequent development of others from a primary or mother wart, to which Vidal directed attention and which many others have noted, its spread by contiguity, as, for example, occasionally around the ungual borders, observed by Morrow, Allen, Bronson,[1] and others, its spread from one child or member to another of a family, as not infrequently observed, of which Vivès[2] recently reported an instance, are all suggestive. A short time ago a gentleman was under my care with some warts on the hand, who stated that his fiancée had also subsequently presented several similar growths. Payne[3] relates how in a case he thoughtlessly used his own thumb-nail to scrape off a wart previously softened by an application, and that some time later a similar formation developed at this site (under the edge of the nail), with subsequently two more on the thumb higher up. These are a few examples to which many similar ones could be added.

[1] Morrow, Allen, Bronson, *Jour. Cutan. Dis.*, 1899, p. 183 (case demonstration and discussion).

[2] Vivès, "Verrues de Famille," *Jour. mal. cutan.*, 1899, p. 463 (3 members, one after another).

[3] Payne, "On the Contagiousness of Common Warts," *Brit. Jour. Derm.*, 1891, p. 184.

In fact, the clinical evidence is more than suggestive, and to this we can now add the favorable inoculation experiments by Jadassohn, Variot, Lanz, and one or two others.[1] Lanz's experiment was convincing to him, although unsuccessful on the patient upon whom he was experimenting; his patient had warts on one hand and forearm, and a small portion of the growth was superficially implanted on the arms, with negative result. He then tried rubbing across the large or mother wart on the forearm on to the neighboring skin once or twice daily for several days, using his first and second fingers, with no result on the patient, but some time afterward three lesions developed on the rubbing surface of his own fingers. The inoculations by the others named were on an extensive scale and seemingly conclusive. The incubation period is of long duration—from over one month up to seven or eight, although probably, in favoring locations, as in Payne's case, a much shorter period suffices. Jadassohn's experiments furthermore apparently indicate, although not sufficiently positively, that the juvenile flat wart produces its like, as does likewise an ordinary wart, and therefore of different etiology. There is still wanting confirmatory proof of microorganisms, Kühnemann,[2] I believe, being the only one who has discovered a microbe (a bacillus) of seeming pathogenic importance, and with which he succeeded in producing suggestive lesions experimentally on rabbits. The influence of slight traumatism, excoriations, pressure, and the like, which were formerly considered as active causative factors, is now recognized as contributory toward furnishing favorable opportunities for successful inoculation. Schaal[3] and others, however, are firm in the opinion that local irritation—implantation of some minute foreign body, according to Schaal—gives rise to hypertrophy of the connective tissue and papillæ, and thus produces the wart. Both Fox and Allen,[4] and also myself, have noted cases in which both molluscum contagiosum and warts were present, and Fox is inclined to believe that there may be a common cause or close connection. Such conclusion, it seems to me, is scarcely warrantable when one considers the frequency of warts among the poorer children, and with which cutaneous diseases other than molluscum contagiosum could be found just as or more frequently associated, and yet no question of relationship arise.

As to verruca acuminata, it is more than probable that this is an entirely distinct affection etiologically from the other forms. With

[1] Jadassohn, "Sind die Verrucæ Vulgares überträgbar?" *Verhandl. der V. Deutschen Dermatolog. Gesellsch.* (1895), 1896, p. 497 (with review of the subject with references; of 74 inoculations, made at different times, on 6 different persons, 31 were successful); Variot, "Un cas l'inoculation expérimentale des verrues de l'enfant a l'homme," *Jour. de Clinique et de thérap. infant*, 1894, No. 34, p. 529; Lanz, "Ein Beitrag zur Frage der Ueberträgbarkeit von Warzen," *Correspondenzbl. f. Schweizer Aerzte*, 1898, p. 264.

[2] Kühnemann, "Zur Bacteriologie der Verruca Vulgaris," *Monatshefte*, 1889, vol. ix., p. 17; Schweninger stated (*ibid.*, p. 380) that the culture-inoculations made by Kühnemann had been apparently successful in rabbits.

[3] Schaal, "Zur Aetiologie der Hautwarzen," *Archiv*, 1896, vol. xxxv., p. 207 (the accidental implantation of minute specks of glass gave rise to warts on his own hand).

[4] Fox, *Trans. Amer. Derm. Assoc. for 1888*, p. 50 (discussion); Allen, "Molluscum Contagiosum—an Analysis of 50 Cases," *Jour. Cutan. Dis.*, 1886, p. 238.

these, irritating secretions are unquestionably of etiologic importance. These warts and their secretions are doubtless contagious and autoinoculable. Ducrey and Oro[1] found in the secretion, in the growth and tissues, in addition to the staphylococcus pyogenes aureus and bacillus subtilis, two colonies of unknown micro-organisms, but experiments with these latter on animals and man failed to produce any result.

Pathology.—From what has already been stated in discussing etiology, it would seem highly probable that the initial factor in the formation of a wart is a local irritation, and it is not unlikely that, in most instances at least, this irritant is a microbic one. The organism doubtless gains entrance, as Kühnemann suggests, through some small break or fissure in the epidermis.

While anatomically (Bärensprung, Virchow, Auspitz, Unna, Kühnemann, and others)[2] there are some slight differences in the several varieties, there is primarily a connective-tissue growth or central prolongation common to all, and the interior of which contains one or more vascular loops; and to this are added varying degrees of epidermic and papillary hypertrophy. In many the hypertrophy of the papillæ is more apparent than real, due to their elongation and thinning by the epithelial growth; in others there are fewer than normal, some being flattened down by the proliferating rete. Both Auspitz and Unna, as well also as Kühnemann, state that the process starts in the rete and that the enlargement of the papillæ is due, in fact, to the proliferation and downgrowth of the former, and that the vascular and other changes in the corium are purely secondary. The proliferation of the rete, which, as Kühnemann especially contends, extends upward as well as downward, brings about some changes in the upper epidermal layers, the horny layer in the ordinary wart being usually markedly hypertrophied. Owing, however, to defective or modified action in the process of keratinization, the thickened horny layer is scarcely so dense or closely packed as normally, the nuclei, according to Kühnemann, still being susceptible of staining. The histology of the peculiar small flat warts of children and young adults (verruca plana juvenilis), according to the studies of Thin, Kühnemann, Herxheimer, Jadassohn, Dubreuilh, and Darier, is, with the exception of some minor differences, essentially that of the beginning verruca vulgaris, although both Darier and Dubreuilh noted a slight preceding exfoliation due to breakage and separation of the horny layers not observed in other warts.

The anatomy of the seborrheic wart—the verruca plana of old people—has been studied by Neumann, Balzer, Handford, and Pollitzer,[3] whose findings are somewhat divergent. Pollitzer's investi-

[1] Ducrey and Oro (The Pathology of Condyloma Acuminatum), Naples, 1893—abs. in *Brit. Jour. Derm.*, 1894, p. 158.

[2] Kühnemann, "Beiträge zur Anatomie und Histologie der Verruca vulgaris," *Monatshefte*, 1889, vol. viii., p. 341 (with two histologic plates, review of the subject, and bibliography); Unna, *Histopathology*, p. 786.

[3] Pollitzer, "The Seborrheic Wart," *Brit. Jour. Derm.*, 1890, p. 199 (with two histologic cuts, and abstract of opinions of Neumann, Balzer, and Handford—with references).

gations are the most recent and based upon material from 3 cases, and led to the following conclusion: "The seborrheic wart is characterized histologically by a slightly thickened stratum corneum, a considerably hypertrophied rete, and in the papillary and subpapillary cells, the occurrence of epithelioid cells arranged in groups and lines, separated by bundles of connective tissue, and terminating abruptly below the horizontal subpapillary plexus of vessels; together with a peculiar infiltration of fat, affecting the coil-gland epithelium, the middle and papillary layers of the cutis, and epithelium of the rete; and perhaps an atrophy of the sebaceous glands and hair-follicles." The crust, more commonly found in those who make little use of the bath, or more pronounced in such cases, consists of fatty epidermic scales and foreign matter, wool-fibers, particles of carbon, etc., often firmly attached and dipping down into the follicles.

In verruca acuminata, made up largely of connective-tissue elements, are to be found marked papillary enlargement, excessive development of the rete, and an abundant vascular supply. The process differs from the other warts in the absence of any special increase or modification changes in keratinization (Unna, Kühnemann); in fact, the horny layer is often almost or completely wanting. The most striking and characteristic feature is the exuberant proliferation of the rete. The connective-tissue framework contains large blood-vessels and lymphatics.

Diagnosis.—The characters of ordinary warts are so well known and they are so unlike other lesions that a mistake can scarcely occur. The somewhat rounded warts, with but little epidermic thickening, might, in their beginning, be confused with the starting lesions of molluscum contagiosum, but the central depression and aperture of the latter, usually recognizable by the naked eye, certainly by a magnifying-glass, would prevent mistakes; moreover, the face is their common site, while verruca vulgaris is usually seated upon the hands. The plantar wart differs from a callosity by its painfulness on pressure; by cutting or shaving off the overlying callous the wart is readily recognized, and it can thus be also distinguished from a corn, with which it is often confounded. The small flat wart (verruca plana juvenilis) is suggestive of lichen planus, but the latter rarely occurs on the face, except in very generalized cases, and then to a relatively slight extent, whereas this is the usual place for the small flat wart; and when the latter is also upon the back of the hands and fingers, they are generally more numerous on the face. Moreover, the lichen planus papules are usually larger, of a darker, violaceous color, are itchy, and tend to run together and become rough, scaly, and then show a good deal of infiltration, features not observed in small flat warts. Care should be taken not to confound this juvenile flat wart, or the common wart, with the rare affections angiokeratoma and xanthoma, more especially xanthoma multiplex and diabeticorum. The ordinary flat wart, or seborrheic wart, of advancing years is usually upon the back, sometimes on the neck, and is, as a rule, quite greasy or crusted, and of yellowish or blackish color, and can scarcely be confounded with any other lesion. The raspberry or mushroom-like character of verruca acuminata, and the

localities affected, are sufficient usually to prevent error with other lesions; they should not be confounded with the flat moist papules of syphilis, which also occur about the same parts.

Prognosis.—Warts, as commonly met with, have no significance beyond disfigurement, being benign in character. The seborrheic wart, as already stated, occasionally shows epitheliomatous development. This wart exhibits no tendency to disappearance; all the others do, although they may last sometimes almost indefinitely. Verruca acuminata, however, is usually persistent, unless measures are taken for its removal, although under the institution of rigorous cleanliness the warts will frequently disappear without treatment. All these different varieties are usually readily remediable, occasionally, especially the plantar wart, requiring, however, persistent treatment, and sometimes operative measures.

Treatment.[1]—The therapeutic management of verruca upon which most reliance is to be placed consists of external treatment of an antiseptic, caustic, or operative nature. It cannot be gainsaid, however, that there is substantial evidence that a variable influence can be exerted by certain remedies administered internally, more especially to be advised in those instances in which numerous lesions are present. The curative action of arsenic is well attested by the favorable experience of a number of observers, among whom are Sympson,[2] Pullin,[3] Herxheimer and Marx (*loc. cit.*), Thin (*loc. cit.*), Hallopeau and Leredde,[4] and many others. My own experience is confirmatory. It is to be given in moderate dosage, $\frac{1}{4}$ of a minim (0.016) or more to children, and 2 to 5 minims (0.135–0.335) to adults, three times daily. In recent years magnesium sulphate has been commended by Colrat,[5] and its good effects in some cases corroborated by Crocker,[6] Brocq,[7] and Hall,[8] although many, notably among whom Besnier and Bowen,[9] have failed to see any influence. The results were negative in several cases under my own care. It is given three times a day, in dose of 1 to 20 grains (0.065–1.35) or so, according to age. Crocker (*loc. cit.*) states also that in some instances full doses of nitromuriatic acid had seemed to be of service.

Whatever may be the differences of opinion as to the value of internal medication, there is, of course, unanimity as to the effectiveness of local treatment. One of the best methods of treating warts, more especially when but one or several are present, is by means of electrolysis, as originally suggested by Hardaway. The growth is almost wholly or completely transfixed with the needle attached to

[1] Except when otherwise stated, the remarks apply to the several varieties, except the seborrheic wart and verruca acuminata.

[2] Sympson, "Note on the Treatment of Warts by the Internal Administration of Arsenic," *Quarterly Med. Jour.*, vol. ii., 1893–94, p. 57.

[3] Pullin, "The Treatment of Warts by the Internal Administration of Arsenic," *Bristol Med. Jour.*, 1887, p. 269.

[4] Hallopeau and Leredde, *Dermatologie*, 1900, p. 409.

[5] Colrat, *Lyon Médicale*, vol. liii., 1886, p. 45 (soc'y communication).

[6] Crocker, *Diseases of the Skin*, third edit., p. 580.

[7] Brocq, *Traitement des Maladies de la Peau*, second edit., p. 852.

[8] Hall, *Brit. Jour. Derm.*, 1904, p. 264. Both Watson (*Brit. Jour. Derm.*, 1903, p. 178), and Hall (*ibid.*, 1906, p. 106), are inclined to believe that the purgative action of this or other drug is the factor of importance.

[9] Bowen, *Twentieth Century Practice*, vol. v. (Diseases of the Skin), p. 637.

the negative cord, and the wet positive electrode grasped by the hand or applied near by; the current is allowed to act for thirty seconds to one or two minutes, according to the size of the growth and the strength of the current—the latter varying from 1 to 4 or 5 milliampères. If the growth is hard, large, and old, the needle should be withdrawn and reintroduced, crossing the first insertion. In small lesions, and also in large growths, one to several introductions from the top, instead of transfixing, will also usually be successful. The wart either gradually shrivels away, or some irritation and crusting ensue, which finally drop off, leaving occasionally a slight but scarcely perceptible scar. The method does not seem to be so satisfactory for warts on the anterior aspect of the finger-bulbs, where they are usually surrounded with calloused and thickened epidermis, the operation here sometimes producing considerable underlying irritation and swelling.

Various applications are also used and are often quickly effective; paring, scraping, or sand-papering down of the lesion, except when the epidermic thickening is insignificant, is usually a valuable preliminary. I am in the habit, when the growths are at all numerous, of prescribing frequently a saturated alcoholic solution of salicylic acid, with which the warts are moistened once or twice daily, removing the softened warty coating thus resulting from time to time. The same remedy is also often used in collodion, 10 to 20 per cent. strength. If the latter is employed, two or three coatings should be made night and morning for a few days, and then, after the film loosens or cracks, as it commonly does in a day or two, the parts are soaked in hot water, and the pellicle and softened horny layer are rubbed off, sometimes using with advantage pumice-stone or scraping with a curet. The salicylic acid plan, which is, of course, a mild one, is slow, and often not completely successful. Paring or sand-papering the growth, combined with cauterization with silver nitrate, and repeating every several days, is another mild, and often efficient, though somewhat slow, method. Lactic acid applied scantily one to several times daily also acts in some cases efficiently and without much irritation, the softened surface being rubbed or scraped away from time to time. Other applications resorted to are formalin,[1] glacial acetic acid, acid nitrate of mercury, and nitric acid; chromic acid, caustic potash, and chlorid of zinc are also valuable, but are strong and destructive and must be used with care. The application of high-frequency current, by means of the carbon or glass-point electrode, has been lately lauded.[2] The constant wearing of a rubber covering—acting by its macerating action—has also been commended.[3]

For the plantar corn-like wart I have usually employed the following plan: The calloused covering is first removed by paring or by a few days' application of salicylic acid plaster, and then the outer surface of the uncovered wart gently scraped or curetted away, and the cavity filled with salicylic acid and over this painted several coat-

[1] Engman, "The Nature of Some Epithelial Growths and Their Treatment with Formalin," *Medical Review*, vol. xli., 1900, p. 405.

[2] Bulkley, *Amer. Medicine*, Nov. 19, 1904, p. 882.

[3] Purdon, "Note on Verruca or Warts," *Dublin Jour. Med. Sci.*, vol. cviii., 1899, p. 99.

ings of an 8 per cent. salicylated collodion; this must usually be repeated one to three times at intervals of several days or a week. In obstinate cases it is necessary, under cocain anesthesia, to curet more energetically and follow with a cautious application of caustic potash, or, as Eddowes recommends, with acid nitrate of mercury or the galvano cautery. Fitz[1] found for foot warts, as well as the growth on other parts, which had failed to respond to the salicylic acid treatment, successful results from daily, or twice daily, applications of a 10 per cent. solution of chrysarobin in liquor gutta-perchæ or in ether; previous to the application the part is to be pared or sand-papered. Hardaway and Allison believe the correction of any existing foot malposition is helpful and sometimes curative.

The pedunculated and filiform warts can be readily snipped off with the curved scissors, and the base touched with silver nitrate. This method can also be used with the ordinary warts. I have found a good plan in the scalp warts, usually the digitate variety, is gently to curet and touch the base with pure carbolic acid or silver nitrate.

The small flat warts can be treated with repeated applications of carbolic acid applied with a pointed match-stick or wooden tooth-pick, or the milder applications already referred to can be employed. If electrolysis is used, the needle is introduced superficially from the top, and, as a rule, a mild current employed. In these cases, in which the lesions are usually numerous and sometimes close together, I have seen benefit from the use of a 5 to 10 per cent. sulphur or calomel ointment, rubbed in in small quantity twice daily; also from a saturated solution of boric acid with 2 to 10 or 15 grains (0.135–1.) of resorcin to the ounce (32.) (Davis); and from Vleminckx's solution. Arsenic was at the same time given internally.

The seborrheic wart is to be treated by frequent soap-and-water washing and the rubbing in of a mild sulphur-salicylic acid ointment, composed of 20 to 100 grains (1.35–6.65) of precipitated sulphur, 10 to 60 grains (0.65–4.) of salicylic acid, and 1 ounce (32.) of ointment base, consisting of petrolatum or equal parts of petrolatum and lard. If there is a thick or hardened horny layer or crust, the salicylic acid collodion, already referred to, can be at first employed. Ordinarily treatment well followed out can keep the growth down to clean plain flat warts, and prevent the tendency to epitheliomatous degeneration displayed in some lesions. If it is desired to remove the growth completely, the stronger caustics named can be used, first, however, trying the salicylic acid collodion, and a strong, 20 to 40 per cent. salicylic acid plaster-mull or rubber plaster.

In the management of verruca acuminata the maintenance of cleanliness is absolutely essential. The parts should therefore be cleansed at least twice daily by the ordinary washing methods, or, if numerous and crowded, by free irrigation, and subsequently the bountiful use of powdered boric acid, to which, in some instances, 1 to 10 per cent. of alum can be added with advantage. Powdered alum alone is also sometimes employed. A 5 to 10 per cent. solution of salicylic acid in equal parts alcohol and water will prove curative in some instances. Painting the parts with solution of sub-

[1] Fitz, *Boston Med. and Surg. Jour.*, June 29, 1899.

acetate of lead, pure or weakened, has also been used. If these milder measures are unsuccessful, stronger remedies must be resorted to, such as the careful applications of glacial acetic acid or chromic or nitric acid, tried in the order named.

CORNU CUTANEUM.

Synonyms.—Cornu humanum ; Cutaneous horn ; Horny excrescence ; Horny tumor ; *Fr.*, Corne cutanée ; Corne de la peau ; *Ger.*, Hauthorn ; Hornauswuchs.

Definition.—Cornu cutaneum is a true horny cutaneous outgrowth varying in size and shape.

Symptoms.—Horns are rarely met with in human beings, and may be classed as dermatologic oddities. Although resembling animal horns closely, their anatomic structure differs in not containing bone and in having a cutaneous attachment, and therefore more or less movable, whereas the former are located upon an osseous base. They show a preference for the hairy scalp and for the face, occurring occasionally elsewhere, as on the trunk, cheeks, eyelids, glans, scrotum, and extremities, no part of the body, however, being exempt. Occurring on the penis, they not uncommonly develop from acuminated warts, as in the remarkable cases recorded by Pick [1] and by Brinton.[2] While generally solitary, they may be multiple, and may occur in quite large numbers, as in a case reported by Bätge,[3] in which the whole lower part of the body was studded

FIG. 116.—Cutaneous horns, showing beginning epitheliomatous degeneration of the base (after Pancoast).

[1] Pick, *Archiv*, 1875, p. 315 (with two colored plates ; also refers to 9 other cases).

[2] Brinton, *Medical News*, Aug. 6, 1887 (with a résumé of 15 other cases) ; Gould, *London Pathol. Soc'y Trans.*, 1887, vol. xxxviii., p. 355, also records a case, associated with epithelioma.

[3] Bätge, *Deutsche Zeitschrift für Chirurg.*, vol. vi., 1876, p. 474 (also records another case having 6 upon the face, with illustrations and references to other cases).

with these growths, although, with the exception of 2, all were of small size. Their appearance is usually slow and insidious, although exceptionally somewhat rapid; in their earliest formation there is a resemblance to a hard wart, and they may, in fact, begin as a simple verrucous growth. Their size and shape are also subject to variations; thus they may be only large pin-head in size, and again they may measure several or more inches in length; the unusual length of 12 inches has been recorded. Their diameter varies from $\frac{1}{8}$ of an inch to 4 or 5 inches, and is greater at the base than at the extremity. Rodriguez's extraordinary case, quoted by Crocker, growing on the side of the head, was 14 inches around at the base. Porcher[1] also observed a similar case, on the side of the scalp, the horn being, however, much smaller.

In appearance they are solid, rough, wrinkled, and laminated and round, angular, pointed, straight, or twisted. They show different shades of color, as gray, yellow, brown, or black. The base is concave or flattened and is seated directly upon and in the skin; the neighboring integument may be normal or inflammatory in appearance, and sometimes inflammatory action is followed by suppuration, and the horn may be cast off. As a rule, their growth is slow and they do not give rise to subjective symptoms unless they are injured by traumatism or torn off, in which case the base presents an ulcerating surface, which may again become the seat of a horn. After reaching a variable size they may remain stationary; or, when having reached a certain length, they may grow loose and finally drop off, usually preceded, however, by a localized degenerative process, which is left behind and commonly develops into epithelioma. According to Lebert, 12 per cent. of the cases have an epitheliomatous termination. This development in its early stages is shown in the accompanying case (Pancoast),[2] and another example of this tendency is shown in Gould's patient.

Etiology and Pathology.—We are lacking in positive knowledge as to the exciting causes. Although usually occurring after forty years of age, they have been observed in the very young; they are somewhat more frequent in females than in males. The growth is rare, although quite a number of cases are now on record.[3] It is not improbable that isolated instances of limited ichthyosis hystrix and keratosis follicularis may have been included. They may have their starting-point in cutaneous injuries or lesions, such as sebaceous cysts, scars, warts, and other keratoses.

Horns bear a close resemblance to warts: are, in fact, hypertrophic horny warts. They arise usually from the deeper layers of the stratum mucosum, either from that lying above the papillæ or from that lining the follicles and glands; and are to be attributed to

[1] Porcher, *Charleston Med. Jour. and Rev.*, 1855, p. 333 (with résumé of other cases of cutaneous horn and references).

[2] Pancoast, *Photog. Review of Med. and Surg.*, 1870–71, vol. i., p. 3.

[3] Wilson, *Med.-Chir. Trans.*, 1844, vol. xxvii., p. 52, and *Dis. of the Skin*, sixth edit., p. 796, gives a summary of 90 cases and references; Bergh, "Fälle von Hauthörnern," *Archiv*, 1873, p. 185; Lebert, *Ueber Keratose*, Breslau, 1864 (a collection of 109 cases); Hessberg, *Beitrag zur Kenntniss der Hauthörner von Menschen und Thieren*, Dissertation, Göttingen, 1868, adds 25 to Lebert's list.

a pathologic hypertrophic and cornified condition of the epidermic cells, the earliest stage of their formation consisting, according to Unna, in a simultaneous acanthosis and hyperkeratosis. The papillæ are hypertrophied, and the growth is situated on the papillæ, and not infrequently groups of greatly enlarged papillæ extending some distance into the horny mass have been observed. The base is surrounded by telangiectatic blood-vessels, which sometimes ramify into



FIG. 117.—Small beginning cutaneous horn, × about 20; showing broadened base extending down into the corium and the projecting rounded summit (courtesy of Dr. B. H. Buxton).

the horn substance. The horny formation itself consists essentially of agglutinated epidermic cells, forming small columns or rods; in the columns themselves the cells are arranged concentrically.

Treatment.—The growth, as a rule, does not show a tendency to recur if thoroughly removed. It must not be overlooked that, if neglected, epithelioma may develop. Quite frequently it is accidentally knocked off, but under such circumstances, unless the base is cauterized, it is apt to regrow.

The radical treatment of these growths, therefore, consists in their detachment, and subsequently the destruction of the base. The former is accomplished by dissecting it away from the base or forcibly breaking it off; the latter by means of any of the well-known caustics, such as caustic potash, chlorid of zinc, and the galvanocautery. A rapid method is to excise the base, the horn coming away with it; this necessitates, however, considerable loss of tissue.

ICHTHYOSIS.

Synonyms.—Fish-skin disease; Xeroderma; Xeroderma ichthyoides; Ichthyosis vera; Ichthyosis congenita; Sauriasis; *Fr.*, Ichtyose; Ichthyose; *Ger.*, Fischschuppenausschlag.

Definition.—A chronic disease of the skin of congenital origin or developing in early life, characterized by more or less generalized dryness and harshness, slight to plate-like scaliness, and a variable degree of follicular papulation, sometimes warty or horn-like.

Symptoms.—Several grades of the disease are encountered, but commonly classed under two heads—ichthyosis simplex and ichthyosis hystrix. The mildest development of **ichthyosis simplex** is often referred to as *xeroderma* (also xerosis), in which the condition consists of scarcely more than a dry, harsh, somewhat rough-feeling skin, most pronounced on the extensor surfaces of the extremities, and on the back, although commonly recognizable also on other parts, especially when the weather is more or less continuously cold, dry, and windy. There is usually with this, or existing as the predominant feature, a slight or moderate degree of keratosis pilaris, most pronounced and frequently noticeable only on its common situations, the anterolateral aspects of the thighs and posterolateral surfaces of the arms. There is generally also branny scaliness, sometimes more decided, and with a slight tendency here and there to larger thin scales, with a disposition for the edges to turn outward (general pityriasis). Not only is the skin dry, harsh, rough, slightly scaly, and often with a dirty-grayish or unwashed appearance, but it is also somewhat lacking in suppleness and elasticity. There is a trifling thickening of the epidermis, and usually a slight accentuation of the lines of the skin. The skin of such patients is more susceptible to ordinary irritating influences, and in winter exposed portions tend to chap readily, and sometimes to show an eczematous inclination.

FIG. 118.—Ichthyosis of average development (courtesy of Dr. W. Frick).

From this mild type there are many gradations to the extreme type of ichthyosis simplex. In its slighter developments the scaliness is more marked than described, consisting of thin, film-like, irregularly shaped or quadrilateral scales, most striking about the extensor surfaces of the region of the elbows and knees, but with, however, more or less general slight development. In addition there is, likewise, often a greater development of keratosis pilaris than observed in the mild form—xeroderma—just referred to. The face and scalp, too, may show a slight dryness and furfuraceous scaliness. In more marked cases all the features become exaggerated, the epiderm is considerably thickened, the scales are thicker and more plate-like, with pronounced follicular keratosis and usually a universal involvement of the surface, always most developed, however, on the surfaces named, and in these cases the trunk as well often showing marked plate-like scaliness. The plate-like scaliness gives the skin a fish-scale aspect, and hence the name ichthyosis, or fish-skin disease. In still more marked cases the scales are noted to be quite thick, plate-like, usually more or less quadrilateral, divided by somewhat deep furrows; and even the flexor surfaces of the joints —regions relatively or often completely spared in the milder types— show slight or moderate involvement. The scalp is dry, scaly, and the hair often lusterless and lifeless-looking, the face rough, dry, and covered with branny or film-like scaliness. The plate-like character of these extreme types is so strikingly like the thick scales of certain fish or water animals, as the alligator, as to give rise to the designation, "**alligator skin.**"[1] In these, as well as in some of the less developed examples, the elasticity and suppleness of the skin are so compromised that mobility is more or less interfered with, and fissures, often somewhat deep, occur about the joints. Moreover, in these instances, as well as, in fact, in milder cases, during cold weather, eczematous tendency and complication, especially of the face, hands, and forearms, are frequently observed, in which event the features of this latter disease are superadded. Some subjects seem more predisposed to the effects of irritation than others.[2]

These several grades represent examples of what might be termed true ichthyosis, in contradistinction to ichthyosis hystrix, about the status of which there is some difference of opinion. The condition of the surface varies from a branny desquamation to that of thick, horny plates, the latter usually more or less quadrilateral and roughly diamond shaped. Those regions where the integument is thin and softer, as the flexures, neck, face, inner part of the thighs, etc., are always less involved than other parts, and in many of the milder cases are scarcely or at all affected. The scales are exceptionally somewhat shiny and seemingly translucent (ichthyosis nitida, ichthyosis nacrée), but usually are dirty grayish, and, in marked and extreme cases, often brownish gray, greenish, or blackish (ichthyosis nigricans). Other terms are occasionally met with in literature—ichthyo-

[1] See papers by G. H. Fox, "The 'Alligator Boy'—A Case of Ichthyosis" (with colored plate), *Jour. Cutan. Dis.*, 1884, p. 97; and by Yandell, "The 'Man Fish' of Tennessee," *Louisville Med. News*, 1878, p. 262.

[2] Besnier, "Ichthyoses irritables," *Annales*, 1889, p. 534.

sis serpentina, or resembling the skin of a serpent, ichthyosis sauroderma, or sauriasis, suggestive of a crocodile skin, ichthyosis scutellata, scales somewhat shield shaped. The hair and nails usually show nutritive changes, being harsh and lusterless, the nails being often quite fragile and easily broken. The sweat and oil secretions are much diminished, and sometimes in complete or relatively complete abeyance. As already remarked, there are rarely any subjective symptoms, occasionally slight itching, which, however, is more commonly due to eczematous complications. Fissures, when present, may, however, be quite painful.

The course of the malady in these cases is usually quite characteristic, appearing early in life, increasing slightly during childhood and adolescence, and being less pronounced during the warm season and most marked in winter. The type once established, whether mild, moderate, or severe, remains about the same throughout life. In the milder cases, during the summer weather, owing to the increased activity of the sweat and sebaceous secretions, evidences of the malady almost wholly or entirely disappear, to present again on the approach of cooler weather. In the severe types also there is a variable lessening of the condition during such period. The amount of scaliness present in a given case depends to some extent upon the patient's habits as to the frequency of general ablutions.

FIG. 119.- Ichthyosis congenita. Case photographed when four days old. Mother pregnant seven times, giving birth the fifth and the last (present case) to infants with congenital ichthyosis; the former (Sherwell's case referred to) still living (courtesy of Dr. J. MacF. Winfield).

The malady is usually first noted in the first or second year, although it is probably born with the individual, but that during the first months it is so slight, the skin so frequently washed, and owing to the warmth of the body, the consequently perspiratory action, favored by the usual overclothing at that period, so free, that it could be thus kept in abeyance, and its existence readily overlooked. In other rarer instances the child is born with all the conditions of a marked ichthyosis present, sometimes of pronounced character (**ichthyosis congenita, keratoma diffusum, intra-uterine ichthyosis**), examples of which have been reported by a number of observers, among whom Le-

bert,[1] Caspary,[2] Hutchinson,[3] Sutton,[4] Elliot,[5] Sherwell,[6] Winfield,[7] and others. The scaliness in these cases varies from a brownish, parchment-like exfoliation to that of plate-like character, and usually with superficial or deep rhagades, more or less ectropion, puckering and fissuring of the mouth and other mucous outlets, and sometimes distortion of the nose and ears as well, constituting the so-called "**harlequin fetus.**" These children are, as a rule, prematurely born, and frequently do not survive many days or weeks. Hebra and Kaposi have considered all these cases as generalized seborrhea (ichthyosis sebacea), a view, however, which is not at all in consonance with the observations of others.[8] It is not improbable that several maladies may present somewhat similar conditions at birth, such, for instance, as a pronounced and somewhat persistent vernix caseosa. Some of the milder cases presenting at birth a membranous coating somewhat suggestive of a layer of collodion or oiled paper, such as those of Hallopeau,[9] Grass and Török,[10] and Bowen,[11] are, in the opinion of Bowen, "examples of a persistence of the epitrichial layer, which has usually been cast off by the seventh fetal month, but in these instances maintained its integrity up to the time of birth, when it enveloped the infants like a distinct membrane, such as is found in certain animals. After a short time this membrane begins to peel off in large masses and sheets, leaving the normal skin below in a state of moderate desquamation, which slowly subsides." Grass and Török take a somewhat similar view, but they would also include the ichthyosis sebacea of Hebra and Kaposi in the same category. In the 3 cases referred to "the general health was not visibly affected by the abnormality of the skin." A reading of the literature would indicate that, while many, such as most of Lebert's, Elliot's, Sherwell's, Winfield's, and others, are clearly examples of congenital or fetal ichthyosis, all reported cases do not represent this malady—some the type of delayed physiologic shedding just referred to, others doubtless generalized seborrhea (ichthyosis sebacea, persistent vernix caseosa), and, it is not improbable, in a few instances, infantile dermatitis exfoliativa.

Ichthyosis hystrix is usually looked upon, as already remarked, as an infrequent variety of ichthyosis, but it has many features which

[1] Lebert, *Ueber Keratose*, Breslau, 1864 (reviews 9 cases).

[2] Caspary, "Ueber Ichthyosis Fœtalis," *Archiv*, vol. xiii., 1886, p. 3 (2 cases, with review and references, colored plate, and two histologic cuts).

[3] Hutchinson, *Clinical Lectures—Rare Diseases of the Skin*, p. 172 (Mackenzie's case).

[4] Sutton, "A Case of Generalized Seborrhœa or 'Harlequin' Fœtus," *London Med.-Chirurg. Trans.*, 1886, p. 291 (with colored plate, histologic cut, and bibliography).

[5] Elliot, *Jour. Cutan. Dis.*, 1891, p. 20 (2 cases, with review and some literature references).

[6] Sherwell, *ibid.*, 1894, p. 385 (with some literature references).

[7] Winfield, *ibid.*, 1897, p. 516 (with case illustration and autopsy, and microscopic examination by Van Cott). See also Wasmuth's recent paper, "Beitrag zur Lehre von der Hyperkeratosis Congenita," *Ziegler's Beiträge*, 1899, vol. xxvi., p. 19 (case illustration, histologic cuts).

[8] See Caspary and Elliot's papers.

[9] Hallopeau and Watelet, *Annales*, 1895, p. 149 (case demonstration).

[10] Grass and Török, *ibid.*, 1895, p. 104.

[11] Bowen, "The Epitrichial Layer of the Epidermis and its Relationship to Ichthyosis Congenita," *Jour. Cutan. Dis.*, 1895, p. 485 (gives abstract review of above two papers). Meneau, "De l'ichthyose foetale dans ses rapports avec l'ichthyose vulgaire"; *Annales*, 1903, p. 97 (a thorough review with complete bibliography).

seem to stamp it as a practically distinct affection. It is rarely, if ever, generalized, but usually limited to one or several regions; exceptionally, it is true, it is more or less irregularly diffused. It presents in patches of various size and shape, sometimes ill defined, made up of thickened, rough, warty-looking, hypertrophic, papillary elevations of variable size up to one-half inch or more. The surface is uneven, more or less corrugated, sometimes with horny, spinous growths, which may be of considerable dimensions—hence the term hystrix, or spiny, and also the term applied to extreme cases—"*porcupine men*," "hedge-hog skin," "rhinoceros skin." In the milder cases of this type there is a resemblance to the rough bark of a tree. The underlying skin is harsh, dry, and often considerably thickened, and in some instances—suggestive connecting cases between ichthyosis simplex and ichthyosis hystrix—the intervening surface is dry, rough, and scaly to a variable degree, corresponding to that of the more common form of ichthyosis. As a rule, however, the skin between or outside the areas is normal. In color the patches vary somewhat, being yellowish-gray, yellowish, or greenish. Sometimes the warty or spine-like protuberances are cast off from time to time, as in one of the celebrated Lambert cases,[1] to be rapidly reproduced.

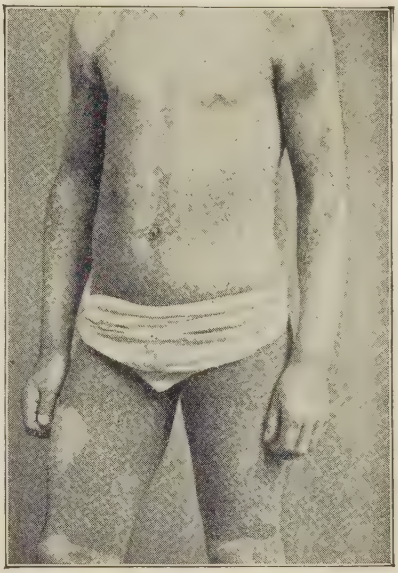

FIG. 120.—Ichthyosis hystrix in a lad aged twelve, on parts below the knees of mild (ichthyosis simplex) type.

Limited and peculiarly shaped ichthyotic-looking eruptions, heretofore included as cases of ichthyosis simplex and of ichthyosis hystrix, such as "chronic palmar and plantar ichthyosis," "linear ichthyosis," and "ichthyosis linguæ," are no longer considered as belonging to this malady. Chronic palmar and plantar ichthyosis corresponds to keratosis palmaris et plantaris, linear ichthyosis to linear nævus, and ichthyosis linguæ ordinarily to leukoplakia. It is not improbable, moreover, that some cases of keratosis follicularis were formerly described under ichthyosis. While ichthyosis simplex and ichthyosis hystrix usually exhibit clinical distinctions throughout their course as to give good ground for the belief in their individuality, yet in exceptional instances the features of both are seen to be present in the one case,—constituting the **mixed variety**,—as in the case of my own here illustrated. In this the hystrix variety of moderate degree is shown especially on the thighs from the knees up, as well

[1] Telesius, "Beschreibung und Abbildung der beiden sogenannte Stachelschwein-Menschen aus der Englischen Familie Lambert," oder "the Porcupine man," Altenburg, 1802—abs. account by Lebert, *loc. cit.*, p. 126.

as less markedly in other places, while on regions, as below the knees and elsewhere, the dryness, harshness, slight to moderate scaliness, quite characteristic of ichthyosis simplex. In Thibiérge's case,[1] as in some others on record, the mixed character was also observed. In this latter instance, moreover, the mucous membrane of the mouth and nares shared in the process—an extremely rare and almost unknown occurrence. Another exceptional feature is an atrophic condition of the skin, which has been noted in a few instances by Jadassohn,[2] Hallopeau and Jeanselme,[3] and Audry.[4] It is true some slight doubt was expressed as to the true nature of these cases, but they seemed to be examples of ichthyosis in which atrophic changes were superadded, the latter being possibly accidental and not necessarily a part of the ichthyosis process. In Audry's case, a woman aged seventy, the explanation might be found in the occurrence of old age atrophy in an ichthyotic patient. Unusual features in a so usually well-marked malady as ichthyosis must always be viewed with suspicion.[5]

Etiology.—The malady is congenital, and in most cases a hereditary tendency is noted, the history of one or more direct ancestors or collateral relatives having the same disease being quite usual. While the condition of the skin, referring more especially to ichthyosis simplex, is generally noticed only toward the end of the first or second year, it is quite probable, as already stated, that it is in reality always congenital. I am inclined to share Hutchinson's[6] belief on this point, "that it usually takes its origin during intra-uterine existence, but that it may be, in many cases, so slight at the time of birth that its presence is entirely overlooked. On the other hand, it may have already developed to such a degree of severity that the infant is quite incapable of taking on the functions of life for itself." These latter represent those of the so-called ichthyosis congenita already described. Exceptionally examples of an ichthyotic condition of the skin have been noted in which the development presented later in life, but these are usually open to question, although Crocker[7] refers to a suggestive case of **acquired ichthyosis** in a man aged seventy-four, in whom the sweat function became less active or more or less in abeyance ten years previously, and the skin then began to get dry and scaly, finally presenting appearances clinically similar to those in the ordinary cases. In some instances the hereditary predisposition is exhibited only in one or two of the children, but examples of its occurrence in three and more members of the same family have been recorded from time to time by various observers (Kaposi, Crocker,

[1] Thibiérge, "Cas extraordinaire d'ichthyose genéralisée avec altérations des muqueuses buccale et nasale des cornées," *Annales*, 1892, p. 717.

[2] Jadassohn, "Ueber Pityriasis alba atrophicans," *Verhandl. der IV. Deutsch. Dermatolog. Gesellsch.*, 1894, p. 392.

[3] Hallopeau and Jeanselme, "Sur une ichthyose avec hypotrophie simulant une sclérodermie," *Annales*, 1895, p. 1016 (case demonstration).

[4] Audry, "Sur les formes atrophicantes de l'ichthyose et leur histologie," *Jour. mal. cutan.*, 1895, p. 265.

[5] See also Joseph's paper, "Ueber ungewöhnliche Ichthyosisformen," *Verhandl. der IV. Deutsch. Dermatolog. Gesellsch.*, 1894, p. 407 (case illustration and histologic cut—case suggestive of both acanthosis nigricans and Darier's disease).

[6] Hutchinson, *Archives of Surgery*, 1891–92, vol. iii., p. 64.

[7] Crocker, *Brit. Jour. Derm.*, 1895, p. 217 (case demonstration).

Jeanselme, Frick, and others).[1] Occasionally a predominant family tendency to its appearance in those of one sex has been noted. Both sexes are, however, its subjects in probably about equal proportion, although most of the cases under my own observation have been males. It is observed in all stations of society. It is not, however, a common disease, although in its slight grade (xeroderma) it is doubtless more frequent than it apparently seems. It is met with in all countries. In districts where family intermarriage is not uncommon its relatively more frequent occurrence is suggestive of an endemic character, as in the Indian Archipelago, especially the Molucca Islands, referred to by Hirsch,[2] and also, according to Jablonowski,[3] among two Albanian tribes on the Adriatic shores. As Hirsch states, however, and as Jablonowski's description indicates, it is probable that all these cases thus referred to are not examples of this disease. In fact Henggeler[4] has noted, in India, that most cases thought to be ichthyosis were cases of tinea imbricata. A condition of the skin somewhat similar to that of ichthyosis has been noted by Schuchardt[5] in workers in paraffin. From the absence of the thyroid in his case of "ichthyosis congenita," Winfield suggests further observation on this point as to possible etiologic relationship.

Pathology.—It is the common opinion that ichthyosis is to be viewed as an inherited deformity of the skin rather than a disease. The pathologic changes were originally considered seated essentially in the epidermis, but later observations, however, tend to hold the surface alterations as due, partly at least, to underlying processes in the corium, especially of the connective tissue. That the nervous system is a factor seems probable from the observations concerning examples of local dryness and scaliness resulting from nerve injuries. Leloir,[6] who among others considers the disease of trophoneurotic origin, found in 2 cases a degenerative peripheral neuritis, and in 1 of these cases also degenerative changes in the spinal roots. These observations have not, however, been corroborated by others. The histologic characters have been studied by various observers, the latest among whom are Esoff,[7] Unna,[8] Audry,[9] Tommasoli,[10] Giovannini,[11] and others. Esoff found the increased formation of epithelial scales, with heightened tendency to cornification, and the greater thickness of the epidermis due principally to

[1] Kaposi, *Diseases of the Skin* (English translation by Johnston), p. 440 (in a family of 8 children, 5 affected); Crocker, *Diseases of the Skin*, third edit., p. 569 (5 in a family of 10 children); Jeanselme, *Annales*, 1894, p. 1277 (4 out of 5 children); Frick, *Jour. Cutan. Dis.*, 1897, p. 19 (3 in a family of 4 children).

[2] Hirsch, *Handbook Geog. and Histor. Pathology*, Syd. Soc. Translation, vol. iii., 1886, p. 666.

[3] Jablonowski, abs.-ref. in *Monatshefte*, vol. iii., 1884, p. 383.

[4] Henggeler, "Ueber einige Tropenkrankheiten: Tinea Imbricata," *Monatshefte der Haut*, 1906, vol. xliii., p. 325 (with excellent case illustrations).

[5] Schuchardt, *Volkmann's klin. Vorträge*, No. 257 (Chirurgie No. 80), p. 2214.

[6] Leloir, *Arch. de Physiolog.*, 1881, p. 405.

[7] Esoff, "Beitrag zur Lehre von der Ichthyosis, etc.," *Virchow's Archiv*, 1877, p. 417 (with histologic cuts and references).

[8] Unna, *Histopathology*, p. 322 (with histologic cuts).

[9] Audry, "Critique anatomique de quelques keratonoses," *Annales*, 1893, p. 384.

[10] Tommasoli, "Sur l'histopathologie et la pathogenèse de l'ichthyose," *Annales*, 1893, p. 537 (with literature references).

[11] Giovannini, *Giorn. della R. Accad. de Med. di Torino*, Dec., 1893, p. 653—abs. in *Annales*, 1894, p. 1176.

its longer retention, the process of exfoliation being slowed. Degenerative changes were also observed in both the coil- and sebaceous glands. Unna states that there is deformity of a weakly developed prickle layer and of the papillary body, together with a much thickened horny layer. The granular layer is everywhere absent on the surface of the prickle layer, and there is absence of keratohyalin, the horny layer being formed directly from the rete, without, as usual, the intervention of this substance. The horny cells thus formed have no nuclei and are homogeneous, there occurring, in fact, a special form of abnormal cornification. In the changes in the tissue of the cutis the papillary body is sometimes more cellular than normal, the cells often larger, as likewise the endothelia and perithelia of the superficial capillaries, and also increased in number. The collagenous tissue is thickened, and the lymph-spaces correspondingly narrowed. A small collection of ordinary spindle cells sometimes surrounds the hair-follicles. In the more severe cases the cellular infiltration is more pronounced. The papillæ are usually more or less compressed and thus lengthened, sometimes being flattened. He believes that the findings indicate a low inflammatory basis is to be ascribed to ichthyosis, and that it is not simply a thickening of the horny layer. Tommasoli also found somewhat similar changes in the cutis, as well as the usual changes in the epidermis. Audry did not, on the contrary, find evidences of an inflammatory process; the granular layer was considerably hypertrophied; the sweat-glands seemed unchanged, but there was atrophy of the sebaceous glands. In a case investigated by Giovannini the predominant changes were observed about the periphery of the sweat-gland ducts, with mitosis of the epithelial cells of the ducts.

The process consists, in the simplex variety, of an accumulation and thickening of the epidermis, but especially of the horny layer, and often a somewhat thinned condition of the rete. The formerly considered papillary hypertrophy is apparent, more than real, the irregularities resulting from a dipping-down of the horny strata, the papillæ being thus compressed and elongated. In fact, the papillæ themselves often show atrophy. Slight evidences of inflammatory action are sometimes found in the cutis, and the glandular structures in marked cases, usually after long continuance of the malady, undergo degenerative changes. There is, as a rule, poor development of the panniculus adiposa. The associated keratosis pilaris, often most marked in some of the milder types, presents but little, if any, essential variation from that form which occurs independently.

In ichthyosis hystrix, according to Schourp,[1] the direct transition from rete cells into horny cells without material intermediate change is also noted. Kaposi (*loc. cit.*) states that the anatomic conditions in this form of the disease do not differ from those in old warts: enormously elongated papillæ, above which the horny layer is piled up in thick, stratified coats. There is moderate cell-infiltration of the papillæ, with dilated vessels.

Diagnosis.—The features of ichthyosis are usually so characteristic that no difficulty arises in the diagnosis. The harsh, dry skin, with thickened epidermis, and furfuraceous to plate-like scaliness,

[1] Schourp, "Ueber Ichthyosis hystrix," *Dermatolog. Centralblatt*, 1898, p. 242.

with frequently follicular elevations (keratosis pilaris) or warty-looking growths, its greater development upon the extensor surfaces, and the absence of inflammatory symptoms, constitute a picture quite readily recognized. Moreover, there is the history of the affection dating back to infancy or earliest childhood, and its amelioration, or in mild type complete, or almost complete, disappearance during the summer weather, as corroborative evidence. It is to be borne in mind, however, that in some instances, especially in cold, snappy, windy weather, eczematous complications, more particularly, however, of exposed parts, is occasionally observed, and this fact should not be permitted to mislead. The local character of the ichthyotic-looking skin in elephantiasis, as well as the other associated symptoms, will prevent this latter being confused with true ichthyosis. The same may be said as to the exceptional instances of eczema verrucosum of the region of the lower leg and ankle.

The features of ichthyosis hystrix are usually still more pronounced and characteristic, and an error is scarcely possible. It should not be confused with linear nævus.

Prognosis.—There is generally a slight, but often not material, increase in the condition up to the age of youth or early adult life, after which it remains practically stationary, with sometimes trifling improvement. The type once established, it practically remains unchanged, the mild, moderate, and severe varieties each continuing as such. The outlook for the patient as regards a cure is unfavorable, as may be inferred from what has already been said, but the process in ichthyosis simplex may usually be kept more or less in abeyance, or rendered endurable by proper measures. The disease continues throughout life, and, so far as I know, but two exceptions to this are on record—by Hebra[1]: in one instance of an ichthyosis simplex in a girl of eight, which disappeared permanently in consequence of an attack of measles; the other, the hystrix variety, after an attack of variola. It is not impossible that if treatment were begun in early life and perseveringly continued, in the milder varieties at least, a favorable result might be brought about.

Treatment.—The treatment of ichthyosis is essentially external, but first a few remedies occasionally administered internally should be referred to. Of the several so employed, those which seem at times to have a favorable, though temporary, influence are pilocarpin and thyroid extract. In several instances it has seemed to me that pilocarpin or jaborandi, administered in dosage sufficient to stimulate the sweat secretion, has tended to make the skin more supple and the scaliness less marked. Thyroid is a preparation that deserves trial, in view of the favorable, though admittedly temporary, influence reported by Don,[2] Bramwell,[3] Abraham,[4] and a few others. Hardaway[5] believes that he has seen some effect in mild cases from the administration of two or three Garrod's sulphur tablets

[1] Hebra and Kaposi, *Hautkrankheiten*, vol. ii., 1876, p. 41.
[2] Don, *Brit. Med. Jour.*, 1897, ii., p. 1334.
[3] Bramwell, *Brit. Jour. Derm.*, 1894, p. 205.
[4] Abraham, *ibid.*, 1896, p. 106 (discussion).
[5] Hardaway, *Manual of Skin Diseases*, second edit., p. 261.

daily. Fagge[1] recommended antimonial wine. In those of impaired nutrition cod-liver oil seems to be of some slight service. Sherwell[2] thought the administration of linseed to be of advantage. After all, the treatment which must always be adopted in these cases, if certainty of amelioration or relief is desired, consists in external measures, and these, if properly followed up and continued, will often bring about the appearance of an apparently normal skin. When this is effected, treatment is to be continued, but much less rigorously. There are especially two objects to be kept in mind in the management of these cases—removal of the scaliness and the maintenance of a soft and pliable condition of the skin. For the first, frequent baths will often suffice. These baths will, according to the severity of the case, be either plain warm baths, alkaline baths, or hot-water baths with the free use of sapo viridis—the same, in fact, as used in psoriasis. Steam and hot-air baths may also be had recourse to for rapidity of action or in cases in which there is considerable firm epidermic thickening. After each bath the skin should be rubbed or anointed with a mild salve or oil. In the mildest cases the baths alone will serve to keep the skin in an apparently normal state; in the others, and always in the more severe cases, an oily application should be made after each bath. A weak glycerin lotion, from ½ dram to 2 drams (2.–8.) to the ounce (32.) of water, oil of sweet almonds, cold cream, benzoated lard, petrolatum, or the like will answer for this purpose. The addition of lanolin in the proportion of from 25 to 50 per cent. to one of the ointments named will sometimes prove an advantage. In most cases the incorporation of from 10 to 40 grains (0.65–2.6) of salicylic acid to the ounce (32.) of ointment will be found more effective. A satisfactory ointment is one consisting of 10 to 40 grains (0.65–2.6) of salicylic acid, glycerin 20 minims (1.35), lanolin 2 drams (8.), benzoated lard and petrolatum, each, 3 drams (12.). The quantity of salicylic acid depends upon the amount and rapidity of scale accumulation. The addition of resorcin, 3 to 10 per cent., is an advantage; this drug, applied in ointment of 3 per cent. strength in mild cases, and 5 to 20 per cent. in markedly developed cases, has been strongly recommended by Andeer[3] and indorsed by Jamieson.[4] The latter considers it superior to the sulphur ointment plan. Unna[5] speaks well of a course of treatment consisting of the daily application of sulphur ointment of variable strength, usually 5 to 10 per cent., and also of ichthyol applications, 10 per cent., with water or in ointment, and frequent baths; he refers to several cases in which the good results remained for several months or longer after active measures had been discontinued. Occasional sulphur vapor baths in conjunction with the milder ointment and bath plan will sometimes prove of additional benefit.

In ichthyosis hystrix, alkaline, steam, hot-air, and sulphur baths,

[1] Fagge, quoted by Pye-Smith, *Diseases of the Skin*, p. 284.

[2] Sherwell, "The Use of Linseed and Linseed Oil as Therapeutic Agents in Diseases of the Skin," *Arch. Derm.*, 1878, p. 303.

[3] Andeer, "Resorcin bei Ichthyosis," *Monatshefte*, 1884, vol. iii., p. 365.

[4] Jamieson, *Diseases of the Skin*, 1888 edit., p. 371.

[5] Unna, "Aphorismen über Schwefeltherapie und Schwefelpräparate," *Monatshefte*, vol. ii., 1883, p. 197.

together with the use of the strong salicylic acid ointment, will, in the milder varieties, usually suffice to clear off the horny accumulation. Sometimes, however, the formation is so hard and adherent that the application of salicylic acid plasters, 10 to 25 per cent. strength, is required, and in extreme cases it may be necessary to have recourse to caustics or to the knife.

POROKERATOSIS.

Synonyms.—Hyperkeratosis eccentrica; Keratodermia eccentrica; Hyperkeratosis figurata centrifuga atrophicans; *Fr.*, Porokératose; Hyperkeratose figureé centrifuge atrophiante.

Under this title Mibelli[1] called attention to a rare and undescribed variety of hyperkeratosis, presenting in small, eccentrically developing areas. Simultaneously appeared also a description of the malady by Respighi,[2] and since these first cases new reports have been made by the same observers and by Hutchins,[3] Reisner,[4] Joseph,[5] Gilchrist,[6] G. W. Wende,[7] and Basch.[8] The disease is extremely slow and insidious, appearing first as a trifling, superficial but slightly elevated, warty-looking formation, or as thin, callous spots. These gradually enlarge, sometimes months or years elapsing before reaching conspicuous dimensions. The spots extend by a peripheral thickened "seam," "dike," or "wall," and usually leave an atrophic, generally slightly or moderately calloused, center. In some cases the inclosed portion consists of somewhat atrophic glossy epidermis, in others a trifle thickened, but perceptibly depressed, and sometimes presenting a dotted appearance. The border is rather sharply defined against the outlying sound skin, and is hard or horny in character, with often a linear horny ridge, in the middle line of which there is a narrow sulcus, and in this very often a thin, horny, thread-like or cord-like elevation, somewhat irregularly dividing the sulcus into two lateral halves. In this thus inclosed line are often found here and there round, millet-seed or smaller sized blackish epidermic concretions, which can be picked out (Hutchins). Occasionally, too, these or similar concretions or minute wart- or papillary-like corneous projections are found imbedded in the inclosing horny lateral elevations of the seam or border, as well as within the atrophic hardened inclosed portion. Sometimes the border is distinctly wall-like, its inclosing side

[1] Mibelli, *Giorn. ital.*, 1893, p. 313; *Monatshefte*, Nov. 1, 1893; *International Atlas of Rare Skin Diseases*, vol. ix., 1893, plate xxvii; *Annales*, 1905, p. 503.

[2] Resphigi, *Giorn. ital.*, 1893, p. 356, and 1895, p. 69, and *Monatshefte* (translation of first paper), 1894, vol. xviii., p. 70, with case illustration and histologic cuts.

[3] Hutchins, *Jour. Cutan. Dis.*, 1896, p. 373 (with case illustration and a review of the published cases, with references).

[4] Reisner, *Ein Fall von Porokeratosis*, Inaug. Dissertation, Strassburg, 1896.

[5] M. Joseph, *Archiv*, 1897, vol. xxxix., p. 335 (case illustration and 11 histologic cuts; review of other published cases and references).

[6] Gilchrist (preliminary paper), *Bull. Johns Hopkins Hosp.*, 1897, p. 107; (main paper) *Jour. Cutan. Dis.*, 1899, p. 149 (with case illustrations; 5 histologic cuts and bibliography).

[7] G. W. Wende, *Jour. Cutan. Dis.*, 1898, p. 505 (with case illustration and histologic cut and bibliography).

[8] Basch, *Pester med.-chirurg. Presse*, 1898, p. 626—abs. in *Jour. Cutan. Dis.*, 1898, p. 547. Heidingsfeld, *Jour. Cutan. Dis.*, Jan., 1905, reviews the subject and gives complete bibliography.

rather sharply perpendicular, and the other side rapidly, but not precipitously, merging into the surrounding skin. In contour the areas are sometimes fairly well rounded, but often somewhat wavy, others of irregular squarish shape, and others still more irregular in outline. The inclosed portion almost always shows slight or moderate epidermic thickening and variable atrophy, with slight scaliness or fairly smooth; but occasionally it is but little changed, having a faintly atrophic appearance, and the hairs may or may not have disappeared. The color of this part may be grayish white, dirty gray, sometimes with a brownish hue, and exceptionally, more especially in ill-developed spots, a pinkish tinge. The "seam," "wall," or "dike" may be dirty gray or brownish gray, and is usually quite pronounced, horny, and elevated; in others—ill-defined spots—it may appear sim-

FIG. 121.—Porokeratosis (courtesy of Dr. G. W. Wende).

ply as a loose rim of epidermis, made up of one or several layers, and the free edges directed inward and slightly upward. In one and the only instance under my own care there was but a single patch, of years' duration, and seated on the dorsal surface of the hand, between the metacarpal bones of the thumb and forefinger; the patch, about an inch to an inch and a half in diameter, was irregularly rounded, with a pronounced wavy elevated border, with an ill-developed irregular and broken sulcus, more or less studded with hard concretions or seed-wart-like epidermic accumulations. The inclosed portion was depressed, somewhat horny, slightly scaly, uneven, and with here and there the imbedded minute, warty-looking concretions just referred to. The broken character of the dike or wall is not unusual, although it is often continuous.

The favorite regions are the hands and feet, more especially the dorsal aspects, but also not uncommonly on the palmar and plantar surface as well. The patches occur on other parts, however, as the face, limbs, and trunk. But one or several may be present, or there may be many in various sizes and of somewhat general distribution. As a rule, they do not exceed one to several inches in diameter, and sometimes remain much smaller. There is usually slight extension, but sometimes, after reaching a certain development, they remain practically stationary; where several contiguous patches coalesce a considerable area may result. As a rule, there are no subjective symptoms, although in some cases variable itching has been noted. The sweat and sebaceous secretions of the affected areas are more or less in abeyance. While the integument alone is usually the seat of the malady, Respighi and Ducrey [1] have shown that it is not at all uncommon for lesions to be seen on the mucous membranes of the mouth also; in 3 of the 4 cases observed by them, lesions occurring here, as well as on the skin, appearing as opalescent, rounded, or irregularly rounded patches, each inclosed by a distinct white raised line or border, sometimes interrupted, and surrounding which there is usually a slight zone of hyperemia. Its course here, as on the skin, is slow and chronic, and apparently gives rise to no inconvenience. Mibelli [2] also found, in an extensive case, lesions in the mouth as well as on the glans penis.

Etiology and Pathology.—But little is known as to the cause of the disease, although a hereditary tendency was indicated in Respighi's case, as the father of the patient had similar lesions; the hereditary factor has been convincingly shown by Gilchrist in his report of 11 cases in one family—in 4 generations. Respighi and Ducrey also report an instance of the malady occurring in several generations. It is a rare disease, the cases of Hutchins, Gilchrist, Wende, and my own [3] apparently being all that have been noted in this country. It is seemingly not so rare in Italy, but is scarcely known in England, France, and Germany. It is met with in both sexes and at all ages, but it has its beginning more frequently in early life. There is no direct evidence to prove that the disease is parasitic, although in 30 experimental inoculations made by Wende on 4 different individuals one proved successful, but as this was on the affected patient, it is not wholly conclusive; it is possible that the local irritation produced may have been sufficiently potential in a predisposed skin, although it is true in this instance the inoculation, made on the unaffected hand, was positive only after 10 unsuccessful attempts. Respighi's experiments in transplantation were without result. Examinations made for micro-organisms have been uniformly negative. The predominance of parts subject to pressure

[1] Respighi and Ducrey, *Annales*, 1898, pp. 1, 609, and 734—an exhaustive account of the disease,—clinical and histologic,—3 case illustrations, and 48 histologic cuts.

[2] Mibelli, *Archiv*, 1899, vol. xlvii., pp. 1 and 231; review of the disease, 5 case illustrations, and 6 histologic cuts.

[3] I saw this case in 1887 or 1888, on two occasions only, but was puzzled by it and did not recognize its nature, intending to publish it later; the papers of Mibelli and Respighi appearing subsequently showed me that I had missed an opportunity of priority.

and friction as sites of the eruption, as the hands and feet, appears to indicate that these factors may be contributory.

Histologic examinations were made by almost all the observers named, and their conclusions in the main agree that the malady is a special form of hyperkeratosis, and affecting chiefly the lower horny and upper rete layers, although all parts of the epidermis, especially about the sweat-gland ducts, which are often plugged up with horny epithelium, share in the process. The hair-follicles and sebaceous glands also show involvement. The papillary layer of the derma is almost obliterated in the central area (Respighi). Tommasoli[1] was inclined to question the individuality of the affection and the identity of the various cases reported, believing that they were unusual examples of other keratoses, such as ichthyosis, linear nævus, etc., but the clinical features, as well as the histologic findings, and the behavior and course of the disease, as Mibelli[2] convincingly showed, are strikingly different from any other known malady.

Prognosis and Treatment.—The malady, as will have been seen, is a persistent one, with but little, if any, tendency to spontaneous disappearance, but beyond the disfigurement which it causes need give rise to no anxiety. Occasionally some of the efflorescences may disappear (Joseph). The lesions on the palms and soles are sometimes rendered painful by the constant pressure, friction, etc.

The treatment of the affection is somewhat uncertain as to result unless surgical measures are employed. Joseph was not able to obtain any result from salicylic acid and other keratolytics, but with excision there was no recurrence. Gilchrist found that the lesions always returned after thorough curetting and subsequent application of silver nitrate, a plan which was tried first. Excision proved satisfactory, but naturally left scars. In 2 of his cases the electric needle was used with excellent results, causing very little scarring, and there was no return.

ANGIOKERATOMA.[3]

Synonyms.—Keratoangioma ; Lymphangiectasis (Colcott Fox) ; *Fr.*, Verrues télangiectasiques (Dubreuilh) ; Tuberculides angiomateuses (Leredde) ; *Ger.*, Angiokeratom.

[1] Tommasoli, *Comment. clin. d. mal. cut. e. gen. ur.*, ii., 1894, No. 1.

[2] Mibelli, "Ueber die Porokeratose (Antwort auf eine Kritik)," *Monatshefte*, 1895, vol. xx., p. 309 (with references).

[3] Literature : Cottle, *St. George's Hosp. Reps.*, 1877–78, vol. ix., p. 758, with colored illustration; Pringle, *Brit. Jour. Derm.*, 1891, pp. 237, 282, and 309 (with 2 colored plates and histologic cut, and a résumé of previously reported cases) ; Zeisler, *Trans. Amer. Derm. Assoc. for 1893* (abstract; full paper not published); Fordyce, *Jour. Cutan. Dis.*, 1896, p. 83 (with a colored plate and 5 excellent photomicrographs, and complete literature references to above reports and those of Mibelli (1889), Crocker (1888 and 1891), Colcott Fox (1886 and 1889), Dubreuilh (1889 and 1893), Audry (1893), Deydier (1892), Brocq (1892), Thibiérge (1892), Joseph (1892 and 1894), Tommasoli (1893), Renault (1894)) ; Dubreuilh, *Annales*, 1896, p. 1202; Mibelli, *Monatshefte*, 1897, vol. xxiv., p. 428 ; Wisniewski, *Archiv*, 1898, vol. xlv., p. 357 (with 2 colored histologic cuts, review of the subject, and references) ; W. Anderson, *Brit. Jour. Derm.*, 1898, p. 113 (general distribution, with almost complete immunity of the hands and feet; 2 cuts showing distribution, and 1 of histology) ; Dore, *ibid.*, 1903, p. 23 (with chilblain circulation, erythema pernio, and erythema induration).

Definition.—An affection usually of the extremities, occurring, for the most part, in those subject to chilblains, and characterized by the appearance of telangiectases which subsequently develop into warty-looking elevations.

Symptoms.—The descriptions of Cottle, Mibelli, Pringle, Zeisler, Fordyce, and others have given a pretty clear picture of the symptomatology of this rare malady. It generally follows one or more attacks of chilblains, minute vascular dilatations or telangiectases subsequently arising. They are pin-point to pin-head in size, discrete, or in close proximity or crowded together. At first they may be pinkish in tinge, later becoming darker and even with a dark-purplish hue or color, the central point usually being the darkest; occasionally the color partakes of a reddish brown. The backs of the fingers and the dorsal surface of the toes, and especially toward the basal portions, are the favorite sites; the lesions may occasionally appear on the palmar surfaces also. Exceptionally they are seen elsewhere, as in Fordyce's case, in which the lesions were confined to the scrotum, and in Anderson's patient, of more or less general distribution. In Zeisler's case, in addition to the ordinary lesions on the hands and feet, the auricles, forearms, and legs were the seat of pedunculated vascular tumors and nævus-like patches. The fingers and hands have been, however, the most frequent localization. After a while slight elevation is noted, and the surface may become rough and irregular and somewhat horny, and present, more especially when close or bunched together, a warty aspect, the resemblance to small warty growths leading Dubreuilh to designate the malady "telangiectatic warts." Closely lying vascular dilatations sometimes practically fuse together, forming a slightly raised patch, a fractional part of an inch in diameter, with small projecting or irregular horny elevations, the reddish or purplish color being most marked peripherally. Different stages of the process are usually to be seen, from the passive, livid congestion of chilblains, to the well-marked warty character. As a rule, the color may partly, rarely completely, be made to disappear on pressure. The condition is commonly worse during the cold season, at which time new points are more apt to appear. Thus the malady tends to become more wide-spread, the growths showing no signs of retrogression. There are no subjective symptoms, and beyond the disfigurement, the malady gives rise to no trouble, although the larger projecting growths, if roughly knocked, may show a disposition to bleed.

Etiology and Pathology.—The disease is rare, although somewhat similar scattered single lesions, lacking distinct horny characters, are occasionally seen on the hands and upper trunk. The malady usually begins in childhood or youth, although in Fordyce's patient, aged sixty, it had apparently begun much later, and Zeisler's case—a male—began when aged forty-nine. The female sex seems to furnish the majority of cases. In some instances more than one member of the family has exhibited the disease; according to Dubreuilh,[1] Mibelli saw 6 cases in the same family. Local circulatory weakness, as that resulting from chilblains, is apparently an important factor in most instances, although in the 2 cases reported by Fordyce and

[1] Dubreuilh, *loc. cit.*

Anderson this preliminary feature was wanting; in Fordyce's case, however, the patient had a double varicocele, indicating a tendency to blood-vessel dilatation. In some instances, however, there was no apparent cause.

Mibelli, who gave the present accepted name to the malady, was the first to investigate the pathologic histology, since which time his findings have for the most part been corroborated by Pringle, Joseph, Audry, Wisniewski, Fordyce, Unna, and others. The primary pathologic change is a vascular one, the keratosis, a secondary phenomenon. The lesions, quoting Fordyce's words, consist of lacunar spaces filled with blood, occupying the papillary portion of the derma, some of

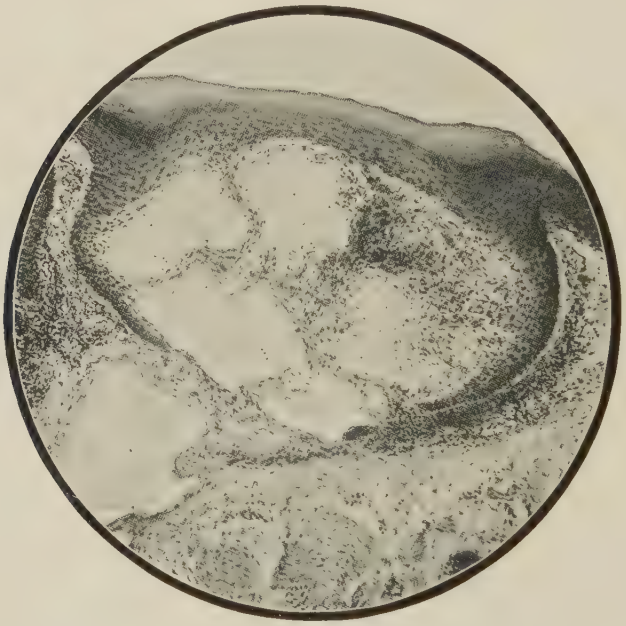

FIG. 122.—Angiokeratoma (× about 100), showing cavernous space filled with blood-corpuscles and divided by fibrous septa; hypertrophy of the corneous layer and rete (courtesy of Dr. J. A. Fordyce).

which are found inclosed in the rete; and these cavernous spaces are evidently the essential, and probably primary, feature of the disease. It is probable, as Mibelli and Pringle suggest, and in which opinion Fordyce is inclined to coincide, that the lacunar dilatations result from changes in the papillary vessels, superinduced by causes which impair the contractility of the vessel-walls, the most common being attacks of chilblains. Fordyce's investigations lead him to coincide in Pringle's hypothesis that the blood-spaces in the rete Malpighii are caused by a downgrowth of the cells of this layer, producing a constriction of the terminal loops and their resulting distention. In addition to these several changes, there is a slight inflammatory infiltration in the underlying derma, and thickening of the

corneous layer. Differing from other observers, Mibelli and Audry found also some dilatation of the lymph-spaces.

Diagnosis.—The primary minute telangiectases and subsequent warty tendency, with the associated dark-red or purplish color and the localization, together with often a history of previous exposure to severe cold, with consequent chilblains, are usually sufficiently diagnostic. The vascular dilatation is entirely wanting in ordinary warts, and the growth and appearance of the latter different.

Prognosis and Treatment.—The malady is persistent, with no tendency to involution. The treatment consists, as successfully employed by Pringle, of electrolysis, each lesion receiving attention, the needle being attached to the negative pole, and a current of 2 or 3 milliampères used. Measures should be advised as to proper hand and foot covering in cold weather, and the maintenance of circulatory tone by exercise and suitable tonics if indicated.

SCLERODERMA.[1]

Synonyms.—Hide-bound skin ; Sclerema ; Scleriasis ; Scleroma adultorum ; Dermatosclerosis ; *Fr.*, Sclérodermie ; Sclérème des adultes ; *Ger.*, Sklerodermie.

Definition.—A chronic disease, characterized by a circumscribed localized, or general and more or less diffuse, usually pigmented, rigid, stiffened, indurated, or hide-bound condition of the skin.

The manifestation differs materially in extent and character, in some cases being more or less diffused, hard, hide-bound, and with usually considerable pigmentation, and in others consisting of rather sharply circumscribed patches or bands of a somewhat lardaceous appearance, and often, especially the rounded areas, with a pinkish border. The former is the variety usually known as diffuse symmetric scleroderma; the latter, as circumscribed scleroderma or morphea. Duhring maintains that morphea is distinct from scleroderma, and it must be confessed that the extremes of these two types bear practically no clinical resemblance, one to the other, but other cases approach more closely and merge into each other, some cases presenting the typical conditions of both.

Symptoms.—The diffuse type may begin insidiously or rapidly. In the former event the first symptom noted is a slight stiffness of the part involved, which may at first be extremely limited. On examination, variable swelling or infiltration is usually noted, the surface is somewhat tense looking, and sometimes shining; at other times there is noted, along with the first symptoms, more or less yellowish-brown or brownish pigmentation, and which may, indeed, be the first manifestation observed by the patient. As a rule, there

[1] Some valuable recent literature: Lewin and Heller, *Die Sklerodermie*, Berlin, 1895 (a review of the entire subject, embracing 508 collected cases) ; Osler, *Jour. Cutan. Dis.*, 1898, pp. 49 and 127 (a report of 8 cases of diffuse scleroderma, with review comments on the disease, especially diagnosis and treatment with thyroid extract) ; Dercum, *Jour. of Nervous and Mental Dis.*, July, 1896 (3 cases) and (on scleroderma and rheumatoid arthritis—with reports of 2 cases), *ibid.*, October, 1898 ; Méneau, *Jour. mal. cutan.*, 1898, p. 145 ; Colcott Fox, *Brit. Jour. Derm.*, 1892, p. 101, also contributes an interesting historic paper bearing upon early observations of English observers on the disease.

are no subjective symptoms complained of in the early stages, except in some cases occasional neuralgic or rheumatic pains. The division between the affected and the healthy skin is not well defined, one insensibly disappearing into the other. The process gradually extends, and, after the course of weeks or some months or several years, finally involves one or more regions or the greater part of the entire surface. It may be limited to the arms or the lower extremities, extending sometimes on to the trunk, or the face, neck, and immediately adjacent parts are the seat of the induration. When well established the

FIG. 123.—Scleroderma—band or ribbon type, extending full length of the arm. Several "morphea" patches on back.

integument is brawny or leathery, hard to the touch, stiff, rigid, and cannot be lifted up into folds. It is usually apparently agglutinated with the subjacent tissues, and the entire part is more or less immobile.

In the rapidly spreading or acute type, the process is commonly ushered in by more or less edematous infiltration, with or without preceding chills, fever, or other constitutional disturbance. The tissues and skin are tense and generally glossy, and in some instances may pit slightly upon pressure, although, as a rule, owing to the tenseness and beginning hardening, this is not readily produced. In these edematous or infiltrating cases the skin is often whitish or waxy, somewhat similar to the appearances observed in ordinary edema. The disease rapidly extends, and soon a greater part of the entire surface is invaded. The infiltration or edema dis-

appears as the integument becomes hard and rigid, and practically the same picture is presented as in the insidious form: the skin is dry, sometimes harsh, sometimes smooth, hide-bound, stiff, and hard and more or less pigmented, and not infrequently with some shriveled epidermic scaliness. In some instances, in places, especially the lower leg, there is slight wart-like papillary hypertrophy.

If the limbs are involved, they are stiff and immobile, and later become shrunken and withered, the underlying muscles also atrophying, and the whole region—skin, tissue, muscle, and bone—seems glued together and atrophic. In some cases (Thibiérge)[1] the muscles are noted to be atrophic, even where there is no overlying sclerodermic areas. If the face is the part involved, the countenance is immobile, expressionless, the wrinkles and lines obliterated, and the mouth slightly or firmly rigid. In fact, the integument has a wooden or petrified look. Atrophic changes may take place here also, but not so commonly as with the extremities. When seriously involving the latter, joint symptoms of an arthritic or rheumatoid arthritic character are noted, and, in addition to the enormous shrinking and atrophy which sometimes ensue, even to the extent of reducing the arm of an adult to almost that of a child, the joints become ankylosed, the fingers bent and fixed, resulting in a veritable *sclerodactylia*, an associated condition to which Ball called attention, and well shown in cases more recently reported by Osler,[2] Dercum,[3] Elliot,[4] Uhlenhuth,[5] and others.[6] Both the fingers and toes may be the seat of these changes, as in some of the cases just referred to and in one referred to by Kalischer.[7] Sometimes such distortion is preceded by pain, occasionally cyanosis, and, in fact, many of the other symptoms of Raynaud's disease (Bouttier, Chauffard, and others).[8] Ulcerations are apt to form over the knuckle prominences, and the whole condition be a painful and troublesome one. In such cases and in others often the first troublesome symptom noted is slight ulceration of the finger-ends; Jacoby's[9] case began in the form of open sores, the different finger-tips being successively attacked, and Eichhoff[10] observed an instance somewhat similar, but in which the apparent exciting factor of the atrophic and destructive process was a favus of the nails. In some cases, especially those in which the subcutaneous tissues and muscles have atrophied, the hardened skin may tend to ulcerate over sharp bony prominences.

[1] Thibiérge, "Contribution a l'étude des lésions musculaire dans la sclérodermie," *Revue de Méd.*, 1890, p. 291, calls special attention to the characters of the muscular atrophy observed and refers to other literature cases; Bloch, *Berlin. klin. Wochenschr.*, 1899, p. 307, has added a case of bone and muscle atrophy to those already reported; also case reported by Adler, *ibid.*; and one by Nixon, *Bristol Medico-Chirurg. Jour.*, Dec., 1903, and refers to case by Dreschfeld (*Manchester Med. Chronicle*, 1897, p. 263).

[2] Osler, *loc. cit.*

[3] Dercum, *loc. cit.*

[4] Elliot, *Jour. Cutan. Dis.*, 1899, p. 575.

[5] Uhlenhuth, *Berlin klin. Wochenschr.*, 1899, p. 207.

[6] Gordonier, *Amer. Jour. Med. Sci.*, vol. xcvii., p. 15, 1889, reports a case and reviews others.

[7] Kalischer, *Wien. med, Rundschau*, 1899, p. 65.

[8] Bouttier, "De la Sclérodermie," *Thèse de Paris*, 1886; Chauffard, abs.-ref., *Annales*, 1897, p. 895; also noted by Osler, Dercum, and others.

[9] Jacoby, *Philada. Med. Jour.*, April 15, 1899.

[10] Eichhoff, *Archiv*, vol. xxii., 1890, p. 857 (with cut).

The disease may, however, begin on any region, and the most frequent one is that of the neck, although shoulders, back, chest, arms, and face are not uncommon sites. It may limit itself somewhat, or it may gradually or quickly involve almost the entire surface. As a rule, it is extensive. It may be somewhat irregular in its distribution, but it is usually symmetric—in a case described by Britton,[1] the disease was not only diffused over most of the surface, but its symmetric character was perfect; and in one recently noted by Bruns,[2] the disease involved both lower extremities, extending upward and stopping short level with the second sacral vertebra. Not only may the skin be involved more or less extensively, but the mucous membrane of the mouth as well, and this has also been observed even when the integumentary involvement was limited. Sometimes, too, the teeth loosen and fall out (Dercum). In some cases the scleroderma presents in wide strips or bands, and occasionally associated with circumscribed areas of more or less typical morphea, and in exceptional instances, in addition to the sclerodermic changes, there are noted associated alopecia and leukoderma.[3]

As a rule, there are no distinctive or special constitutional symptoms in scleroderma; some of the less extensive cases and most of those of wide distribution are ushered in by chills, fever, and other evidences of general disturbance. There are not infrequently, however, concomitant or developing rheumatic symptoms and occasionally those of rheumatoid arthritis. Pigmentation is sometimes marked, and sometimes suggestive of Addison's disease; in exceptional instances this latter has been reported to coexist. Local pain, occasionally cramp-like in character, heat or burning, and a sense of numbness, and, as already referred to, edema are sometimes precursory and early accompanying symptoms. The sweat secretion of the involved region is diminished, and usually entirely suppressed. Sensibility of the parts is rarely affected, but there is itching in some cases. Changes in the thyroid gland have also been observed in some instances (Singer, Jeanselme, Ditscheim, Grünfeld, Osler, Uhlenhuth, James, Samouilson, and others), but usually in association with coexistent Graves's disease. In extreme types, especially when the face is involved, from stiffening and often contraction of the mouth, proper nourishment is interfered with, and the patient suffers from inanition. From hardening and contraction of the integument of the chest breathing is also seriously interfered with in some cases.

The course of the disease is essentially chronic, sometimes extension being slow, at other times rapid. In some cases there is occasional retrogression, which may even go on to complete recovery, but before such a fortunate conclusion there may occur one or more exacerbations, usually foreshadowed by chilliness or chills and other systemic disturbance. The edematous cases are more likely to lead to atrophic changes—Crocker believes this to be the result in all of them.

[1] Britton, *Brit. Jour. Derm.*, 1891, p. 227.

[2] Bruns, *Deutsche med. Wochenschr.*, 1899, p. 487.

[3] Eddowes, *Brit. Jour. Derm.*, 1899, p. 325, exhibited before Derm. Soc'y of Great Britain and Ireland a case presenting general alopecia, leukoderma, scleroderma, and morphea patches.

Circumscribed Scleroderma—Morphea (known formerly as Keloid of Addison).—The disease may present some variations. The typical examples, those which seem wholly different from scleroderma, begin, as a rule, by the appearance of light-pinkish or hyperemic, usually oval or rounded, small coin-sized patches. There may be slight elevation or an appearance of scarcely perceptible puffiness. The color, in the course of some days—a variable time—fades out, and the patch is observed to be encircled with a faint rosy or pinkish zone, which, on close examination, is found to be made up of minute capillaries, while the area itself is whitish or ivory-like, or lardaceous, and seems inlaid in the skin. It is usually on a level with the sur-

FIG. 124.—Circumscribed scleroderma (morphea) in a man aged thirty; consisting of the two symmetric areas shown, which were waxy or lardaceous in appearance, quite firm to the touch, and with a slight peripheral, pinkish border, although this was not at all marked and discernible only upon close inspection. Duration one year and of gradual appearance.

face, or it may be slightly depressed; it often has a polished look, and it is either somewhat soft to the touch, and when pinched up not materially different from the surrounding skin, or it is noted to be firm, hard, leathery, and even brawny. On close inspection very often the surface is observed to be coursed over by minute blood-vessels, sometimes forming a faint network. Later, instead of a smooth, shining surface, there may be slight, thin, shriveled epidermic coating. Beyond the faint pinkish, or sometimes lilac-colored, border, a slight yellowish or yellowish-brown, often mottled, irregularly diffused pigmentation is noticeable, which may extend some distance from the patch.

In some instances the patches, instead of being pinkish or rosy, begin as whitish or bluish-white (Handford[1]) areas, later becoming yellowish. In exceptional instances the erythematous stage usually noticed is prolonged. As a rare example of this latter was

[1] Handford, *Illust. Med. News*, June 22, 1889, p. 265, records, in a report of 2 cases, a case of this kind (with colored plate and histologic cut).

one under Cavafy's[1] observation, in which the legs were for months the seat of erythematous areas of obscure nature, but which finally began to harden, the erythema disappearing and giving place to lardaceous patches. In other instances, instead of the typical characteristic patches, there appear several or more small or large scar-like

FIG. 125.—Circumscribed scleroderma (morphea) in a middle-aged working-woman; disease limited to the patch shown on the leg. Duration about one year. The pinkish or lilac border present in most cases is shown by the dark peripheral shading. The inclosed area is whitened and lardaceous in appearance. The two small ulcerations are accidental, due to traumatism.

spots, sometimes slightly depressed; the skin is atrophic or thin, and often with neighboring telangiectases of reddish or bluish color. Pigmented areas, true sclerodermic areas, pit-like atrophic depressions, and atrophic lines are also present in some cases.[2] Or, instead of lesions of these characters, the disease may present in irregularly

[1] Cavafy, *Brit. Jour. Derm.*, 1896, p. 275.

[2] Duhring, *Amer. Jour. Med. Sci.*, Nov., 1892, reports an interesting case of associated morphea patches and atrophic lines and spots.

rounded areas, or short or long bands, hard and brownish, sometimes with the peculiar pinkish capillary border or with abrupt termination in the skin beyond, which may or may not be pigmented. Occasionally a band extends almost the entire length of a limb, and may be elevated or countersunk. In these cases paroxysmal attacks of cramp-like pain are now and then noted.

The course of the typical lesions of morphea is variable—usually slow and chronic in character; they frequently enlarge slowly, and if close together, coalescence results, and large areas may be covered. Very often after reaching the diameter of a few inches they remain stationary for an indefinite time, either with a gradual tendency to enlargement or to retrogression and disappearance. In some cases decided atrophic changes ensue, and the final result is akin to that observed in diffuse scleroderma: the skin is shriveled and thin, and sometimes hard and fibrous, the tissues beneath gradually atrophy, and the parts agglutinated together, finally forming irregular, smooth or furrowed, sunken, contracted scars, sometimes of keloidal aspect or nature. In rare instances ulceration takes place, usually in parts of the involved area only.

Morphea patches may develop upon any region, but its most common sites are the upper trunk, face, neck, abdomen, and the arms and thighs; as a rule, but several areas are seen, but it may be wide-spread over several regions, as in extensive cases described by Morrow[1] and Cavafy,[2] in which there were numerous large areas from the hips down on both legs, and with more or less perfect symmetry. Ordinarily patches of the disease are irregularly distributed, sometimes presenting on but a single region; occasionally the distribution corresponds to that of the cutaneous nerves, and exceptionally the manifestation has been strictly limited to the fifth nerve, as in Anderson's[3] case, in which the entire region of the distribution of the three divisions of the right fifth nerve was the seat of sclerodermic changes, including the mucous membrane of the mouth and the upper part of the pharynx. Barrs[4] observed a case in which the disease, upon both arms and left leg, followed very accurately the nerve-fields.

In rare instances, closely analogous to the last, as in a case also reported by this last observer (Barrs), as well as by others previously, the disease seems to limit itself, chiefly at least, to one side of the face (**hemiatrophia facialis** or **unilateral atrophy of the face**), but not infrequently with one or several characteristic patches elsewhere. With these cases, however, the atrophic "shrinking" influence of the disease is especially noticeable, not only the skin, but the subcutaneous tissues, muscles, and even the bones becoming involved, and great deformity sometimes resulting.

Etiology.—Both types of scleroderma are infrequent—the diffused type rare, the circumscribed variety—morphea—much less so. It is met with in both sexes, but with a considerable preponderance on the female side, and this, I believe, is even more pronounced in

[1] Morrow, *Jour. Cutan. Dis.*, 1896, p. 419 (with 3 illustrations) and discussion (White and Duhring), p. 446.
[2] Cavafy, *loc. cit.*
[3] W. Anderson, *Brit. Jour. Derm.*, 1898, p. 46.
[4] Barrs, *ibid.*, 1891, p. 152.

morphea. In Lewin and Heller's statistics, out of 435 cases, 292 were females. It is chiefly observed in those between the ages of fifteen and forty-five, but no age except early infancy is exempt, as it has been met with both in the very young (the youngest patient recorded being thirteen months old) and the very old. Various causes have been assigned, but there remains much to be learned before anything definite can be stated on this score. Rheumatism, chills, exposure to cold and wet, prolonged sun-exposure, thyroid disease, exhaustion from any cause, emotional and other nervous disturbances, filaria sanguinis (Bancroft), arterial disease, and many other factors are named as of etiologic influence. Some cases have apparently had their start in some local irritation or injury, another example of which is recently recorded by Leslie Roberts.[1] In some instances, however, the patients at the time of the attack are apparently in good health, and when the involvement is not unusually extensive, the general condition may remain comparatively undisturbed; this is especially so in most cases of morphea. Zambaco[2] is inclined to view the disease as an anomalous or modified form of leprosy.

The rheumatic origin of the disease has the frequent occurrence of rheumatic and rheumatoid arthritic symptoms to support it, such symptoms sometimes antedating the sclerodermic changes, and in other cases being concurrent. These facts are, however, in my judgment, more especially as to rheumatoid arthritis, merely an added evidence in favor of the neurotic cause of the disease, which, upon the whole, has the greatest support. That changes in the thyroid gland are noted in some cases has already been remarked upon, usually, however, in association with Graves's disease, but also in some instances in which this latter did not exist, usually atrophic in character, as reported by several observers, more recently by Hektoen,[3] Uhlenhuth,[4] James,[5] and others.[6]

In favor of its being a neurosis are the occasional nerve distribution, its frequent symmetric arrangement, the occasional preceding or concurrent finger symptoms, suggesting Raynaud's disease, the occasional local sensory symptoms, the sometimes noted coexistence of alopecia and leukoderma, the pigmentary changes, the muscle and bone atrophy, etc.

Pathology.—Knowing so little regarding the essential causes which provoke the disease, it is difficult to formulate a satisfactory explanation of the pathologic changes which take place in the cutaneous structures. As Osler succinctly states, as already in part intimated in etiology, the disease is variously regarded as a trophoneurosis dependent upon changes in the nervous system—a perver-

[1] Roberts, *Brit. Jour. Derm.*, 1900, p. 118.

[2] Zambaco, *Trans. First Internat. Leprosy Congress.*

[3] Hektoen, *Jour. Amer. Med. Assoc.*, vol. xxviii., p. 1240, June 26, 1897.

[4] Uhlenhuth, *Berlin klin. Wochenschr.*, 1899, p. 207.

[5] James, *Scottish Med. and Surg. Jour.*, May, 1899.

[6] Samouilson, "De la Coéxistence de la sclérodermie et des altérations des corps thyroïde," *Thèse de Paris*, July 21, 1898, considers the subject at length and reviews the literature, with the conclusion that the disease is sometimes due to an intoxication resulting from abnormal action of the thyroid gland. Leven, *Dermatolog. Centralblatt*, Feb., 1904 (associated development of thyroid).

sion of nutrition analogous to myxedema, and due to disturbance of the thyroid function; a sclerosis following wide-spread endarteritis; a primary slow hyperplasia of the collagenous intercellular substance of the corium—fibromatosis; or a primary affection of the lymph-channels, central or peripheral. Lewin and Heller, from their valuable studies, are led to view the disease as a neurosis—an angioneurosis, trophoneurosis, or angiotrophoneurosis. As Crocker states, most of the symptoms can be referred to obstruction,—arterial, lymph, and venous,—and that the variable character of changes observed in different cases depends upon which of the vascular systems is most involved. According to Unna, the first changes are in the connective tissue, especially its intercellular substance. It is probable that the primary pathogenic influence is to be found in the central nervous system, although many (Chiari, Spieler, Dinkler, and others) have failed to find such evidence; but, on the other hand, Westphal,[1] Jacquet and de Saint-Germain,[2] Schulz,[3] and Steven[4] have noted degenerative and sclerotic changes in the brain, spinal cord, or sympathetic, but there was no uniformity, and the exact relationship cannot, therefore, be definitely stated. Brissaud[5] believes it takes its origin in some disturbance of the sympathetic. In Schulz's case, in which there was considerable general pigmentation, one suprarenal body was found somewhat diseased.

The anatomic changes observed in the diffuse type (Neumann, Kaposi, Auspitz, Schwimmer, Faggé, and others) are essentially in the corium and subcutaneous tissues. Pigmentation, it is true, is found in the rete, and not infrequently in the corium also, especially in the papillary layer. Both in the true skin and subcutaneous connective tissue there is a marked increase of connective-tissue element, with thickening and condensation. The fat atrophies and gives place to connective tissue. The vessels are found surrounded by masses of small cells of unknown origin, and are thereby diminished in caliber; the latter is also due to thickening of the media and intima. The glandular structures are irregularly surrounded by these cell-masses, but are primarily otherwise unchanged; in the later stages, however, they are atrophied. Excepting the presence of these cells there are no inflammatory signs. The papillæ are usually normal in size, although in some cases in which a papillomatous tendency is noted hypertrophy is observed. The connective tissue and elastic tissue of the corium are increased, densely packed, and the entire cutaneous structure is converted into a dense mass. The histologic changes in the circumscribed form, studied carefully by Crocker, vary relatively little from those of the diffused type in its

[1] Westphal (2 cases—1 autopsy), *Charité-Annalen*, vol. iii., p. 341, Berlin, 1876.

[2] Jacquet and de Saint-Germain, *Annales*, 1892, p. 508.

[3] Schulz, "Sclerodermie, Morbus Addisonii und Muskelatrophie," *Neurologisches Centralblatt*, 1889, pp. 345, 386, and 412, with references.

[4] Steven, *Glasgow Med. Jour.*, Dec., 1898; editorial review of same in *Lancet*, 1899, vol. i., p. 43; clinical account of case in *Internat. Clinics*, 1897, vol. ii., July, p. 195, with 4 illustrations (an interesting case leading to pronounced hemiatrophy of the face, body, and extremities, with deformity and fibrous ankylosis of the joints).

[5] Brissaud, *La Presse médicale*, 1897, p. 285—full abstract in *Brit. Jour. Derm.*, 1897, p. 367—reviews the various theories (with many references).

early stage, both having the same anatomic basis, the cell exudation bringing about the first change—narrowing of the vessels, fibrillar tissue formation, and atrophic changes; the pinkish or violaceous zone is due to collateral hyperemia around an anemic area. Duhring found in a soft, pliable, whitish patch of some months' duration a condensation of the connective tissue of the corium, with a shrinkage of the papillary layer.

Diagnosis.—In well-marked cases of diffused scleroderma the characters—rigidity, stiffness, hardness, and hide-bound condition of the skin, with usually more or less pigmentation—are quite distinctive and scarcely admit of error. In the less marked and obscure examples possible confusion might occur with Raynaud's disease, the brawny induration sometimes observed in scorbutus, myxedema, and leprosy, but the features and mode of onset of these several affections are clearly different. The nervous phenomena, the usually preceding and long-continued and often periodic stasic and anemic conditions of the favorite limited regions in Raynaud's disease, are differential points of value, and together with the absence of any tendency to extensive hardening or thickening will usually serve to prevent a mistake in this direction. The localization of the brawny hardness of scurvy, the purpuric element, and other symptoms are distinct from those of scleroderma. The edematous stage observed in some cases presents a similarity to myxedema, but the distribution and mode of onset of the latter, the absence of sclerotic and other features, are different. Leprosy can scarcely be confounded with diffuse scleroderma, the sensory disturbances usually present and often preceding the development of the cutaneous symptoms in the former, the absence of tendency to brawny hardening, the history of the case, and the exposure to the disease are points to be considered. The malady can scarcely be mistaken for angioma pigmentosum et atrophicum. Sclerema neonatorum, a somewhat allied disease, is an affection of earliest infancy, whereas scleroderma has never been noted before the second year of life.

The early white plaques of morphea—circumscribed scleroderma—in some cases resemble closely similar areas not infrequently seen in leprosy, but the symptoms and characters of the latter already noted are of different nature. The morpheic white areas may also bear resemblance to vitiligo, but in the latter the sole essential symptom is loss of pigment—no thickening or other change in the skin. In women a mistake between carcinomatous skin invasion of the breast (cancer en cuirasse) and the circumscribed sclerodermic disease has been made, but careful investigation should prevent error.

Prognosis.—The outcome in a given case of either variety as regards cure is uncertain; the diffused type is often fatal, usually from some intercurrent affection superinduced by the patient's condition. In those in which the chest is practically incased in an unyielding armor, and the mouth narrowed and fixed, and the jaws firm, interfering with respiration and nutrition, the prospect is unfavorable. According to Méneau, the scleroderma, progressive in char-

acter, beginning at the extremities and spreading to other parts, is generally fatal. On the other hand, in many extensive cases and seemingly unfavorable, if decided atrophic changes have not occurred, recovery takes place.

The circumscribed form—morphea—is a relatively mild affection, often persisting, it is true, and in some cases, almost indefinitely, but is not necessarily dangerous, and very often, after some months or a year or two, either as the result of treatment and sometimes spontaneously, complete recovery ensues. Considerable deformity may, however, result in the rarer instances in which atrophy takes place.

Treatment.—The patient's general health must receive proper attention, and such tonics as quinin, strychnin, iron, arsenic, sodium salicylate, and cod-liver oil have an important influence in some cases. Of these, several, arsenic, sodium salicylate, and cod-liver oil have in my experience been the most valuable, and probably possess more than a simple tonic and alterative value. My own observations, however, have concerned, for the most part, the circumscribed forms of the disease. In extensive cases, in addition to those remedies named, the administration of pilocarpin, properly supported with stimulants and tonics, and its action on the sweat-glands promoted by warm clothing or bed-covering, is of some value when the sweat secretion is markedly in abeyance. Recently thyroid extract has been advocated, but the reports are at variance. Osler has not been favorably impressed with its use, although still recommending its trial. The cases mentioned by Lewin and Heller, in which this treatment was adopted, were not materially influenced, and this was also the experience of Uhlenhuth, Dreschfeld,[1] and some others. On the other hand, Marsh,[2] Lustgarten,[3] Gayet,[4] and Eddowes[5] have seen betterment take place. In one case under my own care, of somewhat extensive sclerodermic band type, it was administered, but the effect was negative. As yet, therefore, the exact value of this remedy remains to be determined—it should, however, be tried, in all diffused cases at least.

The local treatment most efficacious consists essentially in the use of friction with oils or ointments and massage. The applications should usually be of mild character, or in limited, obstinate, non-irritable areas, quite stimulating. As a mild ointment may be mentioned one containing salicylic acid, 10 grains (0.65), cacao-butter, 2 drams (8.), lanolin, 2 drams (8.), petrolatum, 4 drams (16.); or 1 or 2 per cent. salicylated oil can be used. In the hard, thickened, sclerodermic areas in the circumscribed form I have used with advantage an oil consisting of 1 or 2 parts of oil of turpentine with 6 parts oil of sweet almonds; and an ointment of 2 parts oil of turpentine, 1 part beta-naphthol, 2 parts oil of sweet almonds, and 10 parts

[1] Dreschfeld, *Medical Chronicle*, 1896–97, vol. vi., p. 263.
[2] Marsh, *Med. News*, vol. lxvi., 1895, p. 427.
[3] Lustgarten, *Jour. Cutan. Dis.*, 1895, p. 27 (brief reference only).
[4] Gayet, *Jour. mal. cutan.*, Jan., 1900.
[5] Eddowes, *Brit. Jour. Derm.*, 1899, p. 325.

lanolin; and in the tough band areas on the extremities, sometimes associated with paroxysmal pain, an ointment containing 5 or 10 grains (0.35–0.65) of menthol and ½ dram (2.) of chloroform to the ounce.

In the typical soft or moderately hard areas of morphea, especially in the earliest stages, the mild applications are to be used, the stronger sometimes tending to produce irritation. Electric treatment, consisting of general and local galvanization, has been commended by some observers; with the former I have had no experience, but the latter, using a current of 2 to 10 milliampères, with friction movements of the two electrodes—labile application—has seemed to me of some advantage; likewise the use of the static battery roller electrodes made over the part, while covered with the clothing or some fabric. In the past few years favorable statements have been made of electrolysis in the treatment of circumscribed patches by Brocq,[1] Darier and Gaston,[2] and Allen.[3] I have had no experience with this method. It is employed in the same manner as in the removal of superfluous hairs: current strength between ½ to 10 milliampères, according to sensitiveness of the patient and the integumentary conditions; the stronger current in the more infiltrated areas, if the patient bears it, and in such cases, too, the duration of the application somewhat longer than in the softer and less infiltrated patches. Brocq employs as supplementary to the electrolytic procedure the application of mercurial plaster, which, I believe, should have a share in the credit for the good results claimed by him.

SCLEREMA NEONATORUM.

Synonyms.—Scleroderma neonatorum; Sclerema of the new-born; Underwood's disease; *Fr.*, Sclerémè des nouveau-nés; Algidité progressive; L'endurcissement athrepsique (Parrot); *Ger.*, Das Sklerem der Neugeborenen; Das Fettsklerem.

Symptoms.—This rare disease of infancy, first described by Underwood,[4] shows itself usually at or shortly after birth, and, as a rule, first manifests itself upon the lower extremities, and more or less rapidly invades other parts, in most cases the general involvement ensuing within three or four days. In some instances jaundice has been associated. The skin is at first generally whitish and waxy in appearance; it later becomes faintly livid or mottled, and is hard, stiff, leathery, and tense, and the surface cold. It does not pit upon pressure. Fusion or agglutination with the subjacent parts is noted, and in consequence of this or as a result of induration of the integument, or of both, the infant is as if frozen or hewn from marble; it is unable to move or suckle, respires feebly, and usually, already weakened by intestinal disorders, pneumonic or circulatory disturbance, the pulse falls, the temperature drops to several degrees below normal, and it perishes in a few days or one or two weeks. In those cases in which it appears to

[1] Brocq, *Annales*, 1898, No. 2.
[2] Darier and Gaston, *ibid.*, 1897, p. 451.
[3] Allen, *Jour. Cutan. Dis.*, Jan., 1899, p. 40.
[4] Underwood, *Diseases of Children*, 1784, p. 76.

be congenital or develops immediately at birth, death usually results in one or two days. In extremely exceptional instances the disease, after involving a small portion of the surface, retrogresses, the involved tissues soften, regain their elasticity, and recovery ensues; or it may remain stationary, for a time at least, and resemble somewhat scleroderma in the adult.[1]

Etiology.—Fortunately the malady is extremely rare, appearing within the first ten days of life;[2] and the cases recorded have for the most part been in emaciated or atrophic infants in maternity wards or foundling asylums. Both Underwood and Parrot consider it an institution disease, often in overcrowded rooms, and associated with bad hygiene and improper feeding. Some cases seem to be congenital; others develop in a day or two after birth without recognizable cause; in others it appears several days after birth, apparently as a result of constitutional diseases which rapidly depress or drain the vitality and bring on collapse, such as diarrhea, lung affections, cardiac weakness, etc. According to J. L. Smith,[3] a considerable proportion of infants with this disease are prematurely born.

Pathology.—Although the disease had been previously described by Underwood and a few others more than a hundred years ago, it was not until Parrot's [4] observations that the confusion between this affection and œdema neonatorum was dissipated, although there is yet a not uncommon belief that these two affections are allied, and that they may be also closely related respectively to the sclerous and edematous types of scleroderma, a view which has, I believe, much in its favor. Langer [5] looks upon the malady as due to solidification of the fat, resulting from the temperature depression, the fat of the new-born containing relatively so much palmatin and stearin, which readily solidifies when the body-heat drops below normal—a view which scarcely accords with the anatomic findings of Parrot and Ballantyne,[6] who found practically a "dried-out" skin, some thickening of the layers and diminution of the fat, and no true sclerosis and no serous effusion, the drying out being due to the diarrhea. Wiederhofer[7] and Soltmann[8] also practically accept the belief that the draining of the tissues by serum loss is of pathologic import.

[1] Barr, *Brit. Med. Jour.*, May 4, 1889; Bunch, *Brit. Jour Derm.*, 1898. p. 145 (case demonstration); Pringle, *ibid.*, 1899, p. 290 (case demonstration); and W. Browning, *Jour. Cutan. Dis.*, 1900, p. 563, report interesting cases of somewhat limited and peculiar character.

[2] Money, *Lancet*, 1888, vol. ii., p. 811, records 2 cases, sisters, developing one or two months after birth, associated with paralysis, death ensuing two or several months later; another sister had previously died from the same disease, also developing late and lasting a few months before death ensued. The only other child—a boy of two and one-half years—had so far remained free. I am not sure that these cases belong to this disease; they are apparently connecting cases between this affection and some cases of scleroderma, as observed in the adult.

[3] J. L. Smith, *Diseases of Children*, eighth edit., 1896, p. 149.

[4] Parrot, *Clinique des Nouveau-nés, L'Athrepsie*, Paris, 1877.

[5] Langer, *Wien. med. Presse*, 1881, pp. 1375 and 1412.

[6] Ballantyne, *Brit. Med. Jour.*, Feb. 22, 1890, p. 403, and editorial comment, p. 439.

[7] Wiederhofer, in Gerhardt's *Handbuch der Kinderkrankheiten*, vol. iv., 1880, 2. Abth., p. 557.

[8] Soltmann, Eulenberg's *Real-Encyclopädie*, vol. xxii., 1899, p. 482 (excellent contribution both as to sclerema neonatorum and œdema neonatorum, with full bibliography).

Northrup, quoted by Smith, and others found histologically nothing especially abnormal.

Prognosis and Treatment.—Apparently only cases in which the sclerema is not general or complete recover, and these are rare, a fatal end being the almost invariable result. Treatment consists in measures to increase the body-heat and the administration of proper alimentation and stimulants, by tubes passed through nose or mouth to the pharynx and stomach, or by the rectum, or both.

OEDEMA NEONATORUM.

Synonyms.—Edema of the new-born ; *Ger.*, Das Sklerödem.

Symptoms.—The characteristic symptoms of this affection are edema and variable hardness or induration, in both these respects corresponding somewhat to the edematous type of scleroderma in the adult. It begins almost invariably on the legs, very exceptionally on other parts, such as the face or trunk, and, as a rule, in the first day or two of life. It is sometimes preceded by drowsiness, or this develops with the cutaneous phenomena. Beginning usually on the lower part of the legs, it gradually creeps upward, and about the same time the hands are likely to show involvement, and then other parts. It is rarely general. Exceptionally it is limited to the lower portion of both extremities, especially the hands and feet (J. L. Smith). To the touch the parts are either somewhat rigid, due to enormous serous infiltration, or they are soft and doughy, and pit upon moderate pressure. The skin is of a yellowish, dusky, or livid color, and sometimes glossy or shining. The general symptoms of drowsiness, feeble circulation, and weakened respiratory action usually increase; the temperature is noted to be below the normal, and sooner or later, with some exceptions, from some intercurrent affection or complication superinduced by the patient's condition, such as diarrhea, pulmonary disease, nephritis, with collapse, lead rapidly to the end.

Its chief differences from sclerema neonatorum are the edematous infiltration, always most marked in dependent regions, the absence of pronounced integumentary sclerosis and articular immobility, the pitting upon pressure, and less general rigidity, and its less generalized distribution.

Etiology.—It develops in the first few days of life. The causes seem to vary in different cases, although, as a rule, feeble, ill-nourished, premature infants, with marked cardiac weakness, are its usual subjects, and especially in the children of ill-fed and insufficiently nourished mothers. Pulmonary atelectasis, nephritis (Elsässer, Henoch),[1] hereditary syphilis (Soltmann[2]), erysipelas (J. L. Smith), incomplete establishment of respiration (Dumas), exposure to cold immediately after birth (Crocker[3]), have been variously considered as influential in some cases. On the other hand, in Blacker's[4] case there seemed an entire absence of recognizable factors.

[1] Quoted by J. Lewis Smith, *Diseases of Children*, eighth edit., p. 151, 1896.
[2] Soltmann, *loc. cit.*
[3] Crocker, *Diseases of the Skin*, second edit., p. 422.
[4] Blacker, *Brit. Jour. Derm.*, 1898, p. 87 (case demonstration).

Pathology.—Ballantyne[1] ascribes œdema neonatorum to disturbances of the cardiac, pulmonary, renal, or vascular system, believing it akin to anasarca in the adult. Dumas, from his studies and observations, considers the disease as a symptom of phlegmasia alba dolens, which is developed during the first days after birth, but that the venous thrombosis is more frequently located in the inferior vena cava than it is in the adult. Jarisch[2] believes the various observations made and the autopsy findings, so often diverse, point rather to the condition being a symptom or a part of other grave diseases, rather than an independent malady. At all events, it consists essentially of an edema—a serous transudation into the subcutaneous tissue. The fat is found to be somewhat dense, crumbly, or granular, and not infrequently of a yellowish or brownish color. Autopsies have disclosed in some instances pulmonary disease, venous thrombosis, nephritis, enlarged liver, etc.

Prognosis and Treatment.—According to Soltmann, at least 80 to 90 per cent. of the cases die. Treatment is essentially the same as in sclerema neonatorum—increasing and maintaining the body-heat, sufficient and proper nourishment, and stimulants. Dumas advises, as a preventive measure, suitable care to establish thoroughly the respiratory function in the new-born at the moment of birth, and not too hasty ligation of the cord.

ELEPHANTIASIS.[3]

Synonyms.—Elephantiasis Arabum ; Pachydermia ; Barbadoes leg ; Morbus elephas ; Elephant leg ; Elephantiasis indica ; Bucnemia tropica ; Spargosis ; *Fr.*, Éléphantiasis.

Definition.—A chronic endemic or sporadic disease of the skin and subcutaneous tissues, usually of the leg or genitalia, characterized by enlargement and deformity, lymphangitis, swelling, edema, thickening, induration, pigmentation, and more or less papillary growth. In the description following the term non-parasitic will be applied to those cases not due to filaria.

Symptoms.—The malady usually begins, in the endemic variety, and less commonly in sporadic cases also, with general symptoms of fever (elephantoid fever), chilliness, often nausea, and sometimes vomiting, and, in some instances, more or less rheumatic pain, especially about the lumbar region. Along with these, concomitantly or precursorily, there is an erysipelatous or pseudo-erysipelatous inflammation of the part, with swelling, pain, heat, redness, and, as a rule, lymphangitis. There may be considerable edema, varying somewhat in different cases, and not infrequently, especially if there is marked lymphatic

[1] *Loc. cit.* [2] Jarisch, *Hautkrankheiten*, 1900, p. 824.

[3] Literature: P. Manson, *Tropical Diseases*, London, 1898 ; chapter on "The Filariæ Sanguinis Hominis and Filaria Disease," in Davidson's *Hygiene and Diseases of Warm Climates*, Edinburgh and London, 1893. Manson's earlier contributions on this subject are practically reviewed in these publications, and references to the principal observations of other writers are made. W. M. Mastin, "The History of Filaria Sanguinis Hominis ; its Discovery in the United States," *Annals of Surgery*, Nov., 1888; Esmarch and Kulenkampff, *Die Elephantiasistichen Formen*, Hamburg, 1885, with numerous illustrations; full bibliography is given by Hyde, Morrow's *System*, vol. iii. (Dermatology), p. 451.

involvement, more or less discharge of a clear or milky character. The inflammation, in some cases, takes its origin in a local lesion, such as a slight cutaneous abrasion, injury, or scar; but in the large majority of instances manifests itself without any recognizable local cause. The part is considerably enlarged, sometimes tense, and only pitting upon pronounced pressure; or the condition, and especially after a few days, is more of the nature of an edema, somewhat doughy, and which pits quite readily. In several days the acuteness of the symptoms, both general and local, has abated, the former often entirely disappeared, and gradually the swelling, tenderness, and redness subside, and, after a few weeks or longer, as a result of treatment or spontaneously, the affection is apparently at end, except that the region involved is observed to be somewhat larger than before the onset. This enlargement is, however, in most cases, often scarcely perceptible after the first attack; later, with each succeeding seizure, it becomes more and more noticeable. The period of freedom or quiescence varies from several weeks to some months.

The amount of increase depends measurably upon the duration and severity of the attack, the latter in some being slight and relatively transitory, in others intensely acute and protracted. Exceptionally it is of slight character, but practically continuous, and the enlargement, though trifling, is steadily progressive. After months or one or more years the enlargement or hypertrophy becomes conspicuous, the part is chronically swollen, edematous, and hard; the skin thickened, the normal lines and folds exaggerated, the papillæ enlarged and prominent, and with often more or less fissuring and pigmentation. This goes on, there is gradual increase in size, the parts in some instances reaching enormous proportions; the skin becomes rough and warty, eczematous inflammation is often superadded, and, sooner or later, ulcers, superficial or deep, either spontaneously or from injury or from varicose veins, form—which, together with the crusting and moderate scaliness, and sometimes with intermittent or continuous lymph-like discharge, present a striking and characteristic picture. In a minority of cases, more especially until the disease is well advanced, the surface remains comparatively smooth. The course of the malady, when once thoroughly established, is usually steadily, although often scarcely perceptibly, progressive; but there are in most cases periods of comparative inactivity, or, after reaching a certain development, the disease may, for a time at least, remain stationary. The accumulated crusts, composed of epidermis, discharge blood and dirt, undergo variable change or decomposition, and there is emitted an offensive, and often penetrating, odor.

The general and local symptoms in the endemic variety are essentially similar whatever the part attacked, varying in intensity in different patients. In the scrotal or genital form there is often a good deal of pain in the parts themselves and along the spermatic cords. In both the leg and genital cases the inguinal glands are enlarged to a varying degree, and sometimes tender and painful. In the non-parasitic cases, usually met with outside of the endemic districts or countries, the general symptoms are rarely marked, and often absent, depending upon the intensity of the erysipelatous inflammation. In these latter this inflammation seems to be similar to, or

identical with, ordinary erysipelas, and according to extent and severity will the constitutional involvement be insignificant or pronounced. In others, both of the endemic and non-parasitic kinds, the disease is insidious, slowly progressive, and without systemic disturbance. Much depends upon the character of the case, its extent, and the nature of the operative cause or causes, as will be referred to under etiology and pathology.

The regions involved in elephantiasis are most commonly the legs (elephantiasis cruris) and, less frequently, in the severe forms at least, the genitalia (elephantiasis genitalium). Other parts may, however, be the seat of the disease, as more or less generalized, as in Felkin's case,[1] the arm and hand (Crocker, Mackenzie, Hoyer, and others),[2] the side of the face (Richards, Hebra and Kaposi, Moncorvo, and others),[3] eyelids (Gorand),[4] and other regions. It is probable, though, that many of these cases of anomalous localization are not true examples of the disease, but rather unusual forms of fibroma or the allied condition, dermatolysis. In elephantiasis of the leg quite frequently but one leg is involved, and the right more commonly; in the endemic variety, however, both legs are often invaded. In some cases, more particularly the sporadic, it may be limited to the foot and ankle, for a time at least. A verrucous surface is not uncommon on the dorsum of the foot, usually covered with horny epidermis or sodden accumulation. Generally, however, the whole leg up to the middle thigh shows variable enlargement, being most marked on the lower part, where it may reach three or more times the normal circumference.[5] While in some cases, more particularly of moderate development, it is smooth, or relatively so, and well shapen, as a rule it is rough and irregular or warty, scaly, crusted, and much deformed, often deserving the term elephant leg, by which it is sometimes described. The disease varies considerably, however, as to growth, and cases of all degrees of severity are met with, from the comparatively insignificant to the extreme condition which hinders the patient from getting about.

Elephantiasis of the genital region may involve the entire parts or only the scrotum or the penis. Almost invariably, however, even when the hypertrophic changes are conspicuously pronounced on one part, the other is enlarged also, but to relatively less extent. The enlargement varies from insignificant to enormous dimensions, in one instance the scrotal growth weighing 110 pounds (Clot-Bey).[6] The neighboring lymphatic glands are usually enlarged.

[1] Felkin, *Edinburgh Med. Jour.*, vol. xxxiv., part ii., 1889, p. 779.

[2] Crocker, *Diseases of the Skin*, second edit., p. 426, also refers to Mackenzie's case; Hoyer, *Buffalo Med. and Surg. Jour.*, vol. xxv., 1885–86, p. 452 (with illustration).

[3] Moncorvo, *Pediatrics*, 1897, p. 481.

[4] Gorand, *Annales de la Polyclinique de Bordeaux*, April, 1892, p. 105 (3 cases); Schuster (Gussenbauer's clinic), *Prager med. Wochenschr.*, 1880, p. 201, reports a case of elephantiasic nose enlargement, developed after an injury, associated with, however, fibromatous or fibroneuromatous general integumentary lesions; a tabulation of a number of cases of localized elephantiasis with literature references is given; these cases can scarcely be called, however, elephantiasis, as this term is generally understood.

[5] McCall Anderson, *Jour. Cutan. Med.*, 1868, vol. i., p. 180, records a case in which the calf circumference reached 27 inches.

[6] Quoted by Schwimmer, Ziemssen's *Handbook of Skin Diseases*, p. 227; Manson, *Tropical Diseases*, 1898, p. 483, states the largest recorded weight to be 224 pounds, but gives no reference as to source.

The malady, when limited to the genitalia, varies very little, if at all, from that of the legs, but is probably much more insidious and progressive, with less tendency to extreme acute exacerbations than the disease of the latter region. There is often considerable milky lymphatic discharge, and the enormous tumor, sometimes hanging as far down as below the knees, is a source of great discomfort, a dragging feeling, and often pain. Eczemas and ulcerations are frequently added, and increase the patient's misery still further. In women the brunt of the disease, when involving the genitalia, usually falls upon the labia majora; the clitoris and other parts may, however, and almost always in extreme cases, share in the hypertrophic process. The condition may be a slight one, and give rise to but little discomfort, or it may eventually be excessive.

Lymph-scrotum (varix lymphaticus; lymph tumors; nævoid elephantiasis; milky exudation of the scrotum) is to be looked upon as a form of elephantiasis, probably occupying a middle ground between this latter and *chyluria*. According to Manson, the characteristic feature of this affection is the presence, on the surface, of dilated lymphatics and lymphatic vesicles, which often rupture and discharge coagulable lymph. There is a certain amount of hypertrophic enlargement, and often with attacks of erysipelatous inflammation and elephantoid fever. Manson believes that the three diseases—elephantiasis, lymph-scrotum, and chyluria—and their varieties may be considered as but accidental modifications of the same pathologic conditions and etiologically identical.

Elephantiasis telangiectodes, which is also known as nævoid elephantiasis and telangiectatic elephantiasis, is a hypertrophic development, which, according to Virchow, has a congenital origin, and which subsequently undergoes hypertrophy.[1] The elephantiasic enlargement may be slight or may attain considerable dimensions. The hypertrophic growth is thought by Virchow to be due to the overnutrition of the part, resulting from the underlying increase of the vascular supply, the deep vessels often attaining considerable size. In some cases the tissue and vessels enlarge progressively, and while the surface is not necessarily changed, occasionally increased vascular supply ensues superficially and a reddish aspect is presented.

Acromegaly[2] is a hypertrophic condition, first clearly presented in Marie's classic paper, which deserves brief mention in connection with elephantiasis. The bones and soft parts, especially of the face, feet, and hands, undergo thickening and increase in volume, in extreme cases almost giant-like in appearance. The affection is usually slow and insidious, the individual scarcely knowing when the process began.

[1] Merrill Ricketts, *Jour. Cutan. Dis.*, 1889, p. 140 (with illustration), reports an interesting case involving the chin, lower lip, and contiguous lower part of the cheeks, in which increased growth did not ensue until adult life was reached.

[2] Literature: Paul Marie, *Revue de méd.*, 1886, p. 297, and Marie and Marinesco (pathologic anatomy), *Trans. Internat. Cong.*, Berlin, 1890; Arnold, *Virchow's Archiv*, vol. cxxxv., p. 1; Souza-Leite, *De l'Acromegalie*, Paris, 1890—abs. of 49 cases; translation by Syd. Soc'y, London; F. A. Packard, *Amer. Jour. Med. Sci.*, June, 1892, p. 657; Collins, *Jour. Nervous and Mental Dis.*, Dec., 1892 (digest of cases since Souza-Leite's publication), and Feb., 1893 (bibliography); Dercum, *Amer. Jour. Med. Sci.*, Mch., 1893; Church and Hessert, *Med. Record*, vol. xliii., 1893, p. 545; W. G. Shallcross, *Philada. Med. Jour.*, April 20, 1901.

The arms and legs, especially toward the distal ends, share materially in the hypertrophic enlargement, and all parts, even the trunk (as in one of Dercum's cases), may be involved also. In the face, the lower jaw, cheek bones, nose, supra-orbital prominences, and ears usually stand out prominently. In the hands the parts are often huge, broad, and flat, the fingers markedly increased in volume, and the ends blunt. The nails are, as a rule, thick and flat, but not usually widened; as Bramwell[1] remarks, the nails appear to be small in proportion to the size of the fingers, and in most cases grooved longitudinally. The hairs on the affected regions are frequently stronger, and exceptionally there is a tendency to more or less general hairy development (Weir Mitchell). The skin, more particularly of the face and extremities, is more or less thickened, and not readily pinched up into folds, and often exhibits pigmentary spots; occasionally more or less general pigmentation develops (Weir Mitchell). The sweat function is usually increased. According to Souza Leite, headache is a frequent concomitant. The cause of the disease is not known; Marie's suggestion of involvement of the pituitary body and its enlargement has been noted in a number of autopsies, but in other cases it has been found to be wholly normal. Klebs's idea that it might be due to persistence and enlargement of the thymus gland is also without sufficient corroborative data to give it standing. In fact, postmortem findings have shown in isolated instances enlargement of one or other of the various glandular structures, as well as nerve and cerebral lesions,[2] but a judicial review of the cases leaves nothing substantial as to its nature and causes.

Anatomically there is practically no change noted in the epidermis except pigmentation of the prickle layer, but both cutis and hypoderm are thickened, essentially consisting of collagenous hypertrophy (Unna). Degeneration of muscles, blood-vessels, and nerves has also been observed; the walls of the arteries and veins and the sheaths of the nerves are thickened.

Etiology.—Elephantiasis occurs in all parts of the world, but is much more frequent in tropical climates, where it is more or less endemic. In the endemic districts it is chiefly in malarial regions, in the lowlands, and also along the sea-coast and sea islands. Manson has shown that the mosquito is a probable factor—an intermediate host, the filaria hominis sanguinis, being the essential agent. Poor food, unhygienic living, and similar conditions are doubtless of contributory influence. It is rare in the well-to-do and wealthy classes. It is not contagious, nor is it hereditary. In endemic districts, it is true, owing to the facts of the common exposure to the same influences, the disease is often seen in two or more members of the family; according to Richards,[3] in a large percentage of cases (about 75 per cent. in his tabulation) the disease was present in one or both parents. Occasional instances of the coexistence of leprosy

[1] Bramwell, *Atlas of Clinical Medicine*, vol. ii., 1893, p. 104.

[2] In Waldo's case, *Brit. Med. Jour.*, Mch. 22, 1890, cavities were found both in cerebrum and cerebellum.

[3] Vincent Richards, chapter on "Elephantiasis Arabum," in Fox and Farquhar's *Endemic Skin and Other Diseases* London, 1876.

and elephantiasis have been observed (Richards), although the association is purely an accidental one, the two diseases being in no way related. The malady is seen in both sexes and at all ages, but is much more frequent in early adult and middle life, although it is occasionally observed in childhood, and in some instances as a congenital affection.[1] The disease is largely confined to males, the proportion being about 3 to 1, and the darker races are the more susceptible.

While the filaria—for which Manson suggests the name of filaria hominis nocturna, inasmuch as it is found circulating in the blood only at night—is to be accepted as an important, if not the sole, factor in the endemic disease, there are, however, many cases which present essentially the same symptomatology which are entirely independent of this agent. In fact, whatever gives rise to inflammation or obstruction of the lymphatics and veins may lead to this hypertrophic development. For example, disease and enucleation of the inguinal glands have been known to be followed by elephantiasis, of varying degree, of the genitalia, both in men and women, of which many cases have been reported in recent years by Lassar,[2] Riedel,[3] Brouardel,[4] Koch,[5] and many others. Obstruction produced by various tumors, neoplasms, ulcerations, chronic skin diseases, phlegmasia dolens, syphilis (Francis),[6] gonorrhea (Humbert, Farner, and others),[7] and sometimes following local injury (Berry, Hutchinson, and others).[8]

Pathology.—The pathologic changes are the result, as already intimated, of lymphatic obstruction, and this may be due to various causes. According to Manson, Lewis, Bancroft, Sabouraud, and others, there remains no doubt that in the endemic cases the obstruc-

[1] Barwell, *London Path. Soc'y Trans.*, 1881, p. 282 (unilateral—head and face; bones and soft parts; with illustration); Spietschka, *Archiv*, 1891, vol. xxiii., p. 745 (a case involving both legs, with illustration and literature references); Nonne, *Virchow's Archiv*, vol. cxxv., 1891, p. 189 (4 cases from same family, in which it had prevailed for several generations; 6 illustrations); Coley, *N. Y. Med. Jour.*, June 20, 1891 (of face and scalp, with illustration—apparently allied to fibroma or dermatolysis; good result from operation); Uthemann, *Deutsche med. Wochenschr.*, 1895, p. 826 (penis and scrotum—apparently beginning at age of four—two illustrations, showing condition and result of operation); Busey, *Congenital Occlusion and Dilatation of Lymph Channels*, New York, 1878; Moncorvo, *loc. cit.*, reports 2 new cases and refers to 10 others previously reported by him; Jopson, *Arch. Pediatrics*, 1898, vol. xv., p. 173, records 2 cases, brothers, aged one and one-half and four, involving feet and legs; father had suffered from a similar affection in childhood, which was later outgrown; gives brief review of the subject, with references.

[2] Lassar, *Dermatolog. Zeitschrift*, 1894, p. 550.

[3] Riedel, *Langenbeck's Archiv*, 1894, Bd. xlvii., p. 216.

[4] Brouardel, *Annales*, 1896, p. 863.

[5] Koch, *Archiv*, 1896, vol. xxxiv., p. 203 (Koch describes a number of cases of varying enlargement in women, and gives references to the contributions of Virchow, Mayer, Neisser, Jacobi, Lesser, Fritsch, and Schroeder).

[6] A. G. Francis, *Brit. Jour. Derm.*, 1894, p. 225, gives notes of several cases associated with tertiary syphilis.

[7] Humbert, *La Semaine Med.*, May 25, 1894 (case presentation—penis, consequent upon a gonorrheal lymphangitis); Farner, *Centralbl. für Gynäkologie*, 1885, No. 17, abs. in *Münch. med. Wochenschr.*, May 7, 1895 (female genitalia—apparently originating from an acute gonorrhea).

[8] Berry, *Provincial Med. Jour.*, vol. viii., 1889, p. 284 (hand and forearm—2 illustrations—following a burn); Hutchinson, *Clinical Jour.*, 1895–96, p. 29 (brief report—developed after a crush of foot; leg subsequently amputated; later development in other leg).

tion is due to the filaria, probably both directly by their presence in numbers blocking up the lymph-channels, and indirectly by the inflammatory conditions of these vessels or glands which they may provoke. According to Manson, only the embryo filaria is found circulating, the parent filaria living in some part of the lymph-trunk, discharging its ova into the lymph streams, which find their way into some of the glands, in which they find lodgment, and are subsequently hatched out, and then enter the general circulation. Manson's investigations would make it seem probable that the mosquito abstracts some of the embryos from the blood of an affected individual, and, after undergoing some development, these finally find their way into the drinking-water, and are thus conveyed to man. In consequence of obstruction varices of the lymphatics, glandular structures, and veins result, in varying degree, in anastomes by which the embryos get into the blood, and in some cases there is rupture of such formations and discharge of lymph upon the surface.

Many of the non-parasitic cases,—almost all those of our own country, for instance,—Unna[1] believes, result from repeated attacks of streptogenes inflammation (erysipelas, phlegmon, lymphangitis), and independent of any circumscribed stagnatory cause. The persistent recurrent attacks bring on doughy soft edema, and which later becomes harder, with tissue increase and progressive enlargement. He is of the opinion, therefore, that true sporadic cases may be said to develop from incompletely healed erysipelas attacks, those which leave behind disturbances of circulation, and the products of which are not completely absorbed nor all the streptococci destroyed; to this variety he would give the name elephantiasis streptogenes or elephantiasis nostras. Examinations of this variety of the disease by Sabouraud[2] disclosed during the erysipelatous attacks the presence of streptococci of Fehleisen. With each attack or exacerbation, as Sabouraud remarks, there is a fresh advance of edema, and that each new edematous infiltration is probably followed by local organization of the emigrated embryonal cells into connective tissue.

The anatomic studies (Virchow, Kaposi, Mosely and Morison, Marcacci, Crocker, and others) of the disease agree substantially as to the findings. The seat of the changes is essentially the subcutaneous tissue, and the bulk of the enlargement is made up of hypertrophic connective tissue. On section the tissues are found quite firm, with a whitish or yellowish surface, usually exuding a lymph-like, yellowish, sometimes gelatinous, fluid. In addition to the connective-tissue hypertrophy the whole integument is thickened, sometimes moderately, in other cases markedly so. As is to be inferred from the clinical verrucous appearances in some cases, there is often papillary hypertrophy, the papillæ being elongated and broadened. There is often also increase in pigment matter; in the case examined by Mosely and Morison[3] (a negress) a large

[1] Unna, *Histopathology*, p. 493.

[2] Sabouraud, "Sur la parasitologie de l'elephantiasis nostras," *Annales*, May, 1892, pp. 592 and 629.

[3] Mosely and Morison, *Medical News*, April 23, 1887.

amount of pigment granules, chiefly in heaps, was found in the corium beneath the line of the papillæ. There is, in addition, enlargement of blood-vessels and lymphatics. Secondarily, after prolonged duration of the disease, the underlying muscles undergo atrophy and fatty degeneration, and the bones may show enlargement, uniformly or irregularly.

Diagnosis.—The diagnostic characters of beginning elephantiasis are the recurrent erysipelatous inflammation and the gradual enlargement of the parts. To these, in the endemic or filaria variety, and in some of the non-parasitic sporadic cases, the concurrent febrile disturbance is an added factor. The appearances, later in the course of the disease, such as increased size, thickening, induration, often varicosities of lymphatic and venous nature, papillary hypertrophy, etc., are so distinctive that a mistake is scarcely possible. The filaria variety admits of ready recognition by careful examination of the blood drawn during the night, the parasites being quite characteristic; in some cases, however, they are not so abundant, and at least several examinations should be made before an absolute conclusion is reached.

Prognosis.—While the subjects of the disease are necessarily rendered more or less miserable by the weight of the parts and hindrance to locomotion, life itself is rarely endangered. In the endemic parasitic variety much depends, as also in non-parasitic cases, upon the stage at which the patient comes under observation; in the first months of its development there is a possibility, and according to some writers a probability, that the disease can be checked or held in abeyance; when well established, rarely more than palliation is to be expected, although some cases are on record where remarkable benefit followed therapeutic measures. In elephantiasis of the genitalia, more especially in the male and when of the scrotum, the results of surgical removal are satisfactory.

Treatment.—In the endemic or filaria variety of disease the general treatment during the febrile attacks and the cutaneous exacerbations, really resolves itself into the ordinary measures indicated by the symptoms—saline purge or aperients, quinin in full dosage, with or without strychnin, and iron, according to circumstances, and sleep-producing drugs, if needed, such as opiates, phenacetin, sulphonal, and the like. The general management of the exacerbations in the non-parasitic cases depends upon the severity of the erysipelatous outbreak, differing but little, if any, from the above, when such attacks are severe; locally the ordinary applications useful in erysipelatous inflammations, and, if very painful, fomentations of lead-water and laudanum. Rest in the recumbent position is useful in all cases, more perceptibly so in the advanced disease. An important measure in staying the progress of the malady, and even curing it, as attested by Fayrer, is removal, in the early stages, from the endemic region to one in which the disease does not prevail. In the endemic variety Thomasz[1] some years ago reported brilliant results, in the early stages, from calcium sulphid, 1 to 2 grains (0.065–0.13).

[1] Thomasz, *Ceylon Med. Jour.*, Aug., 1888, p. 1.

twice daily, but I have not been able to find a report of such treatment by others, either favorable or unfavorable. Lawrie's[1] hopefulness as to thymol, in 2- to 5-grain doses (0.135–0.32) three or four times daily, based on its apparently successful action in 2 cases of chyluria due to filariæ, and therefore probably useful in elephantiasis, has been negatived by the experience of Manson, Crombie, Williams, and others.[2] The constitutional treatment of elephantiasis during the intermission between the acute exacerbations is symptomatic—tonics, cod-liver oil, etc., if indicated.

In elephantiasis of the leg, along with rest, certain local measures have a value—absolute cleanliness, massage, and compression. Hardaway[3] warmly suggested or indorsed the reducing influence exerted by the rubber bandage well applied. Conjointly with such measures the use of the continuous and interrupted electric currents is strongly recommended by Aranjo.[4] Ligation of the main artery of the limb (Carnochan, Wernher, Bryant, Erickson, Leonard, and others)[5] has often been followed by material reduction in the size of the part, and sometimes with alleged cure. Nerve section has also been practised by Morton and others with decided improvement in a few cases, but there is great risk of secondary trophic and sensory disturbances. As a measure of relief Curl[6] speaks favorably of the results of removing wedge-shaped strips of skin and subcutaneous tissue from time to time; in this manner the leg being considerably reduced in size. The treatment of elephantiasis of the genitalia is operative, and recorded results, chiefly regarding the male genitalia (Osgood, Fayrer, Charles, and others), are extremely favorable, and have become more so, and practically without danger, under the surgery of to-day.[7]

MYXEDEMA.

Synonyms.—Cretinoid edema (Gull); *Fr.*, Myxœdème; Cachexie pachydermique (Charcot); Athyroidie (Besnier); *Ger.*, Myxœdem.

Definition.—A constitutional affection, chiefly in women, induced by atrophy or ablation of the thyroid gland, and characterized by cretinoid changes and edematous swelling, and thickening and induration of the skin and subcutaneous tissues.

[1] Lawrie, *Lancet*, 1891, vol. i., p. 364 (2 cases), and 1892, vol. ii., p. 1247 (letter communication, referring to another case).

[2] Quoted by Manson, Davidson's *Hygiene and Diseases of Warm Climates*, p. 835, with references.

[3] Hardaway, *St. Louis Courier of Medicine*, May, 1879.

[4] Silva Aranjo, *Atlas des Maladies de la Peau*, Rio de Janeiro, part iii., 1889; Moncorvo et Silva Aranjo, "Du traitement de l'elephantiasis par l'électricité," *Journal de Thérapeutique*, 1882, vol. ix., p. 1.

[5] Leonard, *Brit. Med. Jour.*, 1879, vol. i., p. 934, states that he has found statistics (but references and particulars not given) of 69 cases; of these, 40 were cured (3 by digital compression), 13 improved (3 temporarily), and 16 unsuccessful.

[6] Curl, *Jour. Cutan. Dis.*, 1905, p. 402.

[7] Havelock Charles, *Indian Med. Record*, vol. lxii., 1897, p. 165, reports a series of 60 cases successfully treated (abstract in Sajous's *Annual and Analytical Cyclopædia*, 1899, vol. iii., p. 91).

Symptoms.—This somewhat rare malady, which was first clearly described by Sir William Gull[1] in 1873, is usually of slow and insidious development, the earliest symptoms presenting, as a rule, being those of ill-defined general poor health, with, more especially, an anemic condition and disinclination to physical or mental exertion. These become more marked, and then consist of sluggishness of movement, unsteadiness of gait, slow and halting speech, and mental hebetude. The subject becomes mentally dull and listless, the temperature subnormal, and often shows glycosuria or albuminuria. At the same time is noted atrophy in the thyroid, the gland partly or almost wholly disappearing or undergoing fibrous change.

Along with these constitutional symptoms the skin also becomes the seat of peculiar changes. It becomes yellowish and waxy in appearance, thickened, firmly edematous, and swollen, particularly the face, neck, and the extremities. The face is noted to be enlarged and rounded, more or less moon-shaped, the lips, nose, and eyelids are swollen, thickened, and variably indurated, giving the coarsened features an immobile or fixed, expressionless aspect. As a result of these tumefactive changes there is only a slit-like opening between the puffy and swollen eyelids, the nostrils are broadened and thickened, and the lower lip everted and pendulous. There is often an ill-defined, dull-red flush on the cheeks, although, as a whole, the countenance is of a dead yellowish or waxy appearance. The neck also undergoes similar changes, especially the supraclavicular region, where there may be a cushion-like accumulation of fat. The hands show like conditions, becoming massive, deformed, and shapeless, the fingers so swollen and thickened as to give it a broadened, spade-like aspect. The entire surface more or less shares in this peculiar development, the regions of the joints especially showing the thickening and edema-like infiltration, and often to such an extent as seriously to compromise the natural suppleness and mobility of the parts. In some instances there is variation in the degree of swelling, and, according to Ord,[2] this is particularly so with the face, and generally having a relationship with the intensity of the general symptoms, especially the nervous symptoms, partial amelioration of the swelling being followed by headache and neuralgia, and its increase or recurrence by relief of the severity of the nervous phenomena.

The skin is usually dry and rough, with, in some places, a translucent look. It is, as a rule, harsh and hard to the touch, with often a fine branny scurfiness, occasionally lamellar, and perspiration is lessened or wholly absent. The hair likewise becomes harsh, dry, and scanty, and there may finally be partial or almost complete scalp alopecia. In addition, especially later in the malady, the skin may be more or less pigmented, in areas or generalized, as in Addison's disease, although rarely to so pronounced an extent or depth. The soft parts of the buccal cavity, especially the tongue and uvula and the arches, share in the swollen, edematous process. The edema, while apparently similar in appearance to the edema of renal disease,

[1] Gull, *London Clin. Soc'y Trans.*, 1874, vol. vii., p. 180.
[2] W. M. Ord, "Myxedema and Allied Disorders," *Brit. Med. Jour.*, 1898, ii., p. 1473.

differs in being firm and not pitting on pressure; nor is it influenced by position.

Etiology and Pathology.—The disease is rare and chiefly seen in adult life, usually about the middle period, and is predominantly confined to the female sex. While in many respects the disease is etiologically obscure, it is now known that it is connected with atrophy or loss of the thyroid gland. This is disclosed by clinical observation as well as by the fact that the condition (so-called "sporadic cretinism") is noted sporadically in congenital deficiency of the gland and also following, in a large proportion of instances, its partial or complete surgical removal. According to the analytic study of the committee (Ord, Cavafy, Goodhart, Horsley, Mackenzie, and others) of the London Clinical Society,[1] it developed in 69 out of 408 instances in which the gland was completely extirpated, and in no case in which removal was not complete. Billroth,[2] on the other hand, had never noticed the occurrence of myxedema after the extirpation of goiter. Moreover, question has been raised by some observers as to the identity of true myxedema and that condition, the so-called "cachexia strumipriva" of Reverdin and others, which develops after the extirpation of goiter. Aggregate observations, however, fortified as they are by the investigations of the London Clinical Society Committee and those of Hun and others, do not afford substantial support to this doubt.

Ord, who gave the malady the name of myxedema, found that the edematous infiltration was due to a proliferation and deposit of mucin in the superficial connective tissue, the amount present estimated to be fifty times the normal quantity. According to Hun, however, the connective-tissue spaces in the corium were pushed asunder by a fluid which was not mucin. This observer also found a general atheromatous endarteritis, although this is not in accord with the observations of Caspary, Grawitz, and others (quoted by Kaposi). There is, however, fairly general agreement as to the involvement of the nervous system, and Charcot considered the implication of the nerve-centers as the primary factor, and the other pathologic changes as secondary to this. The thyroid gland, with rare exceptions, has always been found atrophied. Kaposi (*loc. cit.*) has stated that various observers (not named) were unable to demonstrate clinically atrophy of the thyroid gland; Adami,[3] on the contrary, as more in consonance with common belief, was not able to find an account of any autopsy upon cases diagnosed clinically as myxedema in which the gland was found normal or but little affected.[4]

Diagnosis.—This is rarely a matter of difficulty if the case is at all developed, as the aggregate symptoms are striking and characteristic; there is merely a faint similarity, never a puzzling resem-

[1] "Report on Myxedema," *London Clin. Soc'y Trans.*, supplement to vol. xxi., 1888 (a most exhaustive and comprehensive investigation).

[2] Billroth, quoted by Kaposi, *Diseases of the Skin*, p. 475.

[3] Adami, "Internal Secretions Considered in Their Physiologic, Pathologic, and Clinical Aspects," *Trans. Cong. Amer. Phy. and Surg.*, vol. iv., 1897, p. 103 (a valuable and suggestive paper, with review of the subject and bibliography).

[4] See also Hun's paper (150 collated cases), *Amer. Jour. Med. Sci.*, Aug., 1888, p. 196.

blance, to some cases of acromegaly, as in the latter the bones are greatly enlarged and there is also lacking the rounded or moon-shaped face, that of acromegaly being an elongated oval. The nervous symptoms and the changes in the thyroid are also distinctive of myxedema. The malady can scarcely be confused with the edema of renal disease or with the infiltrated nodular swelling of leprosy.

Prognosis and Treatment.—The course of myxedema is persistent, progressive, and chronic, and if untreated usually leads sooner or later to the development of a grave mental and physical disorder, marasmic condition, and a fatal ending. Fortunately, since the discovery of the value of thyroid extract, a greater control has been exercised over the disease, as noted by Bircher, Beatty, Putnam, Osler, Murray, and others.[1] The dose should at first be small and cautiously increased, as emphasized by 2 instances in patients suffering from heart disease, under Murray's observation, in which death from syncope immediately due to exertion followed the prolonged administration of thyroid for myxedema.

DERMATOLYSIS.

Synonyms.—Loose skin; Cutis laxa; Cutis pendula; Pachydermatocele (Mott); Chalazodermia; *Fr.*, Dermatolysie; Chalazodermie.

Definition.—A rare disease, consisting of hypertrophy and looseness of the skin and subcutaneous connective tissue, with a tendency to hang in folds.[2]

Symptoms.—The hypertrophic form of dermatolysis may be congenital or acquired, and may be limited to a small or large area, or develop simultaneously at several regions. The development may be so extensive that the integument hangs in large folds, although ordinarily it is much less marked. All parts of the skin, including the follicles, glands, and subcutaneous connective tissue, share in the hypertrophy. The skin and tissues are, however, soft and pliable, and sometimes show variable elasticity. The follicular openings are often enlarged, and occasionally contain comedo-like sebaceous plugs. The

[1] Bircher, "Das Myxödem und die cretinische Degeneration," *Volkmann's Sammlung klinische Vorträge*, No. 357 (Chirurgie, No. 110) (a thorough exposition of the malady, with case citations, review, references, and illustrations); Putnam, *Amer. Jour. Med. Sci.*, vol. cvi., 1893, p. 125; Osler (case resembling Bright's disease), *Montreal Med. Jour.*, vol. xxv., 1896–97, p. 642; Murray, "The Pathology of the Thyroid Gland," *Lancet*, vol. i., 1899, pp. 667 and 747 (a valuable contribution).

[2] For examples of extreme development, as well as its occasional resemblance and identity to pendulous fibroma, the reader is referred to the following cases, some of which are mentioned by Professor Duhring (*Diseases of the Skin*, third edit., p. 421): Keen, *Photo. Rev. of Med. and Surg.*, vol. ii., 1871–72, p. 45 (neck and shoulders, hanging down to the buttocks; illustration); Mott, *London Med.-Chirurg. Soc'y Trans.*, vol. xxxvii., 1854, p. 155 (5 cases, some of which doubtful, with 2 illustrations); Fritsche, *London Clin. Soc'y Trans.*, vol. vi., 1873, p. 160 (2 cases with 1 illustration and supplementary note by Tilbury Fox); John Bell, *Principles of Surgery*, edit. 1808, vol. iv. (Eleanor Fitzgerald case—2 illustrations, op. pp. 32 and 34); Stokes, *Dublin Jour. Med. Sci.*, 1876, p. 1 (scalp case—apparently a soft fibroma; with illustration); Cooke's case (described by Duhring (*loc. cit.*), and also by Wilson, *Lectures on Dermatology*, 1874–75, p. 163—the latter also describes Bell's case) (left hip and thigh, and hanging in folds to the knee, like the legs of a pair of loose Turkish trousers); Alibert, *Monographie des Dermatoses*, 1855, vol. ii., p. 719, also pictured in *La Pratique Dermatologie*, vol. i., p. 695 (face—numerous folds entirely concealing the visage); Wright, *London Patholog. Soc'y Trans.*, 1864–65, vol. xvi., p. 269 (on neck—2 illustrations).

enlargement of the follicles, and of the natural folds and rugæ, usually present to a variable degree, gives rise to an uneven surface, but soft, and sometimes slightly unctuous to the touch. There is also a tendency to increased pigmentation, the integument becoming more or less brownish. It will be seen that the condition bears a close resemblance to certain cases of fibroma, but its looseness and absence of any "body" or tumor-like formation, it seems to me, entitle it to a separate consideration. It is usually slowly progressive, although it may, after reaching variable development, remain stationary. There are no subjective symptoms, and, except for its weight and inconvenience, gives rise to no discomfort. It may be seated about the face, arms, neck, head, thighs; in fact, on almost any part of the body.

The looseness and inelasticity of the integument (*wrinkled skin*, *loose skin*) common to advancing years (see also atrophia senilis), and also resulting from the disappearance of fatty accumulations and following the overdistention of pregnancy, etc., may here be briefly referred to. In these instances the skin is not hypertrophied nor thickened, but is somewhat loose or wrinkled, to a variable degree, from slight to quite pronounced, as if too large for the enveloped part. In the senile form, which is usually upon the face, or most marked on this region, there is sometimes a trifling increase in the pigmentation. Its elasticity is usually lost, and if picked up between the fingers, returns but slowly to its place.

Etiology and Pathology.—Its etiology is obscure. As already remarked, it is congenital in some instances, and occasionally it has been noted to be hereditary, as in Graf's case,[1] involving the left side of the neck and lower eyelids, and which had occurred in several generations, developing between the fortieth and fiftieth years. In the congenital cases there is usually increased growth subsequently, generally most marked beginning with puberty. It is undoubtedly allied to fibroma, with which it is by most authors considered to be identical, and also possesses some analogy to elephantiasis (Hebra and Kaposi), and, in some instances, to mollusciform and lipomatous nævi and elephantiasis telangiectodes, or angio-elephantiasis. These various growths, though usually decided variants clinically, have a suggestive family resemblance. In acquired dermatolysis the process sometimes takes its start at the site of an injury or slight traumatism, as noted by Bell, Crocker, Demarquay,[2] and others. This has led some writers to believe the affection to be trophoneurotic in origin. There is much confusion as to the histopathologic findings, owing to the fact that in many instances they have been based upon the formations known as mollusciform nævus and fibroma. According to Duhring, "the growth consists of a simple hypertrophy of the integument, including all its parts, especially of the subcutaneous connective tissue. Under the microscope it is seen to consist largely of soft fibrous or lipomatous tissue, or of both in varying proportions."

Prognosis and Treatment.—There is no tendency to spontaneous disappearance in this affection; on the contrary, there is

[1] Gräf, *Casper's Wochenschrift*, 1836, p. 225, quoted by Esmarch and Kulenkampff, *Die Elephantiaschen Formen*, Hamburg, 1885, p. 204.

[2] Demarquay, *Bull. de Soc. de Chirurg.*, 1864, p. 343.

usually a disposition to increase and extend, although often, after a time, or at periods, there is a relative or complete cessation of growth. The treatment, when desirable from the extent and situation of the hypertrophic mass, consists in excision, bringing the skin together with sutures, the scar left being linear and comparatively insignificant.

For the senile and similar wrinkling or looseness of the skin, referred to above, for which, more especially that occurring about the face, advice is sometimes sought, a variable degree of benefit can usually be brought about by careful massage, the application of the faradic and galvanic currents, and sometimes also by the employment of slightly stimulating remedies, such as a 3 to 10 per cent. salicylic acid or resorcin salve; and, occasionally, by plaster-like applications which bring about a slight or moderate reactionary redness or dermatitis and consequent exfoliation. A preparation that can be used for this last is that which is referred to in the treatment of acne as the "peeling paste," of one-third to full strength there given. It should be constantly worn from one to several days or longer, according to the action, and then a mild salve applied until exfoliation has been completed. The constant application of one of the commercial, 10 to 25 per cent. salicylic acid rubber plasters, will also usually bring peeling of the skin and often lessening of the blemish. The application should be constant and continuous. These severe measures should not, of course, be employed in those eczematously inclined.

Elastic Skin (Synonym: Cutis hyperelastica (Unna)).—This peculiar condition, to which Crocker and a few others believe the term dermatolysis is more appropriately applied, has only comparatively recently received attention. It is that in which the integument is simply loosely attached to the underlying tissues, and having the property of great elasticity and distensibility; closely similar, in fact, to that which obtains normally in the cat and many other animals. There are macroscopically no perceptible textural changes, the skin being to all appearances perfectly normal, although usually with quite a sense of softness to the touch. The amount of stretching permissible in these rare cases is almost beyond belief—the skin of the breast can be brought up over the lower part of the face, and that of the chin can be stretched out like a long beard, and as soon as let go, returns quickly to its place. The subjects of this anomaly are known as "elastic-skin men," "India-rubber men," several remarkable examples having been referred to or reported by Turner,[1] Duhring,[2] Kopp,[3] and Seifert.[4] Such cases are occasionally to be seen on exhibition around the country. The one referred to by Duhring was also under my notice, the elasticity and distensibility being really phenomenal. In this case, as Dr. Duhring stated, the skin was more elastic in some

[1] Turner (Meekrin's case, a Spaniard, Georgius Albes), *Diseases of the Skin*, fifth edit., 1736, introduction, p. x; this case is also referred to by Wilson (*loc. cit.*, p. 162), and of which an illustration is given in John Bell's *Surgery*, vol. iv., 1808, op. p. 36.

[2] Duhring, *Medical News*, vol. xliii., 1883, p. 705 (clinical demonstration, reported by Henry Wile).

[3] Kopp, *Münch. med. Wochenschr.*, 1888, p. 259 (2 cases—father and son).

[4] Seifert, *Centralb. für klin. Med.*, 1890, p. 49.

directions than others—more when drawn transversely to the natural lines than when drawn in a parallel direction. When the stretched fold of skin was held up to the light, the cutaneous circulation was beautifully seen. The elasticity may be general or only in certain regions; in the case cited by Turner the skin of the left side of the body was free, or relatively free, from this peculiarity.

Sections of the skin from Seifert's patient, which Du Mesnil [1] also subsequently described, were made by the latter and histologically studied by him and also by Williams and Unna, with some slight diversity as to the findings. Kopp was of the opinion that the elastic fibers were increased, but Du Mesnil did not find this to be the fact, but that the fibers were merely wavy. The derma consisted of a more or less homogeneous mass, inclosing fusiform cells, and with absence of the normal connecting tissue fibers; the latter Williams, in his examinations, found present, but modified. This myxomatous condition would seem to represent an arrest of development. In addition the nerves and vessels showed elongation and were more or less winding, and, according to Williams and Unna, the muscle-fibers were increased—to this last they are inclined to attribute the elasticity of the skin in returning rapidly to its normal position, flying back quickly. These several investigators place most stress upon the abnormally winding course of the vessels and nerves, permitting of considerable lengthening, and also believe, moreover, that there is a special yielding property in the skin tissue itself. These several facts, together with the comparative absence or modification in the connecting fibrous tissue which normally binds the skin closely to the underlying structure, would serve to explain the stretching of which the integument in the cases is capable.

[1] Du Mesnil, *Verhandl. der. physic. med. Gesellsch. in Wurzburg*, vol. xxiv., 1891 (same patient as described by Seifert, but a fuller account, with case illustration and 7 histologic cuts); Williams, Unna—Unna's *Histopathology*, p. 984.

CLASS V.—ATROPHIES.

ALBINISMUS.

Synonyms.—Albinism; Congenital leukoderma; Congenital leukopathia; Congenital leukasmus; Congenital achroma; *Fr.*, Albinisme.

Definition.—A congenital absence, either partial or complete, of the pigment normally present in the skin, hair, and eyes.

Symptoms.—**Partial albinismus**, sometimes termed leukoderma, which, as a rule, involves the skin pigment alone or that of skin and hair, is identical in its features to vitiligo, except it is congenital, and lacks the increased pigmentation of the bordering skin observed in the latter affection. One, several, or many areas, and of various size, may be present, and they may be rounded or irregular in shape. The skin of the areas is milky-white in color, sometimes with a pinkish tinge; the hairs are generally likewise colorless. The patches are irregularly distributed, although, exceptionally, they show cutaneous nerve distribution, of which Lesser[1] cites an example. In rare instances the albinismus is limited to one or two patches of hair, and in some of these latter cases the white lock or locks are noted to be situated about alike through several generations (see canities). Partial albinismus, as to the integument, is most frequently seen in negroes (called "pied" or "piebald" negroes). As a rule, the patches remain the same throughout life, but in occasional instances the areas extend, and exceptionally, as in 2 cases—negroes—noted by Simon,[2] a tendency to pigmentation is shown.

In **complete albinismus** the skin of the entire body is milky-white, with usually, however, a pinkish tinge, due to the integumental blood; the hair is very fine, soft, and white or whitish-yellow in color, although in an exceptional instance noted by Folker[3] it was bright red. The irides are colorless, pinkish, or light blue, and the pupils, owing to absence of pigment in the choroid, are red or reddish-pink. This absence of pigment in the eyes gives rise to photophobia and nystagmus, noticed in these individuals, and which also leads them to keep the lids partly closed during the lightest part of the day, and to avoid brilliant light exposure. The subjects of this complete form are known as **albinos** (*Ger.*, Kakerlaken), and they are noted, as a rule, to be of rather feeble constitution, and many exhibit imperfect mental development, although to this are many exceptions. There are no structural alterations in the skin, there being no departure from the normal other than complete absence of pigment; and its functions are performed in a perfectly natural manner. The condition is permanent, although Ascherson,

[1] Lesser, *Ziemssen's Handbook of Skin Diseases*, p. 447 (with illustration).

[2] Simon, "Ueber Albinismus partialis bei Farbigen und Europäern," *Deutsche Klinik*, 1861, pp. 399 and 406. Almost all the numerous cases described in this paper are, however, examples of acquired leukoderma—vitiligo.

[3] Folker, *Lancet*, 1879, vol. i., p. 795.

Phœbus, and Mayer, quoted by Seligsohn,[1] have noted exceptional instances in which it partly disappeared; in Mayer's case the red color of the iris disappeared from year to year.

Beyond the influences of heredity no cause is known, and a history of this etiologic factor is not always obtainable. It is rarely direct, from one generation to another, the parents usually being free. It is seen in both blacks and whites. It is quite common for two or three of the children to be similarly affected; in fact, a single case in the family is rather exceptional. In the celebrated Cape May (New Jersey) cases reported by Marcy[2] the father and mother were full-fledged negroes, and so far as could be ascertained there had been no similar instance in the family. The first two children, males, were black, then came two females, both albinos, one after the other, then another black female child, and the last and sixth child, a male, another albino; they had all the attributes of albinism—cream-colored and silky, though woolly, hair, the pink eyes, and milky skin. In Folker's cases (Caucasians), in addition to the albino girl with red hair, two other children had the white hair and pink eyes of the pure albino; the others, five in number, showed no evidence of the condition; the father and mother were free from the deformity. In the family observed by Sym,[3] in which the complexion was dark in the father, mother, and relatives, and without previous history of the condition, of seven children four—the first, third, fifth, and seventh—were albinos, the others resembling their parents in color. In three cases the irides were bluish. Lesser (*loc. cit.*) refers to a family of seven children, of whom six were albinotic, and Pickel[4] an instance of a family of thirteen, of whom seven were albinos; and Mayer, where the second and fourth children were albinos, the first and third normal. It would seem, by Boyle's[5] observations, that the condition in some cases may fail of being absolutely complete. He cites an example seen among the blacks of Borneo, whose skin was of a dirty-white color, interspersed with large, freckle-like spots; the "color of the hair could hardly be described," the eyes were pale blue, and he was unable to see well until the sun was low. The parents of the case had the natural complexion, but his brothers and sisters were albinos, and many of his ancestors were said to have had the same blemish. According to Burton, quoted by Beigel, in West Africa there is occasionally observed a condition which might be termed *semi-albinismus*, in which the skin, in color, is between the natural hue of blacks and whites, and he refers to a case, of which he subsequently saw a number, of a black, with a *café-au-lait*-colored

[1] Seligsohn, "Albinismus," in *Eulenburg's Real-Encyclopædie*, vol. i., 1880, p. 160; and also by Behrend, in vol. xiii., 1897, p. 476.

[2] Marcy, *Amer. Jour. Med. Sci.*, 1839, p. 517—also a short preliminary report of the first children, in *Amer. Med. Intelligencer*, vol. i., 1837–38, p. 225.

[3] Sym, "Albinism—A Curious Family History," *Trans. London Ophthalmolog. Soc'y*, vol. xi., 1891, p. 218.

[4] Pickel, *Blumenbach's Med. Bibl.*, vol. iii., p. 167—quoted by Lesser, *Ziemssen's Handbuch der Hautkrankheiten*, vol. xiv., p. 181.

[5] Boyle, "Adventures Among the Dyaks of Borneo," London, 1865, p. 96—quoted by Beigel (albinismus and nigrismus), *Virchow's Archiv*, vol. xliii., 1868, p. 529; full translation of Beigel's paper in *Amer. Jour. Syphilog. and Dermatol.*, 1870, p. 136.

skin, hair dull yellow, but short and woolly, and the eyes a "lively brown."

In addition to the hereditary factor demonstrable in some instances other influences have been suggested, especially fright or shock during pregnancy. This does not, however, seem to be based upon a rational foundation or upon much clinical support, although the mother of Marcy's cases attributed the first child to the fright produced, while pregnant, by the falling down of an old white mare while driving; and in a case reported by Jefferiss,[1] in an only child, with no family history of the malady, the mother ascribed it to the strong impression made, in the first months of pregnancy, upon her mind by seeing an albino. Aubé, quoted by Seligsohn, is inclined to ascribe the condition to the marriage of blood relations, and believes the facts of its occurrence in animals are suggestive of this. Its rather rare appearance, however, would seem to negative such an opinion.

As may readily be inferred, albinismus cannot be lessened or influenced by treatment—it is, in fact, without remedy.

VITILIGO.

Synonyms.—Leukoderma; Leukopathia; Acquired leukasmus; Acquired leukopathia; Acquired achroma; Acquired piebald skin.

Definition.—A disease involving the pigment of the skin alone, characterized by the development of several or more round, oval, circumscribed, smooth, milky-white patches, tending to increase in size, and exhibiting at their margin increased pigmentation.

Vitiligo and leukoderma are synonymous and interchangeable terms, although some authors use the former for the acquired disease and the latter for the congenital patchy loss of pigment, also designated partial albinismus.

Symptoms.—In this affection there appear one or more small round or oval white spots, most frequently primarily on the backs of the hands, trunk, and face, these being favorite localities. In their earliest beginning, which, as a rule, is insidious, they are usually unnoticed, and often they escape observation until they are the size of a pea or larger. It is not improbable that close inspection would show, in some cases at least, that the first change was a hyperpigmentation followed by atrophy of pigment and the development of the characteristic milky-white spot. They tend to enlarge slowly, the neighboring skin showing an excess of pigment, usually sufficient in degree to give it a much darker color than obtains in the normal state. Indeed, in those of white skin the darkened border is often considered by patients as the pathologic condition, and the inclosed white areas looked upon merely as integument not yet affected. In those of darker skin, however, and in negroes, the change to the milky whiteness is naturally the more conspicuous. The spots are smooth on the surface and are not elevated above the level of the skin, there being no changes other than pigment diminution with surrounding increase in pigmentation. They vary in size from a scarcely measurable spot to that

[1] Jefferiss, *Lancet*, 1872, vol. ii., p. 294.

of the palm and even larger. Their shape is usually round or oval, sometimes irregular, owing to the spots becoming confluent; the edges are always convex, those of the pigmented bordering skin concave. New spots may form from time to time and coalesce, and may cover a surface of greater or less extent, forming large white areas with irregularly rounded or scalloped borders. When such ensues, the loss of pigment is much less noticeable than the surrounding hyperpigmentation. In color they are pinkish-white or dead milky-white. Both to the touch and sight no difference from the normal skin is to be detected, and none in reality exists, except that of the pigment changes. Within the whitened areas the hairs may retain their normal color, but generally they also share in the pigmentary loss. The activity of the sebaceous and sudoriferous glands is not interfered with, and subjective symptoms are not present.

FIG. 126.—Vitiligo; patient a dark brunette aged thirty; considerable increase in pigmentation beyond the white vitiligo areas.

The malady may be extremely slight, only a few spots presenting, or they may be numerous, and exceptionally may gradually invade the entire surface, as in instances observed by Lévi, Hall, Hardaway, Simon, and myself.[1] While the affection shows a predilection for the dorsum of the hand, the face, neck, and trunk, and also the genital and perineal region, it may begin or occur upon any hairy or non-hairy part[2] of the body. Occasionally there will be a few spots on the face and hands and one or several in the scalp, the latter making themselves known by the whitening of hair growing thereon. Not an infrequent site is around the eyes, surrounding them by a white band, which in the negro produces striking disfigurement. The disease is characterized by its slow course and by its chronicity, months and sometimes years elapsing before it reaches conspicuous develop-

[1] Lévi, "Recherches sur le Vitiligo," *Receuil de Mem. de Méd. de Chir. et de Pharm. mil.*, 1865, p. 193 (3 cases); Hall, *Louisville Med. News*, vol. x., 1880, p. 148, records the case of a dark mulatto who, with the exception of a part of the chin and a few small patches on the hands, became completely white. Hardaway, *Manual of Skin Diseases*, second edit., p. 280 (2 cases, 1 a white man and 1 a negro, with illustration of the negro, p. 278); Simon (*loc. cit.*) noted a few instances of practically general involvement. Stelwagon, *Amer. Jour. Med. Sci.*, July, 1885 (white man); and *Trans. College of Physicians*, Philada., 1894 (negro).

[2] In 31 instances noted by Lévi it began on the scalp in 6 cases, epigastric region in 4, forearm in 3, scrotum in 3, breast in 3, ends of the fingers in 2, hands in 2, face in 2, back in 1, arm in 1, penis in 1, and at the site of scars in 2 (region not stated).

ment. It may, after a time, remain stationary, and in rare instances retrogresses, but, as a rule, however, it is progressive, although its increase is often so slow that it is scarcely perceptible. With some exceptions it can be stated that when the normal pigment has once been lost, it does not return. When a larger area has been deprived of its pigment by the coalescence of several or more patches, and the coalescing hyperpigmented borders may not have completely disappeared, the brownish islets remaining are taken for the diseased condition and may lead to errors in diagnosis. Season of the year has no material influence, if any, upon the morbid process, but

FIG. 127.—Vitiligo; showing also the surrounding hyperpigmentation. A common site for the patches.

during the summer months the discoloration is more noticeable and disfiguring, owing to the increase in depth of coloring of the bordering pigmentation, which is due to the greater action of the actinic rays and to the direct exposure to the sun, the whitened areas being but slightly, and usually not at all, influenced. As a result the white looks relatively more pronounced, the surrounding pigmentation is increased, and the blemish, in consequence, more noticeable. In women of naturally very light skin the patches give rise to but little annoyance except during the sunny season, when, for the reasons stated, they become quite conspicuous. Not infrequently, however, considerable disfigurement results when such regions as the face,

neck, and hands are involved, even in the winter time, and proves a source of much mental worriment. The malady in the negro is, of course, a striking one, and extensive milky-white surface often results, examples of the disease in this race giving rise to the occasional newspaper notices of a "negro turning white"; in a few instances already referred to the change was in reality complete. At no time during its course is the general health impaired, the malady having no damaging influence, but, on the other hand, ill health from any cause is apt to lead to further increase in the patches.

Etiology and Pathology.—The cause of vitiligo is unknown. Although not common, it is not infrequent. A relationship to disease of the suprarenal capsules has been suggested (McCall Anderson). It occurs in males as well as females, and with, usually, about like frequency, although of Lévi's 37 cases 28 were men. It rarely begins before the tenth, nor after the thirtieth, year. According to statistics, it is more frequent in tropical countries (India) and in the dark races. Forel[1] states that it is very common in certain districts of Columbia, where the natives are mostly of mixed negro, Spanish, and Indian blood. It is not frequent, but still not at all rare, in our own country. Some observers are of the opinion that extremes of heat and cold both seem of possible etiologic import. At times it is hereditary. It is undoubtedly to be looked upon as a neurosis, and of more frequent occurrence in neurotic individuals. Often, however, absolutely no history of systemic disturbance can be obtained. In some instances severe illness, such as ague, scarlatina, and typhoid fever, would appear to exert an influence. There scarcely seems a doubt that the nervous system plays an important part, as shown by the observations of Fèvre, Wyss, Fournier, Schwimmer, Bulkley, and others.[2] Extensive cases resulting after fractures and injuries to nerves have been reported. It is not infrequently associated with alopecia areata, and occasionally with morphea. Its occurrence in Graves's disease has also been noted (Trousseau, Raynaud, Rolland, Bramwell, Dore, and others).[3] The malady has been occasionally observed to begin at the site of an injury, from pressure, ulcerations, condylomata lata, and burns. Shepherd has noted the disease in one instance to start from the pressure of a collar-stud and another from the spots left after burning warts. Hebra believed that not infrequently the first area arose in close proximity to a previously existing pigmented mole. The so-called pigmentary syphilid (*q. v.*) is thought by some observers to be a vitiligo (vitiligo syphilitica) starting at the sites of former macules.[4]

The very earliest pathologic change to be noted in vitiligo is, I believe, an increase of pigment,—a hypertrophy instead of an atrophy,—followed by diminution or atrophy, and in the further spread

[1] Forel, *Münch. med. Wochenschr.*, 1897, p. 1009.

[2] Quoted by Leloir, *Twentieth Century Practice*, vol. v., p. 848; Lebrun, *Thèse de Lille*, 1886, was also of the opinion that other nervous disturbances were usually to be found.

[3] Dore, "Cutaneous Affections Occurring in the Course of Graves's Disease," *Brit. Jour. Derm.*, 1900, p. 353.

[4] That syphilis has, however, any etiological relationship to true vitiligo, as Marie and some others suggested, seems, in my judgment, without the slightest tangible foundation. Thibierge (*Annales*, Feb., 1905, p. 128), and others give ample negative evidence, as for example the existence of vitiligo in those whose syphilis is contracted subsequently.

of the lesions the same pathologic steps are gone through. Anatomically, as to be inferred, the whitish spots are seen to be wholly devoid of coloring-matter, whereas the surrounding brown discoloration shows hyperpigmentation. The atrophy of the terminal nerves noted by Leloir[1] and Chabrier has not, up to the present, been confirmed.

Diagnosis.—The diagnosis is usually not difficult. In extensive cases, where the pigmented portions are the more striking, it might be confused with chloasma, but it may be differentiated from the latter by the fact that the white areas have convex borders, and the pigmented part would naturally show the reverse,—concave,—while in chloasma these would be reversed, the chloasma pigmentation being irregularly round or diffused. Moreover, chloasma, as generally encountered, is upon the forehead and sometimes on other parts of the face as well, but it is rare elsewhere. Under the same circumstances it could possibly be confounded with tinea versicolor, but the same points as regards the borders would obtain here also, and when it is borne in mind that in tinea versicolor the patches are usually furfuraceous, of a yellow or fawn color, and the intervening skin is normal in appearance, no error should arise; furthermore, the microscope will reveal the presence of the microsporon furfur, the causative agent in the latter malady. Another disease which, upon casual inspection, it resembles to some extent is morphea. The latter, however, is associated with structural changes in the skin, while in vitiligo there exists only an absence of pigment in circumscribed patches, and which are on a level with the skin, whereas in morphea the patches may be somewhat elevated above it, or sometimes slightly depressed, and the seat, as disclosed to the touch, of other distinct changes. Occurring in tropical climates, it is at times confounded with the white patches of true leprosy. Indeed, according to Minch, vitiligo is somewhat widely distributed in Turkestan, and is considered contagious by the Sarts; affected persons are segregated and kept with the lepers within special inclosures (Ziegler)—a most extraordinary procedure unless, as is possible, they are held as simple suspects temporarily. In this type of leprosy, however, the whitish patches are anesthetic and there are structural changes in the skin and constitutional symptoms present, which is not the case in vitiligo. Partial albinism, which, as already remarked, is often termed leukoderma, is, in reality, similar to this malady except that the normal pigment is absent from birth; it is, therefore, a congenital condition, whereas vitiligo develops during life.

Prognosis and Treatment.—The outlook for recovery from the malady is not very encouraging. The spots tend, as a rule, to increase quite slowly in size for a number of years, and the skin over parts of the body may become entirely deprived of pigment. In such instances the last remnants are a few islets of pigmentation, the remains of portions of the pigmented borders, which also gradually fade away. General involvement is, however, extremely rare. Not infrequently, after progressing for some years, it comes to a standstill, and exceptionally it retrogresses and disappears. Fortunately, the disease gives rise to no symptoms other than the disfigurement.

[1] Leloir, "Contribution a l'Étude des affections cutanées d'origine trophique," *Arch. de Physiol.*, 1881, p. 397; see also interesting clinical and histologic paper by Marc, "Beiträge zur Pathogenese der Vitiligo und zur Histogenese der Hautpigmentirung" (with review and references), *Virchow's Archiv*, vol. cxxxvi., p. 21.

It is questionable how far treatment influences its course. The continued administration of arsenic, along with tonic remedies, if indicated, has in some instances, it is believed, influenced it favorably. Duhring considers this the most valuable remedy, and in some cases under my care the progress of the malady seemed to be stayed. Pilocarpin has likewise been suggested, and also thyroid; recently good effects from suprarenal gland have been claimed. In young patients cure has been stated to follow the use of potassium bromid internally, along with alkaline baths (Besnier and Doyon). General galvanization and the use of the battery with the positive electrode to the back of the neck and the other over the patches has been credited with favorable influence. The general condition of the patient should receive attention, and measures directed toward bringing the health up to the normal state adopted.

Externally the white patches can be rendered less conspicuous, and the disfigurement lessened, by reducing the pigmentation of the border by the means used in the treatment of chloasma. Recently Savill [1] successfully employed for this purpose pure phenol, painting it over; the outer epidermis subsequently exfoliating, with a disappearance of the discoloration. In cases of sensitive skin it would be advisable to apply it at first weakened with alcohol, and to limit the application to a small area. In addition to endeavoring to lessen the bordering pigmentation, stimulating applications to the white patches, with a view to producing hyperemia and consequent pigment deposit, can, if thought advisable, be practised. One of the best for this purpose is the negative electrode of a galvanic battery, with a current of 2 to 5 milliampères. It should not be held on the same spot for more than one to several minutes, so as to produce redness, but to avoid too great effect, otherwise some damage might be done. The application of the tinsel or metallic brush, either with the faradic or galvanic battery, will likewise produce redness. Mustard, in the form of a plaster, cantharides, burning glass, and similar measures are also resorted to. The white patches may be masked by coloring, from time to time, with walnut juice or similar stain, or with an extremely weak tincture of iodin or like substance.

GLOSSY SKIN.

Synonyms.—Atrophoderma neuriticum; *Fr.*, Peau lisse.

Symptoms.—It is to Paget,[2] Weir Mitchell, Morehouse, and Keen [3] that we owe our chief knowledge of this affection, although, according to Leloir,[4] it was first described by Alexander Denmark in case of a wound of the radial nerve. Its most common and usual site is some part of the hand, and in almost all instances the fingers, rarely all of them. The affected skin is at first noted to be a deep

[1] Savill, *Brit. Jour. Derm.*, 1898, p. 99.

[2] Paget (Some Forms of Local Paralysis), *Med. Times and Gazette*, 1864, vol. i., p. 333.

[3] Mitchell, Morehouse, and Keen, *Gunshot Wounds and Other Injuries of the Nerves*, Philadelphia, 1864, p. 77. Mitchell, *Injuries of Nerves and their Consequences*, Philadelphia, 1872.

[4] Leloir, *Twentieth Century Practice*, vol. v. (Diseases of the Skin), p. 834.

red or mottled or red and pale in patches, and smooth and shining, giving it a glossy appearance, and hence the term commonly used to describe it—glossy skin. It is dry, thinned, and with a pseudocicatricial aspect. The fingers, from the varying, usually slight, associated atrophy of the skin and subcutaneous tissue of the distal portion, are often tapering, with, as a rule, the almost entire disappearance of the wrinkles, the skin appearing as if tightly drawn over the subjacent tissues. The general effect, as Mitchell expresses it, is: the surface of the affected part is glossy and shining, as though it had been skilfully varnished, or in some instances presents the characters of large, thin, and highly polished scars. Not infrequently, especially in the beginning, as Paget states, its resemblance to chilblains is often striking. The hair growth of the part usually wholly or partially disappears. In places there may be a tendency to partial loss of the overlying epithelium, the cutis being exposed, and cracking or fissuring of the thinned skin is sometimes observed. The nails at the free border are usually curved over both at the end and sides. Occasionally slight retraction of the skin from the matrix occurs, and when about the toes, painful fissures or ulcerations sometimes result. The atrophic condition is also observed on the palm, and here the glossy thin area or spots are noted to be slightly depressed. The malady is generally preceded and accompanied by neuralgic or burning pain, of variable degree, but usually severe; while commonly more or less limited to the affected region, it may involve the whole limb. In Watson's [1] case the neuralgia was extreme, acute in character, lasting about a day, and shifted from one hand to the other. While the skin is, as a rule, unnaturally dry, in some instances increased sweat secretion has been observed.

Etiology and Pathology.—The malady is a trophoneurotic one, and is due to any cause which brings about disease or injury of the supplying nerves. A neuritis or injury from a gunshot or other wound is the most common exciting factor. In nerve lesion the condition, according to Mitchell, never appears before the second week, usually coinciding with the beginning of the healing process. As a complication it has also been observed in some general disorders, such as chronic myelitis, leprosy, gout, and rheumatism. Watson's case was apparently independent of any recognizable cause.

Prognosis and Treatment.—The duration is variable, from weeks to years, although, according to Mitchell's observations, there is final spontaneous disappearance. Treatment consists in removing or modifying the cause, restoring the nerve tone of the part, and the use of local protective measures of a soothing and oily character, and the avoidance of exposure to cold.

ATROPHIA SENILIS.

Synonyms.—Atrophia cutis senilis; Atrophoderma senile; Senile atrophy; Old age of the skin.

Old age changes in the skin are commonly observed after the sixtieth year is passed, and sometimes earlier, although rarely before the

[1] Watson, *Lancet*, 1890, vol. i., p. 647.

age of forty-five or fifty.[1] The skin is noted to be of a dull yellowish hue, with sometimes a greenish tinge; it is dry, inelastic, with often positive thinning, sometimes slight scaliness, usually of a branny character; somewhat wrinkled, with here and there pigmented areas of freckle-like nature, and pea- to bean-sized yellowish or brownish spots, covered with a variable amount of grayish or brownish sebaceous scaliness or crusting, which, if removed, often discloses a red, sometimes granular-looking, surface and atrophic thinning (degenerative seborrhea). Sometimes, instead of being so covered, the coating is found to be hard, somewhat horny, and firmly adherent, or there may be small, thickened, corneous, pea- to bean-sized, slightly scaly or crusted areas, which may also undergo surface degeneration—keratosis senilis. These senile keratoses, as well as the degenerative seborrheic patches, which may often begin as slightly horny, scurfy spots, are not infrequently the seat of epithelial changes, which may develop into epithelioma, although they frequently persist for years without displaying any destructive tendency. In some instances slight white or grayish atrophic points or spots are also noted, and dilated capillaries, isolated or in tufts, are quite frequently seen. A pigmented pea- to finger-nail-sized slightly elevated wart, covered with a greasy brownish coating (seborrheic wart, verruca senilis), and sometimes present in considerable number, is also not an uncommon lesion; at times the surface is slightly uneven or papillomatous. Small, solid fibromata which may have existed, more commonly on the neck and back, undergo central absorption or atrophy, and remain as shriveled, pendulous sacs. The face and dorsal surface of the hands are the sites where the changes are usually most conspicuous, although the shoulders and upper part of the back, and also the lower part of the legs, frequently show one or several of the described lesions. The upper part of the back and less frequently the dorsum of the hand are favorite regions for the sebaceous warts, where several to ten, fifteen, or more sometimes develop.

These various lesions are not, however, necessarily present in the same individual: in some a dry, inelastic, slightly harsh, possibly somewhat branny, condition of the skin is noted, with an accentuation of the natural folds or wrinkles, whereas in others the skin is somewhat similarly affected, with a general dingy hue and with many pigmentary or freckle-like spots, with, possibly, one or two small crusted seborrheic patches. These latter are more common about the nose and sides of the forehead. As a rule, there are no subjective symptoms associated with these various conditions, although in those instances in which the dryness and harshness, with a tendency to branniness, are especially pronounced, there may be, particularly upon the extremities, a variable amount of itching.

The histologic changes have been studied by Neumann, who found, in the quantitative or simple atrophy, thinning of the epider-

[1] Rossbach (Ein merkwürdiger Fall von greisenhafter Veränderung der allgemeinen Körperdecke bei einem achtzehnjährigen Jüngling), *Deutsch. Archiv f. klin. Med.*, vol. xxxvi., 1884–85, p. 197, reports, with 4 illustrations, an extraordinary instance of senile wrinkling and other changes in the skin in a youth of eighteen, giving him the appearance of a man of advanced years.

mis and corium, with its connective-tissue corpuscles usually smaller and less numerous. Partial or complete disappearance of the papillæ is noted. Pigment is found between the connective-tissue bundles and also here and there in the vessels. The sebaceous glands and hair-follicles also generally show some alteration, the former being sometimes observed with dilated acini filled with epidermic scales and débris, and in other cases seem made up of a yellowish-brown mass. The sweat-glands rarely show change. In degenerative atrophy a granular or vitreous degeneration of the cutaneous elements, especially of the connective tissue, takes place, considered by some as amyloid or fatty degeneration. Unna[1] is inclined to believe that simple atrophy is not observed as a senile change, but that it is always degenerative in nature, and that the different constituents do not share in it equally. He calls attention especially to the fact of the relative youth and proliferative power of epithelium in the aged, compared to the connective tissue, as demonstrated by the tendency to epithelial growths at such age.

Treatment.—While nothing can ordinarily stay the ravages of time, the maintenance of a condition of good health, hygienic living, and cleanliness, with frequent bathing, will do something toward diminishing its effects. Scurfiness and dryness can be counteracted by an occasional oily application, such as almond oil, vaselin, or cold cream. The tendency to degeneration, as displayed by the seborrheic spots and the corneous accumulations, can best be stopped by ointments containing sulphur and salicylic acid, 5 to 30 or more grains (0.335–2.) of the former, 3 to 20 (0.2–1.335) of the latter, to a half-ounce (16.) of cold cream or vaselin: to be rubbed in nightly, the strength of application depending upon irritability of the skin, stopping just short of irritation. The timely use of such applications has, in my hands, often stayed the tendency to epitheliomatous change, a fact to which Montgomery[2] and others have also attested.

STRIAE ET MACULAE ATROPHICAE.

Synonyms.—Atrophic lines and spots; Atrophoderma striatum et maculatum; Atrophia maculosa et striata; False cicatrices; *Fr.*, Vergetures; Stries atrophiques.

Symptoms.—The atrophic striæ (atrophia cutis linearis; striæ atrophicæ; linear atrophy) are usually one or two lines in width, of variable length, somewhat depressed, and commonly closely set and arranged in parallels; or they may be irregular and undulating, and with a scarcely perceptible depression. In color they are a pinkish-white, grayish, or white, with usually a glistening, scar-like appearance. Occasionally with the lines are noted pin-head to bean-sized or larger spots (maculæ atrophicæ), of closely similar appearances, and slightly depressed; these latter may rarely be the sole manifestation. There are, with rare exceptions, no subjective symptoms and no change in sensibility. The hairs on the involved areas

[1] Unna, *Histopathology*, p. 1032.

[2] D. W. Montgomery, *Philadelphia Med. Jour.*, Jan. 20, 1899. See keratosis senil s for other suggestions as to treatment.

or lines usually show atrophic tendency, and sometimes completely disappear. In origin these atrophic lines and spots may be idiopathic or symptomatic, although there is a predominant belief that they, or most cases at least, belong in the latter class, and due essentially to mechanical overstretching. The most familiar example is that of lineæ albicantes, observed on the abdomen of pregnant women (lineæ gravidarum) and others in whom abdominal stretching has resulted from tumors or, and on other parts as well, from rapid development of fat. They are mostly closely set, in parallels, and running transversely to the direction of greatest distention, although in some instances in which the stretching is fairly uniform in all directions they may be concentrically arranged (Langer). Independent of pregnancy, however, probably from the other cause mentioned,—from fat development,—these atrophic lines are quite common, as Schultze, quoted by Jarisch,[1] found in 36 per cent. of unmarried adult women parallel atrophic lines running perpendicularly on the front of the upper thighs, and the same, but of less regular direction, in 6 per cent. of men examined; he believed that the preponderance is explained by the fact that at puberty there is pronounced broadening of this region in women, whereas in men, in whom the streaks were just as frequently transverse, the rapid growth is in the length.

While such instances are probably to be designated as symptomatic, others have been observed which cannot be so readily placed in this class, but are more properly to be considered idiopathic, as, for example, those in which the condition has followed typhoid fever, of which Shepherd[2] has reported a remarkable example. In his patient, a boy of fifteen, the stripes were situated above both knees and over both patellæ, depressed, thin, and dry, purplish in color, elliptic in shape, and tapering to a fine point at each end, the largest being one-half inch wide and six inches long. There was a distinct tendency to parallelism, transversely to the limb, and a few atrophic macules were also to be seen. The new lesions which appeared while the patient was under observation were, for the most part, in spots which united to form a stripe. The first step was the appearance of a shiny, depressed, cicatricial-looking spot, and no antecedent hypertrophy, as described by Liveing, Duhring, and others. Bradshaw, quoted by Shepherd, had almost a precisely similar case as to location and characters in a girl aged thirteen. Plagge[3] has observed the striæ on the abdomen in typhoid fever, in which there had been no abdominal distention, but, on the contrary, extreme emaciation. Barrs[4] had a case under observation in which there were striæ parallel with the ribs in the dorsolumbar region, four on left side and eight on right,

[1] Jarisch, *Hautkrankheiten*, 1900, p. 918.

[2] Shepherd, *Jour. Cutan. Dis.*, 1891, p. 59 (with illustration and some valuable literature and references, to which I am indebted. Several recent interesting cases of these striæ about the knees (*striæ patellares*) have been reported by Northrup (1 case), Fischer (1 case), Köbner (2 cases); and by Bunch (2 cases), *Brit. Jour. Derm.*, Jan., 1905, who reviews the subject with reference to the above cases and others. The condition in these 6 cases was observed in growing children, and, with the exception of 1 case, developed during or after typhoid fever.

[3] Plagge, *Zeitschrift f. die Staatsarzneikunde*, 1861, p. 369.

[4] Barrs, *Brit. Jour. Derm.*, 1891, p. 152.

the widest one-fourth inch wide, and the longest, four inches, having the ordinary appearances, and which had followed an attack of pneumonia a year previously, and appearing without preliminary edema or inflammation or distention. The patient, a nervous woman, had experienced, at the time, intense pain over the streaks. There was no anesthesia. Wilks,[1] quoted by Shepherd, also noted 2 instances of linear atrophy, about the knees in a youth aged nineteen, and a girl of eighteen, with striæ all over the body, but especially the legs; in the latter the marks were tender and sensitive, at first faint red, subsequently purple, and then dead white. In these two there was no apparent cause, although the boy had a tuberculous knee-joint. A case was under my own care in a male adult in whom, on the lumbar region, right side, there were numerous parallel atrophic lines, with a few cross striæ, of unknown origin, the patient being in good health. In some instances, as in 1 of 2 cases of the striated type observed by Féré and Quermonne,[2] principally in the lumbar region, the lines present bordering pigmentation; in their other case, involving the throat, breast, lumbar and gluteal regions, the malady began as brownish striæ, subsequently growing white. Other examples by Troisier, Manouvrier, and Bouchard, of apparently idiopathic origin, are also referred to by Shepherd (*loc. cit.*). It is probable, therefore, that all cases of atrophic lines cannot be placed to the score of being mechanically produced by overdistention, although Bouchard suggests that the rapid increase of tissue after fevers might be the factor, but this does not seem to be supported by a study of the cases. Even with the acceptance of this there must be some underlying inherent condition of the cutaneous tissues. According to the observations[3] of Auboger, Bouchard, and Manouvrier linear atrophy developing in typhoid is a symptom of grave import, as the fever in such instances generally assumes an ataxo-adynamic form.

Idiopathic atrophic macules usually present the same characters as the lines as commonly met with. In the cases observed by Wilson,[4] Liveing,[5] and Duhring[6] there was an antecedent erythematous tinge; also in Taylor's[7] case. In Jadassohn's[8] patient, a woman aged twenty-three, there were numerous lentil- to dime-sized, bright red, depressed, and thin areas, covered with wrinkled epidermis, on the extensor surface of both arms, from the wrist to the shoulder; shilling-sized, dark-red similar spots over the olecranon, with depressed striæ branching from them; and groups of red, depressed striæ blanching upon pressure; some ordinary striæ on thighs; the first stage of the macules seemed to be a small red papule. Some of these various cases referred to would, I believe, better bear the interpretation of morphea than that of the malady under consideration;

[1] Wilks, *Guy's Hosp. Reps.*, 1861, p. 297.
[2] Féré and Quermonne, *Le Progrès Med.*, 1881, p. 839.
[3] Paris letter, *Brit. Med. Jour.*, 1887, i., p. 300.
[4] Wilson, *Diseases of the Skin;* also *Jour. Cutan. Med.*, vol. i., 1868, p. 140.
[5] Liveing, *Brit. Med. Jour.*, Jan. 19, 1878.
[6] Duhring, *Diseases of the Skin*, third edit., p. 442.
[7] Taylor, *Arch. Derm.*, 1876, p. 114.
[8] Jadassohn, *Trans. Ger. Derm. Cong. III.*, Leipzig, 1891; full abs. in *Brit. Jour. Derm.*, 1893, p. 30.

the relationship is doubtless often a close one.[1] Jadassohn's case of so general and almost continuous involvement seems midway between "atrophic lines and spots" and idiopathic general atrophy.

Symptomatic or consecutive patch atrophy, sometimes presenting a clinical analogy to idiopathic atrophic macules, is observed in certain skin diseases, such as leprosy, lupus vulgaris, lupus erythematosus, syphilis, lichen planus, etc., but this is considered in connection with the disease with which they are associated.

Pathology.—Exclusive of the cases in which overstretching is the factor it is probable the condition is, as Schwimmer and some others believe, of trophoneurotic origin, and, as Shepherd states, that in those instances following fevers the latter were severe and prolonged. The symmetry of the lesions and the neurotic character of most patients also lend weight to this view.

The pathologic histology of the atrophic lines has been studied by Kaposi, Langer,[2] and a few others, who found an atrophic condition of the epidermis, the papillæ obliterated, diminution of the blood-vessels, and disappearance of the fat-cells, separation of the connective-tissue fibers, and the glandular structures atrophied. Langer's investigations led him to believe that the striæ are produced by violent stretching, due to disarrangement or separation of the connective-tissue fibers, and not to rupture. Jadassohn noted in his case thinning of the epidermis, but with no structural alteration, and more or less complete disappearance of elastic fibers of the cutis; there were no signs of an inflammatory process, although some blood-vessels were surrounded by slight round-cell infiltration; the papules referred to indicated, however, Jadassohn believes, that inflammation is the initial factor.

When once the atrophic lines and spots are established, the condition is a permanent one, and not removable or influenced by treatment.

DIFFUSE IDIOPATHIC ATROPHY OF SKIN.[3]

A more or less diffuse atrophy of the skin (also called general idiopathic atrophy, progressive idiopathic atrophy, atrophia cutis universalis) has been reported from time to time. The chief features

[1] Johnston and Sherwell (*Jour. Cutan. Dis.*, 1903, p. 302, with histologic study and cuts) describe a case of "**white-spot disease,**" the peculiar manifestation consisting of a striking dead-white, snow-colored, slightly raised pin-head to about bean-sized spots. Some undergo involution, a thin scale separates, and there result punctate and striate atrophy. Histologically, the process was limited to the papillary body and upper portion of the reticular layer, and found to be a pure degeneration. A strong irritative treatment (saturated alcoholic solution of resorcin) had a satisfactory result. The cases of Westberg and F. H. Montgomery (considered a peculiar form of morphea) are referred to. Two cases (mother and daughter), presenting a suggestive clinical resemblance, have been observed by Macleod (*Brit. Jour. Derm.*, 1904, p. 224). In a recent paper (*Jour. Cutan. Dis.*, 1907, p. 1), F. H. Montgomery and Ormsby add 3 cases (with histology and illustrations), review reported cases (10), and conclude that it should be considered as an unusual type of morphœa or localized scleroderma ("morphœa guttata").

[2] Langer, *Med. Jahrbücher*, 1880, p. 49 (with 6 histologic cuts).

[3] Literature, E. Wilson, *Lectures on Dermatology*, London, 1878, p. 393; Schwimmer, *Die neuropathischen Dermatonosen*, p. 189; Atkinson, *Richmond and Louisville Med. Jour.*, vol. xxiv., 1877, p. 564; Glax, *Allg. Wiener med. Zeitung*, No. 35, 1874; full abs. in *Archiv*, 1875, p. 114; Buchwald, *Archiv*, 1883, p. 553 (with illustration); Behrend, abs. in *Archiv*, 1885, p. 346 (original in *Berlin. klin. Wochenschr.*, No. 6, 1885); Touton, *Deutsch. med. Wochenschr.*, 1886, p. 6; Pospelow (2 cases), *Annales*, 1886, p. 505 (with illustration and references); Groen, *Norsk Magazine*, abs.-ref. in *Lancet*, 1891, vol. ii., p. 1238; Beer, *Archiv*, 1892, p. 835; Williams, *Brit. Jour. Derm.*, 1894, p. 342 (case demonstration); Bronson, *Jour. Cutan. Dis.*, 1895, p. 1 (with colored

are: atrophic thinning, dryness, and a variable degree of branniness, or ill-defined, thin, flaky scaliness, with usually loss of the hairs and absence, relative or complete, of the sweat secretion; and sometimes a white, streaky, or patchy appearance, frequently with interspersing of brownish discoloration; with, in typical examples, a variable amount of looseness and wrinkling of the skin, and in some cases a conspicuousness of the surface veins. In some instances there is an underlying dusky red hue, with sometimes intermingling of purplish or brownish. In some places, varying considerably in different cases, there is also noted a waxy, glistening, parchment-like surface, as in macular atrophy. Indeed, not infrequently the atrophic changes are more marked here and there, producing spot-like or small, white, thin, scar-like areas, somewhat depressed. On parts covering prominent bony projections, as at the ankles, ulcers are apt to form. In

FIG. 128.—Atrophy of the skin; old woman; chiefly involving the legs, especially the knee and lower thigh regions.

Fordyce's patient a number of outbreaks of bullæ about the ankles occurred. As a rule, there are no distinctive subjective symptoms, although occasionally shooting pains, as in Bronson's case, involving both extremities, and rarely a sensitiveness to touch or pressure. The amount of surface involved varies from that of a part of one or two limbs, as in Elliot's patient, to that of practically the entire surface, as in Neumann's and Colombini's cases, and in the congenital cases of Behrend and Williams. The lower extremities are most commonly involved, and the region of the knees is a not infrequent starting-point; in some both upper and lower extremities are affected (Touton, Pospelow, Groen, Bronson, Fordyce, Holder). In several instances the first evidence was upon the dorsal surface of the hand.

plates and other illustrations and references); Elliot, *ibid.*, 1895, p. 152; Fordyce, *ibid.*, 1897, p. 230 (case demonstration); Kaposi, *Archiv*, 1897, vol. xxxix., p. 413 (case demonstration); Neumann, *ibid.*, 1898, vol. xliv., p. 3 (with references and 3 colored histologic cuts); Colombini, *Monatshefte*, 1898, vol. xxviii., p. 65; Holder, *Jour. Cutan. Dis.*, 1899, p. 37 (case demonstration).

Some of the cases, more especially those first reported, could, I believe, be better placed as examples, probably anomalous, of other maladies. There is, as Crocker suggests, a strong suggestion of scleroderma, with marked atrophic tendency in several,—especially in those of Wilson, Schwimmer, Atkinson, and Glax,—although Atkinson's case, which was unilateral, lacked the ordinary features of scleroderma, and had much in common with cutaneous atrophy. Some cases were of more or less limited character and chiefly patchy, as in Beer's patient; in this there was preceding edema, and it was somewhat suggestive of a circumscribed scleroderma. Both Schwimmer and Glax, at the time, thought their cases probably, but incorrectly, belonged under xeroderma pigmentosum. Those described by Buchwald, Pospelow, Bronson, and Colombini have much in common, especially as to laxity of the skin; this, in one of Pospelow's cases, was, however, somewhat extreme, resembling dermatolysis. In Neumann's patient, practically universal, there was diffuse redness, with thinning, wrinkling, and furfuraceous and lamellar desquamation. The wrinkling observed in most of these patients, as in Bronson's patient, follows the cleavage lines of the skin; in most instances it is not especially noticeable, resembling, at a distance, minute striæ, giving the thinned skin a cigarette-paper appearance, but in others it is of the nature of distinct folds. In Bronson's case, as in some others, there is remarkable symmetry in the distribution. In some patients the neighboring lymphatic glands were enlarged.

The causes of the disease are not known; in rare instances it is congenital, in others, and probably in almost all, appearing at mature or advancing adult age. In 10 cases it began in 1 (Pospelow—female, aged fifty) at the age of sixteen, 1 (Buchwald—male, aged thirty-six) at twenty, 3 (Bronson, Elliot, Neumann—males, aged forty-five, forty-five, and thirty-two) at about thirty, 1 (Touton—male, aged fifty-seven) at thirty-five, 1 (Fordyce—female, aged forty) at thirty-eight, 1 (Holder—female, aged fifty-four) at the age of forty-six, 1 (Pospelow—female, aged fifty) at forty-eight, and 1 (Colombini—female, aged fifty-five) at fifty-four and a half. In 12 cases the sexes were evenly divided. The health of most patients seemed fair, although in several instances the malady followed "taking cold" or a chill; in the cases of Fordyce and Holder there were associated symptoms of headache, dizziness, and extreme nervousness. The primary pathologic condition in some instances appeared to be a scarcely perceptible inflammatory process, which seems borne out by the histologic examination (Colombini). In Elliot's case a purplish-red zone bounded the advancing area of atrophy, and this Elliot believed was the primary step in the process, and the atrophy only a consequence. The process in this case and in some others bears in this respect, in my judgment, a close analogy to that of morphea. The changes found are those of well-marked atrophy, involving the entire integument and glandular structures, similar, in fact, to those observed in striæ et maculæ atrophicæ. Fordyce found marked changes in the vessels, the lumen of some being completely obliterated.

The **prognosis** for the malady is not favorable for recovery,

although beyond variable discomfort, however, the general health did not seriously suffer, except in the generalized cases. There seems practically no tendency to extensive involutionary changes, the malady usually progressing up to a certain point, and then remaining, relatively at least, stationary. In most instances several years elapse before reaching its greatest extension, although in Kaposi's and Colombini's cases in five or six months almost the entire surface was involved. The general **treatment** indicated would be arsenic, cod-liver oil, and tonics, with mild oily applications to reduce the dryness and harshness.

KRAUROSIS VULVAE.

Breisky,[1] and later Heitzmann,[2] Janovski,[3] Ohmann-Dumesnil,[4] Baldy and Williams,[5] and Ewald,[6] have called attention to a rare, peculiar, and obscure affection of the genitalia in women, characterized by atrophic changes, shriveling, and contraction. The parts usually involved are vestibulum, labia minora, with the fourchet and præputium clitoridis, the inner surface of the labia majora, extending to the posterior commissure, and the immediately adjacent perineum. The folds are partly or completely obliterated, and later the labia minora almost entirely disappear, their site being indicated by a slight sulcus or furrow. The atrophic change may involve the præputium clitoridis to such a degree as to leave no recognizable trace. The posterior portion of the vulva also suffers to a great extent, and here and in the other parts there is noted a tightening or spanning of the tissues, with a tendency to some hardening. The contraction may be sufficiently marked, as Breisky and the others have pointed out, to be an obstacle to childbirth, and even to coitus. These various features seem, to a variable degree, common to all cases, but as to other symptoms, there is considerable divergence. There is generally some patchy thickening, which may be somewhat similar to the plaques of leukoplakia buccalis. The contiguous and covering integument is usually grayish or whitish, dry and often glossy, and sometimes thickened. Breisky stated that there was no preceding or accompanying inflammation or erythema; but in some instances, pruritus. Heitzmann's cases showed features of chronic eczema of patchy character, these patches being slightly milky and psoriatic looking, and with considerable tormenting itching. Baldy and Williams recognize the etiologic bearing of pruritus, which, in consequence of the scratching, leads to inflammation, with

[1] Breisky, *Zeitschr. für Heilkunde*, 1885, p. 69 (12 cases; histologic cuts).

[2] C. Heitzmann, abs. *Trans. Amer. Derm. Assoc. for 1888* (4 cases); never published in full—abs. of the cases in Ohmann-Dumesnil's paper.

[3] Janovski, *Monatshefte*, 1888, vol. vii., p. 951 (6 cases).

[4] Ohmann-Dumesnil, *ibid.*, 1890, vol. x., p. 294 (4 cases, with résumé of all other published cases and others (unpublished) communicated to the author—in all a tabulation of 35 cases).

[5] Baldy and Williams, *Amer. Jour. Med. Sci.*, vol. cxxviii., 1899, p. 528 (1 case, with a review of literature).

[6] Ewald, *New Yorker med. Monatsschrift*, 1901, p. 209.

The case described by R. F. Weir, *New York Med. Jour.*, Mch., 1875, as "Ichthyosis of the Vulvæ," seems also to be an example of this affection.

the subsequent cicatricial tissue formation in the corium and hypoderm, although admitting that there is still an unknown factor to which the unusual changes are due.

Janovski's cases led him to believe that gonorrhea and luetic ulceration were predisposing. Excepting as to the frequency of leukorrheal discharge, the experience of the others did not accord with this view. In short, nothing definite can be said as to etiologic factors, except that vaginal discharge and pruritus are the most common recognizable antecedent and accompanying symptoms. In Ohmann-Dumesnil's tabulation the earliest age is nineteen and the oldest seventy-one. It appears to bear no relation to coitus or pregnancy, as it is observed among both the unmarried and married, the chaste and the prostitute. The histologic examination, according to Breisky (quoted by Janovski), shows atrophic changes in the upper part of the corium, especially the papillary layer, which is found sclerosed, dull, vitreous looking, and lightly streaked. The glandular structures are almost completely gone, and there is a small-celled infiltration at the bottom of the papillæ. Heitzmann stated that to the touch the patches appear to be thickened epithelium, with subjacent infiltrated connective tissue.

Unfortunately, the malady is persistent, and in spite of **treatment,** usually continuous. The possibility of epitheliomatous development, as in Weir's case, must be kept in mind. The vaginal discharge, if present, should receive attention, as it serves to aggravate, even if its removal does not cure. Heitzmann was the only hopeful observer as regards the result of treatment; he states that he succeeded in curing his patients by removing the thickened patches present in his cases by the curet, and followed by continuous applications of from 0.5 to 2 per cent. of salicylic acid solution, alternating with pyrogallol solution of the same strength. Owing to the tendency to recur, however, the treatment must be repeated in some cases. Baldy and Williams advise the total removal of the affected parts as a curative measure.

AINHUM.

Synonym.—Dactylolysis spontanea.

Definition.—A disease characterized by a slow but gradual linear strangulation of one or more of the toes, especially the smallest, and resulting eventually in spontaneous amputation. This affection, an account of which was first presented by Clark,[1] and since by Da Silva Lima[2] and others, is seen most frequently in the negro and Hindu races, although cases have occurred in Arabs, Mussulmans, and Chinese. Only 4 cases have been recorded in white individuals.

[1] Clark, *Trans. Epidemiolog. Soc'y*, 1860, vol. i., p. 105 (brief notice).

[2] Da Silva Lima, *Arch. Derm.*, 1880, p. 367. Accounts are also to be found in Hirsch's *Geograph. and Histor. Pathology*, New Syd. Soc'y's Translation, vol. liii., 1886, p. 728 (with bibliography), and Fox and Farquhar's *Endemic Skin Diseases of India*, etc., app. vii., p. 114, London, 1876; De Brun, "L'ainhum des auteurs, constitue-t-il une entité morbide distincte, ou bien n'est-il qu'une modalité de la léprose," *Bull. de l'acad. méd.*, vol. xxxvi., 1896, p. 248 (an excellent review, with many references); Pyle, "Ainhum," *Medical News*, 1895, i., p. 85 (a complete presentation with bibliography); Ohmann-Dumesnil's paper in *Medicine*, 1895, p. 202, also contains bibliography; N. D. Brayton (*Jour. Amer. Med. Assoc.*, July 8, 1905), review, case report, and bibliography.

It is met with not infrequently on the west coast of Africa, Egypt, Trinidad, India, in Bahia, Rio de Janeiro, Buenos Ayres, and some other parts of the world. It is also rarely seen in parts of the United States, as Virginia,[1] North Carolina, and Illinois.[2]

FIG. 129.—Ainhum; small toe of left foot already gone, beginning "ligation" of the third toe, and similar tendency in some toes of the other foot, and on the small finger of the left hand; in fact, this constricting tendency is noted on almost all the fingers and toes. Patient is a male adult, aged about twenty-eight, a farmer, native born, with a generalized condition of the skin suggestive of a pityriasis rubra pilaris, and existing since childhood (case referred to in the text).

Symptoms.—The affection begins with a furrow on the plantar aspect, usually of the little toe, at the interphalangeal articulation. This furrow extends quite slowly around the toe, and becomes gradually deeper, until the constriction completely surrounds that member. The end of the toe enlarges to twice its normal size. After several years, varying from four to ten, the phalanx is absorbed, the blood-vessels become obliterated, and the toe drops off. The process, as a rule, is not accompanied by subjective symptoms, although later it is sometimes painful, and toward the end there may be inflammation or ulceration. Sometimes a small ulcer forms in or near the digito-plantar fold, and in such instances the pain is usually very severe. At times other toes on the same or on the other foot may be involved, and even a finger may become affected. Involvement other than the small toe is, however, exceptional. It would seem that it may be

[1] Duhring, "A Case of Ainhum, with Microscopic Examination by H. Wile," *Amer. Jour. Med. Sci.*, vol. lxxxvii., 1884, p. 150.

[2] Herrick, *Phila. Med. Jour.*, 1898, i., p. 246 (with illustrations); Shepherd (Montreal, Canada) also reports a case—*Amer. Jour. Med. Sci.*, vol. xciii., 1887, p. 137; both of these cases were male negroes.

associated with other maladies in which epidermic thickening and keratosis are noted. Hyde and Montgomery[1] noted a similar, gradually constricting band in three white subjects, associated with symmetric palmar and plantar keratosis; and in a patient under my care presenting features suggestive of a general pityriasis rubra pilaris there had been gradual amputation and loss of one small toe, and the little finger and others of the digits and toes were showing beginning evidences of such constriction. The diseased parts usually retain their normal sensibility, and the nail is rarely affected.

Etiology and Pathology.—The disease usually attacks adults, although a few cases have been reported in children. It is quite rare in the white race. More cases occur in males than females. Da Silva Lima, Duhring, and a few others believe that it may occasionally be hereditary. In Duhring's case the father of the patient (negro, aged forty) had lost both his small toes in the same manner, and the mother, at the time of observation of the patient, had the same malady. We are in the dark, however, as to its true causation. It is thought by some to be of parasitic origin. By others it has been attributed to traumatism, owing to the habit of negroes of going barefooted, and also to the wearing of a ligature applied intentionally, but such hypotheses are not borne out by the facts. Nor does the view advanced by Zambaco Pacha[2] that it is an attenuated form of leprosy have any substantial support. It is probably a trophoneurosis. Microscopic examination shows the epidermis and papillary layer, especially the former, to be hypertrophied, the interpapillary downgrowth being quite marked. The blood-vessels are the seat of the following changes: in the walls of the larger arteries the adventitia is greatly increased and the intima much thickened, thus interfering with the caliber of the vessel. The constriction is usually about the shaft of the proximal phalanx, although it also has occurred (Crombie) at the interphalangeal articulation; absorption of the osseous tissue occurs as constricting fibrous tissue takes its place (Eyles).[3] Pyle, from his review of the subject, largely guided by Eyles's histologic study, states that the findings show it to be a direct ingrowth of the epithelium, with a corresponding depression of the surface, due to rapid hyperplasia that pushes down and strangles the papillæ, thus cutting off the blood-supply from the epithelial cells, causing them to undergo a horny change. It would seem that the malady might be pathologically analogous to congenital amputation, as Proust[4] has suggested, a view, however, which does not find general acceptance.

Treatment.—It is stated by Da Silva Lima, Murray, and others, that if, in the earlier stage of the disease, the constricting band is transversely incised freely, the affection may be brought to a stand. When, however, the disorder is of long duration, amputation of the toe is the only recourse.

[1] Hyde and Montgomery, *Diseases of the Skin*, seventh edit., 1900, p. 609.

[2] Zambaco Pacha, *Bull. de l'acad. de méd.*, July 28, 1896; see De Brun's paper (*loc. cit.*).

[3] Eyles, "The Histology of Ainhum," *Lancet*, 1886, ii., p. 576.

[4] Proust, *Gazette des hôpitaux*, 1889, p. 369.

PERFORATING ULCER OF THE FOOT.

Synonyms.—Malum perforans pedis; *Fr.*, Mal perforant du pied; *Ger.*, Perforirendes Fussgeschwür.

Definition.—Perforating ulcer of the foot is a trophoneurotic disease beginning primarily as a degenerative, circumscribed, more or less calloused formation, and developing into an indolent, and usually painless, sinus, leading down through the deeper tissues to the bone.

This malady is rare, and comes more frequently under the notice of the surgeon, although occasionally also under dermatologic observation. It has long been known, especially among the French surgeons. The most elaborate study of the disease, both from a clinical and pathologic standpoint, was that by Savory and Butlin,[1] although others, both before and since, among whom Michaud,[2] Duplay,[3] Lagrange,[4] Schwimmer,[5] Gasquel,[6] have also described and discussed the malady, that of the last named being especially complete.

Symptoms.—It begins with the formation of a localized callosity or epidermic thickening, sometimes essentially the nature of a corn, on the plantar surface, and most usually situated over the articulation of the metatarsal bone with the phalanx of the first or last toe, the regions which are subjected to more or less pressure. Exceptionally, however, it has also been observed on the palm of the hand, as in Terrillon's case,[7] over the metacarpophalangeal articulation of the ring-finger. Beneath this callous plate suppuration and necrosis take place, and the overlying horny covering, or the central part of it, is generally soon cast off, disclosing a shallow ulcer or sinus, which gradually extends more and more deeply, and finally exposes the bone, which soon, as a rule, also shares, to a variable degree, in the necrotic process. The orifice is sometimes surrounded by granulations, beyond which the adjacent epidermis is usually much thickened. This latter is often a conspicuous feature, the sinus apparently having its opening through a callous mass or large, flattened-out, clavus-like formation. The external opening is generally of less diameter than the deeper part of the sinus. There is very little discharge. The formation is extremely indolent and usually painless, and, moreover, shows but little, if any, tenderness on pressure, although walking itself is sometimes painful. The affected part is, especially in places, commonly more or less anesthetic and of subnormal temperature, although occasionally hyperesthesia has been noted. The foot frequently, sooner or later, becomes the seat of other symptoms or changes pointing toward nerve impairment, such as increased hair-growth,

[1] Savory and Butlin, *London Medico-Chirurg. Soc'y Trans.*, vol. lxii., 1879, p. 373 (with colored plate, histologic cuts, and bibliography).

[2] Michaud, "Sur l'état des nerfs dans l'ulcére perforant," *Lyon Médicale*, 1876, p. 5.

[3] Duplay, *Arch. gén. de méd.*, vol. xxvii., 1876, p. 346 (hospital service reported by Marot), and *Jour. de méd. et chirurg. prat.*, vol. xlvi., 1875, p. 13.

[4] Lagrange, "De l'étiologie multiple des mal perforant plantaire," *La Semaine Méd.*, vol. vi., 1886, p. 485.

[5] Schwimmer, *Ziemssen's Handbuch der spec. Pathol.*, vol. xiv., 1883–84, p. 80.

[6] Gasquel, *Thèse de Paris*, July, 1890.

[7] Terrillon, *Bull. de la soc. de chirurg., de Paris*, vol. ii., 1885, p. 155 (case demonstration).

hyperidrosis, usually of a fetid character (bromidrosis), pigmentation, and alterations in the nails. The plantar surface may also exhibit more or less diffused epidermic thickening or several or more scattered callosities or clavus-like lesions. The ulcer is usually single, but in some cases several have been present; in the latter event they may be on the sole of one foot, or both feet may be the seat of the disease. As already stated, exceptionally a similar formation has been observed on the palm.

The course of the malady is slow. Sometimes, but more especially when the patient is kept at rest, the sinus heals up, to break down again usually as soon as the patient becomes active. The destructive process may bring about complete disorganization of the involved joint.

Etiology and Pathology.—The malady occurs principally in association with those diseases in which there are nerve involvement and loss of tissue resisting power, such as locomotor ataxia, anesthetic leprosy, syphilis, peripheral neuritis, diabetes,[1] etc. It is, in fact, accepted that the malady is a trophoneurosis, and dependent upon impairment or degeneration of the central, truncal or peripheral nerves. This is shown in Gasquel's analytic study of 91 cases: 69 had central, and 8 peripheral, nerve-lesion. Of the number, 32 were subjects of locomotor ataxia, and 17 of general paralysis, while 8 were alcoholics and 14 diabetics, and 12 had varied diseases or lesions of the cord, of which 4 were of traumatic origin. While, therefore, there is underlying nerve degeneration, there is but little doubt, too, that local pressure and traumatism are also important factors. As regards sex and age liability, of Gasquel's 91 cases 84 were males and 53 occurred between the ages of thirty and fifty, 19 over fifty, and 7 under thirty, 3 of which were under twenty.

According to Savory and Butlin, there is degeneration of the sensory and nutrient fibrillæ of the affected nerves, resulting from pressure upon them by the thickened endoneurium; the motor fibrils, owing to their thicker medullary sheath and larger size, escape damage. In some cases there is arterial disease, the coats of the vessels being found undergoing calcareous or other degeneration, and this has led to the view that there is a causal relation between such and the perforating ulcer; but this is contradicted by the fact that in other instances the vessels have been in normal condition.

Diagnosis.—When the associated general nervous disease and phenomena are taken into consideration with the local development and behavior of the lesions, a mistake could rarely occur. There may be possible confusion in the beginning with a circumscribed callosity; later with a simple suppurating corn, and still later with a tuberculous ulcer.

Prognosis and Treatment.—Treatment is, as a rule, unsatisfactory, the affection being persistent and exceedingly rebellious, and permanent betterment or cure scarcely possible. Nor have the results in those cases which have been operated upon, either by thor-

[1] Wessinger, *Jour. Cutan. Dis.*, 1889, p. 178, reports a case occurring in a diabetic, in a woman of advancing years, first developing in one foot and then in the other.

ough curetting, excision, or partial or complete amputation, been, except in some instances, under favoring circumstances, permanent, as the malady is apt to recur, even sometimes in the stump of the amputated limb. If curetting is employed, the surrounding hardened horny plate should first be softened and removed by a 25 per cent. salicylic acid plaster. Treves[1] accomplishes this by continuous poulticing with linseed meal, shaving away the softened part from day to day; finally, after its removal has been attained, requiring ten to fourteen days, the poultices are discontinued, and a paste composed of salicylic acid and glycerin, of the consistence of thick cream, with the addition of 10 grains (0.65) of carbolic acid to the ounce (32.), is applied to the sore. Under this plan complete healing often takes place, especially if the bone is not diseased. Success is only temporary, however, unless the pressure can be kept from the part, and for this purpose Savory and Butlin advise an artificial leg applied to the bent knee. For pure surgical methods, excision, amputation, etc., the reader is referred to works on surgery, to the domain of which the management of the malady properly belongs.

MORVAN'S DISEASE.

Synonyms.—Syringomyelia; Myelosyringosis; Analgesic paralysis with whitlow; *Fr.*, Panaris analgésique; Maladie de Morvan; *Ger.*, Morvansche Krankheit.

Definition.—An affection of the spinal cord, with peripheral symptoms, chiefly of the upper extremities, and characterized by muscular atrophy and trophic disturbances, partial anesthesia, and the occurrence of whitlows, cutaneous ulceration, and necrosis.

This disease was first described by Morvan,[2] in the year 1883, under the title "De la parésie analgésique à panaris des extrémités supérieures ou pareso-analgésie des extrémités supérieures," and regarded by him as being a special disease, independent of syringomyelia. The present acceptance, on the whole, however, is to regard this condition as a type of the latter, a view adopted by Charcot, and also previously by Roth,[3] and the correctness of which is confirmed by the histologic findings of Joffroy and Achard[4] and others.

Symptoms.—The disease usually begins insidiously, with pain in an arm, accompanied by loss of muscular power, which is succeeded by analgesia and the occurrence of recurrent whitlows, in some instances occurring in one or several crops. In some cases analgesia is the first symptom which attracts the patient's attention. One or several whitlows may present at the one time, and in the course of the disease as many as nine have been known to occur (Morvan). They may succeed one another rapidly, or several years may inter-

[1] Treves, "Treatment of Perforating Ulcer of the Foot," *Lancet*, 1884, ii., p. 949.

[2] Morvan, *Gazette hebdom.*, 1883, pp. 580, 590, 624, and 721.

[3] Roth, "Contribution a l'étude symptomatologique de la gliomatose médullaire," *Arch. de neurologie*, 1888, p. 161, records a number of cases.

[4] Joffroy and Achard, "Un cas de maladie de Morvan avec autopsie," *Arch. de méd. exper.*, 1890, p. 540 (with histologic and other illustrations); see also paper by Joffroy, "Syringomyelie et maladie de Morvan," *Le Progrès méd.*, 1890, vol. xii., p. 51 (regarding identity and histologic findings).

vene between their appearance. They usually are seen on the fingers only, but occasionally the same condition has been noted on the toes. The phalanges become necrosed and drop off, the hand generally becomes claw-like, great deformity resulting. Trophic and vasomotor cutaneous disturbances, blueness of the skin, fissures, vesicles, bullæ, ulceration involving the sheath of the tendons, changes in the nail substance, pigmentary changes, and glossy skin are quite frequently also observed. Other symptoms are hyperidrosis, more or less loss of tendon-reflexes, impaired vision, scoliosis, and arthropathies. Atrophy of the muscles of the hand and flexor muscles of the wrist and paresis result; the sensations of heat, cold, and pain are lost, although the sense of touch remains.

Ordinarily the upper extremities are alone involved, and it may be confined to one, but usually first one and then the other becomes affected. In other rare instances one leg and foot show the changes, or it may be in both lower extremities, and exceptionally it has involved both arms and legs. A rare instance is also reported by Jacquet,[1] in which trophic ulcerations were on the neck, head, and shoulders. The malady is not only insidious, but often extremely slow in its progress, in some instances, as in Prouff's[2] cases, lasting many years, sometimes with more or less prolonged remissions.

Etiology and Pathology.—This rare affection occurs more frequently in males, and with occasional exception between the ages of twenty and fifty. Some of the cases are seemingly attributable to traumatism, malaria, syphilis, rheumatism, and other constitutional diseases, but it is to be said that these are simply possible factors, and that the underlying cause, in the great majority of instances, is wholly obscure, and certainly cannot be demonstrated. Its resemblance to anesthetic leprosy has been remarked upon, and Zambaco[3] believes it to be a slight or modified form of that disease. Dyer[4] states that, except the absence of bacillus, it has no distinguishing features from some of the mild types of lepra, and reports a few cases in point.

Pathologically, the malady is apparently of central spinal origin. According to Gombault, Joffroy, Church, Marinesco, Dercum and Spiller, and Starr, cavities surrounded by dense neuroglia are found behind the central canal, and are believed to be due to absorption of gliomata. Sclerosis of the posterior horns and columns of the cord has also been noted. Gombault and Joffroy[5] examined the periph-

[1] Jacquet, part vi., plate xviii., *International Atlas*, 1891.

[2] Prouff, *Gaz. hebdom.*, 1887, p. 249 (lasted over forty years).

[3] Zambaco, *Trans. of First Internat. Leprosy Conference*, Berlin, 1898; see also his paper, "Lepra anesthetique et syringomyelie," *Gaz. hebdom.*, 1891, vol. xxviii., p. 196.

[4] Dyer, "Syringomyelia and Lepra nervorum," *New Orleans Med. and Surg. Jour.*, vol. xxi., 1893–94, p. 81; see also Cagney, "Syringomyelia and Leprosy," *Brit. Jour. Derm.*, 1894, p. 375; and Jeanselme's paper, "La Lepre," *La Presse méd.*, 1897, Nos. 84 and 85 (containing suggestive cases, with illustrations); also von Düring, "Die Schwierigheiten in der Diagnose nervösen Lepraformen, insbesondere in Beziehung auf die Syringomyelie," *Archiv*, 1898, vol. xliii., p. 137; Pick's *Fetschrift*, part i. (with 3 plates and references).

[5] Gombault, in Monod and Reboul's paper, *Arch. gen. de méd.*, 1888, ii., p. 28; Prouff and Gombault, "Un cas de mal. de Morvan suivi d'autopsie," *Gaz. hebdom.*, 1889, pp. 308 and 318; Joffroy and Achard, "Un cas de mal. de Morvan avec autopsie," *Arch. de med. exper.*, 1890 (with 7 histologic cuts).

eral nerves and found sclerosis and neuritis. Sachs and Armstrong[1] suggest that the earliest pathologic process may be seated in the peripheral nerves, and that the central changes are secondary. This would be in consonance with the belief that some cases seem to follow a local peripheral traumatism. Both the pathologic findings and clinical symptoms are in accord with the view that the malady is identical with syringomyelia.

Diagnosis.—As already remarked, the clinical features of the disease at times bear a close resemblance to some cases of leprosy of the anesthetic type; but the absence of the bacillus, as well as other differences, are usually sufficient to distinguish. There is occasionally a slight similarity in some of the hand symptoms in certain cases of scleroderma, but that is the whole extent of the resemblance, so that a mistake is scarcely possible if the usual and more extensive symptoms of scleroderma are kept in view.[2]

Prognosis and Treatment.—The outlook for a cessation or cure of the malady is not promising. Its progress, as already stated, is slow, ten, fifteen, sometimes more years elapsing before serious consequences, as regards life, ensue. The resulting deformity and mutilation are gradual. Treatment is essentially symptomatic. The parts are to be protected against injury, and the whitlows and ulcerations treated upon ordinary antiseptic surgical principles. The patient's general health should receive attention. Arsenic, strychnin, silver nitrate, and other remedies have been tried, but no estimation as to their possible value can be definitely stated. Application of the galvanic current up and down the spine, and also along the main peripheral trunks and branches, has been suggested as of benefit.[3]

[1] Sachs and Armstrong, "Morvan's Disease," *New York Med. Jour.*, 1892, vol. lv., p. 482 (with bibliography).

[2] Pospelow, in a recent valuable exhaustive paper, "Trophische Störungen der Haut bei spinaler Gliomatose oder Syringomyelie," *Archiv* (Pick's *Festschrift*, part ii.), vol. xliv., 1898, p. 91, believes, from his study of the subject, that scleroderma is occasionally associated with the malady.

[3] Other valuable contributions on the disease are: Bruhl, *Contribution a l'étude de la syringomyelie*, Paris, 1890 (an exhaustive monograph with bibliography); Thibiérge, "Les alterations cutanées de la syringomyelie," *Annales*, 1890, p. 799; Schlesinger, *Die Syringomyelie*, Leipzig and Vienna, 1895 (a complete exposition with bibliography).

CLASS VI.—NEW GROWTHS.

CICATRIX.

Synonyms.—Scar; Scar-tissue; *Fr.*, Cicatrice; *Ger.*, Narbe.

Definition.—Scar is, briefly defined, a connective-tissue, soft or firm, reddish or whitish, new formation replacing loss of substance.

The appearances of ordinary scars are well known, and have, to some extent, been already described in the preliminary chapter on lesions of the skin. According to the causes which have led to its formation a scar may be linear or irregular, slight or pronounced. At first the color is usually a pinkish or reddish, frequently with variable pigmentation, later becoming, as a rule, white and glistening. The normal scar is flat, on a level with the skin or somewhat sunken, or simply replacing tissue loss. In others—atrophic scars—there is considerable depression, the scar-formation developing only sufficiently to cover or skin over the preceding depressed wound or ulcer. This is particularly noted in the scars replacing substance loss in some diseases, as smallpox, acne varioliformis, etc. On the other hand, the scar-tissue formation, instead of ceasing at the point of compensatory replacement, continues, and the result is a **hypertrophic scar,** sometimes projecting but slightly, at other times becoming of considerable proportions; it never extends laterally beyond the original substance loss which it replaces—does not, in fact, invade the surrounding healthy tissue, in this respect differing essentially from keloid, to which it bears resemblance. Indeed, ordinarily, from a contraction of the constituent tissue of the scar, the surrounding healthy parts are usually drawn upon somewhat and stretched, so that finally the scar area is much smaller than the area of substance loss which it replaces. The scar is thin or thick, depending chiefly upon the depth of the tissue loss. Damage to the integument must involve at least the upper part of the corium; destruction, which extends only to the corium, although removing the whole epidermis, including the rete, does not leave a scar, being replaced; hence in eczema and similar diseases the disease disappears without trace. Destruction of the superficial part of the papillary layer is doubtless often possible with scarcely perceptible, certainly rarely permanent, scarring. Even with destruction of the whole depth of the papillary layer there is usually but shallow scarring, and this generally eventually practically disappears.

The division of cicatrices into *traumatic scars* and *pathologic scars* is of scarcely any import—the former, as readily inferred, due to injury, the latter the consequence of some morbid process. In the latter class the shape often gives a clue to the causative malady, as in the circinate or segmental scar grouping of the late syphilodermata. The syphilitic scar is, moreover, usually quite soft; on the other hand, the cicatricial formation in lupus vulgaris is often thick, tough, and stringy. It is true scars even from the same disease will sometimes vary considerably, being soft and smooth, or hard, irregular, or keloidal in appearance. As a rule, there are no subjective

symptoms, but occasionally there may be attacks of a "burning sensation" or of pain, probably from an entrapped and compressed nerve-fiber; when about the joints, mobility may be more or less impaired, due to the tough and unyielding character of the formation and to the resulting contractions; these latter are sometimes sufficient to produce considerable distortion.

Pathology.—As is to be supposed, the principal and practically entire constituent histologically of a scar is connective tissue, and this is found to consist of coarse interlacing bundles, with absence of glandular structures, hair-follicles and hairs, and furrows. In its earliest stage the formation resulting from the granulation tissue is primarily of myxomatous nature, rich in vascular supply; gradually this myxomatous and myxofibrous granulation tissue becomes changed into a purely fibrous cicatricial tissue (Heitzmann),[1] and the blood-vessels become lessened in size and may be obliterated. According to Heitzmann, "the old view that papillæ are absent is erroneous, for these are found in almost every scar, though, as a general rule, they are shallow and irregular. Even in cases where the surface appears smooth to the naked eye shallow papillary formations are found to exist." This is contrary to the opinion of Kaposi and some others, who state that they are always absent. The epithelial layers do not differ from those of normal thin portions of skin (Heitzmann).

Treatment.—Scars are permanent formations, except those following extremely superficial substance loss, which usually, after some years, partly or completely disappear. There is, in fact, in almost all scars of small and not too deep a character, a tendency to become slightly less conspicuous as the years go on. Exceptionally, however, there is an increased upward growth, which may reach a marked character, as in the so-called hypertrophic scar.

Treatment of these formations is usually without much effect. When small, numerous, and close together, massage and slightly or moderately stimulating applications, such as are sometimes of some influence in lessening senile looseness of the skin, or wrinkled skin, may, if persevered in, bring about some improvement. Ordinarily, however, unless the scar is unnecessarily large and unsightly, nothing is to be done; but in the latter cases, when practicable, an operation—excision of the cicatrix—and slight undermining of the skin of the flaps, permitting greater stretching and a closer adaptation, will sometimes result in replacing an unsightly scar by a linear or narrow cicatricial band; or the plan of plastic operation and transplantation can be adopted. Hypertrophic scars can also be thus treated, sometimes, however, showing a recurring tendency, as is exhibited in their closely analogous formation—keloid. Vidal advised thoroughly hashing the part with parallel and cross incisions. In fact, the various plans for the treatment of hypertrophic scars are the same as in keloid (*q. v.*). This may also be said of the plans for the treatment of painful scars. Röntgen-ray treatment,[2] pushed to the point of moderate reaction, has proved of some service in occasional instances, more especially in small-pox and acne scars.

[1] Heitzmann, Morrow's *System*, vol. iii. (Dermatology), p. 471.
[2] Varney, *Internat. Jour. Surg.*, Oct., 1903, p. 309.

KELOID.

Synonyms.—Cheloid; Alibert's keloid; Kelis; Kelos; *Fr.*, Chéloïde; Kéloïde.

Definition.—Keloid is a fibrocellular new growth of the corium appearing as one or several variously sized, irregularly shaped, elevated, smooth, firm, pinkish, or pale-reddish cicatriform lesions.

Symptoms.—The growth begins as a small, hard, elevated, occasionally somewhat deeply imbedded, pinkish or reddish tubercle or nodule, increasing gradually in size. Usually months or years elapse before the tumor reaches conspicuous dimensions. In fact, not infrequently, and more especially in multiple cases, the growth increases but slowly, and, after attaining small proportions, sometimes scarcely greater than a large pea or bean, remains stationary more or less indefinitely or permanently. These small growths are of a pinkish-white or reddish color, firmly seated in the corium, distinctly elevated, and usually smooth and glossy, with a rounded or somewhat flattened top, and with almost perpendicular or slightly sloping sides. It is hard, and the surface may show, on close inspection,

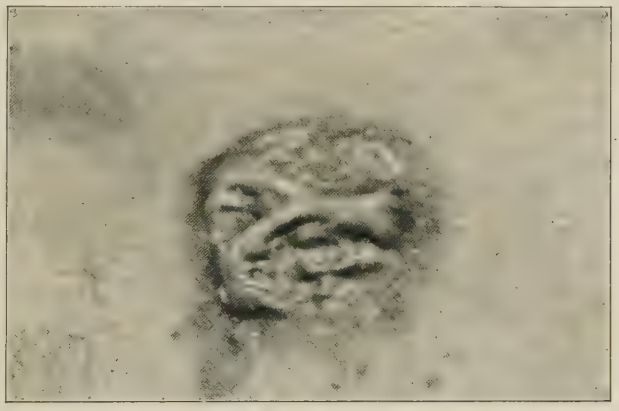

FIG. 130.—Keloid; over sternum.

one or two capillaries. Ordinarily, however, and particularly in the single growth, it gradually increases in size, spreading laterally by an invasion of the surrounding skin, and frequently extending upward as well, sometimes finally reaching considerable elevation. Very commonly the border extends outward in the shape of several or more claw-like projections; to this feature is owing the name keloid. The process may go on slowly or somewhat rapidly, and in extreme cases a large area may be involved and enormous proportions reached.

In average cases, when developed, the growth is observed to be one, several, or more inches in diameter, is sharply defined, elevated, hard, rounded or oval, fungoid or crab-shaped, and firmly implanted in the skin, and having a scar-like aspect. It is of a pinkish, pearl white, or reddish color, commonly devoid of hair, with no tendency to scaliness, and with usually several vessels coursing over it. In some instances it is elongated and ovalish. The surface, which is

generally shiny and glistening, with the epidermis having a stretched and tense appearance, is flattened or irregularly rounded, or with slight nodular projections; often the central part is slightly lower than the main and peripheral portions. Sometimes, instead of the colors just named, it is of slight or distinctly purplish hue; and occasionally, in place of the rounded, ovalish, lozenge- or crab-shaped growth, the formation is exceedingly irregular, with prolongations which may extend to a considerable distance, and from which also may go claw-shaped extensions; exceptionally it is streak- or band-like. In general the height is about $\frac{1}{4}$ to $\frac{1}{2}$ inch, although in the enormous keloids it may reach several inches or more, the whole growth assuming large, tumor-like proportions.

While in many instances there are no subjective symptoms,—which, in fact, may be said to be the rule,—in others itching or tenderness is complained of, and occasionally it is spontaneously painful. The most frequent situation for keloid is over the sternum, although other parts of the upper trunk are often the site of the growth; it may also appear on the face, ears, neck, and extremities. Commonly but one or two lesions are present, but there may be several or more up to a considerable number, as in the instances observed by Wilson,[1] Schwimmer,[2] De Amicis,[3] Goodhart,[4] Smith,[5] Hardaway,[6] and others. In those cases following small-pox the lesions are usually numerous, though, as a rule, small. In some of the instances of multiple keloid the growths are more or less symmetrically arranged, as in the cases of De Amicis and Smith just referred to, and also in an instance observed by Vidal.[7]

Etiology.—The cause of keloid is not known. It has been the custom to divide these growths into two varieties—those that arise at the site of burns, cuts, acne, syphilis scars, etc., designated *scar keloid*, *cicatricial keloid*, *false keloid*, *spurious keloid*, *secondary keloid*, and those that are believed to originate in normal and uninjured skin, as *idiopathic keloid*, *primary keloid*, *spontaneous keloid*, *true keloid*. In later years there has, however, been less and less tendency to make these two divisions, and the doubt of a keloid arising without a slight traumatism is pretty generally entertained. When we consider that the injury which often seems to start the pathologic process may be extremely slight, such as scratching, insect-bites, slight pricks, and the like, it can readily be seen how such could be easily overlooked or actually be so insignificant as to go

[1] E. Wilson, *Diseases of the Skin*, 1867, p. 381 (39 growths—30 on the breast, 9 on back), cited by Schwimmer.

[2] Schwimmer, "Die multiple Keloid," *Archiv*, 1880, p. 225 (105 growths, more or less general, with review of the subject and principal references to date; histologic report of this case by Babesiu, p. 237).

[3] De Amicis (Chéloïde spontanée multiple), *Trans. Internat. Dermatolog. Cong.*, Paris, 1889, p. 93 (318 growths, symmetrically on the scapulohumeral regions and arms; 3 colored plates).

[4] Goodhart, *London Clin. Soc'y Trans.*, vol. xiii., 1880, p. 51 (development from small-pox scars—numerous and quite pronounced, with colored plate of face).

[5] W. G. Smith, *Brit. Jour. Derm.*, 1889, p. 157 (numerous, but number not stated, more or less general, and, upon the whole, a decided tendency to symmetry).

[6] Hardaway, *Manual of Skin Diseases*, second edit., case illustration op. p. 287 (negro—with numerous lesions on trunk and arms).

[7] Vidal, *Trans. Internat. Dermatolog. Cong.*, Paris, 1889, p. 103 (12 growths, symmetric over shoulders and nape of the neck).

unrecognized, and thus give rise to the assumption that the keloid was spontaneous. Even the more or less general cases, such as those of De Amicis, Schwimmer, and others, which are apparently spontaneous, and which are usually quoted as convincing examples of this variety, could be readily explained upon the assumption of such trifling abrasions or injuries as just noted. There is, therefore, in my judgment, considerable ground for Unna's[1] opinion that the most frequent site for the so-called spontaneous keloid growth, over the sternum and about the breast, is due to the irritation and scratching invoked by seborrheic eczema, so common in this region. Crocker suggests that possibly the frequency in this region "may be accounted for, in women, by the pressure and friction of the stays, and, in men, by the fact that this part is exposed to similar influences, as leaning against a desk, etc."

It would seem, in fact, that the evidence against the possibility, certainly probability, of a keloid arising without some break in the continuity of the cutaneous tissues, be it ever so slight and superficial, is extremely remote.[2] The arising of the growth in trifling or severe destructive injuries and burns, usually after apparently normal scarring has taken place, is common enough; and sometimes the increased growth does not extend beyond the original scar, constituting the already described *hypertrophic scar*, and which, for this reason, is considered distinct from keloid; more commonly, however, the process extends and invades the surrounding tissue, representing the keloid growth proper. It is to be noted, however, that relatively few persons are susceptible to this development, as it is rather uncommon, so that a predisposition of the tissues is to be accepted. This predisposition is especially observed in negroes, in some of whom, as well as much less frequently in the white race, traumatism,[3] even of the slightest character, or scarring cutaneous lesion, leads to keloidal development. They may arise from unsuspected causes, as in those noted by Block[4] and Crocker.[5] According to Taylor (*loc. cit.*), ½ of 1 per cent. of syphilitic cicatrices become the seat of keloid. It is possible that the nature or the intensity of the irritant or character of the irritation may be a factor in some instances, as suggested by Welander's[6] case, in which, in the same tattooed figure, keloid

[1] Unna, *Histopathology*, p. 839.

[2] See interesting and exhaustive report on Goodhart's case and keloid in general, in its various aspects, by committee (Duckworth, Liveing, Crocker, Hutchinson, and Goodhart), in *London Clin. Soc'y Trans.*, vol. xiii., 1880, p. 54.

[3] Taylor, *Jour. Cutan. Dis.*, 1893, p. 114 (Soc'y Trans.), exhibited a rather remarkable and extreme instance of a colored woman, aged twenty-three, who, from the constant carrying of heavy loads of brush and stone, which knocked against and lacerated the skin through her thin clothing, developed large masses of keloidal tissue, encircling the waist, and very closely resembling masses of intestines; for the same reason large keloidal growths appeared on the arms, shoulders, and breasts, and there was also a large lesion on the ear, following ear-piercing.

[4] Block, *Jour. Cutan. Dis.*, 1895, p. 107 (with 2 illustrations), records an instance of rather extensive typical keloidal growths following some months after a burn produced by a stroke of lightning, the burn having been superficial and leaving no scar.

[5] Crocker, *Diseases of the Skin*, third edit., p. 938, states one of the most extensive cases of keloid recorded followed a prolonged attack of prickly heat in a soldier in India—see Longmore's report of this case (with 2 illustrations), *Trans. London Med.-Chirurg. Soc'y*, vol. xlvi., 1863, p. 105.

[6] Welander, *Nordiskt. med. Arkiv*, 1893, No. 3—quoted by Unna (*loc. cit.*).

developed only where the part was tattooed with red, and not where it was tattooed with blue.

Sex and age have but little if any influence; for obvious reasons the male sex, being more exposed to the usual exciting factor of traumatism, probably presents the greater number of cases, although the contrary has been stated by some authors. While observed at any age, it is most common between the ages of twenty-five and fifty. In occasional instances a family and hereditary vulnerability has been noted (Hebra, Wilson, Hutchinson).[1]

Pathology.—The formation is a connective-tissue new growth, as demonstrated by the histologic studies of Langhans,[2] Warren, Crocker, Neumann, Leloir and Vidal,[3] Unna,[4] Joseph,[5] and others, although beyond the fact of traumatism or cutaneous lesions being usually the initial factor, but little is known of its pathology. The growth takes its start in the corium, and, as Warren and others have shown, about the vessels, and consists of dense bundles of fibrous connective tissue running parallel to the surface and usually in the direction of the long axis; here and there, however, they run vertically. The whole cutis is occupied by this new formation, a layer of loose connective tissue which is more or less highly vascular, separating it from the epidermis, and, in fact, incompletely encapsulating the growth; the tumor itself centrally is not, however, rich in blood-vessels. Nuclei and spindle-shaped nucleated bodies are noted in some abundance along the vessels in the peripheral part, although scanty in the body of the growth. According to Warren, the vessels are affected far beyond the keloid mass, an observation confirmed by Crocker's investigations, and this probably explains its recurrence after what would appear to be complete removal of the tumor. Kaposi makes three divisions histologically of keloidal growths—spontaneous keloid, keloid originating in a scar, or false keloid, so called, and hypertrophic scar. In the first, he states, the epidermis, together with the papillæ, is normal, in the third—hypertrophic scar—the papillæ are gone, destroyed by the disease or traumatism which gave rise to the scars; in the false keloid the conditions of the other two are usually combined. The absence of papillæ (Babesiu) in Schwimmer's case, presumably a typical example of spontaneous keloid, and the finding of shallow papillæ in hypertrophic scar (Heitzmann), show that these divisions are to a great extent purely arbitrary, although Leloir also upheld Kaposi's differentiation between the "true" and "false" keloidal growths. Joseph likewise, in his admirable paper, remarks that his own investigations teach that there are histologic differences in these several keloidal formations. Nevertheless the aggregate investigations show that the histologic conditions in keloids originating apparently spontaneously, and those

[1] Hutchinson, *Edinburgh Med. Jour.*, 1897, vol. xliii., p. 5.

[2] Langhans, *Virchow's Archiv*, vol. xl., 1867, p. 330 (case illustration, 6 histologic cuts, review of previous investigations and references).

[3] Leloir and Vidal, *Traite descriptif*, 1889–93, p. 111 (with résumé of previous observations and references). [4] Unna, *Histopathology*, p. 839 (with principal references).

[5] Joseph, *Archiv*, 1899, vol. xlix., p. 277 (with histologic cuts—4 photomicrographs showing gross features, and 10 colored cuts showing finer structure; based upon study of hypertrophic scar, true keloid, and false keloid, with a complete résumé and references of the investigation of others).

These four papers give a complete presentation of the subject and literature.

starting at the site of a traumatism or a scar, except for the difference naturally to be found at the seat of the latter, and those naturally to be found in the early and later stages, show no material divergence. The glandular structures, hair-follicles, and muscular fibers are not found within the growth, but are pushed aside, where they are, according to Crocker, noted to be copiously infiltrated with round cells, obscuring or even breaking up their structure.

Diagnosis.—This is usually a matter of no difficulty. It resembles hypertrophic scar, but this latter, which, although essentially keloidal in appearance and in its upward growth, does not extend beyond the limit of the original scar or line of injury. In many cases the claw-like prolongations, often present even in the early stages, disclose the keloidal nature. As spontaneous keloid and keloid originating in a traumatism or scar are essentially, and probably wholly, identical histologically, and certainly clinically, there is no need of undertaking the impossible task of differentiating the one from the other.

Prognosis.—With but few exceptions the growth is persistent, and usually irresponsive to treatment. In many instances, however, after attaining an indefinite development, often quite small, it remains stationary. Hutchinson[1] takes rather a favorable view, stating that (he includes hypertrophic scars in this generalization): "In a very large majority of cases keloid shows a tendency, after some years' duration, to spontaneous disappearance," and "the common cases in which, in children, the scars of burns are attacked, almost invariably get well, and their duration is in many instances only short." This favorable opinion is, however, not generally shared, but from my own observations I should say that in a moderate proportion of the aggregate cases gradual lessening of the growth finally takes place, and in some instances almost complete disappearance. Those developing at the site of small-pox scars seem less hopeless than in other instances, as illustrated by Goodhard's case (*loc. cit.*), in which involution was rapid. Taylor (*loc. cit.*) states, as to keloid found in connection with syphilitic scars, that two forms are found—the acute and succulent variety, which causes a good deal of pain and pruritus, and which, after a few months or a year, undergoes involution; and, second, the chronic variety, which gives rise to little, if any, discomfort, but is permanent.

Fortunately, keloids are benign in character and remain throughout as such, although, like any projecting abnormal growth, constant and repeated irritation might, especially in those advancing in years, set up malignant change.[2] Such an outcome is, however, to be looked upon as exceptional and probably as purely accidental.

Treatment.—The treatment of keloid, it must be admitted, is rarely wholly satisfactory. In average examples of keloid, unless in a conspicuous situation, treatment is rarely sought, and, upon the whole, except beyond the trial of mild applications, are just as well let alone. There is nothing to be expected ordinarily from any

[1] Hutchinson, *Med. Times and Gazette*, 1885, i., p. 671.

[2] Anderson, *Lancet*, i., 1888, p. 1025, records an instance in which malignancy developed in a growth in the abdominal region, which was looked upon as primarily of keloidal nature.

constitutional remedies, although in one instance J. William White[1] noted a diminution in a growth in a patient to whom thyroid extract was being given in moderate dosage. Led by White's observation, I have tried this remedy in several cases, and in one, a keloid developing from a large scar, there has been some material diminution, although whether the result of such treatment or a spontaneous subsidence I am not prepared to say. In addition to this preparation, in multiple cases especially, a possible influence from the continued and increasing administration of arsenic should be considered.

The palliative measures which have seemed to me, in some instances, of service in retarding the growing tendency and lessening the pain and itching sometimes complained of, and occasionally in reducing the size of the growth, consist of frictions with a 10 to 25 per cent. ichthyol ointment, the continuous application of a plaster-like ointment made up of salicylic acid, 10–20 grains (0.65–1.35), lead plaster and soap plaster, each, 3 drams (12.), and petrolatum to make the ounce (32.); or this same ointment, with the still further addition of 1 or 2 drams (4.–8.) of ichthyol. Mercurial plaster continuously applied is also beneficial in some instances. The usefulness of these applications is in accord with Professor Duhring's[2] experience, who considers that iodin and lead and mercurial plasters are the best remedies to be used with the view of promoting absorption. Occasionally, in the painful growths, belladonna, cocain, and menthol applications are necessary, and very exceptionally morphin injections. Recently Balzer and Mousseaux,[3] and subsequently Péré,[4] reported a favorable effect with a plan of treatment previously suggested by Marie,[5] consisting of injections into the tumor, at many points, of a solution of creasote in olive oil of 20 per cent. strength, until the tumor becomes pale; inflammation, tumefaction, and sloughing of a portion usually result, and, when healed over, injections are again made. Tousey,[6] and subsequently Newton[7] and Crocker and Pernet,[8] have noted somewhat favorable influence from injections of thiosinamin, Tousey recording a cure, although Jackson,[9] in a number of cases, failed to get any result. It is administered as a 10 to 15 per cent. solution in equal parts of glycerin and water, or in alcohol, 10 to 20 minims (0.65–1.35) at an injection; or it may be given, in the dose of 3 grains (0.2) daily, by the mouth.

Should treatment be demanded and the milder measures fail, if thought advisable operative measures may be cautiously tried. Of these, the safest and least likely to be attended by a possible result of increased growth is electrolysis; next in order may be mentioned punctate scarification, linear scarification, and last, excision. The method

[1] J. William White, "Memorandum as to a New Use of Thyroid Extract," *University Med. Mag.*, Aug., 1895 (scar keloid; with illustrations).

[2] Duhring, *Diseases of the Skin*, third edit., p. 461.

[3] Balzer and Mousseaux, *Annales*, 1898, p. 1147.

[4] Pére, *Jour. mal. cutan.*, 1899, p. 454.

[5] Marie, *Bull. et mem. soc. méd. des hôp*, 1893, vol. x., p. 167.

[6] Tousey, "Thiosinamine: A Treatment for Inoperable Tumors and Cicatricial Contractures," *New York Med. Jour.*, 1896, vol. lxiii., p. 579.

[7] Newton, *ibid.*, 1897, vol. lxvi., p. 624.

[8] Crocker and Pernet, *Brit. Jour. Derm.*, 1899, p. 431 (case demonstration).

[9] G. T. Jackson, *Diseases of the Skin*, fourth edit., p. 330.

by electrolysis was suggested by Hardaway,[1] although admitting that it was only occasionally beneficial; it has also been favorably spoken of by Brocq[2] and Crocker.[3] It is seldom curative, but, as I can myself confirm, it quite frequently stays the growth or reduces its size, and lessens or abolishes the pain and itching sometimes present. A current of about 5 milliampères is used, the needle being thrust from the edge slantingly toward the center, and moderately deeply, and at various places, close together. It may, especially in the larger growths, also be inserted at different points in the top of the tumor. Crocker advises it to be thrust from the side of the base, at close intervals, so as to cut off the blood-supply. It is somewhat painful, and, as a rule, but a limited amount can be treated at the one time, and usually several repetitions may be necessary in the same portion. It may be stated to be, as also Leviseur[4] and Joseph[5] found it, a moderately successful plan in some cases, and generally those where the growth is small.

The next plan in point of value, in my experience, is that of linear scarification, as originally suggested, I believe, by Leloir and Vidal,[6] the parts being thoroughly cross-tracked, as in lupus vulgaris (*q. v.*). Immediately afterward a mild antiseptic dressing is applied, such as a wet or dry boric acid dressing, followed the next day and subsequently by the continuous application of one of the plaster-like applications already named, and compression made by a pad and bandage. Lawrence[7] was successful in a case with this plan, combined with persistent, moderate pressure secured by placing over the minced growth large rubber tubing and binding firmly down by adhesive strips.

Excision is the most common surgical method, but it is rarely permanently successful, recurrences usually taking place. It is probable that if the line of excision were extended far beyond the apparent borders of the tumor, results would be more satisfactory, as in this way the blood-vessels in the immediately adjacent seemingly healthy tissue, which, as remarked, Warren and Crocker have shown to be involved, would be removed, and no focus for new development left.

While these various operative methods prove useful in some instances, it is to be borne in mind that not infrequently renewed activity in the progress of the growth is noted to follow, although I have not observed this in the cases in which electrolysis was employed. This latter method, conjointly with the application of the compound plaster named, has seemed to me the most conservative plan, although only occasionally more than moderately successful. Recently favorable influence has been claimed for the X-rays.

[1] Hardaway, *Jour. Cutan. Dis.*, 1889, p. 112.
[2] Brocq, *Traitement des maladies de la peau*, second edit., p. 373.
[3] Crocker, *Brit. Jour. Derm.*, 1899, pp. 297 and 431 (case demonstration).
[4] Leviseur, "Cutaneous Electrolysis," *New York Med. Record*, 1899, vol. lvi., p. 262.
[5] Joseph, *loc. cit.*
[6] Leloir and Vidal, "De la chéloïde," etc., *Annales*, 1890, p. 193 (an exhaustive exposition of the subject of keloidal growths, with treatment by Vidal; with numerous references).
[7] Lawrence, *Brit. Med. Jour.*, 1898, ii., p. 151.

DERMATITIS PAPILLARIS CAPILLITII.[1]

Synonyms.—Acne keloid or acné cheloïdienne (Bazin); Sycosis frambœsiformis (Hebra); Dermatitis papillomatosa capillitii; Folliculitis nuchæ sclerotisans (Ehrmann).

Definition.—A frambesiform disease of the nucha, and usually extending upward toward the occiput, presenting mixed sycosiform, nodular, and keloidal aspects.

Symptoms.—The disease begins at the lower occipital region, or just at the border of the hair, with the appearance of a number of isolated cutaneous tubercles or sycosiform or acne-like lesions, pinhead to small pea in size, but which grow larger, and, with the accession of new lesions, soon become closely grouped or bunched. They are then frequently pea- to small cherry-sized, red, pale red, or whitish in color, and sometimes contain pus; or pus may form beneath the mass here and there, and tend to undermine; the nodule, upon incision, emits a creaking sound. In some instances the surface becomes raw, and then may later present a papillomatous granulation tissue growth, the whole being occasionally covered with crusts, and secreting a gummy or seropurulent fluid, and emitting an offensive odor.



FIG. 131.—Dermatitis papillaris capillitii; man aged thirty-nine, of five years' duration; some slight undermining, keloidal aspect predominant.

There is more or less scar-tissue with hair loss, and here and there are seen small projecting tufts of hair; some of the hairs are atrophied and crooked. In some or many of the lesions, or at many points in the disease mass, keloidal changes are noted; and in the milder cases the eruption presents a decidedly keloidal and tubercular, acne-like appearance. It is this keloidal tendency which distinguishes it from an ordinary sycosiform inflammation. The disease develops slowly, and

[1] Literature: Kaposi, *Pathologie und Therapie der Hautkrankheiten*, Wien, 1880, and subsequent editions; Morrant Baker, *Trans. London Path. Soc'y*, vol. xxxiii. (1882), p. 367 (with colored plate); Williams, *ibid.*, vol. xxxv. (1884), p. 397 (with histologic plate); Hyde (2 cases), *Jour. Cutan. Dis.*, 1883, pp. 33 and 78; Marcacci, *Giorn. ital.*, 1887, p. 295; Eve, *Illus. Med. News*, London, June 8, 1889 (with colored plate); Dubreuilh (histology), *Annales de la Policlinique de Bordeaux*, 1889, p. 107; Heitzmann, *Jour. Cutan. Dis.*, 1889, p. 450; Crocker, *Diseases of Skin*, second edit., p. 624; Leloir et Vidal, *Traité Descriptif;* Melle, *Giorn. ital.*, 1891, p. 181; Mibelli, *ibid.*, 1893, p. 469; Ullmann, *Archiv*, 1893, vol. xxv., p. 727; Ehrmann, *ibid.*, 1895, vol. xxxii., p

in some cases, after several months or years, halts, and remains apparently stationary. Rarely retrogressive changes are observed in some parts. On the other hand, the malady may progress and reach considerable dimensions, both in area, extending up to the vertex, and forming somewhat massive projections. The several cases coming under my observation were moderately developed, constituting the average case met with.

Etiology and Pathology.—The cause of the disease is not known. It is infrequent. It may occur in either sex, but is much more common in males, and is most frequently seen during early adult and middle age.

There is some difference of opinion among investigators as to whether the process begins about the follicles (Leloir and Vidal, Dubreuilh, Unna, Ehrmann) or as an inflammatory process in the cutis (Kaposi, Ledermann). Clinically its origin seems certainly connected with the follicles, and it appears as if due to some infection. Besnier and Doyon consider it a papillomatous growth developing from acne lesions, etc., and traumatism. The formations in the earlier stages are of the nature of highly vascular papillary growths, with structure somewhat similar to granulation tissue; later they undergo sclerosis, with atrophy of the hair-follicles. Round-cell infiltration is noted in the corium; hypertrophy of the epidermis and enlargement of the papillæ and blood-vessels are also observed. Hyalin corpuscles are seen (Mantegazza, Secchi), which the latter observer considers to be blastomyces. Ehrmann found staphylococci. In my cases, 6 in number, the sclerotic or keloidal element was quite a marked feature. Of the 6 cases, all were men—4 negroes and 2 whites; 2 of the negroes were brothers.

Diagnosis.—Its features are so peculiar that it can scarcely be confounded with any other disease. In its beginning sycosis and acne nodules are suggested.

Prognosis and Treatment.—No tendency to spontaneous cure is noted, but in some instances, as already remarked, the process halts after a variable time; it may, however, be progressive. The general health is not influenced by it. It is extremely rebellious to treatment, commonly resisting all measures; moderate improvement is, however, not unusual.

The treatment used is similar to that employed in sycosis. The hairs are to be extracted, the parts frequently cleansed, and any pustules or pus-accumulation evacuated. A sulphur and ichthyol ointment is the most valuable: 1 to 2 drams (4.–8.) of the latter to an ounce (32.) of sulphur ointment full strength or weakened, according to inflammatory conditions. The object is not irritation, but mild antiseptic stimulation. Resorcin and boric acid lotions are also at times of some service. Of the operative methods commended as of some benefit may be mentioned electrolysis (Ehrmann), linear scarification

323; Porges (with 4 colored histologic cuts and bibliography as to histology), *ibid.*, vol. lii., 1899, p. 323; Stelwagon (brief report of case with photo.), *Jour. Cutan. Dis.*, 1893, p. 230; Secchi, *Monatshefte*, 1896, vol. xxiii., Nov. 15; Ledermann (histology), *Verhandlungen der Deutschen Gesellschaft, V. Cong.*, 1896, p. 443; Van Harlingen, *Trans. College of Physicians*, Phila., 1897, p. 208; Dyer, *Amer. Jour. Derm. and Gen.-Urin. Dis.*, July, 1899.

(Hallopeau and Leredde), and excision (Ledermann). Van Harlingen states that he has cured several cases in the incipient stage by thorough destruction by the electro-cautery; in one case in which complete excision had been made by a surgeon there was a return of the growth. Judging from its favorable influence in sycosis, the X-ray treatment should be of value in this disease.

MOLLUSCUM CONTAGIOSUM.

Synonyms.—Molluscum epitheliale; Molluscum sebaceum; Epithelioma molluscum; Epithelioma contagiosum; Acné varioliforme (Bazin).

Definition.—A contagious disease of the skin characterized by pin-head- to pea-sized or larger, rounded, semiglobular or slightly flattened, pearl-like elevations, of whitish or pinkish color, and with minute central depression.

Symptoms.—The lesions begin as pin-head-sized, waxy-looking, rounded or acuminated elevations, which often, in the very beginning, bear some resemblance to minute warts. They gradually attain the size of pin-heads and small and large peas, and display, sometimes quite perceptibly, in others visible only on close inspection, a depression or umbilication, in the center of which is noted a darkish point representing the mouth of the follicle. In the beginning they are usually rounded or semiglobular; as they increase in size the top becomes somewhat flattened. They have a broad base, but occasionally in some cases in a few lesions, after some duration, a tendency to become pedunculated is noted. They may be either whitish, almost skin colored or pinkish, and often look not unlike drops of wax or small

Fig. 132.—Molluscum contagiosum.

pearl buttons. Sometimes they have a slight resemblance to the prepustular lesion of variola; hence the French term, acné varioliforme (Bazin). While firm at first, and sometimes continuing so, they usually, as they increase in size, tend to soften slightly, and if squeezed emit from the central orifice a semisolid, cheesy-looking substance. Sometimes this latter, slightly or moderately hardened,

projects a line or two out of the opening. Some lesions, after weeks or months, having attained the size of a moderately large pea or small cherry, redden, become inflamed, tend to break down and suppurate, and then heal up and disappear, usually without trace. As a rule, however, they are sluggish in character and unaccompanied by any active signs of inflammation. Not infrequently, indeed, the lesions disappear slowly by absorption, and possibly partly by desiccation, without apparent previous softening. The course of a single lesion varies, sometimes disappearing spontaneously in several weeks or a few months, or lasting one or two years. As a rule, while the older ones are gradually disappearing new growths may present, so that, if at all numerous, all sizes and various stages are commonly to be seen. In most cases 10 or 12 lesions are present, although occasionally they may be quite numerous.[1] They are usually discrete, but exceptionally 2 or 3 may be bunched together,[2] and in rare instances are somewhat closely packed, forming almost a solid mass.[3] Their most common seat is the face, but not infrequently, along with those on the face or independently, the growth occurs on other parts,[4] more especially such as the neck, breast, arms, scalp, and genitalia. In the last region they seem more common on the Continent of Europe than in England or in our own country. In rare instances the eruption has been more or less generalized, sparsely scattered, or numerous. On the face, the most common situation is about or on the eyelids, and even on the border, in this latter situation sometimes exciting considerable irritation, and exceptionally a conjunctivitis (Steffen, Muetze).[5] While in almost all cases the size of the lesion may vary between pin-point and an average pea in size, occasionally they are somewhat larger, and very exceptionally they may attain much greater dimensions, rarely, however, the extreme size (molluscum giganteum), of one to several inches in diameter, as in cases described by W. Smith,[6] Laache,[7] Kaposi,[8] and a few others.

[1] Frick, *Jour. Amer. Med. Assoc.*, 1899, i., p. 536, reported a case, a male adult, with over 400 lesions, chiefly about face, neck, forehead, and scalp; and also cites other instances, with references.

[2] Crocker, *Diseases of the Skin*, third edit., p. 730, describes a case in which there were compound tumors with 2 or 3 openings or plugs.

[3] Hallopeau, *Jour. mal. cutan.*, 1899, p. 405, records a remarkable case in a woman presenting numerous and variously situated lesions, in some places closely crowded together and resembling bunches of grapes.

[4] In Fordyce's case (*Jour. Cutan. Dis.*, 1892, pp. 367 and 372) the lesions were on inner aspects of both thighs, just above the knees; Pringle's (*Brit. Jour. Derm.*, 1898, p. 198), on the scrotum, perineum, and contiguous parts, and in another (*ibid.*, p. 418) on the scalp; Abraham's (*ibid.*, 1899, p. 474), in addition to a large number of wide distribution on the cutaneous surface, the mouth was also the seat of lesions, closely crowded together, resembling plaques of leukoplakia, and there were also massed lesions on the penis; Allen's (*Jour. Cutan. Dis.*, 1886, p. 238), some lesions on the vermilion border of the lips; Sprecher (*Dermatol. Centralbl.*, Sept., 1899, p. 354), on the dorsum of one foot.

[5] Steffen, *Klin. Monatsblätter f. Augenheilkunde*, 1895, p. 457, and 1896, p. 66; Muetze, "Ueber Molluscum Contagiosum der Lider," *Archiv f. Augenheilkunde*, vol. xxxiii., 1896, p. 302 (with review of the subject, histology, with 2 cuts and literature references).

[6] Walter Smith, *Dublin Jour. Med. Sci.*, Nov., 1878 (numerous and general, reaching the extreme of three inches in diameter).

[7] Laache (Nicolaysen's case), *Nordiskt Medicinskt Arkiv*, 1882, vol. xiv., p. 21—abs. in *Jour. Cutan. Dis.*, 1885, p. 64 (tumor the size of two fists).

[8] Kaposi, *Wien. klin. Wochenschr.*, 1896, No. 26, and *Archiv*, 1897, vol. xxxviii., p. 144.

There are no subjective symptoms, the lesions appearing and continuing throughout their course, with apparently no pain, itching, or burning. Those which become inflammatory accidentally or spontaneously by tendency to break down may be slightly sore and painful. There are no constitutional symptoms.

Etiology.—The disease is contagious. Since the time of Bateman, who first clearly described the malady, there has been much dispute on this point, but in England,[1] where it is apparently more common than elsewhere, its contagiousness has been generally recognized; and this is supported in this country by the overwhelming evidence presented by Fox, Allen, Mittendorf, Jackson, Graham, and myself.[2]

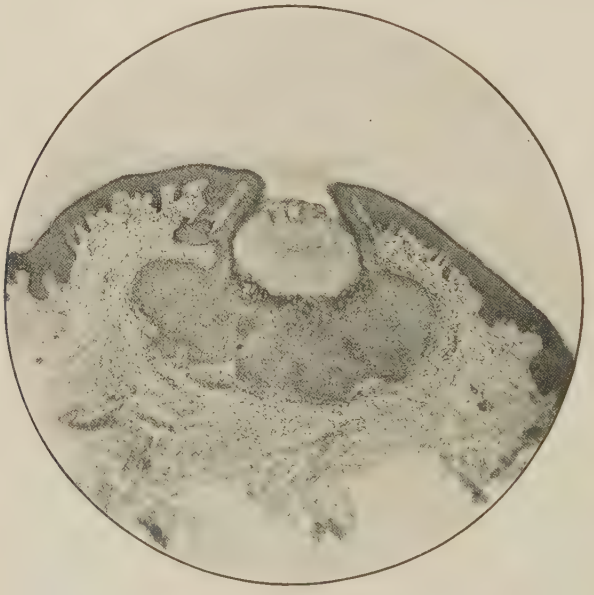

FIG. 133.—Molluscum contagiosum; section through a small lesion, showing its epithelial lobular formation, with the connective-tissue septa separating the lower part of the lobules; the plug in the central upper part consists of a crowded accumulation of the so-called "molluscum bodies" (courtesy of Dr. H. G. Piffard).

Wigglesworth, Allen, and Brocq were subjects of accidental inoculation. Retzius, Peterson, Vidal, Stanziale, Pick, Haab, and Nobel succeeded in experimentally producing the disease; there are, it is true, many recorded failures at experimental inoculation, including my own, but these have no weight in the face of successful attempts, even though scanty in number. The incubation period, as proved in the above cases, and also by clinical observation, is long—from

[1] Duckworth, *St. Bartholomew's Hosp. Reports*, vols. iv. and vii., reviews literature to 1872.

[2] Stelwagon, "The Question of Contagiousness of Molluscum Contagiosum," *Jour. Cutan. Dis.*, 1895, p. 50. This paper reviews the literature, with references, bearing upon this point (numerous examples of contagion in families, schools, asylums, of accidental inoculation and successful experimental inoculation) upon this point, citing among other English observers, cases observed by Liveing, Morrant Baker, W. Smith, and Mackenzie; and among other foreign observers, Caillaut, Havenith, Ebert, Tommasoli.

several weeks to a few months. Hutchinson, Crocker, and Malcolm Morris have noted that Turkish baths are a source of contagion—the first stating that most of his male patients were frequenters of these baths. Malcolm Morris[1] observed, in a series of at least a half dozen cases that came under his notice within a short period, that the disease seemed to follow a visit to the same Turkish bath establishment. In such instances, doubtless, the media of contagion are the towels and gloves, the bath, as Crocker believes, bringing the skin into favorable condition for successful inoculation.

The disease is seen in both sexes and at all ages, but it is by far most common in children and among the poor, especially, as in most of my own cases, in asylums and institutions. Several observers have noted the occasional coexistence of warts and molluscum contagiosum, but this does not seem to me unusual, inasmuch as warts are quite common among the poorer children.

Pathology.—The growth was originally considered, and is still

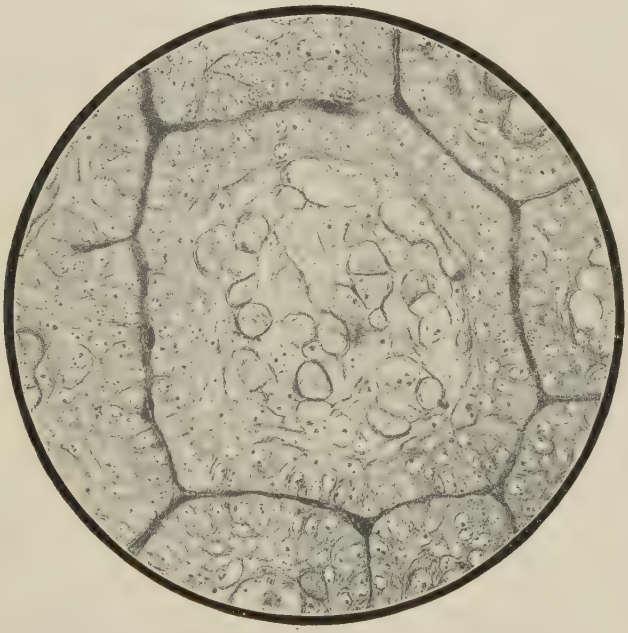

FIG. 134.—Molluscum contagiosum; transverse section, showing the lobules, the septa, and the various stages of the cell changes; in the central part the so-called "molluscum bodies" or "molluscum corpuscles" (courtesy of Dr. J. A. Fordyce).

so held by several prominent observers, to have its seat in the sebaceous gland (Tilbury Fox, Kaposi, Leloir, Vidal, and a few others), and the hasty examination of a tumor is very suggestive of a pathologically changed, lobulated glandular structure; but later and repeated studies, led by Virchow and confirmed by others (among whom Boeck, Simon, Robinson, Crocker, Sangster, Thin, Neisser, Piffard, Fordyce, Gilchrist, Kuznitzky), have demonstrated that it

[1] Malcolm Morris, *Diseases of the Skin*, 1894, p. 506.

takes its origin from the epithelium,—in fact, that it is in reality a hyperplasia of the rete or a benign epithelioma,—and with no connection with the sebaceous gland. Opinions differ somewhat as to whether it takes its start from the epithelial lining of the hair-follicle or in the rete layer proper.

A vertical section through a molluscum growth shows it to be made up of several lobules, due to the downgrowth of the rete, which converge toward the apex and broaden toward the base, the fine connective-tissue septa, formed by the compressed papillæ, which divide them, appearing continuous, and extending about half-way up, as is clearly shown in the cut. The upper central part, approaching the outlet, where they have fused or converged together, is composed of a mass of changed epithelial cells, opaque and whitish in color, rounded or ovoid, somewhat sharply defined, fatty-looking bodies, constituting the so-called molluscum bodies first described by Patterson. The epithelial cells in the lower part of the lobules are at first practically unaltered, but which, as they are crowded up by the underlying proliferation, undergo degeneration or some peculiar change, become enlarged, and result in the peculiar formation referred to; others again, instead of the changes briefly referred to, harden and are more or less cornified. The whole molluscum lesion is inclosed in a fibrous capsule, the base resting on the corium. The first change noted in the transformation of the epithelial cell is the appearance within of small, clear, or hyaline bodies, as a rule close to the nucleus of the cells, usually oval in shape, with tapering or pointed ends, and containing a nucleus—molluscum bodies; further growth ensues, and finally, in some, a granular-looking mass results, with a waxy-looking translucent peripheral zone; or, in consequence probably of further growth, degeneration ensues and the cell-wall and the remaining protoplasm cornify and grow opaque, and the contents are rendered less recognizable. The term "molluscum body" or "molluscum corpuscle" has been applied both to the bodies forming within the cell and to the completely crowded cell, although its proper or more exact application should be, as Macallum suggests, only to the former, the cell containing them to be more accurately named the "molluscum cell."

Although admittedly contagious, what starts the pathologic process remains yet a mystery. The readiest and most natural explanation, in the light of other bacteriologic studies, is to be found in the assumption of a parasitic element, which, I believe, persistent search will yet find. While it can probably be said that the psorosperm theory, so promisingly lighted by the writings of Darier, Wickham, and others, has been almost wholly abandoned, still Neisser,[1] who

[1] Neisser (Ueber das Epithelioma (sive Molluscum) Contagiosum), *Archiv*, 1888, p. 553 (with 11 cuts); an elaborate and exhaustive paper; the writer deals with the disease in all its aspects, and gives a complete bibliography; also (Ueber Molluscum Contagiosum), *Verhandl. der IV. Deutsch. dermatolog. Cong.* (with a number of excellent cuts). These two papers give a review of the contributions and work of others to date. Other important literature of recent date bearing upon pathology and histology: Török, *Monatshefte*, 1892, vol. xv., p. 109 (with references); Lubarsch, Lubarsch-Ostertag's *Ergebnisse der allgemeinen Pathologie*, 1895, abt. ii., p. 398 (with references); Macallum, *Jour. Cutan. Dis.*, 1892, p. 93 (with good cuts); Beck (Ehrmann's laboratory), *Archiv*, 1896, Bd. xxxvii., p. 167.

has contributed much time to the investigation of this malady, together with a few others (more especially Bollinger, Mansüroff, Touton, Winogradow, Lindström), maintains, with considerable show of reason, that the molluscum corpuscles or bodies are parasites (coccidia) to which the disease is due. In this connection it is interesting to recall that Virchow directed attention to their resemblance to the gregarinæ of rabbits some years ago. The parasitic character of the molluscum bodies can scarcely be accepted, however, in view of the investigations and observations of Boeck, Caspary, Piffard, Crocker, Török and Tommasoli, Kromayer, Unna, Audry, Macallum, Fordyce, Lubarsch and others, which, for the most part, indicate that these intracellular masses are a peculiar form of cell degeneration, of a colloid, hyaline, or protoplasmic character. C. J. White,[1] in a recent valuable study, concluded that nobody has demonstrated, up to this time, any parasitic body in the growth, and that the change is not a colloid or hyaline degeneration, but rather an extraordinary metamorphosis of rete cells into keratin.

As bearing upon the pathogenic factor is the observation by Bollinger[2] and others, who have remarked upon the resemblance of molluscum tumors to the growths found on the beaks and eyelids of fowls, especially chickens and pigeons, and with which the observations of Salzer,[3] Colcott Fox,[4] and Shattock[5] appear to prove their identity. Recently Salzer reported a suggestive, but not unquestionable, case in which the patient had shown the disease about the time some pet pigeons, which she was in the habit of feeding out of her hand, had developed growths on the beak. Colcott Fox met with the growths on the legs, feet, and head of a white Wyandotte chicken, and microscopic examination proved them typical of molluscum contagiosum. Shattock observed similar growths in two mated sparrows.

Diagnosis.—There should be no difficulty, as a rule, in the diagnosis, as the size of the lesions, their waxy or glistening appearance, and the presence of the central depression and orifice are sufficiently characteristic. The disease is to be differentiated from fibroma, milium, warts, and acne.

Fibromata are rounded growths of small or large size, always exceeding, when at all developed, that of the tumors of molluscum contagiosum, and are situated deeply in the skin, or even in the subcutaneous tissue; the lesions of molluscum contagiosum are superficial, seated in the upper skin and epidermal tissues, and are, comparatively speaking, small in size; the tumors of the former have no central orifice, depression, or opening, while these are usually quite distinct in the latter disease.

Milia resemble the small molluscum growths to some extent, but are usually whitish, and lack the pearly or waxy appearance and the central orifice of the latter. These latter characters will

[1] Chas. J. White and W. H. Robey, Jr., "Molluscum Contagiosum," *Jour. Med. Research*, April, 1902, p. 255 (a personal study, general review, and résumé, with histologic cuts, and full bibliography).

[2] Bollinger, *Virchow's Archiv*, vol. lviii., 1873, p. 349 (with colored plate).

[3] Salzer, *Münch. med. Wochenschr.*, 1896, No. 36, p. 841.

[4] Colcott Fox, *Trans. London Patholog. Soc'y*, vol. xlix., 1898, p. 393 (with illustrations).

[5] Shattock, *ibid.*, p. 394 (with illustrations).

also serve to differentiate it from small warts, to which it bears a rough resemblance; moreover, warts are harder and more solid. It is scarcely possible to mistake the disease for acne—small papular acne—as the lesions in this latter disease are usually seen in all stages of papulation and pustulation.

Prognosis and Treatment.—The prognosis of molluscum contagiosum is favorable, and it is only exceptionally that any permanent trace of the disease is left. In many instances the tumors will disappear spontaneously in the course of several weeks or a few months. In others, active measures are necessary to bring about their removal. All cases should, however, receive prompt treatment, in order that a possible source of contagion may be removed.

If there are but a few lesions, their contents may be immediately pressed out, and a deep application, through the central orifice, be made with a strong solution of silver nitrate or carbolic acid by means of a sharply pointed stick; or the lesions may first be incised, and then the cauterization made. If the formations are numerous, and especially when seated on a limited region, a mild stimulating or parasiticide ointment should be tried before operating upon individual growths; for this purpose one containing 20 to 40 grains (1.35–2.65) of white precipitate or sulphur to the ounce (32.) should be rather vigorously rubbed into the affected parts once or twice daily; or a drying lotion, such as the calamin-zinc-oxid lotion, with boric acid solution as the basis, can be applied freely once or twice daily. A number of my cases have gone on to recovery under such measures. If this method should, after trial, prove without effect, the mild operative and cauterizing applications mentioned are to be resorted to. Lesions which have become pedunculated may be snipped off with scissors and the base touched with silver nitrate.

MULTIPLE BENIGN CYSTIC EPITHELIOMA.[1]

Synonyms.—Epithelioma adenoides cysticum (Brooke); Adenoma of the sweat-glands (Perry); Acanthoma adenoides cysticum (Unna); Trichoepithelioma papillosum multiplex (Jarisch); *Fr.*, Hydradénomes éruptifs (Jacquet and Darier); Syringo-cystadénome (Török); Cellulome épithélial éruptif kystique (Quinquaud); Cystadénomes épithélieux bénins (Besnier); Nævi epitheliaux kystiques (Besnier); *Ger.*, Gutartiges Epithelioma, mit kolloider Degeneration (Philippson). Syringocystoma.

[1] Literature: Jacquet and Darier, "Hydradénomes eruptifs," *Annales*, 1887, p. 317 (2 colored case illustrations and 2 colored histologic cuts); Török, "Das Syringo-cystadenom," *Monatshefte*, vol. viii., 1889, p. 116; Quinquaud, "Le Cellulome epithélial éruptif," *Trans. Internat. Cong. Dermatolog.*, Paris, 1889, p. 412 (case demonstration); Jacquet, "Épithéliome kystique bénin de la peau," *ibid.*, p. 416 (case demonstration); Perry, "Adenomata of the Sweat-glands," *Internat. Atlas Rare Skin Diseases*, iii., 1890, plate ix.; Brooke, "Epithelioma Adenoides Cysticum," *Brit. Jour. Derm.*, 1892, p. 269 (with 3 case illustrations and 7 histologic cuts and references); Fordyce, "Multiple Benign Cystic Epithelioma," *Jour. Cutan. Dis.*, 1892, p. 459 (with colored plate case illustration and 7 photomicrographs); J. C. White, "Multiple Benign Cystic Epithelioma," *ibid.*, 1894, p. 477 (with case illustration, histologic examination and cut by Bowen); Dyer, *New Orleans Med. and Surg. Jour.*, vol. l., 1897–98, p. 530 (with case illustration); see also Besnier's article in Besnier-Doyon's French translation of Kaposi, vol. ii., p. 367; W. Fick (its relation to adenoma of the sebaceous glands), *Archiv*, 1901, vol. lviii., p. 201; Hartzell (2 cases with unusual features, with review and references) *Amer. Jour. Med. Sci.*, Sept., 1902, and (its relationship to so-called syringocystadenoma, syringocystoma, and hæmangio-endothelioma), *Brit. Jour. Derm.*, 1904, p. 361 (with histologic cuts); C. J. White, *Jour. Cutan. Dis.*, Feb., 1907, p. 50 (case report with illustrations and histologic cuts; analytical review and bibliography).

Symptoms.—In recent years a malady has been described characterized by small, tubercular or nodular lesions, of a pinkish, pearly, or pale-yellowish color, and usually seated about the face, upper part of the trunk, anteriorly or posteriorly, and less frequently on the arms. In size they vary from a pin-head to a pea, rarely exceeding the latter, projecting above the surface, and have a shining, semitranslucent appearance. They are usually rounded or conic, smooth, with sometimes, in the largest growths, a slight central depression. Occasionally they are somewhat flattened. Some of the lesions may have a distinctly translucent aspect and look like vesicles; others have a milium-like appearance, or the surface of the large one may show several milium-like bodies. In some the surface, and occasionally the immediately adjacent surrounding skin, shows minute capillaries.

FIG. 135.—Multiple benign cystic epithelioma; the coalescent group showing degenerative changes.

They are painless, not sensitive to the touch, nor tender upon pressure. Usually the lesions are somewhat numerous, discrete, or somewhat crowded together, and sometimes coalescent or bunched.

They appear first as pin-point- to pin-head-sized lesions, similar in their features to the more advanced lesions; in others the earliest formations resemble small papules or black dots (Brooke), sometimes small scaling papules. While ordinarily in color they are, as already stated, pinkish, pearly, or pale yellowish, occasionally it is that of the normal skin, and in some instances there is a bluish tinge. They are firmly imbedded. Their growth is slow, and, after reaching the size of a small or large pea, remain stationary. It has been commonly thought that no degenerative or ulcerative changes ever take place, and this absence of malignancy is the rule, but in White's case, in one observed by Jarisch,[1] and also in mine, the large or bunched

[1] Jarisch, *Hautkrankheiten*, 1900, p. 788.

lesions exhibited surface degeneration with ulceration, and approached closely to the rolled, pearly-bordered, superficial epitheliomata. The growths show no tendency to involution. While sometimes presenting a pseudo-vesicular appearance, they are usually firm and apparently solid in character, and if pricked, show no liquid contents, but simply bleed slightly. Dyer states that in some lesions in his case, if punctured, clear fluid exuded, in others blood, and in others again a distinctly gelatinous substance; and that the lesions always began with a scaling spot. This case, therefore, apparently differs in some respects from most of those reported, as, in addition to the peculiarities just mentioned, some of the lesions were somewhat soft—"gelatinous to the touch," and there was also a tendency to "self-destruction and self-elimination." Perry, who thought his case an adenoma of the sweat-glands, says that if punctured, "nothing but clear fluid could be expressed."

The face is the most common site, and here there usually is a predilection shown for the region of the eyelids, forehead, cheeks, root of the nose, chin, ears, and interpalpebral space. The interscapular region, breast, and arms are also not uncommon sites, and the lesions have, moreover, been found on other regions. There are no subjective symptoms, nor is there any disturbance of the general health, the cases coming chiefly under observation owing to the disfigurement produced.

Etiology and Pathology.—The cause of the disease is unknown. Both sexes are liable, and almost any age, although it usually has its beginning during adolescence, most commonly about puberty. Brooke's 3 cases consisted of mother and two daughters, and Fordyce's, of a mother and daughter, with the history in the latter instance of a similar condition in a preceding generation. Colcott Fox[1] also noted probable examples, clinically viewed, of the malady in mother and daughter. Quinquaud's patient stated that a sister presented similar growths.

Crocker,[2] in a recent valuable contribution, expresses the opinion that the cases reported really constitute two distinct types or affections, for which he suggests, for the sake of convenience, of holding to the names given to the representative of the one class by Kaposi —lymphangioma tuberosum multiplex—and, to the other class, that by Brooke, acanthoma adenoides cysticum; including, in the former, without necessarily implying that the condition is lymphangiomatous, the cases of Kaposi, Jacquet and Darier, Török, Quinquaud, Lesser and Beneke, and others,[3] and, in the latter, those of Perry, Brooke, Fordyce, White, and some others. It is true that a study of these various cases suggests some clinical, although probably unimportant, differences. Crocker gives the chief of these: in lymphangioma tuberosum—mainly on the trunk, discrete and not grouped, bilateral and not symmetric, distinctly colored, in males and females alike, and

[1] Colcott Fox, *Brit. Jour. Derm.*, 1897, p. 230 (case demonstration).

[2] Crocker, "A Case of Lymphangioma Tuberosum Multiplex," *London Clin. Soc'y Trans.*, vol. xxxii., 1899, p. 151 (with colored plate and bibliography).

[3] Literature references to the cases of Kaposi, Lesser and Beneke, and also to Hoggan's and Jarisch's papers, which concern cases of benign cystic epithelioma, etc., are given under lymphangioma.

not hereditary; and for acanthoma adenoides cysticum—mainly on face, discrete, but very closely grouped, closely symmetric, almost or quite pearly white, or a faint bluish or yellowish tinge, most of them hereditary and all females. Jarisch's case and my case, however, which come in this latter group, were males. To these Crocker would add anatomic dissimilarity—the former consisting of "cysts in the derma, with straight processes of non-epidermic origin," and the latter, "solid, coil-like masses with small cysts scattered through them and of epidermic origin." Hartzell believes that these (or most of these) variously named cases are simply varieties of the one and same affection, while C. J. White contends that there are several distinct clinical and pathologic groups.

Histologically (Darier, Brooke, Fordyce, Bowen, and others) the lesion is shown to be an epithelial growth, the epithelial cells being found in irregularly rounded, oval, and elongated masses and tracts of epithelial cells corresponding to those in the lowermost layer of the epidermis and external root-sheath of the hair-follicle, these masses being distinct or composed of intercommunicating bands and tracts, in some places resembling coil-ducts; cell-nests are to be seen, as in malignant epithelioma (Fordyce). Colloid degeneration is also noted. Lying in the tracts, or more generally in the masses, were cysts of circular or oval shape, sometimes elementary, others well formed, filled with either purely colloid matter or partly with colloid and partly with concentric layers of apparently horned epithelium (Brooke). It is generally believed (Quinquaud, Jacquet, Darier, Philippson, Fordyce) that the growths take their start from embryonic epithelial germs misplaced during fetal life, and remaining in a latent condition until excited by some influence into active proliferation (Fordyce), and this excitation is apparently furnished most frequently at the period of puberty, doubtless by the tissue changes and glandular activity at this time of life. In Hartzell's cases the growth had its origin in the epithelium of the hair-follicle, and C. J. White's investigation showed his to be a new growth and cystic dilation of sweat ducts. Its relation to superficial epithelioma or rodent ulcer is probably a close one, and although the lesions are thought benign and to show no destructive changes, the exceptional cases of White, Jarisch, and my own furnish, in my judgment, connecting examples. Philippson,[1] in his report of a case, has endeavored to show that colloid degeneration of the skin and benign cystic epithelioma are essentially pathologically identical, a view, however, that has received no support.

Diagnosis.—The lesions bear some resemblance to molluscum contagiosum, but are distinguished from the latter by the fact that they are persistent, showing no tendency to disappear, and have, as a rule, no central depression, and have no central aperture. Molluscum contagiosum is, moreover, more commonly a malady of childhood: benign cystic epithelioma rarely presents before puberty. There is also a resemblance to hydrocystoma, but in the latter the growths have fluid contents and are usually fluctuating as to their

[1] Philippson, "Die Beziehungen des Kolloid-milium (Wagner) der kolloiden Degeneration der Cutis (Besnier) und des Hydradenom (Darier-Jacquet) zu Einander," *Monatshefte*, vol. xi., 1890, p. 1; and also in *Brit. Jour. Derm.*, 1891, p. 35.

existence, disappearing and reappearing. Between colloid degeneration of the skin and this disease there is also some clinical similarity. The colloid lesion begins as yellow, translucent, gelatinous-looking nodule: cystic epithelioma as a small, skin-colored papule or black dot, and gradually progresses; the former may undergo involution and disappear without trace; the latter is persistent. Histologically in the former the colloid material is infiltrated in the fibrillæ of the connective tissue, enveloping the connective-tissue bundles and following their directions, and there are no epithelial tracts or cords, and no cysts—findings different from those of cystic epithelioma (Brooke).

Prognosis and Treatment.—There is no tendency to spontaneous disappearance, and though the malady is usually to be considered benign, development of a more active epithelial proliferation and ulcerative degeneration is a possibility. In view of the epitheliomatous development in his case White justly says, I believe, that the correctness of the appellation benign must be regarded as problematic. Treatment is surgical. Fordyce has found that simple incision in the smaller lesions and squeezing out the growth will sometimes be successful, although stating that curetting constitutes the best plan. In a case under the care of Dr. C. N. Davis, of Philadelphia, that I had an opportunity of seeing, in spite of several thorough curettings there was persistent recurring tendency. Electrolysis and cauterization can also be resorted to.

ADENOMA SEBACEUM.[1]

Synonyms.—Adenoma of the sebaceous glands; Vegetations vasculaires (Rayer); Nævi vasculaires et papillaires (Vidal); Adenoma sébacés (Balzer and Ménétrier).

Definition.—A rare affection, originally described by Rayer, Addison, and Gull, and since by others, consisting of small tumors

[1] Recent literature: Balzer and Ménétrier, *Arch. de physiolog.*, 1885, vol. vi., p. 564 (1 case with histologic cuts); Balzer and Grandhomme (1 case), *ibid.*, vol. viii., 1886, p. 93; Pringle, *Brit. Jour. Derm.*, 1890, p. 1 (with case illustration and photomicrographs, and a résumé of the above 2 cases and 2 by Vidal and 1 by Hallopeau); Caspary, *Archiv*, 1891, vol. xxiii., p. 371 (with literature, references, colored plate, and histologic cuts); Crocker, *Trans. Internat. Derm. Cong.*, Vienna, 1892, p. 505, and *Diseases of Skin*, second edit., p. 769; Jamieson, *Brit. Jour. Derm.*, 1893, p. 138 (girl, aged fifteen—most lesions on right side of forehead close to hair margin); Stopford Taylor and Barendt, *ibid.*, p. 360 (3 cases in one family—father, son, and daughter, began in all about the age of five—of defective mental development); Pollitzer, *Jour. Cutan. Dis.*, 1893, p. 475 (male subject—with case illustration and 2 histologic cuts); Rosenthal (case demonstration), *Monatshefte*, 1894, vol. xix., p. 374; Dockrell (case demonstration), *Brit. Jour. Derm.*, 1895, p. 340 (epileptic boy—some cicatrices present); W. Anderson, *ibid.*, p. 316 (male subject, aged twenty-seven, began at seven—associated with fibromata); Brooke, *ibid.*, p. 332 (discussion; 2 cases—1 in idiot girl, the other in epileptic young woman); Perry (case demonstration), *ibid.*, 1896, p. 99 (girl, aged eleven, with some fibromata); G. H. Fox (case demonstration) (1 case—young girl), *Jour. Cutan. Dis.*, 1897, p. 88; and (2 cases—girls), *Trans. Amer. Derm. Assoc. for 1898*; Gottheil, *Jour. Amer. Med. Assoc.*, July 20, 1901, p. 176 (girl, aged nineteen, on one side of scalp, an area of $2\frac{1}{2}$ by $\frac{3}{4}$ inches); Poor, *Monatshefte*, April 1, 1905, p. 379 (1 case, with review and literature references), from his study concludes that the cases can be divided into two classes, called by him: Nævus sebaceus symmetricus and nævus sebaceus circumscriptus asymmetricus; the former usually on the face, especially the nose, and its congenital origin is not yet definitely settled; and the latter, on any part of the body, usually linearly arranged, never symmetrical and always congenital.

of sebaceous gland origin, seated usually on the face, more especially at the sides of the nose.

Symptoms.—The disease has been more recently described in France by Balzer, in association with Ménétrier and Grandhomme; in England, by Pringle, Crocker, and others; in Germany, by Caspary, Rosenthal, and a few others; and in this country, by Pollitzer. It is characterized by small tumors, which are, as a rule, congenital or appear after birth. In size they vary from a pin-head to a split pea, are rounded or convex, and may be either normal skin color, waxy, brownish or reddish—the latter most usually. The epidermal covering may be smooth, rough, or warty, with, in many cases, the surface irregularly streaked with ramifying dilated capillaries. This latter character may be, as in Vidal's case, a conspicuous feature. In fact, their color is measurably influenced by the degree of this associated telangiectasis, although not wholly, as pressure causes but little, if any, change. They are more or less grouped or bunched at either side of the nose, with outlying scat-

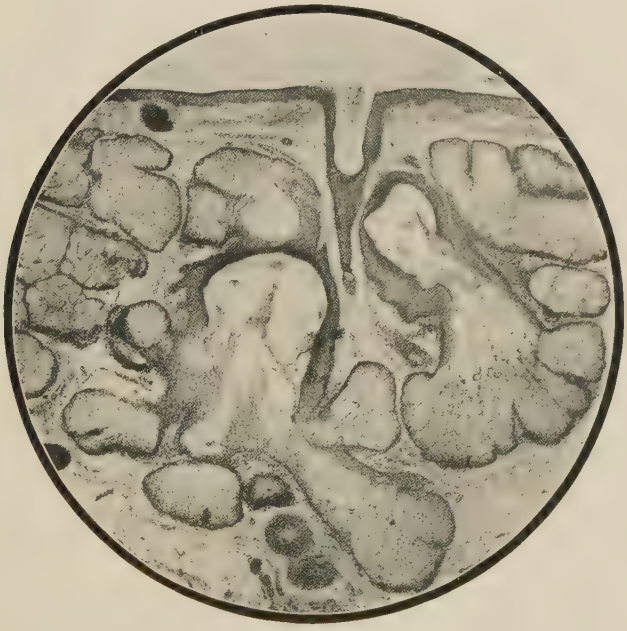

FIG. 136.—Adenoma sebaceum; moderate magnification; showing the striking hypertrophy and development of the sebaceous glands (courtesy of Dr. J. A. Fordyce).

tered ones, or they may be somewhat disseminated over the whole facial region, and exceptionally in the scalp. The acne rosacea regions are, however, its common sites. They are usually symmetrically distributed. The forehead is rarely the seat of many lesions, although in some instances those on this region are quite large. Pollitzer's case was exceptional in that the tumors were arranged in a linear manner, and, as practically likewise in Jamieson's case, confined to one side of the forehead. Their appearance and growth are

gradual, the latter usually noted to be more active at about puberty, at which time especially there may be also a decided increase in numbers. Involution may occasionally be noted in some of the growths, and such may completely disappear, their site being marked by insignificant atrophic spots or scars. Other cutaneous lesions, such as comedones, pigment spots, nævi, warts, and fibromata, have been variously noted, especially the first named, and commonly associated with a coarse, pasty-looking, large-pored skin. There are no subjective symptoms.

Etiology and Pathology.—The affection is believed to be of congenital origin, although this does not seem true in all instances; in Pollitzer's case the lesions first presented when aged nineteen. Its subjects, for the most part, although by no means exclusively, have been noted to be of defective mental development. It is observed more frequently, too, among the poorer classes, and Crocker is inclined to think that more cases could probably be found in asylums. In fact, according to Colcott Fox,[1] the malady seems to be quite common in England, and chiefly met with among children in imbecile asylums.

The pathologic anatomy has been studied by Balzer, Pringle, Crocker, Barendt, Pollitzer, and others, and although there are some minor divergences, all agree that the process is one of hyperplasia of the sebaceous glands, and probably, too (Balzer, Crocker), of the sweat-glands. In fact, Crocker's examination disclosed increased development of all the appendages,—sebaceous glands, sweat-glands, and hair-follicles,—and he would prefer to classify it as a pilosebaceous hydradenoma. In addition to the hyperplasia of the glandular structures, Crocker found in one lesion hyperplasia of the fibrous tissue also; Pringle, the upper papillary layer enormously hypertrophied, but without evidence of inflammation or cellular infiltration; and Balzer, in 1 of his cases, cysts in both sweat- and sebaceous glands.

Diagnosis.—The diagnostic features are the early appearance, the region involved, and the associated telangiectasis and persistent course. The malady can scarcely be confounded with acne rosacea, although usually occupying the region of the latter disease, but its early beginning, lack of pustular tendency, and course are wholly different. And only careless examination could lead to a confusion with lupus vulgaris, as the behavior and atrophic or ulcerative tendency of the latter would be sufficiently differential. There is more resemblance to multiple benign cystic epithelioma and colloid milium, but the former develops later in life, is more frequently seated upon the upper part of the face or upon other regions, especially the upper part of the trunk, and occasionally tends to superficial ulceration. Colloid milium rarely involves the lower part of the face, being most commonly on the upper portion, and the lesions are free from the surface dilated capillaries, and are, moreover, more distinctly yellow in color. Molluscum contagiosum could be readily differentiated by the central depression and opening.

Prognosis and Treatment.—In rare instances spontaneous

[1] Colcott Fox (discussion), *Jour. Cutan. Dis.*, 1897, p. 88.

involution has been observed, but this is scarcely to be expected, as the disease is almost always persistent, the growths usually increasing in number for a time, and then the malady remaining stationary. Treatment is essentially and solely surgical, as no result has yet been achieved by local applications or general treatment. If their removal is called for, it can be accomplished by means of the knife or curet or electrolysis. This last has been employed successfully by Crocker, using a current of 3 or 4 milliampères, the procedure being the same as in hypertrichosis or telangiectasis—the needle attached to the negative pole. Jamieson effected a removal of the lesions and what seemed to be an apparent cure by producing exfoliation by rubbing in a paste composed of: ℞. Resorcin, gr. xx (1.35); zinci oxidi, gr. xl (2.65); kaolin, gr. ij (0.135); adipis benzoat., gr. xxviij (1.9).

ADENOMA OF THE SWEAT-GLAND.[1]

Synonyms.—Spiradenoma ; Spiroma ; Adenoma sudoriparum.

Most of the cases which have been described under this or an equivalent title are now known to have had no connection with the sweat-glands, but represented what is at present recognized as multiple benign cystic epithelioma (*q. v.*). It is not improbable, however, that the conclusions on this point have been entirely too sweeping, and that in a few of the examples these structures may have played an important pathologic part. It is in some instances, doubtless, however, a secondary development, as in the cases of linear nævus recorded by Peterson[2] and Elliot,[3] although the former was of the opinion that his cases represented a primary adenoma of the sweat-gland. According to Buxton, who has carefully gone over the subject, the true adenoma must be distinguished from mere hypertrophy ; as an example of this latter he considers Elliot's case just referred to. Gland hypertrophy is not infrequent in tuberculosis cutis and in the neighborhood of malignant tumors ; and he himself gives a histologic example of its occurrence near the site of a carcinoma of the breast. Unna asserts, however, that these cases, which may be considered as secondary adenoma, and which are relatively numerous, may also, in addition to the actual hypertrophy, show adenomatous development. Genuine cases, excluding the secondary cases and those which are rather to be looked upon as examples of hypertrophy, are rare ; and, according to Unna, are represented by those reported by Thierfelder,[4] Lotzbeck,[5] Hoggan,[6]

[1] In the herewith brief presentation I am indebted to the papers of Unna, *Histopathology*, p. 803 (with bibliography) ; Buxton (Benign Tumors of the Skin), *Jour. Cutan. Dis.*, 1901, p. 161 (with admirable cuts and bibliography) ; Fordyce, Morrow's *System*, vol. iii. (Dermatology), p. 618.

[2] Peterson, *Archiv*, 1892, vol. xxiv., p. 919, and "Beiträge zur Kenntniss der Schweissdrüsen-Erkrankungen," *ibid.*, 1893, vol. xxv., p. 441 (review of subject and references).

[3] Elliot, *Jour. Cutan. Dis.*, 1893, p. 168. These two cases are also referred to under linear nævus.

[4] Thierfelder, *Archiv f. Heilkunde*, 1870, p. 401 (with 3 histologic cuts and some references).

[5] Lotzbeck, *Virchow's Archiv*, vol. xvi., 1859, p. 160.

[6] Hoggan (G. and F. E.), *ibid.*, vol. lxxxiii., 1881, p. 233.

Chandeleux,[1] and Audry.[2] Unna also quotes one by Krauss, and gives brief notes of one under his own observation.

The clinical appearances are simply those of a subcutaneous tumor, varying in size from a pea to an egg or larger, usually slow in development. In Lotzbeck's case it had a pseudo-angiomatous aspect. In the cases of Chandeleux and Hoggan the nodules were tender and liable to spontaneous attacks of pain. In both instances the nodule was encapsulated by firm connective tissue and the nerves distributed outside. The overlying skin shows but little departure from the normal. The growth is usually single, and may occur on any region—by Lotzbeck, on the cheek; by Thierfelder, at the hairy margin of the forehead; by Krauss, at the outer border of the foot; by Chandeleux, near the elbow; by the Hoggans, on arm; in Unna's case the position is not stated. It may appear at any age and in either sex.

Unna would distinguish the growth arising from the coil-duct, to which he gives the name of *syringadenoma*, from that arising from and involving the glandular structure proper, as an example of the former citing Peterson's case, already referred to. The origin and, in fact, the diagnosis from other clinically similar tumors in these various cases and histologic varieties are possible only through careful microscopic examination. In fact, their individuality, true position, and relationship to other growths are still undetermined. There is scarcely a doubt that occasionally such a formation constitutes the starting-point of carcinomatous or other malignant change,[3] and it is fairly questionable also whether, in some of the instances in which the adenomatous development of the coil-glands was thought to be secondary to malignant growths, it may not have been the primary affection and the starting-point of the malignancy.

The **treatment** of sweat-gland adenomata is that of other tumor formation—complete excision.

LYMPHANGIOMA.

The subject of lymphangioma remains still an obscure one, to which the many conflicting case reports have as yet contributed but comparatively little definite knowledge. While, strictly speaking, this term carries with it the implication of new growth of the lymphatics, yet in some recorded instances there is more reason to believe that the condition was one of lymphangiectasis. It is highly probable, however, that the former does not exist without the latter, and that, therefore, in most cases, there is an association of the two processes. A reading of the literature shows that there are several varieties, some of which may be classed as deep-seated cystic growths, others as more superficial lymphatic varicosities, consisting of more or less tortuous and crowded or closely adjacent dilated, and pos-

[1] Chandeleux, *Arch. de physiolog.*, 1882, vol. ix., p. 639.

[2] Audry and Nové-Josserand, *Lyon Médicale*, 1892, vol. lxix., p. 315.

[3] See papers by Darier, "Contribution a l'étude de l'epithéliome des glands sudoripares," *Arch. de méd. exper.*, 1889, p. 115 (with 10 histologic cuts); Fordyce, "Adenocarcinomata of the Skin Originating in the Coil-glands," *Jour. Cutan. Dis.*, 1895, p. 41 (with 7 excellent photomicrographs).

sibly new, lymphatic channels, or discrete, irregularly grouped or scattered, pea- to cherry-sized, tumor-like dilatations; and still another in which the lesions are within the middle and upper part of the corium, close to the surface, and crowded or bunched together, forming plaques of pearly or pinkish-red, thick-walled vesicles, often dotted with minute telangiectases or vascular tufts. These several classes correspond to the divisions made by Wegner,[1] who placed the cases in three groups—simple lymphangioma, cystic lymphangioma, and cavernous lymphangioma. Chipault's[2] classification is based chiefly upon the part especially involved—whether affecting the lymph-glands, the main lymphatic channels, or the plexuses, and with further subdivisions, based upon the superficial or deep situation of the process. It possibly is more in accord with histopathologic findings, but is much more elaborate, and, considering our present knowledge, probably unnecessarily so, and is certainly not so feasible or convenient as that of Wegner. Most of the contributions are based upon the latter, although the relationship of one form to another is not infrequently observed, as shown in the contributions on the subject by Hoggan,[3] Jarisch,[4] Nasse,[5] Leslie Roberts,[6] and others.[7]

In some cases the lymphatic vesicular dilatation and dilated channels, or *lymphangiectasis*, are not the consequence of a primary pathologic process of these structures, but the result of mechanical injury and obstruction, as in the instances of Elliot,[8] Besnier,[9] and others. Lymphangiectasis is not only sometimes a result of demonstrable or probably mechanical obstruction following injuries, but it is likewise a part of certain maladies in which the same factor, while doubtless causative, is not always so evident, as in elephantiasis. Some instances are also observed in which, in a more or less limited region, there is distinct and pronounced dilatation of the lymphatic vessels, forming elevated, doughy-feeling, compressible, cord- or knotted-chain-like vessels. Hardaway[10] noted such a case in a woman in whom both thighs, the buttocks, and lower part of the abdomen presented innumerable varices of the superficial lymph-vessels. In a somewhat similar case under my own care, in a man of thirty, the whole of one

[1] Wegner, *Arch. f. klin. Chirurg.*, 1877, vol. xx., p. 641.

[2] Chipault, *Gaz. des Hôp.*, 1888, p. 1329.

[3] Hoggan, "Multiple Lymphatic Nævi of the Skin and Their Relations to Some Kindred Diseases of the Lymphatics," *Jour. Anat. and Phys.*, vol. xxviii., 1884, p. 304 (with histologic cuts).

[4] Jarisch, "Zur Lehre von den Hautgeschwülsten," *Archiv*, vol. xxviii., 1894, p. 164 (with 15 histologic cuts and review of the subject and references).

[5] Nasse, "Ueber Lymphangiome," *Arbeit. aus der chirurg. Klinik der Univ. Berlin* (Von Bergmann), fourth part, 1890, p. 1.

[6] Leslie Roberts, "Five Cases of Lymphangioma," *Brit. Jour. Derm.*, 1896, p. 309 (with review and references).

[7] See literature of lymphangioma circumscriptum.

[8] Elliot, *Jour. Cutan. Dis.*, 1894, p. 137 (vesicles developed at the edge of an old scar, the manifestation apparently clinically similar to lymphangioma circumscriptum, but histologic examination indicated dilatation of the lymphatic capillaries, probably due to obstruction).

[9] Besnier, quoted by Bowen, *Twentieth Century Practice*, vol. v. (Diseases of the Skin), p. 685 (an acute form of lymphangiectasis involving penis and scrotum, vesicles and some edema developing eight days after a contusion of the penis.

[10] Hardaway, quoted by Hersman, Morrow's *System*, vol. iii. (Dermatology), p. 512.

thigh, more especially on the inner and anterior aspects, was the seat of a network of both superficial and deep-seated lymphatic dilatations, with here and there distinct cystic growths, forming tumors partaking of the nature of both lymphangioma and fibroma; the color of the covering skin is usually normal or slightly purplish. In this rare case at times these formations increase gradually in dimensions, becoming somewhat solid and hardened, and, after reaching the size of a walnut or a small orange, remain stationary; or the overlying skin, which had slowly become thinned and of a livid color, reddens, and after two or three months breaks through at the central part and discharges a slightly bloody, lymphatic fluid, the tumor becoming a trifle tender and painful. Healing takes place after one to several months, usually with an obliteration or partial obliteration

FIG. 137.—An unusual case of fibrolymphangioma (case referred to in the text)

of the cavity, although there is now and then a reformation. This case has now been under my observation, at intervals, for a period of fifteen years; he is now aged forty-five and as yet the malady shows no malignant tendency, although all along it has in its general appearance been suggestive in that direction. As a whole, the formation is becoming gradually more pronounced, but, except as to its inconvenience, gives rise to no actual discomfort.

Simple lymphangioma consists usually of both dilatation and new growth, and doubtless the examples just cited, although also illustrating lymphangiectasis, might be more properly considered as belonging to this group. Ordinarily, however, the formation presents as isolated, or adjacent circumscribed, compressible, and somewhat elastic swellings, variously sized, and with sometimes dilated lymphatic

channels leading into them. They may be seen upon any part, but the genitalia and lips and mouth are the most frequent localities. Not uncommonly there may be some edema and thickening, and a condition of slight elephantiasis results. The surface is sometimes scantily or moderately abundantly beset with transparent vesicles, which, if ruptured or broken, give exit to fluid exudation, occasionally a more or less prolonged leakage. Bowen observed a case of "a boy of eighteen who presented upon the inner side of the thigh a large, easily compressible tumor, which was surrounded and covered by small vesicles," from which, when punctured, "a milky fluid continued to exude for a long period, after which the large tumor diminished greatly in size, but attained its former dimensions in a short time." Such lymphangiomata upon the lips usually give rise to a condition designated *macrocheilia*, and when on the tongue, to *macroglossia*. Under simple lymphangioma should also be included, I believe, the cases reported by Van Harlingen[1] and Pospelow,[2] under the name *lymphangioma tuberosum cutis multiplex*, with the belief that they represented the malady previously described by Kaposi.[3] Leslie Roberts[4] has since reported a similar case. Kaposi's case, and also a similar one since described by Lesser and Beneke,[5] belong, however, as now generally believed, to the increasing and somewhat confusing group of cases classed under benign cystic epithelioma (*q. v.*), although Kaposi does not fully concede this.

In the 3 cases of Van Harlingen and Pospelow and Roberts, representing apparently true lymphangiomatous development, the lesions were somewhat numerous, scattered, varying in size from a pin-head to a hazel-nut, and elastic and compressible; the integumental covering was apparently normal, although mostly of a rosy or a violaceous tinge; some lesions had a pale violaceous or bluish, translucent-looking center. Associated with these formations was a somewhat dingy condition of the skin and spots or areas of pigmentation. A few of the tumors may resemble small, flabby, molluscum fibrosum growths, but for the most part they are smooth, rounded, or ovoidal elevations, and so compressible under the finger as to feel like "bladders filled with air and to give the sensation similar to that of an umbilical hernia in a child." They were free from inflammatory action, and there were no subjective symptoms. The three patients were women, aged twenty-three, thirty, and thirty-two. Microscopic examination showed the structure to be composed of fibrous and granulation-cell tissue, with numerous irregular spaces—sections of dilated lymphatic vessels (Van Harlingen).

Cystic lymphangioma, another of Wegner's classes, needs to be but cursorily referred to here, as it rarely comes under the observation of the dermatologist, belonging essentially to the province of surgery, to the works on which the reader is referred for a descriptive

[1] Van Harlingen, "A Case of Lymphangioma Tuberosum Cutis Multiplex," *Trans. Amer. Derm. Assoc.*, 1881, p. 28 (abstract only—full paper never published).

[2] Pospelow, "Ein Fall von Lymphangioma tuberosum cutis multiplex," *Archiv*, 1879, p. 521 (with colored case illustration and histologic cut).

[3] Kaposi, Hebra and Kaposi, *Hautkrankheiten*, vol. ii., p. 282 (with histologic cuts).

[4] Leslie Roberts, *loc. cit.* (case V.).

[5] Lesser and Beneke, *Virchow's Archiv*, vol. cxxiii., 1891, p. 86 (with histologic cuts).

account. It is usually congenital in origin, consisting of large multilocular cysts, most commonly seen on the upper part of the neck, in which region they are often known as hygromata colli. In this locality their prolongation may extend somewhat deeply, going in between the muscles, even as far as the mediastinum (Bowen).

Cavernous lymphangioma, the other group in Wegner's classification, as it is commonly observed in the domain of dermatologic practice is that form of lymphangioma to which the name of lymphangioma circumscriptum is given, and which is, therefore, owing to its importance, given separate description. While it has in its purest type well-defined and fairly uniform clinical characteristics, it presents in some instances, as an analytic study of the cases reported will show, features indicating a relationship to other types of lymphangioma and also to nævoid formations.

LYMPHANGIOMA CIRCUMSCRIPTUM.

Synonyms. — Lymphangioma cavernosum (Besnier); Lupus lymphaticus (Hutchinson); Lymphangiectodes; Lymphangioma simplex; Lymphangioma superficiale simplex (Unna); Lymphangioma capillare varicosum (Török); *Fr.*, Angiome cystique (de Smet and Bock); Lymphangiome circonscrit vesiculeux (Brocq and Bernard).

Definition.—A limited, regional, or patch eruption connected with the lymphatics, characterized by pin-head- to small pea-sized, usually somewhat deep-seated, often red-dotted, closely crowded vesicles.

This rare disease, for which the name lymphangioma circumscriptum, given by Morris, seems the most appropriate one, was first described by Tilbury Fox, and later by Hutchinson, Köbner, Noyes and Török, Morris, J. C. White, Leslie Roberts, Francis, Elliot, Hartzell, Gilchrist, and others.[1]

[1] Literature: Tilbury and Colcott Fox, *London Pathol. Soc'y Trans.*, vol. xxx., 1879, p. 470 (with histology); Hutchinson, *ibid.*, 1880, vol. xxxi., p. 342 (2 cases with colored plates and histologic report by Sangster), and *Arch. Surgery*, vol. i., 1889–90, plates xv. and xvi. (of above 2 cases and an additional one); Köbner, *Virchow's Archiv*, vol. xciii., 1883, p. 343 (hand and arm, somewhat cavernous development; with 3 case illustrations), also full translation in *Annales*, 1884, p. 293; Malcolm Morris, *International Atlas*, 1889, plate i. (colored illustration of his own case and Hutchinson's 3); Noyes and Török, *Brit. Jour. Derm.*, 1890, p. 359, and 1891, p. 8 (résumé and critical review of cases (4 of which do not, however, come under this disease) to date; with histologic examination, cuts, references); Török, *Monatshefte*, vol. xiv., 1892, p. 169 (relation to angiokeratoma—critical analysis of cases and principal references)—abs. analysis in *Brit. Jour. Derm.*, 1892, p. 397; Schmidt, *Archiv*, vol. xxii., 1890, p. 529 (2 cases, 1 of upper lip and oral mucous membrane; 2 histologic cuts; review and references)—abs. analysis in *Brit. Jour. Derm.*, 1892, p. 133; Jamieson, *Edinburgh Med. Jour.*, vol. xxxvi., 1890, p. 269 (case demonstration, with notes); Elliot, *New York Med. Record*, vol. xxxix., 1891, p. 561; Besnier-Doyon, French translation of Kaposi. vol. ii., p. 380; de Smet and Bock, *Jour de med. de chirurg. et de pharmacol. Bruxelles*, 1891, vol. xcii., p. 495; Hartzell, *Medical News*, 1892, Jan. 16 (with a résumé of 8 previously reported cases and references); Epstein, *Jour. Cutan. Dis.*, 1892, p. 213 (2 illustrations; a somewhat anomalous case, seated about the genitalia, lower abdomen, and left buttock, beginning when aged twenty-four, and tending to disappear); Francis, *Brit. Jour. Derm.*, 1893, pp. 33 and 65 (7 cases—1 or 2 not clearly defined, with résumé and analysis of all previously reported cases); another case, *ibid.*, p. 364; J. C. White, *Jour. Cutan. Dis.*, 1894, p. 474; Leslie Roberts, *Brit. Jour. Derm.*, 1896, p. 309 (5 cases of lymphan-

Symptoms.—The type of this rare malady is represented by one or several contiguous or closely adjacent patches, composed of variously sized, thick-walled, frog-spawn-like, grayish, pinkish, or reddish vesicles, somewhat thickly set or even slightly crowded or bunched. If a single patch,—probably the most frequently observed,—it is usually made up of two or three aggregations, with here and there a few discrete vesicles between. The patch varies in size and shape, generally one to three or four inches in its largest diameter, and rather irregularly rounded or ovalish. The lesions, more especially the smaller and more recent ones, present a glimmering, translucent, distinctly vesicular, grayish or pearly aspect; in some cases some of the older lesions very often show epithelial thickening and roughening, and the translucency is lost, and when such a condition is predominant, a slightly warty appearance is given to the individual elevations and to the patch as a whole. Quite commonly, on the covering wall of the vesicle, minute telangiectases in the form of dots or striæ are to be seen. This feature, if conspicuously developed, lends to the lesions a pinkish or pinkish-red, opalescent aspect, and in some instances (Hutchinson) so marked as more or less completely to mask their usual color. In some, from rupture of these minute capillary vessels and admixture of the escaped blood,—usually minute in quantity,—a deep-red, purplish, or blackish look is given the vesicles. In a well-marked patch of long duration it is usual to find, therefore, clear shining vesicles, vesicles capped with red dots or striæ, purplish or blackish lesions, and wart-like elevations. The lesions are firm and, as a rule, thick walled and not easily ruptured, although presenting a vesicular appearance, which can readily be corroborated by pricking, the discharge being slight, but sometimes leakage being continued for some minutes or an hour or two. In occasional cases, as in White's patient, there is, in places, crusting of very firm consistence, of a yellow or reddish color, formed apparently by the coagulation of the contents of the vesicles, and is quite tough and somewhat persistent.

In several instances (Besnier and Doyon, Hutchinson, J. C. White, and others) the part and immediate vicinity have exhibited a recurring erysipelatous inflammation, in all probability accidental, or possibly of the same character as observed in other maladies with lymphatic involvement. As a rule, there is but little if any distinct elevation of the skin area in which the lesions are seated; in some cases, however, there is an underlying nævoid, tumor-like elevation, and in others an underlying basis of lymphatic dilatation, and, on the extremities, a varicose condition of the veins; these cases are somewhat questionable and anomalous, although the surface lesions

gioma—various types); Gilchrist, *Johns Hopkins Hosp. Bull.*, 1896, p. 138 (with histologic cut); Colcott Fox, *Brit. Jour. Derm.*, 1896 (case demonstration); Malcolm Morris, *ibid.*, 1898, p. 52 (case demonstration); Walsh, *ibid.*, p. 338 (case demonstration—involving eye and eyelids); Freudweiler, *Archiv*, vol. xli., 1897, p. 323 (colored case illustration, histologic cuts, review, and references); Brocq and Bernard, *Annales*, 1898, p. 305, "Sur le lymphangiome circonscrit de la peau et des muqueuses" (an elaborate and exhaustive review of the whole subject, with résumé and references and histologic cuts); Pawlof, *Monatshefte*, vol. xxix., 1899, p. 53 (with 2 histologic cuts, and with review of histologic findings and references); Waelsch, *Archiv*, vol. li., 1900, p. 97 (with 2 colored plates and histologic review); Pollitzer, *Jour. Cutan. Dis.*, 1906, p. 493 (2 cases, histologic with illustrations).

and characters are identical. The eruption may be on almost any part, but the shoulders, neck, and scapular region are favorite localities. According to Schmidt and Brocq and Bernard, the lips and mouth may also be the seat of the malady. The eruption is persistent, although some of the vesicles disappear, others taking their place; and there may be some variation, but, as a rule, the area is gradually extended. Occasionally, as in 1 (Hartzell's case) of the 2 cases under my observation for some time, there was a gradual shifting of the area, progressing at one side and receding at the other, and, according to Hartzell, several years later the entire patch had moved from the scapular region to the summit of the shoulder, the former site showing some slight atrophy of the skin, faint pigmentation, and here and there a few small, isolated papules. There are no subjective symptoms except those due to accidental circumstances.

Etiology.—With few exceptions the malady has begun in infancy or early childhood, and it is quite probable that in most of them it was congenital. It is observed in both sexes. In some cases it has been associated with nævi (Besnier and Doyon, Fox, Pye-Smith, and others).[1] In several instances lesions and lesional groups, apparently representing this same malady, though possibly due to mechanical obstruction of the lymphatics, have developed at the border of a scar following surgical operation. Development—recurrences—at the border of previously cauterized patches of the disease has also been noted.

Pathology.—The histologic conditions have been investigated by most of the observers already named (see literature). The process has its seat more especially in the papillary and subpapillary layers of the corium, and is now generally agreed to be of lymphatic origin. It consists of lymphatic dilatation as well as new growth of these vessels, resulting in somewhat flask- or funnel-shaped cavities. De Smet and Bock take issue with this generally accepted conclusion and consider these cavities or cysts to have their origin in the capillaries of the papillary layer. Török believes that both the lymphatics and blood-vessels are concerned in the process; mainly, however, the former. It would seem, from a clinical standpoint, as well as from histologic findings by several observers, that this has considerable basis, capillary dilatation and new blood-vessel formation being quite pronounced in some instances, although practically absent in others. In fact, Besnier and de Smet and Bock question the propriety of classing all the reported cases together, believing that some are pseudo-lymphangiomata; not lymph vascular growths at all, but true hemangiomata, in which the blood-cysts have become filled with serum and converted into clear vesicles (Jacquet). Gilchrist examined several differently sized lesions and found them all to consist not only of dilated, but also hypertrophied, lymphatics of the papillary (principally) and middle layers of the corium. Sangster's investigations led him to believe that the deeper cavities are dilated lymphatic channels, while those more superficially seated are

[1] Pye-Smith, *Diseases of the Skin*, p. 359 (appearing upon a large congenital port-wine stain).

to be ascribed to distention and rupture of the lymph-spaces in the papillary layer. The cavities are often divided into several subdivisions by septa formed of the unaltered corium, and a well-marked layer of cells can be traced, forming an endothelial lining to the cavities (Bowen). Bowen also found some infiltration of round-cells around the cysts and cavities in the earliest stage of the lesions, but none in other parts of the cutis, and Gilchrist also noted collections of mononuclear cells in the corium. The epidermis commonly shows but little change, in some places being slightly thinned, in others thickened. The vesicular covering usually consists of the entire epidermic layer, and sometimes a well-defined thin layer of connective tissue; hence their firm and not readily ruptured character. The pigment in the deep cells of the rete is frequently observed to be increased. The contents of the cysts consists of very finely granular matter, lymph coagula, a scanty, though variable number of leukocytes, and occasionally a slight admixture of blood.

Diagnosis.—The character of the area, beginning usually in early life and consisting of aggregated and crowded yellowish or grayish, somewhat translucent, deep-seated, tough vesicles, some often with a rough, thickened covering, and others with red dots or striæ, and occasionally one, several, or more with purplish or blackish contents, are sufficiently striking as to prevent confusion with any other malady.

Prognosis and Treatment.—There is but little, if any, tendency to spontaneous disappearance, but, on the contrary, there is a disposition to extend, although individual vesicles often disappear. Treatment consists in thorough removal by cauterization, curet, or other means. There is, however, a tendency to reappear at the edge of the scar, and recurrence is almost a certainty if the removal has not been radically complete. In a few instances electrolysis has been employed with a favorable influence; each vesicle should be treated, and the whole area gradually gone over.

MULTIPLE BENIGN TUMOR-LIKE NEW GROWTHS.

Under the name of multiple, benign, tumor-like new growths a case has been pictured and described by Schweninger and Buzzi,[1] characterized by lentil- to bean-sized, whitish or bluish-white, rounded or slightly flattened, circular or oval projections, the larger somewhat puckered. They seem hollow, and when one is pressed in with the finger, it can usually be pushed below the level of the surface into a concave depression; immediately upon withdrawing the finger it springs up again. In short, they present the physical characteristics of an elastic, hollow, bladder-like tumor. The smaller beginning formation is usually rounded, and when moderately developed, is frequently more elastic than the older, larger, and often somewhat flattened growth. A variable degree of spontaneous involution takes place, although they do not actually disappear, merely becoming more flaccid, with the skin slightly atrophic, and with, usually,

[1] Schweninger and Buzzi, *International Atlas of Rare Skin Diseases*, 1891, vol. v., plate xv.

minute scar-like depressions or striations. They appear slowly, and at first there are relatively few, but the addition of new tumors from time to time finally results in a variable, but usually considerable, number. According to Crocker,[1] the malady has also been observed by Malcolm Morris, Colcott Fox, and Van Hoorn. I have met with a similar instance in a middle-aged woman, with 30 to 40 such bladder-like tumors over the region of the right shoulder and immediately adjacent part of the back; they were of extremely slow development, and, as in the other cases, gave rise to no subjective symptoms. Over the well-developed and older tumors the integument was distinctly atrophic or cicatricial looking, but soft and elastic.

The shoulders, trunk, and thigh are favorite situations. There has been no recognizable cause. Of the 5 cases, 4 were women. Histologically, Buzzi's findings show that the skin alone is involved in their formation, the elastic fibers being absent in the main part of the covering integument, and in increased quantity peripherally. This passive retraction or atrophy of the elastic tissue appeared to be the essential and primary factor of the pathologic process, and recognizable in all the lesions, whether small or large, and this fact would place the tumors among the atrophies, although in their appearance, projection, etc., clinically they would naturally be placed among the new growths. Round-cell collections were noted about the superficial horizontal capillary network and about the vessels of the glandular structures; the sebaceous glands showed enlargement. No influence is to be expected from treatment.

XANTHOMA.

Synonyms.—Xanthelasma (Wilson); Vitiligoidea (Addison and Gull); Fibroma lipomatodes (Virchow); *Fr.*, Xanthome; Plaques jaunâtres des paupières (Rayer); Molluscum cholésterique (Bazin).

Definition.—A slightly elevated, flattened, or somewhat rounded, soft, neoplastic growth of a yellowish color, usually seated as one, several, or more lesions about the eyelids, and occasionally of more or less general distribution. There are two varieties observed—xanthoma planum and xanthoma tuberculatum seu tuberosum; in the former the lesions are flat or plate-like, and usually seated about the eyelids; in the latter, rounded and nodular, and somewhat general in distribution (xanthoma multiplex). This last term is also applied to the mixed type, which, however, is almost invariably more or less disseminated.

Symptoms.—Xanthoma Planum.[2]—This, the macular or plane variety, is usually seen about the eyelids (xanthoma palpebrarum), and consists of one, several, or more small or large, round or elongated, smooth, opaque, yellowish patches, sharply defined and often slightly raised, and looking not unlike pieces of chamois leather implanted in the skin. Their first appearance is probably most com-

[1] Crocker, *Diseases of the Skin*, third edit., p. 702.

[2] Hutchinson, *London Med.-Chirurg. Soc'y Trans.*, 1871, p. 171, has contributed a valuable paper on xanthoma palpebrarum, based upon 36 cases under his own care—cases are detailed and tabulated; he also gives another table of 7 cases observed by others, of which 3 are of the multiplex variety.

monly on or near the inner canthus on the upper lid, and it is alleged more frequently the lid of the left eye. As a rule, however, when medical attention is directed to the blemish, the growth is to be seen on the lids of both eyes. From my own experience I cannot say that the upper is more frequently invaded than the lower. Usually the patches are to be found on both lids, more or less symmetrically arranged. There may be but several present, or the eyes may be more or less surrounded by an apparently continuous band. In most cases, however, there are several closely contiguous patches, which, unless closely inspected, seem to be fused into one strip. The growth is smooth, scarcely elevated, soft and compressible, and of a lemon- or orange-yellow color, more frequently a dingy lemon hue, which becomes more pronounced when the skin is put upon the stretch. Examined closely, especially if the skin is stretched, or with a magnifying-glass, the patch resolves itself into numerous, crowded, small yellowish spots, each with a minute pinkish or reddish central point. The surface of the skin overlying the yellow plaques is apparently normal and free from scaliness. Occasionally, instead of a yellow hue, a whitish or creamy color is observed, and exceptionally, especially in some lesions, the color may be much darker than usually observed—from a dark yellow to a deep brown; a rare instance of the latter was noted by G. H. Fox,[1] in which the xanthoma band, in a male, of eleven years' duration, was roughly suggestive of an ecchymosis. Their growth is, as a rule, exceedingly slow, several years or more usually elapsing before they have attained considerable dimensions. Exceptionally, in addition to the patches on the eyelids, the spots are also observed beyond the lids, on other parts, and even in the mouth; as a rule, however, in the latter cases the growths are of the nodular type, and sometimes of mixed character. There are no subjective symptoms, although exceptionally occasional itching or burning is experienced.

Xanthoma tuberculatum seu tuberosum (xanthoma multiplex)[2] is, as the qualifying term signifies, of a nodular character. In most respects

[1] G. H. Fox., *Jour. Cutan. Dis.*, 1889, p. 103 (case demonstration).

[2] Xanthoma multiplex—important literature: Committee Report (Hutchinson, Sangster, and Crocker) of London Patholog. Soc'y, *Transactions for 1882*, p. 376 (with an analytic tabulation of 23 cases in adults, with associated jaundice, a tabulation of 5 cases in adults without jaundice, and a tabulation of 8 cases in which the disease was congenital or appeared before puberty). Török (De la nature des xanthomes), *Annales*, 1893, pp. 1109 and 1261 (an exhaustive report with references, and a detailed analytic tabulation of 40 cases of xanthoma multiplex in the adult, and another of 30 cases in children). These two papers cover the cases pretty fully to date. Among other cases recorded since: Shepherd, *Montreal Med. Jour.*, 1893–94, vol. xxii., p. 765 (case demonstration—adult—jaundice); James, *Brit. Med. Jour.*, 1894, ii., p. 805 (child—congenital); Feulard, *Annales*, 1894, p. 544 (child); Thibiérge, *ibid.*, p. 318 (2 boys—brothers); Stout, *Jour. Cutan. Dis.*, 1894, p. 244 (with illustrations—adult—jaundice); Leslie Roberts, *Brit. Jour. Derm.*, 1894, p. 148 (adult—no jaundice); Colcott Fox, *ibid.*, 1896, p. 89 (case demonstration—adult, with jaundice—profuse eruption), and 1898, p. 414 (case demonstration—adult, with jaundice and profuse eruption); Whitehouse, "Xanthoma Multiplex (Histology of the Palmar Striæ)," *Jour. Cutan. Dis.*, 1904, p. 470 (histologic examination by Johnston), abstracts of several interesting cases reported during the past few years by Dehot, Richter, Parkes Weber, Leven, McFarland, and Tennenheim, are given in *Jour. Cutan. Dis.*, 1905, pp. 186–190. Leven's paper, in the original, *Archiv*, 1903, vol. lxvi., p. 61, reviews and analyzes 23 cases from literature, some of diabetic variety.

the growths are similar to those of the plane variety, but they are usually rounded in outline, somewhat elevated, and are either soft or of moderately firm consistence. They are rarely found about the eyes, but on other parts, and hence this term is practically synonymous with **xanthoma multiplex**. Occasionally, however, it begins about the eyelids as the ordinary flat variety, and at the same time or later presents on other regions, commonly as the tubercular form, although the eruption is sometimes made up of the several varieties of lesions; or there may be an appearance of lesions about the hands, knees, and elbows, subsequently developing upon other parts, and the eye region may be entirely spared. The growths average a small pea, but are often crowded together into groups, bunches, or almost solid plaques. In some cases the nodules are noted to have a pinkish periphery, especially in their formative period. Exceptionally they may reach considerable dimensions, usually due to coalescence of several of the growths. An instance of this kind was observed by Lehzen and Knauss,[1] the patient being a child, some of the growths reaching the size of an egg. Similar tumors, although not quite so large, have also been observed by Carry and Chambard.[2] In general cases certain parts are most frequently the sites of the lesions, such as the hands, about the elbows and knees, the buttocks, and the feet; the face, and especially about the eyes, also frequently shares in the eruption. Occasionally the distribution or grouping is somewhat unusual or anomalous. In Morrow's[3] case the lesions, which were somewhat hard, were, for the most part, limited to the soles, with some lesions about the knees and some previously upon the palms. In 2 instances—brothers—of somewhat extensive eruption observed by Mackenzie,[4] some was disposed in ridges and lines, and in both cases with an almost continuous band of some width around the neck.

Jaundice is a usual precursory or associated symptom in xanthoma multiplex in the adult, although not invariably present; in children, in whom, however, the malady is less frequent, it is always wanting. The eruption in the latter is quite extensive, usually more so than in adults, a most remarkable example of which has been reported in recent years by Jackson,[5] in a young child, covering a greater part of the surface. In children the eruption exhibits nothing in any way different from that in adults; while usually abundant, it is sometimes quite scanty, consisting of but one, several, or more patches, as in the cases referred to by Crocker,[6] Török, and others; and in some of these instances the patches were small, several of the patients coming under medical inspection accidentally. There is no question at all that other organs than the skin can also be the seat of xanthoma, as

[1] Lehzen and Knauss, *Virchow's Archiv*, vol. cxvi., 1889, p. 85 (with case illustration and 4 histologic cuts).

[2] Carry, *Annales*, 1880, p. 64; Chambard, *Arch. de phys. norm. et pathol.*, 1879, p. 691 (with numerous references and 2 colored plates showing disease on palm, penis, and chin, and 5 colored histologic cuts).

[3] Morrow, *Jour. Cutan. Dis.*, 1893, p. 1 (with colored plate).

[4] Mackenzie, *London Patholog. Soc'y Trans.*, 1882, p. 370.

[5] G. T. Jackson, *Jour. Cutan. Dis.*, 1890, p. 241 (with colored plate, with references to other general cases).

[6] Crocker, *Diseases of the Skin*, third edit., p. 742.

shown in some autopsies. The mouth and lips, as already referred to, sometimes share in the eruption, although seldom and only to a slight extent. The eye itself, in rare instances, has been noted to become involved. In von Graefe's case, quoted by Virchow,[1] and also referred to by Pye-Smith,[2] the growths were observed on the cornea as well as in other parts.

Ordinarily xanthoma develops gradually: xanthoma palpebrarum, always slowly; occasionally, however, in the multiplex variety several months suffice to show considerable eruption, and exceptionally, as in Korach's[3] case, extensive development was reached in a few weeks. The course of xanthoma of either variety is chronic and slowly progressive, with but little, if any, tendency to undergo involution, although this is sometimes observed in a few lesions in the multiplex variety, and exceptionally this latter has shown a tendency to complete disappearance (Fagge, F. Smith, Legg, and Kaposi).[4]

Etiology.—While xanthoma planum (xanthoma palpebrarum) and xanthoma multiplex are probably the same disease,—certainly in their clinical aspects identical,—yet they differ in some of their etiologic factors, and these varieties can be more conveniently considered separately. Xanthoma palpebrarum is not uncommon and is essentially a disease of adults, rarely being observed in children, and it is, moreover, much more frequent in females. Hutchinson's analytic table makes the proportion 3 women to 2 men, but this seems much larger than dermatologic observation would indicate. This careful observer also states that in half of his cases the patients were subjects of migraine, and one-sixth had suffered with jaundice. Gouty and rheumatic conditions, utero-ovarian derangements, and other affections have variously seemed in certain cases to be of influence, but it is doubtful whether they are more than accidental, or, at the most, contributory. There is, however, a factor which is noted sufficiently often to be of probable import, and that is heredity. In Church's[5] cases, often quoted, there were 3 cases in each of two succeeding generations; and Wilks[6] also observed it in mother and daughter; Fagge[7] also in mother and daughter, in whose family there was a history of the malady for four generations. Hutchinson[8] observed it in two brothers whose paternal grandfather had also had it.

Xanthoma multiplex is rare, although recorded cases are gradually approaching a considerable number. It is met with both in children and adults and in both sexes. In children it may be congenital, or develop in the earlier years of life, and the eyelids do not commonly share in the eruption nor is jaundice observed. In some of these instances (children) there seems to be a family prevalence; Mackenzie[9] had under observation 3 cases in a family of 7 children, and

[1] Virchow, *Virchow's Archiv*, 1871, vol. lii., p. 504.

[2] Pye-Smith, *Guy's Hosp. Reps.*, 1877, vol. xxii., p. 97, refers also to various other xanthoma cases.

[3] Korach, *Deutsche med. Wochenschr.*, 1881, p. 329.

[4] London Path. Soc'y Committee Report (*loc. cit.*).

[5] Church, quoted by Mackenzie, *London Patholog. Soc'y Trans.*, 1882, vol. xxxiii., p. 370.

[6] Wilks, *ibid.*, vol. xix., p. 446 (also quoted by Mackenzie).

[7] Fagge, quoted by Crocker, *Diseases of Skin*, second edit., p. 492.

[8] Hutchinson, *loc. cit.*

[9] Mackenzie, *loc. cit.*

Startin[1] a brother and sister, and Thibiérge[2] in two brothers. The tabulations referred to furnish additional examples.

Jaundice is, as before remarked, often associated with multiple xanthoma in the adult—in 23 out of the 28 cases tabulated by the London Pathological Society Committee. Schwimmer[3] quotes the following proportions, based, however, upon totals of both varieties combined: Kaposi, 15 in 27 cases; Chambard, 22 in 58 cases; in 10 consecutive cases of his own, including 2 cases of xanthoma multiplex, icterus was not observed in a single instance.

Kaposi, Hardaway, and others are inclined to consider the jaundice not as a causative factor, but as probably due to development of the xanthoma growths in the liver, a view which, I believe, has much in its support. Autopsies have furnished evidence both for and against its causative influence, the liver often being found uninvolved, and in other cases exhibiting various diseased conditions. According to Besnier and a few others, the yellow color is not always due to jaundice, but the disease itself may be responsible for the cutaneous discoloration—xanthodermic, as Besnier designates it.

Pathology.—Xanthoma is a benign, connective-tissue new-growth development, possibly of mildly inflammatory origin, with concomitant or subsequent, but usually partial, fatty degeneration. The suggestion of a diathesis originating in the digestive apparatus, leading to hepatic derangement, has been advanced as a pathologic factor, and Quinquaud's assumption that there may be, from some unknown cause, a surcharge of the blood with fatty elements, may have some theoretic basis, but lack substantial foundation. Under such a supposition the xanthoma multiplex cases could readily be explained by the additional determining factor of local irritation, as those sites—hands, elbows, buttocks, knees, and feet—which are always subject to knocks, frictions, and the like are the parts upon which the eruption is commonly or most abundantly seen. Histologic studies made by Pavy, Chambard, Balzer,[4] Touton,[5] Crocker, Pollitzer,[6] Török, and others, are all agreed in essential facts as to conditions found, but differ as to whether or not the process is primarily an inflammatory one, an opinion supported by Chambard, Crocker, and others, while Touton is the most insistent as to the opposite view. There seems also to be more or less unanimity as to the histologic identity of the two types, Pollitzer and Unna dissenting, Unna so strongly as to say that the generalized form is so different, both histologically and clinically, as to deserve an entirely different name. Excepting sometimes slight thinning and some pigment staining and deposit of yellowish pigment granules in the rete, the epidermis shows but little alteration, at times some of the lower rete cells showing slight atrophic changes and vacuolation. The chief changes are noted in the corium, especially in the middle and

[1] Startin, *London Patholog. Soc'y Trans.*, 1882, p. 373 (with colored plate).
[2] Thibiérge, *loc. cit.*
[3] Schwimmer, *Ziemssen's Handbook of Diseases of the Skin*, p. 577.
[4] Balzer, *Arch. de physiologie*, vol. iv., 1884, p. 65 (with references).
[5] Touton, *Archiv*, 1885, vol. xii., p. 3, with histologic illustrations and references.
[6] Pollitzer, "Nature of the Xanthomata," *New York Med. Jour.*, 1899, ii., p. 73 (a histologic study, with 11 illustrations and references).

lower layers. Large cells filled with fat granules and closely aggregated fat-drops having a defined membrane and a large, sometimes several or more, nuclei, are found lying between the bundles of connective tissue, constituting the so-called "xanthoma cells"—"xanthoma giant-cells." Transition cell-formations are also to be seen. These cells vary somewhat in size, some being small, others quite large, and are found in considerable numbers, sometimes massed together in groups, frequently around and following a blood-vessel; some may at times be found in the subcutaneous tissue, although this latter structure is, as a rule, practically unchanged. The glandular structures show but little alteration. Connective-tissue increase is usually a pronounced feature, varying considerably in degree. Touton considers the process to be a new growth made up of a deposit of fat and increased connective-tissue elements, and showing a histologic resemblance to some forms of pigmentary nævus. Pollitzer, from investigations of tissue from xanthoma palpebrarum, believes the xanthoma cells to be fragments of degenerated muscle-fibers, and the process a slow, fatty, muscle-fiber degeneration of the orbicularis muscle. Unna also considers this muscle an important factor. Schwimmer found, in addition to the usual conditions, dilated lymph-vessels with swollen endothelia. The old view of Hebra, Geber, and Simon that the growth was of sebaceous gland origin is no longer maintained. The color of xanthoma is assumed to be due to the abundant fat-granules present. According to investigations by both Török and Unna it would seem that in xanthoma we have a special form of fat. In autopsies xanthoma growths have been found in the esophagus, in the trachea and capsule of spleen, in the liver, aorta, heart, and other situations.

Diagnosis.—The characters of the malady are usually so pronounced that confusion with other diseases is scarcely possible. The chamois-leather-colored patch or patches about the eyelids, sometimes band-like and partially or almost completely surrounding it, and occurring in middle and late adult life, is, for this type, sufficiently diagnostic. Possibly upon hurried examination beginning minute lesions might suggest milium, but this latter is cystic, usually white in color, and if punctured, permits easy expression of the sebaceous contents. Xanthoma multiplex would scarcely be confused with the xanthoma-like lesions seen in some cases of urticaria pigmentosa, although this latter affection has been in a few instances reported as xanthoma. Xanthoma multiplex lesions are, however, of fairly uniform character as to color, possibly varying somewhat in shade, whereas in urticaria pigmentosa the active lesions are distinctly urticarial, and there is usually an urticarial condition of the skin. Pollitzer[1] has called attention to the possibility of some cases of multiple dermoid cysts being mistaken for xanthoma, and, in addition to the one coming under Sangster's and his own observation, refers to several similar instances, and suggests, in order to avoid such an error, the puncturing of a lesion in xanthoma-like eruptions or histologic examination, a dermoid cyst being thus readily recognized.

[1] Pollitzer, "Multiple Dermoid Cysts Simulating Xanthoma tuberosum," *Jour. Cutan. Dis.*, 1891, p. 281.

A fact to be remembered in xanthoma multiplex is that almost all cases in the adults have an associated jaundice. Its differentiation from xanthoma diabeticorum will be considered under this latter disease.

Prognosis.—There is practically no prospect for spontaneous disappearance of the malady; the several instances already referred to in which involutionary changes were observed are rare exceptions to the rule that the disease is persistent, and up to a variable point progressive. After reaching a certain development the progress seems stayed, and the growths remain stationary. In some cases, however, of limited extent, treatment has been effectual in removing the blemish.

Treatment.—Xanthoma palpebrarum may be removed by excision or the curet, and in some instances by mildly caustic applications and electrolysis. I have employed two methods: The application of trichloracetic acid and electrolysis. The trichloracetic acid is applied in scant quantity, limiting it to the area of the disease (only to a small part at one time if the area is large), and in those of very delicate skin it should be first tried diluted with an equal part of water; considerable surface reaction follows in some cases, with superficial crusting. Vaselin or cold cream can be applied till the irritation subsides and the crust comes away. A second or third application may be necessary. Sometimes the blemish is thus completely removed, but more commonly only rendered less conspicuous; sooner or later it shows a disposition to return. Electrolysis requires a current of 1 to 5 milliampères, the growth being punctured superficially and, if large, at several points. The operation in some cases must be repeated at intervals of two to four weeks before a final result is reached, and in most cases the effect, while favorable, is not permanent, although more frequently than with the trichloracetic acid method. If the growth is extensive, but a portion should be treated at a time. McGuire[1] has reported good results from monochloracetic acid. Stern's[2] method of applying a 10 per cent. solution of corrosive sublimate in collodion has not met with favor. Morrow,[3] in his case of xanthoma multiplex, used successfully a 25 per cent. salicylic acid plaster, worn continuously for several days or longer, after which a considerable part of the growth was found softened and could be readily removed, after which the part is washed or soaked in hot water, and a plain diachylon ointment applied for a day or two, when the plaster is to be resumed. Leslie Roberts[4] employed a somewhat similar application, a compound salicylated collodion paint: ℞. Ac. salicylici, ʒj (4.); chrysarobini, ʒss (2.); ol. ricini, ʒss (2.); collod. flex., ad ℥j (32.). Evans and Whitehouse had good results from the X-rays; the latter also from the high-frequency current.

Internal treatment is apparently fruitless in xanthoma, although Besnier[5] saw good results from the administration of phosphorus in increasing dosage, given in cod-liver oil, for a few weeks, to be followed by turpentine.

[1] McGuire, *Jour. Cutan. Dis.*, 1898, p. 328.
[2] Stern, *Berlin. klin. Wochenschr.*, 1888, p. 393.
[3] Morrow, *loc. cit.*
[4] Roberts, *Brit. Jour. Derm.*, 1894, p. 148.
[5] Besnier, *Jour. de méd. et de chirurg.*, April, 1886—quoted by Jackson.

XANTHOMA DIABETICORUM.[1]

Definition.—A rare eruption observed in diabetic individuals, consisting of scattered, sometimes grouped and aggregated, somewhat inflammatory papular or nodular elevations, with usually, in most lesions, the basal portion reddish and the apex of a yellowish or yellowish-white color, and generally accompanied by slight subjective symptoms of itching and pricking.

Until recent years this malady had scarcely been known, but since the clear exposition by Malcolm Morris its clinical individuality has been generally recognized, and, in addition to Morris's case, and the few previously reported, numerous new examples have been recorded by other observers, among whom Colcott Fox, Hutchinson, Cavafy, and others in England, Besnier and Vidal in France, and Hardaway, Robinson, Pollitzer, Schamberg, Johnston, and others in America.

Symptoms.—The eruption may present itself gradually, or it may be more or less abundant from the start. In their earliest development the lesions are usually dull reddish or of inflammatory hue, sometimes a raw-beef color, with very soon, in most or many of them, a yellowish or yellowish-white apex, somewhat suggestive of a minute pustule, and later a fading of the peripheral and basal portion to a pinkish color, and usually a widening-out of the yellow tint. The lesions are somewhat firm or hard, pin-head- to small split-pea-sized, rounded or conic, rather sharply defined, papules; discrete for the most part, although often aggregated, and sometimes crowded close together into patches. Some papules may be pierced by a hair, and there may be also some showing red points or lines due to capillary dilatation. Some of the lesions may undergo involution and disappear without trace, and new papules may continue to appear from time to time. Exceptionally the yellowish xanthoma color is quite conspicuous or predominant. The lesions sometimes occur in ill-defined streaks or seem to follow, in some regions, the

[1] Literature: Malcolm Morris, *London Patholog. Soc'y Trans.*, 1883, vol. xxxvi., p. 278, with histologic plate (committee report on the subject, p. 284); a second case, with histologic examination, by J. C. Clarke (with histologic cuts), *Brit. Jour. Derm.*, 1892, p. 237. In this case Morris gives an abstract and literature references of the cases reported by Addison and Gull, Bristowe, Hillairet, Chambard, Hardaway, Barlow, Cavafy, Colcott Fox, Besnier and Robinson. Johnston (Xanthoma Diabeticorum; Its Place among the Dermatoses), *Jour. Cutan. Dis.*, 1895, p. 401, reviews the subject and gives full bibliography (both as to cases and other pertinent literature) to date—including, in addition to the above cases, those since reported by Crocker, Payne, Tims, Pollitzer, Jamieson, Hallopeau, and Schamberg. I am indebted to this exhaustive paper for much of the description of the disease here given. Other cases and literature since recorded: Robinson (another case—woman), *Trans. Amer. Derm. Assoc. for 1896;* Norman Walker, *Brit. Jour. Derm.*, 1897, p. 461, with colored plate and a valuable analytic table and literature references of all cases above (except Robinson's second case), and those since recorded by Darier, Colombini, Toepfer, Geger, making in all 30 cases. Abraham, *ibid.*, p. 484 (case demonstration—male, aged forty-five); Sherwell, with histologic report by Johnston (case, woman, aged forty), *Jour. Cutan. Dis.*, 1900, p. 387; Schwenter-Trachsler, *Monatshefte*, 1898, vol. xxvii., p. 209 (male—colored plate and an abstract résumé and references of most of the reported cases); Krzysztalowicz, *ibid.*, 1899, vol. xxix., p. 201 (male—with 8 colored histologic cuts and bibliography); Sequeira, *Brit. Jour. Derm.*, 1901, p. 56 (case demonstration—male—free from glycosuria); total, 36 cases. Abstracts of several interesting cases, reported in the past three years by Abraham, Antonino, and Bossellini (3 cases), are given in *Jour. Cutan. Dis.*, 1905, pp. 186–190.

cutaneous nerve distribution. Some of the lesions may be more or less flattened, as in Hardaway's[1] case, and the whole aspect be somewhat similar to ordinary xanthoma. While scarcely any portion of the body is free from the possibility of being the seat of lesions, the buttocks, the extensor surfaces of the forearms, the elbows, knees, and the back are favorite situations; in some of the less extensive cases they may be more or less limited to these regions, with other parts sometimes showing a slight sprinkling only. The feet, legs, hands, and face also frequently show the characteristic discrete and bunched papules. In Hutchinson's[2] case, in which the eruption was extremely extensive, the scalp, face, and lips were the seat of numerous and well-developed lesions, the scalp especially being thickly covered.

In most patients the eruption is not abundant, but in that just named, and in those of Hardaway, Morris (second case), Johnston, and a few others, it was present in great profusion, and tended in places to coalesce and form plaques, the latter being usually dotted over with the yellowish points showing the individual component lesions. The eruption is rarely on the eyelids,—the common site of ordinary xanthoma,—Besnier's and Hardaway's cases being exceptional in this respect. Occasionally the eruption has also been seen in the mouth. In some instances the itching and burning, usually present to a variable degree, may be quite troublesome. The papules are, especially when appearing, often quite tender. The course of the disease varies somewhat, but in most instances, after lasting several months or a few years, during which time there is apt to be irregular accession of new lesions and involution of some of the old ones, the eruption gradually disappears. No permanent traces are left.

Etiology.—There has been an associated diabetes mellitus in most patients, and this has, therefore, been looked upon as etiologic; it was, however, wanting in the cases of Cavafy, Hutchinson, Vidal, Geyer, Sequeira, and a few others, and extremely slight in some instances. The extent of eruption has, however, been usually noted to vary according to the amount of sugar in the urine; this was especially noticeable in Johnston's patient. In one instance (Colombini)[3] there was pentosuria. In some of those cases in which sugar was not found, as well as in a few others, albumin was noted to be present—Cavafy's case had suffered from nephritis. Jaundice was present in Hardaway's patient, and the urine showed but a trace of sugar. The malady is seen chiefly in the male sex—out of the total of 36 reported[4] cases there were only 5 women (Hillairet (2), Walker, Robinson (second case), and Sherwell). Its subjects are commonly of the florid and obese type, and many in apparently good health; almost all were between the ages of twenty-five and fifty, Pollitzer's case, a boy aged seventeen, being the youngest.

Pathology.—The proper position of this affection is not yet determined, some holding that it is essentially a form of ordinary

[1] Hardaway, *St. Louis Courier of Medicine*, Oct., 1884.

[2] Hutchinson, *Arch. of Surgery*, vol. i. (1889–90), p. 381.

[3] Colombini, *Monatshefte*, 1897, vol. xxiv., p. 129.

[4] Hyde (discussion, *Trans. Amer. Derm. Assoc. for 1897*) also refers briefly to 2 cases, which would make the total 38; in 1 of his cases there was abundant glycosuria associated with albuminuria.

xanthoma, others that it is a distinct affection. Both the clinical and histologic aspects furnish some support to either view. Besnier and Doyon[1] are the most pronounced in their belief that the malady is not separable, except as a variety, from ordinary xanthoma, and believe that the glycosuria is merely the determining factor in the clinical differences. Török,[2] on the contrary, from his study of the various types, takes a diametrically opposite view; most other investigators lean one way or the other, but apparently their convictions are not as yet of a decided character. The lack of involvement of the eyelids would seem to indicate individuality, although Hardaway's case presented many features common to both. Its apparent relationship to diabetes mellitus, and its disappearance under treatment for the latter, shows pretty strongly that there is a common underlying cause, and this fact would, moreover, seem to separate the malady from ordinary xanthoma, which is persistent and unresponsive to any general treatment, and is rarely associated with glycosuria. Perverted liver function, however, seems to be a factor in both varieties of the multiform xanthomatous process. Török, Kaposi, Johnston, and a few others (quoting from Johnston's paper) believe the cutaneous phenomema are due to an irritative process, the irritation being supplied by the excess of glucose or some faulty product of metabolism circulating in the blood; Johnston believes that this has some support in the fact that the nodules begin in the corium in the neighborhood of the sweat-glands and the hair-follicles, with their attached sebaceous structures, all of which are supplied by the same set of vessels, part of the excretory apparatus of the skin.

The pathologic histology has been studied by Robinson, Crocker, Clarke, Payne, Schamberg, Pollitzer, Walker, and others, and with few exceptions the conclusions are that microscopically the process closely resembles that of ordinary xanthoma, except that the inflammatory element is clearly evident, and the connective-tissue growth less pronounced—according to Crocker, there is no actual connective-tissue growth. This latter, however, is not in accord with the investigations of Robinson and others. The changes are especially conspicuous about the hair-follicles. The "xanthoma cells" are also found. The process is practically confined to the corium, and apparently the first step is vascular dilatation, followed by other evidences of inflammatory action. Central degenerative changes of a fatty nature take place, and to this mass of fatty granules is due the central yellowish color. Pollitzer,[3] who has made extensive histologic studies of the various xanthomata, considers the two varieties of generalized xanthoma as histologically identical, the process in the diabetic form being a little more diffuse and the tendency toward fatty degeneration more marked than in the non-diabetic variety; in the Cohnheim sense he scarcely thought the process could be considered an inflammatory one, but an irritative hyperplastic development of connective tissue, with a tendency to fatty degeneration. Walker agrees with Pollitzer in not viewing the process as inflammatory; he considers it approaches nearest to the chronic granulomata, and suggests the possibility of some organismal cause.

[1] Besnier and Doyon in French translation of Kaposi's treatise, vol. ii., p. 335.
[2] Török, *loc. cit.* [3] Pollitzer, *loc. cit.*

Diagnosis.—The color of the growths,—the reddish or pinkish peripheral and basal portion, and the yellowish central apex,—their sudden evolution, absence from the eyelids, the firm, solid character of the lesions, the occasional follicular origin, the involutionary changes, often quite noticeable, and the accompanying glycosuria and the subjective symptoms, together with the tendency, after months or a few years, to spontaneous disappearance—are all different from the symptoms of ordinary xanthoma multiplex, and will serve to distinguish the one from the other.

Prognosis and Treatment.—Probably sufficient has already been said as to prognosis. The malady frequently disappears spontaneously in a few months or years, more quickly by treatment. Instances of long duration—over seven or eight years in Cavafy's case—and of the tendency to extensive relapse in Johnston's case, are of exceptional occurrence.

The treatment consists in the adoption of measures for the cure or palliation of the associated glycosuria, more especially by means of regulation of the diet and the administration of such remedies as arsenic and codein, or other drugs if indicated by other conditions. For relief of the itching, often present, lotions of carbolic acid, of liquor carbonis detergens, with or without saturated boric acid solution as a basis, or any of the milder lotions or ointments employed in acute eczema or in pruritus, would doubtless answer the purpose.

COLLOID DEGENERATION OF THE SKIN.

Synonyms.—Colloid milium (Wagner); Hyaloma; *Fr.*, Dégénéréscence colloïde du derme; Colloïdome miliaire (Besnier); Colloïd milium; Hyalome (Vidal and Leloir); *Ger.*, Hyaloma der Haut (Auspitz); Colloide Degeneration.

Definition.—An affection characterized by pin-head- to split-pea-sized nodules, of a yellowish color, having a translucent appearance, and usually observed on the upper part of the face, and due to colloid degeneration of the dermal connective tissue. The literature[1] of this rare malady is scanty, but few unquestioned cases being

[1] Literature: Wagner, *Arch. der Heilkunde*, 1866, p. 463; Besnier, *Annales*, vol. x. (1877–80), p. 461; Balzer, *ibid.*, p. 468 (histologic examination of Besnier's case); Feulard-Balzer, *ibid.*, 1885, p. 342; Liveing, *Brit. Med. Jour.*, 1886, i., p. 586; Philippson, "The Relationship of Colloid Milium (Wagner), Colloid Degeneration of the Skin (Besnier), and Hydradenoma (Darier-Jacquet) to One Another," *Brit. Jour. Derm.*, 1891, p. 35, and *Monatshefte*, 1890, vol. xi., p. 1 (a histologic and clinical study with case citations and references); Perrin-Reboul, *Trans. Second Internat. Dermat. Cong.*, Vienna, 1892, pp. 435 and 438 (with references); G. H. Fox's case, *Jour. Cutan. Dis.*, 1893 (with illustration), seems more probably a case of disseminated lupus, which Dr. Fox was at first inclined to believe, and which is supported by Elliot's histologic examination. The curet was used in some lesions; others disappeared spontaneously. C. J. White, *ibid.*, 1902, p. 49, reports a case, with histologic examination and cut, and concludes, from an analytical study of cases on record, that, including his own, there seem to be only 5 which can be considered genuine cases of this malady. Bossellini, (*Annales*, 1906, p. 751, 2 cases; brothers, histologic, and review, with bibliography), found the disease a degenerative process primarily, and involving the collagenous and elastic connective tissue of the subpapillary zone.

Hardaway, *ibid.*, 1884, p. 169, records 5 cases (4 children, 1 adult) of "an unusual papular eruption," in which the lesions, pseudo-vesicular in appearance, but solid in character and lemon-yellow in color, were suggestive of colloid milium, but upon puncture simply a drop of blood could be pressed out. They were not numerous, and variously seated upon the face, neck, or arms, and had been of months' duration, and some with associated itching, although slight. An ointment containing 1 dram (4.) each of ammoniated mercury and liquor picis alkalinus to the ounce (32.) of vaselin, rubbed in, proved effectual in a few weeks.

recorded, of which the first was described by Wagner. Besnier, Balzer, and Feulard have done most to give the disease the stamp of individuality.

Symptoms.—The favorite sites are the forehead, about the orbits, the nose, and cheeks—usually the upper half or two-thirds of the face. In one of Liveing's patients the neck and arms were also the seat of the growths. In Perrin's patient, in addition to the upper part of the face, some were seen on the ocular conjunctiva, near the inner canthus, and on the backs of the hands. In C. J. White's case the growths were on the backs of the hands and face. The lesions are of slow development, commonly appearing in groups of two or more, and occasionally two or three may tend to fuse together, but the individual character of such component tumors remains recognizable. In size they vary from that of a pin-head to a small split-pea, rarely larger, and while well seated in the derma show elevation, although usually slight, above the surface. They are lemon yellow or yellowish white in color, and are translucent in appearance, suggestive of a vesicular formation. They are, however, of firm consistence; if punctured or incised, only a small amount of gelatinous material and a droplet of blood can be pressed out. With some there is surrounding capillary dilatation, giving a reddish hue. There are no subjective symptoms. The malady is persistent; in only one instance—one of Liveing's cases—did the disease disappear spontaneously. In some lesions involution has been noticed, beginning in the central surface portion, giving rise to central depression, and the growths thus gradually pass away, leaving a slight depression. In one instance (Liveing) some of the growths became inflamed, crusted over, and disappeared, leaving an atrophic or scar-like mark. Jarisch[1] exhibited before the German Dermatological Society a case he thought to be an example of this disease, in which destructive action was also noticed, but the correctness of the diagnosis was questioned, and Jarisch himself has since spoken of it with implied reservation.[2]

Etiology and Pathology.—The youngest case (Liveing) of the few reported was over fifteen; the others were adults of various ages. Sex apparently has no influence. Beyond the possibility of weather exposure to which most of the patients were subjected, and precursory and associated headache or neuralgia in 2 instances being of some influence, no cause could be assigned. Wagner called the disease colloid milium, believing that it was allied to ordinary milium, and that it was a degeneration of the sebaceous gland structure. His observations were, however, purely clinical. The careful histologic studies—by Balzer of the 2 cases of Besnier and Feulard, by Reboul of Perrin's case, and by C. J. White of his case—show clearly that the disease is independent of the glands and epithelial structures, and that it is purely a degenerative process, involving the connective-tissue bundles and cells of the corium and the fibers surrounding the blood-vessels and nerves—the degenerative process changing this

[1] Jarisch, "Colloidoma ulcerosum," *Verhandl. d. V. Cong. Deutsch. dermatolog. Gesellsch.*, Vienna, 1896 (case demonstration).

[2] Jarisch, *Die Hautkrankheiten*, 1900, p. 927.

tissue into so-called colloid matter. Although Philippson has endeavored to show that the cases described variously as hydradenoma, benign cystic epithelioma, etc., and colloid degeneration are the same histologically, such a conclusion is not warranted by the investigations of the several careful observers referred to, and whose opinion is supported by Besnier,[1] who has observed examples of both affections, and who is firmly convinced of their non-identity, presenting a clear exposition of the clinical and pathologic differences.

Diagnosis.—The disease is to be distinguished from xanthoma, hydrocystoma, and benign cystic epithelioma. The soft character, non-translucent appearance, and the practical limitation to the eyelids of xanthoma will serve to prevent error with this latter disease. The distribution alone of xanthoma multiplex is essentially different. The lesions of hydrocystoma lack the yellow or yellowish color of colloid degeneration, and, moreover, contain fluid which can readily be demonstrated by pricking. Benign cystic epithelioma may show some resemblance, but the latter is usually lacking any yellowish color, generally appears early in life,—in most cases about puberty,—and is sometimes seen in more than one member of the family, and while often on the face, may be elsewhere, especially about the clavicular region and upper trunk. In some instances a histologic examination would be necessary for a positive conclusion. The color of ordinary milium, its commonly much smaller size, and its cystic character will prevent a mistake in this direction. The possibility of confusion with disseminated lupus is also to be kept in mind.

Treatment.—As the lesions show no tendency to disappearance (Liveing's 1 case an exception), their removal, if desired, must be effected by operative measures, such as the curet, as successfully employed in Feulard's patient, or by electrolysis. This latter certainly deserves a trial before other more positive procedures are adopted.

NAEVUS VASCULOSUS.

Synonyms.—Angioma; Nævus vascularis; Nævus sanguineus; Mother's mark; Birth-mark; *Fr.*, Angiome; Nævus vasculaire; *Ger.*, Angiome; Feuermal; Gefässmal.

Definition.—A congenital new growth and hypertrophy of the vascular tissues of the corium and subcutaneous tissues, of a light red to a deep bluish or purplish color, exceptionally making its appearance a few weeks or later after birth.

Various divisions of the blood-vessel growths, or angiomata, are made by different writers. Kaposi divides the cases into four classes: (1) Telangiectasis; (2) vascular nævus; (3) angio-elephantiasis (also called elephantiasis telangiectodes); (4) cavernous tumor. Unna[2] makes a complete division between certain cases, which he designates vascular moles (vascular nævi), both the flat and the elevated, from the angiomata proper, the former being histologically primary angiectases, without any capillary budding, consisting of dilatation of previously existing vessels, and predominantly of the venous capil-

[1] Besnier and Doyon, French translation of Kaposi's treatise, vol. ii., p. 370.
[2] Unna, *Histopathology*, to whose article I am indebted.

laries; angioma proper is characterized by both a new growth of capillaries, predominantly the arterial capillaries, and dilatation. The former are in some forms congenital and in others acquired, while the angiomata proper are mostly congenital, but develop materially or mainly after birth. The latter class is represented by the *angioma simplex hyperplasticum* of Virchow (or the *angioma plexiforme* of Winiwarter, or the *angioma simplex seu glomeruliforme* of Unna); and by the so-called *cavernous angioma* (angioma cavernosum), which latter, excluding those examples now believed to be partly or wholly lymphangiomatous in character, according to Winiwarter,[1] is anatomically analogous to the corpora cavernosa, and consists of soft tumors of lobular formation and semispheric or protruding surface, and of a steely-blue, rarely a reddish, color. The simple angioma consists of a variously sized, smooth, nodular or lumpy, compressible growth, of a bluish-red to a bluish-black color, and is the common angiomatous tumor (or, as more usually called, vascular nævus, capillary nævus), noticed in infants chiefly about the head. As representing the *angiectases* may be mentioned the telangiectases, consisting of capillary dilatation, so common about the nose in acne rosacea; the papillary capillary varices of old people, seen chiefly on the trunk, the vascular nævi proper, of which an example is the so-called port-wine mark, and finally the varicosities and cavernous changes observed in the veins of the lower part of the legs.

While these various distinctions and divisions are more scientifically exact, to the clinician a description of the various conditions under the two headings adopted by Duhring, Crocker, Hardaway, and others—nævus vasculosus and telangiectasis—seems more satisfactory and sufficiently comprehensive, and is the plan here followed, the former including the congenital vascular new growths and all tumor-like formations, and the latter the acquired capillary dilatations, with which may also be included the others of Unna's angiectases, excepting the vascular nævi proper.

Symptoms.—One of the most common forms of the vascular nævi encountered is that known as angioma simplex, angioma simplex hyperplasticum, capillary nævus, etc., already briefly referred to, consisting of red to bluish or purplish red, slightly to considerably elevated, usually readily compressible, growths observed in young infants. The surface is either smooth, irregular, lumpy, or nodular; it may be smooth at first, and then become subsequently uneven. It is of congenital origin, although not infrequently at birth it is quite insignificant, and sometimes scarcely perceptible, increasing rapidly in size in the first days or weeks of life. It is most frequently seen about the head, either upon the scalp or face, although it may also occur elsewhere. It is variable as to size—from that of a bean to an area as large as the palm or greater. It remains stationary or increases in extent, but usually, after reaching variable dimensions, ceases to grow. In some instances, after a time,—several months or longer,—retrogression takes place, the nævus becomes gradually smaller, and finally disappears without trace or leaving a slightly

[1] Winiwarter, *Die chirurgischen Krankheiten der Haut*, 1892, p. 534.

thinned looking or atrophic patch. In others the growth is, unless treated, persistent. Anything that disturbs or impedes the circulation of the part, as coughing, crying, position (gravity), leads to temporary increased prominence. As a rule, it is somewhat spongy to the touch, usually, however, quite soft and readily compressible; in other cases comparatively firm. In exceptional instances, more especially when involving a greater part of a region, as the ear or extremity, a firm spongy character is noticed, connective-tissue increase being equally present and of pronounced character,—the so-called *angio-elephantiasis*, *elephantiasis telangiectodes*, etc.,—in which, doubtless, too, in some cases at least, there is also lymphangiomatous development (see also elephantiasis). Occasionally the surface is accidentally broken, or this takes place spontaneously, and some hemorrhage results, sometimes of an apparently dangerous character. Occasionally sloughing gradually ensues, limiting itself to the nævus area, and this leads to cure, with slight scarring. If the growth is a pronounced one, and especially when over bony prominences, pulsation can usually be felt.

In occasional instances a nævus may undergo cystic or cavernous changes, and it has been stated that it may possibly develop into the **angioma cavernosum** of Winiwarter. This latter, a rare formation, is, however, usually, and probably always, primary, arising commonly in the first year of life, and in most instances having its start in a trauma, even of a mild or insignificant character. Rarely it is congenital. It may be diffused or defined, soft, lobulated, protruding, or hemispheric, sometimes distinctly encapsulated. It is turgescent, often quite painful, and tends to increase in size, in exceptional instances invading soft tissues, cartilage, and even bone.

A form of nævus which is occasionally congenital, but usually acquired, and therefore to be more especially referred to under telangiectasis (*q. v.*), is that known as **nævus araneus,** or **spider nævus,** consisting of a red dot or spot with radiating red lines. A well-known, but fortunately not very common, form of nævus is that known as the **port-wine mark, port-wine stain, claret stain, birth-mark, nævus flammeus, nævus simplex** (**Feuermal** of the Germans, and **tache de feu** of the French). The terms angioma and angioma simplex are likewise occasionally used to designate it. It is congenital, although in some instances there is variable increase after birth. In size it varies from that of a small, insignificant spot to several inches or more in diameter; and exceptionally it may involve a whole region. The face is its common site. It is rounded, ovalish, or irregular in shape, of a bright or dark-red color, usually flattened, and often not perceptibly elevated. It may, however, be raised above the surface, and present a smooth, uneven, nodular surface, and sometimes with here and there verrucous-like thickening or projections. Between this type and that first described, angioma simplex or capillary nævus, all gradations are met with.

To these several forms of nævi other terms are sometimes given, when additional peculiarities or properties are present or associated. Thus in some instances pulsations are quite distinct, and hence the term *pulsating nævus;* in others the color is dark, the blood-vessel

growth deep seated and chiefly venous,—*venous nævus, angioma varicosum*,—the surface is predominantly rough and tubercular,—*nævus tuberosus*,—slightly fungoidal or mulberry-like in appearance,—*mulberry nævus, strawberry-mark* (the latter also used with flat forms of strawberry color),—and so on. Not only, however, may a nævus be turgescent and pulsating, but it may exceptionally be erectile, and rarely there is also more or less hairy growth noticeable. In fact any or all constituents of the integument may be participants along with the blood-vessel dilatation and new growth.

As a rule but one nævus is present in a case, but occasionally there may be two or three, and exceptionally, as in the remarkable instances recorded by Ullmann,[1] Kopp,[2] Pollitzer,[3] and Post,[4] they may be numerous and of wide distribution, those of the first two presenting some characters of telangiectases. Besnier and Doyon[5] are of the opinion that generalized angiomatous or telangiectatic lesions are the forerunners or first signs of malignant development, probably based upon the significance of the early telangiectases observed in xeroderma pigmentosum.

Etiology and Pathology.—The cause of these blemishes is not known. According to Gessler's[6] study of 1265 collated cases, the affection is doubly as frequent in females as in males. Various factors have been suggested, among which, more especially, are maternal impressions and intra-uterine pressure, but neither will bear the scrutiny of searching analysis, although as to the influence of maternal impressions during pregnancy various striking instances are recorded, but even in such the chances of pure coincidence or misinterpretation are so great as to throw doubt upon relationship. Unna (*loc. cit.*) is a strong advocate of the pressure theory, stating that "the almost entire limitation of the congenital angiomata to the superficial layers would seem to point out that they are developed by the action of some external cause." His clinical observations concerning this point have, he adds, shown him that these growths are practically always on regions which are most likely to suffer from pressure during intra-uterine life; and in support of this he states that "an extraordinary percentage (10 to 20 per cent.) of individuals have a nævus in the neighborhood of the occipital fontanel, hidden by the hair, though often only traces of it are to be found in adults." Out of 114 new-born infants examined by Pollitzer[7] for the purpose

[1] Ullmann, *Archiv*, 1896, vol. xxxv., p. 195 (with case illustrations and histologic cut; patient, a woman of forty-four; numerous bluish-red, small pea- to small hazel-nut-sized growths on the face, coming out crop-like at irregular intervals; began apparently as telangiectases; first appearance when verging on forty years).

[2] Kopp, *ibid.*, 1897, vol. xxxviii., p. 69 (patient a young man aged nineteen; numerous flat and nodular compressible lesions about genitalia and legs, and also appearing on trunk and upper extremities; to some extent, especially in the flat lesions, of the nature of telangiectases, and tending to bleed easily; began about puberty).

[3] Pollitzer, *Internat. Atlas*, 1899, plate xlii. (patient, male aged twenty-five; noticed a few weeks after birth, and no change since; numerous, closely contiguous nævi, averaging the size of a dime, over the entire surface, except head, palms, and soles).

[4] Post, *Jour. Cutan. Dis.*, 1903, p. 498 (with illustration).

[5] Besnier and Doyon, French translation of Kaposi's treatise, second edit., p. 357.

[6] Gessler, Inaug. Dissertation, Tübingen, 1889, brief abs. in *Monatshefte*, vol. x., 1890, p. 241.

[7] Pollitzer, *Bangs-Hardaway's American Text-book*, p. 1009.

of investigation of this point, 40, or 35 per cent., had nævi in this region. These observations are more or less confirmatory of Depaul's[1] statement, which has always seemed open to question, that nævi were found in about one-third of the children born at the Paris Clinique, in most of them, however, disappearing within a month. Gessler's analysis shows 76 per cent. about the head, 3 per cent. on the neck, 11 per cent. on the trunk, and 9 per cent. on the extremities. It is not improbable, therefore, that pressure may be an important factor, but it would seem that Virchow's belief, quoted by Unna (whose words I repeat), is more probably the more influential one. "Virchow was the first to indicate a possible anatomical cause, namely a connection of the embryonic fissures of the skin, especially the branchial fissures, with the appearance of angiomata at their areas of predilection (eyelids, cheeks, ears, nose, lips), which he names the 'fissural angiomata'; and, according to him, 'a very slight irritative condition at the borders of these fissures, which are very abundantly supplied with vessels, is sufficient to induce a greater vascular development, which might possibly be recognized as a nævus, but which remains latent and only later becomes manifest.'"

Anatomically vascular nævi have their seat principally in the papillary layers of the corium. In some instances, however, the whole corium as well as the hypoderm are involved. According to Billroth,[2] the new formation starts first from the capillary plexuses of the hair-follicles, the sweat-glands, the sebaceous glands, or the fat-lobules. The growth consists, according to its nature and development, of dilated as well as newly formed blood-vessels, which may be but slightly, moderately, or markedly dilated and abundant, in extreme instances reaching pouch-like or cavernous distention and sinuses; in some lesions the process is chiefly or wholly limited to the arterial capillaries, while in others (venous nævi) the veins are predominantly implicated. Babes states that "in many cases, however, the newly formed vessels correspond neither to veins nor to capillaries, and form manifold convolutions and networks." In addition to the vascular dilatation and new growth, the connective tissue, especially about the vessels, may be increased slightly or considerably; in some instances, in fact, all tissues may participate. The cavernous variety, as already remarked, according to Winiwarter, bears some resemblance to the cavernous tissue of the penis.

Diagnosis and Prognosis.—These formations offer no difficulty as to recognition—they could scarcely be confused with other lesions. The prognosis as to effect upon health or life is, of course, wholly favorable, although exceptionally dangerous hemorrhage has been noted in the elevated, growing capillary nævi in infants, but a fatal outcome would certainly be a great rarity; in these instances, very usually from the pressure immediately made and the clotting which ensues, retrogressive tendency is shown and the lesion may gradually disappear. In an instance under my casual observation (not under my care), involving the ear in an adult, which began in early life, there has been a gradual aneurysm-like distention in late

[1] Depaul, quoted by Crocker, *Diseases of the Skin*, third edit., p. 962.
[2] Billroth, quoted by Babes, *Ziemssen's Handbook of Skin Diseases*, p. 601.

years, which, from its threateningly dangerous character, has required surgical attention, the chief supplying arteries being cut down upon and tied; temporary improvement resulted, but the vascular dilatation, growth, distention, and tissue thinning soon presented again, and a third operation, of tying the main truncal artery, has recently been resorted to. In some cases of capillary nævus, as already stated in describing it, there is not infrequently a tendency, after a time, to undergo involution and to disappear, leaving a faint atrophy or no trace at all; and this tendency is sometimes apparently started by a slight knock or injury to the part or attempts at treatment. Occasionally superficial ulceration ensues, and this is usually the beginning of a spontaneous cure; the possibility of hemorrhage is to be kept in view, but while this is sometimes temporarily alarming, it is rarely dangerous. The firm, slightly elevated growth and the various grades of the port-wine mark, as well as the larger cavernous nævi, are persistent, although they seldom show any disposition to increase. In the smaller capillary nævi and in the other circumscribed forms much can usually be accomplished by treatment, and frequently a cure be brought about; but in the large growths and in the port-wine varieties, not much is to be expected.

Treatment.—The cases most commonly coming under dermatologic observation are those known as angioma simplex, or capillary nævus, and the so-called port-wine mark; the former being that type brought for treatment during the first weeks or months of infantile life, either because it is growing larger or simply as a blemish desirable to be removed. In this type the most satisfactory methods seem to me to be those of pressure, electrolysis, and puncturing with a needle or sharpened stick charged with nitric acid. There can be no doubt that in some of the cases but a slight impetus is needed to start the process of involution and gradual disappearance, and, therefore, unless the child has passed the age of one or two months, the mild plan should always be tried. The simplest, and probably the best, of these to begin with is that first named—pressure. This is effected by repeated and thick paintings with collodion, continued for some days or a few weeks or longer. This pressure method can also be combined with discrete puncturing, the latter being done in several places over the growth, $\frac{1}{8}$ to $\frac{1}{4}$ inch apart, with an ordinary needle, or, better, triangular-edged needle, slightly breaking up the tissues within, and then, with due aseptic precaution, immediately applying the several coatings of collodion. The "electric needle" can also be used in the same manner in conjunction with pressure. The slight local disturbance so caused gives rise, when pressure is continuously exerted, to more or less plastic exudation and agglutination and gradual obliteration of the growth.

In many cases, however, the pressure plan, as thus outlined, is not successful, and when the child has already passed the second or third month, the growth seems to have become permanently established, losing, as a rule, the disposition, often noticed earlier, to spontaneous or easily provoked disappearance, and more energetic measures are necessary, and which are also applicable at an earlier date when thought preferable to the pressure plan. The two methods I

have employed are those of electrolysis and punctures by a needle charged with nitric acid. Electrolysis, a method which has been favorably used by many, and strongly advocated by Hardaway, Duhring, Beard, Fox, and others, answers well in some instances, as I also can testify; it occasionally brings about a rapid result. As a rule, it is tedious, and must often be repeated, at intervals, several or more times. It is usually quite painful. In the smaller growths a current of from 1 to 3 or 4 milliampères is sufficient, but in the larger and more pronounced formations a stronger current may be necessary. In the former cases, and if the child is quite young and can be easily and firmly held, an anesthetic is not necessary, but in older children and in extensive growths electrolysis, owing to the pain of the operation, cannot be satisfactorily managed without anesthesia. The needle, ordinarily in my practice, is attached to the negative electrode, although others prefer the positive as more likely to bring about coagulation, and I am not yet convinced which is the better plan; the other electrode with wet sponge or cotton covering can be applied nearby, as on the hand or arm. In all electrolysis operations about the head, especially the upper part, the current should be increased gradually, and also broken off slowly, in order to avoid dizziness and other disagreeable effects. When possible, needles can be attached to both electrodes and inserted in the nævus. If attached to the positive electrode, the needle should be of gold or iridoplatinum, as a steel one undergoes oxidation (see hypertrichosis). Some are in the habit of coating the needle with rubber or other insulating substance, such as shellac, up to within $\frac{1}{8}$ of an inch of the point, in order to prevent action on the skin at the point of entrance. The needle is inserted into the growth, preferably somewhat slantingly, and down to the base, the current then allowed to act for one-half to two or three minutes; it is then withdrawn and reintroduced at another part, and so the nævus gone over, the punctures being $\frac{1}{8}$ to $\frac{1}{4}$ inch apart. They should not be made too close, lest too much destructive action ensue. If the growth is small, the needle can be introduced at the center, going slantingly toward the side, allowed to act, then almost completely withdrawn, and then thrust in another direction, after the manner of the "Marshall-Hall method," and so on. In some instances more influence is noted to result from the introduction of the needle just at or outside of the edge of the growth, and thus going completely around it at $\frac{1}{8}$ to $\frac{1}{4}$ inch intervals, encompassing the growth in this manner with the idea of cutting over the basal vascular supply. In the larger growths treated by electrolysis under anesthesia several needles can be attached to the electrode and inserted at different points of the nævus. I have always preferred to do too little than too much at one time, and then to repeat the treatment at intervals of one to three weeks; in this way there is less risk of unnecessary destruction, and, moreover, in occasional instances a trifling amount of such treatment will start involution changes in the growth. When, in the cases stated, anesthesia is necessary, as much as possible should, of course, be done at the one time. The application of pressure for several hours or more after the treatment is, I believe, of considerable value in aiding toward a good result.

Instead of electrolysis, or conjointly with it, punctures with a needle dipped in nitric acid can be employed; or the hard, smooth, sharp-pointed wooden tooth-picks can also be used for this purpose. The needle or tooth-pick is merely moistened with acid, and then gently and slowly pressed into the growth from above, and the nævus thus gone over, punctures being made about the same distance apart as in electrolysis. As with this latter, frequent repetitions are sometimes necessary, and subsequent pressure is of material advantage.

Other methods of treating these and similar nævi are variously advocated, such as vaccination of the part, painting over with nitric acid (Duhring, Crocker) or acid nitrate of mercury, application of sodium ethylate, made by adding sodium to absolute alcohol (Richardson),[1] caustic potash solution, 10 to 50 per cent. strength, cautiously used (Duhring), the "Marshall-Hall method,"[2] and the application of the high-frequency current by means of the carbon-pointed electrode (Bulkley).[3]

The removal of the so-called port-wine mark has been essayed from time to time, and when the blemish is of small compass, much can be done, but if at all of extensive area, the outlook is unpromising, and usually the effort inadvisable. For the treatment of this blemish the various plans already noted, except that of pressure alone, which would be without influence, have been employed, in limited cases, with varying results, but unless sufficiently thoroughly to produce scarring, sometimes more disfiguring than the original blemish, the amelioration or relief, as a rule, scarcely justifies the trial. An exception to this, however, may possibly be made in favor of the method by electrolysis as suggested and practised by Hardaway,[4] and also favorably spoken of by Piffard, G. H. Fox, and others, by which often a distinct lessening, exceptionally almost complete obliteration, in the depth of the color is attained. At first this writer advised the employment of a bunch of needles for this purpose, but later, owing to the occasional production of suppuration and of keloidal scarring, has expressed his opinion in favor of a single needle as being more manageable, although necessarily rendering the method much more tedious. Hardaway is conservative as regards the value of the method, admitting its frequent absolute failure, and, at the most, with rare exceptions, only amelioration, but, all things considered, believes it the best for the purpose. This has likewise been my experience—occasional partial and fairly satisfactory success, but usually scarcely sufficient amelioration to compensate for the trouble, so that in extensive cases I should hesitate to advise it, certainly not

[1] Richardson, "On the Remedial Application of Ethylate of Sodium and Potassium, or Caustic Alcohols," *Lancet*, 1878, vol. ii., p. 654 (the preparation should be fresh and kept in a cool place; it is applied with a glass rod, and the crust formed allowed to come off spontaneously).

[2] The Marshall-Hall method consists in thus radiating the growth with a cataract needle, without electrolysis; the needle is, however, thrust in at the edge of the growth, and not at the center. It is sometimes efficient.

[3] Bulkley, *Amer. Med.*, Nov. 29, 1904, p. 882.

[4] Hardaway, *St. Louis Courier of Medicine*, vol. xv., 1886, p. 201, and *Trans. Amer. Derm. Assoc.*, 1885, p. 18 (with discussion); also Morrow's *System*, vol. iii. (Dermatology), p. 498.

without a clear and candid statement to the patient as to its tediousness and chances of failure and partial success. Squire's[1] plan of treatment, by oblique cross-cut incisions, and Sherwell's[2] method, by punctures with the multiple needle charged with carbolic acid, or a solution of chromic acid, have not met expectations. Sherwell has practically abandoned his for electrolysis.

Among other plans of treatment of some of the varieties already mentioned, as well as the deeper and more pronounced growths, may be mentioned those by excision and galvanocautery, both of which have been employed successfully in some instances. In a few rebellious cases I have had recourse to puncturing with the galvanocautery needle, combined with pressure, and found the plan of service. Well-defined circumscribed growths could, as often practised by surgeons, be excised. In larger nævi, excision, if practised, needs to be supplemented by the Thiersch method of skin-grafting. The plan formerly much in vogue, of injecting irritating liquids into the growth, needs to be mentioned only to be condemned. Recently good results have been claimed from X-ray exposures, pushed to the point of a moderate dermatitis. The high-frequency current, with the point electrode, is also capable of lessening the port-wine blemish, but not without some scarring.

TELANGIECTASIS.

Synonyms.—Acquired vascular dilatations ; *Fr.*, Télangiectasie.

Definition.—An enlargement, and probably new growth as well, of the cutaneous capillaries, usually appearing during middle life, and seated, for the most part, about the face.

Symptoms.—Dilatations or new formation of capillary vessels are not at all uncommon in association with certain diseases, such as acne rosacea, sometimes constituting the predominant or whole feature of the case, and then usually designated *rosacea*. They are also seen in association with angiokeratoma, xeroderma pigmentosum, some cases of lupus, syphilis, lupus erythematosus, and similar disorders, in which a prolonged, persistent hyperemia has existed. Telangiectases occur, however, as an entirely independent affection, and most commonly about the cheeks and alæ of nose, especially in individuals in middle and advanced life, and more particularly in those of plethoric habit, or in those who naturally, or through diet, indigestion, and alcoholic stimulants (not necessarily in excess), are subject to repeated facial flushings. They are, probably, as an independent condition, most common or numerous in the middle region of the cheek, which Hutchinson calls the flush-patch. They are noted to be straight, zig-zag, or tortuous, thread-like, red lines, $\frac{1}{8}$ to $\frac{1}{4}$ of an inch long, sometimes branching, in others being simply irregularly crowded together. In some cases the dilatations may be much more pronounced and slightly elevated. The condition may merely consist of several such dilated capillaries, or they may be so numer-

[1] Squire, *Brit. Med. Jour.*, 1879, ii., p. 732 ; and, *On Port-wine Mark and its Obliteration without Scar*, London, 1880.

[2] Sherwell, "Tattooing of Nævi," *Arch. Derm.*, 1877, p. 214, and second paper, *ibid.*, 1879, p. 354.

ous as to give the face or part affected a distinctly rosaceous or flushed appearance, due to some of the causes named, and occasionally, especially when about the region of the nose, also to possible vascular obstruction due to intranasal pressure (see acne rosacea). In some cases, instead of distinctly visible capillaries, it consists of a pinkish or reddish spot, which only on close inspection discloses the fact that it is composed of numerous minute capillaries. While its usual site is the face, exceptionally the development is seen on other parts.

In some instances, and in infants and children, as well as in adults, a not uncommon form, which is usually acquired, although it is occasionally congenital, is that known as **nævus araneus,** or **spider nævus** (also spider cancer). It consists of a pin-head- to small pea-sized central red spot or dot, flattened or slightly elevated or rounded, from which radiate several or more red lines (capillaries), in a more or less straight, irregular, or tortuous manner, extending one to several lines outward. It presents, first, as a scarcely noticeable formation, and gradually becomes more conspicuous, but rarely attains more than small dimensions. After lasting for some months or several years or longer such a blemish sometimes spontaneously disappears; in other instances,—and in the large majority,—however, persisting indefinitely, and may undergo further enlargement, although seldom to a conspicuous extent. One or several such formations may be present, and usually about the nose and the region under the eyes. In a few rare exceptions, as in instances observed by Mandelbaum[1] and Crocker,[2] they were quite numerous and more or less general. Hillairet and Vidal[3] have also each observed an instance of more or less generalization. In the anomalous cases of multiple vascular nævus recorded by Ullmann and Kopp, referred to under the latter heading, the telangiectases, primarily of the striated, stellate, or spider-nævus characters, underwent development, and changed into small, vascular, tumor-like growths. Vidal's case, according to Kopp, was partly of this character, bearing resemblance to his own.

The **papillary varices,** usually involving the capillary loops of a number of contiguous papillæ, consist of pin-head- to small pea-sized, pale to dark or purplish red, flattened or rounded elevations. They are commonly seen on the trunk, especially the upper part, and usually in adult life, more particularly in those of middle age or advanced years, and are suggestive of blood extravasation and the so-called blood-blister. They are frequently moderately soft and somewhat compressible, with, as a rule, no striæ peripherally, as in

[1] Mandelbaum, *Archiv*, 1882, p. 213 (face, trunk, and limbs).

[2] Crocker, *Diseases of the Skin*, third edit., p. 967 (face, backs of the hands, and forearms).

[3] Hillairet and Vidal, quoted by Hyde and Montgomery, fifth edit., p. 590 (I have not been able to find the originals); Malcolm Morris, *Brit. Jour. Derm.*, 1896, p. 222 (Society trans.), exhibited a case of a woman, aged thirty, with "an unusual variety of angioma" on both legs, symmetrically about the ankles, extending upward $4\frac{1}{2}$ inches, and down to the instep, "with a general uniform redness as a groundwork, and on this vessels radiating from three distinct centers, with, scattered in the general redness, small, oval, white patches (no scarring); the redness (according to the patient) first appeared in three or four small patches on the outer side of each ankle when she was eighteen, and gradually spread and joined."

the spider nævus. Some of them, on close inspection, are noted to be composed of a tuft of dilated capillaries, and which can be emptied by pressure; others are somewhat hard, probably due to the conditions sometimes found, as described by Unna: minute cavities or spaces inclosing blood capillaries; a number of minute spaces filled with thrombi; and, in another instance, coagulation, the thrombi consisting of fibrin and a few leukocytes; and also, in some of them, in addition "the remaining space filled by closely packed red corpuscles." In such instance the blood-lesion is more solid and pressure makes but little impression.

The *varicosities* and cavernous changes so commonly observed in the veins (*varicose veins*) of the lower part of the leg, especially in those of middle life and advancing years, and probably more frequently in women who have borne many children, need scarcely be referred to here, belonging more properly to the domain of surgery. It is to be looked upon, however, in some instances as having an etiologic bearing upon the production of eczema of these parts, and also to impaired tissue nutrition which results in ulceration—the well-known leg ulcer.

Treatment.—The treatment of the ordinarily observed telangiectases, such as observed upon the face and in association with acne rosacea, is purely operative, the best method consisting in their destruction by the electric-needle process (electrolysis), as suggested by Hardaway, for the particulars of which the reader is referred to the treatment of acne rosacea. Incision at several points across their length, or a longitudinal cut with the ordinary bistoury, as likewise mentioned in connection with the latter disease, is also practised; and when the dilatations are numerous and crowded together, superficial linear scarification, after the plan referred to in lupus vulgaris, has also been advised. I have never had recourse to other treatment than electrolysis. It must often be repeated, however, nor does it prevent the formation of new dilatations, as long as the underlying etiologic factor, commonly unknown, continues in force. In the so-called spider nævus, introducing the electric needle in the central dot superficially, and allowing the current ($\frac{1}{2}$ to 1 or 2 milliampères) to act for five to thirty seconds, often leads to its disappearance; occasionally one or two repetitions may be necessary, probably from too weak a current or of too short duration originally, but it is better to err on the side of safety and thus avoid a scar, although minute and insignificant. These spider nævi can also usually be destroyed by puncturing with a plain needle, stirring it slightly around, but not so surely as with the electric needle. The papillary varices rarely call for treatment, the same plan, but a stronger current, usually sufficing when measures are demanded.

For the treatment of varicose veins the reader is referred to surgical works. As a palliative measure, to be employed when associated with eczema, the roller bandage, to give support to the parts, can be used. The rubber bandage may also occasionally be resorted to, but should not be applied to the uncovered skin, as it often itself produces eczematous irritation; the part should first be wrapped with a thin roller bandage, or a long, snugly fitting stocking put on.

ANGIOMA SERPIGINOSUM.[1]

Synonyms.—Infective angioma or nævus lupus (Hutchinson); Sarcome angioplastique réticulé (Darier).

Symptoms.—The seat of this rare malady has varied in the different cases reported. In the original case reported by Hutchinson, and also that described by Jamieson, the back of the arm was the beginning site, from which it gradually extended downward, passing beyond the elbow and upward to the shoulder, Jamieson's extending chiefly downward to the base of the thumb. In the latter, too, there were some lesions on the side of the chest on a line with the fifth rib. Tay's case started on the right calf, finally involving both legs; Lassar's originated on the cheeks, appearing later on the ears, and also downward on the right side on the arm. In White's patient the disease first appeared below the right scapula, and gradually extended anteriorly toward the nipple; in Crocker's patient it was on the forehead and cheek. The malady is insidious and slow, beginning usually early in life, and as minute, firmly seated, pin-point- to pin-head-sized, elevated, bright red to dull red or purplish points or papules. Gradually the lesions increase in size, and when about the size of a pea usually tend to undergo centrally involution changes, while still extending peripherally, so that an annular or circinate configuration is assumed, and which, if coalescing, form irregular serpiginous figures. During this time new papules—infective satellites, as Hutchinson aptly designates them—are forming beyond the main area, and these in turn undergo central absorption and spread in an annular manner, fusing with other rings. The malady is steadily progressive, although exceedingly slow, and probably with periods of at least relative quiescence. No positive atrophic changes ensue, the central involuting portion usually merely showing some discoloration. As a rule there are no subjective symptoms, although in White's case slight itching and tenderness on pressure were present.

Etiology and Pathology.—Of the 7 cases now on record, 5 began in the first two years; 5 were females. Apparently there is no assignable cause, although in 2 instances (Hutchinson, Hyde and Montgomery) there seems to have been a preexisting nævus. The pathologic histology has been studied by Bowen, Darier, and Councilman—all from tissue of the same (White's) case. According to Bowen,[2] who had also observed White's case clinically, the microscopic findings by Darier and Councilman practically agree with his, and are indicative of an angiosarcomatous character. The process seems to begin, quoting from Bowen, by a proliferation of the endo-

[1] Literature: Hutchinson, *Arch. of Surg.*, 1889–90, vol. i., p. 289, with colored plate; *ibid.*, 1890–91, vol. ii., p. 71 (Jamieson's case); *ibid.*, p. 111 (Lassar's case); *ibid.*, 1891–92, vol. iii., p. 166 (Waren Tay's case); J. C. White, *Jour. Cutan. Dis.*, 1894, p. 505 (report of a case, male, aged twelve, with illustration and excellent histologic cuts, including reports on pathology by Darier, Councilman, and Bowen); Crocker, *Brit. Jour. Derm.*, 1894, p. 367 (case demonstration—woman, aged twenty-eight, with 3 or 4 rings on forehead, 1 on cheek, of two months' duration; one on cheek, developed two years previously, had almost disappeared, leaving a slight whitening of the surface); Hyde and Montgomery, *Diseases of the Skin*, seventh edit., p. 644 (brief reference—female infant, developing as a sequence of congenital nævus of the vulva).

[2] Bowen, *Twentieth Century Practice*, vol. v. (Diseases of the Skin), p. 680.

thelium of the vessels, accompanied by a corresponding proliferation of the perithelium. The epidermis and the papillary layer were filled with longitudinally shaped, ribbon-like masses of cells, extending in their general arrangement parallel to the surface. The cells had large oval nuclei, with a slight amount of surrounding protoplasm, and the groups or clumps, concentrically arranged, usually presented a central lumen, indicating their intimate connection with the vessels. Here and there, in the groups, granular masses resulting from cell degeneration were observed. Histologically the growth was comparable to angiosarcoma, and Bowen is inclined to regard it as due to some anomalous congenital condition of the vessels. Darier looks upon it as an anomalous type of sarcoma, of a disseminated, reticulated form, developing along the vessels, with a tendency here and there toward true angiomatous characters. These findings would seem to indicate, as Bowen states, the possibility of later malignant changes.

Prognosis and Treatment.—The malady is persistent and progressive, and in the cases in which the growths were destroyed by cauterization (Hutchinson, White) and excision, new lesions appeared peripherally or in the resulting scar tissue. Possibly electrolysis along the borders of the area, as Crocker suggests, with the object of causing occlusion of the vessels, might stay its progress, but the failure of the more active methods already tried would scarcely lend much hope to this plan.

FIBROMA.

Synonyms.—Molluscum simplex; Molluscum fibrosum; Fibroma molluscum; Molluscum pendulum; Molluscum non-contagiosum; *Fr.*, Fibrome; Nævus molluscoïde; Molluscum vrai; *Ger.*, Fibrom.

Definition.—Fibroma is a connective-tissue new growth, appearing as one or more sessile or pedunculated, pea- to egg-sized or larger, soft or firm, rounded, sometimes flattened, painless tumors, seated beneath and in the skin.

Symptoms.—The tumors appearing in this disease show variations as to size, shape, and numbers. There may be but a single growth, or they may be numerous. Occurring as a single tumor, which is the more common, it is usually more or less pedunculated, and, when reaching any great size,—and it quite frequently attains considerable dimensions,—it becomes pendulous (fibroma pendulum). In the multiple cases the growths may be somewhat scanty in number, or may exist in great profusion, as in the instances observed by Octerlony,[1] Hewson, and others; in extreme examples they may be present in such abundance as to crowd the surface, as in the case reported by Dunn.[2] In these extensive cases the growths vary from a pea to an egg or larger, and may be almost all more or less rounded and sessile, although usually some show a trifling or moderate tendency to narrowing at the base, giving the tumors a pear shape, and

[1] Octerlony. *Arch. Derm.*, 1875, p. 300, having 2333 growths (with illustrations); Wigglesworth, in the same journal for 1876, p. 193, also records a similar case (with illustration), having 1193 tumors; Hashimoto, *Sei-I-Kwai Med. Jour.*, Dec., 1888, p. 197 (with illustration), described a case with 4503 growths; Pooley, *Jour. Cutan. Dis.*, 1894, p. 117, has also published an extensive case (with illustrations).

[2] Dunn, *Med. Press and Circular*, 1890, p. 623 (with good illustrations); a plate of this remarkable case, credited to Hutchinson, will also be found in Morrow's *System*, vol. iii. (Dermatology), op. p. 478.

such, when the narrowing is at all marked and the growths moderately large, are generally slightly pendulous. Others may be sausage-shaped, and exceptionally show a tendency to lobulation. In other cases the tumors will be, for the most part, as just described; but one or several extremely large pedunculated growths (fibroma pendulum) will be present, with a comparative small pedicle and a variously sized, pear-shaped, often somewhat flattened, pendulous mass, which hangs down and often covers up some of the smaller tumors. In these general cases the upper part of the back seems to be a favorite region for the pendulous growth, as in Tappey's and Iurkewicz's [1] patients. The smallest tumors project but slightly, in some instances appearing to be practically subcutaneous, although in other cases they are intimately associated with the skin proper and are more elevated. In the moderate and larger sized growths the elevation is conspicuous, and when narrowing of the base is present, they are essentially situated wholly above the surrounding level.

The skin over the tumors is generally normal, but it may be tense or lax, and of a natural pinkish or reddish color. The reddish color is

FIG. 138.—Fibroma (front and back view of the same patient) (courtesy of Dr. Addinell Hewson).

generally seen in those growths which develop rapidly, the slowly growing tumors—the usual course—remaining more or less normally colored. In some tumors, more especially those of larger size, the openings of the sebaceous glands are enlarged and hypertrophied, and sometimes contain blocked-up secretion or plugs. In other instances, usually in those lesions in which the skin is tense and distended, the follicles may be atrophied and the integument somewhat thinned. To the touch they usually feel soft or doughy and slightly elastic, and

[1] Tappey, *Jour. Cutan. Dis.*, 1889, p. 179 (with illustration); Iurkewicz, *Meditzinskoïe Obozreniё*, No. 21, 1891, p. 738 (with drawing)—abs. in *Brit. Jour. Derm.*, 1891, p. 367.

are painless. They do not undergo destructive change, although with the heavy, pendulous formations, as a result of weight or pressure, surface abrasion and ulceration may occur; and when crowded together, owing to their number, size, and location, as a result of interference with motion or by accidental injury, the larger growths may occasionally become inflamed, and exceptionally undergo ulceration and even become gangrenous. In some of the rapidly developing tumors the skin, which becomes red and vascular, may later become excoriated and even ulcerated. Gangrenous destruction also occasionally occurs in the growths with extremely thin pedicle. Ordinarily, however, such accidents do not occur, and except for the disfigurement and discomfort of their presence, they give rise to no serious condition. In the course of time, but usually slowly, some lesions continue to increase in size, new ones may arise, while others, having obtained variable dimensions from small to large, remain more or less stationary, so that there are usually to be seen, in a given case, tumors of all sizes from that scarcely larger than a pin-head or small pea to that of considerable proportions; the latter, especially the large pendulous tumors, sometimes reaching huge size, and weighing many pounds. The greatest size and weight are observed in the single fibroma, although in the multiple cases sometimes one or two tumors also attain enormous development.

Occasionally the tumor growths are ill defined, consisting of irregular and nodular, confluent, wrinkled, and fold-like masses, and when such formations are numerous and of gigantic size, they give the patient in regions an elephantine appearance—the extreme development, which seems really a combination of fibroma, elephantiasis, and dermatolysis, giving rise to the appellation "elephant man."[1] In this instance there were also some exostoses. Occasionally a growth, usually those of moderate size, undergoes partial involution or absorption of the interior portion, and hangs like a flaccid, partly filled pouch or sac. This absorption exceptionally takes place in the large pedunculated or sessile growths, and when more or less complete, results in a soft mass of pendant, variously hypertrophied skin—dermatolysis (*q. v.*). This same change is also at times noted in the small pea-sized, isolated fibromata, and fleshy moles, soft warts, or solid, warty-looking growths, in the skin of those advancing in years (see atrophia senilis), which are often pedunculated, and which result in small, pendulous sacs; to these the name of fibroma simplex, or *acrochordon*, is sometimes given, although the term fibroma, when employed, usually refers to the more pretentious growths, which have been described, but which, as remarked, may undergo similar involutionary changes.[2] Occasionally, in a pea- to cherry-sized growth, more especially the smaller, when such absorption or involutionary change takes place, there remains a slight projection, seemingly hollow and readily compressible, and sometimes of a bluish tinge.

In some instances neurofibromata have coexisted, as in the cases

[1] Editorial report of an extreme example in *Brit. Med. Jour.*, 1886, ii., p. 1188 (with illustrations); an abbreviated account, with illustrations, also in *Jour. Cutan. Dis.*, 1887, p. 110.

[2] See Taylor's paper, "Molluscum fibrosum and its Relation to Acrochordon and other Cutaneous Outshoots," *Jour. Cutan. Dis.*, 1887, p. 41; and to "Keloid," *ibid.*, p. 161.

recorded by Atkinson,[1] von Recklinghausen,[2] Payne,[3] Brigidi,[4] Briquet,[5] and others.[6] In some cases, as Recklinghausen and some others believe, the lesions are doubtless all neurofibromata (Recklinghausen's disease, neurofibromatosis). Other lesions sometimes associated are brownish, pigmentary stains, sometimes freckle like, small or large areas, and occasionally more or less diffused discoloration. While, as Wickham[7] states, some authors touch upon this feature, present in many cases, by others it is entirely ignored. In Wickham's 8 generalized cases such pigmentary conditions were present in all; and in addition there were small, violaceous, compressible prominences, already noted, but which Wickham apparently considers arise as such, and not necessarily as a result of involutionary changes.

Any part of the surface may be the seat of fibromata, but, as a rule, the tumors are most numerous and largest on the trunk, both front and back. The scalp[8] and other parts of the head are also favorite localities, and the extremities usually show the smallest number. The palms and soles are rarely invaded, and, when so, the growths are small and flattened. In some instances they have also been found on the mucous membranes, as on the lips, gums, hard palate, and tongue.

Another form of fibroma, called **hard fibroma**, or *desmoids*, in contradistinction to that which is ordinarily met with and just described (sometimes called **soft fibroma**) is in many respects similar to the more solid small growths already referred to as fibroma simplex. They are rarely larger than a pea, usually occur singly, or as several scattered solid growths, covered by normal skin; are sharply defined, round or oval, smooth and compact, and movable. Their appearance is insidious and their growth slow, and they may appear at any age, and are even present, in some instances, at birth.

Etiology.—The affection is not a common one in our own country, England, or the Continent, but is, according to Hashimoto, quite frequent in the eastern countries. Its etiology is obscure, although it is known, from the observations of Virchow,[9] Königsdorf,[10] Octerlony,[11] Atkinson,[12] and others, to have occurred in several successive generations, or sometimes in more than one member of the same family. Heredity or family tendency must, therefore, be con-

[1] Atkinson, *New York Med. Jour.*, vol. xxii., 1875, p. 601 (2 cases in family).

[2] Von Recklinghausen, *Ueber die multiplen Fibrome der Haut, und ihre Beziehung zu den multiplen Neuromen*, Berlin, 1882 (a résumé of fibroma cases; 5 plates, 2 of case illustrations, and 3 histologic).

[3] Payne, *Brit. Med. Jour.*, 1889, i., p. 592.

[4] Brigidi, *Monatshefte*, vol. xix., 1894, pp. 190 and 237 (with histologic cuts and bibliography).

[5] Briquet, *Jour. mal. cutan.*, 1898, p. 219 (with bibliography).

[6] Whitfield, *Lancet*, Oct. 31, 1903, p. 1230 (newly-formed nerve-fibers were found in the growth); Krzysztalowicz, *Monatshefte*, 1903, vol. xxxvi., p. 421 (case report, histologic review, and bibliography to date); Piolett, *Hospital Gazette*, 1902, No. 137, brief abstract in *Jour. Cutan. Dis.*, 1905, p. 363 (with more than 600 tumors); Benaky, *Annales*, 1905, p. 977; Merk, *Archiv*, 1905, vol. lxxiii., p. 139.

[7] Wickham, Paris letter, *Brit. Jour. Derm.*, 1890, p. 151.

[8] W. G. Smith, *Brit. Jour. Derm.*, 1896, p. 115, describes and illustrates a case of extensive, somewhat lobulated fibroma, seated upon the scalp, with no tumors elsewhere.

[9] Virchow, *Virchow's Archiv*, vol. i., 1847, p. 226 (according to the patient's statement his grandfather, father, brother, and sister had the same disease).

[10] Königsdorf, "Ein Fall von Fibroma Molluscum Multiplex," Dissertation, Würzburg, 1889 (quoted by Jarisch).

[11] Octerlony, *loc. cit.* (a brother also had it).

[12] Atkinson, *loc. cit.*

sidered a factor. It occurs in both sexes, in all nationalities, and usually begins in childhood and frequently in early infancy; in some instances it is congenital (Hahn, Tappey, Hallopeau, and others).[1] In early life the lesions are, however, small and relatively scanty, and the increase in size and number takes place very slowly, as a rule, not developing to any extent until much later. In the cases of single fibroma its appearance is, as a rule, later in life. The subjects of the malady, as Hebra pointed out, and also shown in those of Pooley, Pringle,[2] Iurkewicz, and many others, are often of weak physical and of defective mental development, but while so in the larger number of cases, it by no means obtains in all. Moreover, it is not improbable, as Hutchinson[3] suggests, that the mental apathy is the indirect result of the gross disfigurement, the patient holding himself aloof and shunning his fellows. Traumatism is thought a possible determining factor in their production, or, more probably, only in influencing their location, more especially in the single fibroma developing later in life. Schwimmer, Taylor, and Recklinghausen, as well as a few others, have noted this; the last calling attention to the fact that those parts of the body most subject to friction, pressure, etc., usually show the most numerous growths.

Pathology.—According to the investigations of Rokitansky, Virchow, Neumann, Sangster, Duhring, Crocker, and others, the growth is due to a hyperplasia of the connective tissue, although there is not the same unanimity as to its exact starting-point, whether from the connective tissue of the corium, of the framework of the fat-globules, or of the walls of the hair-follicles and sebaceous glands. As to what gives rise to this hyperplasia is unknown. Recklinghausen, from his investigations of multiple fibromata, believes that they are really neurofibromata, and that they are formed primarily by proliferation of the connective-tissue sheaths of the nerves, and subsequently added to by proliferation of the same tissue of sweat-glands, sebaceous glands, and blood-vessel sheaths. The admixture of neurofibromata in some cases is generally recognized, but that fibromata, as commonly met with, are all of the same origin or nature is negatived by the collective investigations of others. Both Pringle[4] and Anderson[5] have also called attention to the fact that there is sometimes an association of fibromata with adenoma sebaceum, and it is not at all impossible, therefore, as these several gentlemen suggest, that certain tumors of different origin and character, which are sometimes found together, may have some common pathologic relationship. Crocker suggests that the growth may be due to obstruction of the superficial lymphatics, and that this, as well as other, anatomic analogies bring it into pathologic relationship with elephantiasis.

As the beginning lesions grow and extend the skin is pushed upward, and they finally project as simple or lobulated, sessile or

[1] Hahn, "Beiträge zur Casuistik des Fibroma Molluscum," Dissertation, Würzburg, 1888; Hallopeau, *Annales*, 1889, p. 707 (case demonstration and histologic examination).

[2] G. L. K. Pringle, *Edinburgh Med. Jour.*, vol. xlix., 1900, p. 260 (with plate).

[3] Hutchinson, "Molluscum fibrosum," *Rare Diseases of the Skin*, p. 205.

[4] Pringle, "Case of Congenital Adenoma Sebaceum," *Brit. Jour. Derm.*, 1890, p. 1.

[5] Anderson, "A Case of Adenoma Sebaceum Intermingled with Mollusca Fibrosa," *ibid.*, 1895, p. 316.

pendent tumors; they are adherent to the skin only at their base, and may thus be easily enucleated (Heitzmann). Crocker states that a sebaceous gland or hair-follicle forms the center in many of the small tumors, while these structures in the larger or older growths have undergone atrophy or disappeared. According to Taylor, in their very earliest stage the tumor consists of a gelatinous structure, which, under the microscope, is found composed of a succulent, edematous, wavy connective tissue with many cells, while in the older growths the fibers are firm and not edematous, and the cells are less numerous. On cutting through a well-formed tumor of some duration, quoting chiefly from Crocker and Heitzmann, it is found to consist of a white, fibrous mass, inclosed in a dense connective-tissue capsule, with the central portion soft and pulpy, and from which a small quantity of clear yellow fluid can be pressed out. The fibrous tissue is firmest and most developed at the base, the fibers becoming less firm and softer as the interior is approached. Connective-tissue cells with large nuclei are found between the fibers, being most numerous in the gelatinous central portion. The vascular supply consists of large afferent and efferent vessels, readily demonstrable at the base, and which spread peripherally, terminating in fine capillaries. The epidermis remains unchanged, although the sebaceous gland-ducts are sometimes hypertrophied, patulous, and plugged with comedones.

Diagnosis.—In a large single and pedunculated fibroma, and in cases of multiple, scattered, variously sized growths, most of which are sessile, and possibly a few with a narrowed neck or pedicle, a correct diagnosis is a matter of no difficulty. Confusion is most likely to occur with multiple lipoma, but in this latter they are commonly lobular, somewhat flattened, rarely present in numbers, and never pedunculated. From multiple neuromata they are to be distinguished by the absence of pain, as well as usually by their more general distribution. A mistake has sometimes been made with molluscum contagiosum, but the growths of the latter are much smaller, rarely numerous, most commonly seated about the face, especially about the eyelids, and, moreover, are superficial, have a central depression or aperture, and are covered by skin, which is usually thin, stretched, and which has a semitranslucent appearance. There might also be a possibility of confusing fibroma with the early tumor stage of granuloma fungoides, but the usual preceding and accompanying eczematoid symptoms of the latter, as well as the tendency, in some growths, toward the formation of fungoidal ulcerating masses, and the late development and sometimes capricious behavior of the tumors,—appearing and disappearing,—are wholly different from the features of fibroma. The soft and warty moles, sometimes congenital and sometimes developing later in life, can scarcely be confounded with fibroma, as commonly understood, although such growths, usually small and few in number, and generally more or less pigmented, are to a great extent to be placed in the same category. In the similar lesions observed in old people about the face and back, the surface is, as a rule, dark colored, often warty, and frequently covered with a greasy scale or crust. It is scarcely likely that fibromata could be confused with the nodules of leprosy, sebaceous cysts, or gummata.

Prognosis.—The outlook, so far as life is concerned, is always favorable, but as to the growths themselves, they are persistent, and usually add gradually to their size and also increase in numbers. While not, therefore, involving the general health, still, by their presence, they often give rise to inconvenience and discomfort by interfering with freedom of motion and through accidental injury, besides being the source of mental worry, which sometimes leads to an apathetic or neurasthenic condition. Exceptionally, in some growths, a tendency to spontaneous involution is exhibited. In single fibroma, and also in moderate multiple cases, there may be relief or comparative freedom brought about through operative procedures. Unfortunately, the malady is not influenced by constitutional treatment, although one instance of great improvement, to be later referred to, has been recorded.

Treatment.—Surgical measures alone are of any reliance, and the method, whether by ligation, écraseur, galvanocautery, or excision, depends upon the size and character of the growths. Large pendulous tumors can always be removed readily, and with great relief to the patient. The smaller tumors also admit of removal if not too numerous and if done a few at a time. The huge, flabby growths, approaching the nature of dermatolysis, have also been excised with success. Whatever the method, the tumor should be thoroughly extirpated or a regrowth is probable. Electrolysis has proved serviceable for the small tumors.

In multiple cases, in view of the favorable influence from the long-continued administration of arsenic exceptionally observed in other multiple tumor growths, this drug might also be tried in fibromata, more especially so now in view of the favorable influence apparently exerted in a case under Whitehouse's [1] care.

LIPOMA.

Synonym.—Fatty tumor.

Definition.—A new growth composed of fat tissue, seated in the corium or subcutaneous tissue.

Symptoms.—This formation, which usually comes under the domain of surgery, is observed in two forms—the circumscribed and the diffused. The *circumscribed lipoma* appears as one, several, or more rounded, usually lobulated elevations, and covered with normal or slightly pigmented integument, although occasionally somewhat thickened and raised in folds. They are, as a rule, freely movable, and of soft consistence. They are of various dimensions from a cherry to head size or larger, and sometimes, in the larger growths, with a tendency to ill-defined pedunculation. The overlying skin, if exposed to constant rubbing, irritation, or injury, may become firmly agglutinated with the tumor proper, and this is frequently noted as apparently a spontaneous occurrence in those of large size; and exceptionally surface ulceration may result. Their appearance is gradual, and after reaching variable size, usually remain more or less stationary. They are not painful, except when nerves are

[1] Whitehouse, "A Case of Generalized Fibroma Molluscum; Tumors Disappearing Rapidly Under the Use of Asiatic Pills," *Jour. Cutan. Dis.*, 1899, p. 383 (case demonstration).

involved or have received accidental injury. The favorite situations are the neck, back, and buttocks.

Diffuse lipoma is less common than the circumscribed form, and appears as soft, flattened, variously elevated, somewhat lobular elevations, usually distributed over relatively large areas, and with no sharp limitation, but gradually merging into the surrounding uninvolved parts. A rather ill-defined or mixed variety of lipoma, lumpy and infiltrating, involving the neck (*fatty neck*) and occurring in males, to which Brodie,[1] MacCormac,[2] Hutchinson,[3] Baker and Bowlby,[4] and Madelung[5] have called attention, is exceptionally encountered. The condition sometimes reaches enormous proportions.

In connection with lipoma the rare and independent affection known as *adiposis dolorosa* (Dercum's disease), which Dercum,[6] and subsequently Henry,[7] Debove,[8] and others, have described, may be briefly referred to. This malady, which has been observed in middle life and in women, is characterized by large, irregular, sometimes quite pronounced, nodular and diffused, or bolster-like, fatty deposits in the subcutaneous tissues. The condition is gradual in its progress, and usually involves various portions of the body, and is finally more or less general. With this are associated great muscular weakness, pain, nerve tenderness, diminution, alteration, or abolition, in certain areas, of the tactile and temperature senses, and other nervous disturbances, together with hemorrhages from the mucous surfaces, but more especially from the stomach and uterus. Pain is usually an early symptom, and headache common. The skin is noted to be dry, with now and then periods of free perspiratory action. In 1 of Dercum's cases purpura was noted, and in another a herpetic eruption. In 2 of the cases in which a fatal termination ensued the thyroid gland was found small and nodular, and exhibited calcareous deposits. It bears a rough, gross resemblance to myxedema, but differs materially, especially in the nervous disturbances and the muscular phenomena, the muscles in adiposis dolorosa being weak, flabby, and exhibiting other features of degeneration.

Etiology and Pathology.—Lipomata are almost always acquired, only exceptionally congenital cases being observed, several of which have been recorded by Jacobi.[9] Circumscribed forms are much

[1] Brodie, *Lectures on Pathol. and Surgery*, 1846, p. 202 (Amer. edit.).

[2] MacCormac, *St. Thomas' Hosp. Rep.*, 1884, vol. xiii., p. 287 (4 cases, 7 illustrations).

[3] Hutchinson, *Trans. London Ophthal. Soc'y*, 1884, vol. iv., p. 40.

[4] Baker and Bowlby, *Trans. London Med.-Chir. Soc'y*, 1886, vol. lxix., p. 41.

[5] Madelung, *Archiv f. klin. Chirurg.*, vol. xxxvii., 1888, p. 106 (4 illustrations).

[6] Dercum ("Myxedematoid Dystrophy"), *University Med. Magazine*, Dec., 1888, and *Amer. Jour. Med. Sci.* ("Three Cases of a Hitherto Unclassified Affection Resembling, in its Grosser Features, Obesity, but Associated with Special Nervous Symptoms—Adiposis dolorosa), vol. civ., 1892, p. 521 (3 cases—former case, a second case, and Henry's case; with illustrations).

[7] F. P. Henry, "Myxedematoid Dystrophy (Paratrophy)," *Jour. Nerv. and Mental Dis.*, 1891, p. 154.

[8] Debove, "Lipomatose douloureuse," *Gaz. de Hôp.*, Sept. 27, 1904.

[9] A. Jacobi, "Congenital Lipoma," *Arch. Pediatrics*, 1884, p. 65 (with résumé and references of other reported cases). This observer remarks that the shape in congenital lipoma is frequently irregular, and not spheroid, as it commonly is in the adult, nor is it generally capsulated; the occiput and back, the abdomen, upper extremities, besides the calves of the legs and the dorsal and plantar surfaces of the feet, are the usual seats of the adipose deposit.

more common in women, and usually in adult age. The diffused variety occurs almost invariably in males, and, as a rule, at about middle life. The etiology is obscure. Anatomically the growth consists of masses of fat-globules, more or less lobularly arranged, and enveloped in a connective-tissue framework, which also holds the blood-vessels. The consistence of the tumor, whether soft or moderately firm, depends upon the relative proportions of these two constituent tissues, the fatty mass being softer in those of loose and scant connective-tissue structure. While the tumors may persist unchanged, in some instances the connective-tissue framework is the seat of calcareous deposits or even of ossification. Excessive fat-tissue formation is also sometimes noted in connection with nævus (nævus lipomatodes) and other growths, such as angioma, sarcoma, etc.

Diagnosis.—The characteristic features of lipoma are their soft consistence, lobular character, painlessness, and movability, and are usually sufficient to prevent confusion with fibromata, sarcomata, or other growths. In doubtful cases microscopic examination of the component tissue would immediately settle the question.

Prognosis and Treatment.—Lipomata are benign growths and do not, therefore, involve life, and beyond their appearance and the discomfort caused by their presence or size are not cause for anxiety. When treatment is sought or considered necessary, excision is the sole efficient recourse; and if the tumor is completely removed, occurrence is not probable. In several cases of "fatty neck," and in one or two other instances, Brodie brought about considerable reduction by large doses of liquor potassæ—½ to 1 dram (2.–4.)—largely diluted, three times daily; but Baker and Bowlby found no influence from its use.

MYOMA.

Synonyms.—Dermatomyoma; Leiomyoma; Muscle tumor; *Fr.*, Myome cutané; *Ger.*, Myom; Dermatomyom.

Definition.—Myoma of the skin is a rare tumor, consisting of smooth muscle-fibers mixed with the fasciculi of fibrous tissue. Besnier[1] divides the cases into two classes: simple myoma, or leiomyoma, which is rare and presents as small multiple growths; and dartoic myoma, occurring usually as a large single tumor, and where the cutaneous muscular development is more abundant, as about the

[1] Besnier, "Les tumeurs de la peau, les dermatomyomes," *Annales*, 1880, p. 25; *ibid.*, vol. vi., 1885, p. 322; and Besnier-Doyon's notes to translation of Kaposi's work, vol. ii., p. 346 (with reference to reported cases to date). Other important literature: Crocker, "A Case of Myoma Multiplex of the Skin," *Brit. Jour. Derm.*, 1897, pp. 1 and 47 (with colored plate and histologic cuts, and a résumé of recorded multiple cases to date, which includes Hardaway's case); Neumann, *Archiv*, vol. xxxix., 1897, p. 3 (with 4 colored plates—2 case illustrations and 2 histologic); Audry, *Annales*, 1898, p. 182; Herzog, *Jour. Cutan. Dis.*, 1898, p. 527 (with several histologic cuts and bibliography); C. J. White, *ibid.*, 1899, p. 266 (with case illustration and histologic cuts); Leslie Roberts, *Brit. Jour. Derm.*, 1900, p. 115 (with a résumé of the preceding 4 cases); Hardaway (second report on his case), *Jour. Cutan. Dis.*, 1904, p. 375; Nobl, *Archiv*, 1906, vol. lxxix., p. 31 (extreme case—disseminated); Beatty, *Brit. Jour. Derm.*, Jan., 1907, p. 1 (multiple; with resumé of 7 multiple cases reported since Roberts' paper; case and histologic illustrations with complete bibliography); Heidingsfeld, *Jour. Amer. Med. Assoc.*, Feb. 16, 1907 (with histologic cuts and review of literature, with references).

scrotum, mammæ, female genitalia, and which usually comes under the surgeon's care. The latter develops from the cutaneous muscle-fibers, while the former, from the arrectores pilorum muscles or tunica media of the blood-vessels. In multiple myoma the lesions generally appear as pale rose-colored, rounded or ovalish, somewhat elevated macules or papules, which develop into pea-sized tumors. In color they are pink, red, or normal, elastic to the touch, and with a smooth surface. They are usually grouped, and are accompanied by a varying amount of pain, sometimes spontaneous in character, sometimes experienced only on pressure. They may occur upon any region, but the sides of the face and the arms have been the most frequent sites. They generally show a tendency to increase in size and number, and, as a rule, are steadily, though slowly, progressive; at times spontaneous involution takes place.

The single—dartoic myoma—and more common tumor is generally met with as a sessile or pedunculated growth, the size of an almond or walnut or larger. It is situated, as stated, in such regions as the scrotum, nipple, or labia. As a rule, it is painless, contractile, and provided with blood-vessels, and grows slowly. When the tumor consists principally of fibrous tissue, it is known as fibromyoma; when it is highly vascular, containing many blood-vessels, myoma telangiectodes (also angiomyoma); and when the lymphatic structures are conspicuously involved, lymphangiomyoma. This growth, being essentially of surgical interest, will not be further considered here.

Beyond the fact that females, adults, and middle life seem more prone to the growths, nothing is known etiologically. In a few instances they began in childhood. In Brigidi's case the growths began as an ecchymosis. In one of Jadassohn's it was stated that they followed vaccination, doubtless purely a coincidence. Anatomically the multiple tumors consist of unstriped muscle-fibers, surrounded by elastic tissue, and take their origin from the arrectores pilorum or from the fibers of the middle coat of the blood-vessels. There may in some cases also be an undue development of vascular, lymphatic, and fibrous tissue, giving rise to the compound names already referred to. Evidences of degeneration were noted in White's case, and the same can probably be seen in most of those tumors which undergo involution. In the diagnosis of these tumors the microscope is generally essential. Their insidious appearance, slow progress, and their usually occurring in circumscribed localities, with frequently, as they grow larger, considerable pain, and with no tendency to ulceration, will be sufficient for their recognition in well-marked cases. The possibility of confusing them with xanthoma, lymphangioma, fibroma, and even with keloid and neurofibroma is to be kept in mind. As to prognosis, the growths are, of course, benign, and in themselves have no influence on the general health, but if extremely painful, may indirectly be detrimental.

Treatment consists in their removal by excision. In one instance (Jadassohn) the pain persisted after extirpation. If the growths are numerous and excision not advisable or desired, the continued administration of arsenic could be tried.

NEUROMA.

Synonyms.—Nerve tumor; *Fr.*, Névrome; *Ger.*, Neurom; Nervenschwamm.

Definition.—Neuroma of the skin is characterized by the formation of variously sized, usually numerous, firm, immovable, and elastic fibrous tubercles containing new nerve-elements, and accompanied by violent paroxysmal pain. It is an exceedingly rare disease, and up to the present time but few cases in which the skin was primarily affected have been reported; one of these was by Duhring[1] and another by Kosinski.[2] According to Duhring, the subcutaneous nodule of Wood, resembling neuroma closely, differs in being situated in the subcutaneous tissue, is always freely movable under the skin, and is solitary. This and other cases of subcutaneous neuromatous tumors are not, strictly speaking, cutaneous growths, although they are usually so considered in the description of the disease. Nor is Rump's case,[3] sometimes quoted, a clear example of the malady, consisting essentially of a fibroid tumor of the nerve (false neuroma of Virchow), and was not accompanied by pain.

In Duhring's case, a man of seventy, the disease began at the age of sixty in the form of small, rounded nodules or tubercles upon the shoulder. For a period of four years they continued to appear in increasing numbers, the arm and shoulder becoming fairly well covered with them. The lesions consisted of numerous small, firm, flat tubercles, the size of a split pea, situated on the left scapular region, shoulder, and outer surface of the arm to the elbow. The color of the tubercles was purplish or pinkish, and they were irregularly distributed, apparently without regard to the course of the nerve. Over the shoulder and arm they were closely packed together and firmly imbedded in the skin. The integument covering the growths was slightly scaly. The skin between the tubercles was normal. The color of the affected area varied, however, according to the position of the limb and the presence or absence of pain, becoming hot and violaceous when painful. The tumors did not give rise to any discomfort until several years after the beginning of the affection, after which pain then became a troublesome symptom, and occurred in paroxysms, and was of a violent character, radiating down the arm, across the chest, and up the side of the neck and head. The paroxysms generally lasted for an hour, and were aggravated by exposure to cold air, mental emotion, or movements. In Kosinski's case, a male aged thirty, the disease appeared when sixteen years of age. The lesions were situated on the posterior and external aspect of the right thigh and a portion of the buttock, and numbered about one hundred. Pain was quite marked, and the lesions were exceedingly sensitive when subjected to pressure.

Etiology and Pathology.—As already stated, true cutaneous

[1] Duhring, "Case of Painful Neuroma of the Skin," *Amer. Jour. Med. Sci.*, Oct., 1873, and Oct., 1881.

[2] Kosinski, "Neuroma Multiplex," *Centralbl. f. Chirurgie*, No. 16, 1874, p. 241.

[3] Rump, *Arch. Path. Anat.*, vol. lxxx., part i., 1880, p. 177.

neuroma is rare, and in the broadest application of the term the malady is not common. It usually develops in adult life. The cause is unknown. It is not improbable that traumatism and irritation play a rôle in its production. Virchow believes that tuberculous patients are more prone to them. A family tendency has been noted. Histologically the growth is found seated in the corium, extending into the deeper structures. Upon examination it is seen to be made up of firm connective tissue containing non-medullated nerve-fibers, running up as high as the papillary layer of the corium, blood-vessels, and lymphoid cells, constituting true neuroma amyelinicum (Virchow) of the skin. They are in reality fibroneuromata. In the **diagnosis** the aid of the microscope in determining the exact nature of the growth may have to be resorted to, as it bears a close clinical resemblance to myomata, and this is especially so in some cases of the latter, as Hardaway's.[1]

The **treatment** is purely surgical, consisting of excision of a portion of the nerve-supply. In Duhring's case resection of a part of the brachial plexus relieved the pain markedly and the growths diminished in size. In Kosinski's case removal of a portion of the small sciatic nerve was followed by immediate cessation of pain and almost entire disappearance of the tumors.

RHINOSCLEROMA.

Synonyms.—Gleoscleroma (Besnier); *Fr.*, Rhinosclérome.

Definition.—A neoplastic chronic affection, characterized by an exceedingly hard, tubercular new growth involving the anterior nares and region of the nose.

Symptoms.—This disease, which was first described by Hebra and Kaposi in 1870, usually has its starting-point on the mucosa of the nose, particularly of the alæ and septum, and extends very gradually to the cartilages and skin of the nose and surrounding parts. According to Wolkowitsch,[2] in at least 90 per cent. of the cases the nose, both skin and nares, is the seat of the disease. In some cases the posterior part of the soft palate and the neighboring organs, as the larynx and trachea, are the starting-point. As the growth enlarges, the shape of the nose is gradually altered, becoming broader and flatter, and feels rigid and hard to the touch, resembling ivory. The lumen of the nasal passages becomes narrowed, and in some cases completely occluded, due to the inner walls becoming hypertrophied. The growths in the mucous membrane of the nose, pharynx, and larynx are flattened, and appear puckered and contracted as they cicatrize. The tumor tends to increase gradually in size, and the nose, including the lips and choanæ, are implicated in the process, resulting not only in great disfigurement, but interfering with nasal respiration, and also more or less with the mobility of the lips.

The cutaneous growths are flat, slightly elevated, sharply defined, isolated or confluent plaques or nodules; they are painful on pressure,

[1] Hardaway, *Amer. Jour. Med. Sci.*, April, 1886, p. 511.

[2] Wolkowitsch, *Archiv f. klin. Chirurg.*, vol. xxxviii., 1888, p. 449 (an exhaustive paper from every standpoint).

and very hard, though somewhat elastic, to the touch. They are firmly imbedded in the cutis and can only be moved with it. Their surface is normal or reddish in color, smooth or wrinkled, and shiny, and is traversed by blood-vessels and devoid of hair-follicles. It is impossible to grasp the affected tissue between the fingers, as it is firmly bound down. The epidermis is dry, and fissures appear occasionally, secreting a sticky fluid which forms yellowish crusts. The nodules rarely ulcerate.[1] The disease pursues a chronic course, extending over years, ordinarily extremely slow, but steadily progressive.

Etiology and Pathology.—It attacks both sexes alike, and is usually observed between the ages of fifteen and forty. The affection is met with most frequently in Austria and Russia, and some cases in Central America and Brazil. It is quite rare in England and Italy. In our own country 5 cases have been reported, and all occurred in individuals of foreign birth, natives of Austria or Russia, with the exception of 1 instance of the disease in a native-born American, observed by G. W. Wende,[2] in a boy aged eleven. Rona[3] states that the records show 21 cases in Hungary, 29 in Russia, 27 in Austria, and 23 in middle America.

The direct cause of the disease is believed to be a special bacillus—bacillus rhinoscleromatis—which primarily Frisch, and later Paltauf, Cornil and Alvarez, Payne, Marschalko, and others, found in the tissues. The bacilli are usually non-motile, occur in twos and fours; are capsulated commonly, and bear a strong resemblance to pneumococci. According to Rona, the bacillus cannot always be found. Secchi states that two forms of organisms are present, one resembling the blastomyces and the other resembling a bacillus; the latter, he thought, was a degenerative form of the blastomyces; the Frisch-Paltauf bacillus he considers a harmless parasite. Besnier and Doyon think the rarity of the malady and its practical limitation to certain countries are antagonistic to the acceptance of the parasitic view. A peculiar degenerated cell is also thought to be more or less histologically characteristic. Mibelli describes two cells—a colloidal and a dropsical—practically corresponding to those found by Mickulicz. Marschalko states that these cells are connective-tissue cells which

[1] Zeissl, *Wien. med. Wochenschr.*, 1880, p. 621, noted an instance, however, in which considerable destructive ulceration had ensued; Rona, *Archiv*, 1899, vol. xlix., p. 265, also saw a somewhat similar case.

[2] G. W. Wende, *Jour. Cutan. Dis.*, 1896, p. 90, with 2 cuts. Among other cases observed in this country, in foreign-born, may be mentioned by: Jackson, in Hungarian woman, *Jour. Cutan. Dis.*, 1893, p. 382 (with colored plate); Klotz, in German woman, *ibid.*, 1895, p. 121 (case demonstration); Allen, *ibid.*, 1900, pp. 282 and 379 (2 cases—demonstration; in one sloughing had occurred—nationality not stated).

[3] The following 3 recent papers give collectively, from a dermatologic standpoint, a complete presentation of the subject and the various reported cases and pathologic investigations, with bibliographic references; Rona, "Ueber Rhinoscleroma," *loc. cit.*, describes 16 of the Hungarian cases; Marschalko, "Zur Histologie des Rhinoscleroms," *Archiv*, 1900, vol. liii., p. 163, and vol. liv., p. 235 (exhaustive complete contribution on the subject from every standpoint—gives his own studies of 2 cases and a brief résumé of bacteriologic and histologic investigations, etc., of others, with bibliography and with 2 plates containing 10 histologic illustrations, some colored); Secchi, "Osservazione sulla istologica ed etiologia del Rhinoscleroma," *Gazetta della Cliniche*, xix., No. 4, 36, Aug. 1, 1899, brief abs. in *Archiv*, 1899, vol. xlix., p. 438; Castex, *Jour. mal. cutan.*, 1892, p. 161 (review paper with references).

have undergone degeneration through the action of the bacillus, which organism, primarily at least, is inclosed within these cells singly or in groups. The characteristic cell he thinks resembles the lepra cell. Upon the whole, there is general accord upon the histologic features, especially the gross findings. The process is viewed as of granulomatous character, the corium, and especially the papillary layers, is densely infiltrated with small cells, which Kaposi regards as being similar to small-celled sarcoma. Epithelial cells are also found, and some larger dropsical and colloidal round cells already referred to. True giant-cells, however, are not present. There is noted in places very dense fibrous tissue. The epidermis shows, as a rule, primarily at least, but little if any change, although some observers have called attention to interpapillary epithelial downgrowths.

Diagnosis.—The great rarity of the malady and, in England, our own country, and some other countries, its practical limitation to foreign-born subjects of certain nationalities are to be borne in mind in considering cases which may be clinically suggestive. The characteristic hardness and the absence of softening and ulceration, its tumor-like involvement of the nose, usually both within and without, its slow course and rebelliousness to anti-syphilitic treatment, serve to distinguish it from syphilis. Upon casual inspection it might be mistaken for keloid or epithelioma. Keloid is usually preceded by known traumatism, and, moreover, seldom occurs about the nose; in doubtful instances a histologic examination would be decisive, as keloid growths are essentially different. Epithelioma begins, as a rule, later in life, rarely involves the upper lip, and usually has infiltrated, often elevated, pearly edges, and with a clear tendency to ulcerate. In rhinophyma, the extreme development of the third stage of acne rosacea, the softness of the growth and vascular dilatation, often with nodules and pustules, are distinguishing features.

Prognosis and Treatment.—The malady is usually progressive, and hence the prognosis is very unfavorable. It is extremely rebellious to treatment. The neoplasms have invariably recurred after operation. Owing to stenosis of the nose, mouth, and larynx, respiration is seriously interfered with, and the patient is unable to take nourishment properly. The general health is not affected during the earlier progress of the malady, and later only indirectly. Removal of the formation with the knife and curet may be resorted to, but a permanent cure cannot be expected. The galvanocautery can also be employed to lessen the nasal stenosis and to check temporarily the invading growth. Lang speaks favorably of the repeated injection into the tumor of a 1 per cent. solution of salicylic acid or 2 per cent. solution of sodium salicylate, the drug also being administered in full doses by the mouth three times daily.

TUBERCULOSIS CUTIS.

In the class of **tuberculoses of the skin** must be placed all those cutaneous lesions which are due to the presence of the bacillus of Koch. Owing to the work of this latter observer, Baumgarten, and many others, we now know that many of the cases formerly called

papilloma, anatomic wart, lupus vulgaris, tuberculosis cutis, scrofuloderma, etc., are examples of the one and same process, probably modified by the condition of the patient, the resistance of the tissues, and other factors.

The subject of tuberculosis, indeed, is becoming a broad one, and the interest is ever increasing. The gravity of the disease, whether internal or integumentary, is receiving the attention it deserves. Its danger to the community is not yet, however, sufficiently recognized, and the indifference of the individual, the public, and the press to the presence of hundreds of cases of internal tuberculosis contrasts strikingly with the hysteric clamor aroused by the discovery of a single leper in our midst.

There have certainly been many cases of cutaneous tuberculosis which could be traced directly or indirectly to another in the family having the constitutional disease, which, with other evidence, will be touched upon again in considering etiology. While many clinical phases have been reported in recent years, the cases of tuberculosis of the skin can practically be included under five heads: (1) Tuberculosis ulcerosa; (2) tuberculosis disseminata; (3) tuberculosis verrucosa; (4) scrofuloderma; (5) lupus vulgaris. The first two are extremely rare, the third uncommon, the fourth not unusual, and the last—lupus vulgaris—relatively quite frequent. These various types deserve separate clinical description; consideration of their etiology, pathology, and detailed methods of treatment will follow the last.

1. TUBERCULOSIS ULCEROSA.

This variety, also termed **tuberculosis cutis vera, miliary tuberculosis of the skin, tuberculosis cutis orificialis** (and *tuberculose ulcéreuse* of the French), was at one time thought to be the only manifestation of integumentary tuberculosis, cases of which have been observed by Jarisch,[1] Chiari,[2] Riehl,[3] Schwimmer,[4] Zeisler,[5] Kaposi,[6] and many others. The disease is almost exclusively seated about or close to the mucous outlets, from which, in most instances, it can be considered an extension of an already existing process. The earliest formation consists usually in the appearance of minute miliary tubercles, which undergo rapid cheesy softening and ulceration. Cases are rarely seen before the characteristic ulcers are present; these are superficial, sluggishly granulating, irregularly rounded or oval, the edges soft and but very slightly infiltrated, and, as a rule, covered with a thin crust which, on removal, discloses the ulcer floor, somewhat uneven and of an indolent, reddish-yellow color, with a scanty secretion of a thin, purulent character. They are rarely painful. One or several may be present, and if the latter, after gradual

[1] Jarisch, *Archiv*, 1879, p. 265.
[2] Chiari, *ibid.*, p. 269, and *Mediz. Jahrbücher*, Wien, 1877, p. 328.
[3] Riehl, *Wien. med. Wochenschr.*, 1881, pp. 1229 and 1260.
[4] Schwimmer, *Archiv*, 1887, p. 37 (5 cases).
[5] Zeisler, *North Amer. Practit.*, Mch., 1889.
[6] Kaposi, *Archiv*, vol. xliii. and xliv., 1898 (Festschrift for Pick), "Ueber Miliartuberkulose der Haut und der angrenzenden Schleimhaut—Tuberculosis miliaris seu Tuberculosis propria cutis et mucosæ" (brief review of recorded cases and detailed analysis of 22 cases under his own observation).

extension, often result in coalescence and serpiginous configuration. There is no tendency to healing; on the contrary, there is usually progressive extension, sometimes so slow, however, as to be almost imperceptible from day to day. Miliary tubercles can occasionally be detected upon the surface, especially in the ulcers on mucous surfaces. It is met with exclusively in those with internal tuberculosis, and chiefly of the respiratory tract. According to Kaposi, however, its subjects are not invariably those in the last months or cachectic stage of constitutional tuberculosis, as generally believed. Contrary to general observation, Kaposi also states that healing may occasionally take place, either spontaneously, which is rare, or as the result of combined systemic and local measures. Almost without exception, however, the cutaneous disease is a part of a general tuberculosis which goes on rapidly to a fatal end. In the light of Kaposi's experience (22 cases), the disease cannot be considered so extremely rare as commonly believed.

As to be inferred, the integumentary ulcers are the result of extension or inoculation from mucous lesions or from the discharges. Its most common locality is the mouth and about the anus and genitalia. Ehrmann,[1] who has observed a number of these cases involving the genitalia, states that in general there are three modes of origin: (1) By contiguity, the disease extending from some part of the genital apparatus; (2) through the blood circulation, tuberculous material from some internal focus finding its way to the integument of these parts; (3) infection from without, as from saliva of tuberculous individuals—as, for instance, in ritual circumcision. In the first method the disease may spread along the urethra on to the penis, or the urethra may escape and be simply the passage through which morbid material finds its way from tuberculous kidneys, bladder, prostate, or seminal vesicles.

The diagnosis of tuberculous ulcers is rarely one of difficulty, owing to the presence of the constitutional affection and often the associated patches on the mucous membrane. The ulcers themselves are, indeed, quite characteristic. In doubtful cases, however, microscopic examination can be resorted to, as the bacilli are usually present in numbers; or, if necessary, recourse can be had to animal inoculation.

Treatment.—Not much is to hoped for except in those rare cases referred to by Kaposi, in which the patients are not in the last stages of phthisis. General roborant and nutritive remedies, especially cod-liver oil and nourishing food, are the best, and locally mildly stimulating and antiseptic applications, such as silver nitrate stick or solution, lactic acid, usually weakened with one to several parts water, cleansing with weak corrosive mercury solutions, and, when advisable, the curet.

2. TUBERCULOSIS DISSEMINATA.

Under this head it is convenient to class those rare cases in which the eruption consists of small, scattered lesions, more or less general-

[1] Ehrmann, "Zur Casuistik der tuberculösen Geschwüre des äussern Genitales," *Wien. med. Presse*, 1901, p. 202.

ized, and of an acute or subacute character. Several variations are encountered, and always in children. Heller and Gaucher[1] have described an acute tuberculosis of the skin in which the lesions were of multiform character, consisting of macules, papules, vesicles, blebs, and pustules, undergoing ulcerative change, forming ulcers of a deep, irregular, circinate type, usually crusted, and associated with caseation and suppuration of the neighboring lymphatic glands. The tuberculous character of the eruption was demonstrated by the presence of the bacilli and by inoculation experiments. Another type is that of which an example was recently recorded by Pelagatti[2] in a child two years old, in which the eruption, seated on the regions of the loins, buttocks, thighs, and legs, consisted of recent pin-head-sized papules, hemp-seed-sized papules of longer duration, both with slight central crusting, and larger papular lesions undergoing ulceration. They were pale yellow in color, somewhat elevated, and without areola. The characteristic bacilli were found in abundance. Death ensued from pulmonary and intestinal tuberculosis.

Another variety—exanthematic tuberculosis—presents, in its clinical features, a rough resemblance to flat lupus tubercles, to sluggish acne papules, and to lichen scrofulosorum. It usually follows the exanthematous fevers, especially measles. The lesions are indolent and of a dull, brownish-red hue; not infrequently they are noted to be connected with the follicles. The eruption is more or less disseminated, but is commonly seen on the face, arms, and legs; when the trunk is invaded it is only to a slight degree. It consists of variously sized lesions from a small papule to small patches of a fractional part of an inch in diameter; the latter usually resulting from an aggregation or confluence of several of the smaller ones. They are more or less persistent, but may undergo involution, and may or may not leave scars. Other symptoms of tuberculosis are commonly present, such as glandular enlargements, suppurating glands, chronic otitis, hip-joint disease, or scrofulous gummata, etc. Subjective symptoms are generally wanting. The tuberculous nature of the disease is usually demonstrable by inoculation experiments, and the lesions have also been noted in some instances to contain bacilli. The manifestation is rare, although several cases of allied but varying character have been recently reported, following measles, by Colcott Fox,[3] Haushalter,[4] Du Castel,[5] and Adamson.[6]

Treatment.—There is nothing special to be said on this point other than that the manifestations are to be treated as outlined later, basing constitutional measures upon general principles, and the selection of the local treatment according to the character, extent, and type of the lesions; salicylic acid, mercurial and pyrogallol applications usually being the best, as well as least painful, the curet and galvanocautery playing, in certain lesions, a possible secondary rôle.

[1] Quoted from Hyde and Montgomery, *Diseases of the Skin*, fifth edit., 1900, p. 611.

[2] Pelagatti, *Giorn. ital.*, 1898, No. 6; abs. in my review of dermatology in Hare's *Progressive Medicine*, Sept., 1899, p. 225.

[3] Colcott Fox, *Brit. Jour. Derm.*, 1898, p. 253 (case demonstration).

[4] Haushalter, *Annales*, 1898, p. 455.

[5] Du Castel, *ibid.*, 1898, p. 729.

[6] Adamson, *Brit. Jour. Derm.*, 1899, p. 20.

3. TUBERCULOSIS VERRUCOSA.

Verruca necrogenica, or anatomic tubercle, is the simplest and most common of this rare form of cutaneous tuberculosis. It is a localized, papillary or wart-like formation, occurring usually about the knuckles or other parts of the hand or forearm. Its most common site is over one of the metacarpophalangeal joints. It begins, as a rule, as a small, papule-like growth, increasing gradually, but very slowly, in area, and when well advanced, appears as a pea- or dime-sized or larger, somewhat inflammatory, red, elevated, flattened, warty mass, with commonly a tendency to slight pus-formation between the papillary projections, and of which small drops can, as a rule, be made to ooze upon slight lateral pressure. The surface, which is usually irregular, may be somewhat hard or horny, or the growth may be covered with a crust. In fact, the beginning papular lesion often becomes pustular, and this dries up and forms a crusted covering, which, if removed by accident or design, rapidly forms anew; later it acquires a warty aspect from papillary hypertrophy, and the same condition results as described above. The border especially is often superficially indurated, rarely deeply. There is also a disposition toward central healing and peripheral spread, although the patch rarely reaches more than an inch or so in area. The growth is more or less persistent, but in some cases, after a variable time, undergoes involution, leaving usually a slight smooth or corded scar. While the lesion is, generally speaking, relatively benign, it is occasionally followed by extension along the lymph-channels, with involvement of the lymphatic glands and constitutional infection; according to Knickenberg,[1] Guizzetti,[2] Hallopeau,[3] and others, this occurs more readily in this form than in that known as tuberculosa verrucosa cutis (of Riehl and Paltauf). Its usual subjects are those who have to do with decomposing animal matter; hence it is chiefly encountered among medical students, physicians, dissection-room and hospital-ward attendants, and butchers. Besnier and Vidal originally noted its occurrence among those making autopsies in tuberculous subjects, and recognized its analogy to some types of lupus. The investigations of Riehl,[4] Finger,[5] and others demonstrated that verruca necrogenica is due to tubercle bacilli infection.

Tuberculosis verrucosa cutis (of Riehl and Paltauf), while for some years irregularly met with, was first brought into prominent notice by the classic paper by Riehl and Paltauf,[6] whose studies were based upon 14 cases observed in Kaposi's clinic, and which showed the analogy and probable identity of this with anatomic tubercle just described; also its resemblance to lupus verrucosus. It was by them thought to occur in adults who had to do with animals and animal products, but we know to-day that many cases are also contracted

[1] Knickenberg, "Ueber Tuberculosis verrucosa cutis," *Archiv*, 1894, p. 405.

[2] Guizzetti, "Ueber einen Fall von Tuberculum anatomicum. Histologisch-bakteriologische Untersuchungen," *Monatshefte*, vol. xxix., 1899, p. 253.

[3] Hallopeau, "Sur les rapports de la tuberculose avec les maladies de la peau autres que le lupus vulgaris," *Jour. mal. cutan.*, 1896, p. 522.

[4] Riehl and Paltauf, "Tuberculosa verrucosa cutis," *Archiv*, 1886, p. 19.

[5] Finger, "Ueber die sogenannte Leichenwarze," *Deutsche med. Wochenschr.*, 1888, p. 85.

[6] *Loc. cit.*

from other tuberculous individuals. White [1] believes that this variety may fairly be accepted as the ordinary form of manifestation in the cutaneous tissues of the inoculation of the same with tuberculous matter, whether derived from the cadaver of man or other animal, or by contact with infective material from living subjects. While it usually begins in an insignificant manner, practically similarly to verruca necrogenica, it is much more extensive and may cover several inches or more of surface. One, several, or more small patches arise, and if the latter, generally near together, and sooner or later coalesce and form an irregularly shaped or serpiginous area. The

FIG. 139.—Tuberculosis verrucosa cutis; in a negro.

degree of inflammatory action present varies considerably, the area or areas being surrounded by a band-like redness with some infiltration. The whole patch is, as a rule, somewhat elevated, infiltrated, and beset with wart-like papillary hypertrophy, or with dull or purplish-red tubercles or nodules, isolated or grouped; or with closely aggregated or discrete, usually minute pustules, seated directly upon the sluggishly inflamed purplish area, or at the summits of the tubercles or nodules. Not infrequently the interstices between the papillary or projecting vegetations contain some sero-

[1] J. C. White, "Clinical Aspects and Etiologic Relations of Cutaneous Tuberculosis," *Boston Med. and Surg. Jour.*, Nov. 12, 1891, p. 509.

purulent or purulent fluid, which can be pressed out. While the disease spreads peripherally, a slight tendency to thin scarring is generally to be noted in the earliest portions. In fact, in some cases, especially where there are several areas or one extensive plaque, all the described features can usually be seen. One of its characteristics is that it rarely shows any positive ulceration.

Its favorite region is the back of the hand—sometimes one, sometimes both. It often spreads on to the fingers and the interdigital folds, up the wrists, and less frequently on to the palms. On this last-named region it is, however, rare, and always appearing as an extension from the dorsum, as in the 2 cases reported respectively by Cutler[1] and Weber.[2] Inasmuch as this type is frequently seen in association with pulmonary phthisis, 4 examples of which have been recently reported by Béclère,[3] it is probable, as stated by this observer, following Vidal, that its presence in this region finds its explanation in the fact that phthisical patients, and especially men, in whom this manifestation is most frequently encountered, after coughing wipe off the mouth and mustache with the back of the hand. Of interest and suggestive in this connection is Schoull's[4] experiment, who took some hair from the beard of a tuberculous patient, and, after soaking and agitating it in distilled water in a test-tube, injected some of the liquid into a guinea-pig, the animal shortly succumbing to tuberculosis. Fabry[5] called attention to its occurrence in coal-miners, in whom the numerous and constant injuries and cuts about the backs of the hand incident to their work play an important rôle, affording opportunities for inoculation, phthisis being not an uncommon disease among such workmen.

Like anatomic tubercle, it is slow in its course, often stationary for periods, and in certain parts retrogressive; it often lasts for years, and occasionally disappears spontaneously. There is usually left a thin, atrophic-looking scar, sometimes with the sieve-like aspect noted in lupus erythematosus. It bears a striking resemblance to blastomycetic dermatitis (*q. v.*), with which doubtless it has sometimes been confounded.

Various other forms allied to this in general character have been described, but they are scarcely to be considered as separate manifestations, but rather as aberrant types, in which one or other clinical element predominates, and sometimes presenting features partaking of the nature of both this form and lupus vulgaris; moreover, it may occasionally be upon other situations. Thus, in Morrow's[6] case (tuberculosis papillomatosa cutis) the eruption was seated upon the

[1] Cutler, *Jour. Cutan. Dis.*, 1898, p. 535 (case demonstration)—on backs and palms of both hands.

[2] Weber, *Brit. Jour. Derm.*, 1899, p. 161 (case demonstration).

[3] Béclère, *Gaz. hebdom.*, 1898, No. 34; *Annales*, 1898, p. 794.

[4] Schoull, *Jour. des prat.*, 1899, p. 347.

[5] Fabry, "Ueber das Vorkommen der Tuberculosis verrucosa cutis (Riehl and Paltauf) bei Arbeitern in Kohlenbergwerken," *Archiv*, 1900, vol. li., p. 69 (7 cases, most of which with associated pulmonary tuberculosis, or with the latter in the family; 2 cuts of cases); and Schulze (Fabry's clinic), *ibid*, 1904, vol. lxx., p. 329 (a synopsis of 160 cases).

[6] Morrow, *Jour. Cutan. Dis.*, 1888, p. 361 and 401 (with colored plate). Shelmire, *Jour. Cutan. Dis.*, 1906, p. 20, reports a case of probably a mixed type, the verrucose element predominating; eruption on face and neck in a negress.

face, and consisted of rather bright-red, abundant, and extremely prominent papillomatous vegetations; in Mracek's[1] and Ravogli's[2] cases, the leg was the seat of the manifestation, which was quite extensive.

In some rare cases, as described by Riehl[3] as *tuberculosis fungosa cutis*, the growths are somewhat fungoidal or mushroom-like, and resemble similar formations observed in granuloma fungoides; the disease usually originates in osseous or periosteal lesions; fistulous ulcers are formed, growing nodular swellings, with fungoidal aspect, and later the ordinary appearances of tuberculous ulcers. Other lesions, occasionally seen in the average type, are tubercles or nodules, small pustules, papillary elevations, and crusting. In other instances, as described (fibromatosis tuberculosa cutis) by the same author, along with papillomatous vegetations, ulcers, etc., there is marked sclerosis, found on different parts, not infrequently about the nose, mouth, and other mucous outlets. Wickham and Jessner have also described cases with frambesiform lesions, in that of the latter the eruption being disseminated. In fact, almost all types of nodular, vegetating, and ulcerative lesions are encountered as the result of tubercle bacilli infection, and Besnier, Lejars, Jeanselme, and others have noted rare instances (lymphangitis tuberculosa cutanea)[4] in which the lymphatics, usually of the extremities, were the seat primarily or secondarily of infection, and the eruptions of various characters, lupoid, nodular, and papillomatous, corresponding to the lymphatic distribution, and commonly with some elephantiasic enlargement. To lymphatic involvement is doubtless due also the hypertrophic character noted in other types.

Diagnosis.—The sluggish character of the growth, its dull red or purplish-red color, its localization, history, and slow course, and the papillomatous tendency displayed, the absence of distinct ulcerative action, and usually of brownish or reddish-yellow tubercles, will serve to distinguish it from both syphilis and other forms of tuberculosis. Its resemblance to blastomycetic dermatitis is striking, and, in fact, unless other symptoms of tuberculous nature are present, a conclusive differentiation is possible only by microscopic and bacteriologic means.

Treatment.—Of the various local measures to be mentioned in the section on treatment of the tuberculoses, the use of the antiseptic applications, such as the mercurial preparations, together with the use of strong salicylic acid plasters and pyrogallol salves, and, when necessary, the curet, are the most valuable. The X-ray and Finsen treatments have been variously commended.

4. SCROFULODERMA.

Formerly this term was applied to all those various peculiar and suppurative and ulcerative conditions of the skin occurring in strumous subjects. While this still holds to a limited extent, it is now

[1] Mracek, *Hand Atlas of Skin Diseases*, second edit., plate 86.

[2] Ravogli, "On Various Forms of Cutaneous Tuberculosis," *Jour. Amer. Med. Assoc.*, April 16, 1898.

[3] Riehl, *Verhandl. der Deutschen dermatolog. Gesell.*, IV Congress, 1894, p. 354.

[4] See Pringle's remarks supplementary to a report of a case by Cahill, *Brit. Jour. Derm.*, 1895, p. 1, reviewing the models of the malady in Baretta Museum, Paris.

chiefly restricted to the sluggish ulceration or involvement of the skin resulting by extension from an underlying caseating and suppurating lymphatic gland. Occasionally, however, it appears to have its origin as subcutaneous tubercles independently of these structures. Arising from the former, the gland or glands, usually the cervical, are noted at first to be somewhat swollen, sometimes attaining many times their normal size. While they may be hard at first, they soon soften, and as the overlying skin is distended, the latter becomes of a dull-reddish or violaceous hue. In occasional instances, after reaching this stage, they gradually disappear by absorption. Usually, however, the caseation and suppurative changes finally involve the skin, which may show one or more points of softening and destruction, resulting in the formation of sinuses which lead down to the underlying diseased glandular structures. When this ensues, more or less flattening takes place, and when the process is thus advanced, the area is noticed to be of a purplish-red color, with pea- to dime-sized ulcerated openings, and the sluggish inflammatory infiltration extending slightly beyond the immediate area of disease. The skin, once thus involved, the process extends superficially, implicating the surrounding integument, often to a considerable extent. The intervening islets of purplish-red, weakened skin occupying the original area often break down completely, and the scrofulous ulcer is formed. This may also result without much invasion of the adjacent integument. If beginning in a subcutaneous nodule, independently of the lymphatic glands, the induration increases in size in all directions, attaining the dimensions of a large cherry or walnut, thus undergoing about the same changes noted when the glandular structures are primarily involved; the skin breaks down over almost the entire mass, or first at several points.

Instead of a preceding deep-seated nodule or gland enlargement, there may appear one or several superficial pin-head- to small pea-sized indurations, which soon become pustular and enlarge peripherally, forming a fairly large, flat, often irregularly shaped, yellowish or brownish-yellow, flat, thin, crusted pustule, with an areola of a dull red or violaceous color. The crusting is slow in formation, beginning centrally, and quite scanty, entirely unlike that seen in the large flat pustular syphiloderm, which it slightly suggests. As the crusting takes place the lesion may extend peripherally; or if two or three are in close proximity, coalescence sometimes ensues. On removing the crust, the superficial, irregular edged, granular-looking, scrofulous ulcer, with uneven base covered with thin purulent secretion, is disclosed. Their course is slow, and they may remain for months; healing is followed by soft and superficial scars. They may appear upon any region, but in the several cases under my care were on the upper part of the breast or neck. This type is that designated by Professor Duhring as the *large flat pustular scrofuloderm.*

The process rarely extends deeply; even when beginning in the glands, the subsequent course after destruction of the overlying integument is laterally, rather than deeply, although this latter can take place when the caseating and suppurating glands or nodules are quite large (*scrofulous gummata*, scrofulogummata, tuberculous gum-

mata, tuberculides gommeuses of the French). Involvement of the lymphatics, especially when these tuberculous gummata are on the lower extremities, occasionally is observed, lymphangitis resulting, and sometimes elephantiasic enlargement.

The ulceration is usually superficial, has thin, dull red or purplish, undermined edges, as a rule irregular in outline, and has an uneven base with sluggish granulations covered scantily with pus. Its spread is generally gradual, and there is but moderate, and sometimes extremely slight, outlying infiltration. Occasionally there is a tendency to heal and form here and there weak cicatricial tissue; this is observed sometimes when the overlying skin has suffered only irregular and incomplete destruction. In such cases, in some instances, there is later developed a tendency in the outlying skin to the formation of lupus tubercles, and the disease may later even assume the partial or complete clinical aspects of lupus. As a rule, however, the practical absence of infiltration, the weak, sluggishly red skin, with the violaceous hue and the superficial ulceration typifying this variety of cutaneous tuberculosis, are maintained throughout. Occasionally temporary crusting is noted. In some instances, after the glandular structure softens and breaks down, the reparative process gradually sets in and healing finally takes place. Or the caseating and suppurating glands, with the several resulting sinuses, may continue almost indefinitely, the sinuses closing up now and then, the disintegrating tissue and secretion collecting beneath and again finding exit.

The condition is usually one of childhood and adolescence, and is commonly associated with other symptoms of a tuberculous nature, such as keratitis or its scars, chronic otitis, bone or joint disease, etc. It not infrequently follows in the wake of some severe systemic disease. In old people, in whom the manifestation is rare, after ulceration results a papillomatous or verrucous tendency sometimes develops, and the picture of lupus verrucosus or tuberculosis cutis may be presented; or later epithelial degeneration may set in. The course of this form of cutaneous tuberculosis is slow, but it usually responds rapidly to appropriate treatment.

The Small Pustular Scrofuloderm (Duhring).—Some years ago Duhring[1] called attention to a peculiar small-pustular eruption occurring usually in the scrofulous or those of scrofulous history, and which was of a chronic character and was followed by scars.

The face and extremities, especially the face and the upper extremities, are its usual sites. The lesions are disseminated, and, as a rule, not abundant. They begin as pin-head- to small pea-sized papulopustules, resembling somewhat closely the small papulopustular syphiloderm. The pustular character is often slight and occupies the central part of the summit, the outer portion of the lesion being slightly hard, and in the beginning with an insignificant areola. The formation is superficial, not extending deeply into the derma. "They crust over gradually in the course of from one to several weeks, with depressed, shrunken, hard or horny, yellowish or grayish, adherent crusts, which in time drop off, leaving marked, punched-out-looking, indelible scars, resembling those of variola. The lesions

[1] Duhring, *Amer. Jour. Med. Sci.*, 1882, vol. lxxxiii., p. 70.

are further characterized by a sluggish, chronic course and may last weeks or months. They appear at irregular periods, new ones coming out as the older ones disappear, so that the patient is rarely free from them. The disease may continue for years." I have met with 5 or 6 cases of exactly the same characters. The eruption was confined to the face, arms, and hands, extremely sluggish, with the peculiar variola-like scarring and persistent course. The patients were, for the most part, of scrofulous habit or history. The disease, as can be seen by Duhring's graphic description quoted, and as my own cases indicated, is extremely suggestive of an acne varioliformis

FIG. 140.—Represents Prof. Duhring's small pustular scrofuloderm, and can be also viewed, clinically at least, as an unusual acne varioliformis of peculiar distribution; as folliclis; as necrotic granuloma, and other variously named like or allied affections.

of mild character and peculiar distribution, and I should be inclined to consider it, with other allied eruptions, as probably identical with it, or as at least closely related, as stated under the head of that affection.

Diagnosis.—The peculiar character of the ulceration in the common form of scrofuloderm, its origin usually from a lymphatic gland or cutaneous or subcutaneous nodule, the absence of outlying tubercles and infiltration, together with its history and course, will serve to distinguish it from other forms of the cutaneous tuberculoses; these features, together with other strumous symptoms commonly present, will prevent its confusion with syphilitic ulceration.

Treatment.—The various constitutional remedies are referred to in the part on the treatment of the tuberculoses; but of these, of greatest value are cod-liver oil and iodid of iron. The most appropriate local measures consist, in the type with deep glandular involvement, in enucleation and curetting, with supplementary cauterization with lactic acid; in the cases in which the process involves the superficial glands only, or in those cases arising independently of these structures, thorough curetting, with the subsequent use of the pyrogallol salve for a few days, usually constitutes the best plan. In some cases good results have followed both X-ray exposures and the Finsen-light treatment.

5. LUPUS VULGARIS.

Synonyms.—Lupus; Lupus vorax; *Fr.*, Lupus vulgaire; Lupus tuberculeux; Scrofulide tuberculeuse; *Ger.*, Fressende Flechte.

Definition.—A chronic cellular new growth, due to invasion of the integument by the tubercle bacillus, characterized by variously sized, soft, reddish-brown tubercles, tubercular and infiltrated patches, usually terminating in ulceration and scarring, sometimes in absorption, exfoliation, and atrophy.

Symptoms.—The most common site for the manifestation of the malady is the face, especially the region of the nose, although other parts of the surface are not infrequently invaded either conjointly with the face or independently. This will be referred to again. The disease begins by the development of several or more pin-head- to small pea-sized, deep-seated, brownish-red or yellowish macules (lupus maculosus) or small discrete infiltrations or tuber-

FIG. 141.—Lupus vulgaris in a girl of fifteen, of six years' duration.

cles, having their seat in the deeper part of the corium, and which are somewhat softer and looser in texture than normal tissue. As the disease progresses, usually, however, very insidiously and slowly, by new lesions or infiltration at the bordering part, a variously sized patch, consisting of crowded or aggregated tubercles, results. The earlier nodules or infiltrated points, having attained a certain size or development, about that of a small pea, remain stationary, for a time at least, and then, sooner or later, exhibit retrogressive changes and tend to break down and disintegrate, and destruction results,

terminating in ulceration. These latter are rounded, shallow excavations, with soft and dark-reddish or brownish-red borders, and with a variable amount of purulent secretion, but usually slight in quantity, which leads to more or less crust-formation. Later, as the patch gradually increases in area, the ulcerations are disposed, as a rule, to heal, and finally give place to cicatricial tissue, generally of a firm and fibrous character. The patch spreads by the appearance of new papules or infiltrations at the peripheral portion, and not infrequently new islets arise just outlying the border; the intervening space is gradually filled up by other lesions, and the whole area becomes continuous.

In a typically developed patch of lupus, in which, as more commonly noted, ulcerative tendency is observed (**lupus exedens; lupus exulcerans**), several conditions are to be seen, even when the area is

FIG. 142.—Lupus vulgaris; chiefly of the exfoliative type, with pigmentation and atrophic scarring; showing, as a result, ectropion; ulcerative action on other cheek. Patient aged thirty-five; duration twenty years.

scarcely larger than a silver quarter: the characteristic soft, small, yellowish- or reddish-brown (of apple-butter color and appearance) cutaneous and subcutaneous points and papules; similarly colored or yellowish-brown tubercles and infiltrations; ulcerations, usually small, rounded, and shallow, sometimes confluent and irregularly shaped; cicatricial formation, which, as a rule, is rather tough and keloidal; and, in addition, outlying the involved area, but close to the border, can often be seen a few isolated small infiltrated points or tubercles. These various lesions show the several stages of the process from the beginning cellular deposit to the resulting necrosis and cicatrization. So the disease continues, often apparently remain-

ing stationary for months or longer, so that in many instances, and especially as met with in our country, several years or more may have elapsed before the area involved is more than one or two inches across—usually irregularly shaped, although, as a rule, somewhat rounded or ovalish. In other cases, instead of resulting in necrosis and ulceration, the matured or oldest papules or tubercles or infiltrated patch, after long continuance, slowly diappear, chiefly by absorption, fatty degeneration taking place, and partly by exfoliation, leaving an exfoliating, atrophic, or thin, cicatricial, pigmented tissue, constituting the clinical variety known as **lupus exfoliativus.** And in this way the disease continues, presenting the various stages and lesions noted in the ulcerating form, except the ulceration and tough

FIG. 143.—Lupus vulgaris in a youth of sixteen, of five or six years' duration.

fibrous scar-formation. It is not uncommon, both in the atrophic and scar tissue resulting from the earliest lesions, for new foci of disease to appear from time to time, usually isolated, and with very little tendency to confluence.

The disease may be more or less pronounced in one or more of its features. In exceptional instances the ulcerations may be the seat of exuberant granulations, and the underlying inflammatory and cellular infiltration and edema be quite considerable or extreme, and with the resulting cicatricial formation giving rise to hypertrophic disfigurement and distortion—**lupus hypertrophicus.** In some cases, while in most respects the disease is as usually observed, the cicatricial development is hypertrophic, tough, and thick (**lupus sclerosus**); or there may show itself a distinct keloidal tendency in the resulting scar tissue (lupus keloides). In some instances the ulcer-

ations become the seat of papillary elevations or hypertrophy, and there is then presented a somewhat uneven, papillomatous, exuding, and crusted surface—**lupus papillomatosus, lupus verrucosus.** As the disease gradually advances the border of tubercles or almost continuous infiltration may be irregular or tortuous, the innermost part showing the usual scar or atrophic tissue, and the whole configuration and manner of spread be of serpiginous character (**lupus serpiginosus**), somewhat closely resembling the serpiginous tubercular syphiloderm; and in cases with this tendency, as a rule, the lupus infiltration and ulceration go almost hand in hand, so that sometimes a rather large, pigmented, atrophic or tough cicatricial area, with an infiltrated, ulcerating, irregular, or serpiginous border, is presented. The various other terms sometimes used in connection with the disease, such as *lupus planus, lupus nodosus, lupus elevatus, lupus tumidus, lupus œdematosus, lupus elephantiasicus*, etc., are self-explanatory, signifying merely the accentuation or undue development of some special feature.

When the nose and immediate region are the parts involved, the tissue, except cartilage, of this organ, especially at and about the end, is gradually destroyed and changed into a firm, irregular, and thin cicatrix, producing considerable deformity, the resulting contraction often narrowing the nasal outlets. In other cases the atrophic thinning and cicatricial tissue may tend to distend the nostrils. In occasional instances, however, of lupus involving the nose the earlier tubercles or infiltration give way to ulceration and then become the seat of papillomatous vegetations or hypertrophic granulations, resembling the same type of syphilis very closely, as in a few instances under my own care;[1] later scarring and the usual disfiguring changes result. Zeisler[2] records a somewhat similar case. When the spreading disease encroaches toward the eye, the cicatricial formation which ensues frequently draws upon the eyelid and produces moderate or marked ectropion. Involving or spreading on the upper lip, often considerable edematous infiltration is noted, the part assuming large proportions (lupus hypertrophicus). Ordinarily, however, the usual features are presented, and with the consequent tough, often keloidal, cicatricial ending, the mouth is drawn, sometimes slightly puckered, and the opening inconveniently narrowed. Both when implicating the lip and the nose, the invasion of the nasal mucous membrane, and even that of the mouth, is frequently observed, and, indeed, the disease often starts from within the nasal orifice.

In some cases of lupus of the face, as well as when seated elsewhere, not infrequently new foci appear one or several inches or more from the original patch; or the disease may develop at several points simultaneously, or one follow closely after the other. As a rule, however, and especially as observed in our own country, there are but one or two areas, which may be quite small and scarcely progressive, or exceptionally extensive and involve a greater part of the

[1] Stelwagon, "A Somewhat Unusual Case of Lupus Ulceration of the Nose," *Jour. Cutan. Dis.*, 1892, p. 428.

[2] Zeisler, "Remarks on Tuberculosis of the Skin," *North Amer. Practitioner*, Mch., 1889 (a clear and terse review, with many references).

face. In addition to the disease presenting on the face, foci sometimes develop elsewhere on the general surface, usually conjointly or subsequently to the face manifestation. While, however, the face is the sole seat of the malady in most patients, and commonly shares in the disease in instances in which the eruption is noted on other parts, still there occur cases, not often, it is true, where the eruption develops on the leg, arm, neck, trunk, or about the genitalia, and remains limited to its original region, the face remaining free throughout. Bender,[1] in an analysis of 374 cases, found that the face was the seat of the disease in 287, of which, in 115, it was more or less of the entire face; in 70, it was on the nose; 35, on the cheek; 25, nose and other parts of face; 16, on lips; 15, nose and lips; 6, temple and forehead; 3, chin; and 2, eyelids; 40, upper extremities; 15, lower extremities; 12, face and neck; 6, face and extremities; 3, face and arm; 3, ear; 2, general; 2, scalp; 1, hand and foot; 1, nape of neck; 1, back, and 1, palate. It presents no special peculiarities in the various unusual localities, exhibiting primarily the beginning maculopapular, yellowish-brown papules or tubercles, closely aggregated or contiguous and confluent, and progresses in the ordinary manner and with the same changes. There seems to be a greater tendency shown on these regions for the malady to be serpiginous in character, often exhibiting a close resemblance to the serpiginous tubercular syphilid. In these cases, too, the exfoliative feature is often more pronounced than it is usually upon the face. In most the disease is limited to one region, although it often involves a great extent of surface. The ulcerative tendency, when present, is often quite pronounced, and if the disease is about a joint, may result in serious deformity and materially restrict the mobility of the part. When on the lower part of the leg and also about the genitalia and anal region, the ulcerations are often the seat of papillomatous vegetations (lupus papillomatosus, lupus verrucosus), with crusting and offensive discharge; considerable thickening and edematous infiltration with lymphangitis are also frequently noted with the disease when on the extremities.

Lupus of the mucous membranes has been incidentally mentioned in connection with that of the lip and nose, but the involvement may also be conjointly with the disease some distance from these parts. In fact, it is not improbable that in many cases of cutaneous lupus the primary infection is within the nose. And cases of lupus invading the throat are also recorded from time to time, though few in number, in which there is no evidence of the eruption upon the integument. It may consist of an insignificant or moderate diffused infiltration, with slight papular or tubercular elevations, or more the nature of papillary excrescences; or the area is studded with whitish epithelial opacities. Superficial ulceration is not uncommon, and may assume a serpiginous configuration; or it presents the aspects of a raw granulating patch. The most commonly involved site is that of the nares, near the outlets, and the mucous membrane of the inside of the lips, contiguous to the adjacent skin. In most of these

[1] Max Bender (Ueber des Beziehungen des Lupus vulgaris zur Tuberkulose), *Deutsch. med. Wochenschr.*, 1886, p. 413.

cases the disease has progressed from the skin, although, as already stated, the primary involvement may doubtless not infrequently be on the mucous membrane. Other parts, such as soft palate, velum, hard palate, etc., may also be the seat of the malady. According to Finsen,[1] in the cases of lupus treated at his light-institute, in 70 to 80 per cent. the mucous membrane of the nose or mouth was also involved, a surprisingly large proportion when compared to average American experience, and much, I feel sure, above that generally observed. Bender,[2] in 380 cases, found in about 45 per cent. (173 cases) mucous membrane involvement conjointly with the skin; in 6 cases only was the disease limited to the mucous membranes. In 147 of these 173 cases in which inquiry was made as to place of beginning it was elicited that in 46 cases, or 31.2 per cent., the mucous membrane was the part originally attacked. While in a number of instances but one mucous surface was invaded (nose, 75; tear-duct, 9; conjunctiva, 8; lips, 12; palate, 11), in many several regions were the seat of the disease, so that in tabulating, the mucous membrane of the nose was found implicated in 115 cases, conjunctiva in 21; tear-duct in 24; lips in 43; palate in 31; tongue in 1; larynx in 13; rectum and vulva in 1.

While in the very large majority of lupus patients the usual characters and location are observed, occasionally atypical cases, especially as regards distribution, configuration, extent of eruption, and association with other forms of integumentary tuberculosis present. A rare form, usually on the face, but sometimes on other parts, is that described by Leloir[3] as **lupus vulgaris sclerosus erythematoides**, which resembles closely and simulates lupus erythematosus (also referred to under this latter disease). It is very slow in its course, tending to spread in a centrifugal manner, and never ulcerates. It is of a bright or dusky red color, disappearing partly under pressure, and here and there, especially peripherally, covered with fine scales or small lamellated crusts; somewhat raised at the border, and slightly depressed centrally in consequence of the tendency to atrophic cicatrization or interstitial resorption. If the involved skin is put upon the stretch, as a rule small miliary tubercles of a yellowish color become visible; there is a good deal of infiltration underlying, which also distinguishes it from lupus erythematosus. Histologic and bacteriologic findings with experimental inoculation proved its tuberculous nature, although it presents clinically a meeting-ground between these two affections. Hardaway[4] believes this form much more common than generally thought, but that it is usually confounded with lupus erythematosus, a view which I am inclined to share. Very exceptionally lupus patches from the start display a tendency to circinate shape,

[1] Stelwagon, "An Account of a Visit to Professor Finsen's Light-Institute at Copenhagen," *University Med. Mag.*, Philada., Dec., 1900.

[2] Max Bender, "Ueber Lupus der Schleimhäute" (a review of the literature with references), *Archiv*, 1886, vol. xx., p. 892. See also valuable paper by Doutrelepont, "Ueber Haut- und Schleimhauttuberculose," *Deutsche med. Wochenschr.*, 1892, p. 1033.

[3] Leloir, *Jour. mal. cutan.*, 1891, p. 241; good abstract in Brocq's letter, *Jour. Cutan. Dis.*, 1892, p. 27.

[4] Hardaway, *Manual of Skin Diseases*, second edit., 1898, p. 317.

with clearing, usually atrophic or cicatricial center, in some respects resembling, in shape more especially, the lupus vulgaris erythematoides of Leloir, except that the borders are distinctly nodular. It begins as a nodule, and this sinks centrally as it spreads. A rare instance of this form, which was of added interest by the large number of such areas, all of the same characters, varying in size from a pea to a dime or slightly larger, and chiefly about face, is recorded by Elliot,[1] which could be well described by the name lupus annularis. In other cases, somewhat rare, the eruption, instead of being

FIG. 144.—Lupus vulgaris involving the entire face, scalp anteriorly, and the ears; there is also a tubercular patch on the upper part of the arm; many years' duration, slowly progressive (courtesy of Dr. L. A. Duhring).

limited to one or two regions or areas, is quite generally distributed (**lupus disseminatus**). Crocker refers to a case, a boy aged ten, in whom there were 47 variously sized patches scattered over the whole body; and Morrow,[2] a case, a woman of twenty-two, in whom the disease developed some years previously, exhibiting, with some caseating glands, various plaques of extensive distribution; and Fordyce,[3] in a man aged twenty-eight, in whom it had first appeared at the age of four, and involved the whole face and neck, with numerous patches over the arms, chest, back, etc. Some years ago, when associated with Professor Duhring, I saw in his clinic a case of a Hungarian

[1] Elliot, *Jour. Cutan. Dis.*, 1896, p. 476.
[2] Morrow (case demonstration), *ibid.*, 1895, p. 259.
[3] Fordyce (case demonstration), *ibid.*, 1900, p. 119.

woman of twenty-one in whom a large part of the entire surface was involved, on the legs the disease forming one continuous covering, with, however, but little tendency to ulceration; and also recall several instances of almost universal distribution in the clinics of Hebra, Neumann, and Kaposi during my student days in Vienna. Such cases are, however, extremely rare in our own country; less so in the European capitals. In rare instances a verrucous or papillomatous tendency is noted in cases showing scattered patches, with but few or no typical lupus nodules, closely allied to or identical with tuberculosis verrucosa cutis.

In other instances lupus vulgaris areas are found associated with various other tuberculous integumentary lesions and other signs of

FIG. 145.—Lupus (tuberculosis cutis) of papillomatous type; in a negro youth of eleven; duration two to three years; has yielded almost completely to X-rays.

tuberculosis. White[1] briefly details 10 such cases, which had been under his direct care, in which one or more clinical forms of tuberculosis were present in association with lupus vulgaris, such as caseating and ulcerating glands, tuberculosis verrucosa, tuberculous dactylitis, etc. Wickham[2] relates a case in which three forms were present: lupus vulgaris on face, tuberculosis verrucosa cutis on hands and feet, and these two forms about one knee, and tubercular abscesses—tuberculous gummata—on face and hands; and Brousse and Ardin-Delteil[3] had under observation a somewhat similar case, a girl aged sixteen, in whom the cutaneous lesions, following a disease of the bone of the right toe when aged four, consisted of a tuberculosis verrucosa cutis

[1] J. C. White, "Clinical Aspects and Etiologic Relations of Cutaneous Tuberculosus," *Boston Med. and Surg. Jour.*, Nov. 12, 1891, p. 509 (an excellent presentation and review of the subject).

[2] Wickham, Paris letter, *Brit. Jour. Derm.*, 1890, p. 337.

[3] Brousse and Ardin-Delteil, *La presse méd.*, 1898, No. 32, p. 189.

of the right foot and leg, an area of lupus vulgaris on the left cheek, and a tuberculous gumma of the side of the face. W. G. Smith[1] describes an unusual case in which lupus of the ordinary type was seated about the nose, symmetric exostoses on nose and fingers, and on the latter also pulpy nodosities, and a psoriasis-like eruption on the body and limbs, apparently leaving scars; the true nature of this last was obscure. In rare instances, however, the lupus lesions do present a psoriatic aspect, designated by Hutchinson lupus-psoriasis. Colcott Fox[2] recently recorded an example of this variety in a girl under three years in whom there were two patches on the left knee and three on the right; three on each buttock, very closely symmetric; one on the point of left elbow; one on the back of right heel; three on dorsum of left hand and fingers; and one on the back and on the flexor aspect of the right wrist, and one on right thumb, the bilateral, and to some extent symmetric localization, and the size and character of the patches simulating psoriasis. In these rare cases, however, there is usually greater and denser infiltration, with well-defined and infiltrated edges, than observed in this latter disease. Sooner or later, as a rule, there is atrophy or scarring, and sometimes ulcerative tendencies develop, as in a patient under my own observation, a young girl aged eight, in whom the lesions, seated about the neighborhood of both knees, were scaly and psoriatic in general appearance, although tending to crowd together; several years later these gave place to ulcerations of scrofulous aspect, and also simulating those observed in erythema induratum and in syphilis.

The neighboring lymphatic glands in lupus cases, if of any extent, sometimes, although not frequently, show inflammatory swelling and enlargement, and tend to break down and suppurate, but, as a rule, this is observed only in those instances in which ulceration is a feature, and often due, doubtless, to the added pyogenic factor in the case. It has been shown by Leloir,[3] however, that in addition to adenitis due to inflammatory products there is gland involvement due to direct tuberculous infection or transference from the lupus area; in 7 cases examined by him this was established both by microscope and inoculation experiments.

There are no constitutional symptoms in lupus, unless from an associated internal tuberculosis; the occasional and probably, one might say, frequent occurrence of other tuberculous processes, usually of the lungs, noted will, as is to be expected, give rise to some general symptoms. Lespinne[4] has observed infective intoxication occur at times, with rise of temperature, etc., and some suspicious pulmonary signs, due, he considers, to the absorption of the products of the bacilli; from which, however, as a rule, no organic disease results; during such attacks he has further noted that the lupus patch shows some reactionary symptoms similar to those observed after tuberculin injection.

[1] W. G. Smith, *Brit. Jour. Derm.*, 1897, p. 187.
[2] Colcott Fox, *ibid.*, 1898, p. 329 (case demonstration).
[3] Leloir, abs. of paper, *ibid.*, 1890, p. 55.
[4] Lespinne, *Jour. mal. cutan.*, Oct., 1891, p. 531.

The **course** of lupus has already been inferentially stated. It is almost invariably a slow disease, appearing insidiously and from week to week or month to month with scarcely perceptible progress. Frequently it develops gradually, but often with periods of apparent quiescence, into a variously sized patch of a dime to that of one several inches in diameter, and then remains stationary for a time; from occasional partial subsidence of the inflammatory element retrogression sometimes seemingly, and possibly with certainty, is observed now and then, but, upon the whole, the malady gradually extends, showing no tendency to disappear. Its presence, as a rule, gives rise to but little trouble beyond its disfigurement, subjective symptoms being practically absent, or not sufficiently annoying to give rise to complaint; the ulcerations, especially when a decided pyogenic character is added, sometimes are painful and sensitive. Enlarged, swollen, and inflamed and caseating glands may result in some cases, and general tuberculous infection may eventually ensue. As we see the disease here, however, and for the most part elsewhere, the patients are but little disturbed in a general way by the presence of the local tuberculous process. Occasionally, it is true, the open lesions seem to favor the development of erysipelas; and later in life, in some instances, an epitheliomatous degeneration sets in, and the malady then acquires a more serious character, especially as lupus tissue seems to permit of rapid epithelial involvement and destruction, often of a malignant type. I have met with one case of this kind involving the face which, after

FIG. 146.—Lupus vulgaris of extensive development; areas on nose, ears, trunk, and thighs (courtesy of Dr. M. B. Hartzell).

many years, became epitheliomatous and ran a rapid and malignant course. Dubois-Havenith[1] in 118 cases noted this complication 5 times. Fordyce[2] records a case in which an endothelioma developed in scar tissue.

Etiology of Cutaneous Tuberculosis.—The disease, more especially the ordinary type—lupus vulgaris—to which most of these remarks apply, is common in some parts of the world—as, for example, in Austria—and somewhat infrequent in others—as, for instance, in our own country. The reasons for this are not perfectly clear, although doubtless it is mainly to be found in the different methods of living, the character of the food-supply, and other causes not known. Great Britain also furnishes a large number of cases compared to this country. The worst cases in this country, moreover, are usually found among the foreign-born population. It is much more common in females than males—at least two or three to one. It usually has its beginning in the first periods of life, as in childhood and early adolescence; to this, however, there are exceptions, although it is rare to see it beginning after middle age. In Colcott Fox's[3] analysis of 96 hospital cases under his observation, more than half began before the age of ten, and 30 of these under five, and of the latter, 5 in the first year; 10 began after the thirtieth year, and of these, 4 after the fortieth. Of the 96 cases, 64 were females. Tuberculosis verrucosa and tuberculosis ulcerosa are often first seen later in life, and exceptionally lupus may begin at that period.[4]

The direct cause of the disease, as first demonstrated by the findings of Demme, Doutrelepont, Pfeiffer, and Koch, and since by many others, is the tubercle bacillus, a view which already had much support in the clinical association with other tuberculous processes. In fact, the clinical evidence of its tuberculous nature is to-day sufficiently large to be in itself convincing. Bender[5] found in 159 cases in which inquiry was made, there were 99 (62.3 per cent.) patients in whom present or past evidences of tuberculosis existed; hereditary predisposition was noted in 33.3 per cent.; and at the time of examination in 77 cases other signs of tuberculosis were present; 2 of his cases, while under observation, died of other forms of the disease—1 of laryngeal and pulmonary tuberculosis, and the other of tuberculous meningitis combined with caries of the petrous bone. Colcott Fox in his series also noted the frequency of family history of consumption, and in 33 of the 96 cases there were evidences of the exist-

[1] Dubois-Havenith, *Du lupus vulgaire*, Brussels, 1890 (an exceedingly valuable monograph with a good review of etiology, pathology, and treatment).

[2] Fordyce, *Amer. Jour. Med. Sci.*, Aug., 1900.

See also the excellent monograph, *Épithéliome et Lupus*, by Desbonnets, Paris, 1894 (contains a review of reported cases); also Hutchinson's paper, "Notes on Cancers and Cancerous Processes," *Archives of Surgery*, vol. ii., 1890-91, p. 138 (details several cases of his own and refers to 6 cases observed by others).

[3] Colcott Fox, "On the Nature of Lupus Vulgaris from a Clinical Standpoint," *Westminster Hospital Reports*, 1893, p. 23.

[4] See papers by Colcott Fox (Four Cases of Senile Tuberculosis of the Skin), *Brit. Jour. Derm.*, 1892, p. 160; and by Travers Smith (Lupus and Senile Struma), *ibid.*, p. 162. Colcott Fox refers to several other contributions on the subject.

[5] Max Bender, *Deutsche med. Wochenschr.*, June 17, 1886.

ence of glandular disease of some kind; 16 per cent. of the patients suffered at some time from scrofulous gummata. In Block's[1] 144 cases 114 were affected with some form of tuberculous disease, either prior to the attack (about 28 cases) or following it. In the series reported by Sachs,[2] out of 115 patients there were only 15 in whom no past or present or hereditary tuberculosis could be found.[3] Single reported examples suggestive of its tuberculous origin are innumerable. A striking one is that referred to by Walsh,[4] of a young woman with lupus upon the face and other tuberculous symptoms, whose father died of phthisis, her mother of bronchitis, and eight or nine brothers of pulmonary tuberculosis. Winfield[5] records a case of a subject with pulmonary tuberculosis, in whose wife and daughter lupus developed. Howe[6] has also reported some suggestive examples. Such instances, often less striking, it is true, are common in the experience of all observers, and dermatologists of the present day are in accord as to their significance.

Further evidence is to be found in examples of contagion or accidental inoculation and also in the success of experimental inoculation. Several of the former may be referred to. White[7] has observed a number of cases in which lupus was presumably due to the inoculation of tuberculous matter, 12 cases within a period of three years. Corlett[8] also met with such an instance; Jadassohn[9] records 2 cases, 1 from a tuberculous ulcer and the other from a phthisical tattooer; Dent[10] observed 3 cases of the disease develop in three sisters who slept in the same room, while the other eight children of the family were free—the malady apparently originally arising from a preexisting tuberculous ostitis in one of the patients. Wild[11] has recently called attention to suggestive examples: 4 of lupus of the lobule of the ear following ear-piercing; 3 cases of tuberculosis verrucosa cutis of the hands in laundresses who had washed linen from tuberculous individuals; several cases of the same type, and 1 of lupus vulgaris, which apparently originated from tuberculous patients in the same households. Elliot's[12] case of tuberculosis verrucosa in a woman aged seventy is also an example of contagion; the disease, which was on the back of the hands, developing after nursing and washing the

[1] Felix Block, *Archiv*, 1886, vol. xiii., p. 201 (also gives the age at which disease began, as well as regions affected, practically similar to the observations made by Bender and Colcott Fox).

[2] Sachs, *ibid.*, p. 241.

[3] See interesting paper by J. C. McGuire (Lupus Vulgaris: Its Relations to Tuberculosis), *Jour. Cutan. Dis.*, 1891, p. 264, with review of this question, and interesting replies concerning it from various authorities; also Payne's address on Lupus, full abs. in *Brit. Jour. Derm.*, 1891, p. 369.

[4] D. Walsh, *Brit. Jour. Derm.*, 1898, p. 19 (case demonstration).

[5] Winfield, *Jour. Amer. Med. Assoc.*, Dec. 12, 1896, p. 1220 (with illustrations).

[6] Howe, "Thirteen Cases of Tuberculosis of the Skin," *Jour. Cutan. Dis.*, 1892, p. 303.

[7] J. C. White, *loc. cit.*, cites other cases from literature.

[8] Corlett, *ibid.*, 1893, p. 146.

[9] Jadassohn, *Virchow's Archiv*, vol. cxxi., 1890, p. 210.

[10] C. J. Dent, *Brit. Jour. Derm.*, 1891, p. 156.

[11] Wild, "Some Sources of Infection in Cutaneous Tuberculosis," *Brit. Med. Jour.*, Nov. 11, 1899, p. 1353.

[12] Elliot, *Jour. Amer. Med. Assoc.*, Jan. 12, 1889, also quotes statistics showing frequency of pulmonary tuberculosis in association with the cutaneous lesions.

linen of a phthisical son. I have had several young children with beginning face lupus as patients, in families in which tuberculous individuals lived and by whom they had been frequently nursed and caressed. Ware[1] reported an additional instance of tuberculous inoculation following ritual circumcision, and states that there is a record in literature of 21 such cases—and I believe probably even a greater number, as Dubreuilh[2] collected 17 cases of tuberculosis of the penis consequent upon this religious rite by consumptive operators. That lupus and other cutaneous tuberculoses occasionally, although not frequently, arise at the point of vaccination has been shown by Besnier[3] and others, and quite recently another probable case came under Perry's[4] observation, and 1 also under Little's[5] notice, to which I can add 1 of my own (the sister of a physician), the disease making its appearance shortly after that procedure in early childhood, and when coming under my care, ten or twelve years later, it had reached the size of a palm. To this overwhelming evidence of the tuberculous character of these various cutaneous processes and the communicability of the disease must be added the success of experimental animal inoculation, notably by Leloir[6] and Eve,[7] and the reactionary symptoms brought about by tuberculin injections.

Pathology of Tuberculosis Cutis.—The tubercle bacillus, being the accepted cause of the disease, its mode of entrance into the cutaneous tissues other than by direct inoculation already referred to remains to be solved. Sticker[8] believes that in lupus, as well as in leprosy, the primary lesion or infection is in the nose, and through the lymphatics to the skin, and this, in face cases, which constitute the overwhelming majority of cases, seems, as also suggested by Leredde,[9] Meneau and Frèche,[10] and others, not improbable. Leloir[11] believed the bacillus gains access to the integument in one of the following ways: (1) By direct inoculation from without; (2) indirect inoculation by continuity from deep tuberculous foci; (3) inoculation by way of the lymphatics or the veins passing through a tuberculous focus more or less remote; (4) infection of hematic origin; (5) infection by inheritance; the first two being probably, as I believe myself, the usual methods. Besnier, quoted by Leloir, holds the view that the tuberculous ulcer of phthisical patients is secondary to general infection, while lupus and tuberculosis verrucosa cutis are the result of external inoculation.

It is doubtless probable that weakened tissue and regions disposed to circulatory disturbance show less resistance to invasion. As in lupus erythematosus, the "flushing" parts, as the cheeks, nose, ears,

[1] Ware, *New York Med. Jour.*, Feb. 26, 1898.
[2] Dubreuilh and Auche, *Archives de méd. exper. et d'anat. patholog.*, Sept., 1890, p. 601; abs. in *Annales*, 1891, p. 95 (in all, 60 collated cases of integumentary inoculation).
[3] Besnier, "Lupus Vaccinal," *Annales*, 1889, p. 576.
[4] Perry, *Brit. Jour. Derm.*, 1898, p. 196 (case demonstration).
[5] Graham Little, *ibid.*, 1900, p. 60 (case demonstration).
[6] Leloir, *Comp.-Rend. et Mémoire de la Soc. de Biol.*, 1882, p. 843.
[7] Eve, *Brit. Med. Jour.*, 1888, i., p. 644.
[8] Sticker, *Dermatolog. Zeitschrift*, 1898, vol. v., H. 6.
[9] Leredde (Hallopeau et Leredde, *Traite pratique de Dermatologie*, p. 468).
[10] Meneau and Frèche, "Origine nasale du lupus de la face," *Annales*, 1897, p. 516,
[11] Leloir, *Brit. Jour. Derm.*, 1894, p. 298.

etc., and dependent situations, where the circulation is sluggish, as the extremities, and regions weakened by chilblains, are most vulnerable. These are, it is true, the parts which are most exposed to injury and to inoculation. Its tendency to appear primarily at the site of injuries or in scar (weakened) tissue has also been noted, both by Crocker and Malcolm Morris; in their treatises they refer to this, and an example has been lately reported by Walsh,[1] the disease making its appearance some years after the scars had been produced. Hutchinson[2] is disposed to believe, in view of its frequently beginning after slight injuries, that a stage of congestion and cell effusion, indistinguishable from common inflammation, usually precedes for a short period the characteristic growth. The arising of new points or foci beyond the main patch is doubtless due, as suggested by this writer, to the bacilli or their products spreading either in the perivascular spaces or along the lymphatic channels. It is difficult, however, to explain the varying clinical conditions found in cutaneous tuberculosis, but the individual nutrition, resisting power, and possibly virulence of the bacillus may be of some importance. A striking fact, however, is that in most instances there is but a single type in the individual case, distinct and clean cut throughout, only occasional cases being observed in which several of the manifestations are present in the same patient; and according to my own observations, this latter seldom occurs so primarily. So distinctive are these types usually that the possibility has often suggested itself that, after all, we may be dealing with several varieties of bacillus, apparently morphologically and biologically the same, according to our present methods, but which later refinements may lead to differentiation. But a few years back the various types of ringworm were thought to be due to one and the same fungus, but investigation, research, and microscopic and bacteriologic investigations have since demonstrated the incorrectness of this view and given explanation for the several clinical varieties. Leloir and Tavernier's[3] opinion as to the forms or certain phases of lupus seems to me to offer a partial explanation of these cases—that it is due to the combined action of the bacillus of Koch and suppurative agents. They believe that there are two microbic processes—(1) neoplastic, due to the irritation of tubercle bacillus, and (2) suppurative, due to the staphylococcus aureus, the latter, determining the presence or absence of the ulcerative feature, not being found in the non-ulcerative form.

In lupus the bacilli are seen in extremely scant numbers, sometimes scarcely to be found, in others not more than a single bacillus in a cell (Cornil and Leloir). It is possible that the bacilli may undergo rapid destruction, or that the morbid action results from their products or toxins. In other forms of cutaneous tuberculosis the bacilli are often found in greater abundance, and this is especially so in the more acute lesions—as, for instance, in the type described as tuberculosis ulcerosa.

[1] Walsh, "A Case of Lupus in Symmetrical Seton Scars," *Brit. Jour. Derm.*, 1894, p. 365.
[2] Hutchinson, *Brit. Med. Jour.*, Jan. 7, 14, and 21, 1888.
[3] Leloir and Tavernier, *Jour. mal. cutan.*, Oct., 1891, p. 543.

The pathologic histology of cutaneous tuberculosis, more especially lupus vulgaris, has been studied by numerous investigators (Virchow, Auspitz, Lang, Kaposi, Friedländer, Thin, Jarisch, Leloir, Unna, Bowen, and others), whose findings and interpretations in the main and essential points coincide. Bowen,[1] a careful and well-known dermatologist, has given us an admirable and terse review and summary, based upon the work of others and his own observations, and from which I shall largely quote verbatim.

The disease has its starting-point in the corium, affecting primarily the lower portions, progressing upward by extension of the foci of disease, and causing, in most instances, secondary and non-specific alterations of the epithelial elements. The first appearance of the lupus tissue is found to be an accumulation of cells, situated about the capillaries and lymph-channels, in many cases representing a growth of the adventitia of these vessels, and constituting the primary nodule or point of infiltration—of so-called granulation tissue—made

FIG. 147.—Lupus vulgaris section (low power): *e*, Epidermis; *c*, *c*, *c*, corium, infiltrated with the tuberculous neoplasm; *g*, *g*, Langhans' giant-cells (courtesy of Dr. J. T. Bowen).

up of the peculiar cell-formations more or less characteristic of tuberculous processes: small round cells, found abundantly at the periphery of the nodule; larger, epithelioid cells, with clear nucleus, and the so-called giant-cells, with homogeneous center and peripherally arranged nuclei. The epithelioid cells are fewer in number, and the giant-cells in larger representation than is observed in the classic tubercle of tuberculosis; there are, moreover, more vascularity and a greater formation of connective tissue. Unna believes that many of the small round cells at the periphery of the lupus nodule are not leukocytes, but early derivatives of the connective-tissue cells; he regards these as identical with the "plasma cells" of Waldeyer, and distinct from Ehrlich's mast-cells. He has named these cells plasma cells, and holds that they are the first appearances in various chronic inflammatory and infectious processes. This view is not, however, generally accepted. It would seem probable, as Bowen states, that the

[1] Bowen, "The Pathology of Cutaneous Tuberculosis," *Boston Med. and Surg. Jour.*, Nov. 12, 1891, p. 516; and Morrow's *System*, vol. iii. (Dermatology), p. 535.

fixed tissue-cells are, at least in the main, the parents of the epithelioid and giant-cell formations. This giant-cell, when discovered in lupus nodules by Friedländer, was, with cheesy degeneration of the nodule, thought to be characteristic of tuberculous lesions, but it is now known to be present in other pathologic processes, notably in the gummatous and small papular syphilitic lesions; still its presence, especially when considered in connection with the other histologic features, and with their formation and development, is of special significance. The feature that is absolutely pathognomonic, however, is the bacillus, which is constantly present, though sometimes sparingly.

The next stage in the history of the lupus nodule is the degeneration of the newly formed cells and of the fibrillary tissue. The

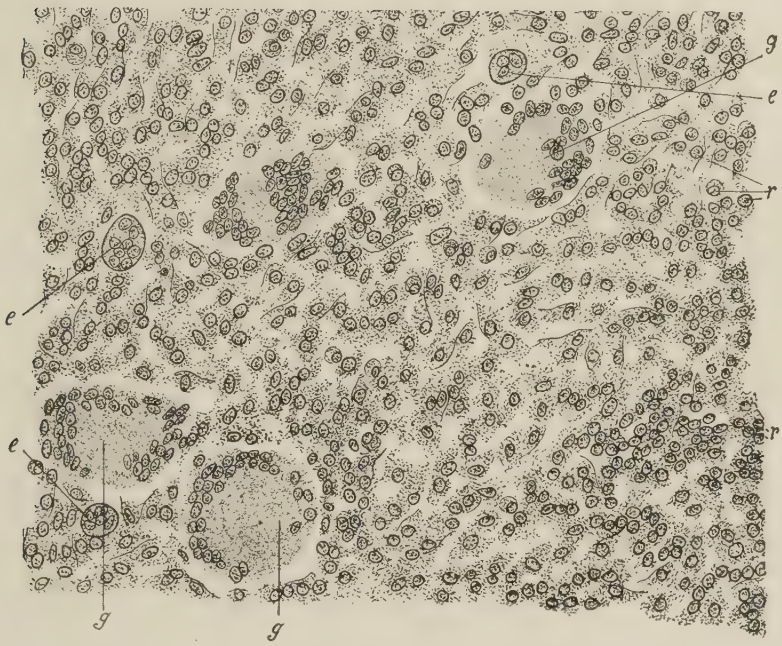

FIG. 148.—Lupus vulgaris section (high power): *g, g, g,* Langhans' giant-cells; *e, e, e,* epithelioid cells; *r, r,* small round cells (courtesy of Dr. J. T. Bowen).

cells lying in the center of the nodule are the first to be affected, their protoplasm becomes homogeneous, while the nuclei lose to a certain extent their susceptibility to staining. Following Weigert, the cells in lupus, as in internal tuberculosis, are regarded as undergoing a coagulation necrosis, although this view is opposed by Unna. At all events the tuberculous elements undergo necrotic degeneration in consequence of the toxic influence of the bacilli; owing to the small numbers of the latter, it is of slow progression. Together with this degeneration in the epithelioid cells there is also a regenerative process—the cells are capable of proliferation when not affected by the virus to the extent of advanced degeneration, and may finally become converted into connective tissue. In this

manner is produced the lupoid scar tissue, which, however, Unna considers distinct from ordinary scar tissue; inasmuch as there is never a reproduction of elastic fibers, the connective tissue is never arranged in intersecting bundles, but placed horizontally to the surface, and it contains numerous large "cell spindles" rich in protoplasm. If this regenerative connective-tissue process is excessive, the hypertrophic or elephantiasic feature of the disease sometimes observed results. Proliferation of the epithelial elements is also at times noted, which Bowen considers an accidental and secondary process; the interpapillary downgrowths deep into the corium, with the outgrowth of the papillæ, explain the papillomatous forms. Lang also pointed out the occasional proliferation of the glandular elements.

When the tuberculous infiltration of the corium reaches a certain grade of intensity and the overlying epidermis is stretched and

FIG. 149.—Tuberculosis verrucosa section: *h*, Hypertrophied horny layer, dipping down into the corium; *p*, epithelial downgrowths, with enlarged papillæ between them; *g*, giant-cells; *e*, enlarged papillæ (courtesy of Dr. J. T. Bowen).

thinned, a fracture of the latter frequently ensues, and the disease foci are exposed and ulcerations result. In such instances, as noted by Leloir and Tavernier, there is probably, frequently at least, an added septic process, due to the presence of pus-cocci.

In the lesions of tuberculosis ulcerosa (miliary tuberculosis of the skin), as Bowen states, the cutis is found to be filled to a considerable depth with foci of small round cells, with occasional epithelioid and giant-cells. In the center of these foci the necrosis has progressed rapidly, so that upon macroscopic examination the appearances of softening and cheesy degeneration are apparent. The

tubercles often, by their coalition, form masses of softened and necrotic tissue, in which the evidences of unaltered granulation tissue can be found only in the outlying parts. In the cases examined by Bowen the bacilli were present in large numbers, in one instance every field containing enormous masses, according, as he states, with the observations of Riehl, Doutrelepont, and others.

In scrofuloderma, according to Bowen, the anatomic characters differ in no essential way from tuberculosis of the internal organs; granulation tissue of small round and epithelioid cells, with a moderate quantity of giant-cells, has its seat in the subcutaneous tissue, undergoes degeneration, and may break through the thinned and tense layers of the epidermis above, giving rise to the characteristic ulcer of this type. The degeneration is, as a rule, much farther advanced than in lupus, large areas of necrotic, softened tissue being usually visible under the microscope. The bacilli in some instances are scanty, in others numerous, and generally much more so than in lupus, and in less abundance than in tuberculosis ulcerosa.

In tuberculosis verrucosa the findings of Riehl, Paltauf, Bowen, and others practically agree. Bowen states that the chief anatomic characteristic of this form, in distinction from the papillary growths of lupus, is the situation of the tuberculous neoplasm; while in the latter the foci of granulation tissue lie in the lower and middle portions of the corium, in tuberculosis verrucosa they are quite constantly found in the upper papillary layers, usually in the papillæ themselves, and this corresponds to the observations of Riehl and Paltauf. Moreover, the papillary outgrowth is an early feature of the process, appearing at the very beginning: in lupus, on the other hand, it is met with at a later period, and, as a rule, only when ulceration has taken place. As Bowen adds, many transitional forms occur, and it may be difficult, in some instances, from microscopic examinations alone, to determine which of these two clinical varieties is represented. A characteristic of the typical process, however, in most cases distinguishing it from other forms, is the occurrence of foci of acute inflammation immediately below the rete, and the formation of miliary abscesses, a secondary phenomenon due to the invasion of micrococci; in some cases, however, Bowen has noted this secondary inflammation to be very slight or entirely wanting. Bacilli are found readily in some instances; in others a good deal of careful search is necessary; and in this respect, while some observers have noted the contrary, Bowen, in his examinations, was not able to demonstrate a striking divergence from lupus.

Diagnosis of Tuberculosis Cutis.—The diagnosis of the types of tuberculosis cutis other than lupus vulgaris has been sufficiently touched upon; these remarks, therefore, concern the latter, the form with which practitioners are most likely to come in contact. The peculiar yellowish-red infiltrated macule, point, or tubercle of soft consistence, readily disturbed by slight pressure with a probe or blunt instrument, is an important characteristic of this type, and in itself often sufficient for the diagnosis. The diseases of the skin with which lupus vulgaris is sometimes confounded are epithelioma, more espe-

cially of the superficial or rodent ulcer type, and syphilis; its confusion with lupus erythematosus, acne rosacea, and eczema is much less probable. The difference between this disease and blastomycetic dermatitis will be referred to under the latter.

As to epithelioma, it differs from lupus in the following particulars: it is usually single, begins commonly late in life, has a peculiar pearly, roll-like, or markedly infiltrated border; it frequently arises from a preexisting mole or wart, or from a circumscribed, long-continued, scurfy or crusted spot; the ulceration begins almost invariably at one point, and is often somewhat deep, with frequently, and always sooner or later, considerable loss of substance; its course in some cases is slow, but in others, after the disease is once established, is frequently quite rapid.

The tubercular syphiloderm in many cases bears considerable resemblance to lupus—in fact, these two diseases are often strikingly similar in their symptomatology, and occasionally even the trained specialist may for a time be puzzled. I find that with general practitioners the admitted respectability of a patient, especially if a woman, is permitted to have too much weight, and leads often to an erroneous diagnosis of lupus. It is not to be lost sight of, however, that syphilis is often innocently contracted—as, for example, through the marital relation. An important clinical fact bearing upon the diagnosis between these two diseases is that lupus vulgaris is in this country comparatively rare, and that the physician is much safer and almost always right in considering a tubercular eruption with atrophic or ulcerative tendency appearing in adult life to be syphilitic rather than that of lupus, unless there are conclusive reasons for considering the contrary; and in a surprisingly large number appropriate treatment will confirm the tentative diagnosis by the extremely rapid improvement which ensues. Generally speaking, however, a careful study of the symptoms presenting will render a purely arbitrary and unscientific method unnecessary, for in almost all cases there are sufficient differences which will serve to prevent mistakes. The common site of lupus is the face, and while it may appear elsewhere independently, as a rule, when occurring upon other parts, it is in conjunction with the disease upon the former region. The tubercular syphiloderm, on the other hand, occurs upon almost any part independently, although it cannot be denied that the face is quite a frequent seat. This manifestation of syphilis being usually a late one, is, for obvious reasons, more commonly observed toward middle or late life; lupus, in most instances, has its start in childhood and early adolescence, and is somewhat rare in beginning after thirty or forty. The color of the syphilitic eruption is a darker red, more of a coppery-red, while that of lupus is more of a yellowish-red or brownish-red color. The former is relatively more rapid in its course, and in a few years' time may cover several square inches, whereas in lupus several years often elapse before more than a silver-dollar-sized area is covered. In syphilis crescentic and serpiginous groupings, crescentic and horse-shoe-shaped ulcerations are almost invariable: in lupus such conditions or configuration are uncommon.

The ulcerations of syphilis may be superficial or deep, those of lupus almost uniformly shallow; there is usually a moderately or profusely abundant purulent discharge in the ulcerations of the former, whereas in lupus destruction it is, as a rule, scanty—sometimes extremely so. In the former disease bone may become involved in the destructive process; in lupus such destructive action is rarely seen. In lupus the cicatricial formation is often thick, dense, and tough, whereas in syphilis it is usually soft, and when compared to the sometimes preceding extensive ulceration, insignificant.

In the non-ulcerating forms of lupus and tubercular syphiloderm the differentiation is often fraught with greater difficulty than in the more common or ulcerating types. Most of the facts pointed out, however, are also of service here. The history of the case is sometimes valuable: in lupus not infrequently the patient comes of a tuberculous family, with a history of consumption in the immediate or collateral branches; sometimes an examination of the patient will disclose other evidences of a scrofulous character, such as scars of a cervical adenitis, marks of a keratitis, or even tuberculous involvement of the lungs. On the other hand, in syphilis, upon careful inquiry or inspection, evidences or history of preceding characteristic phenomena of that disease may usually, but by no means always, be elicited. As already stated, however, it must be admitted that in rare instances the several differences mentioned as distinguishing these two cutaneous diseases are practically lacking, or sufficiently so as to make a positive diagnosis without further observation of the case almost impossible. Nor are the differences as given absolute, as exceptions as to character, course, etc., are encountered in both affections. In such instances, and in fact in all except those cases in which the diagnosis can be made without difficulty and with certainty, the general physician is much safer in withholding an opinion or expressing himself guardedly, and in the mean time treating the patient as if the disease were of syphilitic origin. When, in obscure cases, a positive conclusion is urgent, resort may be had to the tuberculin test, but such would scarcely be justifiable if a skilled opinion was within reach.

Lupus vulgaris differs from lupus erythematosus chiefly in the presence of papules, tubercles, and often ulceration and tough fibrous scarring, all of which are wanting in this latter disease; moreover, the former is lacking in the patulous or stuffed-up gland-ducts and the firm yellowish-gray adherent scales, so commonly noted in lupus erythematosus. Lupus vulgaris is almost always deeper seated. Lupus vulgaris erythematoides of Leloir bears a close resemblance, but here also the deeper infiltration and the lupus infiltrated points or nodules which can generally be recognized when the skin is put upon the stretch serve to distinguish it from lupus erythematosus.

Acne rosacea merely exhibits an apparent similarity, but the dilated vessels, acne lesions, and history and course, with absence of any tendency to destructive action, are sufficient to prevent error. Both scaly eczema, when rather sharply circumscribed, and psoriasis patches bear some likeness to non-ulcerative or exfoliative lupus, but

the infiltration of the latter and its scant scaliness, its slow, sluggish course, and persistence in the same spots will usually prevent all possibility of such a mistake. Moreover, the itchiness of eczema and its occasionally frequently presenting a disposition to gummy exudation, and the more or less general distribution of psoriasis, are further points.

Prognosis of Tuberculosis Cutis.—As to the prognosis of lupus vulgaris, much depends upon the age of the subject, duration of the disease, extent of the territory involved, and the thorough cooperation of the patient. It is always a chronic disease, usually exceedingly rebellious to treatment, and one that calls for a guarded opinion; moreover, relapses, sometimes due to inefficient or insufficiently radical treatment, are not uncommon. According to my experience, however, small beginning areas of the disease, especially in the young, are usually readily curable, and, as a rule, show no tendency to relapse if treatment has been sufficiently thorough. The same holds true with small areas in the adult; and in areas of large size, more especially in American born, permanent results are not unusual, although not infrequently one or two relapses may occur before this favorable termination is reached. In cases of considerable extent, if treatment is persisted in, the final result is often satisfactory, even though outcroppings of tubercles in the scar tissue, or at the edge of the patch, as generally observed, recur several times and call for further measures. One might feel hopeful of more extensive cases if the patient's continued cooperation were given, but in many such instances the repeated disappointments experienced from the recurrent evidences of the disease often lead to a total abandonment of medical aid. It is true that in such cases the prognosis must be guarded, for even with well-directed and persistent treatment the malady is frequently rebellious and recurrent; and occasionally, too, when the area involved is comparatively small, it is likewise noted to be extremely obstinate. Fortunately, lupus does not thrive as well with us as elsewhere, and when it does occur, it is noted to be, as a rule, less virulent and progressive, and generally yields much more readily to therapeutic measures than is observed in those countries where the disease is more common.

The danger of general infection is not to be forgotten, although in most cases the health usually remains good and uninvolved; on the other hand, death from tuberculosis of the lungs or general tuberculosis has been, as already stated, noted in some instances, probably more frequently than is commonly believed. The statements under etiology as to the frequency of the systemic tuberculous association are convincing on this point, and to these may be added the observations of Besnier and Leloir;[1] the former noted that 21 per cent. of his lupus patients died of consumption, and the latter refers to a number of instances in his own experience in which pulmonary tuberculosis followed lupus through the medium of the lymphatic system.

[1] Besnier (Le lupus et son traitement), *Annales*, 1883, p. 377; Leloir, "Les rapports du lupus avec tuberculose," *ibid.*, 1886, p. 328.

The prognosis as to the other forms of cutaneous tuberculosis has been already incidentally touched upon. As a rule, they are, excepting the small pustular scrofuloderm and disseminated type, more amenable to treatment, unless very extensive. The same possibility, however, to general infection exists. The prognosis of miliary tuberculosis of the skin is, as stated in its consideration, always grave.

Treatment of Tuberculosis Cutis.—While the remarks as to treatment are more especially directed to that of lupus vulgaris, they apply also to the other forms, modified of course to suit the different conditions presenting. The most expedient methods for the latter have been briefly referred to in connection with the description of these other varieties.

The rational management of lupus keeps in view the supervision of the patient's general health, together with the employment of local measures having as an object destruction or removal of the diseased tissue. As a rule, but little stress is placed by most writers upon **constitutional treatment,** but in accepting the tubercle bacillus as the essential factor of the disease, with the frequent association of allied and systemic tuberculous affections observed, the importance of general measures (not necessarily medicinal) cannot, in my judgment, be ignored, if the best results are to be attained. In short, the patient, as well as his cutaneous disease, must receive attention; good, nutritious food, fresh air, outdoor exercise, and plenty of sunshine, with, in many cases, the administration of such remedies as cod-liver oil, hypophosphites, iron, quinin, and other alterative tonics. Judged by my own experience, cod-liver oil in small or moderate doses long continued is the most valuable of the internal remedies, and has in some cases a material influence in limiting the spreading or active tendency of the disease, and in aiding toward making the results from local treatment more permanently favorable; in other words, rendering the soil a less favorable habitat for the bacillus. The hypophosphites have also proved of service.

Other remedies have likewise been credited with favorable effect. The syrup of the iodid of iron is one which has had some support, and Liveing commended 3 to 5 minims (0.18–0.3) of tincture of iodin, sometimes associated with a few drops of Fowler's solution. Duhring[1] believes that potassium iodid favorably influences some cases; and also speaks well of iodin and phosphorus, in combination with cod-liver oil. Lately Philippson[2] stated that the internal use of parafluorbenzoate of sodium, in 7- or 8-grain doses (0.465–0.533) three times daily, acts favorably; and Stepp[3] commends fluoroform ($CHFl_3$), a gaseous substance taken up by water to the extent of 2.8 of its volume, and of this solution the dose is 1 to 4 drams (4.–16.), four or five times daily. Several observers—Bramwell and Taylor[4] and a few others—have seen a favorable influence exerted by thyroid feeding or

[1] Duhring, *Diseases of the Skin*, third edit., 1882, p. 481.
[2] Philippson, *Dermatolog. Zeitschr.*, 1899, No. 3.
[3] Stepp, abs. in *Monatshefte*, vol. xxix., 1899, p. 551.
[4] Bramwell, *Brit. Jour. Derm.*, 1894, p. 345; Stopford Taylor, *ibid.*, p. 345.

thyroidin. Taylor does not consider it safe for out-patients, inasmuch as to obtain satisfactory influence acute thyroidism must be produced; and he further adds that it is only likely to benefit those in which there is much chronic inflammation marking the disease, or where ulceration is taking place. According to Pringle,[1] in cases of lupus in which the hyperemic or inflammatory element is marked, thyroid feeding had given results little short of marvelous in many instances under his observation and without necessarily producing the disagreeable phenomena of thyroidism.

Tuberculin injections, which at one time aroused the hopes of the dermatologic world, have been, undeservedly I believe, almost wholly abandoned, but a careful review of the earlier experiences and recent observations with the new tuberculin show the remedy to be of distinct value in many cases, although its use requires caution and care. Many of the earlier experiments proved, upon the whole, of distinct benefit, but the unfavorable reports of its trial, more especially in St. Louis Hospital, Paris, by Besnier and Hallopeau,[2] and the deaths reported as following its use in lupus,—1 by Hallopeau and 1 each by Jarisch, Burckhardt, and Blanc,[3]—brought it rapidly into disrepute. In the past few years, however, there has been a slight rebound, the new tuberculin being employed, and apparently without injurious results, and with alleged favorable influence upon the disease (Bukovsky, Napp and Grouven, Krzysztalowicz, Ravogli, G. H. Fox, Lustgarten, Wright, and others).[4] An impartial judgment of the facts at hand would seem to me to justify, in recurrent cases which had proved rebellious to other means, the use of the new tuberculin (tuberculin R.—TR.), not with the belief of its being curative in itself, but as a substantial aid in rendering the local measures more effectual. Most observers, among whom those above named,

[1] Pringle, *ibid.*, 1899, p. 433.

[2] Full abs. in Brocq's Paris letter, *Jour. Cutan. Dis.*, 1891, p. 191.

[3] These 3 cases are cited by Piffard (with brief abstracts and references), *ibid.*, 1891, p. 172.

[4] It has recently been tried by the following observers, and in the number and variety of cases stated, usually with favorable, but variable, influence: Bukovsky (Janovsky's clinic), *Archiv*, 1898, vol. xlvi., p. 223 (15 cases lupus, 2 of scrofuloderm, and 2 of tuberculosa verrucosa cutis); Napp and Grouven (Doutrelepont's clinic), *ibid.*, p. 399, with bibliography (39 cases, of which 36 were of lupus, 2 tuberculosis cutis, 1 tuberculosis of tongue; in 2, serious symptoms of collapse without recognizable reason); Krzysztalowicz, *Wien. med. Wochenschr.*, 1898, pp. 59 and 108 (13 cases); G. H. Fox, *Jour. Cutan. Dis.*, May, 1898, p. 232; Lustgarten, *ibid.*; Bussenius and Cossmann, *Das Tuberkulin R.—seine Wirkung und seine Stellung in der Therapie der inneren und äusseren Tuberkulose*, Hirschwald, Berlin, 1898; Adrian, *Archiv*, 1898, vol. xlv., H. 1 (in one of his cases, lupus of the face complicated with chronic nephritis, dangerous symptoms arose); Van Hoorn, *Deutsche med. Wochenschr.*, 1898, No. 27 (greatest improvement between the first dose and maximum dose (20 mg.)—above that failed to influence and sometimes was damaging); Porges, *Wien. klin. Wochenschr.*, 1898, p. 366 (improvement at first); Heron, *Brit. Med. Jour.*, July 9, 1898 (refers to 5 successful cases with old tuberculin, and 1 case with new tuberculin); Starck, *München. med. Wochenschr.*, April 26, 1898 (3 cases—2 cured, 1 unfavorable); Taylor, *Brit. Med. Jour.*, July 9, 1898 (first weeks improvement, later stationary, and then a recrudescence); Ravogli (Tuberculin in Dermatology), *Chicago Clinic*, 1897, p. 143 (favorable influence; with brief review of the subject and some references). See also recent interesting paper by McCall Anderson, "A Plea for the More General Use of Tuberculin by the Profession," *Brit. Jour. Derm.*, 1905, p. 317 (with illustrations), and same paper in French in *Revue pratique*, 1906, p. 175; R. C. Low, "Tuberculin in Diagnosis and Treatment," *Scottish Med. and Surg. Jour.*, May, 1905, and in French in *Revue pratique*, 1906, p. 100.

who have largely employed it, do not claim that it cures, but accord it value as an adjuvant. The first dose should be small and subsequent dosage and frequency regulated by a study of the opsonic index (Wright) of the blood; overdosage and too great frequency, it is to be noted, would lessen the opsonic power, or phagocytosis, and probably do damage, and are therefore to be guarded against.[1]

Injections of thiosinamin have been recommended by Hebra, Jr., using a 15 per cent. alcoholic solution, of which the beginning dose is about ♏iv (0.265) increasing to ♏xv (1.); an injection is administered every two or three days. As with tuberculin, it is to be looked upon as an adjuvant only, and should be combined with suitable local measures. Calomel injections have also recently had some support as auxiliary treatment of value (Asselbergs, Du Castel, Brousse, and Tschlenow),[2] an injection of about $\frac{3}{4}$ of a grain (0.05) in 1 c.c. of sterilized oil being administered, usually in the buttocks, every week or ten days. Fournier[3] is inclined to consider such cases of syphilitic nature, and that the favorable effects are explainable upon an error of diagnosis.

Local Treatment.—The Finsen method and the X-ray are playing an important part in certain centers in the local treatment of this disease, but these are, for various reasons, often inconvenient or impracticable, and, before referring to them specifically, the plans long in vogue and still quite generally employed will be described. These measures can be roughly divided into: (1) mild and stimulating; (2) destructive. In almost all cases the area of apparent disease can be materially reduced by the former, partly by controlling the inflammatory element of the malady, and in some by a possible effect upon the bacilli and their products or upon the added pyogenic organisms. The mildly antiseptic plans are, especially in the crusted and ulcerative forms, in accord with the well-based views of Leloir and Tavernier,[4] referred to. Leloir was therefore accustomed to direct his whole treatment primarily against the staphylococcus aureus as a preliminary to a final more active plan against the neoplastic growth due to the bacillus. If the disease is at all extensive or attended with destructive changes, the use primarily of the mild or non-destructive applications is to be advised. When the hyperemic element is pronounced and there is any irritability, the frequent or constant application of the calamin-zinc-oxid lotion can often be used temporarily with considerable apparent benefit. The continuous application of a good diachylon ointment is also found valuable at this time. One of the best of the milder preparations, however, is an ointment of oleate of mercury, which, in a few instances proved useful in my hands.[5]

[1] For further remarks on this method and literature references, see "Opsonins" p. 108.

[2] Asselbergs, *Annales*, 1898, p. 10 (25 cases; in some cases slight amelioration only, in others marked improvement, and in others complete disappearance); Du Castel, *ibid.*, 1898, p. 674, and 1899, p. 527 (3 cases; 2 cases improvement, 1 uninfluenced); Brousse, *Jour. mal. cutan.*, April, 1890, p. 235 (1 case; favorable effect); Tschlenow, abs.-ref. in *Monatshefte*, vol. xxix., 1899, p. 549 (2 cases; favorably influenced).

[3] Fournier (Pseudo-lupus syphilitique), *Annales*, 1896, p. 854.

[4] Leloir and Tavernier, *loc. cit.*

[5] Stelwagon (Clinical Lecture on Lupus, with illustrations), *International Clinics*, July, 1896, p. 341.

Brooke's[1] formula is the most satisfactory: ℞. Oleate of mercury, 5 per cent., ℥j (32.); powdered zinc oxid and powdered starch, āā ʒij (8.); white vaselin, ʒiv (16.); salicylic acid, gr. xx (1.35); ichthyol, ♏xx (1.35). This can be colored the skin tint by adding 10 to 30 grains (0.65–2.) of calamin or some Armenian bole. If the surface of the involved area is unbroken, this is to be rubbed in for several minutes night and morning, and, when possible, also spread upon lint and kept continuously applied as a plaster; if ulcerated, the latter method is the only feasible one. The constant application of mercurial plaster is also of value in many cases. It is possible the mercurial preparation has a bactericidal action, as Doutrelepont,[2] and later White,[3] had already, from clinical results, pointed out in their use of corrosive sublimate applications. White employed lotions of 1 to 2 grains (0.065–0.135) to the ounce (32.), and an ointment of the same strength; the former he found more satisfactory in the tubercular and all closed forms, and the lotion on open ulcerated and crusted surfaces. The application is to be made twice daily. Other remedies of allied action to that of the mercurials are sulphurous acid, advised by Hutchinson;[4] salicylic acid (salicylic acid, ʒj–iss (4.–6.); vaselin, ℥j (32.)), or 2 to 10 per cent. strength, as recommended by Marshall;[5] guaiacol, as recently extolled by Funk and Alivisatos,[6] with occasional applications of a 10 per cent. lactic acid solution. Sulphurous acid is also esteemed by Harrison.[7] Guaiacol was variously used—pure, with equal part glycerin or with equal parts sterilized olive oil, and applied frequently; and with, occasionally, other more active measures. The compound lotion of zinc sulphate and potassium sulphuret advised in acne and lupus erythematosus is also often useful as a preliminary application. Iodoform, usually as an ointment, 5 to 15 per cent. strength, has had some praise, but it is not superior to other remedies already mentioned, and which are free from the all-pervading odor of this drug. The mild preparations, which, however, have been most employed by myself, are the calamin-zinc-oxid lotion, and the oleate of mercury ointment, generally as in the formula prescribed by Brooke.

One soon finds, however, in the great majority of instances, that if much advance is to be made, recourse to stronger remedies is necessary; and if the area of disease is small, and in cases in which time is a consideration, it is best to adopt such measures from the start. First, as to those of moderate activity, which are not usually actively destructive. The best of these are salicylic acid, resorcin, and pyrogallic acid. The first—salicylic acid—may be prescribed in several ways—in collodion, 30 to 60 grains (2.–4.) to the ounce

[1] Brooke, "A Preliminary Treatment of Lupus Vulgaris," *Brit. Jour. Derm.*, 1890, p. 145; "On the Treatment of Scrofuloderma and Lupus," *ibid.*, 1891, p. 383.

[2] Doutrelepont, *Monatshefte*, 1884, p. 1.

[3] J. C. White (On the Treatment of Lupus by Parasiticides), *Boston Med. and Surg. Jour.*, Oct. 25, 1885.

[4] Hutchinson, *Med. Times and Gazette*, April 26, 1884.

[5] Marshall, *Brit. Med. Jour.*, June 25, 1884, p. 1253.

[6] Funk, *Monatshefte*, vol. xxix., 1899, p. 216; Alivisatos, *La semaine médicale*, 1900, p. 10 (guaiacol and olive oil, each, 4 parts; alcohol (60 per cent.), 1 part).

[7] Harrison, *Brit. Med. Jour.*, Aug. 6, 1892.

(32.); in plaster mass, made up with petrolatum and resin plaster, 1 to 2 drams (4.–8.) to the ounce (32.); mixed with sufficient glycerin to make a paste, as recommended by Treves; and as Unna's plaster-mull. This last is made in several strengths; the weakest can be placed among the mild remedies already mentioned, the strongest, which are here referred to, containing respectively about 1 ounce (32.) and 1½ ounces (50.) to the spread meter, and with about the same quantity of creasote, which lessens the pain of the application. Unna,[1] Jamieson, and others have warmly commended this plaster-mull, more especially in the superficial and non-ulcerative types, and from its use in several cases I can subscribe to its value. It is kept continuously applied, changing daily; the tubercles undergo destruction, and are, so to speak, shelled out. A 10 to 20 per cent. salicylated collodion is also satisfactory. In ointment form, used 2 or 3 drams (8.–12.) to the ounce (32.), and kept constantly in contact, it is also quite active. I have had no experience with the salicylic acid glycerin paste. Resorcin can be employed in the same manner and strength as salicylic acid, most commonly as a strong ointment. As a rule, it is not painful.

Of the several remedies just named, however, pyrogallol, originally recommended by Jarisch, is in my experience the most certain in action. Upon the whole, it is best employed as a stiff ointment, made up with resin cerate and vaselin, or with some resin plaster added during the warm season. I have not had much success, however, with the 10 per cent. strength as commonly advised, nor secured action in several days, as Jarisch and others reported; on the contrary, I can agree with G. H. Fox[2] that to secure effective result a strength of at least 25 per cent. should be employed, generally in about one-third proportion. During the cooler season an ointment made up as follows can be used: ℞. Pyrogallol, ʒij–iij (8.–12.); vaselin and resin cerate, āā, q. s. ad ℥j (32.).

This is spread thickly upon patent lint or any other suitable material, and kept closely applied, changing to a fresh plaster twice daily. At each renewal the parts are wiped off gently with a piece of soft linen or cotton, and any loose skin, crust, scale, or slough thus removed. At the end of five to eight days it is usually noted that a superficial slough or a slough of variable thickness has formed, which may be more or less adherent. This, if but slightly adherent, may be rubbed off or picked off; if firmly adherent,—and this is more commonly the case,—poultices are to be applied until it softens and comes away, which may require several hours or a day or more. The parts are then gently washed with soap and water, rinsed, and wiped dry, and the pyrogallol ointment reapplied; and so on until the destructive action has been deemed sufficient. A course of such treatment usually requires from ten days to two or three weeks. After removing the final slough a carbolized resin cerate or an ointment of pyrogallol of 1 or 2 per cent. strength may be

[1] Unna, *Aerztliches Vereinsblatt für Deutschland*, No. 166, 1886; *Lancet*, Sept. 25, 1886.

[2] G. H. Fox, "The Therapeutics of Cutaneous Tuberculosis," *Boston Med. and Surg. Jour.*, Nov. 12, 1891.

used, and healing allowed to take place. Others follow this treatment, as I have also done in some instances, with an ointment made up of equal parts of mercurial plaster and petrolatum or with pure mercurial plaster. After thorough healing it is often seen that in places the disease is still persistent, or soon afterward new foci reappear in the scarred tissue; the same method is to be resumed, usually for a shorter period.

Belonging in this same class, or occupying a middle position between these and the more destructive caustics, is arsenic, in the form of an ointment or paste. It is one of the older methods, but, in my opinion, is far superior and more effectual than many of the newer remedies. For application to areas of two or three square inches to that of a palm an ointment used by Hebra, consisting of arsenious acid, gr. xx (1.35); cinnabar, ʒj (4.); cold cream, ℥j (32.), is to be commended. In order to diminish the pain of the application—its greatest drawback—5 to 10 grains (0.35–0.65) of cocain muriate can be added. This is spread, somewhat thickly, upon lint and covered with wax tissue and bound on; it is changed twice daily, and continued from two to four days. Considerable edema and inflammatory swelling result, which, however, soon subside after the arsenical application has been discontinued. Its action is, unless too long continued, only on the diseased tissue; the nodules and other lupus infiltration are converted into a grayish, necrotic mass. The after-treatment for several days should, when possible, consist of poulticing until the sloughs come away, and then subsequently a 1 or 2 per cent. pyrogallol salve, or an ointment of equal parts of mercurial plaster and vaselin. As with all other methods, the arsenical application may have to be repeated one or more times before a permanent result is reached. If the area of disease is quite small, the arsenical application can be made in the form of a strong paste with acacia, as advised in epithelioma.

Among other remedies of this same class may be mentioned lactic acid, strongly commended by Mosetig. It is chiefly prescribed in the ulcerative types, and applied on a wad of cotton for ten to thirty minutes, once or twice daily at first, and during the interim using a mild salve, such as boric acid ointment or a 5 to 10 per cent. aristol ointment.

Various caustics, in addition to the safer preparations mentioned, have been advocated from time to time, such as Vienna paste, fuming nitric acid, chlorid of zinc (see epithelioma), but these are rarely resorted to at the present day. The galvanocautery, however, has been strongly urged by Besnier[1] and others, using variously shaped knives and points, practically combining cauterization with scarification. The Paquelin cautery has also been variously advocated, and Unna often employs this in conjunction with the plaster-mulls. Somewhat similar is the Holländer hot-air treatment, or hot-air cauterization[2] by means of a suitable apparatus, by which air heated

[1] Besnier, "Le lupus et son traitement," *Annales*, 1880, p. 687, and 1883, p. 377 (a review of the various methods, and especially descriptive (1883) of his own favorite method, with cuts of instruments).

[2] Holländer, *Deutsche med. Wochenschr.*, 1897, p. 688; *Berlin. klin. Wochenschr.*, July 12, 1899.

up to several hundred degrees is projected on the surface. It requires anesthesia and some skill and care not to go beyond the safety limit. Properly managed, however, according to reports, its effects are excellent. Plonski[1] saw 1 case practically cured in one sitting. Like all heat-cautery methods, however, it is potent for evil if poorly handled.

Of the **operative methods**, and those which have been and still are largely in vogue, are to be especially mentioned those by curetting and scarification. Volkmann originally suggested the former, and since then it has figured largely in the treatment of this disease. It can be employed when patients do not object to operative measures, in conjunction with caustic applications; and the two together constitute a plan of treatment to be warmly commended. Etherization is usually necessary. The parts are thoroughly curretted, the edges being well looked after. Inasmuch as some morbid cells or tissue are left, a supplementary cauterization is an essential part of this method. One of two plans can be used: either momentary cauterization with caustic potash in stick or strong solution, or several days' use of a 25 per cent. pyrogallol salve. The latter, I believe, assures less chance of recurrence. The subsequent treatment is the same as following the



FIG. 150.—Galvanocautery needle, knife, and spiral points (Besnier).

caustic methods. Linear scarification, warmly advocated by Vidal, and which has the strong support of Morrow, Brocq, Squire, Malcolm Morris, Stopford Taylor, and others.[2] Both Morrow and Taylor are warm in praise of this plan, the experience of the latter as to the various methods being based upon 250 cases. Both consider that it is the remedy *par excellence* for extensive lupus of the face, where mutilation and disfiguring scarring have to be avoided. The great difficulty in its employment is the pain which it produces, so that anesthesia is necessary, and, moreover, it must be repeated at intervals of one or two weeks for a variable number of times. Taylor has found that nitrous oxid gas as an anesthetic has abolished the objections formerly held, owing to the unpleasantness of ether administration. The latter observer found the subsequent application—

[1] Plonski, *Monatshefte*, vol. xxix., 1899, p. 562 (case demonstration).

[2] Morrow, "The Mechanico-surgical Treatment of Skin Diseases," *Jour. Cutan. Dis.*, 1888, p. 132. Stopford Taylor, "A Comparison of the Various Methods of Treating Lupus Vulgaris During the Past Twenty Years," *Brit. Jour. Derm.*, 1894, p. 345. Both papers give reviews of the subject and more or less details of the principal methods in vogue. Brocq, Paris letter, *Jour. Cutan. Dis.*, 1888, p. 103, gives Vidal's method of quadrilateral linear scarification in minute detail.

immediately following the operative procedure—of unguentum glycerini plumbi of advantage, inasmuch as it causes considerable oozing of serum and thus further depletes the tissues.

The method of procedure is as follows: the parts are thoroughly gone over with close parallel incisions, $\frac{1}{8}$ to $\frac{1}{6}$ inch apart, reaching down through the diseased tissue, and then the area is cross-tracked in the same manner. Taylor finds it unnecessary, as a rule, to cross-

FIG. 151.—Single scarifier.

track the incisions, as in so doing the epidermis is likely to be torn off, the papillæ exposed, and suppuration ensue, healing being thus delayed. The hemorrhage is rarely troublesome, and is, as a rule, readily controlled by a wad of cotton. There is no question about the excellent cosmetic effect of this method, and in nose cases, where there has been a good deal of destructive deformity, it saves tissue

FIG. 152.—Multiple scarifier (as modified by Van Harlingen).

and even seems to create new tissue, so that the deformity is much diminished. On operating on the nose the nares are firmly supported by plugging with cotton or lint, so as to have a good foundation. The objection raised against the operation by Unna and others—that it makes autoinfection possible—is not supported by the observations of those who have most frequently performed it. Multiple puncture (Dubini, Volkmann, Veiel) is a somewhat similar operation, with which Volkmann was accustomed to supplement erosion with the curet, and it has been employed independently, but is less satisfactory than linear scarification.

Excision has from time to time had support, but rarely employed until Lang[1] gave it the weight of his advocacy, although Clark,[2] Bidwell,[3] and a few others[4] previously or since have reported favorable results. It has not been looked upon with favor in England or this country, except for circumscribed areas. The method consists in complete excision, going well beyond the borders of the disease, and then supplementing with Thiersch grafts usually immediately after

[1] E. Lang, "Der Lupus und dessen operative Behandlung," Vienna, 1898; also (later communication on the results, with illustrations), *Wien. med. Wochenschr.*, No. 38, 1900.

[2] Bruce Clark, *Lancet*, Mch. 18, 1893 (7 cases).

[3] Bidwell, *Brit. Jour. Derm.*, 1893, p. 288 (4 cases—1 relapse).

[4] M. B. Hutchins (2 cases), *Jour. Amer. Med. Assoc.*, Dec. 12, 1896, p. 1223; Popper, *Dermatolog. Zeitschrift*, vol. iv., H. 1, 1897 (Lang's method—34 cases, only 3 recurrences; gives minute details of cases and operation); Buschke, *Archiv*, vol. xlvii., 1899, p. 23 (18 cases); Urban, *Monatshefte*, vol. xxvi., 1898, p. 429; Tavastsjerna, abs.-ref. in *Jour. Cutan. Dis.*, 1899, p. 148 (18 cases—a large number involving nose and mouth; cure held in 5 cases two years after operation); Nélaton, *Jour. mal. cutan.*, Jan., 1900.

the operation. The chief objection is the disfigurement. Stopford Taylor's experience in 20 cases was not sufficiently satisfactory to commend the operation.

For destroying lupus tubercles which are isolated, more especially those that spring up in the scar tissue, and often irrespective of what the active plan of treatment has been, a sort of a double burr (Malcolm Morris) or ordinary dental burr (G. H. Fox)[1] has been warmly commended. For the same purpose, as well as for the systematic treatment of cases, the pointed silver nitrate stick has been used, particularly in Vienna; it is easily bored into the discrete tubercles, and while it thus disturbs and destroys the body of the lesion, its mild cauterizing action is damaging to the morbid cells with which it comes in contact. It is rarely resorted to to-day, scooping out with the curet, the burr, or the electric needle being far preferable if an operative method is elected.

Electrolysis may likewise be used for circumscribed patches, in a manner originally proposed by Gärtner and Lustgarten[2] and since commended by Jackson.[3] The former used a silver metal plate, and the latter one of zinc, with a rim of hard rubber projecting about a millimeter beyond the metal, to protect the healthy skin or to prevent too severe action at the edge, the diameter of the plate being from $\frac{1}{2}$ to $\frac{4}{5}$ of an inch; this is attached to the negative pole, the anode sponge electrode being placed at any convenient point. The current strength required is from 5 to 10 milliampères. The plate electrode is pressed gently upon the patch to be treated, and the current passed for about seven or eight minutes. The area is gone over at intervals of a week for a few times, and then the isolated tubercles which are left are treated with the electric needle, using a current of 3 milliampères.

Two other methods of increasing importance, and which in countries or centres where lupus is more common have to some extent supplanted the plans of treatment formerly in use, are the Finsen-light treatment and the Röntgen-ray treatment.)

First as to the **Finsen treatment**.[4] Finsen and his capable assistants, Bang and Forchhammer, have been practising the method devised by him, at his institute at Copenhagen, for some years, and with final results eminently satisfactory. As referred to in the introductory chapter the method is thought to hinge upon the bactericidal properties of concentrated chemical rays, using the arc light, and controlling or preventing the action of the heat rays. Others, among whom Lereddle, Sequeira, Malcolm Morris, Hyde and Montgomery, and Lesser, have also reported favorable results, so that the method is now regarded as one of the most important in the therapeutics of this disease.

During a visit to Copenhagen, four years ago, I had the pleasure of observing this method as practised by Finsen himself. In the summer of 1904, at the International Dermatological Congress, held at

[1] G. H. Fox, "On Various Methods of Treating Lupus Vulgaris, Including the Use of Burr and Hook," *Jour. Cutan. Dis.*, 1885, p. 70.

[2] Gärtner and Lustgarten, *Wien. med. Presse*, 1886, p. 776.

[3] G. T. Jackson, *Jour. Cutan. Dis.*, 1890, p. 416.

[4] See under General Remarks on Treatment regarding apparatus and other points not here considered.

Berlin, I saw over 30 patients who had been brought over from Copenhagen to emphasize the good effects of this plan. The favorable results and the excellent cosmetic effects were well in evidence. In the past several years I have used a modified Finsen lamp in some circumscribed cases with good results; but, in spite of the good effects, I am not able to escape the conviction that, with some of the other methods mentioned, as thoroughly and persistently carried out, the same end could have been attained, but probably with not as good cosmetic results. Judgment as to the value of the Finsen treatment should, however, be based upon the use of the so-called Finsen lamps, for, as already mentioned, these lamps in their depth of action exceed any other yet introduced. Where lupus is at all common—or, say, not rare or uncommon, as it is with us—the Finsen-light treatment can be efficiently and easily conducted, owing to proper training of the attendants in the technique. On the other hand, where only an occasional case of the disease is met with, it will, owing to the lack of proper training in its application, scarcely supplant the other known methods—unless there are still further improvements in the apparatus and a considerable shortening of the time of exposure.[1]

The duration of an exposure with the Finsen or Finsen-Reyn lamp varies from three-quarters to one-and-a-half hours, depending upon whether the disease is superficial or deep. It is usually necessary to repeat the treatment on the same area at least once or twice, but before a new exposure is made the reaction from the preceding one should have been allowed to subside; this ordinarily requires, on an average, about ten days. The reaction comes on from a few hours to a day after the exposure, and varies from an erythematous to a vesico-bullous character; there is no necrosis. When the disease is extensive, one area after another can be treated, so that it often is necessary to give a daily séance, and then several months, or much longer, may be required before the entire involved surface has been sufficiently covered. Patients should report a few months after an apparent cure for examination, and the exposures resumed should there be any evidence of lupus tubercles or infiltration. For superficial types, the first part of the treatment can be done with the lamp of the Lortet and Genoud model, or with the iron-electrode lamp; this will often act satisfactorily and relatively more rapidly in removing a great part of the disease, and then the Finsen or Finsen-Reyn lamp can be subsequently used for the remaining deeper lupus deposits. The same combined plan can in many cases be satisfactorily

[1] Malcolm Morris and Dore, "The Light Treatment in Lupus and Other Diseases of the Skin," *Practitioner*, April, 1903, give a fair statement as to the method and one with which my own observations accord:

Disadvantages of the Treatment.—The disadvantages of the treatment are the great length of time required (the patient must be kept under observation for one to three years); the tediousness of the treatment for one hour daily, and the loss of time which it involves; the occasional pain during the application; the inconvenience and pain caused by continual inflammatory reaction in parts treated; the expense of outlay and working.

Advantages of the Treatment.—The advantages are the excellent cosmetic results; no bad scar or disfigurement results from the continual applications; no anesthetic is required; no injurious effect is produced on the general health; the trustworthiness of the method—improvements may be expected in all cases, provided sufficient time is given to the treatment.

adopted with the Röntgen-ray and Finsen treatments; the former being employed first, and when the disease area has been reduced to one or several obstinate patches the Finsen treatment can be resorted to. In Copenhagen, in some instances, in order to shorten the period of treatment, there is a preliminary treatment of the deeper-seated areas with pyrogallol applications, as already outlined. In ulcerated areas, a preliminary treatment by any appropriate plan is necessary before the Finsen treatment is resorted to, as this cannot be used satisfactorily upon ulcerated surfaces. Its special field is in the dry non-ulcerative cases. When the mucous membranes, as in the nose, etc., are affected, the disease cannot be satisfactorily treated with the light. Such regions are to be handled as described later.

The favorable reports of the curative action of the X-rays[1] in lupus made by the pioneers in this method (Schiff, Freund, Neisser, Pusey, Kummel, and others) have been corroborated by many other observers, and it has now become, along with the Finsen plan, one of the accepted methods. I can fully endorse its great value in some cases. One cannot say, however, in a given case how much good it will do, and in some instances it seems to have but little influence; in others, only after considerable reaction has been produced; and in others again, not till the danger-point of Röntgen-ray reaction has been passed. Nevertheless, it shares the honors at present with the Finsen light, and to some extent has supplanted it. Its great advantage is that a large part or the entire diseased surface can be treated at the one time, and in cases which show response to its influence a good result is comparatively quickly obtained. In a few instances a favorable action is noted without the production of X-ray erythema, but ordinarily it is necessary, for the best and most rapid effect, to bring about a moderate and continuous reaction; sometimes it is necessary to push it to the point of X-ray dermatitis of the second degree —vesiculation or serous exudation—before an impression is made upon the disease, but caution should be exercised and such action kept within the bounds of safety, intermitting when necessary. As in the use of this active agent in any disease, the first exposures should be cautiously given, with a tube of low to medium vacuum, at ten inches distance, and for five minutes' duration, and at intervals of three to four days. After a period of ten days to two weeks, if no susceptibility has been shown, the distance can be gradually reduced to three or four inches, and the time lengthened to ten or fifteen minutes, and the exposures made at more frequent intervals. The inexperienced, however, cannot be too cautious in the bolder use of this method, as its effects when carelessly pushed are sometimes unpleasant, not to say disastrous. In those instances where moderate reaction has been purposely provoked and kept up, after a few weeks' treatment should be discontinued till this subsides, and in some cases improvement sets in and continues. The method should again be resumed as soon as improvement begins to flag.

Treatment of lupus of the mucous membranes must be more or less limited, owing to the difficulty of application—continuous appli-

[1] See under General Remarks on Treatment regarding apparatus, protection of patient, and other points.

cations and linear scarification usually being entirely impracticable. Curetting can be made use of, especially when the disease is readily reached and within easy view, and supplementary cauterization with silver nitrate stick or strong solution. The best method, however, here consists in cauterization by means of the galvanocautery, repeating at intervals of a few weeks until the morbid tissue is all destroyed. The Paquelin cautery may also be employed for this purpose, but is not so valuable or generally useful as the galvanocautery. At Finsen's institute they make a daily application of a compound solution of iodin and potassium iodid, and twice weekly galvanocauterization. Lactic acid is a valuable remedy in these cases, and can be applied pure, or with one to several parts water, according to whether it is used alone or with preceding curetting, and also upon the character and infiltration of the area to be treated. Various other remedies have been advocated from time to time, but the most valuable, in my judgment, are curetting, galvanocauterization, and lactic acid. The use of cocain solution as a preliminary in those who bear pain poorly, carefully employed, reduces the pain of treatment and avoids the necessity of a general anesthetic.

LUPUS ERYTHEMATOSUS.

Synonyms.—Seborrhœa congestiva (Hebra); Lupus erythematodes; Lupus sebaceus; Ulerythema centrifugum (Unna); *Fr.*, Lupus érythémateux; Scrofulide érythémateuse.

Definition.—Lupus erythematosus is a chronic, mildly or moderately inflammatory, small-celled superficial new growth formation, characterized by one, several, or more circumscribed, variously sized, usually oval or rounded, discrete or confluent, pinkish to dark-red

FIG. 153.—Lupus erythematosus; a not uncommon situation and configuration (courtesy of Dr. J. A. Fordyce).

patches, covered slightly and more or less irregularly with adherent grayish or yellowish scales, and seated most commonly upon the face, less frequently upon the scalp also, and very exceptionally upon other parts.

Symptoms.—Two varieties are encountered, the circumscribed or

discoid (lupus erythematosus discoides) and the more or less diffuse, scattered, or disseminated (lupus erythematosus disseminatus). The former is the common clinical type, and is usually seen about the nose, cheeks, and ears, and less frequently the scalp, and when on the last, generally conjointly with the disease on the face. It may, however, be limited to the scalp, for a time at least, and very exceptionally it may exist on this part for some years without appearing elsewhere.[1] In rarer instances the hands also show the eruption, but, as a rule, in conjunction with the patches elsewhere. In most cases, however, coming under observation the face is the sole seat of the disease, and the flush areas—nose, cheeks, and ear-lobes—are its most usual sites.

FIG. 154.—Lupus erythematosus.

There are no constitutional symptoms except in the disseminated type, to be referred to later, nor are subjective symptoms present to a troublesome degree; there may be slight burning or itching, but usually no local discomfort is complained of. In the discoid type—the common clinical type—the disease begins as one or several rounded, circumscribed, pin-head- to pea-sized pinkish or reddish spots, upon which, if undisturbed by frequent washing, slight adherent scaliness is observed. They are somewhat elevated, at times scarcely perceptibly, in others quite noticeably, and this is most pronounced at the border. They slowly, or exceptionally somewhat rapidly, increase in area by peripheral growth, and, after attaining variable size,—a fractional part of an inch to an inch or more in diameter,—they are apt to remain stationary; or they may increase still further and several contiguous areas coalesce, or a disposition to retrogression may show itself in some patches, and a tendency to atrophic change centrally. If coalescence ensues, this, with often

[1] Stowers, *Brit. Jour. Derm.*, 1898, p. 144, exhibited before the Dermatologic Society of Great Britain and Ireland, a woman with the disease upon the scalp of eleven years' duration, without any manifestation on other parts.

the appearance of new patches nearby, covers considerable area When at all developed, the clinical picture is quite peculiar and characteristic: the patches are noted to be sharply defined against the sound skin by a slightly or pronouncedly elevated border, while the innermost central part is somewhat depressed and usually atrophic; the glandular ducts are generally enlarged and patulous, and often more or less plugged with sebaceous and epithelial débris; and the entire surface is very thinly and irregularly covered with grayish or grayish-yellow scaliness, although this is, as a rule, scanty in quantity. In some cases, however, it forms a coating with projections into the follicular openings. These cases of marked follicular involvement represent Besnier's follicular type. There is some infiltration or thickening, variable as to degree, but generally slight or moderate. The patch is pinkish or reddish in color, with frequently a violaceous tinge, the color being most noticeable at the border, at the central part often partly hidden or lessened by the scales.

Not infrequently the disease is observed to present itself as one or several patches on the nose and neighboring cheeks, and by growth, and often by the appearance of new spots in the intervening spaces, gradually fuse together and form a large area with the narrowed part over the bridge of the nose, and the outer portion stretching and widening out on each side more or less symmetrically, like, as Hebra expressed it, the out-stretched wings of a butterfly; this distribution and shape have given rise to the name "*bat's-wing disease*." The whole area, with the elevated outline border, may be of uniform appearance and thickness, or thinning and atrophy are noted centrally or here and there in points corresponding to the centers of the several original constituent patches; the former is more usual. Other small characteristic patches are frequently to be seen on outlying regions. Cases of the malady are not uncommon in which but a few fairly large areas present, of a markedly infiltrated character, with a prominent border, and which are persistent and show but little progression or retrogression (lupus érythémateux fixé of Brocq). In some instances or patches retrogressive changes are not infrequently noted without atrophic tendency, and the skin, if the patch disappears, is found to be normal. In other patients, and occasionally in one or two patches, there is very distinct atrophy, so that the surface presents the appearance of a thin, flat, superficial scar, somewhat sieve-like, showing the previously enlarged duct-openings. On the ears, lobe and tip, and less frequently in the concha, and the outermost portion of the canal, it is not uncommon to find patches of the disease, but not, as a rule, so sharply defined; in patches just inside of the concha, however, the duct-openings are often quite noticeable and plugged up, and occasionally dark colored, suggesting an aggregation of comedones.

In some cases the patches are observed to be exceedingly superficial, almost wholly devoid of thickening or infiltration, the duct-openings not conspicuous, but scantily covered with branny scaliness, having, however, the sharply defined border. In these instances the areas are suggestive of mild eczema seborrhoicum, but do not shade off into the sound skin, as the latter commonly does.

PLATE XX.

Lupus erythematosus.

They resemble slightly, too, when the scaliness is extremely trifling, erythematous patches of erythema multiforme or chilblains. This represents one form of Besnier's vascular or erythematous type. In other cases the patches may be somewhat puffy in appearance, quite a lively red, with often a violaceous tone, and but little tendency to scaliness, without noticeable duct involvement, and some appreciable dilatation of the cutaneous capillary vessels; retrogressive changes are usually more decidedly atrophic than in the usual clinical types—constituting the so-called telangiectatic type.

In lesions on the hands, concerning which valuable papers have been contributed by Hyde,[1] Klotz,[2] Ohmann-Dumesnil,[3] and others, the form of the disease is more usually superficial, not very scaly, and the color is frequently a violaceous red, sometimes rosy red; they are fairly well defined against the sound skin, although not so clear-cut in this respect as generally observed in patches on the face. The dorsal surface is the usual seat, either of the body of the hand or the fingers, but the palm and anterior aspects of the fingers may also be affected. Occurring on fingers, toes, and pinnacle of ear, it sometimes begins as chilblain or a simulation of it (lupus pernio). The hands, as already stated, are usually conjointly affected with the face, although it may occur on this region primarily or even independently. From the literature review furnished by the gentlemen named, it would seem that the disease on this region, although relatively rare, is more common in England than elsewhere.

On the scalp the disease is, while not frequent, not uncommon, and presents some features different or in a more aggravated degree than observed ordinarily on the face. Although, according to Besnier, Brocq, Méneau,[4] and others, the varying characters of the disease, as regards discoid, disseminated, superficial, and infiltrated types, may occur upon the scalp, as elsewhere, the somewhat thick discoid form is that generally observed. There is not so much redness, as a rule, as on the face, but usually more thickening, with partial and generally complete hair loss of the affected area, and rather hard, thick, fibrous, depressed scar-tissue formation; although here, as elsewhere in the disease, there is no suppurative action, no ulcerative destruction. The atrophic degenerative change is generally so marked that it simulates true scar tissue, and is essentially scar like in character; it is not usually sieve-like, as observed upon the face. It is somewhat depressed below the skin level. The hair-follicles are permanently destroyed. The patches commonly begin insidiously, with

[1] Hyde, "Lupus Erythematosus as it Affects the Hands," *Jour. Cutan. Dis.*, 1884, p. 321 (4 cases).

[2] Klotz, "On the Clinical Diagnosis of Lupus Erythematosus of the Hand and Foot," *ibid.*, 1888, pp. 50 and 90 (2 cases).

[3] Ohmann-Dumesnil, "Erythematous Lupus of the Hand," *Amer. Jour. Med. Sci.*, Dec., 1888 (1 case). These several papers go into the subject at length, with good surveys of the literature, with references; in the last an analysis of 46 collated cases is given.

[4] Méneau (Lupus érythémateux du cuir cheveleu), *Annales*, 1896, p. 579, reports 4 cases and reviews the literature, quoting from various authorities. Dubois-Havenith records a case, *Jour. mal. cutan.*, 1899, p. 239, limited to the scalp; Galloway, *Brit. Jour. Derm.*, 1897, p. 329 (case demonstration), exhibited a patient in whom blebs of some size developed on the scalp areas—a case apparently unique in this respect.

a slightly or moderately elevated red border, and with patulous and frequently stuffed duct-openings, but there is not, as a rule, much scaliness. While ordinarily not presenting here more than one to several variously sized patches, it may be exceptionally quite extensive and coalesce, and involve a greater part of the scalp. The disease rarely occurs primarily upon the hairy region, but usually secondarily, and commonly associated with patches upon the face or elsewhere. According to my own observations, the malady here is always attended with atrophic or scar-like changes, rarely disappears spontaneously, and always leaves permanent traces—hair loss and cicatricial tissue.

Lupus erythematosus disseminatus, the exanthematic, or disseminated type of the malady, first described by Kaposi [1] and since observed by others (Besnier, Hallopeau, Hardaway, Koch, Cavafy, Bulkley, and others),[2] is, as a rule, a much more serious phase of the disease. It may develop from the ordinary discoid form, but more frequently independently. It is characterized by small, usually numerous, pinhead- to bean-sized spots or patches, appearing primarily on the face, where it may remain and cover considerable surface by the slight enlargement of the original plaques, but commonly by the appearance of others in the clear interspaces. They are hyperemic, show, for the most part, but little infiltration and scaliness, and rarely any marked glandular involvement. The center may be somewhat depressed, and with or without atrophic tendency. A certain capriciousness is sometimes noted, old spots disappearing and new ones presenting. Not infrequently the hands exhibit lesions, and other parts of the body, as the limbs and trunk, also become invaded. In some instances there is a resemblance to the lesions of erythema multiforme,[3] and in one instance to the early eruptive patches of granuloma fungoides (Hallopeau).[4] Very exceptionally vesicular and bullous lesions have been noted, more especially in the central area of the atrophic spots; but in a few instances as beginning lesions. An eczematous aspect with slight crusting has also been observed. In rare cases there are attacks, sometimes persistent, of an erysipelatoid condition of the face associated with the eruption, to which Kaposi especially refers, and denominated by him "erysipelas faciei perstans." New lesions often come out in distinct crops, with symptoms of general disturbance and febrile action. The eruptive phenomena persist, the disease advances and often retrogresses, and in many of these patients sooner or later signs of more or less acute tuberculosis supervene, and death results, probably more than a majority of the

[1] Kaposi, *Archiv*, 1872, p. 36.

[2] Hallopeau, Wickham's Paris letter, *Brit. Jour. Derm.*, 1892, p. 123; Hardaway, *Jour. Cutan. Dis.*, 1889, p. 448, and 1892, p. 268; Koch, *Archiv*, vol. xxxvii., 1896, p. 39 (illustrated); Cavafy, *Brit. Jour. Derm.*, 1897, p. 328; Bulkley, *Jour. Cutan. Dis.*, 1897, p. 178; Brooke, *Brit. Jour. Derm.*, 1895, p. 73; Jamieson, *ibid.*, 1893. p. 115, records 2 cases of more or less general distribution, but not acute in development.

[3] Crocker, *Jour. Cutan. Dis.*, January, 1894 (Lupus Erythematosus as an Imitator of Various Forms of Dermatitis), also describes cases of the ordinary benign types of the disease, in which resemblance was shown to several other eruptions, more particularly papular and nodular erythema and lichen planus.

[4] Hallopeau, *loc. cit.*, exhibited a patient before the French Dermatologic Society in whom the eruptive phenomena appeared to those present to represent the beginning stage of granuloma fungoides—a year later case was again exhibited, and the lupus erythematosus character of the manifestation was evident.

recorded cases ending fatally. In one under my own observation the eruption was quite profuse and more or less generalized, partaking of the appearance of erythema multiforme and lupus erythematosus, with atrophic tendencies in some of the spots; but as regards the course and patient's general condition was relatively benign, although persistent. As in most of these cases, there was a good deal of burning and some itching.

Lupus Erythematosus of the Mucous Membrane.—In lupus erythematosus the disease is almost invariably one of the integument, but it occasionally is, conjointly with cutaneous lesions,[1] met with on the vermilion of the lip, in the mouth, and on the conjunctiva, usually extending from the skin of the lower eyelid. On the vermilion of the lip there may be slight thickening, with scaliness, commonly of a branny or shred-like character, or there may simply be a rounded, abraded-looking, rather sharply defined area, with minute sieve-like puncta. The area is closely similar in color to the lip, but may have a violaceous tinge. Extending into the inside of the lip on to the true mucous membranes, it has the appearance of a superficial abrasion, but, as a rule, well defined. The color of the patch when within the mouth—and it has been observed on various parts—is somewhat variable—some bright red, and sometimes punctate, others a pale red, the latter often with an atrophic thinning. On the conjunctiva the surface is congested, usually sharply defined, and there may be slight thickening, but this is more likely to be on the ciliary border. In a case under my observation, in which a patch extended from the nose on to the nasal mucous membrane, there was considerable infiltration of the latter.

The **course** of lupus erythematosus is essentially chronic and persistent. Although in some cases there occur retrogression and disappearance of old patches, and sometimes without trace, there is almost always a new cropping-out to take their place, and thus the disease is continued. In the large majority of the cases, however, the patches are persistent and progressive, but after reaching a variable size, remain more or less stationary indefinitely. In extremely rare instances, primarily or as a subsequent development, some slight tendency to the appearance of flattened, lupus-like tubercles is observed, and the condition is suggestive of both lupus erythematosus and lupus vulgaris. I have met with two or three such instances in which the acceptance of a mixed type seemed the only solution, corresponding clinically to the lupus erythemato-tuberculeux of Besnier and the lupus érythématoïde of Leloir.

Fortunately, in lupus erythematosus, the disease areas, however long continued, do not show any tendency, as sometimes observed in

[1] Some cases in which the mucous membrane was involved have been in the disseminated type of the disease, an example of which (Petrini's case) is referred to by Leslie Roberts, *Brit. Jour. Derm.*, 1897, p. 177. See also paper by G. H. Fox (case of lupus erythematosus of the face and oral cavity), *Jour. Cutan. Dis.*, 1890, p. 24; also case demonstration by Lustgarten, *ibid.*, 1897, p. 529; Rille, *Wien. klin. Wochenschr.*, 1898, p. 1164; Hassler (case demonstration), *Jour. mal. cutan.*, Jan., 1900; Bowen, *Twentieth Century Practice*, vol. v. (Diseases of the Skin), p. 698; Dubreuilh, *Annales*, 1901, p. 231 (on mucous membrane lesions); T. Smith, *Brit. Jour. Derm.*, 1906, p. 59 (on mucous membrane lesions); Kren, "Ueber Lupus erythematodes der Lippenrotes und der Schleimhaute," *Archiv*, vol. lxxxiii., 1907, p. 13 (4 cases, with review and partial bibliography).

old cases of lupus vulgaris, to malignant (epitheliomatous) change, although quite recently Pringle[1] has recorded such an instance and also refers to a few cases recorded by Dyer,[2] Stopford Taylor, Kreibich, and one or two others.

Etiology.—Lupus erythematosus is not common, and is essentially a malady of early and middle adult life. Kaposi[3] has, however, seen the disease in a child of three years, and Jamieson[4] in one of eight, and exceptionally it has been observed to begin late in life. My own cases have mostly been between the ages of eighteen and forty.[5] While both sexes are its subjects, more than two-thirds are in women. Local congestive conditions and flushings from any cause favor its production, such as seborrhea, eczema seborrhoicum, acne rosacea, exposure to the sun, chilblains, and it has appeared after variola, erysipelas, and similar disorders. The influence of systemic conditions is not known, but I am convinced that cases always tend to get worse during times when the general health is below the standard and when active digestive disturbances and nervous excitement or depression occur. That general systemic states have a material influence is shown by Fordyce's case,[6] in which an extensive eruption appeared early in pregnancy and disappeared toward its termination; and a second case, disappearing during pregnancy and appearing after confinement.

The main question, however, is the possible relationship to tuberculosis. In recent years there has been a growing belief that the eruption is an expression of this disease, and the evidence accumulating and recently set forth, notably by Boeck,[7] following that already formulated by Hutchinson, Besnier, Hallopeau,[8] and others, has materially strengthened this view, with which my own clinical observations coincide. In more than a majority of the cases of the disseminated type reported tuberculosis or some suggestive pulmonary disease developed, rapidly leading to death (in our own country by Hardaway, Fox, Bulkley, and others). In many of the ordinary clinical types variously reported tuberculous tendencies in the family or patients, or the presence of scrofulous glands or other signs of this constitutional state have been noted, and many of the cases eventually succumb to pulmonary disease. In fact, Besnier and Hutchinson have found tuberculosis more frequently associated with lupus erythematosus than with lupus vulgaris. Fordyce and Holder[9] have recently reported a few instances of associated tuberculosis, and a most admirable judicial presentation of the subject has been

[1] Pringle, *Brit. Jour. Derm.*, 1900, p. 1.

[2] Dyer, Daniel's *Texas Med. Jour.*, 1892–93, vol. viii., p. 178.

[3] Kaposi, *Diseases of Skin*, p. 509.

[4] Jamieson, *Brit. Jour. Derm.*, 1893, p. 115.

[5] Two cases in a family are such a rarity that it is worthy of mention that Rona, *Archiv*, 1901, vol. lvi., p. 381, had under treatment 2 sisters aged twenty-four and twenty-eight; and Sequeira, *Brit. Jour. Derm.*, 1903, p. 171, met with 2 cases in sisters, one aged seven, and the other aged ten; and another instance of 2 cases in two sisters aged respectively twenty-six and twenty-eight.

[6] Fordyce, *Jour. Cutan. Dis.*, 1896, p. 89.

[7] Boeck, *Brit. Jour. Derm.*, Sept. 10, 1898; *Brit. Jour. Derm.*, Oct., 1898; *Archiv*, 1898, vol. xlii., p. 71.

[8] Hallopeau, *La sémaine med.*, 1898, vol. xviii., p. 225.

[9] Fordyce and Holder, *Med. Record*, N. Y., July 14, 1900 (refer also to suggestive cases by Jackson and Bronson).

made by Roth,[1] who collated about 250 cases of lupus erythematosus, and of these, in over 70 per cent. there was evidence, more or less pronounced, of tuberculosis. His view, in the absence, so far, of bacilli findings in the lesions, is that possibly the toxin generated was the causative agent, which accords with French opinion on the subject. It is only fair to state, however, that many prominent observers, among whom Duhring, Kaposi, Crocker, Leloir, and others fail to subscribe to this view, although Crocker[2] admits the undoubted frequency of the disease in those of tuberculous family history.[3]

Pathology.—In addition to the French view of the disease being due to the tubercle bacilli toxins, probably by their action on or through the blood-vessels of the part, other theories, as succinctly stated in Fordyce and Holder's papers, "have been advanced from time to time, such as regarding it as an angioneurosis, as cutaneous inflammation due to local causes, a specific infectious disease due to micro-organisms; a form of skin tuberculosis produced by a species of bacilli supposed to differ from those found in the lungs and in lupus vulgaris, a neuritic inflammation of the skin, the result of the growth of the tubercle bacilli in the nerve-fibers in analogy with the skin changes caused by nerve leprosy." As yet, however, these several theories are purely speculative.

The cutaneous lesions are, judging from theoretic, clinical, and anatomic aspects, in all probability a result of two forces: one from within (tubercle bacilli products?), acting, as Boeck and others suggest, primarily upon the vasomotor centers of the skin, and, in the second place, on the parts of the skin in which the vasomotor disturbances are set up—the latter being superinduced by such local influences as flushing, seborrhea, eczema seborrhoicum, or other local conditions.[4] Boeck states that the main anatomicopathologic changes are vasomotor dilatation of vessels, secondary intoxication of the tissue cells, and inflammation, the whole resulting very often in atrophy.

The histologic studies (Neumann, Vidal, Thin, Crocker, Fordyce and Holder, Robinson, and others) of the disease do not agree absolutely in the findings probably due, in a measure, to the stage

[1] Roth, "Ueber die Beziehungen des Lupus Erythematosus zu Tuberculose," *Archiv*, 1900, vol. li., pp. 3, 247, and 395, with brief résumé of all cases reported, with bibliography.

[2] Crocker, Discussion, *Brit. Jour. Derm.*, 1898, p. 375.

[3] In part, this is the theory advanced by Warde, *Brit. Jour. Derm.*, 1902, p. 332 and 380, 1903, p. 161, who believes that lupus erythematosus is not a disease, but merely a stage in the course of many different affections—the damaged part when unable to be self-reparative undergoing destruction and replacement by fibrous tissue. He calls attention to its frequent association with chronic atrophic and hypertrophic rhinitis and ozena, suggestive of an allied nature or relationship. Galloway and Macleod, "Erythema Multiforme and Lupus Erythematosus: Their Relationship to General Toxæmia," *Brit. Jour. Derm.*, 1903, p. 81, are inclined to ascribe the malady to an underlying toxemia, which sometimes may produce erythema multiforme, in others, from lack of reparative power, lupus erythematosus.

[4] Polland, *Dermatolog. Zeitschr.*, 1894, vol. ii., p. 482, recently met with lupus erythematosus and erythema induration in the same patient (woman), who had lost two sisters from lung disease.

and character or activity of the disease process in the patch examined. Nor do investigators place the same interpretation upon the histologic changes observed. One of the latest contributions on the subject is that by Robinson,[1] who reviews the entire subject and gives, in brief, the findings of others. While clinically the process would suggest an essential involvement of the epidermic tissue, examinations show that the alterations in the epidermis (hyperkeratosis, etc.) are secondary and unimportant, and that the principal changes are to be found in the corium, especially about the blood-vessels, and that the primary lesion is focal in character, and when fully developed, constituting in reality a new growth, reticular in structure, and connected especially with the lymph-channels; that there is an associated perivascular infiltration, most marked where the blood-vessels are most numerous, as around the glandular structures and horizontal blood-vessels; no giant-cells and no polynuclear cells; the excretory parts of the glandular structures show some invasion of infiltrated cells; the plugs are, according to Unna, the result of acanthosis, and are not sebaceous material. There is variable edema of the prickle layer and of the cutis. Unna lays stress upon a lymph canalization of the infiltration. Fordyce and Holder [2] found the sebaceous glands affected with hypersecretion, and later their ducts, as well as the sweat-gland ducts, as others have observed, are the seat of infiltration, and subsequently undergo degenerative changes, to which the punctate or sieve-like character of the scar is due. These observers are inclined to believe that capillary obstruction is the primary step in the pathologic process, although admitting that it may be the effect and not the cause of the connective-tissue change. Schoonheid [3] states that the progressive inflammatory changes noted lead to typical degeneration of the elastic fibers, and that it is especially this that is an important factor in the resulting scar-like atrophy.

From his own repeated examinations and from a review of those of others Robinson concludes that: "Lupus erythematosus is a chronic inflammatory disease of the cutis with special histologic characters, as shown by the changes in the blood-vessels—new blood-vessels in the affected area, lymph-vessels, and lymph-channels, and the new formation of an adenoid-like tissue,—reticular tissue,—the presence of mononuclear and absence of polynuclear cells in the cell infiltration; and these changes must depend upon the presence of a poison generated *in loco*. In other words lupus erythematosus is a local infective process—a granuloma."

Diagnosis.—As a rule, there is no difficulty in the recognition of this disease, as its features—the sharply circumscribed outline, the reddish or violaceous color, the elevated border, the tendency to central depression and atrophy, the plugged-up or patulous gland-ducts, the adherent grayish or yellowish scales, together with the region attacked (usually on the nose, cheeks, ears, or other parts of the face), the slow course, and the age of the patient are quite char-

[1] Robinson, *Trans. Amer. Derm. Assoc. for 1898* (with some literature references).
[2] Fordycé and Holder, *loc. cit.* (with 8 histologic cuts).
[3] Schoonheid (Ehrmann's laboratory), *Archiv*, 1900, vol. liv., p. 163 (an elaborate investigation, with 6 colored cuts).

acteristic. It is not to be confused with eczema, eczema seborrhoicum, lupus, and syphilis, and on the scalp with alopecia areata and folliculitis decalvans. The itchy nature of eczema, its diffused character and lack of sharply defined border, and often the presence of vesicles, papules, or oozing, with no disposition to atrophy, together with its history, distinguish it from this disease. Eczema seborrhoicum may be sharply bordered, but the greasy or oily character of the scales and crusts, and its usual association with seborrheic condition of the scalp, and absence of the other features of lupus erythematosus usually suffice. It is not to be forgotten, however, that lupus erythematosus sometimes develops from a seborrhea.

Lupus vulgaris in the vast majority of cases begins in early life, and there are tubercles, usually a tendency to ulceration, and tough cicatricial formation—features wanting in lupus erythematosus; in rare instances the non-ulcerative type of the former, in which the tubercles consist more of a flattened, diffused infiltration, bears some slight resemblance, and, as already noted, a mixed type of the two diseases is within the range of possibility, but confusing examples are, nevertheless, extremely rare. A confluent patch of flattened, slightly scaly, non-ulcerating, tubercular syphiloderm may exceptionally, if hastily examined, be confused with it, but the individual tubercles can usually be made out on close inspection, and there are no patulous or plugged gland-ducts, and the sharply defined border of lupus erythematosus is wanting. The acute disseminated type may remind one possibly of a mild psoriasis of the seborrheic type or an ill-defined erythema multiforme, but the tendency to atrophy noted in some of the patches, the constitutional symptoms commonly present, and the absence of the usual distribution of psoriasis are points of difference; the same features serve to distinguish it from erythema multiforme. In fact, this type is so exceptional that it scarcely needs to be considered.

Patches on the hand are also so extremely rare that the question of differentiation would seldom arise, but in these cases, even if such patches be obscure, others usually found on its common sites will be of aid. Lupus erythematosus of the scalp differs from both alopecia areata and folliculitis decalvans in its slightly or moderately sharply elevated border, and the often present patulous or stuffed gland-ducts; moreover, in alopecia areata there are no inflammatory signs, and in folliculitis decalvans the patch is likely to be irregular or jagged in shape.

Prognosis.—Lupus erythematosus is a chronic disease, slow in its course, lasting indefinitely, and extremely rebellious to treatment. Some cases are capricious, after a time spots disappearing, and sometimes without a trace, in others—the majority—with atrophic scarring. Even in such cases, however, new patches usually arise as others are retrogressing. In most instances the individual areas are, however, persistent. After some years the affected parts are seen to be the seat of flourishing areas interspersed with superficial soft scars or atrophic thinning. In some instances, unfortunately few in number, after an uncertain duration the disease disappears. As already elsewhere stated, tuberculous or suggestive pulmonary disease has been

noted to be the final development in some cases of the malady, and of which it would seem to be one of the earliest signals. Upon the whole, however, except in the acute disseminated type, in which the outlook is always grave, the patients do not seem to suffer in any way from the disease, either locally or constitutionally, and its principal rôle and existence seem to be as "a destroyer of good looks," and, unfortunately, its victims are mostly women.

As to the possibilities of treatment, the areas present can almost invariably be benefited, sometimes much improved, sometimes completely cured; but as to freedom from new spots and a disappearance of the malady, no positive opinion can be vouchsafed without qualification. Some cases respond to persistent measures, and in those instances in which the disease activity has already ceased, permanent cure results; in others, especially those in which the tendency to new spots is still present, treatment is often disappointing.

Treatment.—In the management of this disease both constitutional and external remedies are in most instances to be prescribed. While certain drugs internally administered have from time to time been extolled,[1] the fact remains, I believe, that the best plan of general medication which is most likely to have an influence is that which considers the patient, instead of his cutaneous malady; in other words, to be based upon indications in the individual case. Three conditions, it has seemed to me, may tend to retard favorable effect from local treatment—digestive disturbances and constipation, a general debilitated state, and nervous worry or other neurasthenic influences. For the relief of these the ordinary plans or suggestions referred to in the treatment of eczema can be consulted. The bowels should be kept free, and all foods and work or indulgences which tend to flush the face avoided. Alcoholic drinks in any form, as well as hot, rich soups, and pleasures or employment which require great exertion or stooping, and exposure to sun or wind, are therefore prejudicial. Likewise excessive coffee- or tea-drinking and the too free use of tobacco. There are several remedies which in some cases have seemed to be of special influence. Of these, in strumous subjects and those of enfeebled nutrition cod-liver oil, in small or moderate dosage, is sometimes of distinct value. Arsenic has cured some patients, according to Hutchinson and others, and in sluggish, persistent cases may be worthy of a trial. Iodid of starch, according to McCall Anderson, proved effectual in some cases and benefited others. Phosphorus in moderate doses has been commended by Bulkley, and ichthyol in 5- to 15-drop doses three times daily by Unna, Crocker, and others. Both Unna[2] and Brocq[3] speak well of remedies which tend to reduce cutaneous hyperemia, or modify the conditions which produce it, the former commending quinin, digitalis, belladonna, and ergotin, and the latter ichthyol, ammonium carbo-

[1] J. C. White, "Lupus Erythematosus: its Amenability to Treatment," *Jour. Cutan. Dis.*, 1898, p. 457, refers to the various remedies, both internally and externally, prescribed from time to time for this disease.

[2] Unna, "The Treatment of Lupus Erythematosus," *Jour. Cutan. Dis.*, 1898, p. 465.

[3] Brocq, "Traitement des maladies de la Peau," second edit., 1892, p. 525.

nate, and sodium salicylate. Salicin and quinin in large doses have been warmly spoken of by Crocker,[1] and the latter remedy is also indorsed by Eddowes,[2] Payne, and Hartzell.[3] Iodoform, originally recommended by French dermatologists (Besnier and others), but later more or less abandoned, has recently been credited by Whitehouse[4] with a cure of an obstinate and extensive case, given in the dosage of 1 grain (0.065) after each meal. Of the remedies mentioned, my own observations would give the most value to cod-liver oil, salicin, sodium salicylate, and quinin, but as these various drugs are usually administered conjointly with external treatment, it is difficult to gauge more than approximately the amount of influence they exert. The selected drug is prescribed three times daily in dosage of—salicin, 10 to 20 grains (0.65–1.35); sodium salicylate, 5 to 20 grains (0.35–1.35), and quinin, 5 to 8 grains (0.35–0.55).

The essential part of the management of this disease is, however, the **external treatment**, and should be prescribed in every case. The choice of application is guided by the degree of inflammatory action or hyperemia and the irritability of the skin. Recent years have seen the gradual abolition of the destructive methods, or rather their use has become limited to comparatively few cases. Upon the whole, as both the personal experience of White and Unna and their reviews of the subject show, the mildest applications have the widest field of usefulness and are to be depended upon in most instances. My experience is fully in accord with this. As a rule, unless extremely sensitive and irritable, the parts are to be washed with soap and water nightly before the remedial application; and if at all sluggish, the tincture of green soap may be employed. There are two applications which are often valuable in all types, but especially in the markedly hyperemic cases, and which I can commend highly—the calamin-zinc-oxid lotion and the lotion of zinc sulphate and potassium sulphuret (see acne). The former is mild, but nevertheless often making a favorable impression; the latter, originally suggested by Duhring, is moderately stimulating, but astringent and almost always well borne. With one or the other of these preparations it is a good plan to begin the treatment of every case, and later they can be employed in the interim between more active applications. The lotion is to be thoroughly dabbed on, both night and morning if possible. Should roughness, increased accumulation of scaliness, or irritability arise, it can be omitted for a day or two and a simple ointment applied; for this latter purpose one of cold cream, with 10 to 20 grains (0.65–1.35) each of precipitated sulphur and salicylic acid to the ounce (32.), can be used. After a few weeks, once weekly or every ten days, I am in the habit of applying liquor potassæ, pure or diluted, according to the conditions, permitting to dry on and painting over several coats of collodion; this remains on for two to three days, after which the patient again applies the lotion and thus this conjoint plan is continued so long as good results. This plan is a modification of that prescribed by Unna, who applies a paint consist-

[1] Crocker (regarding salicin), *Brit. Jour. Derm.*, 1898, p. 8.
[2] Eddowes, discussion, *ibid.*, 1898, p. 375. [3] Hartzell, personal communication.
[4] Whitehouse, *New York Med. Jour.*, vol. lxix., 1899, p. 159.

ing of 1 to 2 parts sapo viridis and 10 parts collodion, and which can be made more active by the addition of 3 to 5 per cent. of salicylic acid.

Another valuable application as a preparatory one, or for intermittent use, is one of Lassar's paste with ½ to 1 dram (2.–4.) of precipitated sulphur to the ounce (32.), and sufficient calamin, about 1 to 3 per cent., to give it the skin tinge. This can advantageously be combined with energetic washings with sapo viridis or its tincture. Indeed, in the milder cases this latter, used with any plain ointment, is extremely useful. Exceptionally, in hyperemic cases, this stronger soap is too irritant. Another valuable mild method is with soap washing and the nightly, and during the day too if possible, application of mercurial plaster. Unna's ichthyol plaster-mull is also beneficial in some cases. In addition to these various mild applications ointments of sulphur and ichthyol and the several sulphur lotions mentioned under acne can often be used with varying benefit. The ichthyol collodion application of Unna—ichthyol 1 part; collodion 10 parts—is a compressing application of some value, but it is dark colored and temporarily disfiguring. A salicylated collodion (Payne) of 2 to 6 per cent. strength is a clean preparation and often of value, except in markedly irritable cases. Recently Hebra, Jr.,[1] has had good results from cooling applications—alcohol alone or a mixture of equal parts of alcohol, ether, and spirits of mint; the application is to be made frequently,—at short intervals,—and the oftener the better.

If, after a time, no improvement has taken place, then more active measures are to be adopted, and this is more especially advisable if the patches are persistent, with no indication of spontaneous or capricious changes. Of these measures painting over the diseased area (G. H. Fox) pure liquid carbolic acid deserves special mention; if there are more than several patches, not more than two or three should be painted at the one time, as there is occasionally some pain from the application; it should be repeated a few days after the film-like crust produced by it has fallen off—about a week or ten days after the painting. In some instances several repetitions are necessary to remove the patch, and in others again the effect is slight and temporary, or entirely negative, and exceptionally aggravation results. The painting of a solution of salicylic acid in collodion, from 20 to 60 grains (1.33–4.) to the ounce (32.), is also useful in some cases, repeated according to its effect daily or every second day for several days, and then discontinuing until the film comes off, and resuming the painting again, and so on so long as the action is favorable. Resorcin in alcoholic solution or in collodion—the former of 10 to 50 per cent. strength, and the latter 3 to 20 per cent.—is sometimes beneficial, but the collodion solution must be used weak at first, as it sometimes acts with unexpected energy. Solution of silver nitrate, from 10 to 60 grains (0.65–4.) to the ounce (32.), painted on at intervals of a few days or a week, will also prove serviceable in some instances, but it has the disadvantage of discoloration.

In cases in which the patches have been long stationary and are

[1] Hebra, *Wien. med. Wochenschr.*, 1899, p. 14.

sluggish in character, and which have failed to be influenced by the milder remedies, stronger or cauterizing applications can be resorted to. A point to be kept in mind, however, is that these preparations may produce scarring, and this in a disease in which patches sometimes disappear without trace or with but slight atrophic thinning. Among the most valuable of these applications, and only exceptionally destructive to any marked degree, are pyrogallol and arsenical applications. Pyrogallol can be applied in ointment or paint form; in the former, with salicylic acid, and consisting of 20 to 40 grains (1.35–2.65) of salicylic acid, 30 to 60 grains (2.–4.) of pyrogallol, and 4 drams (16.) each of simple cerate and vaselin; it is applied as a plaster, changing twice daily, and continued until some action is effected, and then one of the milder applications or a plain salve used. Its disadvantage is that it blackens the surface for the time. In collodion with salicylic acid, as first suggested by Brooke, it is much more active, and the weaker proportions should be first employed; the formula most commonly prescribed (Brocq) consists of 1 part salicylic acid, 3 parts pyrogallol, and 40 parts flexible collodion; Bukovsky,[1] following Brooke, recommends even a stronger proportion, with 16 parts salicylic acid, 4 parts pyrogallol, and 40 parts collodion. Pyrogallol in collodion often acts with great energy and needs close supervision. Arsenical salve paste, as used in lupus vulgaris, may be tried in limited obstinate patches; it is destructive, however, if used with too much freedom. A safer plan of using arsenic, which I have employed with satisfaction in a few sluggish cases, is that suggested by Schütz, of painting the patches with a weak solution, composed of 1 part Fowler's solution to 4 or 5 parts water twice daily for several days until an inflammatory reaction is produced, and then applying soothing remedies until this subsides, and resuming the paintings, and so continue if improvement is noted. Joseph[2] indorses the careful application to the areas, from time to time, of equal parts of lactic acid and water, a mild ointment to be used in the interim.

Schiff's[3] observations as to the favorable action of the Röntgen rays in this disease have been confirmed by others. I have had good results in several instances. The method does not seem equally efficacious in all cases, in some having no influence whatever. The best effects are attained by pushing the treatment to the production of mild erythema. The Finsen-light method is also one that can be employed in some cases with excellent results.

Neither Röntgen-ray treatment nor the Finsen treatment is as valuable, however, in this disease as in lupus vulgaris. A new plan of treatment, of which I can speak highly, as serviceable in some cases, is that by the high-frequency current, using preferably the flat, hammer-shaped vacuum electrode, and at a distance of $\frac{1}{8}$ to $\frac{1}{2}$ inch from the surface; it should be applied for 3 to 10 minutes—sufficiently long to bring about some reaction. It is repeated at intervals

[1] Bukovsky, *Wien. med. Wochenschr.*, 1899, pp. 1450 and 1500 (a review of the various plans favored by different authorities).

[2] M. Joseph, *Lehrbuch der Hautkrankheiten*, 1898, p. 235.

[3] Schiff, "Fortschritte der Gebiette der Röntgenstrahlen," vol. ii., No. 4; abs.-ref. in *Monatshefte*, vol. xxix., 1899, p. 340.

of 5 to 10 days, the calamin-zinc-oxid lotion or the compound lotion of zinc sulphate and potassium sulphuret being applied in the intervals.

The operative methods which have been commended from time to time are curetting and punctate and linear scarification; and of these curetting is the least desirable, inasmuch as the scarring resulting may be quite pronounced. Both linear scarification and punctate scarification are procedures that, as a rule, require several repetitions, usually at intervals of one or two weeks. In addition to these methods galvanocauterization by means of variously shaped cautery-points or knives and by the Paquelin thermocautery has been in favor with some French dermatologists, employed as in lupus vulgaris. These operative procedures are, however, but little employed at the present time, and indeed the tendency is to depend more and more upon the milder measures, and in this respect the experience of Duhring, White, Crocker, Hyde, Brocq, and most other observers is fairly in accord. White[1] is right, I believe, when he states that if obliged to give up nine-tenths of the numerous applications variously commended from time to time, he would retain the mildest tenth as the most reliable.

SYPHILIS.

Synonyms.—Pox; Lues; Lues venerea; *Fr.*, Syphilis; Vérole; *Ger.*, Syphilis; Lustseuche.

The syphilitic virus finds its way into the system by inoculation, usually as a result of impure sexual intercourse or through accidental contamination, the first evidence of the malady being the so-called "*initial lesion*" or *chancre*. This may present the appearances of a slightly scaly, flattened papule, a film of infiltration, a surface abrasion with underlying infiltration, or a variously sized, usually small, crateriform ulcer with moderate or marked underlying and surrounding infiltration. Still another type is occasionally encountered, consisting of an abraded surface, with but slight or moderate infiltration, and covered more or less completely with a somewhat tenacious, firmly adherent, pseudomembranous film or exudation. The most common site for the initial lesion in the male, as well known, is some part of the genital region, usually on the glans, at the corona, on the prepuce, or shaft of the organ; in the female, on the small or large labia, on the clitoris, or within the vaginal entrance, or higher up. The lesion as thus met with belongs more distinctly to the province of the genito-urinary specialists, and for detailed description the reader is referred to works on venereal diseases.

The *extragenital* or "*non-venereal*" *chancre* is a matter of not uncommon dermatologic observation. It may be seen upon any part of the body, although by far most frequently about the face, particularly the lips. The tongue is likewise sometimes the seat of the lesion, and it is occasionally found upon the tonsil. The finger, especially at the lateral nail-groove, is also a not uncommon situation.[2] On these extra-

[1] J. C. White, *loc. cit.*

[2] D. W. Montgomery, "The Location of Extra-genital Chancres," *Jour. Cutan. Dis.*, 1905, p. 342, covers the subject well; based upon his own cases and those reported by others, with bibliography; considers also relative frequency (more than 5 per cent.) as compared to genital chancres.

PLATE XXI.

Chancre of the lip: a not uncommon type, with but slight to moderate underlying induration and a quite characteristic pseudo-membranous coating frequently observed.

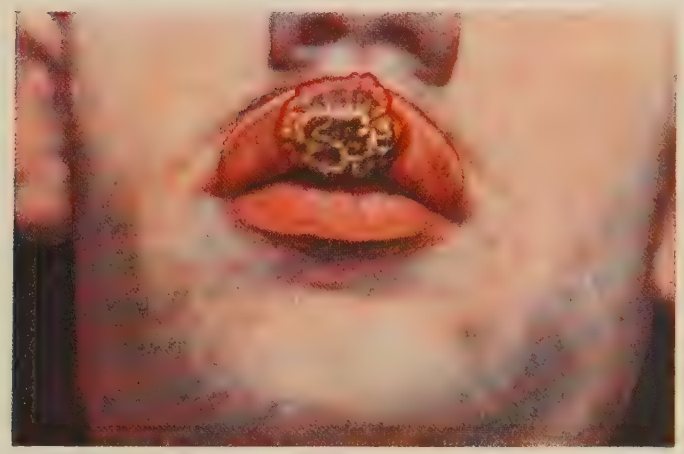

Chancre of the lip: a common type, with considerable underlying and surrounding infiltration and induration.

genital situations chancres do not differ from those seen on the genitalia. On the lip the superficial flat lesion, with the pseudomembranous coating, is not unusual, although in other instances it has the typical subjacent and surrounding infiltration and the crateriform ulcer. This latter variety is also generally that seen on the tonsil. Both on the lip and about the finger-nail the first evidence is often a persistent fissure. In the latter region sometimes the lesion is exceedingly insignificant.

As a rule, there is rarely much difficulty in the **diagnosis** of extragenital chancres, presenting, as they generally do, the slow development and course and the characteristic induration. A patient coming with the statement that he has had a "persistent fissure or fever blister on the lip which will not get well" should always lead to careful inspection. If such lesion has been of a few weeks' duration, an examination will often show a beginning chancre. Any sore on the lip which has existed several or more weeks must be looked upon with suspicion, as ordinarily, if not epithelioma, it is the initial induration of syphilis. In fact, this holds more or less true with any single sore upon the face or other parts. A suspicious lesion, of a few weeks' duration, with enlargement of the nearest anatomically connected lymphatic glands, is almost invariably found to be a chancre. A persistent crack at the border of the nail, in those unaccustomed to fissuring or chapping, should always be carefully watched; not infrequently induration will be disclosed and beginning enlargement of the neighboring glands. A single circumscribed and hardened lesion or ulcer on any part, whether integument or mucous membrane, points commonly to either chancre or epithelioma, and if this is borne in mind, a correct conclusion is generally easily reached. It is by overlooking the fact that a chancre is not necessarily always a genital and venereal lesion that mistakes are ordinarily due, for, as a rule, when this is recognized, the differentiation from other diseases is rarely difficult.

CUTANEOUS MANIFESTATIONS OF ACQUIRED SYPHILIS.

Synonyms.—Syphilis cutanea ; Syphilis of the skin ; Dermatosyphilis ; Syphiloderma ; Syphilid.

Syphilitic manifestations of the skin constitute an important class of dermatologic cases, and the presence of such lesions, history of their occurrence, or resulting scars often furnish important clues to the possibility or probability that some existing obscure organic or constitutional condition may be due to the same cause. The various syphilodermata can be conveniently considered dermatologically without special division of the so-called secondary or tertiary stages, incidental mention being made on this point in connection with each variety of eruption. After the appearance of the initial lesion of syphilis there is, as is well known, a variable period of a few weeks or longer, known as the "period of second incubation," in which the disease is apparently quiescent, except that slowly and gradually following the enlargement of the nearby lymphatic glands, there is a general invasion of this glandular system, although glands

in other situations never reach the same development in this particular as the lymphatic structures connected anatomically directly with the chancre. This general *adenopathy* is usually readily recognized by palpation of the more superficial glands, as the post-auricular, occipital, submental, submaxillary, anterior and posterior cervical, axillary, epitrochlear, inguinal, etc. This adenopathy usually reaches its greatest development at about the time of or during the outbreak of the secondary cutaneous symptoms. The enlargement varies, exceptionally being so slight as to be scarcely, if at all, recognizable, and in occasional instances attaining considerable dimensions. As a rule, however, in the various situations named one or several of the glands are found pea- to bean- and small-nut-sized or somewhat larger, and are hard, indolent, and painless, with no tendency, in uncomplicated cases, to suppurative action. In scrofulous subjects and in others where accidental pyogenic inoculation also takes place, the glands, more especially those anatomically connected with the site of the chancre, may undergo softening and break down. Such, however, is not of common occurrence. The adenopathy of syphilis usually persists, more or less, though the secondary stages of the disease, and often, especially in those patients untreated, somewhat indefinitely. It is not, however, a part of a late tertiary cutaneous manifestation, except sometimes in nearby glands, and more particularly when there is ulceration with suppuration—the glandular enlargement or sympathy being then due rather to the latter process than to the malady itself.

The advent of the secondary stage of syphilis, the most characteristic symptoms of which are the more or less generalized cutaneous eruptions, occurs a somewhat variable time after the date of exposure or inoculation, varying within considerable limits from four or five weeks to some months. Most authors place the average at about eight weeks, and this accords with general experience, although the outbreak is not uncommon about the sixth week, and the possibility of a much longer period is also to be recognized.[1]

Preceding the eruptive outbreak for several days or one or two weeks certain other symptoms—one or several—are not infrequently observed, such as rheumatism, especially about one or two joints, severe persistent headache, neuralgia, bone pains, some loss of weight, a dinginess or unhealthy-looking skin tint, febrile action (syphilitic fever), and a general feeling of lassitude, and occasionally a distinctly cachectic condition (syphilitic cachexia). According to White and Martin, examinations of the blood at this time, and also earlier, usually show a slight increase in the white blood-corpuscles, a lessening of the red corpuscles, and a marked diminution in the hemoglobin percentage. These various symptoms, if present, often persist for

[1] Bergh's review (*Monatshefte*, 1893, vol. xvii., p. 593) of the subject on this point is of value, naturally, indicating considerable variation, although the period just mentioned can be considered the rule. His own statistics of 254 cases in males show that in 2 cases the general eruption appeared in the fourth week, in 11 in the fifth, 20 in the sixth, 28 in the seventh, 32 in the eighth, 21 in the ninth, 30 in the tenth, 23 in the eleventh, 16 in the twelfth, 13 in the thirteenth, 24 in the fourteenth, 27 in the fifteenth, 3 between the twentieth and twenty-fourth, and 4 between the latter and the twenty-ninth; the extremes being twenty-four and two hundred and four days.

days or weeks, or subside measurably or completely upon the full development of the eruption, or they may show no tendency to abate until active and energetic treatment is instituted. The syphilitic fever is occasionally sufficiently severe to simulate or suggest other febrile diseases. Some cases, may, however, remain absolutely free from any such disturbances, and the eruption be the first sign of constitutional syphilis. In fact, the secondary stage of the disease may be so extremely mild in all respects that its occurrence is overlooked, and if the chancre has been slight, or in women and in concealed situations, it may be that late tertiary eruptions or other syphilitic symptoms may be the first recognized evidences of the malady. This is not an uncommon observation in married women who have contracted the disease unknowingly through the marital relation. As a rule, however, secondary manifestations of the disease are sufficiently pronounced to lead to seeking of medical advice, even though the initial lesion had escaped the patient's notice. A few remarks upon some of the characteristics of syphilitic eruptions in general may be of value before describing the various types individually.

General Observations and Diagnostic Characters.—Syphilis, not only in its cutaneous symptoms, but in all its relations, varies considerably in different cases. It may be benign in character (benign syphilis), scarcely making any impression, or in occasional instances extremely severe or malignant (malignant syphilis), striking the patient with tremendous force, giving rise to profound anemia, marasmus, and even death. Ordinarily, however, its course is mild or only moderately severe; in some instances quite pronounced, with a variable degree of malignancy. Sometimes this severe or malignant character seems to be mainly shown in the type, persistence, and recurring tendency of the skin-lesions, the general health remaining fairly good.

Syphilis, in its cutaneous manifestations, at least, can truly be said to be a great imitator, as there is scarcely an eruption, exclusive of some of the exanthemata, that can not, in a measure, and sometimes strikingly, be simulated. Nevertheless, the syphilodermata in most instances are sufficiently distinctive in some features to make their recognition ordinarily a matter of but little difficulty; on the other hand, the resemblance to other affections may sometimes be so great as to demand most careful investigation and occasionally several days' or one or two weeks' observation before a positive conclusion can be reached.

Distribution.—The earlier cutaneous manifestations—those of the secondary period of the malady—are more or less general and symmetric in distribution, although in many instances the different types may show a preponderance on certain regions, as will be referred to in describing the individual eruptions. It may be said, however, that in many cases the upper part of the forehead, just at the margin of the hair, the angles of the mouth, the nasolabial folds, the palms, soles, region of the anus, and genitalia are frequently the seat of lesions. The syphilitic eruptions may be abundant or somewhat scanty, and vary considerably in duration. In relapses the eruption is much more scanty and usually of less general dissemination, with

a disposition to irregular or ill-defined grouping or aggregations. The late syphilodermata, those of the declining active or secondary stage, and particularly those of the tertiary period, are rarely of wide distribution, but, on the contrary, are commonly confined to one or several regions, with a distinct grouping tendency.

Configuration and Color.—In the earlier syphilitic eruptions, as already remarked, there is exhibited but little, if any, tendency to special grouping or configuration. The lesions are usually rounded or ovalish, sometimes irregularly so. In occasional cases of the erythematopapular manifestation, especially in negroes, some of the lesions, more particularly about the mouth, lower part of the face, and neck are distinctly annular. In the later secondary, relapsing outbreaks irregular grouping occurs, sometimes with a segmental or circinate tendency, but, as a rule, these characters are reserved for the later or tertiary eruptions, of which the tubercular syphiloderm is representative. Here the tendency to segment, circinate, and serpiginous arrangement is more or less constant, and, taken together with chronicity, is almost diagnostic.

The color of the syphilodermata is a dingy, sluggish, or dull red, often coppery. In the earliest part of the outbreak, more particularly of the macular syphiloderm, the hue may be a brighter one, often of a quite distinctly inflammatory aspect, but this is soon lost, and the dull red to brownish red soon presents, and which finally amounts to brownish pigmentation, which, however, eventually disappears. The dull or coppery red is often very suggestive, but color alone is rarely to be depended upon for positive differentiation—it is simply to be viewed as one of a group of diagnostic factors, which together are clearly conclusive.

The *ulcers* of early pustular syphilodermata are superficial, and, as a rule, have no special characteristics; those of the later forms are segmental, rounded, or kidney shaped. The *scars* resulting from syphilis are usually soft, pliable, and somewhat insignificant, commonly showing minute puncta or perforations, the sites of former follicles. Those resulting from the later eruptions take the shape of the lesions or groups giving rise to them, and the segmental or horseshoe-shaped scar or scars will often serve as the key to the past or associated present trouble. Such scars are commonly soft, and relatively insignificant compared to the preceding ulceration; they are rarely tough or striated, as frequently noted in lupus cicatrices, although this tendency and a keloidal disposition are sometimes observed when at the joints.

Polymorphism.—While the generalized or secondary syphilodermata can rarely be said to be, to any large extent, polymorphous, the type being usually more or less uniformly papular, pustular, etc., yet it is just as true that in most cases several or more characteristic lesions of another variety than those which chiefly make up the eruption are to be found when the surface is carefully inspected, and this fact is often of value in the diagnosis—as, for example, in differentiating the papular syphilid from lichen planus and the papulosquamous syphilid from psoriasis, etc., two diseases which are always uniform. In the macular syphiloderm will often be found some scattered lesions with a

papular tendency—maculopapules, and commonly also clearly defined papules, especially about the anal and genital regions; in the small papular syphilodermata several or more well-developed scattered pustules are not unusual, and more frequently, especially in the miliary papular syphilid, many of the papules often show a pustular tendency at the summit. The pustular syphilodermata generally exhibit, here and there, typical papules and so on; commonly, too, there is an admixture of several or more lesions of a larger or smaller type than those of which the eruption is chiefly made up, as some large pustules in the miliary pustular syphilid, some large papules in the miliary papular eruption, etc. Occasionally, also, the eruption may be composed of lesions of intermediate type, as in the papulopustular syphiloderm and papulotubercular syphiloderm.

Subjective Symptoms.—The syphilitic eruptions are usually unaccompanied by subjective symptoms, and this factor can sometimes be utilized as a differential point in some instances. An exception must be made to this statement as to the negro, if we are to accept his word for it, inasmuch as in this race slight or moderate itching is usually complained of, although it is rarely sufficiently severe to give rise to active scratching and resulting excoriations. The miliary papular and miliary pustular syphilodermata seem to be most troublesome in this respect, and these forms occasionally give rise to insignificant pruritus in the white race as well. Pain likewise is rarely noted in the early syphilodermata, although about the anus and genitalia, where they are subjected to considerable heat, moisture, and friction, not only may the lesions become somewhat painful, but be also itchy to a varying degree. The statement of many patients with such eruptions, either voluntarily or upon interrogation, that they are or have recently been suffering with an attack of what they think hemorrhoids is not an uncommon one, and is, indeed, often a suggestive one. In the later ulcerating syphilodermata there may or may not be more or less pain; as a rule, however, it is rarely sufficiently great to give rise to complaint.

Course and Duration.—The syphilodermata of the active or secondary stage usually appear somewhat rapidly and attain full development in one or two weeks, after which, except generally in the macular syphiloderm, it is not uncommon for a few new lesions to show themselves irregularly for a short time. In some cases there is but a scanty scattered outbreak at first, followed in several days or one or two weeks with a more or less profuse outburst. Exceptionally the eruption remains scanty throughout. After several weeks the macular syphilid has generally pretty well declined; in the other types there is often a somewhat stationary period for a month or so, with now and then, in some cases, a slight recrudescence. Disappearance gradually takes place, however, in a few months in some instances, much longer in others, occasionally leaving more or less persistent lesions on certain regions, as the palms. The papular eruption is quite prone to slight relapses for some months. In the late, or tertiary, eruption there is but little tendency to spontaneous disappearance.

Concomitant Symptoms.—Along with the cutaneous manifestations

of the active or secondary stage of syphilis other symptoms of the malady are usually associated. The chancre, as is well known, often persists, or its mark or scar is found. The anatomically connected glands are noted to be enlarged, and general adenopathy is likewise usually readily recognized. Sore throat, mucous patches, or superficial ulcers on the inner aspects of the lips, in the mouth, pharynx, etc., are commonly observed, in some cases to considerable extent, in others slightly, and exceptionally scarcely at all. Iritis, cephalalgia, bone pains, etc., are also sometimes noted. The skin is commonly sallow or dingy looking, and the patient anemic, and with a tendency at first to lose flesh. It is seldom, however, that all of these symptoms are observed in the one case—sometimes but one or two. In the late, or tertiary, syphilodermata concomitant symptoms are often wholly wanting, although sometimes bone lesions, bone pains, alopecia, superficial glossitis, leukoplakia—one or more —may be present. Much more frequently, however, only evidences of former disturbances are to be found, such as scars, the effects of iritis, etc.

Under this head *affections of the appendages* of the skin—the hair and nails—due to syphilis, which are also incidentally referred to under diseases of these parts, can be here conveniently briefly described before taking up the individual eruptions proper. **Alopecia**, or hair loss, consisting of a general falling of the hair (defluvium capillorum), more particularly the scalp hair, is noted in the early period of the secondary stage, but rarely amounts to visible baldness, but is more of a simple thinning. The amount varies in different cases, in some the loss daily being considerable, in others slight, and sometimes scarcely enough to attract the patient's notice. It is not only due directly to the infection itself, but sometimes indirectly also to the seborrheic condition, which the disease not infrequently engenders. Occasionally, instead of a general thinning, it occurs in ill-defined and incomplete small and irregular, sometimes coalescent, patches—not the clearly cut patches of true alopecia areata—which give the scalp a "moth-eaten or mangy appearance." The hair also shares in the general "dinginess" which the disease often produces, becoming dry, more or less lusterless, and lifeless looking, associated with the sallow or dingy appearance of the skin, especially of the face. As a rule, in hair loss due to this disease, full or tolerably complete regrowth takes place if the patient is not advanced in years or has no family tendency to baldness—in such the loss is not usually replaced. In cases where ulcerative lesions occur upon the scalp, as occasionally in the late or tertiary stage, and exceptionally earlier, the follicles are destroyed, and in such spots or areas the loss is permanent.

The nails are also occasionally involved, either one, several, or more, and of fingers or toes. Both **onychia** and **paronychia** are met with, usually in the active secondary stage, in acquired syphilis, as well as in hereditary syphilis, referred to later. The usual initial factor is the presence of syphilitic lesions, generally papules or ill-defined infiltration, of the bed, matrix, or nail-folds. There is commonly observed resulting nutritive disturbance, as shown by thickening, brittleness or

friability, and opacity, and often furrows, depressions, or other irregularities; if the underlying infiltration is marked and inflammatory, sometimes with a tendency to ulceration, the nail is usually uplifted, but, as a rule, more or less incompletely, at first at least, becoming more detached later, and not infrequently dropping off. Generally the nails are replaced, although at first may be ill formed. In other instances there are no visible traces of distinct irritation or infiltration of the bed, matrix, or surrounding parts, the nails showing merely the effect of the general impaired nutrition produced by the disease; they become somewhat opaque, brittle, tend to break at the free edges, and occasionally exhibit furrows or other evidences of nutritive disturbance.

Instead of chiefly limiting itself to the bed and matrix of the nail, the inflammatory or infiltrating process may extend to the surrounding parts, or it may begin at the latter, and a somewhat variable grade of paronychia results, with the usual symptoms of this condition. The skin surrounding the nail is reddened, swollen, the tissues infiltrated, and suppuration or ulceration may result, and give forth a fetid discharge. If severe, the finger-end may show club-like enlargement, but this is never so well marked as in infants in hereditary syphilis. In fact cases vary considerably; Taylor divides paronychia into three forms: ulcerative, indolent, which is, as a rule, non-ulcerative, and the diffuse; the non-ulcerative form, usually starting as a more or less continuous band of infiltration; the ulcerative form, beginning as a papule or pustule at the lateral edge or as an ulcer or fissure at the border of the lunula; and the diffuse variety, as a hyperemia, involving the surrounding parts, and later the end of the terminal phalanx, and followed by infiltration and bulbous swelling. The nail is frequently discolored, and also often exhibits other changes, such as just referred to, and may fall off. In the usual grade of cases met with, however, this does not result. One or several may be involved, and either of the fingers or toes. As a rule, there is not sufficient pain to give rise to actual discomfort, and not infrequently, unless knocked, the affected part is practically painless.

Macular Syphiloderm (Synonyms: Macular syphilid; Erythematous syphiloderm or syphilid; Syphiloderma maculosum; Syphiloderma erythematosum; Syphilis cutanea maculosa; Roseola syphilitica; Exanthematous syphiloderm or syphilid).—This is usually the earliest and most common of the secondary syphilitic cutaneous manifestations, appearing commonly about six to eight weeks after inoculation, although its appearance occasionally is somewhat later. It is generally distributed, being most abundant, as a rule, on the sides of the trunk and axillary folds, the umbilical region, the neck, and the flexor aspects of the arms. The palms and soles also generally show numerous lesions, with often in some a tendency to become maculopapular or papular. The face and dorsal surface of the hands and feet frequently escape, although ill-defined papules may sometimes be seen associated at the corners of the mouth and at the nasolabial folds. The eruption may come out at once, or gradually for a period of several days or longer, and, especially in instances of sudden

outbreak, is often preceded and for a time accompanied with febrile action. In many of these latter cases a hot bath or violent exertion or excitement often seems to be the immediate exciting factor.

The eruption consists of small or large, commonly pea- or bean-sized, rounded or irregularly shaped, sometimes slightly raised, macules, which, when well established, do not entirely disappear under pressure. They show no disposition to crescentic or other peculiar shapes, although in a few instances there are associated maculopapular or papular lesions about the mouth, chin, and neck, which exhibit a tendency to annular configuration (annular or circinate syphiloderm). At first the color of the macules is a pale pink or dull, violaceous red, later, after several days or a week, becoming yellowish red or coppery. The efflorescences are usually profuse, frequently crowded, but rarely forming coalescing areas; often they are faint, and do not show clearly until the surface has been exposed for several minutes —cold always makes the eruption stand out more boldly. In cases in which the lesions are of a violaceous tinge the skin is given a marbled look, especially when exposed to a cool atmosphere. In some cases, instead of an abundance and closely crowded, the macules are present in scanty number and widely scattered, and could readily escape observation. In fact, in quite a number of instances it is so mild that patients are first made aware of its presence by the physician, who, led by the existence of suspicious sore throat, mucous patches, or the initial sore or glandular swelling, for one or all of which he may have been consulted, makes a general examination of the surface. There are no subjective symptoms.

After persisting for one to several weeks, it gradually or somewhat rapidly disappears, usually without desquamation, although slight scaling or exfoliation is not uncommon in those macules which tend to papular development, and which is not unusual with lesions on the palms. Slight or moderate brownish-yellow pigmentation may, in some cases, remain for some weeks or longer. Occasionally there may be a slight recurrence, in which the macules are usually scanty in number and somewhat larger than ordinarily, and sometimes tend to annular configuration (annular or circinate syphilid).

In some instances many of the lesions of the macular eruption show a tendency toward papular development, usually reaching a midway stage, forming maculopapules; and occasionally this occurs with almost the entire eruption, so that it is more clearly designated maculopapular in type. Even if this tendency does not present, it is not uncommon to find a few such lesions in the palms or soles and about the genitalia or anus, in the latter two situations often becoming well-developed papules, which may become macerated and moist. The macular syphiloderm disappears rapidly under specific constitutional remedies.

The **diagnosis** of the macular syphiloderm is rarely attended with difficulty, inasmuch as it is commonly associated with other syphilitic manifestations, such as a few or more scattered maculopapules or papules, sore throat, mucous patches, moist papules about the anus, falling of the hair, and, in most cases, the chancre is still present. The presence or absence of such concomitant symptoms is of

PLATE XXII.

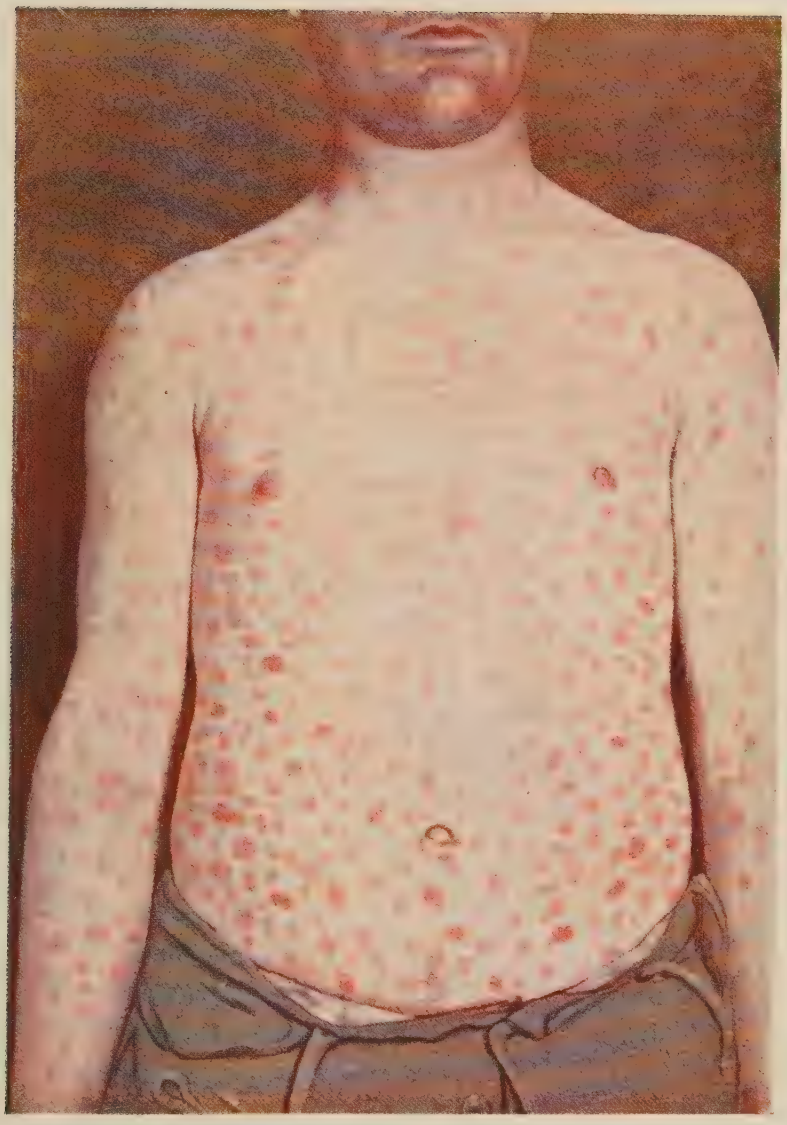

Macular syphiloderm, with some maculopapules on the lower part.

greatest value in the diagnosis. It is to be distinguished chiefly from measles, rötheln, tinea versicolor, and some drug eruptions. Measles is to be differentiated by its catarrhal symptoms, fever, crescentic and blotchy character, and the situation of the eruption, all of which differ materially from those of the macular syphiloderm. Too much stress is not, however, to be placed upon the febrile action, as this sometimes may be quite sharp in syphilis. In rötheln there are small, roundish, confluent, pinkish or reddish patches, with no tendency to pigmentation, and which are of short duration; there is, moreover, usually evidence of its epidemic character, and slight catarrhal symptoms, as in measles. The erythematous drug rashes sometimes following the ingestion of copaiba, cubebs, belladonna, opiates, etc., are a much more vivid red or scarlet, and are, as a rule, quite itchy and of short duration. The evanescent wheal of urticaria, with the accompanying itching, and the punctate scarlet redness of scarlatina, are so unlike the macular syphiloderm that confusion with these diseases is scarcely possible. The differentiation from tinea versicolor is mentioned under the latter disease.

Pigmentary Syphiloderm[1] (Synonyms: Syphiloderma pigmentosum; Syphilitic leukoderma; Vitiligo acquisita syphilitica).—This is a rare manifestation about the correct nosology of which there has been much difference of opinion. It is now pretty generally conceded, however, that it is of syphilitic origin, although some authors still maintain that it has no direct relationship to this disease. While first described by Hardy in 1853, it was not until Fournier's presentation of it (1873) that it received much attention. Since then various observers, among whom G. H. Fox, Atkinson, Taylor, Maireau, Pœlchen, Malherbe, Neisser, and Maieff have reported cases or contributed special papers. It is essentially a macular eruption, although totally unlike the macular syphiloderm as commonly met with and just described; the former is one of pigmentary changes pure and simple, the latter due to hyperemia. It appears during the earlier secondary stage or toward the end of the first year, although it sometimes does not present until a later period. The region of the neck and shoulders is its usual location, Fournier stating that in but 1 in 30 cases is it found elsewhere than on the neck; although it may also, however, exceptionally invade other parts.

According to Taylor, three forms are encountered—(1) as spots or variously sized brownish patches; (2) more or less diffused brownish

[1] Principal literature: Hardy, *Maladies de la peau*, Paris; Fournier, *Leçons sur la syphilis, étudiée plus particulièrment chez la femme*, Paris, 1873, p. 422 (with colored plate); G. H. Fox, "On the So-called Pigmentary Syphilid," *Amer. Jour. Med. Sci.*, April, 1878; Atkinson, "The Pigmentary Syphiloderm," *Chicago Med. Jour. and Exam.*, 1878, vol. lxxxvii., p. 340; Neisser, "Ueber das Leucoderma syphiliticum," *Archiv*, 1883, p. 491; Taylor, "On the Pigmentary Syphilid," *Jour. Cutan. Dis.*, 1885. p. 97; Pœlchen, "Vitiligo acquisita syphilitica," *Virchow's Archiv*, 1887, vol. cvii., p. 535 (with 2 colored plates); Malherbe, "Deux cas de syphilide pigmentaire chez l'homme," *Gazette méd. de Nantes*, Dec. 12, 1895, p. 13 (2 cases), abs. in *Annales*, 1896, p. 968; Maieff, "Contribution a l'étude de la syphilide pigmentaire," *Trans. Internat. Dermat. Congress*, Paris, 1889, p. 677 (with bibliography); Maireau, "Syphilide pigmentaire," *Thèse de Paris*, 1884 (with literature references); Lang, *Vorlesungen über Pathologie und Therapie der Syphilis*, Wiesbaden, 1896, p. 208 (with cut); Ehrmann, "Ueber Hautfärbung durch secondar-syphilit. Exanthemata," *Archiv*, 1891, p. 79.

discoloration, which subsequently becomes the seat of small, spotty, leukodermic changes, which increase in size, and the general appearance of which is retiform (retiform pigmentary syphiloderm or syphilid); (3) an abnormal or uneven distribution of pigment, the surface having a dappled or marmoraceous aspect (marmoraceous pigmentary syphilid). The first, spot or patchy form, varies in color between a light and dark brown, and the spots or patches are rounded or oval, sometimes with irregularly jagged edges, and not commonly with uniform pigmentation, the bordering part frequently showing the deeper shade. Intervening white skin looks relatively of diminished normal pigmentation. The second or diffused form is the most usual type encountered, beginning at the neck, especially at the sides, where it may remain, or it may invade the trunk and arms. Its appearance



FIG. 155.—Pigmentary syphiloderm (neck and shoulders); was first diffused pigmented, the vitiligo-like spots subsequently appearing (syphilitic leukoderma); presented about the sixth to eighth month of the disease. Patient a woman.

may be rapid or gradual. Sooner or later white points or spots show themselves, and the condition is somewhat suggestive of leukoderma. Generally it is this change which first calls the attention of the patient to the existing discoloration. The third variety is the rarest of all, and its advent is insidious, and is always seen (Taylor) on the sides of the neck, with no tendency to spread. According to Taylor, there is no hyperpigmentation, primarily at least, but the process is more that of irregular pigment absorption, the intervening remaining normally pigmented spots appearing dark by comparison; other observers, however, have noted the contrary. For some time the manifestation was considered to occur in women only, but this is now known to be erroneous, as it has been also observed, although much less frequently, in males by Chambard,[1] Malherbe (*loc. cit.*), and others. It is much more common in brunettes.

There is a diversity of views as to whether this eruption, if it may be so called, arises as such or is in reality a vitiligo of syphilitic origin, originating in the spots of a preceding syphiloderm (Fox, Lang,

[1] Chambard, cited by Crocker, *Diseases of the Skin*, second edit.

Neisser, Pœlchen). Its duration is variable,—from a few months to several years or more,—it is without subjective symptoms, and is wholly uninfluenced by antisyphilitic remedies, in this respect differing from all other syphilitic manifestations; and this last fact, it must be confessed, gives some grounds for at least questioning whether it is a syphilitic manifestation *sui generis*, or a chloasmic condition dependent upon a syphilitic cachexia or upon a previous evanescent, ordinary, macular syphiloderm.

In the **diagnosis** care is to be exercised that it be not confused with ordinary chloasma, vitiligo, and tinea versicolor. Its usual limitation to the neck, with little if any tendency to appear in other situations, is unusual with these several affections; tinea versicolor, moreover, always involves at least the upper chest region as well, and its slight furfuraceous or branny scaliness noted when the skin is dry is another differential factor to which many more would, if necessary, readily suggest themselves by referring to the description of that malady.

Papular Syphiloderm (Synonyms: Papular syphilid; Syphiloderma papulosum; Syphilis cutanea papulosa).—There are several varieties of the papular syphiloderm, which, inasmuch as they differ materially in clinical appearances, can be most conveniently considered separately, under the heads of the miliary papular syphiloderm, flat papular syphiloderm, and the papulosquamous syphiloderm.

Miliary Papular Syphiloderm (Synonyms: Miliary papular syphilid; Acuminated papular syphiloderm or syphilid; Follicular syphiloderm or syphilid; Syphilitic lichen; Lichen syphiliticus).—The miliary papular syphiloderm is a tolerably common manifestation of secondary syphilis, but much less so than the flat papular eruption. Other associated symptoms of the active stage of syphilis are naturally usually to be found. It may appear apparently independently of an earlier macular syphilid, and most frequently between the third and fourth months. In contradistinction from the flat papular eruption it is follicular—connected with the hair-follicles. There are two varieties—the small miliary papular syphiloderm and the large miliary papular syphiloderm, although there is in reality but slight difference, and therefore the variety is not always clearly defined. In the small miliary papular syphiloderm the lesions are pin-head in size, in the larger form two or three times as large. They may be acuminate or somewhat rounded. As a rule, the eruption comes out rapidly, and continues to appear for several days or one or two weeks. It is usually most abundant upon the shoulders, upper part of trunk, arms, and thighs. It is also frequently in profusion upon the face. The lesions are often closely crowded, with a tendency to form groups and aggregations, this being especially shown in relapses or when the eruption appears rather late. In relapses they may also tend to form segmental and circular grouping. At first they may be of a pinkish-red color, but, as a rule, and always sooner or later, they are of a dull or ham-red color, with a brownish or violaceous tinge, are solid and somewhat rough to the touch, and in the larger lesions there may be slight or scarcely per-

ceptible central depression or umbilication. Generally, however, they are somewhat acuminate or conic, often with a slightly scaly apex, and not infrequently show minute, vesicopustular or pustular summits. In fact, it is not at all uncommon to see a slight or moderate sprinkling of miliary pustules. There are sometimes also several or more scattered flat papules, especially about the genitalia and anus, where they frequently change into moist papules. After lasting for some weeks or a few months there is a slight, sometimes moderately well-marked, tendency toward spontaneous disappearance; the color becomes duller or more somber, and especially as the papules sink away there is often around the outer portion a collar or collarette of film-like scaliness.

FIG. 156.—Papular and papulo-tubercular syphiloderm; eruption general.

The miliary papular syphiloderm is, as already intimated, somewhat chronic in its course, and often persists for months, and is, when compared with the macular and flat papular syphilodermata, slow to respond to treatment. Those having vesicopustular or pustular summit show a capping of brownish, thin, desiccated crusting. During its existence it is not uncommon to see scattered fresh papules, and sometimes a few pustules appear at irregular intervals. Like the others, there is rarely any complaint of subjective symptoms, but in the negro there seems to be considerable itching associated with this type. Minute brownish stains marking the sites of the lesions

PLATE XXIII.

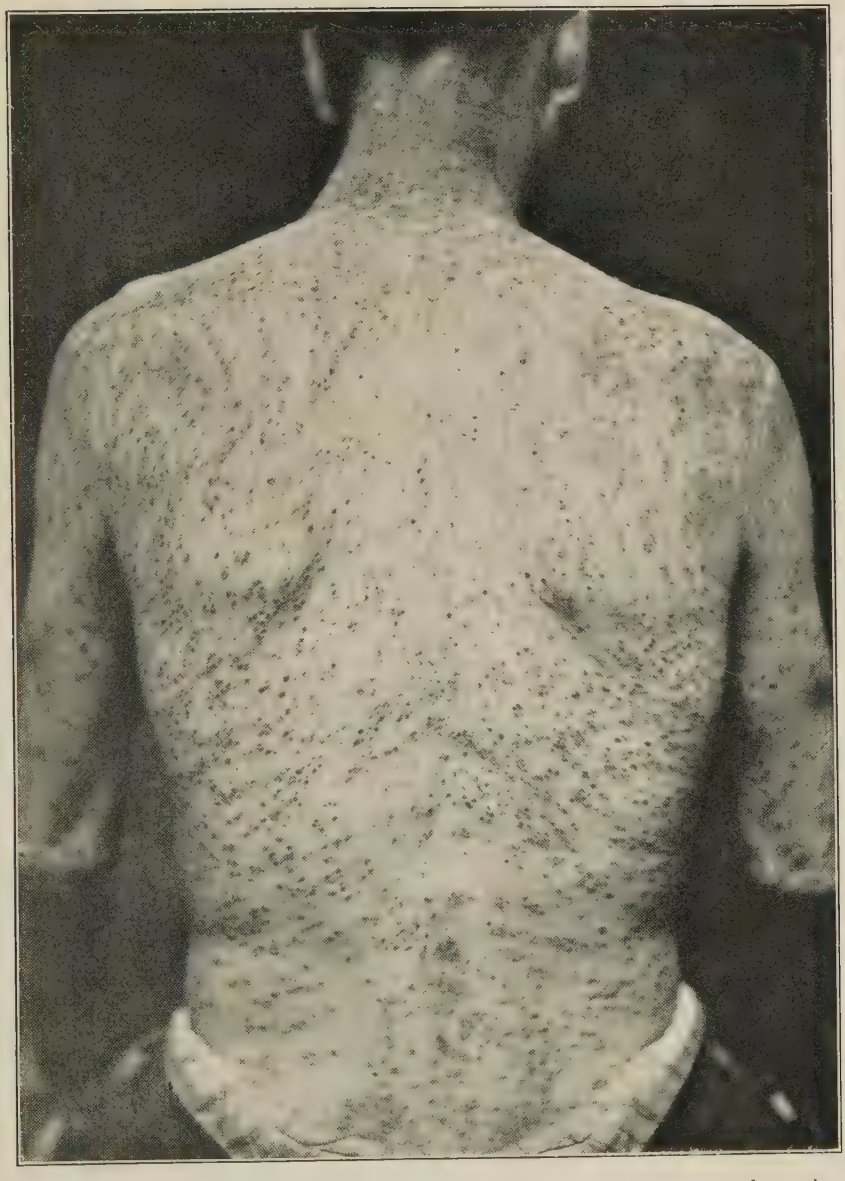

Miliary papular syphiloderm with a tendency in some lesions to become pustular at the summit; shows the disposition toward small aggregations.

are left for a variable period—sometimes for months; there is no scarring, unless with pustular lesions, which may leave insignificant atrophic or cicatricial points or pits.

The **diagnosis** of the miliary papular syphiloderm is to be based upon distribution and extent of the eruption, the color, the tendency to group and form aggregations, and the presence usually of some lesions with pustular summits, often scattered minute pustules, and occasionally a few large papules and pustules; these features, together with the existence of one or several associated symptoms of syphilis, will scarcely permit of error. It is not to be confused with keratosis pilaris, psoriasis punctata, pityriasis rubra pilaris, papular eczema, or lichen planus. Keratosis pilaris is most pronounced and often limited to the thighs, sometimes also on the arms, but rarely on the trunk; there is no crowding or aggregation, it is often itchy, and usually already of long duration when advice is sought, with but little tendency to spontaneous disappearance. The lesions of psoriasis in their earliest formation bear some resemblance, but are not follicular, do not tend to form groups and aggregations, and are all scaly papules, with no pustular tendency, and the distribution, while it may be more or less general, is usually most pronounced about the extensor surfaces of the legs and arms; it is chronic, and commonly a history of long duration is given, and there is, moreover, a definite tendency to enlargement of the lesions into plaques, which may become confluent. Pityriasis rubra pilaris is a scaly papular follicular disease, but without disposition to pustulation, and with a tendency to confluence, marked scaliness, and progressive, persistent spread and chronicity. The marked itchiness of papular eczema, its usually limited distribution and tendency to solid confluent patches, the vivid red color, and often associated vesicles, will serve to prevent mistake. Probably its strongest resemblance in some instances is to lichen planus, but this latter is rarely generalized, favorite situations being the lower part of the legs and forearms, to which it is often limited; there is a decided tendency to confluence and solid scaly patch-formation; it is usually slow in its advent and persistent, often slowly progressive, and, as a rule, very itchy. The scattered aggregations of relapses may suggest lichen scrofulosus, but this latter is a rare affection, usually occurring as several, rarely more, livid or brownish papular aggregations, of chronic, persistent character, and commonly associated with other evidences of the scrofulous diathesis.

Flat Papular Syphiloderm (Synonym: Lenticular papular syphiloderm or syphilid).—The lesions vary in size from that of a pin-head to a bean or larger. In some instances the eruption is made up entirely or predominantly of papules scarcely larger than a pea, and in others almost all the lesions are large—pea- to large coin-size—hence the two so-called varieties—the *small flat papular syphiloderm* and the *large flat papular syphiloderm.* The papules are flattened, often but slightly elevated, rounded or ovalish in contour, dull or brownish red in color, and to the touch often disclose considerable infiltration or depth, at least as compared to elevation above the surface. The lesions are generally distributed, with

but little tendency to closely crowded aggregations, except in some cases of the small papular syphiloderm, in which the region of the nose is a favorite site for some bunching, here partaking sometimes of the nature of tubercles, being papulotubercular in character. Ordinarily in the flat papular syphiloderm there is no disposition to coalescence, the lesions remaining discrete. The eruption is rarely so abundant as in the miliary papular syphiloderm, and, as a rule, there is less tendency in this type to admixture of other forms, although sometimes some macules or maculopapules and a few scattered

FIG. 157.—Small flat papular syphiloderm, of general distribution and extensive development.

pustules can be found, and occasionally some miliary papules. The eruption is found on all parts—scalp, face, trunk, and limbs; the flexor aspects of the last usually show a preponderance over the extensor surfaces. The corners of the mouth, the nasolabial folds, the forehead near the hair-border, the palms, and the genitocrural and anal regions are favorite situations for lesions. The irregularly arranged line of papules on the forehead, at the hairy border, is commonly present in this and sometimes in other forms of syphilitic eruption, and has been termed *corona veneris*.

PLATE XXIV.

Papular and papulosquamous syphiloderm.

This syphiloderm is a common one, and may be in some cases the first recognized cutaneous eruption of syphilis, occurring usually several or more months after the appearance of the initial lesion. In other instances it follows after the macular syphiloderm—probably much more frequently so than clinical experience would indicate, the macular eruption often being slight and readily overlooked. The eruption comes out, as a rule, somewhat rapidly, although in some instances its full development is not reached for several weeks or more. Occasionally it is somewhat scanty, the lesions being seen chiefly about the favorite regions. In other cases they are merely a relatively insignificant, associated part of a macular syphilid. At first the papules are perfectly smooth, sometimes the surface slightly glossy, but later it is not uncommon for them to become covered with a thin film of exfoliating epidermis.

FIG. 158.—Annular syphiloderm.

While they are generally all rounded or oval in shape and persist as such, with no tendency to special or peculiar configuration, exceptionally, however, annular or distinct ring-like patches (**annular syphiloderm, circinate syphiloderm**) are observed, especially about the region of the mouth, forehead, and neck, in association with the eruption of ordinary rounded or oval patches on other parts. This lesion consists of a distinctly elevated, solid ridge or band peripherally, and a more or less flattened central portion. It seems to have its origin from an ordinary, usually scaleless or slightly scaly, large papule, the central portion of which has been incompletely formed or has become sunken and flattened. It is also seen occasionally in association with the macular eruption, in which the band-like ring is but slightly elevated. It is a somewhat unusual manifestation, and is seen most frequently in the negro. In very rare instances the eruption, especially about the face and scalp, may present as closely arranged segments, sometimes of such elaborate arrangement or design as to suggest a resemblance to scroll work.

In most cases after several weeks or a few months they begin to

decline, passing away by absorption, leaving slight pigmentation. which eventually disappears. Not infrequently there is tendency from time to time to less extensive outbreaks, and the eruption may thus persist for some months. As a rule, it responds rapidly to treatment, although palmar and also plantar lesions are often obstinate, and on these regions persistency and recurrence are frequently noted—palmar syphiloderm, plantar syphiloderm. In some situations, moreover, as about moist, contiguous surfaces, papules are apt to undergo certain changes, resulting in the formation of the moist papule. These several forms will be especially referred to later.

In some cases of the flat papular syphiloderm there is a distinct tendency, at times early in the eruption, at others later, toward scale-formation, constituting the type known as the **papulosquamous syphiloderm** or **syphilid** (also termed syphilis cutanea squamosa, squamous syphiloderm, or syphilid ; and, from its resemblance to psoriasis, the misleading and erroneous designation of syphilitic psoriasis, psoriasis syphilitica, has sometimes been used). This tendency of the large papular eruption to become scaly is, when exhibited, more or less common to all the papules, although in some instances it is observed only here and there. The papules usually become slightly less elevated, and are covered with a dry, grayish or dirty-gray, somewhat adherent scale. The scaling on some lesions is simply film-like and somewhat wrinkled, in others more abundant; as a rule, as compared to that of psoriasis, it is less imbricated, less shining or glistening, and relatively slight in amount. If removed, the solid, flat, dusky-red colored papule is disclosed. The eruption may be, as in the ordinary flat papular eruption, general, as usually the case in the earlier months of the disease, or it may appear as a relapse or a later manifestation, and be limited in extent. As a late limited eruption it is most frequently seen on the palms and soles, known commonly as the palmar and plantar syphiloderm. The distribution in the generalized cases is the same as that of the more usual papular syphiloderm, and is less abundant on the extensor than flexor surfaces of the limbs, and there is, likewise, but little tendency to coalescence. It is commonly more or less persistent for several months or longer, although it usually responds fairly promptly to treatment. There are no subjective symptoms, although in this papular syphiloderm, occurring in the negro, as in other forms, itching is frequently complained of.

In the **diagnosis** of the flat papular syphiloderm in the ordinary or relatively scaleless forms there is rarely any difficulty. The more or less generally distributed, variously sized, brownish-red or copper-colored, flattened papules, showing infiltration, are characteristic; moist papules are also usually to be found about the anus and genitalia. As it is an eruption of the active or secondary period of syphilis, other corroborative symptoms will be found. The differentiation between the papulosquamous syphiloderm and psoriasis is considered under the latter disease.

Palmar and Plantar Syphiloderm. — The palms (**palmar syphiloderm**) and soles (**plantar syphiloderm**), especially the former,

are not uncommon seats of the dry syphilodermata—macular, maculopapular, papular, papulotubercular, and tubercular. These parts usually share in the more or less generalized eruptions of the active or secondary stage of syphilis, but they are not infrequently alone the sites of the relapsing secondary eruption, and often show the papulosquamous form at later periods of the disease. It is usually the latter which furnishes the cases of the so-called palmar and plantar syphiloderm. The thickness of the epiderm on these parts gives rise to considerable modification; the lesions are but slightly elevated above the surrounding level, are often rather ill defined

FIG. 159.—Flat maculopapular and papular syphiloderm, with scaling tendency; generalized, the lesions on other parts being maculopapular, papular, and papulosquamous.

peripherally, and when first appearing are much more suggestive of macules than papules. There is some elevation, however, and also distinct infiltration. They are rounded or somewhat irregularly shaped, and in their early stage brownish yellow or brownish red in color; later, owing to the collection of slight scaliness or from being covered with dry, shriveled, broken epidermis, they are dirty gray or grayish white, but when deprived of this covering, the underlying surface or lesion has the usual brownish-red or ham color. Not infrequently there is a slight central grayish or brownish-gray, callus-like thickening, surrounded by a partly visible band of brownish-red underlying papular infiltration, the color being disclosed by the partial or more or less complete removal of the thin scale; beyond this an encircling rim of partially detached epidermis, with its loose, elevated, usually ragged edge directed inwardly. There is often a disposition toward

coalescence of contiguous lesions, and this results in the formation of irregular, segmental, crescentic, and serpiginous patches or tracts. This tendency, particularly the serpiginous and circinate, is observed with the late papulotubercular manifestation, and such patches often creep, with a slightly elevated spreading border, on to the fingers or up the wrist, and not infrequently toward and sometimes over to the dorsal surfaces of the hand and fingers. The general appearances of the papulotubercular and tubercular forms differ but little from that of the ordinary papulosquamous just described, the sole difference being that the lesions are usually somewhat deeper and showing, as a rule, more infiltration, and occasionally the tubercular exhibiting a slight disposition here and there, at the spreading edge,

FIG. 160.—A papulo-squamous syphiloderm, of the palm only; late eruption.

to superficial ulceration. The difference is so slight that, after the eruption is once established, it is scarcely, if at all, recognizable; the spreading elevated infiltrated edge with ulcerative tendency always, of course, indicates the papulotubercular or tubercular syphilid.

In some cases there is a tendency to fissuring and the fissures may be superficial or deep. The scaliness is, as a rule, scanty, more of the nature of fragmentary, ragged, partially detached epidermis, and is reproduced slowly. Occasionally, however, it may be more abundant, and sometimes collects to slight thickness; it is noted to be quite hard and horny. Now and then these hard, horny collections are small and rather sharply circumscribed, extend somewhat deeply, and which can, with some force, be dug out; sometimes they show sieve-like perforations. The French writers called attention to this

condition, which they described under the name of **syphilide cornee.** Exceptionally palmar and plantar lesions remain more or less per-

FIG. 161.—A palmar spreading papulo- and tuberculosquamous syphiloderm of the late period, showing the well-defined border, leaving pigmentation and slight atrophy; no eruption elsewhere.

FIG. 162.—A palmar papulosquamous syphiloderm of the late period; no eruption elsewhere.

sistently as maculopapules or papules, showing some epidermic thickening, with but little tendency to scale-formation.

The eruption is sometimes observed on both palms and soles more or less symmetrically; it may be scanty or abundant. More

FIG. 163.—A palmar tuberculosquamous syphiloderm of the late period, showing segmental configuration; no eruption elsewhere.

commonly it is limited to the palms, and not infrequently to one hand. It may also be confined to one or both soles. It is usually

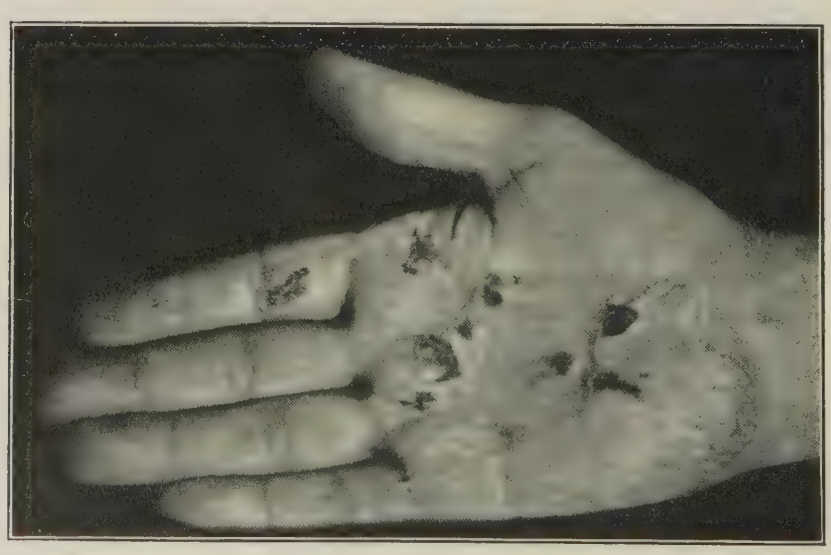

FIG. 164.—A palmar papulotubercular spreading syphiloderm of the late period, with ulcerative tendency, and showing the sharply defined border; no eruption elsewhere.

slow in its advent, spreads gradually, but, as a rule, does not become extensive, sometimes remaining more or less stationary for an in-

PLATE XXV.

Papulotubercular squamous syphiloderm ; undergoing involution (courtesy of Dr. M. B. Hartzell).

definite time. The central portion of the palm, the ball of the thumb, and the volar surfaces of the fingers are favorite situations on the hand. It is not itchy, but if fissuring is present, is, for this reason, often painful; the process is sluggish, more of the nature of an infiltration than inflammation, although it commonly, especially in spreading areas, presents on the parts traversed a reddish, sluggishly or subacutely inflammatory aspect, sometimes with an appearance of thinning, and commonly scantily covered with adherent and detached fragments of epithelial scales.

The palmar and plantar syphiloderm occurring late in the disease is a persistent obstinate manifestation, and often extremely rebellious to treatment. As a part of a generalized eruption of the early or active stage it disappears usually along with the eruption on other regions, although it may remain much longer on these parts, finally yielding to remedies. As a recurrence of the early generalized type, and limited to these regions, it is somewhat obstinate, but much less so than when appearing several years or more after the contraction of the disease. The papulotubercular or tubercular form, more especially that with ulcerative tendency, is generally much more readily cured.

The **diagnosis** of the palmar syphiloderm is often a matter of great difficulty. It bears resemblance to eczema, eczema seborrhoicum, and possibly to psoriasis. As a part of an early generalized syphiloderm a conclusion is naturally easily reached, but special reference is here made to the eruption as found limited to this region. Psoriasis can, I believe, be readily excluded by the fact that it is never limited to these parts alone, but if found here, lesions will surely be found about the elbows, knees, scalp, and probably elsewhere. It is true, a few instances of psoriasis confined to the palms have been reported, but such have been so extremely rare, and inasmuch as the clinical appearances of psoriasis of these parts, when seen exceptionally in connection with a generalized psoriasis, are so much like some cases of eczema, especially eczema seborrhoicum, and even like palmar syphilis, that the alleged cases of limitation to these regions could much more reasonably be placed to the credit of either of the latter two maladies.

In fact, in the diagnosis only eczema and eczema seborrhoicum need be considered. Eczema can usually be differentiated by the more inflammatory aspect, the common and often predominant involvement of the fingers and finger-ends, and generally its appearance also on the backs of the hands, as well as the presence of variable heat and itching; often, too, there is present in one or two places the eczematous discharge, or a history of such; there is no tendency to crescentic, serpiginous, or circinate forms, as often observed in syphilis; and not infrequently it occurs in those who have to do with irritating substances, as dyers, plasterers, pasters, polishers, etc. Sometimes, too, in such eczema cases the eruption in its characteristic aspects is seen on forearms, and possibly elsewhere. It is with the differentiation from eczema seborrhoicum, which, however, is luckily somewhat rare in this situation, that the most difficulty is likely to be

encountered, as itching and burning are often absent in this malady, and it may show a slight tendency to crescentic configuration. A careful consideration of both diseases is occasionally necessary, sometimes supplemented by observation and treatment, before a positive conclusion can be reached. Eczema seborrhoicum is, however, much less likely to form segmental, crescentic, and serpiginous shapes than syphilis, and with such as a predominant feature the latter diagnosis would be the more probable unless there were good reasons for the contrary. Eczema seborrhoicum, fortunately, is commonly associated with the same disease on one or more of its more usual situations, as the scalp, eyebrows, nasolabial folds, bearded region, interscapular and sternal regions; when on the hands, it is usually long after it has already existed elsewhere. Moreover, in eczema seborrhoicum there is not the usually distinctly recognizable infiltration of the syphilid. In many instances in these cases of palmar and plantar syphilid often a history of syphilis is obtainable, or evidences, such as scars, of former syphilitic manifestation can be found. Occurring during the active or secondary period of the disease, of course, other associated symptoms are commonly present, but when occurring a few years or longer after the contraction of the malady, such positive corroboration is generally wanting.

Moist Papule (Synonyms: Mucous patch; Mucous papule; *Fr.*, Plaques muqueuses; *Ger.*, Schleimhautpapeln).—The usual sites on the general integumental surface for moist papules are on contiguous or opposing surfaces, where there is a good deal of natural heat and moisture, and possibly friction. They are usually met with during the active or secondary stage of syphilis, as a part of a general eruption or independently. The most common situation is around the anus

FIG. 165.—Moist papules (after Miller).

and about the genitalia, especially in women; the perineum, genito-crural surfaces, the corners of the mouth, the nasolabial folds, the axillæ, and umbilicus are also not unusual situations. They are also met with between the fingers and toes, just at the web, and beneath

the mammary glands in women. They commonly begin as ordinary papules, which flatten down somewhat, become macerated, generally slightly soft or even spongy, and are grayish or brownish gray in appearance. Their surface is covered with a mucoid secretion, which, when drying slightly, may resemble somewhat a thin, diphtheroid membrane. Ordinarily, however, the surface is kept moist and macerated. At first they are commonly fairly well defined, but later, often from flattening down, especially peripherally, become much less so. On the other hand, instead of flattening down they may become hypertrophied, distinctly elevated, the surface somewhat irregular or uneven, and constitute the lesion or form known as the **broad or flat condyloma.** Contiguous plaques may coalesce and cover considerable surface, encircling the anus or also, in the female, involving and surrounding the vulva. The irregular and uneven surface may sometimes become clearly warty or papillomatous, the papular base sharing in the hypertrophy, and the vegetations prominent and closely packed, giving rise to the manifestation known as the hypertrophic papillomatous or vegetating papule, sometimes designated the **vegetating syphiloderm,** syphilis cutanea vegetans, syphiloderma framboesioides. This latter development is also sometimes observed in the various ulcerative syphilodermata. There is usually considerable mucoid or mucopurulent secretion, which, together with the macerated epithelium, soon, unless extreme cleanliness is practised, gives rise to an exceedingly foul, offensive odor. If neglected, the irritating discharge may produce still further maceration, and ulceration, more especially between the papillary growths, results. Such cauliflower-like formations are also occasionally met with elsewhere on the surface, where the papules, or sometimes other syphilitic lesions, have undergone irritation, or from neglect—as, for instance, the scalp.

The moist papule is one of the common symptoms of the active stage of syphilis, especially about the anus in males, and the anus and vulva in females, and are often present when the syphilitic eruptive manifestations are scant on other parts. For this reason it is of value in diagnosis. As the heat, moisture, and friction of the parts necessarily continue, some tenderness or soreness often results, and patients usually believe they have an attack of hemorrhoids. As a rule, moist papules, if thorough cleanliness is practised, show a tendency to disappear, and are generally rapidly responsive to treatment. Inasmuch as their characters are well defined, the **diagnosis** is not attended with difficulty. They should not be confused with verruca acuminata (*q. v.*).

The lesion which occurs on the mucous membrane, especially of the lips and mouth, usually known as the **mucous patch,** is a somewhat similar formation, and may often be looked upon as a flattened, abraded papule on a mucous surface. They are also seen on the labia minora surfaces of the vulva and on the mucous membrane of the anus. About the mouth, their usual situation, they are most commonly found just within the vermilion border, often extending on to the latter, and especially at the corners of the mouth and the lower lip. The inner surface of the cheeks is

a favorite location, especially opposite or near the last molar. The tongue, uvula, tonsils, velum palati and its pillars, and the gums are also frequently its site. There may be one, several, or more—generally two or three. They are usually observed during the active or second stage of the disease, especially the early period of it, although they are also seen later. They are sometimes called "opaline patches," owing to the appearance presented; they have a grayish-white color, such as is produced by penciling with silver nitrate, often with a pinkish-red periphery. This term opaline is probably more properly applicable to the very slight opalescent, insignificant patches which occur occasionally on the tongue, and sometimes so numerously as to give it a map-like appearance. As a rule, mucous patches are but slightly elevated, always flattened, and not infrequently slightly depressed; are rounded, ovalish, or irregular in outline, and of various sizes. Sometimes, instead of grayish or grayish-white color, they are a pale rosy or rosy-white; and not infrequently, when closely examined, show a thin, film-like membranous coating, which may be an intimate and closely agglutinated part of the patch or somewhat loosened. If detached, the underlying surface is noted to be reddish, appearing as a superficial abrasion or erosion, often distinctly raw-looking. It is not uncommon in some cases to see several plaques, their appearances varying as just described. They are sometimes quite painful, especially when taking hot drinks and hot foods and acid fruits. The patches, more particularly the abraded plaques, have a slight or moderate mucoid discharge, commonly collecting as a thin coating, and which is extremely contagious.

In some instances the abraded or eroded surface of a plaque becomes more deeply invaded, and a rounded or irregular superficial ulceration results, with a mucoid or mucopurulent discharge; occasionally the ulcerative action extends deeply and causes considerable destruction. Later in the disease the grayish-white plaques sometimes undergo thickening, become more or less opaque, and doubtless constitute some cases of leukoplakia buccalis (*q. v.*).

In the early stage of active syphilis it is not uncommon to find a patchy or confluent redness of the posterior fauces, which may be associated with well-defined mucous patches. Very often, however, it is simply a catarrhal redness, sometimes extending into the larynx; there is frequently a feeling of tenderness and soreness, which is more marked when mucous patches are present.

As a rule, mucous patches of the mouth are more or less persistent, unless treated, but will often disappear rapidly under constitutional measures, and usually promptly under local applications. Occasionally, especially the opaline, superficial patches of the tongue seem to lead to a tendency to fissuring, with variable hyperplasia and eventually to well-marked leukoplakia. As the mucous patch in the mouth is commonly one of a group of symptoms of syphilis the *diagnosis* is, as a rule, readily made. The acuteness, generally sensitive, and evanescent character of the "aphthous sores" frequently seen in the mouth, and usually associated with attacks of indigestion, will serve to distinguish them from the syphilitic lesions.

Vesicular Syphiloderm (Synonyms: Syphiloderma vesiculosum; Syphilis cutanea vesiculosa; Varicelliform syphiloderm or syphilid).—This is a rare form of the syphilodermata occurring in the secondary period of the malady. Its existence has frequently been called in question, but the observations of Bassereau,[1] Hardy,[2] and other French observers, as well as Duhring,[3] White and Martin,[4] Hutchinson,[5] and others, attest its occurrence, although admittedly extremely exceptional. I have never met with a case, although occasionally with instances of the pustular syphiloderm in which the earliest stage of formation of some lesions was noted to be vesicular, or more commonly vesicopustular. With so rare a manifestation the possibility of its occasionally being due to drug idiosyncrasy is not to be lost sight of; potassium iodid has been known to be exceptionally productive of vesicles, and this drug is sometimes prescribed in the early stages of syphilis.

The vesicular syphilid may occur in one of several forms: the lesions may be minute, eczematoid, disseminated, and grouped; larger, irregularly scattered, somewhat similar to varicella (varicelliform syphilid), and in other cases occurring in ill-defined herpetiform groups, constituting the so-called herpetiform syphilid. Both Hutchinson[6] and Crocker[7] have also observed a vesicular eruption similar to herpes zoster, except that the lesions are not limited to one side or region, but somewhat symmetrically distributed, and of longer duration than true shingles. In the vesicular syphiloderm an association of papules is commonly noted, and the vesicles, which may be rounded or umbilicated, constituting one form of the varioliform syphilid, soon become seropurulent or purulent. The vesicle generally has a dusky-red, solid, papular base, the vesicular, vesicopustular, or pustular apex usually drying, leaving a more or less characteristic small papule, which, disappearing, gives place to a dark stain of some duration, as observed in other syphilodermata.

Other evidences of the active stage of syphilis are, as in other secondary eruptions, generally present, and can be utilized in the *diagnosis*. The usually solid papular base, its slow evolution, and its duration and sluggish characters are also points which distinguish it from vesicular eczema and varicella.

The **pustular syphilodermata** occur in several distinct types, and are therefore best described separately. They are much less frequent than the papular forms, and are observed more commonly in individuals of poor general nutrition and in a depraved condition of general health. They are relatively much more frequent, therefore, in dispensary and hospital practice than among private cases, and are, moreover, often somewhat persistent, and occasionally, for

[1] Bassereau, *Traité des affections de la peau symptomatiques de la syphilis*, Paris, 1852.
[2] Hardy, *Leçons sur la scrofule et les scrofulides et sur la syphilis et les syphilides*, Paris, 1864.
[3] Duhring, *Diseases of the Skin*, third edit., p. 519.
[4] White and Martin, *Genito-Urinary and Venereal Diseases*, fourth edit., 1900.
[5] Hutchinson, *Clinical Manual on Syphilis*.
[6] Hutchinson, quoted by Crocker, *Diseases of the Skin*, second edit.
[7] Crocker, *ibid.*

a time, somewhat rebellious to treatment. The pustular eruption usually indicates a greater probability of a more severe type of syphilis than do the macular and papular forms. It ordinarily occurs within the first six or eight months, either independently of earlier eruptions of other type or subsequently; but it may be also observed usually as a relapse, or more limited manifestation later in the disease. The several varieties encountered are: the miliary or small acuminated pustular syphiloderm, the large acuminated pustular syphiloderm, the small flat pustular syphiloderm, and the large flat pustular syphiloderm.

Miliary or Small Acuminated Pustular Syphiloderm.—This is not an uncommon form of the pustular syphilodermata, the lesions being minute, pin-head or slightly larger in size, and generally connected with the hair-follicles. In many respects this eruption is similar to the miliary papular syphiloderm, and many of the lesions in their early stage are purely papular, becoming later capped with a small pustule. While the eruption, as a whole, is clearly pustular, many papules will usually be found showing but slight, and sometimes not any, tendency to pustulation. The lesions are, as a rule, numerous, and although generally distributed, often show a tendency to groups and aggregations. This disposition is especially noted in relapses, which, though slight, are not uncommon in this form. Almost all the pustules have, at first at least, a somewhat solid, dusky or brownish-red papular base, which continues with many, but in others becomes later transformed into a part of the pustule. A slight depression of the central part of the summit is observed in some lesions. The eruption makes its appearance either somewhat rapidly, with or without some febrile action, or appears gradually in irregular crops and generally without systemic disturbance. There are no subjective symptoms; occasionally slight soreness or tenderness, and, in the negro, as with the other syphilodermata, often variable itching. It is an eruption, usually profuse, of the secondary stage of syphilis, and commonly appears during the first six or eight months—on an average about the third month; it may, however, occur somewhat later, but ordinarily as a relapse and as a more or less limited eruption. Macules are occasionally seen in association with it, more especially when it makes its appearance early, but miliary papules, as already stated, and sparsely scattered flat papules or flat pustules are much more usual. This eruption is of a sluggish course, often somewhat persistent, and less readily responsive to treatment than the papular syphilodermata. The general health is commonly noted to be bad, and a more or less profound anemia is occasionally associated. The pustules dry to crusts, which fall off, and often leaving temporarily a slight fringe-like exfoliation or scale around the base, constituting a grayish ring or collar. Scarring, consisting of minute points or pits, may be left in some places, although it may also disappear without a trace, except stains which finally fade.

The miliary pustular syphiloderm is so unique and characteristic that a mistake in *diagnosis* can scarcely be made, although corrobo-

ration is usually readily found in the presence of some of the concomitant symptoms.

Large Acuminated Pustular Syphiloderm (Synonyms: Acneiform syphiloderm (sometimes improperly termed acne syphilitica); Varioliform syphiloderm).—This occurs as a more or less generalized eruption, usually within the first six or eight months of the disease, and consists of small or large pea-sized, disseminated or irregularly grouped, acuminated or rounded pustules, bearing some resemblance to the lesions of both acne and variola. They often show a connection with the follicles. As a rule, they begin as pustules, some as papules, although all at first are generally seated upon a slight or insignificant papular base; this in the earliest stage is often pinkish red in color, with some colored areola, later becoming dusky or coppery red. Occasionally some lesions in their first

FIG. 166.—A papulopustular syphiloderm with ulcerative tendency; on face and arms, of limited character; following as a relapse after a generalized pustular eruption.

formation are vesicopapular, vesicular, or vesicopustular, rapidly, however, becoming clearly pustular. It is not uncommon here and there to find a pustule with central depression or umbilication, and occasionally this tendency is so generally and strikingly shown that there is a somewhat close resemblance to variola, and to these cases especially the descriptive term varioliform is quite appropriate.

This pustular syphilid, as with the other syphilodermata, varies as to scantiness or abundance considerably in different cases, but, as a rule, it is more or less profuse, especially when occurring in the first three or four months; later, and also in relapses, it is usually scanty and shows a tendency to the formation of scattered groups or aggregations. The eruption may appear quite rapidly, and sometimes with well-defined precursory and accompanying febrile action and general malaise, or more gradually and with or without systemic disturbance. As a rule, however, in all cases new lesions continue to appear for

one or two weeks or longer, and slight recurrent crops are sometimes observed. It is not uncommon to find sparsely scattered flat pustules and papules. After the first outbreak is well established febrile action, if present, quickly subsides. This pustular syphiloderm is usually accompanied by more or less anemia, and patients are generally pale, weak, and debilitated. Other symptoms or evidences of syphilis are always to be found. The course of the eruption is sluggish, for some weeks, as a rule, showing but little disposition to spontaneous disappearance, during which time many of the older lesions have dried to crusts and new lesions often appear. It is generally, however, more quickly responsive to treatment than the miliary pustular syphilid. The crusts are of various thickness, and when first formed, are usually seated upon superficially ulcerated bases. Becoming finally detached, they leave behind brownish pigmentation, and sometimes atrophic thinning or slight scarring, which may sometimes be depressed or pit-like. In most cases, however, permanent scarring, of any significance at least, does not occur.

Ordinarily the **diagnosis** of the large, acuminated pustular syphiloderm is readily made, but its resemblance, in some instances, to acne, variola, and the iodid eruptions cannot be gainsaid, but especially to variola. Its confusion with acne is, however, possible only with the ignorant or careless, as acne is an eruption practically limited to the face, neck, and shoulders, sometimes also on breast and back; it is made up of blackheads, beginning papules, usually with a blackhead centrally, pustules in all stages, and not infrequently with deeper-seated nodules or abscess-like lesions; moreover, the duration, sluggish character, history, absence of lesions on scalp and other parts, will together furnish sufficient points of difference.

It is the case of pustular syphiloderm of acute development and associated with febrile action and malaise which is most likely to be confounded with variola, but the following considerations are ordinarily sufficient to differentiate: the syphiloderm is generally distributed without any especially greater abundance on any region, although often more numerous on the trunk: variola is almost invariably strikingly more profuse on the face and backs of the hands and on the wrists; the lesions of syphilis are usually pustular from the start, or first papular, but the papules are projecting; the initial start of a variola lesion is a deep-seated, scarcely at all projecting, shot-like papule, which is transformed into a somewhat deep-seated vesicle, with umbilication, and later into a pustule; the syphilitic pustule commonly has a firm, papular base: that of variola is usually all pustular; the covering wall of the former is somewhat thin, easily broken: that of variola is generally firm and tough, and, at first at least, not readily ruptured; the lesions of syphilis are in various stages of development, and new ones continue to appear irregularly for one, two, or more weeks, while those of variola, though possibly of different sizes, are at about the same stage, and, after once out, new lesions rarely appear; the febrile action of the syphilitic eruption is generally slight and abates gradually and disappears: that of variola is, as a rule, relatively severe, and abates rapidly on the outbreak of

PLATE XXVI

Acneiform syphiloderm of general distribution; showing a few intermingled large flat papules and pustules.

the eruption, to appear again as pustulation takes place; the other general symptoms in syphilis are slight, while in variola they are often severe. Far above all these, however, in value to the inexperienced must be placed the presence or absence of other symptoms of syphilis. This latter point can also be used, when necessary, in the differentiation from ordinary acne and from iodid acne. This last is rarely profuse, and, as a rule, not generally distributed, but more commonly on the ordinary acne situations, and there will be a history of iodid administration. Indeed, in all cases of obscure dermatoses the elimination of the possibility of its being due to drug ingestion should receive first attention.

Small Flat Pustular Syphiloderm (Synonyms: Impetigiform syphiloderm or syphilid; Impetigo syphilitica).—This form of the pustular syphiloderm, while not frequent, is not uncommon, and is characterized by an eruption of flat, discrete, sometimes irregularly grouped, pea- to small finger-nail-sized pustules, and occur usually within the first six or eight months of the secondary or active period, sometimes later. There is occasionally, when the lesions are abundant, in one or two regions, as on the scalp and face, especially about the nose and mouth, a tendency toward coalescence. The eruption may be more or less generalized, but probably more frequently present about the face, mouth, scalp, and genitalia in association with macules, maculopapules, or papules on other parts. The pustules form, as a rule, somewhat rapidly, arising as such or from preexisting macules or papules, and soon dry to crusts, which are often quite adherent, and beneath which is found superficial erosion or ulceration. So rapidly in most instances does crusting follow the pustule formation that the pustulocrustaceous character is usually pronounced, and, for this reason, in such cases the term **pustulocrustaceous syphiloderm** or **syphilid** is sometimes heard. The crusts, brownish-yellow or brownish, sometimes with a greenish hue, are somewhat thick, often uneven, and ordinarily granular or friable, although they may be tough; they may not entirely cover the base, in which event the peripheral portion of the base is either superficially ulcerative or slightly infiltrated or papular, with possibly an areola; or the crust may extend beyond the underlying lesion proper. The peripheral basal portion, if visible, and the areola, when present, are dusky red or ham colored. When the eruption is extensive, there are usually an associated depraved state of the health and a more or less profound anemia, but if limited in extent or occurring as a part of a macular or papular syphiloderm, it is generally of benign nature. In the generalized cases some lesions may show somewhat deep ulceration; in the limited forms the surface is merely eroded, or, at the most, superficially ulcerated, although there are exceptions in which the destruction extends more deeply. As a rule, however, it is rarely deep. There is sometimes, especially in relapses, a tendency to circinate or segmental grouping. It is, in the benign cases, generally readily responsive to treatment, although in the extensive disseminated cases often more or less rebellious.

In the **diagnosis** pustular eczema and impetigo are to be excluded.

The confluent crusted patches sometimes observed in scalp, bearded region, and about the mouth are somewhat suggestive of pustular eczema, but in most cases the underlying erosion, often amounting to distinct ulceration, is a differential factor; moreover, characteristic papular or pustular lesions of syphilis are almost always present on other parts of the surface, and these, as well as other corroborative symptoms of the disease, will prevent error. Pustular eczema is likewise quite itchy. About the same differential factors will serve to prevent a mistake with impetigo, the latter usually occurring on face and hands, mild in character, superficial, without ulceration, and of comparatively short duration.

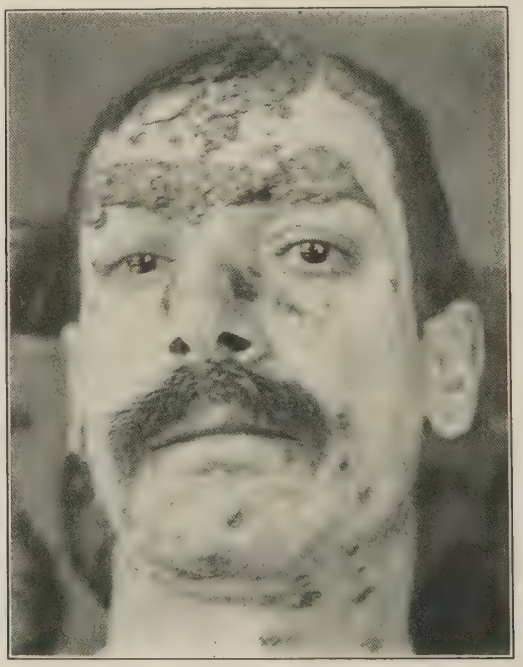

FIG. 167.—Large flat pustular syphiloderm of general distribution; about forehead and scalp, of pustulocrustaceous type and rupial tendency.

Large Flat Pustular Syphiloderm (Synonyms: Ecthymaform syphiloderm or syphilid; Syphilitic ecthyma; Ecthyma syphiliticum).—In many respects the large flat pustular syphiloderm is similar to the small flat variety, except that the lesions are finger-nail-sized and larger. This is especially so with the superficial variety, in which the pustules are flat, drying to yellowish-brown or brownish crusts, which are somewhat adherent, and which in the earlier stages are seated upon an eroded or superficially ulcerated base, sometimes having a slightly infiltrated, dark-red or ham-colored border or areola. If at this stage the crust is removed, there is disclosed an eroded or ulcerated, purulent, secreting surface. Sometimes they dry

so rapidly to crusts as to give rise to the designation of **pustulo-crustaceous syphiloderm** or **syphilid.** The lesions may be numerous or scanty, and associated with papules or smaller pustular lesions.

FIG. 168.—Large flat pustular syphiloderm of general distribution, and of the pustulo-crustaceous, rupial type (courtesy of Dr. W. T. Corlett).

The deeper-seated variety is much less commonly observed than the superficial form. There is always superficial ulceration, sometimes quite distinct, beneath the crust. The crusting is of darker color, sometimes reddish brown, brownish black, with not infrequently a greenish tinge, and much more bulky and usually harder. As in the superficial variety, they may remain flattened, with an uneven surface. Sometimes the ulcerative feature is quite pronounced, and hence the designation **pustulo-ulcerative syphiloderm**

or **syphilid.** Or the crusting may be the most striking feature, and they may become heaped up and stratified; when this latter is of conspicuous character, as it sometimes is, the eruption is commonly known as **rupia.** The crust, greenish or blackish, is raised and bulky, conic, and formed of several layers, with that of small dimensions at the top—similar, in fact, to the stratification observed in an oyster shell. In these cases the pustules, with a distinctly ulcerated, discharging base, are somewhat slow in formation; the surface crust dries, and from the irritation of the hemmed-in secretion below or spontaneously the discharge is probably increased, the basal ulceration spreading peripherally; the already dried layer of crust is thus lifted up, and then the under part again dries, forming naturally a crust of the size of the increased base, and this is, in turn, lifted up, and thus the process continues for some time, the aggregate crust being made up of several or more layers, the uppermost small, and the strata beneath larger and larger as the base is approached. The ulcerations beneath these lesions are usually rounded or irregularly shaped, having a greenish-yellow, puriform secretion. This same form of crusting is sometimes observed, but much less scantily and characteristically, with the rarer bullous lesion, and also occasionally with the tubercular ulcerative and gummatous syphiloderm.

In both the superficial and deep-seated varieties the eruption may be sparse or more or less abundant; rarely, however, is it profuse. The former variety is sometimes seen in association with the papular syphiloderm, and also with the small flat pustular eruption, consisting of scattered, isolated pustules, or being present in one or several irregular groups in one or more regions. The lesions begin as pustules or as maculopapules, papules, or papulotubercles; the last not infrequently with the deep-seated variety. As a rule, in both types the pustules are most abundant on the shoulders, back, and extremities; the rupial formations are usually most characteristically developed on the face and arms. The superficial form is more common in the first six or eight months; the deep-seated type variety is sometimes a later manifestation. The former is generally relatively benign, but not infrequently is associated with grave systemic disturbance, as profound anemia; the deep variety is almost always indicative of a grave type of the disease. Untreated, they are more or less persistent, but, as a rule, respond to specific remedies, although sometimes slowly. Scarring, with associated brownish pigmentation, often exceedingly superficial, at other times deeper, usually marks the site of the lesions, which become gradually less distinct; the pigmentation is extremely slow in disappearing, more especially on the lower extremities, where, indeed, it may be more or less lasting. Other symptoms of syphilis are commonly to be found.

The only disease which is to be considered in the **diagnosis** is ecthyma, but the syphilitic eruptions differ in the lesions being more numerous, in being attended with superficial or deep ulceration, and in being followed by more or less scar-formation; moreover, the history and frequent presence of other syphilitic cutaneous lesions, as

PLATE XXVII.

Pustular syphiloderm of the pustulocrustaceous and rupial type; general, but of greatest abundance and development on the scalp and upper trunk. Initial lesion about six months previously.

well as other corroborative symptoms of the disease, have an important diagnostic value.

Bullous Syphiloderm (Synonyms: Syphiloderma bullosum; Syphilis cutanea bullosa; Pemphigus syphiliticus).—The bullous syphiloderm of acquired syphilis is extremely rare,—so much so that its existence has been denied,—although it is not unusual in the hereditary disease (*q. v.*) in the new-born. Its occurrence in the acquired disease, though rare, cannot, however, be denied. It is a late manifestation, occurring in those in a depraved condition of health, which latter itself may be due to the syphilitic poison, as this syphiloderm is to be considered as indicative of a grave type. It is commonly associated with other eruptive lesions and symptoms of syphilis. It appears in the form of discrete, disseminated, rarely abundant, rounded or ovalish, pea- to walnut-sized, partially or fully distended blebs, having usually cloudy or puriform contents, sometimes with a slight admixture of blood. In some instances they are distinctly pustular from the beginning. The lesions have a dark or dusky red areola, and commonly with variable infiltration. They, either with or without rupturing, collapse and dry to thick crusts of a yellowish-brown or dark, greenish-black color, with an irregular and uneven surface, flattened or somewhat rounded and conic. The underlying surface is eroded or ulcerated, generally the latter, which may be superficial or deep, and secrete a greenish-yellow fluid. There is sometimes the same tendency displayed in this manifestation to the formation of stratified or oyster-shell-like conic crusts (**rupia**), as described in the large flat pustular syphiloderm (*q. v.*). Its course is somewhat uncertain and variable, but it is favorably influenced, although usually slowly, by specific and properly associated treatment.

The **diagnosis** in bullous syphiloderm, owing to the characters of the lesions, the crusts, underlying base, and usual peripheral infiltration, as well as to the presence of additional symptoms of syphilis, either cutaneous or other, is not difficult, and such factors are, as a rule, sufficient to distinguish it from ordinary pemphigus and other pemphigoid eruptions.

Tubercular Syphiloderm (Synonyms: Syphiloderma tuberculosum; Nodular syphiloderm or syphilid; Syphilis cutanea tuberculosa).—The tubercular syphiloderm may exceptionally occur within the first year as a more or less generalized eruption, of characteristic brownish-red or ham-colored, small to large pea-sized tubercles, but even in such generalized cases the lesions are usually, for the most part, more of the nature of papulotubercles (papulotubercular syphiloderm) than tubercles. Less rare is it, although not at all common, to find papulotubercular and tubercular lesions on the face, especially about the nose, forehead, and chin, and somewhat crowded together, in association with the typical papular eruption on other parts. As a rule, however, it is a late secondary or tertiary manifestation, appearing several or more, sometimes many, years after the

contraction of the disease; limited in extent and appearing on one or several regions, and exhibiting a decided tendency to occur in groups of segmental, circinate, and serpiginous configuration.

The tubercles are of the same characters in the late, limited manifestation as in the rare generalized cases. They present commonly as several or more groups of somewhat firm, circumscribed, slightly or moderately elevated lesions extending into the corium and sometimes

FIG. 169.—Tubercular syphiloderm, with slight ulcerative tendency; showing the characteristic spreading border; of several years' duration.

more deeply. They have a smooth surface, with often a glistening aspect, or covered with thin epidermic exfoliating scales; are rounded or acuminated in shape, occasionally somewhat flattened and of a brownish-red or coppery color, and usually the size of small or moderately sized peas. They are, as a rule, closely set together, forming a segmental or ring-like grouping, and showing often a tendency to actual and intimate coalescence. Several contiguous groups may coalesce and form a serpiginous tract of an irregular, winding, snake-like character; or the older lesions of a segmental or circinate group disappear, new ones appearing on the outer edge or just beyond the border, and in this manner the segment or circle enlarges, in a slowly creeping manner, the lesions within this spreading border undergoing involution, and leaving a pigmented, often atrophic, area behind, constituting the so-called **serpiginous tubercular syphiloderm.** Where the creeping and widely extending tendency is not exhibited, the terms **circinate tubercular syphiloderm** and **segmental tubercular syphiloderm** are sometimes employed, according to circumstances. The individual lesions usually develop slowly, are sluggish in their course, remaining at times for weeks or months without material change. As a rule, however, they terminate sooner or later in absorption and exfoliation, leaving, as already described, a more or less

permanent pigmentation, with or without slight atrophy or cicatricial thinning, the disease continuing by the formation of new lesions appearing at the edge or closely adjacent. This form of the eruption, in which ulcerative tendency is not displayed, is not at all uncommon, and is known as the **non-ulcerating tubercular syphiloderm**, with often the additional qualifying terms, circinate, segmental, or serpiginous, according to the configuration. In a few of these cases the scaliness may be more pronounced than ordinarily observed, and have a psoriatic appearance, and such examples are sometimes termed **tuberculosquamous syphiloderm** or **squamous syphiloderm.** In other instances, especially when about the nose, the lesions may partake of the nature of both papules and tubercles,—papulotubercles (**papulotubercular syphiloderm**),—and some of which sometimes break down centrally and form pustules (**tuberculopustular syphiloderm**) which may leave pit-like scars.

FIG. 170.—Tubercular syphiloderm with ulcerative tendency, and showing the well-defined spreading border; of one to two years' duration.

In the majority of cases, however, of the tubercular syphiloderm, instead of the lesions undergoing absorption and exfoliation, ulceration takes place, and this may be displayed from the beginning or occur after a well-formed group or patch has lasted for some weeks, constituting the **ulcerating tubercular syphiloderm.** The patches or groups have the same tendency to the special configurations of segmental, circinate, and serpiginous, already mentioned, and hence one of the descriptive terms, depending upon the characters displayed, is sometimes added, giving rise to the names "ulcerating serpiginous tubercular syphiloderm," etc. In these cases there are, therefore, found tubercles, ulcerations, and usually crusting. The ulceration may be superficial or deep in character, and involve several or all the lesions forming the group. This may consist, therefore, of small,

discrete, punched-out ulcers, or one or more continuous ulcers of segmental, crescentic, or serpiginous shape. Ordinarily they are quite shallow, although in some cases the ulceration extends to considerable depth. They are either covered with a gummy, grayish-yellow, purulent secretion, or are crusted, the secretion drying to crusts. Not infrequently the patch spreading peripherally shows an



FIG. 171.—Tubercular syphiloderm, with but little destructive tendency, showing the segmental configuration; of several years' duration.

extending, elevated, infiltrated border, made up of closely contiguous or coalescent tubercles, which have lost their individuality and form a line of infiltration, which, toward their inner border, have already undergone ulceration, usually covered with crusts; and so the patch gradually invades the surrounding healthy surface, while, as a rule, healing with consequent cicatricial tissue, and commonly more or less yellowish-brown or brownish pigmentation, are noted on the part already traversed. In some instances the tubercles form into closely packed areas of infiltration, the patch presenting both tubercular and gummatous characters, often rapidly ulcerating in places or more or less uniformly; or the lesions, while close but discrete, may also occasionally be of a mixed tuberculogummatous nature; such cases give rise to the term **tuberculogummatous syphiloderm.**

Sometimes there is but a sluggish tendency toward healing, and the ulcerations show a disposition to papiliary hypertrophy or vegetations, with an offensive, yellowish or greenish-yellow, puriform discharge, probably occurring most frequently upon the scalp, con-

stituting, again, as referred to in some cases of moist papules, the modification or variety often designated the **papillomatous** or **vegetating syphiloderm** or **syphilid** (also called syphilis cutanea papillomatosa, syphilis cutanea vegetans). Exceptionally the ulcerated segmental groups crust over, gradually extend, and become crusted over with several or more stratified layers of crust, the smallest at the top, oyster-shell like, as observed in the rupial formation of the

FIG. 172.—Tubercular syphiloderm with ulcerative tendency, of a year's duration, showing the clearing central portion and spreading border.

large flat pustular syphiloderm. The favorite region is the face, especially the region of the nose and mouth, but it is quite common also on the upper part of the trunk, and the arms and legs; in fact, no region is exempt. It may be, and commonly is, limited to one region, but not infrequently areas of small or large size are seen on two or more parts. There are generally no subjective symptoms, although occasionally the ulcerations are tender and painful. Its course is usually slow, and while there is, as a rule, a tendency displayed toward involution or ulceration and healing in the older lesions, new tubercles continue to appear, so that complete spontaneous cure, while it may occasionally result, is not to be expected, and the eruption continues indefinitely. It is, however, almost invariably rapidly responsive to specific constitutional treatment.

The **diagnosis** of the tubercular syphiloderm is, as a rule, not difficult, although it often resembles closely lupus vulgaris. The differential points are considered under this latter disease. The diagnostic features of this syphiloderm are the tendency to form segments, crescents, or circles, its method of spread, the color, ulceration, pigmentation, and atrophy or scarring of the older part; these, together

with the history, and sometimes marks or scars of former syphilitic eruptions, are usually sufficient to warrant a conclusion.

Confusion with epithelioma, acne rosacea, leprosy, sycosis, psori-

FIG. 173.—Tubercular syphiloderm involving arm and forearm, of several years' duration, showing the serpiginous spread and the small soft scars of the earlier eruption; disease contracted some years previously.

asis, and ringworm has occurred, but such errors are almost invariably the result of hasty examination or inexperience, as the several diagnostic features of the tubercular syphiloderm, when considered together, furnish sufficient grounds of difference, without mentioning the differentiating characters of the other diseases named. The lesion of epithelioma is usually single, has an infiltrated, often roll-like border, and often the peculiar, semitranslucent, pearly-looking tubercles or nodules adjacent or surrounding; it is generally much slower in its progress, the discharge is not commonly profuse or offensively purulent, and is often mixed with a little blood; it is more common after fifty, and somewhat infrequent before this age—just the reverse of the tubercular syphiloderm. In acne rosacea there is no segmental or circinate configuration, no distinct ulcerations, the

tubercles or nodules are, as a rule, vividly red, and dilated capillaries are usually present.

When the tubercles or papulotubercles of syphilis are numerous and crowded together on the face, a somewhat leonine aspect is given to the countenance, and a suggestion of tubercular leprosy;

FIG. 174.—Tubercular syphiloderm with ulcerative tendency, of several years' duration, showing segmental configuration and scars of earlier areas.

but in cases of the latter disease there are found symptoms such as a history of febrile attacks, anesthetic patches, neuralgic and other nervous disorders, and brown, pigmented areas. Sycosis vulgaris is follicular in origin, with no tendency to ring-like or segmental configuration, and is not destructive; that form known as ulerythema sycosiforme may, however, resemble syphilis somewhat, but its follicular orgin, slow progress, and usually rather tough cicatricial formation, resulting not from distinct ulceration, but atrophic changes, will serve to distinguish it. In ringworm sycosis, if of the superficial type, there is the ring-like border, but this is not distinctly infiltrated, and is lacking the ulceration and pea-sized brownish tubercles found in syphilis. In the deep-seated ringworm sycosis the subcutaneous nodulations or lumpiness are characteristic, especially when taken together with the history of a follicular or ringworm patch origin. The circinate tubercular syphiloderm has been mistaken

for ringworm of the non-hairy surface, but the absence of defined tubercles or infiltrated border, pigmentation and atrophy or ulceration and scarring in the latter should serve to prevent mistake. The history is, moreover, wholly different. In cases seemingly like ringworm, microscopic examination for the fungus would decide if doubt still remained. The tuberculosquamous type of this syphilid does at times roughly suggest psoriasis, but could scarcely be mistaken for it (see under psoriasis for differential points).

Gummatous Syphiloderm (Synonyms: Syphiloderma gummatosum; Gumma; Syphiloma; Syphilis cutanea gummatosa).—The gummatous manifestation is usually a late tertiary formation. It does sometimes occur in the secondary stage and exceptionally at an early period (syphilis præcox), and is then to be looked upon as probably indicating a malignant grade of syphilis, and in such instances may be present in greater number than late in the disease. Generally, however, it shows itself as one or several painless or slightly painful, rounded or flattened, more or less circumscribed tumors, moderately projecting, at first firm, and having their seat in the subcutaneous tissue. In its earliest beginning it can be felt as a pea-sized deposit or infiltration, and may grow slowly or rapidly, taking one or two weeks to several months before reaching full development. As it increases in size the overlying skin is slightly stretched, and changes from the normal color to a dull pinkish or pinkish-red tint, which later, with increased growth, assumes a dusky or dark-red color. When fully developed, it may be the size of a walnut or much larger, and be considerably elevated. While firm at first, it soon, as it grows in size, becomes soft and doughy, and later tends to break down and ulcerate. It may even, when well advanced, disappear by absorption, but usually it gradually or rapidly breaks down, the skin giving way, at first centrally and then extending or at several points, and resulting in a small or large, deep, punched-out ulcer, with, as a rule, free gummy puriform secretion, which may latter assume a greenish tinge and have an offensive odor.

In other instances, instead of a tolerably well-circumscribed, growing subcutaneous nodule, the gummatous infiltration is more diffuse, involving a palm-sized or large area and without being at all sharply defined peripherally; but the central portion is sometimes considerably elevated, and there is a gradual sloping into the surrounding part; the skin is at first usually pinkish, with a sluggish, violaceous tinge, later becoming dull reddish. It may be less diffused in the beginning and then spread out, or it may start as a large area. The infiltration gradually or rapidly becomes more marked, and the skin and tissue break down, either at scattered points or the destructive process involves the whole plaque uniformly; there results, therefore, either a dull reddish or violaceous, somewhat elevated, or later flattened area, beset with several or more bean- to nut-sized, sharply cut or punched-out ulcers, which may be irregularly disposed or exhibit segmental or serpiginous configuration, with more or less gummy purulent discharge, and which may at times dry to thickish, brownish or greenish crusts; or one extremely large, scooped-out,

often deep-set open ulcer with edges well defined, sometimes slightly sloping, sometimes sharply cut. In occasional instances the infiltration is more superficial and but slightly elevated, having the dull, sluggishly inflammatory aspect, and at first has an acute or subacute eczematoid appearance, soon giving way here and there to superficial ulceration; or the destructive process involves the entire area, and may

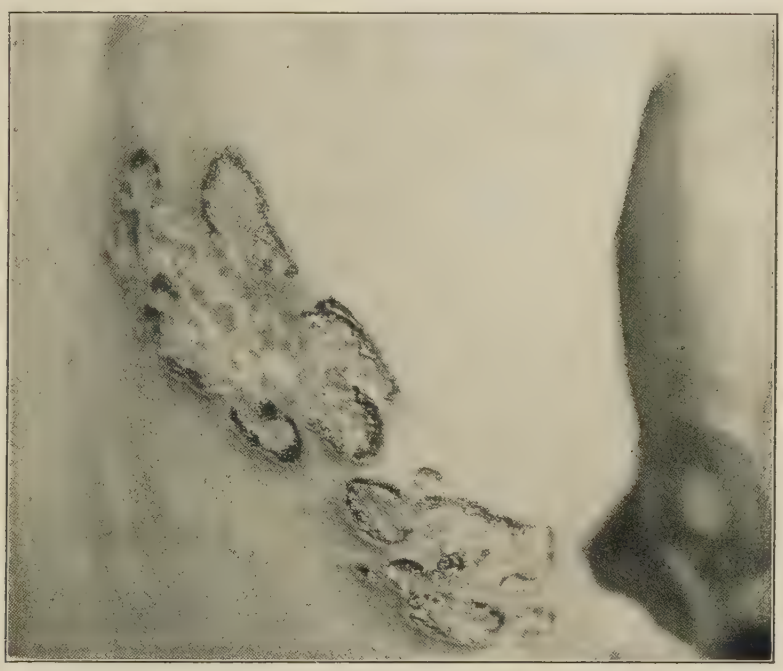

FIG. 175.—Tubercular syphiloderm, with decided ulceration, showing a rare zosteriform distribution (courtesy of Dr. M. B. Hartzell).

later, as in other forms of gummatous infiltration, extend somewhat deeply.

Sometimes the plaque begins similarly to that just described, but is the seat of closely set or crowded tubercles or small gummata, lesions partaking of both the nature of tubercles and gummata, occasionally producing considerable enlargement of the part, constituting a type which is sometimes designated **tuberculogummatous syphiloderm** or **syphilid** or infiltration. When involving the foot and lower part of the leg, it presents a pseudo-elephantiasic aspect, which might be mistaken for both elephantiasis and carcinomatous disease. In these larger diffused gummatous infiltrations the ulcers, instead of being irregularly rounded or ovalish, may be somewhat segmental or crescentic in shape. Occasionally in a large, infiltrated plaque absorption or slight ulceration ensues here and there, and the area therefore sometimes presents irregular grooves, nodular infiltrations, and projections, which may give it a puckered aspect. Exceptionally a gumma may be somewhat superficial, not extending

deeply, and be small, hard, and more or less sharply circumscribed, with or without tendency to soften and break down, and be sluggish and slow in its course. Such a formation has sometimes been observed on the glans penis and other parts, and has doubtless often been mistaken for a relapsing chancre or induration (chancre redux), or for the initial lesion of a supposed second infection.

The favorite sites for the gummatous manifestation of syphilis are



FIG. 176.—Tuberculogummatous syphiloderm involving nose and upper lip, with destructive action; duration eight months; disease contracted some years previously.

the soft parts, especially of the thigh and calf regions, and the trunk. They may occur upon any region, however, and are not uncommon on the face, flexor aspects of the arms, and other parts. The course of gumma or gummatous infiltration is usually slow, although at times developing with rapidity; the ulcers are, as a rule, persistent, and often grow larger, while the gummatous process is extending and invading the contiguous tissues. Sometimes the process is deeply and progressively destructive, involving bone as well as the soft parts, so that not infrequently, especially when about the face, considerable disfigurement results. Treatment is commonly followed by rapid improvement and finally by cure; and, considering the amount of destruction generally observed, the consequent distortion is relatively slight, ulcers filling up and healing over with not strikingly conspicuous scar-formation. At times, especially if about the joints, the cicatricial tissue may exhibit a keloidal tendency, but, as a rule, this is not observed.

PLATE XXVIII.

Gummatous syphiloderm, showing diffused gummatous infiltration, with characteristic ulcers and scarring from former lesions.

The **diagnosis** of gumma in the earliest stage is sometimes difficult, as there is a resemblance to furuncle, abscess, enlarged lymphatic glands, sebaceous, fatty, fibroid, and other tumors, and to erythema induratum. A definite conclusion is sometimes reached only by attention to its origin, course, and behavior, together with the history of the case and the possible presence of other cutaneous lesions or scars of earlier manifestations. Compared to most of these formations gumma is much more rapid in its development. The gummatous ulcer is more or less characteristic, being usually deep, with sharp, punched-out edges, and frequently but slight bordering infiltration, and has a rather free purulent discharge. In epithelioma the border is often semitranslucent and roll-like, or beset with several or more small, pearl-like tubercles or nodules; the ulcer shows less discharge and exhibits a disposition to bleed easily; and its progress is generally slow, and its history often materially different from that of a gumma. The carcinomatous infiltration and nodules often seen to arise in the skin or scar of the breast following operation for breast cancer, and which sometimes arise primarily, can readily be excluded, as a rule, by the history, the much harder character of the infiltration and nodules, the peculiar color, and the progress, supplemented, if necessary, by microscopic examination of the tissue. I have seen a few cases, in consultation, of extensive infiltration involving the female genitalia, strongly suggesting carcinoma, but which, under the influence of the ordinary specific remedies, made full recovery. In all obscure cases recourse should be had to the microscope, and if necessary, owing to possible doubt, treatment should be tried before operative measures are adopted. The differentiation from erythema induratum is considered under the latter disease.

CUTANEOUS MANIFESTATIONS OF HEREDITARY SYPHILIS.

Hereditary syphilis, as the term implies, refers to the disease as transmitted by the parent. It is sometimes also designated **congenital syphilis** and **infantile syphilis**, but these are not so clearly expressive, and the latter could just as well be applied, as in fact it is, to the acquired as to the inherited malady. The symptoms of acquired syphilis in the infant are essentially those of the acquired malady in the adult, and need not be separately discussed. Nor are, in fact, the syphilodermata of hereditary disease materially different, often mixed, and usually of the macular, papular, or bullous type.

In a syphilitic pregnancy in which the fetus has escaped abortion or still-birth, the infected offspring may be born with or without the existence of manifestations at the time of delivery, and in the large majority of cases the child in reality, when born, presents every indication of good health, and the signs of the malady may not present for a few weeks or a few months.[1] A child born of syphilitic parentage, which fails

[1] In 1000 cases observed in a foundling hospital Miller (Die frühesten Symptome der hereditären Syphilis, *Jahrbuch für Kinderheilkunde*, vol. xxvii., 1888, p. 359) states that the disease manifested itself in 64 per cent. in the first month (8.5 per cent. in first week, 13.8 per cent. in second, 24 per cent. in third, and 17.7 per cent. in fourth) and

to present manifestations within the first six months, may usually be considered to have escaped infection, although some exceptions do occur. Most of the cases, however, which have been described as examples of syphilis hereditaria tarda, in which osseous, dermal, and other lesions have been observed as the first evidences in later years, are to be looked upon with considerable question, as the history is often vague or obscure, and there is a probability that the disease, instead of being hereditary, was contracted during or after delivery or at a later period, with latent or mild early symptoms which escaped observation. Late and relapsing manifestations may, however, sometimes be observed in those who have been subject to the usual early postnatal symptoms, although it must be admitted, fortunately, that the hereditary disease, if it yields to treatment, shows, if the latter has been properly carried out, but little tendency to recurrences, although some traces of its ravages or influence may remain. These latter are, however, more commonly the effect of incomplete or neglected treatment, resulting from the halting or damaging effect the disease has upon nutritive processes. Among such symptoms as are of dermatologic interest, and which are also not uncommonly present in the first months or year, may be mentioned interstitial keratitis, notched teeth (Hutchinson's teeth), disturbances of hearing, irregular thickenings or flattened nodosities of the skull, dactylitis (dactylitis syphilitica), onychia and paronychia, inflammation, swelling, and tenderness of the region of the neck of the long bones, and sometimes resulting pseudoparalysis.[1]

Hutchinson was the first to call attention to the *notched condition of the teeth* as commonly indicative of syphilis, but this condition can scarcely, as originally observers were inclined to believe, be absolutely diagnostic, for the same or closely similar condition may occasionally be observed as the result of profound nutritive disturbance upon the child from other causes during the period of second teething. Nevertheless, it possesses considerable import. While the canines and other teeth may also show notching, Hutchinson places the chief significance upon the upper central incisors. At first they are noted to be somewhat short, with thin edges, the two teeth commonly converging, but sometimes widely separated; later the central border breaks or crumbles away, and leaves a broad, shallow notch. It generally disappears between the twentieth and thirtieth years from wearing down of the projecting parts.

22 per cent. in the second month. As the infants are sent out to the country at the end of this time to prevent overcrowding, no further careful record could be made beyond this time. The first symptom noticed was the maculopapular eruption in 46 per cent., papules on skin and mucosæ in 28 per cent., rhagades oris et ani in 22 per cent., maculæ in 17.9 per cent., bullous eruption in 8 per cent., abrasions and ulcers in 5.9 per cent., paronychia in 4 per cent., and pseudoparalysis of the extremities in 4 per cent.

[1] Miller (*loc. cit.*), in his analysis of 1000 cases, shows that the affections referable to syphilis and seated upon or in immediate relationship with the skin and adjoining mucous surfaces were as follows: Papules, including moist papules on the integument or mucous membrane, were present in 74 per cent.; fissures of the lips, angles of the mouth, and anus in 70 per cent.; rhinitis in 58 per cent.; ulcers of the hard palate in 52 per cent.; macules in 45 per cent.; ulcers of the tongue in 27 per cent.; bullæ in 25 per cent.; onychia (paronychia) in 23 per cent.; lymphadenitis chronica in 29 per cent.; laryngitis in 17 per cent.; pseudoparalysis of the extremities in 7 per cent.; ulcers in 4 per cent.; ulcerative gingivitis in 4 per cent. The eruption was maculopapular in 46 per cent. of the cases.

Syphilitic dactylitis is usually observed in the early months of the disease, and differs in no respect from that of acquired syphilis, except that there is ordinarily considerable bulbous swelling. It is persistent and chronic, but, as a rule, will gradually disappear under treatment. It bears close resemblance to tuberculous dactylitis, from which, except by history and other symptoms, it often cannot be distinguished, and with which, in fact, it may be associated. As a rule, however, there is a greater tendency to break down in syphilitic dactylitis. The hair is likely to show some disturbed condition, thinning out, losing its luster, and dry and lifeless-looking. **Lymphadenitis** is an occasional occurrence, especially in those of scrofulous tendency, and the ordinary **adenopathy** as observed in acquired syphilis is also noted, but not so markedly or even so commonly, and is not infrequently practically wanting.

Coming back to the more usual conditions observed, the child born with evidences of the disease is generally noted to present a thin, wrinkled, old appearance, the skin of a brownish-yellow tinge; having a snuffling coryza, commonly a hoarse, peculiar cry, and presenting lesions both upon the skin and mucous surfaces. The lesions in such cases on the skin are usually vesicobullous or bullous, with cloudy contents, and often becoming purulent, constituting the **bullous syphiloderm.** They are more or less general, but the palms and soles are favorite situations; there may be interspersed maculopapules and papules. The bullæ are, as a rule, flaccid, sometimes distended, and are often surrounded by a brownish or coppery rim of infiltration; and are seated either upon an excoriated, eroded, or ulcerated base. About the anus and genitalia, especially the former, moist papules, sometimes coalescent and slightly hypertrophic, constituting the flat or broad condylomata, are not infrequently found. The angles of the mouth and nose may, more frequently than in the acquired disease, be the seat of papules or fissures; mucous patches and superficial abrasions or ulcerations are quite commonly found on the inner side of the lips and on other parts of the oral cavity. The general condition becomes worse, the marasmus increases in degree, and the child after some days or a few weeks, as a rule, succumbs.

The bullous syphiloderm is always indicative of a malignant form of hereditary disease, and usually presages a fatal end, but in the rarer instances in which it does not appear until later,—several to five or six weeks after birth,—while still of generally lethal import, exceptionally recovery takes place. In still rarer instances of children presenting other lesions than blebs at the time of birth the manifestation is commonly macular and papular, similar to the same eruptions appearing later and to be immediately described.

As already remarked, however, the syphilitic offspring at birth, as a rule, presents but little, if any, active evidences of the infection, occasionally being thin, shriveled, and with an old look and a sallow, dingy-looking skin. Ordinarily, however, the child exhibits a fair condition of health, and often, indeed, has a robust appearance. After some days or a few weeks slight coryza is noted, which usually develops into a well-marked and purulent rhinitis,—"snuffles,"—more or less completely blocking respiration through the nose. The

child begins, in most instances, to fall away, often shows cracks at the angles of the mouth, and possibly one or more mucous patches in the mouth. Occasionally in spite of the disease the general health seems to be but little affected, although, with few exceptions, it sooner or later suffers. At about the same time there appears a more or less generalized **maculopapular eruption**, commonly more marked on the palms, soles, and face and neck than in the acquired disease. About the anus, genitalia, and folds they frequently become abraded and moist, forming moist papules, and about the anus showing a tendency to hypertrophic enlargement, and presenting the same characters as the *moist papules* in the acquired disease. The moist papules or mucous patches in the mouth are also commonly present. The macules and maculopapules in the genitocrural region sometimes increase in number, spread, and form larger plaques or a more or less confluent sheet, of a dusky red or ham tint, and, in places at least, somewhat sharply marginate. There may or may not be some other symptoms, such as nail affections, dactylitis, exostoses, etc.

Quite frequently, indeed, a diffused **erythematous** or **macular eruption** appears in the genitocrural region, usually also involving the buttocks, and shows but little, if any, tendency to associated or outlying maculopapules or papules, and, except as to the dusky red color, resembling erythema intertrigo. Not uncommonly it is the first evidence of the disease, or that which leads to procuring medical advice. As a rule, however, inspection or inquiry will show several of the associated symptoms, such as the fissures or papules at the corners of the mouth, one or more mucous patches in the latter, papules at the anus, and possibly lesions on other situations.

These two manifestations,—macular and mixed maculopapular,—according to my experience, are those most frequently observed in the hereditary disease. While developing, as stated, usually in the first several weeks, two, three, or more months sometimes elapse before the outbreak, although the later the appearance, the more, it seems to me, is the tendency toward a predominance of the papular element. Not infrequently the eruption is at first chiefly macular, the macules later developing into maculopapules or papules. In some of these latter cases the papules become slightly scaly, although rarely to such a degree as observed in the papulosquamous eruption of acquired syphilis. The papules are of the flat variety, and not, as a rule, much elevated, and somewhat variable as to size, although usually pea- to finger-nail-sized; the acuminated papules are rarely seen in the hereditary disease.

The manifestations, whether predominantly macular, maculopapular, or papular, are somewhat persistent, and new lesions may continue to appear for some days or longer; in severe cases, and especially in those whose nutrition is impaired, probably through visceral complication or other causes, as neglect or poor feeding, the general health fails, a marasmic condition develops, some of the lesions may show ulcerative tendency, and the child gradually sinks and finally dies. In less severe cases, especially if well nourished and carefully looked after, the manifestations after a time begin to fade, and with or without a few relapsing exacerbations the disease apparently runs its course and the patient recovers, in some instances to have

later other signs of the malady. Whether without proper treatment so favorable a result sometimes ensues is difficult to state, inasmuch as such cases usually receive medical care. Nevertheless I have seen several instances of the hereditary disease, in connection with dispensary practice, presenting one or the other of these milder manifestations, in which apparent recovery followed in spite of gross carelessness and neglect on the part of the parent in carrying out the treatment ordered, although such a result is extremely unusual.

The **pustular syphilodermata** are seldom met with as a hereditary manifestation, although some of the vesicular, vesicobullous, and bullous lesions of the bullous syphiloderm may become purulent and develop into more or less perfectly formed pustules. More commonly several or more pustules, usually flattened, will be seen about the mouth, nose, and genito-anal region in association with the maculopapular or papular syphilodermata. When they occur in any profusion, a grave type is usually indicated. The **tubercular syphiloderm** is rare in the hereditary disease, although it may occur as early as the sixth month, and sometimes later,—several or more years after birth,—but at this period usually as a recurrence. The **gumma** is, as a rule, not met with in the first months or first few years, but generally after the third or fourth year. It is similar in its characters to the same lesion in the acquired disease in the adult.

The **diagnosis**[1] of the hereditary syphilodermata is rarely a matter of difficulty, as the associated symptoms of snuffles, mucous patches in the mouth, moist papules or flat condylomata around the anus, the frequently accompanying shriveled or "old-man appearance," the marasmic tendency, and the usually polymorphous character of the eruption will give a picture more or less characteristic. At least two, sometimes more, of these associated symptoms will generally be present, together occasionally with dactylitis, onychia, keratitis, exostoses, etc. The course and outlook of these hereditary cases have already been incidentally touched upon. The **prognosis** depends upon the variety, severity, general condition of the child, the probability of proper nursing or feeding, and the careful carrying out of the treatment. In breast-fed children the disease is much less fatal than in those artificially nourished. The result is, however, always somewhat uncertain, and by far most cases die. As a general rule, the more distant from the time of birth the manifestations appear, the more favorable is the outcome.[2] Occasionally destructive action takes

[1] The Spirochæta pallida is also to be found in hereditary syphilis; Levaditi in an interesting paper ("L'histologie pathologique de la syphilis héréditaire dans ses rapports avec le 'spirochæte pallida,'" *Annales, mal. vén.*, 1906, p. 22), goes over the ground, with review references to the work of Hoffmann, Buschke and Fischer, Bodin, and others. See also remarks under Etiology, p. 776, and under Diagnosis of the syphilodermata in general, p. 781.

[2] Hyde's paper, entitled "What Conditions Influence the Course of Infantile Syphilis," *Medical News*, Dec. 4, 1897, is a valuable presentation, on pertinent points, based upon his own observations and the statistics of such other careful observers as Kassowitz, Lancereaux, Neumann, Coutts, Jullien, Warner, and others. It shows that in 1700 syphilitic pregnancies the number of abortions and still-births amounted to 579, leaving 1121 born alive, of whom 956 died within the first twelve months; of the remaining 165 who chanced to survive a year, nothing is further known. Of 41 pregnancies in 25 syphilitic mothers under his own observation, there were 31 abortions and children dead at birth or within one year. Henoch (*Vorlesungen über Kinderkrankheiten*, 1889, p. 105), quoted by Hyde, claims that all infants affected with hereditary syphilis die if they are

place in the nose, and a flattening of this organ in such an event will occur.

Etiology.—Syphilis is acquired through heredity, which has been sufficiently touched upon, and in various ways by direct inoculation. The usual and, of course, the most common method is through the sexual act, by conveyance of the syphilitic poison from an existing chancre or other lesion present on the genitalia; houses of prostitution and street prostitutes are its principal sources. But, as already referred to in describing the initial lesion, extragenital chancres are not at all uncommon, and are the result of accidental and, with probably but few exceptions, perfectly innocent inoculation, as by the act of kissing, from drinking-cups or glasses, or the common communion-cup; by infected razors, etc., in barber-shops, tattooing;[1] by medical men also from operations and other professional manipulations, and in many other ways. Knowing the contagiousness of the secretion from mucous patches, which are to be found quite frequently in the mouth, the wonder is, in fact, that the innocent and unsuspecting are not more frequently accidentally infected through the common drinking vessel and in other similar manner. There is an all too common belief that extragenital chancres,[2] especially about the mouth, as well as other parts, are frequently due to unnatural sexual relation, but considering the chances of innocent contraction of the disease, such a suspicion is, with rare exception, an extremely unjust one. The readiness of accidental inoculation is shown by the examples of physicians who, in the course of professional pursuit, through digital vaginal examination, operation, and in other ways, contract a finger chancre. Fifteen to twenty such instances have come to my own notice.[3] It is, too, not improbable, indeed, that medical men themselves have been occasionally, before the days of full appreciation of the value of complete asepsis, the unintentional agents of conveying the disease to others through infected instruments which had not been properly cared for; and the same may be said more positively of dentists, who have to do with a cavity in which contagious material is often present. Fortunately, the best dentists now give attention to the necessity of sterilizing instruments after each use, but there are still many who show a lack of even common cleanliness. The number of extragenital chancres which come under the observation of those engaged in certain lines of special practice, more particularly those of diseases of the skin, venereal diseases, and throat diseases, in which suspicion

not suckled at the breast, and Widerhofer ("Klinische Vorlesung," *Wien. med. Zeitung*, 1886), quoted by the same writer, puts the percentage of such deaths in children artificially reared as high as 99 per cent. It seems to me, however, that it is not at all improbable that in some of those cases the result was considerably influenced by improper or insufficient feeding, neglect of prompt and early treatment due to parental indifference or ignorance, and thus affected the mortality percentage.

[1] Maury and Dulles, "Tattooing as a Means of Communicating Syphilis" (15 cases), *Amer. Jour. Med. Sci.*, January, 1878; Barker, "Outbreak of Syphilis Following on Tattooing," *Brit. Med. Jour.*, 1889, i., p. 985 (12 cases with several cuts).

[2] See Bulkley's most admirable monograph, *Syphilis in the Innocent* (Syphilis Insontium), New York, 1891.

[3] A. Blaschko, "Syphilis als Berufskrankheit der Aerzte," *Berlin. klin. Wochenschr.*, No. 52, Dec., 1904; D. W. Montgomery, "The Acquisition of Syphilis Professionally by Medical Men," *Jour. Cutan. Dis.*, April, 1905 (7 cases, with review of many other reported cases, and references).

often points to these various sources, is sufficiently large to make one feel strongly on the subject.

Infected persons should always be informed of the danger of conveying it to others, and to take all precautions against such possible mishap, and this, together with proper treatment, at present seems the only method of controlling its spread, as effective legal supervision seems both impossible and impracticable. The period of danger of contagion is not a wholly definite one: it exists through the active stages of the malady, and therefore during the first one or two years; persisting, but its virulence or potency probably becoming gradually less, in some instances up to the third, fourth, and even fifth year. The pathologic secretion from any lesion during the time of this activity is capable of producing the disease. The blood of such an individual is also infecting, and while the physiologic secretions, such as the saliva, milk, sweat, etc., are believed to be generally innocuous, yet the possible admixture of even insignificant quantity of blood or discharge from mucous patches or other lesion, however small or unrecognized, renders such secretions dangerous, and this fact is to be kept in mind. Contagiousness is, however, generally considered by those of largest opportunities to be uncommon after the second or third year, but there are sufficient exceptions to this during the fourth and fifth years to consider still the possibility of danger.[1] The belief that the tertiary lesions are innocuous in this respect is not so absolutely held to-day as formerly, and instances have been noted in which the virulence still existed.

While the various facts above mentioned are now common knowledge, the infective germ to which the disease is doubtless due has long been eagerly sought for.[2] The most recent and promising finding is that of the Spirochæta pallida by Schaudinn and E. Hoffmann,[3] whose findings have been since repeatedly confirmed by

[1] See interesting paper by Feulard, "Durée de la periode contagieuse de la syphilis," *Trans. Third Internat. Dermatolog. Congress*, and *Annales*, 1896, p. 1025 (shows that four or five years or more afterward contagious examples have been noted—many cited both from his own experience and that of others).

[2] Krzysztalowicz and Siedlecki, *Monatshefte*, vol. xli., 1905, p. 231, give a brief review of these various findings to date.

[3] Schaudinn and E. Hoffmann, *Arbeiten aus dem k. Gesundheitsamte*, vol. xxii., 1905, p. 527; *Deutsch. med. Wochenschr.*, May 4, 1905; *Berlin. klin. Wochenschr.*, May 29, 1905; *ibid.*, July 10, 1905; E. Hoffmann, *ibid.*, 1905, No. 32; E. Hoffmann and Halle, *Münch. med. Wochenschr.*, 1906, No. 31; E. Hoffmann and Beer, *Deutsch. med. Wochenschr.*, 1906, No. 22. Among the many contributions on the subject may be mentioned the admirable review paper by Shennan, *Scottish Med. and Surg. Jour.*, 1905, p. 457 (with bibliography), and *Jour. Cutan. Dis.* (same paper), 1905, p. 457; Fanoni, *Med. News*, Oct. 7, 1905 and *New York Med. Jour.*, Nov. 4, 1905; Flexner, *Med. News*, Dec. 9, 1905; Pfender, *Amer. Med.*, Mar. 10, 1906 (with bibliography).

The *Spirochæta pallida*, now classified as *Treponema pallidum* is an extremely delicate organism; long, very thin, and filamentous, of a spiral, or cork-screw shape, with pointed ends showing a hair-like flagellum; and as stated by some writers, with a nucleus, although this last is not yet absolutely proved. Its length varies from 4 to 10 μ; its breadth is difficult to gauge, being at most about 0.25 μ; the turns in the spiral number six to fourteen, averaging eight to ten. It is vigorously motile, and progresses by rotating on its long axis, and when at rest it shows undulatory movements in its whole length, suggestive of the play of a vibratile membrane. It exists in numbers and more numerously in the deeper parts of the lesions; is very weakly refractile, stains with difficulty, and is not easily seen, requiring very high power of the microscope, $\frac{1}{12}$ oil-immersion objective with medium to No. 8 ocular. They have been found in primary and secondary

themselves and numerous other investigators. That this organism exists in primary and secondary lesions and lymphatic glands is, therefore, now admitted, and its pathologic importance, although not absolutely proven, seems reasonably assured. It is true that some doubt is engendered by the statements of a few observers that they have also found the organism in nonsyphilitic lesions, but inasmuch as there are other spirochetes resembling the Spirochæta pallida, these statements may, it is hoped, be due to errors of that kind. In a few instances, however, examinations for the organism have been negative. Now that Metchnikoff and Roux[1] followed by Lassar and Neisser, have shown conclusively that syphilis can be transmitted by inoculation to chimpanzees and other apes, a field of investigation is opened that may lead not only to the definite solution of this question, but also of some of the other problems connected with this interesting disease. Difference of opinion exists as to the explanation of the various grades of the disease as shown by the manifestations, which are sometimes slight or even almost wanting, or, on the other extreme, malignant. Some hold that it is chiefly dependent upon the difference in constitution, health, or resisting power of the individual; others that there is possible variation in the degree of virulence of the virus itself. The former certainly has considerable bearing, and the latter also, judging from the observations of other infectious maladies, must likewise be considered as not unimportant. Many external agents, such as heat and cold, etc., do not seem to be productive of any direct special influence, but in many instances of tertiary cutaneous manifestations a determining etiologic factor of import is local irritation or injury, which starts the syphilitic pathologic process.

Pathology.—The pathologic anatomy of syphilitic cutaneous lesions has been studied by various investigators, among whom notably are Biesiadecki, Auspitz, Neumann, Kaposi, Cornil, Unna, and Crocker, those of most recent date being by Neumann,[2] Crocker,[3] and Unna,[4] and whose conclusions in the main coincide. In general it may be said that the syphilitic deposit is essentially a new growth, and consists of round-cell infiltration, especially about the vessels, generally endothelial proliferation, and in the papular, tubercular, and gummatous lesions, the presence usually of a variable but, as a rule, scanty, number of giant-cells. The rete, corium, and in the deep lesions the subcutaneous connective tissue also, are involved in the process, although the initial changes are noted in the upper part of the corium. It differs from some other neoplastic formations by the

syphilitic lesions, and the lymphatic glands, and in almost all tissues and organs in hereditary syphilis. They remain alive for several hours in physiologic salt solution, and they can be seen in smears from the tissue juice, fixed in absolute alcohol, and stained by a modification of Giemsa's method; Schaudinn and Hoffmann employed Giemsa's eosin-azure solution.

[1] Metchnikoff and Roux, *Ann. de l'Institut Pasteur*, Nov. 25, 1905; Neisser, *Deutsch. med. Wochenschr.*, 1906, Nos. 1–3; Bowen, *Boston Med. and Surg. Jour.*, 1905, vol. clii., p. 285, gives a review of these "experimental inoculations."

[2] Neumann, *Archiv*, 1885, p. 209 (with many excellent plates and résumé of the investigations of others).

[3] Crocker, *Diseases of the Skin*, third edit., p. 845, *et seq.*

[4] Unna, *Histopathology*.

absence of all tendency to organization, the retrogressive steps being by involution through fatty degeneration and absorption or by necrosis and consequent ulceration. The ordinary changes are not so well shown in the macular syphiloderm, where, in fact, the changes scarcely go beyond hyperemia with insignificant cell infiltration, and are practically limited to the papillary layer of the corium; often tolerably sharply defined, and sometimes extending a little more deeply, and also, when more than the usual effusion takes place, upward to the lowest strata of the rete. Sometimes also, according to Neumann, the changes extend still more deeply, and cell effusion is noted around the glandular structures as well. The capillaries and other minute vessels are dilated, and both in and surrounding them is found cell accumulation, with also both round and spindle-shaped cells in the adventitia of the larger vessels. A variable number, usually large, of the Spirochæta pallida will, on careful examinations, and more especially after staining, be seen in the lesions; being more numerous in the deeper parts.

Renaut[1] says that all the different forms of syphilitic lesions are, anatomopathologically considered, structurally the same: a reactionary defensive work against a pathogenic agent, which, at a certain stage, gives rise to an endarteritis of a special kind, slowly obliterating, and tending from the first to excite the production of hypertrophy of the tissues about it.

In the miliary papular or follicular syphilid the process is seated especially around and about the hair-papilla, and also in the tissues immediately surrounding and slightly below the follicle, the cell infiltration being of a dense character. The vessels of the papilla are dilated, and both surrounded and filled with cells, the vessel-walls exhibiting numerous nuclei. The hair-sac, especially at its lower part, is dilated and ruptured by the pressure of the dense cell collection. The adjacent horny layers show slight changes, the rete is thickened, and the corium more or less replaced or obscured by the cell infiltration. The sebaceous glands and neighboring sweat-glands are also involved. This papule is not always, however, formed about the hair-follicle, as, according to Crocker's investigations, "it is also formed by the lifting-up of the epidermis by dense cell effusion, in the center of which a sweat-duct can sometimes be traced."

The flat papule may be said to represent the more typical conditions of the syphilodermata, and these show some resemblance to lupus vulgaris. There is marked deposit here, and found seated in the rete, all layers of the corium, and downward in the subcutaneous tissue, where it is sharply defined beneath. There is also sharp definition laterally. The cell infiltration is in places more or less dense, and in others somewhat disseminated, but it is greater in the papillary and subjacent layers, being primarily observed about the vessels and their ramifications of the superficial and deep plexuses. It may be so great in amount as to more or less obliterate the normal structures. A variable number of incompletely formed, and a few typical, giant-cells, and occasional epithelioid cells, are commonly also to be noted.

[1] Renaut, *Rev. prat. d. mal. Cutan., Syph. et vénér.*, Jan., 1903—abs. in *Brit. Jour. Derm.*, 1903, p. 271.

The new growth in the papular syphilodermata, according to Unna, is composed mainly of variously sized plasma cells. The sweat-ducts and coils are frequently involved to considerable degree, both by surrounding cell infiltration and proliferation of the lining cells. The hair-follicle in this papular form usually holds its shape fairly well. In the process of involution the first steps are generally noted centrally, absorption taking place, and the part sinking in slightly, and exceptionally absorption may be so complete in this part, and then with halting or relatively slower retrogression peripherally, that the papules present a ring-like aspect. In the squamous papular lesion the epidermis shows considerable involvement, the horny layers exfoliating, and usually with a moderately or considerably thickened proliferating rete. The moist papule may extend more deeply than the ordinary papule, but ordinarily the conditions are essentially or closely similar, but the rete is usually considerably thickened and the papillæ show variable degrees of hypertrophy and elongation from slight to extreme development.

The tubercle and gumma are not only clinically to be looked upon as enlarged papules, but also anatomically, the process, of course, being much more extensive, and going more widely and more deeply into the tissues. The evolution of the tubercle is much less rapid, and its persistence more prolonged, and atrophic or necrotic changes going into ulceration usually follow. In gumma the infiltration is generally wide-spread and much deeper, although it remains fairly well circumscribed. While the deposit in this growth may ultimately disappear by absorption, its usual course is that of necrosis and ulceration.

The pustular syphilodermata may, in great measure, be viewed as papular processes, plus the consequences and changes produced by local pyogenic cocci invasion. In the basal or more or less persistent papular portion the alterations are similar to those found in papules. Like the latter, therefore, they are well defined, and may be seated in the corium or the subcutaneous tissue. According to Kaposi, as quoted by Duhring, " the essential features of the pustule consist in the presence of dimly contoured, highly granular, cloudy, nucleated cells, and free nuclei within the uppermost layers of the corium, papillary layer, and rete, seated in a succulent, large-meshed, serum-saturated tissue or even in open spaces." As with the papules, the pustular lesions may be connected with the hair-follicles or be seated in the corium independently of this structure and of the sebaceous gland. The anatomic conditions of the several varieties of the pustules themselves are not greatly different from those of similar non-specific lesions, as variola, impetigo, and ecthyma. The pus-chamber is to be found between the epidermic strata, often with the eroded rete as the basal portion, or the corium forming the basal boundary, and not infrequently the suppurative or destructive action extending superficially or more or less deeply through this latter structure, and in such instances followed by more or less marked and permanent scarring.

The dark or dusky red or ham color commonly noted in the syphilodermata is due to the blood-coloring matter derived from the wander-

ing or extravasated red corpuscles, and to the sluggish character of the inflammatory element. The whole process is, in fact, usually slow in evolution and more or less persistent, and this sluggishness is still further emphasized by Neumann's observations that the morbid products, chiefly exudation cells, are to be found four to eight months after clinical evidences have disappeared; and this, as Crocker states, "lends some support to Hutchinson's doctrine 'of residues of the early period of syphilis being the starting-point of later lesions.'"

Diagnosis.—The features of the various syphilodermata have already been considered in connection with the description of each form, and in the general observations concerning the special characters of these eruptions; a study and clear understanding of the latter will go far toward the prevention of errors in diagnosis. The general characters, distribution, color, and associated concomitant symptoms in the early syphilodermata, usually with the history of the initial lesions, are the chief valuable differential points. The finding of the Spirochæta pallida might be the determining factor in a doubtful case, but as yet too much stress is not to be placed upon this, as the same or a closely similar organism has been found by several observers in nonsyphilitic lesions; and, moreover, a few expert investigators have failed in some instances of unquestioned syphilitic lesions to find the Spirochæta pallida at all. Fortunately cases of syphilis are rare that can not be recognized by the gross clinical symptoms alone. In the late eruptions the limited or regional character, segmental, circinate, or serpiginous configuration, together with the color, and commonly an ulcerative tendency, are to be given consideration.

Prognosis.—The prognosis as to the syphilodermata, the duration of contagiousness of the virus, and hereditary syphilis have received more or less consideration in connection with type description and etiology. The cutaneous manifestations of the secondary stage, except sometimes the palmar and plantar papulosquamous lesions, all disappear sooner or later spontaneously, but much more rapidly by treatment. In short, if the patient lives,—and in only rare instances of malignancy does death take place in the secondary period of syphilis,—the eruption or eruptions and relapses of this period are self-limited, even though the patient be neglected. On the palms and soles, in the form mentioned, there may be chronicity, and while many such cases yield more or less promptly to proper constitutional and local measures, some are extremely rebellious. Moist papules are, if untreated, sometimes persistent, but yield rapidly to local measures and also to constitutional medication.

The late syphilodermata show but little if any disposition to spontaneous cure, but, as a rule, respond readily; in exceptional instances, more especially in the tubercular or tuberculogummatous form, and more particularly about the nose, and in the flattened, gummatous, infiltrating variety, the improvement is often slow, and the final cure brought about only by energetic and persistent medication. The apparent obstinacy in some of these cases is due to the patient's tolerance of the specific drugs employed, especially to the iodids. My own observations as to these rare cases have shown me that mercury is the remedy which needs to be pushed, the

potassium iodid even in large doses proving ineffective, and, if this is done, a result is soon obtained. Ordinarily, as with the other eruptions, gummata likewise respond rapidly under treatment, and sometimes disappear without ulceration, even after considerable softening has taken place; ulcerations from this as well as the tubercular or other types show, as a rule, prompt reparative process. In rare instances gangrenous ulceration, due indirectly to syphilis in consequence of resulting endarteritis obliterans, without preceding formation of a gummatous neoplasm, is observed, and which shows but little effect from antisyphilitic treatment.[1] Mucous patches in the oral cavity may be stubborn if smoking is continued and if kept up by irritation from a sharp or rough tooth or by irritating drinks or foods; but with attention as to these points will generally disappear either as the result of internal treatment or local applications. There is a tendency to relapse or new spots, especially under the above conditions, and particularly from smoking. With smokers, even though the active patches themselves finally go, those sometimes present just within, but slightly beyond, the corners of the mouth, while they practically disappear, leave behind somewhat milky-looking, occasionally slightly thickened, areas, the so-called smokers' patches, and which probably are to be looked upon as a mild phase of leukoplakia, and not necessarily possessed of contagious properties.

The mildness or severity of the disease cannot always be foretold by the character of the chancre or the early secondary symptoms. The pustular syphilodermata are usually significant of a severe type, showing either virulence of the virus or impaired resisting power, or both. The condition of the general health has often a material influence in determining the grade of the disease, and subjects with tuberculosis or such family tendency often show severe manifestations. The belief that the infection following extragenital chancres is always more severe is somewhat general, but has nothing substantial to support it, and extensive experience will soon prove that the infection, as regards degree, has no relation whatever to the site of the inoculation. As a general rule it can, I believe, be said that mildness of the early secondary symptoms is indicative of a mild type of the disease, and less probability to late manifestations. This probability is always materially lessened, both in the mild and severe cases, by proper and persistent specific medication. Indeed, late symptoms are to be considered rather exceptional if treatment has been thorough, and I can fully agree with Neisser[2] and others that the most important etiologic factor in the production of the tertiary syphilodermata is to be found in imperfect or deficient mercurial treatment in the early periods of the disease.

Treatment.—The treatment of syphilis as regards the specific constitutional remedies is at the present day clearly understood, but

[1] See paper by Klotz, "On the Occurrence of Ulcers Resulting from Spontaneous Gangrene of the Skin During the Later Stages of Syphilis, and their Relation to Syphilis," *New York Med. Jour.*, Oct. 8, 1887 (with references).

[2] Neisser, "Ueber die ætiologischen Beziehungen der tertiären Lues zur Therapie in der Frühperiode," *Verhandl. V. Deutschen Dermatolog. Cong.* (1895), 1896, p. 164 (with opinions and statistical records from his own practice and that of Fournier, Haslund, Hjelmann, and Ehlers.

concerning the manner or method there is still some diversity. For the minute details and various plans of treating the initial lesion the reader is referred to works on venereal diseases. It consists practically in the maintenance of cleanliness. This can be accomplished by washing the parts with tepid water, occasionally using soap, two or more times daily, according to the conditions, and the use of a bland antiseptic dusting-powder, such as boric acid, of boric acid with 2 to 5 per cent. admixture of acetanilid, iodol, or like substance; or, sometimes, the application of lint wet with black wash, or with saturated boric acid solution containing 2 or 3 minims (0.135–0.2) of carbolic acid to the ounce (32.). As soon as there is no longer question as to its nature, the best application, if it is desired to hasten its disappearance, as more especially obtains on extragenital parts, is mercurial plaster, full strength, or, if irritating, with one or more parts of vaselin or other ointment base, and kept constantly applied, changing twice daily. Ointments, as commonly understood, however, are not usually satisfactory, except as a supplementary application, spread upon lint, in those discharging cases in which there is more or less gumminess, which glues the dry dressing too firmly. In women the same plans are followed, but the importance of cleanliness—frequent washing—is still more important, conjoined with the liberal general use to the parts of mild antiseptic lotions, such as boric acid, with or without a minute quantity of corrosive sublimate, or with a weak solution of potassium permanganate. The parts should be kept separated with pieces of lint. When administration of mercury is begun, it will, if the induration is still present, and it often is when constitutional medication is instituted, have a prompt influence in promoting its absorption. Caustic agents are not desirable or necessary.

Constitutional Treatment.—Before taking up the consideration of the specific treatment proper, the occasional necessity of general tonic remedies and the value of hygienic living in the management of the disease should be referred to. The effect of freedom from excessive or even moderate "drinking," good food, healthy living, and reasonable exercise cannot be overestimated, and are essential to final success in the severe and especially malignant cases, and of more or less material help in the proper handling of the mild types. Smoking is also detrimental, and often the exciting causative factor in the production of mucous patches in the mouth. While in spite of disregard of these ordinary common-sense measures the eventual outcome as to the active stages of the disease is usually seemingly favorable, there can scarcely be a doubt that the tissue-resisting power and recuperative force are not infrequently sufficiently impaired or lessened as to give a greater probability of recurrent manifestations. With, however, the observance of such precautions and the administration of the specific remedies, most cases go on successfully to satisfactory end, some with no other manifestations than the macular or maculopapular, or possibly papular, syphiloderm, and one or several light, concomitant, secondary symptoms, with, in others, a tendency to slight recurrence or outcroppings. In some the disease is, of course, more troublesome, and with, for a variable time, a persistent

tendency to manifestations. In other cases the anemia resulting, the depraved condition of the health engendered, and other occasional accidental, non-specific affections, but indirectly due to the disease, may require the administration of iron, cod-liver oil, strychnin, digestive tonics, and other indicated remedies. It is true that the mild anemia not infrequently encountered will often disappear upon the administration of the specific,—mercury,—which, as Keyes and others have pointed out, has a direct influence in increasing the number of red corpuscles,

The proper time for the institution of the specific constitutional treatment is generally taught to be when the earliest secondary symptoms put in an appearance, when there no longer remains the least question as to syphilitic infection. The main reason for believing the earlier administration of the specific drug injudicious is that there may possibly be an element of doubt as to the nature of the inoculative lesion, which, though it may present the characters of the initial sore of syphilis, yet the induration which distinguishes it may be the result of accident or meddlesome applications, and simply be a chancroid or patch of herpes or other simple irritation which has been thus transformed; under such circumstances the patient would forever be under the impression of having syphilis, believing the constitutional treatment had kept the secondary symptoms in abeyance, which it frequently does in true infection when its administration is begun during the early chancre stage. Another reason is that if administered early, the patient may establish more or less of a tolerance for it, and thus, when prompt effect against the appearance of severe symptoms which may arise is desired, action, owing to this fact, can not be so quickly obtained. Of the two reasons, the former is the more substantial. To the trained expert who is less likely to err as regards the character of the sore, the time for beginning treatment is when its nature is no longer doubtful. In many instances this will be some time before the appearance of secondary symptoms. In cases, however, in which the least question exists, this should not be instituted until the doubt is dispelled by the advent of secondary manifestations.

If the poison of syphilis is bacterial,—and that it is, scarcely no one doubts,—it is not irrational to conclude that if mercury has an antidotal influence, the sooner it is given the better, as there is probably then a smaller bacterial army or a smaller quantity of bacterial products or toxins to overcome than at a later period.

There are two drugs which can be considered as the essential remedies in the management of the disease—mercury and potassium iodid, or its equivalent salt of sodium. Of these two, mercury is fully entitled to be looked upon as the specific one, and the one to be depended upon during the active or secondary stage of the malady, and also to constitute a necessary part of the treatment of the later or tertiary symptoms, although in the latter, whether appearing precociously or at the usual period, the value of potassium iodid is not to be underrated. While there is but little, if any, difference of opinion as to the value of mercury, especially in the early stages, there is a divergence as to the special form of the drug to be employed, and, to a less extent, as to the method of its administration. The

former, if the matter is judiciously investigated, is probably almost wholly the result of training and prejudice, for in reality any of the mercurial drugs capable of invoking physiologic action will prove of antidotal power against the disease. The choice is necessarily somewhat influenced by the plan of administration selected. The several methods of administration are by the mouth, inunction, and subcutaneous injection, each having its advocates, although by far the more usual plan is either by one of the first two named. As regards England and our own country at least, administration by the mouth is the rule, inunction, however, being often resorted to, and subcutaneous injection the least employed.

Administration by the mouth is, for ordinary purposes, a satisfactory method in average cases, and is the one most convenient to both patient and physician, and this will be first referred to. There is much more diversity in this method as to the particular mercurial to be employed than with the subcutaneous plan—as regards inunction there is naturally not much choice. My own preference, as, indeed, that of Taylor, White and Martin, Hyde and Montgomery, as well as many French physicians, is for the protiodid of mercury, and this is possibly in more general use than other preparations. It is to be given in dosage of $\frac{1}{8}$ to $\frac{3}{4}$ of a grain (0.008–0.05), in pill, capsule, or triturate form after each meal, and if it should, as it occasionally does, especially in the larger dosage, give rise to abdominal pain, griping, or diarrhea, a small quantity of opium, on an average about $\frac{1}{12}$ of a grain (0.0055), can be added to each pill. Opium is, however, to be avoided if possible, and a good plan in these cases is to prescribe the protiodid alone and give, if necessary, an occasional dose of paregoric; or two prescriptions for the tablets or pills can be given, one without opium, and one with, the latter only to be taken when the pain or griping demands it. Probably the most usual dose of the protiodid is $\frac{1}{4}$ of a grain (0.016), and it is only occasionally that troublesome pain is produced. Women stand less, as a rule, than men. Unless the case is urgent, the beginning dose should not exceed this latter quantity; this can be continued for four or five days, and, if an evident impression is made, can remain the same. Should, however, no effect be observed, and particularly if new lesions are appearing, the dose is to be increased every two days by $\frac{1}{16}$ to $\frac{1}{8}$ of a grain (0.004–0.008) until some influence is perceived, when the same dosage can be maintained. Or, if no benefit is noted, it is increased until evidences of physiologic action present; the dose is then to be lessened slightly, and continued at the reduced quantity. Occasionally the physiologic action shows itself somewhat suddenly, and not infrequently in quite a pronounced manner, and in such instances it is wise to discontinue entirely for one or two days, and then resume at the smaller dosage.

In severe and urgent cases of the disease it is well to begin with a larger dose,—$\frac{3}{8}$ to $\frac{1}{2}$ of a grain (0.024–0.035),—and increase daily by the addition of $\frac{1}{16}$ to $\frac{1}{8}$ of a grain (0.004–0.008) to each dose until slight physiologic effect is produced, and then reducing somewhat. The proof of such action is to be found, first of all, as well known, in the condition of the gums, such as slight soreness with swelling or

sponginess, especially adjoining the teeth, and a disposition to bleed easily; and even before any evidences are visible there is a tenderness noticeable upon the patient shutting the teeth together rapidly and with some force, and also fetor of the breath and a metallic taste; with these there is not infrequently slight, but scarcely noticeable, increase and possibly thickness of salivary secretion. It should not be pushed beyond the production of such evident physiologic, or, as might be termed, mildly toxic, action, nor this far if it can be avoided unless a prompt effect is, for reasons, especially desirable. As a measure against this accident thorough cleanliness of the teeth is to be maintained, and frequent rinsing with a potassium chlorate and tincture of myrrh wash. Indeed, if cleanliness of these parts is neglected, tartar and food allowed to collect and decay in the interspaces, tenderness and actual soreness and sponginess will result from smaller doses, which is a decided detriment in those urgent or severe cases where the fullest dose of the drug that can be satisfactorily borne is desirable. Under the administration of the mercurial the syphilitic eruption and other symptoms gradually abate, and, after a variable time, pass away; the anemia frequently noted gradually, and often rapidly, lessens, the patient usually increases in weight, and the mental depression often present gives way, and in most instances the patient's general health, in most cases impaired by the disease, seems reestablished. The disappearance of the manifestations of the secondary stage does not mean necessarily, however, that the malady is at end, for, especially if treatment is discontinued, there may be relapses and other symptoms later in the disease. The duration of administration should therefore be much longer, as will be later especially referred to.

In cases in which the protiodid gives rise to pain and griping, and in which the addition of an opiate is undesirable, gray powder—mercury with chalk (hydrargyrum cum creta)—can be substituted. This preparation is, in fact, preferred over all others by some observers, notably Hutchinson, and is also favored by Duhring and Crocker. The dose is 1 to 3 grains (0.065–0.2) or more after each meal, according to circumstances and the tolerance of the patient, the larger dosage often requiring the occasional administration of paregoric or the addition of 1 or 2 grains (0.065–0.133) of Dover's powder to each dose of the gray powder in order to control the resulting diarrhea. Other preparations which have support and which may likewise be prescribed with satisfactory effects are calomel, blue mass, corrosive sublimate, and red iodid—calomel in dose of 1 to 2 grains (0.065–0.133); blue mass, 1 to 3 grains (0.065–0.2); corrosive sublimate or red iodid, $\frac{1}{24}$ to $\frac{1}{8}$ grain (0.0027–0.008), after each meal. In the use of calomel or blue mass an addition of opiate is usually necessary to restrain the laxative action and to relieve the pain sometimes produced. Corrosive sublimate and the red iodid are rarely used in the secondary stage of the disease, but are the favorite preparations in the late stage, conjointly with potassium iodid; in the largest dosage indicated they sometimes give rise to gastric and intestinal irritation and diarrhea.

The *inunction method* of administering mercury, which found its greatest support under Sigmund, of Vienna, and very largely employed by Zeissl, Neumann, Mracek, Kaposi, and others of that school, as well as by other German physicians, is now one of the recognized methods. It has long been an accepted plan in some cases in English, French, and American practice. It permits more readily of the conjoint administration of tonics and potassium iodid by the mouth, if such should be indicated. It is an extremely valuable method, and one that can be satisfactorily employed in urgent cases. It is the plan to be adopted in those instances of obstinate syphilis occasionally encountered, and in which mercury by the mouth is often without material influence, or cannot, owing to gastric irritation or other reasons, be pushed to a dosage sufficient to bring about a result. Such cases are not common, but they are now and then met with, as well as, moreover, instances where the patient is exceedingly tolerant of the drug, not susceptible to ordinary mouth doses, and in which a result is obtained only by inunctions freely employed. Of this latter kind, I have met with 3 extreme examples of tertiary eruptions in which a cure was obtainable only by overwhelming doses—the drug being administered both by the mouth and inunction, with a disappearance of the lesions and absolutely no sign of toxic action. The same precautions as to cleanliness, etc., of the teeth and mouth should be taken with the inunction treatment as in the mouth method. There is a common belief that this method requires care as to the avoidance of taking cold, and the exercise of some judgment as to proper diet and other hygienic observances, but no more than with other methods of administration. The mercurial preparations which have been employed for this plan are the blue ointment (unguentum hydrargyri) and the oleate of mercury; the latter, which was urged as a clean substitute for the blue ointment, proved, however, inefficient and unreliable, and is no longer in use, the blue ointment now being solely employed. It should be freshly prepared, as it is quite probable that the local irritation it not infrequently produces is in many instances due to rancidity of the base and not necessarily always to the incorporated drug.

The amount of ointment required for one inunction is, on the average, about 1 dram (4.), although it is safer to begin with not over 30 or 40 grains (2.–2.65), the effect watched as to evidences of physiologic or toxic action, and the dose thus properly regulated. As a rule, except in those extremely susceptible to the drug, it can be safely increased up to 1 dram (4.), and in some cases more. An inunction is made once daily, intermitting if circumstances indicate; in private patients treated at home the inunction is most conveniently made at night. A general warm bath should precede; during the bath the part which is to receive the medication should be thoroughly washed, soap being used to remove the skin oiliness, so as to render absorption more complete. If a general bath is convenient or impossible, the part itself can be washed with soap and water. After rubbing dry, the ointment is to be rubbed in, and this is

done best by a nurse or professional rubber, although in most cases the private patient does it himself. The rubbing should be gentle but firm, and should last twenty to thirty minutes. Taylor states that after the general bath or local washing a 2 to 3 per cent. carbolic acid solution should be applied to the part, as, "by strict attention to the aseptic condition of the skin, dermal inflammatory complications can almost always be avoided." In order to lessen the chances of such accident the rubbing should never be upon the same part consecutively. The regions usually selected are where the skin is softer and thinner and less likely to be hairy, as the sides of the chest, inner aspects of the arms, and thighs; other parts in extremely sensitive skins can also be added, as the anterolateral surfaces of the abdomen, the lower part of the leg, the soles, etc. This gives six or more regions, and one should follow after the other, thus giving an interval of at least five days before the inunction is again made on the same part. The palm, fortunately, by which the rubbing is done, is not very readily irritated. The inunction treatment should be continued as in the mouth method until symptoms have disappeared, and repeated later on, or give place to another plan, as will be subsequently referred to. Old underwear of suitable thickness for the season of the year should be worn. The chief objections to this plan of treatment, in addition to the possible skin irritation, are the soiling of the wearing apparel next to the skin and the feeling of messiness engendered, and the trouble of its application.

Subcutaneous injections constitute another method of the introduction of mercury, the general trial or introduction of which was due to Lewin, and which is more or less practised at the present day by a few syphilographers as a practically exclusive plan, by others as occasional, and by still others, and by much the larger number, including myself, as an exceptional method.[1] It cannot be gainsaid that it is usually slightly more rapid in its action than mouth administration, but not materially superior, in this respect, to inunction. Its dosage can be accurately gauged, and the patient is kept more under direct control. Its painfulness, variable from trifling and of short duration to somewhat severe and prolonged; the fact that it necessitates the frequent personal attention of the physician; and the occasional painful induration and exceptional abscess formation resulting—are the disadvantages. It is a method to employ, however, when circumstances, either as to the patient or the gravity of the disease, demand prompt and effective action, and when the same cannot be secured by mouth administration or inunction; more especially when objection is made to the latter on the score of possible betrayal of the existence of the disease or when the eruption is of extensive and especially pustular character, making inunction impracticable.

[1] The status of this method is thoroughly discussed in the paper by J. William White, "The Present Position of the Hypodermatic Method in the Treatment of Syphilis," *University Med. Mag.*, Philada., June, 1893, and by Lawrence Wolff, "Status of the Hypodermic Use of Mercurials in the Treatment of Syphilis," *Trans. Philada. County Med. Soc'y for 1894.* Both publications present the published or communicated opinions of numerous syphilographers and dermatologists.

Of the several soluble mercurial preparations urged from time to time for this method—corrosive sublimate, succinamid, albuminate, carbolate, peptonate, bicyanid, iodo-tannate, benzoate, and a few others—the one which has the most support and in general use is corrosive sublimate; the dosage of this is $\frac{1}{12}$ to $\frac{3}{8}$ of a grain (0.005–0.024), $\frac{1}{8}$ of a grain (0.008) being an average dose. It is dissolved in sterilized water, so that 20 minims (1.35) will represent $\frac{1}{8}$ of a grain (0.008) of the drug. In fact, as great a dilution as convenient to inject, within reasonable limits, is best, as least likely to be disturbing. It is considered an advantage by some to add a minute quantity of sodium chlorid, tartaric acid, or sodium chlorid and ammonium chlorid conjointly, to such a solution, and others add a small portion of glycerin; upon the whole, however, the plain solution is in common use. A rubber syringe and good steel needle should be employed, and the injection made deeply and carefully into the subcutaneous tissue; if only into the derma, sloughing is apt to result. Injecting directly into a blood-vessel or vein should be guarded against. The points most commonly selected for the injection are the gluteal region, just behind the great trochanter and the subscapular regions. It is, however, often made on other parts, where some depth is possible. Great care should be taken that the solution, needle, syringe, and skin at the point of injection are thoroughly aseptic. It is well to have a number of needles, and if small items of expense are not to be considered, a good plan is to use a fresh one for each injection. The frequency and dose of the injection depend upon the effect, upon the eruption or other symptoms, and upon the physiologic or toxic evidence of the drug; once daily or every second day constitutes the average.

In more recent years subcutaneous injection of the insoluble mercurial salts[1] has been suggested and tried, with variable results, as compared to the soluble salts. Gray oil and calomel are the favorite preparations, the former being that in most common use. Other insoluble salts of mercury which have also been tried are the yellow oxid, black oxid, cinnabar, tannate, thymol acetate, and several others. The insoluble preparation undergoes gradual absorption, and the action is continuous for several days or longer. Calomel is administered in suspension in a mucilaginous vehicle, in glycerin and water, or in liquid vaselin, about 1 grain (0.065) at an injection, every three or four days, or a somewhat larger quantity at longer intervals. Besnier's formula, cited by White and Martin, consists of 1 part calomel to 20 parts vaselin; Lang's formula, of 65 grains (4.33) each of calomel and liquid vaselin and 60 grains (4) of lanolin; or it can be prescribed in 1-grain dose, in sodium chlorid solution (1 : 30). Gray oil (oleum cinereum) is most frequently prescribed, according to Lang's formula, of which an injection of 10 to 40 grains (0.65–2.65), an equivalent of 5 to 20 grains (0.33–1.33) of metallic mercury, is made weekly. These insoluble injections are, however, attended with greater and

[1] Some recent papers bearing upon the subject are by Milliet, *Annales*, 1894, p. 943; Thibiérge, *ibid.*, 1896, p. 162; Jullien, *ibid.*, p. 171; Portalier, *ibid.*, p. 299; Barthelemy, *ibid.*, p. 331; Klotz, *Med. News*, Apr. 29, 1905.

more disadvantages than those of soluble salts,[1] and are, in fact, upon the whole, no more efficient therapeutically, and are, therefore, to be reserved for the rare instances of grave type in which other plans seem ineffectual or too slow—an event, in my own experience, which has never yet occurred.

Fumigation, or *mercurial vapor-baths*, is a method of introducing mercury in the treatment of syphilis that was at one time quite frequently employed, but it is not much resorted to at the present day. It can be considered as a reserve plan, and could probably be advantageously used in the secondary papular or pustular eruptions, when a local as well as a constitutional influence was desired, with the object of promoting a more rapid disappearance of the cutaneous manifestations. As an occasional treatment, along with mouth administration, in obstinate cases and in those in which rheumatic or neuralgic pains are frequent or persistent, it is often of service. A special vaporizing lamp, both for water and the mercury, obtainable in the instrument shops, is necessary ; and an impermeable enveloping garment or one or two ordinary bed-coverings or blankets, to be closely adjusted around the neck to prevent damaging inhalation of the fumes. Calomel and cinnabar are the salts commonly employed—the former in average quantity of 1 dram (4.), and of the latter the same or a slightly larger amount. Taylor prefers a mixture of the two—20 grains (1.33) of calomel and 40 (2.65) of cinnabar. The vapor-bath, if the sole plan of treatment, is given every two or three days at first, and then daily or every other day, according to circumstances. It is best given in the evening, and not less than two hours after eating ; the duration should be about twenty to thirty minutes, and the patient can then, after cooling off some, retire enveloped in the garment employed during the bath, if it is not too moist. In a prolonged bath of this kind too much steam-vapor is not to be used, as the patient is often thereby weakened. The continuance and duration of this active plan of treatment, as with others, depend upon the obstinacy of the eruption and other symptoms.

Potassium iodid, or its equivalent salt of sodium, is an extremely valuable remedy in syphilis, but it is rarely needed in the secondary or active stages of the disease, in which mercury is with rare exceptions fully adequate to bring about a favorable result. It is often stated that the iodid should be given in secondary syphilis and take the place of mercury, when this latter is contraindicated or not well borne, but such instances, judging from dermatologic observation, are exceedingly rare and almost unknown, for while one plan of mercurial treatment might be found damaging to digestion, for instance, in mouth administration, another method can readily be substituted. It has also been alleged that mercury is not well borne in some cases of malignant syphilis, and therefore it is often advisable

[1] See interesting paper by Horwitz, "A Clinical Investigation to Determine the Value of Corrosive Sublimate and the Gray Oil Administered Hypodermically in the Treatment of Syphilis," *Therapeutic Gazette*, May 15, 1894, and by Garceau (sozoiodolate of mercury and reference to other soluble, as well as insoluble salts), *Jour. Cutan. Dis.*, 1906, pp. 261 and 323.

Injection of "gray oil" is apparently not without danger—see article by Claude and Dobrovici, "Cinq case de mort a la suite d'injections d'huile grise," *Annales mal. vén.*, 1906, p. 96.

to suspend its use, but even in such instances, if properly and judiciously administered, along with the conjoint treatment by iron, strychnin, minute doses of arsenic, cod-liver oil, and other remedies, as may be indicated, its omission or discontinuance is usually unnecessary. Profound anemia, which is often the troublesome symptom in these cases, needs more than mercury to promote the rebound or even to stop the downward trend, and it is, I believe, the failure to recognize this fact or an unsuitable method of administration that has given rise to the view that the mercury may be doing harm. It is true, however, that in extremely rare instances the temporary discontinuance of this drug may be deemed wise, or at least tried, and to the treatment, consisting of tonics and nutrients, small or moderate doses of the iodids be for a time given in its place. A comparatively few physicians are, however, inclined to give the iodids a more prominent place in the active stages, although, with rare exceptions, all of large experience have recourse to them at this period only when precocious tertiary symptoms present, such as persistent rheumatic pains, periostitis, gummata, destructive ulceration, troublesome cephalalgia and other evidences of more or less serious involvement of the nervous system.

Its conjoint administration in moderate dosage is sometimes adopted toward the end of the first year by some as a routine method, but, as a rule, mercury is to be the recourse throughout, if tertiary or other serious manifestations do not suggest its earlier use. It is especially in the later manifestations, such as the tubercular and gummatous and other tertiary evidences, that the iodid is extremely valuable, and under the administration of which symptoms often disappear in a comparatively short time as if by magic. But while it has this power, it does not, in the judgment of many, including myself, seem to have the same influence in preventing recurrences, or, in short, of extinguishing the syphilitic poison, as does mercury, and the latter, therefore, is almost invariably associated, constituting the well-known "mixed treatment." Corrosive sublimate and the red iodid of mercury are the mercurials used most frequently with potassium iodid, the latter, I believe, deserving the preference. The two drugs are commonly ordered conjointly in mixture, with mint-water, cinnamon-water, compound tincture of cardamom, gentian, wine of coca, or the compound syrup of sarsaparilla as the vehicle. This last has long been a favorite, owing to the erroneous or scantily founded belief that it has itself some influence, but its syrupy character has often seemed to me to be responsible for the nausea and gastric uneasiness attributed to the iodid, although the latter is in many instances the exciting cause. I have found that the sodium iodid is much less likely to disagree than the potassium salt, and for that reason frequently prescribe it in preference, although in the same dosage it is not quite so efficient as the potassium salt. With the other iodid salts—ammonium iodid, rubidium iodid, strontium iodid, and lithium iodid—occasionally suggested as substitutes for the potassium and sodium salts I have had no experience, although it is generally admitted that they are not comparable to the two in common use. Not infrequently the iodid is prescribed as a saturated aqueous solution, 1 minim being equivalent to 1 grain (0.065), and the dose can thus be

conveniently increased drop by drop if necessary; it is taken diluted with water or milk, and the mercurial, if advised also, separately in pill, solution, or by inunction. When separately administered as pill or tablet, the mercurial can, as in the earlier stages of the disease, be prescribed as the protiodid, although for this plan also the biniodid or corrosive sublimate is frequently preferred, especially the former, as less liable to give rise to gastric or intestinal irritation or to the other toxic symptoms.

The dose of the iodid of potassium or sodium required is variable —in some cases not requiring urgency it is, as a rule, not necessary to exceed 10 grains (0.65) three times daily, and frequently 5-grain doses (0.33) will suffice; and, indeed, in some cases of the late tubercular syphilid the eruption will rapidly disappear under smaller dosage, as 1 or 2 grains three or four times daily, a fact to which Hartzell[1] has recently called attention. As a rule, however, the drug must be given in moderate doses, and very often the quantity is gradually increased up to 20 or 30 grains (1.33–2.) or more at the dose, and occasionally the total daily amount reached before improvement sets in will be 6 to 8 drams (24.–32.) or more, as sometimes observed, and as I myself have noted in occasional instances.[2] These large doses are, however, only rarely necessary in the management of cutaneous lesions, being sometimes required if the destruction is rapid and threatening, or if indicated by grave concomitant symptoms. In such instances the beginning dose should be moderately large—20 to 30 grains—and rapidly increased. In exceptional instances, however, it is found that the case does not yield so readily to the increase of the iodids as it will to increase in the mercurial, and it is in such that the iodid of potassium or sodium can be given by the mouth and the mercury advantageously by inunction. In rare instances of the late tubercular and gummatous manifestations the iodid, even when increased to extremely large doses, fails utterly to remove the eruption, but, fortunately, such cases are so exceptional that the value of the so-called "therapeutic test" in doubtful cases of suspected late syphilitic eruptions is not materially lessened. In such instances the discontinuance of the drug is advisable; the institution of vigorous mercurial treatment, especially by inunction or hypodermic injections, will usually have a prompt effect.

Sometimes even moderate doses of the iodid salt give rise to such distressing symptoms of iodism that it cannot be increased, and occasionally must be discontinued. One or two drops of belladonna tincture with each dose will sometimes lessen the severity of such symptoms, and administration of small doses of arsenic or potassium bitartrate occasionally seems to exert some control. The belief that the iodid eruption—iodid acne, for instance—and other symptoms of iodism do not arise when the drug is administered for syphilis, and that if they do, it indicates an erroneous diagnosis, is absolutely without basis, as such symptoms arise just as often in a given number of syphilis cases as in the same number of cases of other diseases for

[1] Hartzell, "Some Practical Points in the Treatment of Late Cutaneous Syphilis," *Therapeutic Gazette*, May 16, 1898.

[2] Stelwagon, "A Case of Late Cutaneous Syphilis, Illustrating the Occasional Necessity of Large Doses of Potassium Iodid," *Philadelphia Med. News*, June 27, 1885.

which it may be administered, as shown by J. William White,[1] myself,[2] and others.

Other alleged specific remedies for syphilis lauded from time to time, more commonly proprietary in character, such as the various vegetable remedies, which need not be enumerated, gold chlorid, opium, decoctions, etc., have made no permanent impression, and their supposed effects have mostly been based upon their use in the secondary stage of the disease, when nature alone is, in reality, when properly guided or supported by suitable hygiene, often amply sufficient to bring the eruption and other symptoms to a favorable termination. Not infrequently some of the vaunted mixtures or decoctions contain variable quantities of the two specific drugs, or their addition advised! Indeed, outside of the general management of the disease, or rather the individual who has the disease, by proper living, tonics, etc., when necessary, but two remedies—those already named, the mercurials and iodid of potassium—can be said to exert a special influence against the syphilitic poison. Doubtless remedies having diaphoretic and diuretic properties and promotive of proper action of the bowels do have some influence in hastening the elimination of the syphilitic virus, but such are often attainable by the observance of ordinary rules of hygiene. In this way balneotherapy—warm or hot baths—is doubtless of some service,[3] but, if advisable, it is not necessary that patients go to "hot springs" for bathing purposes, for tub- and vapor-baths at home will answer the same end, provided patients will give the same attention to diet, temperate living, etc., as they willingly follow at the "springs," and, if so, then the statement made by Taylor, "take away the mercurial ointment and iodid of potassium from any thermal spring, and its business will soon close up for want of patronage," is a simple, but strong, expression of the truth. There are, however, patients who are not docile at home, who eat too much, "drink" too much, and smoke too much, and who do not follow up carefully the advice given, and for such the thermal spring, with its strict regimen, moral living, and the incidental change of scene, and the usually rigorous treatment, is a resort sometimes to be professionally advised. The serum treatment, which, in its various phases or modifications, has, quoting from White and Martin, recently received the attention of Bonaduce, Tommasoli, Gilbert, Fournier, Cotterell, and others, is still in the experimental stage, and therefore a definite opinion as to its value must as yet remain in abeyance.

Duration of Treatment.—While there is but little divergence of views as to the remedies to be prescribed in syphilis, there is some difference as to the general plan and duration. It may be said that

[1] J. William White, "Contributions to the Discussion of the Diagnostic Value of the Tolerance of the Iodids in Syphilis," *Therapeutic Gazette*, March 15, 1889 (presenting communicated opinions from a number of eminent syphilographers and neurologists); and "Valeur diagnostique de la tolérance des iodures dans la syphilis," *Union Médicale*, 1889, pp. 628 and 639.

[2] Stelwagon, "On the Alleged Tolerance of the Iodids in Late Syphilis," *Therapeutic Gazette*, Oct. 15, 1889.

[3] Interesting papers on the subject are contributed by Bogart, *Brooklyn Med. Jour.*, Dec., 1895, and Neisser, *Berlin. klin. Wochenschr.*, 1897, No. 16; and Baum, *Medicine*, 1896, p. 253.

all agree in treating the active manifestations of the early stages with a mercurial course, which is to be more or less vigorously pushed, within safe limits, until after these symptoms have disappeared and the patient is free from evidences of the disease. Excepting possibly a variable degree of adenopathy, this end is quite frequently attained three or four months or even less after beginning the treatment, and some syphilographers then discontinue the specific remedy —mercury—until symptoms of one kind or other again present, and then put the patient under another active course of the drug, extending a few weeks beyond their disappearance, and so on as long as recurring evidences show themselves. Should any symptoms arise pointing to the use of potassium iodid, this drug is also temporarily administered. Others follow this, and between the mercurial courses give moderate doses of the iodid. Others again, after active evidences have subsided, continue the mercurial remedy, but in small dosage—about one-third of the daily quantity given during the active treatment,—instead of three doses daily, one dose only being given, the usual more frequent dosage being resumed should symptoms present themselves. When inunction or the hypodermic plan is employed, after subsidence of the manifestations the drug is either continued by the mouth, in one dose daily in the interim, or the method is discontinued and then again resumed on presentation of new symptoms, or systematically at intervals of two or three months, a course of four to six weeks being given each time.

My own plan, which is usually by mouth administration, is to give the drug in more or less active dosage, according to the urgency of the individual case, until one or two months after all manifestations (cutaneous or other) have disappeared, and then continued as a small daily dose—about one-third or one-fourth the daily quantity prescribed during the active treatment—for a period of about two or three months, and then another cycle of the same dosage as in the beginning for four to six weeks, a resumption of the smaller daily dose for another interim of two or three months, and so on for a period of at least two years. This plan is somewhat modified by recurring symptoms, which, if during the interim dosage, gives place again immediately to active treatment. If no symptoms have presented during the final eight or nine months of the second year, treatment is wholly discontinued, although I always advise subsequently, as a matter of precaution, a resumption of the interim dosage for four to six weeks every four or five months for another year. During the latter part of the second year, and subsequently if any symptoms arise, and sometimes at an earlier period, when indicated by precocious tertiary or other symptoms, potassium iodid can be conjointly prescribed. The value of prolonged treatment in extinguishing the disease and lessening the possibility of manifestations in later years cannot, I believe, be too much emphasized, and on this point those having much experience in its treatment are agreed, but differ somewhat on the question of intermittent or uninterrupted administration.

Probably sufficient has been said as to the treatment of *tertiary manifestations* in discussing the iodid salts. The cases coming der-

matologically under observation are chiefly those of limited tubercular eruptions or gummatous lesions, sometimes several to five, ten, or more years after the disease was contracted. The treatment of these and other tertiary or late manifestations consists in the conjoint administration of the iodid and the bichlorid or biniodid of mercury, 5 or more grains (0.33) of the former and $\frac{1}{32}$ (0.002) to $\frac{1}{12}$ (0.006) or more of the mercurial, in any suitable vehicle three times daily; if rebellious, increasing the dose of the potassium or sodium iodid salt, if well borne, up to 2 drams (8.), and then if, as exceptionally occurs, there is no result, giving the patient an active mercurial course, either by stomach, inunction, or hypodermic injection. The inunction plan often acts very satisfactorily in such cases. The treatment in these late manifestations is to be continued actively for one or two months after the disappearance of the symptoms; the iodid is then omitted, and the usual daily dose of the mercurial continued for six weeks to two months, and again resumed once or twice at intervals of three or four months. If the symptoms had been of an urgent character, the subsequent employing of one or two short courses by inunction at the above intervals is to be advised.

External Treatment.—In the majority of cases of the secondary cutaneous manifestations no local applications are called for, but in severe types of the papular eruption, and also in the pustular syphilodermata, baths of corrosive sublimate, $\frac{1}{2}$ to 3 or 4 drams (2.–12. or 16.) to 30 gallons of warm water, can be employed, the patient remaining in the bath for five to fifteen minutes. When the surface shows a good number of abraded lesions, absorption is likely to take place, and the smaller quantities should be used. This bath method was formerly occasionally employed as a plan of treatment for the introduction of mercury, but it was found, except under the condition just noted, that absorption practically did not take place, or at least was uncertain. As the patient is at the same time taking the remedy by the mouth or by one of the other methods, the possibility of such absorption is, however, to be kept in mind, so as to guard against toxic action. A much better plan of medicating the general surface is by the mercurial vapor-bath, but this is not always practicable. Very often the surface in such cases can with advantage be sponged with a saturated solution of boric acid, containing 1 to 2 drams (4.–8.) of carbolic acid to the pint, with or without the addition of 2 to 4 grains (0.135–0.265) of corrosive sublimate. Or this lotion can be applied to the covered surface, and an ointment applied to the lesions on exposed regions, such as one of ammoniated mercury, 20 to 60 grains (1.35–4.) to the ounce (32.); one of oleate of mercury, 5 to 10 per cent. strength; mercurial plaster, full strength or weakened with lard or petrolatum; blue ointment, full strength or weakened; a 2 to 20 per cent. ointment of iodol; resorcin, 20 to 60 grains to the ounce (32.). The selected ointment is gently rubbed on the spots twice daily, or it may be, when possible, as when in the house, applied spread upon lint as a plaster. The base used can be made of equal parts of lard and petrolatum, with some stiffening, as cerate or wax, if it is to be applied as a plaster. For exposed situations, the most elegant, as well as most cleanly, is the ointment con-

taining ammoniated mercury, and this often acts satisfactorily, but in the event of its making no positive impression, one of the others can be tried. In the larger pustular lesions, especially when exhibiting an ulcerative tendency of the base, the crust can be softened and removed, the surface cleansed with mild antiseptic lotions, such as the above, and an ointment spread upon lint and applied, changing once or twice daily, according to circumstances.

In the late or limited syphilodermata, the same applications are, when necessary, resorted to, the ammoniated mercury ointment, the oleate of mercury, the blue ointment, and the mercurial plaster, full strength or weakened, are the most satisfactory. The ulcerating lesions can be cleansed first, an antiseptic lotion dabbed on, and an ointment applied as a plaster. One of the above lotions can be employed, or, and especially in offensive ulcerations, one slightly modified can be substituted, containing 2 to 6 grains (0.135–0.4) of corrosive sublimate, 10 to 20 grains (0.65–1.35) of carbolic acid, 4 drams (16.) of alcohol, ½ to 1 dram (2.–4.) of glycerin, and water to make 4 ounces (128.). Occasional cleansing with a weak hydrogen peroxid solution is often of advantage. Iodol may also be applied to ulcers as a dusting-powder, usually mixed with one to several parts of boric acid or zinc oxid. In sluggish ulcerations the healing process can often be advantageously started, as Zeisler[1] has especially emphasized, by a light cauterization with silver nitrate, and in rebellious cases, if necessary, by a preliminary curetting. The *palmar and plantar syphiloderm*, occasionally observed both in the late secondary and later periods, is treated by the various ointments already referred to, but when there is much thickening this is first to be removed by the continuous application, for one or two days or longer, of a 10 to 25 per cent. salicylic acid plaster; frequently it is necessary to repeat this from time to time; vigorous constitutional treatment conjoined with active local measures is usually required in these cases.

To the papules, often moist and fissured, sometimes found at the angles of the mouth in the secondary period, one of the several ointments can be gently rubbed or smeared on two or three times daily, or they can be painted over, once or twice at one time, with tincture of benzoin containing ¼ to 1 grain (0.018–0.065) of corrosive sublimate to 2 drams (8.), and repeated night and morning. *Moist papules* on other regions, as about the anus and genitalia, often disappear upon the institution of rigorous cleanliness, washing the parts twice or more daily with tepid water and small quantity of soap, rinsing, and tapping dry with absorbent cotton, and dusting on the iodol-boric acid powder noted above, or a powder of one or two parts calomel to the ounce (32.) of boric acid or zinc oxid powder; or in obstinate lesions pure calomel powder alone can be applied. In the latter cases the preliminary use of one of the mild lotions already named can be advantageously used before the powder is applied. Ointments such as named are sometimes advised, but, as a rule, they are not well borne, and the above dry methods are much superior, and along with the constitu-

[1] Zeisler, "The Importance of Local Treatment in Syphilis," *Jour. Amer. Med. Assoc.*, Mch. 16, 1889 (with references).

tional treatment suffice. Very obstinate lesions can be occasionally painted with a 5 to 10 per cent. solution of silver nitrate. These same plans are alike applicable to the hypertrophic warty and vegetating papules. For the *mucous patches* in the mouth absolute cleanliness of this cavity and of the teeth is a measure of usefulness. For this purpose frequent cleansing with the ordinary potassium chlorate and tincture of myrrh or similar mouth-washes or gargles can be employed. Any roughened teeth are to be smoothed down, and smoking prohibited, as well as the ingestion of very hot or acid or other foods which seem to irritate. Sometimes, under such measures, and as the result of constitutional medication, the mucous patch will disappear. In all cases, however, their disappearance can be promoted by touching with the silver nitrate stick, and if no change is observed in two or three days, the application is to be repeated. In sensitive subjects or slight cases a 5 to 10 per cent. solution will answer the purpose. In other cases touching carefully with a minute quantity of lactic acid, nitric acid, or acid nitrate of mercury is sometimes necessary, rinsing the mouth afterward.

The nail affections—onychia, paronychia—sometimes observed require, in addition to the active constitutional treatment, rigorous cleanliness, and the application of mild antiseptic lotions, such as already named, and the enveloping of the part in a mild mercurial ointment, redressing twice daily; when loose, the nail is to be removed. Falling of the hair is managed in the same manner as described in other cases independent of this malady (see alopecia); the hair usually regrows as the general constitutional disease abates.

Treatment of Hereditary Syphilis.—The constitutional treatment of hereditary syphilis is essentially that of the acquired disease in adults, with modifications as to dosage and method. It is understood that if opportunity is afforded in a suspected syphilitic pregnancy that the mother should be vigorously treated with mercurials during this period, as in this way a healthy or seemingly healthy birth will result, or the child will exhibit the disease in a milder phase. In a child born of syphilitic parents and not showing specific symptoms treatment should not be instituted until evidence of inherited disease appears, as it may have wholly escaped infection; to this, however, the exception should be made with children born during a recent syphilis in the mother, especially if it has been untreated. The condition of the general nutrition should be carefully looked after, however, so if the disease does exist, there will be a better chance to subdue its symptoms when they present. In fact, the nourishment of the child in all cases of inherited syphilis, whether the evidences are present at birth or show themselves later, is of greatest importance. The best method of introducing mercury in these cases is by inunction, but the ordinary mercurial ointment should be weakened with 2 or 3 parts of vaselin or cold cream, according to the age of the child; about ½ to 1 dram (2.–4.) of this is spread upon a binder on the part which goes over the abdomen. The surface should have a preliminary washing with a mild soap and water, and, to lessen the chances of irritation, Taylor advises the application of a lotion of boric acid, after which the ointment is bound on. From time

to time, in order to avoid irritation, the ointment can be applied to the back instead of anteriorly. The dressing is to remain on twenty-four hours, the motions of the child serving to rub it in; the binder is then removed, and the washing, etc., gone through with again, fresh ointment gently rubbed in, and the same binder applied, and so the treatment is continued, a fresh binder being substituted every few days. In spite of precautions and care, however, the parts often become irritated, and this plan must give way, temporarily at least, to inunctions gently rubbed on other parts, as with the adult. Under the mild lotions and dusting-powders, such as are employed in erythema intertrigo and acute eczema, the irritation soon subsides.

In some cases of extreme sensitiveness of the skin the inunction method becomes impracticable, and in such instances, and in others where seemingly preferable, treatment by the mouth can be tried. The most satisfactory preparation for this purpose is the gray powder, which can be administered as a powder with sugar of milk in dosage of $\frac{1}{12}$ to 1 grain (0.006–0.065) three times daily after nursing, the dose depending upon the age and effect, the larger doses not infrequently proving too laxative. Jacobi and others prescribe in preference minute doses of calomel, about $\frac{1}{20}$ of a grain (0.0032) three or four times daily. The drug is also sometimes prescribed as corrosive sublimate in solution, $\frac{1}{2}$ grain (0.033) to 6 ounces (192.) of water, of which the dose is one or two teaspoonfuls. In some cases the laxative effect of the mercurial is to be counteracted by the administration of compound chalk powder or other mild astringent. Treatment by corrosive sublimate baths (10 to 30 grains (0.65–2.) to a bath of 8 or 10 gallons) is at times a serviceable method much more frequently employed formerly than at the present day. It is not, however, so certain a plan as those already mentioned. The bath should be warm and the patient remain in for five to ten minutes. Potassium iodid is sometimes prescribed in place of the mercurial, but if deemed advisable, their conjoint administration is preferable; the dose of the iodid ordinarily varying from $\frac{1}{4}$ of a grain to 2 or 3 grains (0.017–0.2) three times daily. Older children can tolerate larger doses. In addition to the specific treatment, cod-liver oil and the iron preparations are sometimes demanded; of the latter, the syrup of the iodid being the most feasible. The duration of active medication depends upon the continued presence of symptoms or recurring evidences of the disease; the patient should be under observation and more or less treatment for a prolonged period, as advised in the acquired disease in adults. Horwitz advises that the child undergo four to six weeks' treatment every year until it reaches the age of puberty.

The external treatment of the lesions of hereditary syphilis is practically the same as in the adult already described. The erythematous or erythematomacular condition sometimes observed about the genitocrural region and the buttocks requires, as a rule, no special application, but mild dusting-powder or lotions can be prescribed with advantage, and especially in cases which may be complicated with a true erythema or eczema intertrigo. The blebs of the bullous syph-

ilid, if distended, should be opened, the contents pressed gently out, and the parts cleansed and dressed with a dusting-powder of boric acid and zinc oxid. Mouth lesions and moist papules about the anus and genitalia usually require attention, similar to that in adults.

ORIENTAL SORE.[1]

Synonyms.—Delhi boil; Delhi sore; Oriental boil; Kandahar sore; Pendjeh sore; Natal sore; Aleppo boil; Biskra button; Gassa button; Puru; etc. *Fr.*, Bouton d'Alep; Clou de Biskra; *Ger.* Orientbeule; Beule von Aleppo.

Definition.—A specific granuloma of the skin, endemic within certain limited areas in warm countries; characterized primarily by a papule, gradually enlarging by peripheral and subjacent infiltration, with scaling or crusting, and which usually, sometimes with an intervening furunculoid stage, slowly breaks down and develops into an indolent ulcer.

It is difficult to give an inclusive definition of this malady, if all the various cases reported and described as such are true examples of it. The differences can only be explained on the assumption of the influence of environment, nutrition, hygienic conditions, and individual resisting power. Errors in diagnosis are doubtless responsible for some of the discrepancies.

Symptoms and Character.—There is a quiescent inoculation period of from three days to one or more months. The lesion appears as an itchy red papule. It gradually increases to the size of a pea or small grape, usually flattened, becoming hard and more vascular. It tends to become scaly, more especially in the central portion where it later generally shows a crust formation with sometimes slight depression. If the crust falls off or is scratched off, a shallow erosion or ulcer is disclosed. From the central necrotic portion there may be some serous oozing, changing to a seropurulent character. It is chiefly of this that the crust is composed. It may continue in this manner, and after a long while, commonly some months, with usually an intervening ulcer formation, gradually heal and disappear; or it may become distinctly furunculoid, gradually break down, discharge, and develop into an ulcer. While a rather distinct, sharply cut, indolent ulcer is a common termination, which

[1] Valuable literature: Murray, *Trans. Epidemiological Soc.*, London, vol. ii., 1882–83, p. 90 (with illustrations); Altounyan, *Jour. Cutan. Dis.*, 1885, pp. 161 and 173; Riehl, *Archiv*, 1886, p. 805; Hirsch, *Handbook of Geographic and Historic Pathology*, Sydenham Soc. ed., vol. iii., 1886, pp. 668–683, with bibliography almost complete to 1884; Riehl and Paltauf, *Archiv*, 1886, vol. xiii., p. 805, etiology and anatomy, with review of previous investigations; Leloir and Vidal, *Traité descrip. des mal. de la peau*, first and second parts, 1890, 1891; Matas, Morrow's *System*, vol. iii., (Dermatology), p. 708; Auché and Le Dantec, *Archiv Clin. de Bordeaux*, Oct. 1894—abs. *Brit. Jour. Derm.*, 1895, p. 98 (bacteriologic, with review of other findings); Unna, Histopathology (with pathologic references); J. H. Wright, *Jour. Med. Research*, 1903, p. 472; and *Jour. Cutan. Dis.*, 1904, p. 1 (bacteriologic, with illustrations); Cox, *Indian Med. Gaz.*, 1904, p. 56 (clinical); Marzinowsky and Bogrow, *Virchow's Archiv f. Path. Anat.*, 1904, vol. clxxviii., p. 112 (etiology); Mesnil, Nicolle, and Remlinger, *Compt. rend. Soc. de Biol.*, 1904, lviii., p. 167 (bacteriologic); James, *Scientific Memoirs by Officers of the Medical and Sanitary Department of the Government of India*, Calcutta, 1905, New Series, No. 13 (chiefly bacteriologic); Malméjac *Echo méd. du Nord*, 1905, p. 103 (treatment); Strong, *Philippine Jour. Sci.*, Manila, 1906, p. 91 (a good résumé of bacteriologic findings, with references).

finally heals and leaves a pronounced scar, the growth may continue as a scaly or crusted nodule, and eventually disappear by desiccation exfoliation, and absorption, with insignificant scar or atrophic mark. It is not unusual for the "sore" to consist primarily of two, three, or more closely aggregated papules, which, as they grow, become solidly crowded or coalescent; the further development being as already described, although occasionally in this coalescent "sore" there is, as less frequently, also, in the single lesion sore, a tendency to fungoidal granulations. On an average a fully developed Oriental sore is an inch or so in diameter. While there is often but one, there may be several or more distinct and sometimes quite widely separated formations. An Oriental sore, when developed, is of a dull red color, is usually of sluggish nature throughout its course, unless constantly knocked, irritated, or having added an active pyogenic factor, when it may become much more inflammatory, and quite tender and painful. The favorite regions are the face, hands and forearms, and legs, but no part is exempt.

The ulcer, as remarked, is usually rather sharply cut, frequently oblong and irregular in shape, with commonly some elevation and infiltration of the surrounding border; the latter may or may not be undermined. It may discharge but slightly, so that it is continually covered with an adherent dry scab; or it is forever discharging abundantly a pale yellow, watery pus, which adds to the discomfort of the patient. After attaining a variable size the ulcer may remain stationary for some time before the reparative process begins. In some cases, however, the ulcer continues to extend, and may finally involve an area of several inches or more, and persist; such instances doubtless furnishing some of the examples of so-called "endemic ulcer," "tropical ulcer," etc. As a rule, however, after a variable period, of from two or three months to a year or more, healing, sometimes more or less interrupted, sets in; and this may be effected under the crust. In some cases the ulcer is still extending peripherally whilst healing is progressing centrally. As intimated, the character of the scar varies; it may be slight or almost nil in some instances, whilst in others, more particularly when about the face and joints, be extremely pronounced and disfiguring, and if contraction occurs can give rise to considerable deformity. In fact, the character, features, course, and cicatrix of the malady show wide variations.[1] There is

[1] A few examples of this variation, especially as to its clinical characters: James (*loc. cit.*) says "the appearances of some true Oriental or Delhi sores are by no means as characteristic as one would expect from the description given in books, and I found that civil surgeons whose experience of the disease was considerable, were often unwilling to express a definite opinion as to whether a given sore was really an Oriental sore or whether it was an example of the ordinary chronic ulcers so common among natives of India. When I say that the first examples of an Oriental sore seen by me in Delhi appeared, at a superficial examination, to be more like a ringworm than anything else, and that I at first considered another Oriental sore to be an ordinary "shoe-bite," it will be apparent that I have felt a similar difficulty in diagnosis." Malcolm Morris (*Derm. Soc'y Trans., Brit. Jour. Derm.*, 1902, p. 130, case demonstration of officer in India medical service with Delhi boils on the arms), stated: "The lesions were in no sense of the word boils, but rather resembled the verrucous forms of lupus of the extremities. Each lesion was about as large as a shilling, and showed a raised, reddish, infiltrated swelling of fairly firm consistence, over which the epidermis was thickened and warty. There were no signs of ulceration or necrosis, which the patient, who was very familiar with the disease, averred to be a later stage of the process."

no systemic involvement, but occasionally the usual accidental complications of such ulcerative processes are noted, such as lymphangitis, erysipelas, and the like.

Etiology and Pathology.—The disease is limited to certain tropical countries, as the various names imply, but it is occasionally met with elsewhere in travelers or immigrants from infected districts, one such instance coming under my own notice. The malady is contagious, inoculable, and autoinoculable; it is doubtless due to inoculation through the media of infected laundry and other clothing and water, breaks in the continuity of the skin being predisposing. Insects are also probable carriers of the infection. It is thought that a poor condition of the general health makes one more liable. In fact, some writers have considered the malady of malarial origin. It is much more prevalent in the autumn months. No age is exempt, but it is much more common in childhood and adolescence and it is rare after forty-five. It is met with in both sexes and in those of all nationalities. One attack seemingly furnishes comparative immunity.

The lesion is admittedly the result of infection by some microörganism, and a number of investigators (among whom Laveran, Duclaux, Heydenreich, Riehl and Paltauf, Leloir, Chantemesse, Wright, James, Strong, and others) have been sanguine as to the import of their individual findings—variously, micrococci, streptococci, staphylococci, and protozoa, or protozoa-like organisms resembling the Leishman-Donovan bodies of tropical splenomegaly. These last (Wright, James, confirmed by Mesnil, Nicolle, and Remlinger), also bear similarity to the organisms found by Cunningham, Firth, Marzinowsky, and Bogrow.[1] As yet, however, it may be said that the matter is not definitely settled.

Microscopic examinations of the tissue of Oriental sore show that it is a reaction of the skin against some virus of low virulence which has produced granulation changes in the corium beneath and around the ulcer (Macleod). The deposit of a tumor-like formation of granulomatous tissue is the first and essential condition; the new tissue infiltrate destroys and replaces all the structures of the true skin, and pressing upon the epidermis causes it to atrophy and disappear, so that an ulcer results (James). In a number of sections examined by Elliot, he found the disease confined to the epidermis and corium extending through to the subcutaneous tissue, with a distinct line of separation between the diseased portion and the surrounding tissue; the area of disease seemed composed almost entirely of small, round, inflammatory or formative cells and epithelial elements, and with no evidence of the disease beginning in the glandular structures. Riehl found giant-cells present quite frequently. Unna looks upon it as a chronic sero-fibrinous inflammation of the whole cutis leading to central necrosis, softening, and ulceration.

[1] Strong (*loc. cit.*) believes the organisms found by him to be a form of blastomyces, and that they seem similar to the bodies which have been found in ulceration of the skin occurring in horses in the tropics suffering from blastomycetic infection, and that these two diseases are probably identical, or at least closely related species.

Diagnosis.—Its origin in and limitation to endemic districts, its site, its beginning as an itchy papule, its growth into a desquamating and crusted nodule, usually followed by ulceration, considered together with its slow development and noninvolvement of the general health, are sufficiently characteristic for many of the cases. One could readily imagine, however, how, especially in its early beginning, it might be mistaken for several other affections, such as ecthyma, the primary lesion or patch of frambesia, lupus, and other scrofulodermata, syphilis, and the like.

Prognosis and Treatment.—Recovery always takes place, usually after some months; but how much is due to the treatment or to the natural course of the disease is difficult to say. Cleanliness is all-important, and this, together with protection and possibly mild soothing applications, is about all that many advise. By some, complete excision, cauterization, and the actual cautery (Murray) are variously recommended for discrete lesions; the milder antiseptics are subsequently used. Painting the beginning lesions with iodin tincture is commended (Hickman, Altounyan), and also mercurial applications (Brocq, Vidal, Bard). Gaucher and Bernard obtained rapid results from daily spraying (ten minutes) with boiled water, and the constant application of compresses of the same; Malméjac strongly commends a somewhat similar treatment: forcible spraying (150 to 200 c.c.) of the sore with boiled distilled water at a high temperature twice daily for eight days, and then once daily, and compresses of dry aseptic gauze. Large doses of quinin and arsenic are said (Besnier, Rankin) to have a favorable influence in promoting the healing of the ulcers.

FRAMBESIA.[1]

Synonyms.—Yaws; Pian; Polypapilloma tropicum; Tonga; Amboyna button; Parangi; *Fr.*, Pian; *Ger.*, Beerschwamm.

[1] Literature: J. Numa Rat, *Yaws: Its Nature and Treatment*, London, 1891 (with bibliography to 1887); review and résumé of the same by Malcolm Morris, in *Brit. Jour. Derm.*, 1892, p. 63; Beaven Rake, "Postmortem Appearances in Cases of Yaws," *ibid.*, 1892, p. 371; Breda, "Beitrag zum klinischen und bacteriologischen Studium der brasilianischen Frambœsia oder Boubas," *Archiv*, 1895, vol. xxxiii., p. 3 (2 colored plates of the disease, and 2 plates with histologic cuts; unsuccessful experimental animal inoculations; literature references); Pierez, "Frambœsia," *Trans. First Pan-American Med. Cong.*, Washington, 1895, part ii., p. 1764 (an elaborate paper); Daniels, "The Non-Identity of Yaw and Syphilis," *Brit. Jour. Derm.*, 1896, p. 426; Powell, "Yaws in India," *ibid.*, p. 457 (a clear presentation of the subject in all its aspects); Hirsch, *Handbook of Geographic and Historic Pathology*, Syd. Soc. ed., vol. ii., p. 110 (with bibliography); Dyer's paper in Morrow's *System*, vol. iii. (Dermatology), p. 687, gives a good account with bibliography. Scheube, *Die Krankheiten der warmen Länder*, 2d edit., 1900; Kynsey, *Brit. Med. Jour.*, 1901, ii., p. 802 (differentiation from syphilis). Nicholls, *Gov't Rep. on Yaws in West Indies*, 1894 (with colored illustrations), condensed critical report of this by Wallbridge and Daniels, in New Sydenham Soc'y vol. for 1897; Manson's *Tropical Diseases* 3d edit., 1903; Dalziel, *Jour. Trop. Med.*, 1904, p. 288 (occurrence and probable origin in South China); R. Koch, *Archiv*, vol. lix., 1902, p. 5 (with case illustrations); J. Numa Rat, *Jour. Trop. Med.*, 1904, p. 86 (its introduction in Auguilla in 1902), and *Select Colonial Med. Reports*, 1904, p. 177, and *Jour. Trop. Med.*, 1904, p. 317 (alkaline treatment); Modder, *ibid.*, p. 213 (bacteriology and alkaline treatment), Dalziel, *ibid.*, p. 288 (in South China); Pernet, *ibid.*, 1905, p. 262 (De Rochas's views, and histologic note); Woolley, *Amer. Med.*, 1904, vol. viii., p. 242; Graham, *Brit. Med. Jour.*, 1905, ii., p. 1275; Jeanselme, *ibid.*, p. 1276, and *La Pratique Dermatologique*, vol. iii., p. 868 (in French Indo-China); De Bossiere, *Jour. Trop.*

Definition.—An endemic, highly contagious disease with or without constitutional disturbances, characterized primarily by an eruption of papules which develop into more or less exuding raspberry or cauliflower-like nodules or patches.

Symptoms.—There is usually a prodromic stage, or stage of incubation, dating from the time of inoculation to that of the appearance of the inoculation lesion. While during this period such symptoms as malaise, slight fever, anorexia, hyperidrosis, vertigo, and rheumatic pains, etc., with pallor of the skin, may be present and even quite pronounced, especially in young children, they are often

FIG. 177.—Frambesia (courtesy of Dr. O. Henggeler).

wholly wanting. At this time or somewhat later, but as a rule, before the papular eruption develops, furfuraceous whitish, usually pruriginous patches appear on the trunk and limbs; these may coalesce and cover large portions of the body. Some of these desquamating patches may disappear early, and leave the skin lusterless and rough; others may remain, and sometimes new ones appear, throughout the whole course of the disease (Castellani). It is upon

Med., 1904, p. 179 (tertiary manifestations); Henggeler, *Monatshefte*, 1905, vol. xl., p. 235 (a comprehensive paper, with 6 case illustrations, a good review and bibliography); Wellman, *Jour. Trop. Med.*, 1905, p. 345 (spirochætæ findings); Castellani, *Brit. Med. Jour.*, 1905, ii., p. 1330 (spirochætæ findings and also oval chromatin-containing bodies), and also in *ibid.*, pp. 1280, 1330, and 1438; and *Jour. Trop. Med.*, 1906, p. 1 (differentiation from syphilis); Macleod, *ibid.*, ii., p. 1266; McCarthy, *Indian Med. Gaz.*, 1906, p. 53 (in lower Chindivin District, Upper Burma); Gimlette, *Jour. Trop. Med.*, 1906, pp. 149, 175, and 186 (The Pura of the Malay Peninsula); Neisser, Baermann, and Halberstaedter, *Münch. med. Wochenschr.*, July 10, 1906 (experimental inoculation in apes); Breda, *Giorn. ital.*, 1906, p. 98.

these patches that many writers state the elements of the eruption appear. On the other hand, Henggeler has not observed these prodromal changes in the skin at all. The period of incubation varies much, from ten days to several weeks or longer;[1] and is followed by the so-called primary stage, characterized by the development of a papule at the point of inoculation. This appears as a hard papule, usually itchy in character, which gradually enlarges and presents upon its summit a depressed yellow spot of inspissated secretion; this latter tends to spread until the whole papule, is absorbed by the ulceration and crusted over (MacCarthy); it quite frequently becomes rapidly papillomatous. Instead of a papule the beginning lesion may be a pustule (Henggeler). The primary lesion is generally extragenital, and may occur on any part; probably most commonly on the extremities in adults, and on the hands and face in children; and in infants who contract it from an affected mother, in the corners of the mouth—the breast in women being a not uncommon site. The inoculation lesion, or beginning lesion, may also present and continue as a nodule or tubercle, desquamating and disappearing by absorption; also as a kerion-like formation; and sometimes as a papillomatous growth, similar to the typical lesion of yaws, to which the name of "mother yaw" is sometimes given. It is quite variable in size, from a fourth to an inch or more in diameter. Some observers have, however, doubted the existence of an inoculation lesion, looking upon this so-called formation as simply a part or an early lesion of the general eruption.

With care and treatment this initial or primary lesion is commonly of but a few weeks' duration; but if uncared for may, especially if it had developed into an ulcer, last for several months. Following this or during its development, and sometimes almost synchronously with its first appearance the papular eruption of yaws is noted—the so-called secondary stage of the disease. This consists of a variable number (sometimes scanty, but usually numerous) of papules or tubercles of but little more than millet-seed size, and commonly appearing, primarily at least, on the favorite localities—the face, especially about the lips, the neck, arms, and genitalia; and being, as a rule, least abundant on the trunk. It may be limited and regional; on the other hand, it may be extensive and general, and when so, and especially if occurring late, it indicates a protracted attack (Manson). The advent of this eruptive stage is quite frequently signalized by a recrudescence of the systemic symptoms, but which subside, or measurably so, when the eruption is well out. Pains in the limbs, sometimes quite severe, may persist for some time (Henggeler). The lesions, while small at first, soon grow rapidly larger, are usually conic in shape, the summits becoming yellowish in color, and often exhibiting a central depression, so that some at this time may suggest a rough resemblance to beginning variola pustules (R. Koch). From these papules the typical eruption of yaws develops; for along with the development of this yellowish summit the lesions become somewhat broader based, some of them much

[1] In the experiments by Neisser, Baermann, and Halberstaedter (*loc. cit.*) upon apes the period of incubation varies from thirteen to ninety-six days.

larger, and crust over. Many may, however, disappear, some before and some after this stage is reached. On removing the crust, which may fall off spontaneously, the surface is noted to be papillomatous, with a raspberry aspect, and discharging an offensive, dark yellow, acid fluid. Rat says the appearance is much less like a raspberry than it is like the top of a pickled cauliflower. Several or more of these lesions may coalesce and form large areas of similar character, crusting and discharging; and this tendency to coalescence, according to de Rochas, is much more common or more pronounced in children than in adults. In some cases fissuring is to be noted in some of the nodules and patches. After a time the lesions gradually flatten down,

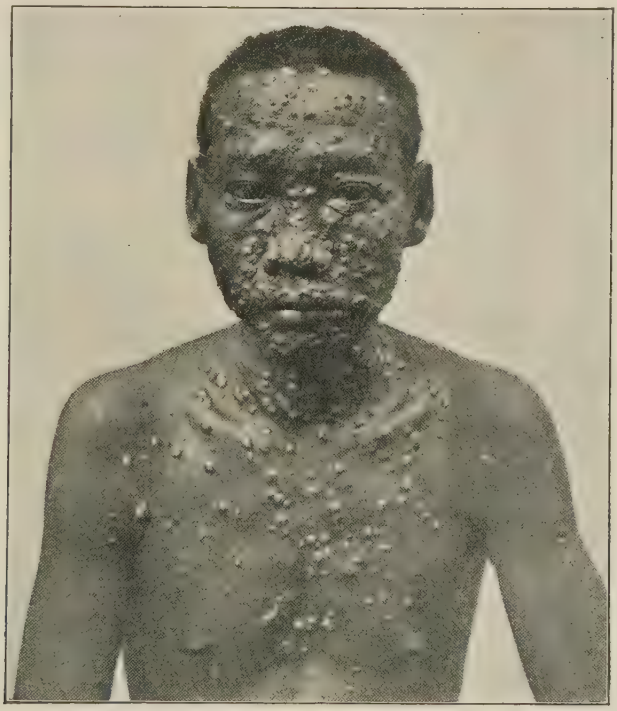

FIG. 178.—Frambesia (courtesy of Dr. O. Henggeler).

change to a yellowish or whitish color, and eventually disappear, leaving a spot characterized in negroes by increased, and in the white by lessened, pigment. The larger lesions and confluent areas sometimes break down and ulcerate, finally healing and leaving scars. Some of the confluent groups may tend to clear up centrally, and a patch is then seen with a ring-like edge (ringworm yaws). In some of the patches a process of hyperkeratosis sets in; they become of much harder consistency, and, especially those on the feet, may be covered with numerous hard, verruca-like, small protuberances.

The disease may, after thus lasting for several weeks to several months, gradually come to an end, favorable changes taking place

and recovery ensuing. In others there are fresh outcroppings from time to time of the papular eruption, with not infrequently a recrudescence of the systemic symptoms, and with the development of some or all of the new papules into the characteristic "yaws." Occasionally some of these latter break down into ulcers. It is, therefore, not uncommon to see all varieties of lesions in the same case: furfuraceous patches, variously sized papules, variously sized "yaws," and in extreme and broken-down cases, sometimes a few or many ulcers as well. Distinct glandular enlargement has been noted by some observers and not noted or denied by others. The mucous surfaces are hardly ever affected, unless about the lips, around the angles of the mouth, and in the nostrils, where the yaws often form clusters (Manson).

In chronic cases, especially in broken-down adults, the "yaws," more particularly the confluent areas, may undergo disintegration and destructive ulcerations, bearing some resemblance to the gummatous ulcerations of syphilis; and some of these may persist long after the general and ordinary lesions have disappeared; furnishing in some instances doubtless cases of so-called "endemic ulcers," and "tropical ulcers."

There is much difference of opinion as to a tertiary stage of yaws, with lesions and symptoms akin or somewhat akin to those noted in tertiary syphilis; most observers deny its occurrence and claim in such instances that there has been either a mistake in diagnosis, or that there has been a coincident or subsequent syphilitic infection; nevertheless a limited number, among whom is De Boissiere, have described tertiary manifestations consisting of ulcers, bone pains, throat ulcerations, lupoid ulcerations of the face and nose, gummata, enlargement of the tibia, synovitis, dactylitis and "soki" (small granuloma on the sole, occasionally on the hand (De Boissiere)), bearing resemblance to the late manifestations of syphilis, and encountered months or even years after the primary invasion.

The subjective symptoms in yaws consist of a variable degree of pruritus, and occasionally some spontaneous pain and tenderness; but, as a rule, the yaw itself is not at all sensitive, and the tumor may be touched with acid even with impunity (Manson).

Etiology and Pathology.—The disease is limited to tropical countries, being endemic in certain regions; it is seen chiefly in the black races, and in both sexes and at all ages, but is most common in children.[1] It is contagious and inoculable, and as in most diseases of this class it is seen most frequently in those in poor health and living unhygienically. One attack is, as a rule, protective. The point of inoculation is almost always extragenital, and quite frequently on exposed parts. It is conveyed by direct contact with the secretion from a yaws lesion, by the contact of clothing, mats, or other agencies in a house infected with the disease, from the dust in a village infected, and through the bites of flies and other insects (McCarthy). The malady is unquestionably due to a microörgan-

[1] McCarthy states that in a series of cases 113 were between one and five, 106 between five and ten, 54 between ten and fifteen, 21 between fifteen and twenty, 43 between twenty and thirty, 35 between thirty and forty, and 59 over forty years.

ism, but there has been as yet no uniformly definite finding. Breda found a bacillus, Pierez, Nicholls, Watts, Modder,[1] and also Powell found cocci, and the last, as well as Haffkine, found a yeast, but further confirmatory observations and experimental investigations as to these have not been as yet forthcoming. In addition to the above findings Castellani has recently found "peculiar oval or rounded chromatin-containing bodies," and also spirochætæ bearing resemblance to those found in syphilis;[2] these latter have also been found by Wellman. Other observers, among whom is Macleod, have either failed to discover any microbic factor, or have considered those seen as the usual accidental contaminations to be found in such formations.

There seems no question, from an impartial study of the disease and its literature, that it is one *sui generis*, and this view is held by the various prominent writers cited in the text and in the literature references given. There still remain, however, a few observers, among whom the most prominent are Hutchinson and Scheube, who believe it to be syphilis modified by unknown conditions. Castellani does not consider that the finding of spirochætæ has any such import. The experiments by Neisser, Baermann, and Halberstädter in apes prove, moreover, that syphilis does not protect from yaws, nor yaws from syphilis; and this is fully in accord with the clinically observed facts.

The anatomy of the yaws lesion has been studied by Charlouis, Pontoppidan, Rat, Breda, Jeanselme, Macleod, Pernet, and others. The findings indicate, as suggested by the clinical picture, that yaws belongs to the infective granulomata, and are very similar, in the main, to those of lupus vulgaris, except that there are no giant-cells (Breda). There is (Macleod) marked cellular infiltration of the corium, involving all its parts except probably hair-follicles, sebaceous glands and coil-glands; and marked proliferation and down-growth of the interpapillary processes so great in the older lesions as to resemble condyloma acuminatum. Some observers believe (Rat, Pernet), that the peculiar frambesial character of the lesion is probably merely the result of secondary microbial infection from without.

Diagnosis.—The disease is to be distinguished chiefly from syphilis, with which it is most likely to be confounded—by the absence of induration of the inoculative lesion, of distinct or pronounced glandular enlargement (not always reliable), and of the usual associated lesions of the mucous membrane of that disease. Daniels states that there is no resemblance to primary or secondary syphilis and that it shows none of the associated lesions of that disease. It would certainly seem that the uniformly prevailing peculiar frambesial or fungoidal character of the eruption, developed out of pre-existing papules, nodular lesions or patches, with an acid secretion, and covered with a crust is quite different from any eruption of syphilis;

[1] Modder (*loc. cit.*) grew and cultivated a micrococcus in acid media; growth ceased in alkaline media.

[2] Castellani (*loc. cit.*) states that he submitted several of his specimens to Schaudinn, who agreed with him as to their close similarity or identity with those found in syphilis.

in the latter disease a frambesiform character may be an accidental condition in some lesions, but never a distinct characteristic of the eruption as a whole. To the trained eye, the histologic differences would be of value in the differentiation.[1]

Prognosis and Treatment.—In mild and limited cases in subjects in good general health, the disease is at an end in six to eight weeks; but in average cases the duration varies in children from three to six months and in adults six to twelve months, and occasionally, with relapses, it may continue much longer. Europeans do not, according to Graham, recover as quickly as natives. In those debilitated by ill-health and dissipation, especially if cleanliness and other hygienic conditions are neglected, septic poisoning may ensue and death result. The ulcers occurring in some cases may exceptionally be persistent and rebellious to ordinary treatment.

There seems to be considerable unanimity as regards the curative value of mercury and the iodids, along with other remedies which may be indicated by the patient's general health. Alkaline treatment has also had a few advocates, Modder especially commending it. Of importance, as may be inferred, are improved hygienic conditions, and good nutritious food. The external treatment consists in cleanliness and the free use of antiseptic lotions, such as of boric acid and corrosive sublimate, and mercurial ointments. Stimulation or mild cauterization of the more obstinate lesions or patches is sometimes advisable. Persistent ulcers, when not responding to the usual remedies, may require erasion with the curet.

Thorough disinfection of clothing, room, and house is of essential importance in limiting the spread of the disease.

[1] Macleod (*Brit. Med. Jour.*, 1901, Sept. 21, and *Practical Handbook of the Pathology of the Skin*, p. 200) gives the following summary of the histologic points which differentiate it from the other infective granulomata: It is distinguished from (1) actinomycosis and rhinoscleroma by the absence of their specific micro-organisms. (2) From the lepromata by the absence of Hansen's bacillus. (3) From mycosis fungoides by the absence of "fragmentation" of the infiltrating cells, and of degenerative changes with the formation of products of degeneration in the collagen and elastin; by the presence of the epidermal changes peculiar to yaws. (4) From tuberculosis, apart from the tubercle bacillus, by the absence of the characteristic architecture with its giant-cells, daughter plasma-cells, more marked disintegration of the fibrous stroma, and complete disappearance of the blood-vessels. (5) From syphilis by the following details, which, considered collectively, strongly suggest that yaws and syphilis are different histologic entities: (*a*) Cellular infiltration: plasma-cells not so definitely arranged in rows or clustered round the blood-vessels as in syphilis; no large multinuclear cells (chorioplaques), or true giant-cells, or intracellular hyaline degeneration noted in yaws. (*b*) Fibrous stroma: rarefaction of the collagen more marked than in syphilis, but no organization or colloid degeneration found, such as occurs in syphilitic gummata. (*c*) Blood-vessels: no distinct proliferative changes in the vessel-walls or endothelium, as frequently occur in syphilis. (*d*) Epidermis: marked proliferation and down-growth of the epithelium, with great thickening of the horny layer (due to hyperkeratosis or parakeratosis) are characteristic features of yaws, while they are unusual in syphilis.

VERRUGA PERUANA.

Synonyms.—Peruvian warts; Carrion's disease; Oroya fever; *Fr.* La Verruga; Maladie de Carrion.

Definition.—A specific, inoculable affection, endemic in some valleys of the Western Andes, in Peru, and characterized by a prodromal febrile period and subsequent outbreak of peculiar, pin-head- to pea-sized or larger, reddish, rounded, granulomatous, wart-like elevations.[1]

Symptoms.—The prodromic period, which may persist for weeks or several months before the cutaneous outbreak, is characterized by

FIG. 179.—Verruga peruana (case referred to in the text).

irregular fever of malarial or typhoid type, with rheumatic joint and muscular symptoms and more or less profound anemia. Upon the advent of the eruptive phenomena these symptoms abate or vanish, or remissions may be noted. The eruption usually first shows itself

[1] An admirable and exhaustive paper by Matas on this disease is to be found in Morrow's *System*, vol. iii. (Dermatology), p. 694; also in Sydenham Soc. edit. of Hirsch's *Handbook of Geographic and Historic Pathology*, vol. ii., p. 110; Escomel, *Annales*, 1902, p. 961; Eder, *Jour. Trop. Med.*, 1906, p. 213.

on the face and limbs and begins as small reddish spots or incompletely formed vesicles, which soon become pin-head- to small pea-sized or larger, conic, rounded, soft, or elastic elevations, which may be sessile or pedunculated. They are somewhat variable as to size, in moderate numbers or abundant, and may be somewhat painful or tender to the touch. They are often crowded together in small bunches. They are bright red in color, later becoming dark red. Thinned epidermal covering often cracks, and in some instances considerable hemorrhage may ensue, and semetimes to a dangerous degree, the usual anemic condition of the patient becoming thereby more pronounced. The lesions may be small and remain small, and

FIG. 180.—Verruga peruana (case referred to in the text).

gradually dry up and disappear. When crowded together, they seem almost confluent, irritated, and abraded, crusting over, and discharging from time to time some sanious pus. While, as a rule, the lesions are on the skin, they may be on the mucous membranes, and even on the serous membranes, or there may be some subcutaneous lesions, especially about the joints. These latter lesions feel at first like small, movable bodies, and gradually disappear, or may increase in size, becoming as large as a nut or exceptionally as small as an orange, and break down. Crowded lesions, either of the surface or the subcutaneous nodules, may undergo disintegration and result in

the formation of superficial fungoid ulcers. In some cases, as in a case observed by me, a good replicate, but less extensive, of the case, shown in Sydenham's atlas under the name of frambesia, the lesions are for the most part small but numerous. In this case, as in others, such lesions shrivel into black spots or specks on a level with the surface, which exfoliate or drop off, leaving no trace. There is a tendency for the eruption in some cases to come out in successive crops.

Etiology and Pathology.—The disease is peculiar to certain valley districts of the Western Andes in Peru, the rare cases seen elsewhere, as the one seen by me in the Philadelphia Hospital, referred to above, having come from that country. It is inoculable, and the essential cause is considered (Yzquierdo [1]) to be a bacillus somewhat larger than the tubercle bacillus. Debility from any cause is a predisposing factor. The connective-tissue growths originating in the upper or lower part of the derma are vascular, and some are cavernous.

A few observers (Manson, Scheube) consider the malady as yaws modified by environmental conditions, but this view is not shared by Hirsch, Plehn, Jeanselme, and others. Certainly both the objective and constitutional characters, especially the latter, speak for its individuality.

The **diagnosis** in the early stage of the disease is difficult: it may be made by exclusion, the fact being known that the patient has resided in the affected district. As soon as the eruption comes out the difficulty is solved, as it is peculiar and characteristic.

Prognosis and Treatment.—The disease is always to be considered grave; under favorable conditions the death-rate is about one in six to eight; it is much higher when the disease is epidemic (Crocker). The slow, sluggish cases, with scarcely any fever after the eruption appears, are the most favorable. My case was under observation about four weeks, and was gradually improving when he left the hospital. The disease may last for weeks or months. Death may result before the cutaneous eruption appears. Tonics, especially iron and quinin, and stimulants, if necessary, are to be prescribed. It seems to be agreed that the eruptive tendency should be encouraged. Removing patient from the affected region to the seashore is stated to be of great curative value.

[1] Yzquierdo, *Archiv für path. Anat.*, etc., Berlin, 1885, vol. xciv., p. 411.

CARCINOMA CUTIS.

The forms of carcinoma cutis of particular interest to the dermatologist are epithelioma, or skin cancer, and Paget's disease. Before taking up their consideration, however, the several other types known as carcinoma lenticulare, carcinoma tuberosum, and carcinoma melanoticum, belonging more especially to the domain of surgery, may be briefly referred to. Lenticular carcinoma and tuberose carcinoma are examples of scirrhus, sometimes called scirrhous, hard, or fibrous cancer, and are usually secondary to cancer of the breast or other organs, only rarely occurring primarily in the skin.

Carcinoma lenticulare, or lenticular carcinoma, is seen most commonly about the breast in women, and developing as a secondary manifestation in mammary scirrhus, or in the scar tissue resulting from an operation for a previously existing mammary growth. It presents itself as several or more whitish or pinkish papules or small nodules, which are usually firmly imbedded in the skin, projecting but slightly above the surface, or the greater portion of the lesions may be above the skin level. They are at first pin-head- to pea-sized, and may persist about the latter size for some time, although not infrequently some of the growths may reach the dimensions of a cherry or larger. The covering integument is pinkish to reddish in color, with usually enlarged capillaries coursing irregularly over its surface. From their growth, multiplication, and extension they become closely crowded or practically fuse together, and form extensive, hard, thickened, nodular areas. A considerable part or almost the entire upper part of the chest, both anteriorly and posteriorly, and shoulders may be gradually involved. In extreme cases the armor-like investment more or less seriously impairs full respiratory action, and from a blocking off or obstruction of the lymphatics and veins considerable swelling of the arms may occur, sufficiently marked as to compromise mobility of the parts (*cancer en cuirasse*). The progress is usually steady and moderately rapid. Softening and ulceration are, as a rule, sooner or later noted, a condition of marasmus develops, and the patient gradually succumbs. Exceptionally there is observed a disappearance of some of the nodules.

Carcinoma tuberosum, tuberose or nodular carcinoma, is a still rarer variety, and which may present on any part of the body; it is not uncommonly disseminated or generalized, but probably oftener or predominantly on the face or extremities. It may be a primary or secondary manifestation, and is generally seen in middle or advanced age. The lesions are, as the name signifies, larger than those of the lenticular variety. They begin as small nodules, somewhat deeply seated, either in the lower part of the corium or in the subcutaneous tissue, and gradually enlarge and project above the surface, the overlying skin assuming a distended, shiny, tense appearance, and of a red color, usually with a brownish, bluish, or purplish tinge. They are of various sizes, sometimes reaching the dimensions of an egg or larger, and in some parts frequently being so crowded as to form large nodular masses. There may, likewise, be an invasion of the internal organs. Sooner or later ulceration ensues and the patient

drifts more or less rapidly into a cachectic or marasmic condition and succumbs. The malady may present somewhat slowly and run a somewhat tardy course, or it may reach a rapid and extreme development in several months.

Melanotic or pigmented carcinoma, while rare, is not so infrequent as previously thought, inasmuch as some cases heretofore looked upon as examples of pigmented sarcoma, starting from pigmented nævi, are now believed to belong among the carcinomata. It would, however, be impossible clinically to differentiate the cases of the pigmented sarcomata from those of pigmented carcinoma,[1] a histologic examination of the morbid tissue being necessary for a positive conclusion. Pigmented carcinoma generally starts from a congenital and acquired pigmented nævus. There may be presented but one variously sized growth, although this is exceptional; more commonly there are several, and they may be quite numerous. Usually there is primarily a single growth, with the development of secondary nodules near by. They may appear on any part of the surface, the extremities and genitalia being favorite regions. The tumors vary in size from a small pea to considerable dimensions, and may be rounded, flattened, or fungoidal in character. In some instances or in some regions the lesions, small in size, are crowded together and form verruca-like patches or infiltrations. In color they are of various dark shades, from a slate color to a purplish and bluish-black. The larger growths, especially those having a fungoidal aspect, tend to break down rapidly. The malady is, as a rule, extremely rapid in its course, often involving the visceral organs early, a fatal ending sometimes resulting in the course of some months or a year or so.

The **treatment** of these various forms consists in early excision. If advanced, and operative measures are inadvisable, the continued administration of arsenic, in increasing dosage, either by the mouth or hypodermically, should be tried; in such instances, too, the possible favorable influence of X-ray treatment should be considered.

PAGET'S DISEASE.

Synonyms.—Paget's disease of the nipple; Malignant papillary dermatitis (Thin); Eczema epitheliomatosa; Eczematoid epitheliomatosis of the nipple; Cutaneous psorospermosis; Psorospermosis cutis; Mammillaris maligna; *Fr.*, Maladie de Paget; Epithéliome de Paget; *Ger.*, Paget's Krankheit.

Definition.—Paget's disease is a rare malignant disease, usually of the nipple and areola in women, beginning as an inflammatory-looking, eczematoid affection, and eventually terminating in cancerous involvement of the whole gland.

Attention was first called to this malady by Paget[2] in 1874, whose description was based upon an observation of 15 cases, in all of which —women between the ages of forty and sixty—cancerous involvement of the gland followed within one or two years after the appearance of the cutaneous symptoms. Since then many additional cases have

[1] See Ravogli's paper, "Multiple Nodular Melanocarcinoma of the Skin from a Nævus," *Jour. Cutan. Dis.*, June, 1901 (with histologic cuts, review, and bibliography). References to the contributions of Gilchrist and others will be found under sarcoma.

[2] Paget, *St. Bartholomew's Hospital Reps.*, 1874, vol. x., p. 87.

been reported, and the malady has received considerable attention, both in its clinical and histopathologic aspects, by various observers,[1] among whom Butlin, Thin, Duhring, Wickham, Bowlby, Hutchinson, Jr., Jackson, Wiggin and Fordyce, and others.

Symptoms.—The disease is exceedingly insidious in its appearance, and scarcely comes under notice until a distinctly eczematoid aspect is presented. In its very earliest stage it consists of slight, scaly, somewhat hardened, thin, epidermic collections or scurfiness of the nipple and the immediately contiguous portion of the areola, with, later, slight redness and often more or less itching. It may remain limited to this small circumscribed area for months or longer, during which time slight or moderate erosion of the nipple may present and crusting ensue. After a variable time the condition spreads out and soon involves the whole area of the areola, and often extends beyond. When at all developed, the diseased area, which is usually sharply marginate, exhibits a florid, intensely red, very finely granular, raw surface, attended with a more or less viscid exudation. There is moderate infiltration, which is well defined below, feeling, in fact, like a thin layer of indurated tissue implanted in the skin.

The malady slowly progresses, fissuring, erosion, and retraction of the nipple gradually ensuing, which sooner or later has entirely disappeared. After some months or several years the process becomes more intense, greater thickening is noted, the nipple and contiguous part of the areola are ulcerated or have "melted away," and some nodular hardening usually develops in the gland structure—in short, gradual scirrhous involvement of the whole breast finally occurs. As a rule, the superficial or eczematoid area does not extend more than several inches beyond the areola, but in some instances, as notably in those reported by Jamieson[2] and Elliot,[3] it is much more extensive; in these two cases the entire surface of the breast was involved and the axillary region partly invaded. In a few instances, too, the malady has affected both breasts. The course of the malady is, moreover, extremely variable. In some cases, as in those reported by Paget, but one or two years elapsed before carcinomatous development in the gland was noted; in others the disease remains for a long time confined to the surface as an eczematoid eruption—in Morris's[4] case six years, in Duhring's case ten years, and in Jamieson's, twenty

[1] Butlin, *London Med.-Chirurg. Soc'y Trans.*, 1876, vol. lix., p. 107, and 1877, vol. lx., p. 153 (with histologic illustrations); Thin, *London Patholog. Soc'y Trans.*, 1881, vol. xxxii., p. 218 (with histologic cuts), and *Brit. Med. Jour.*, 1881, vol. i., pp. 760, 798 (with histologic cuts), "On Cancerous Affection of the Skin," London, 1886 (with review of the subject); Duhring and Wile, *Amer. Jour. Med. Sci.*, vol. lxxxviii., 1884, p. 141 (pathology with references); Wickham, "Maladie de la peau dite maladie de Paget," *Thèse de Paris*, 1890 (with colored plates, review, and bibliography); and *Annales*, 1890, pp. 45 and 139 (with bibliography); Bowlby, *London Med.-Chirurg. Soc'y Trans.*, 1891, p. 341 (notes of 13 cases); Hutchinson, Jr., *London Patholog. Soc'y Trans.*, 1890, p. 214 (with histologic cuts), *Brit. Jour. Derm.*, 1891, p. 278; G. T. Jackson, *Jour. Cutan. Dis.*, 1896, p. 428 (with review and important references); Wiggin and Fordyce, *New York Med. Jour.*, 1897, vol. lxvi., p. 445 (with colored case illustration and histologic cuts).

[2] Jamieson, *Diseases of the Skin*, 1889 edit., p. 482 (woman aged seventy-two).

[3] Elliot, *Jour. Cutan. Dis.*, 1892, p. 272.

[4] Henry Morris, *London Med.-Chirurg. Soc'y Trans.*, 1880, vol. lxiii., p. 37 (colored plate case illustration and histologic cuts).

years. As a rule, however, in two or three years malignant involvement of the breast has ensued.

According to the observations of recent years, it would seem that the disease is not necessarily one limited to the breast. Crocker[1] has observed an instance of its occurrence on the scrotum, Tommasoli[2] on penis, Pick[3] on the glans penis, Sheild[4] on pubic region, extending on to penis and scrotum, Dubreuilh[5] on the vulva, Darier and Couillaud[6] on the scrotum and perineal region, Winfield[7] on the lip, and Ravogli[8] on the nose. Jungmann and Pollitzer[9] in the axilla, Colcott Fox and Macleod[10] in the umbilical region, and Fordyce,[11] probable case on the buttocks. I have met with a case somewhat similar to Ravogli's case, in a woman aged sixty, the whole nose being superficially involved and eroded and clinically suggestive of this malady. An instance of its occurrence on the scrotum has also come under my notice in an old man (Dr. C. N. Davis's patient).

Etiology.—The disease is one of advancing years, occurring most frequently between fifty and sixty. It is practically limited to the female sex and to the nipple region, the cases occurring on other parts in men still being viewed with some suspicion. In one instance, observed by Forrest,[12] however, of apparently eczematous disease of the nipple in a male aged seventy-two, carcinoma developed. There is a somewhat remarkable disproportion in its occurrence on the right side; in not more than 25 per cent. was the left breast the seat of the disease. Various causes have been considered as etiologic. The malady was formerly thought to be a carcinoma developing upon a long-continued eczema, but it is now generally believed that the process is malignant from the start. Doubtless fissures and persistent irritation of the nipple are favoring factors. Darier and Wickham advanced the opinion that psorosperms are the exciting agents; psorosperm-like bodies have also been found by Bowlby, Macallum,[13] Hutchinson, Jr., and others. This view is, however, no longer maintained, that originally held by Thin, and later by Unna, Fordyce, and others, that these bodies merely represent cell changes, is now generally accepted.[14]

[1] Crocker, *London Patholog. Soc'y Trans.*, vol. xl., 1889, p. 187 (with colored plate case illustration and histologic cuts).

[2] Tommasoli, *Giorn. ital.*, 1893, vol. xxviii., Fasc. iv.

[3] Pick, *Prager med. Wochenschr.*, 1891, p. 282.

[4] Sheild, *Brit. Jour. Derm.*, 1897, p. 35 (man aged sixty).

[5] Dubreuilh, *ibid.*, 1901, p. 407.

[6] Darier and Couillaud, *Annales*, 1893, p. 33 (man aged seventy-two, fifteen years' duration).

[7] Winfield, *Brooklyn Med. Jour.*, Mch., 1896 (Soc'y proceedings).

[8] Ravogli, *Trans. Internat. Med. Cong.*, Rome, 1894; abs. in *Jour. Cutan. Dis.*, 1894, p. 222 (patient an old lady).

[9] Jungmann and Pollitzer, *Dermatolog. Zeitschr.*, June, 1904.

[10] Colcott Fox and Macleod, *Brit. Jour. Derm.*, 1904, p. 43 (with case illustration, histologic cuts, review of these special cases and a general review of the disease, and references; man aged sixty-five, of eleven years' duration).

[11] Fordyce, *Jour. Cutan. Dis.*, 1905, p. 193 (with histologic cuts), a probable case of the gluteal region (woman, aged sixty, of six years' duration).

[12] Forrest, *Glasgow Med. Jour.*, vol. xiv., p. 459 (patient aged seventy-two).

[13] Macallum, *Canadian Med. Practitioner*, 1890, p. 473.

[14] Fabry and Trautmann, *Archiv*, 1904, vol. lxix., p. 37, found a yeast fungus, and suggest a possible relationship between Paget's disease and blastomycetic dermatitis. Inasmuch as this has not been observed by other careful investigators, it is probable that in this instance its presence was secondary or accidental.

Pathology.—At the present time there is but little doubt as to the malignant nature of even the earliest phases of the malady.

The pathologic anatomy has been studied by various observers (Butlin, Thin, Duhring, de Schweinitz, Darier, Wickham, Fordyce, Unna, and others). There is practically more or less unanimity in the findings. "The morbid changes (quoting Fordyce) may be briefly stated as inflammation of the papillary region of the derma, leading to an edema and vacuolation of the constituent cells of the epidermis, followed by their complete destruction in places and their abnormal proliferation in others. The change in the epithelium of the lactiferous canals and glandular epithelium, which is also of a proliferative and degenerative nature, is secondary to the changes in the surface epithelium, and may be regarded as of the same nature, and probably produced by the action of the same irritant. The over-distention of the lactiferous canals by the proliferating epithelium, resulting in a malignant infection of the surrounding connective tissue, is the usual termination of the affection." As all observers have found, as Fordyce further states, "the earliest and most carefully studied changes in Paget's disease are those met with in the

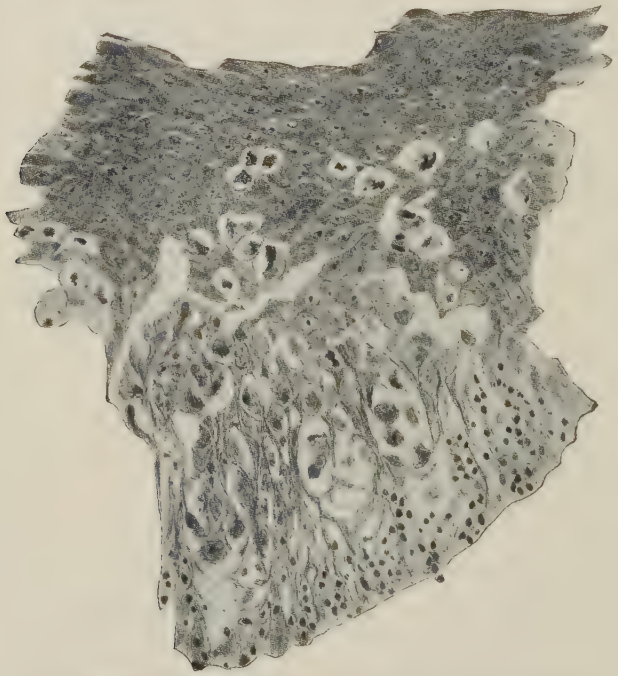

Fig. 181.—Paget's disease, in middle stage, showing the peculiar epithelial cell degeneration and the psorosperm-like bodies (courtesy of Dr. A. R. Robinson).

surface epithelium. It is here that the cell changes and inclusions are met with which were first described by Darier and afterward by Wickham and others, as coccidia. . . . A more careful study of these cell degenerations has pretty conclusively demonstrated the

non-parasitic character of many of them. The infectious nature of Paget's disease has, however, by no means been absolutely disproved, and an element of doubt yet remains as to the character of certain of the cell changes which are found in the affection." The rôle which Darier, Wickham, and others gave these peculiar cell-degenerations, under the erroneous impression that they were coccidia or psorosperms, has, as already stated, been practically abandoned.

Diagnosis.—The disease, in its earliest stage, is to be distinguished from eczema, a matter in some instances of some difficulty, until the case has been under observation for a short period. In its later stages, and especially when the gland involvement is already evident, a mistake could occur only as a result of a hasty and careless examination. The diagnostic features are: The age of the patient; the sharp limitation; the well-defined, indurated film of infiltration; the peculiar, red, raw, granulating appearance; and, later, the retraction of the nipple; and, finally, the involvement of the deeper parts. A persistent circumscribed eczematous-looking eruption of the nipple and areola should always be viewed with suspicion in those advancing in years, which becomes almost a certainty if it is rebellious to the usual treatment of eczema. In the earlier stage in doubtful cases examination may be made for the psorosperm-like bodies, which are characteristic, and not to be found in eczema.

Prognosis and Treatment.—If the disease is recognized early and properly treated, a cure may be often anticipated; but later the prognosis is essentially the same as that of scirrhus of the breast, and depending upon the progress of the disease and the amount of breast involvement.

Treatment, when the diagnosis is clearly established, should be radical, consisting of the plans mentioned for epithelioma, radical operation being the first choice. While mild and palliative applications can do no direct harm, half-way measures are not permissible, as the latter simply serve to spur the disease to more rapid advancement. In doubtful cases the various plans of treating eczema are at first to be employed, and if this disease, the condition will usually readily yield. In clear cases of the disease, in which radical measures are refused, palliative and soothing applications are to be made. In Elliot's patient the use of an ointment of fuchsin, 2 to 5 grains (0.135–0.35) to the ounce (32.) of lanolin and rose-water, of a strength just short of producing irritation, acted satisfactorily, giving considerable relief, and promoting cicatrization.

X-ray treatment sometimes benefits; 1 of Hartzell's cases and 1 of my cases improved under this; Jungmann and Pollitzer report a cure of their axilla case and Fordyce in his gluteal case.

EPITHELIOMA.

Synonyms.—Skin cancer; Epithelial cancer; Carcinoma epitheliale; Cancroid; Noli me tangere; *Fr.*, Épithéliome; Cancroïde; *Ger.*, Hautkrebs; Epithelialkrebs.

Definition.—The term epithelioma, in its strict dermatologic significance, may be defined as an epithelial new growth with destructive tendency, having its origin in the epithelium of the epidermis or of the glands of the skin.

Symptoms.—Epithelioma presents, when at all developed, various clinical phases or characters, usually with, in different cases, a predominance of one of the several features over the others, so that it would be possible to make a number of varieties. For practical and descriptive purposes, however, the three divisions commonly made are sufficiently comprehensive. These several forms of epithelioma are designated the superficial, or discoid, the deep-seated, and the papillomatous.

Superficial Variety.—The superficial, or discoid, form, sometimes also named the flat variety, is, of the several varieties, that most frequently encountered. It may begin in one of several ways: as a small, firm, reddish, yellowish, or pearly papule or tubercle, or as an aggregation of two or three such lesions; as a warty excrescence, primarily of a benign character, such as a simple wart or small, elevated, fleshy mole; and as a small pea- to bean-sized, smooth, or roughened keratosis or greasy, scaly, seborrheic patch (see keratosis senilis and atrophia senilis). In the event of it beginning as one of the several small, solid lesions named, the first evidence of the degenerative change is usually a slight fissure or surface abrasion, which persists and slowly enlarges, and often becomes thinly crusted. After some months the slight pearly, warty, or mole formation has in great measure slowly yielded to the degenerative action, and in great part or wholly disappeared, giving place to a surface ulceration a trifle larger than the lesion which it has gradually displaced. In some cases, however, a long time elapses—some months or one or



FIG. 182.—Epithelioma, superficial type, in an old man aged sixty-five, showing the roll-like border.

two years—before the first lesion has wholly gone, and it is not uncommon for it to be gradually destroyed in the upper part, and the basal portion remain for a shorter or longer period, with an ulcerated surface covered with a thin or slightly thickish incrustation, which is knocked off or falls off from time to time, but which soon reforms. After the lesion has, however, sunken to and usually a trifle below the skin level and a shallow ulcer is in its place, it is commonly observed to have a slightly elevated and often a pearly, roll-like border, which is gradually pushed further as the ulcer becomes larger. In rare instances, as in those observed by Danlos, Brocq,

and myself,[1] the superficial epithelioma spreads by an invading flattened, morphea-like, slightly raised band of one-fourth to one-half inch or so in width.

The ulcer, which has a slight serous or serosanguinolent, viscid, or varnish-like discharge, keeps more or less continuously crusted, and the crust, when it is not frequently rubbed or knocked off, may become quite thick. The discharge is sometimes mixed with pus, but it is only, as a rule, in the more advanced stages, when the ulcer becomes large and tends to extend more deeply, that the purulent character of the discharge is at all noticeable, and never so pronounced or distinctly purulent as in syphilitic ulcers. The superficial variety of epithelioma rarely, certainly not, as a rule, until after some years' duration, extends to much depth. In course of time it does, it is true, gradually eat in, so that when on the side of the nose there is risk of final penetration. In occasional instances of these sluggish superficial types, and especially that form with the pearly

FIG. 183.—Epithelioma of superficial type, crusted, in a woman aged fifty-eight.

border, as the disease spreads there is displayed in the older parts a tendency to cicatricial healing.

In other cases the disease pursues a course which has given it the name of **rodent ulcer** (Jacob's ulcer; Cancroid ulcer; Ulcus exedens; Ulcus rodens; Noli me tangere; Ulcére cancreux; Der flache Hautkrebs); formerly these cases were also designated lupus exedens. The special characteristic of this type is its lateral, steadily progressive spread, with but little, and sometimes no, ele-

[1] Danlos, *Annales*, 1899, p. 656 (case demonstration—patient, woman aged forty-three, with lesion on the neck); Brocq, *ibid.* (discussion—2 cases, both women, aged fifty-five and sixty, with lesion about the nose); Stelwagon, *Trans. Amer. Derm. Assoc. for 1899*, p. 166 (case demonstration—patient, male, aged forty, with flat epithelioma of the temporal region, with almost an inch-wide superficial, morphea-like border).

vated or infiltrated border; in other words, the ulcerating feature is conspicuous, whereas the new growth element is almost *nil*. Not infrequently, especially in the earlier stages, there is a slight, pearly, roll-like border. Some observers are inclined to consider this a distinct malady from epithelioma, although admitting it to be an allied disease, but the origin, behavior, and pathologic characters are in all essential particulars similar to those of other superficial cases. It is true, as Paget states, that it frequently begins as a brownish nodule, different from the pearly tubercle or warty growths which mark the other superficial type, but rodent ulcer, or a lesion clinically indistinguishable, may also begin, as I have often observed, in the same manner as in the cases of the superficial form already referred to. The rodent ulcer variety is commonly a disease of the upper half of the face, being especially frequent about the eyelids and sides of the nose.

The course of superficial epithelioma, as has already been intimated, is usually preeminently slow, and the disease of a relatively benign character, many years often elapsing before serious progress has been made. The rodent ulcer form is often eventually extremely destructive, extending deeply as well as laterally. The lymph-glands are rarely involved in these superficial cases, but there is a possibility

FIG. 184.—Epithelioma, rodent ulcer type, in a man aged sixty, of fifteen years' duration; recurrence several times after curetting and cauterization.

in all instances of final glandular involvement [1] and a change of type into a deep-seated or papillary variety of the disease.

Deep-seated Variety.—The deep-seated or nodular variety of epi-

[1] See interesting paper by D. W. Montgomery, "Report of a Case of Epithelioma of the Skin with Unusual Course of Infection of Lymph-nodes," *Annals of Surgery*, 1898, vol. xxvii., p. 193.

thelioma may start from the superficial type, or it begins as a tubercle or nodule in the skin or subcutaneous tissue. It gradually increases in dimensions, projecting both downward and above the level of the skin, with the overlying integument pinkish or reddish, and frequently with dilated capillaries coursing over it. There may be some lateral extension into the surrounding tissue. In the course of several months or longer the nodule, which has frequently reached the size of a cherry or larger, breaks down centrally, an ulcer is formed, with usually prominent and infiltrated reddish and inflammatory-looking borders. The surface of the ulcer is reddish and granular and secretes a viscid, and often ichorous discharge, and crusts over from time to time. When arising from the superficial variety of epithelioma, this latter is usually noted to become more angry-looking, especially about the edges, the latter becoming more prominent, showing increasing infiltration, and the base of the growth likewise tending to become thicker and hard, and there may, in some instances, be considerable elevation. The progress of the deep-seated type is usually steadily progressive, and, as a rule, at a relatively rapid pace. The infiltration, which is the pronounced feature of this form, spreads gradually, sometimes rapidly; the ulcer enlarges both peripherally and in depth, and presents hard, everted, often more or less undermined edges, sometimes showing here and there small waxy nodules; the base is noted to be irregular, not infrequently slightly or moderately papillomatous or vegetating, and with often considerable

FIG. 185.—Epithelioma, deep-seated, "crateriform" variety.

viscid, varnish-like, sanguinolent, partially or markedly purulent discharge. The base exhibits, as a rule, a disposition to slight bleeding upon the slightest provocation, such as a trifling knock or insignificant roughness in its washing or dressing. In some cases the ulcerative tendency is displayed chiefly in the central portion, the surrounding infiltration being somewhat hard and elevated, and the invasion and

progress rapid, constituting the "crateriform ulcer" of Hutchinson. This rare variety, which usually is seated on the upper part of the face, may also start as a superficial rodent ulcer type. Muscle, cartilage, and bone often finally become invaded. The neighboring lymphatic glands are sooner or later implicated; pains of a burning or neuralgic type are experienced, and with or without recognizable, metastatic tumors in the internal organs, death eventually ensues.

Papillary Variety.—The papillary or papillomatous variety of epithelioma usually arises from the superficial or deep-seated type; or it may begin primarily as a papillary or warty growth. Beginning in the latter manner, it may for some months or longer maintain a pseudoverrucous appearance, projecting higher, however, than ordinary warts, involving more surface,—one-half to an inch or so in diameter,—with a slightly or moderately, mildly inflammatory, infiltrated base, which may extend a line or two beyond the edge of the papillary formations. When the area of disease is small, the vegetations are usually noted to be somewhat higher centrally, although in larger areas also the papillary projections are generally much less prominent toward the extreme peripheral portion. When a papillary epithelioma is fully developed, it matters not in what manner it may

FIG. 186.—Epithelioma of deep-eating rodent type, in a woman aged sixty (courtesy of Dr. A. Van Harlingen).

have originated, it presents an ulcerated, fissured, and papillomatous surface, usually having a viscid or thick secretion, with a variable proportion of purulent admixture. The surface may bear resemblance to a digitate wart, to a cauliflower excrescence, or it may be distinctly condylomatous in appearance. Exceptionally there is a tendency

[1] Hutchinson, "The 'Crateriform Ulcer of the Face,' a Form of Acute Epithelial Cancer," *Trans. London Patholog. Soc'y*, vol. xl., 1889, p. 275 (with colored plates).

toward slight pedunculation. Sometimes the secretion is scanty, the ulcerative action more in the nature of deep fissures extending down between the papillary projections, and the surface of the growth may present a somewhat hard or horny, thin or moderately thick incrustation. In some cases the surface is irregularly ulcerated and papillomatous, the granulations usually presenting an exuberant and fleshy character, which bleed quite readily. It is slowly, sometimes rapidly, progressive, and sooner or later develops a malignant tendency, showing deep-seated infiltration, involvement of the neighboring lymph-glands, and death, as in the malignant, deep-seated variety, gradually results.

Epithelioma of the **lip**, usually on the lower lip toward one side, comes more commonly under the care of the surgeon, although in its earliest stage it is not infrequent in dermatologic practice. It begins in one of the several ways described in connection with its appearance on the cutaneous surface. Its most common commencement is as a slight abrasion, crack, or small papule or warty-looking lesion, and in many cases advice is not sought until a superficial ulcer, with variable infiltration, is noticed, which presents in several months or longer. The future course is about the same as with the more rapid skin cancers, there being usually considerable infiltration and swelling, with comparatively early involvement of the lymphatic glands. The surface is commonly granular-looking, in places often crusted. Cancer of the tongue, which may also, in its beginning stage, first come under the inspection of the dermatologist, begins as a small abrasion or fissure, often started by irritation produced by a tooth, or developing upon a leukoplakia. A superficial ulcer soon results, later infiltration beneath and surrounding, and more or less rapid course and destruction. Epithelioma of the genital organs is also met with, the glans penis, prepuce, and clitoris being not unusual sites. On these parts the papillomatous variety is of common occurrence, starting from an abrasion or a warty growth.[1]

The favorite sites of election in skin cancers are, first of all, the various parts of the face, especially the nose, eyelids, and lips. The forehead and, more frequently, toward or at the temporal region, the ear, the back of the hand, and the genitalia are also localities frequently invaded. Any other part may, however, be, but, as a rule, only rarely, the seat of such growth. On the dorsal surface of the hand the lesion begins usually either as a warty excrescence, developing into the papillomatous type, or as a keratosis or degenerative seborrheic patch, which scales or crusts off from time to time, as already described, and gradually breaks down and into the ordinary epitheliomatous ulcer. As a rule, the growth is single, although in exceptional cases two or three lesions may be present; and in some instances of numerous, scattered, senile, degenerative, seborrheic patches about the face, several or more may gradually undergo epithelial change,—épithéliomatose sébacée of the French,—and multiple epithelioma result. Mention should also be made here of the condition occasionally met with, which will be found described else-

[1] For detailed description and management of lip, tongue, and genital cases the reader is referred to works on surgery.

where under the title "multiple benign cystic epithelioma" (*q. v.*). In this, numerous lesions, discrete or bunched, usually about the face or upper part of the trunk, are present, of a character closely similar, if not identical with, the pearly growths and border, both clinically and pathologically, seen in some cases of ordinary epithelioma; in view of the few instances in which in this mild malady degenerative changes have occurred it is highly probable that the future of these cases may show that the term benign is scarcely acceptable.

In the milder phases of epithelioma no subjective symptoms are complained of, but in the deep-seated and papillomatous varieties burning sensations or pain of a lancinating character frequently develop late in the disease. Unless in close proximity to lymphatic glands, these, in average cases, rarely show involvement in the earliest months, and sometimes never during the whole course of the malady. But if closely situated, more especially with the deep-seated and papillomatous varieties, the lymphatics are sooner or later implicated. In the average run of cases of the type naturally gravitating to the dermatologic specialist, however, glandular implication, judged by my own observation, which covers a large aggregate number, is

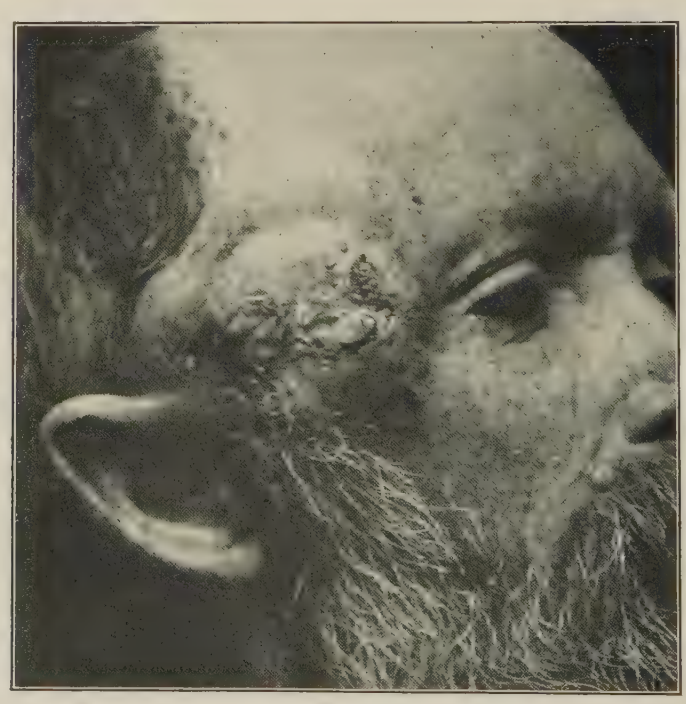

FIG. 187.—Epithelioma of deep-seated type in a man aged fifty-seven.

relatively rare; nor have I seen, with the exception of a few instances, a recurrence presenting itself in the glands. It is only fair to state, however, that most of my cases, fortunately, have happened to be

of the mild, superficial variety, with only in a moderate proportion of instances a disposition to a rapidly malignant tendency.

Etiology.—The cause of cancer is still an undetermined question. There are several factors, however, which may be considered as adjuvant or contributing that are well known. The majority, by far, of epitheliomata of the skin or adjoining mucous surfaces are observed in males. The malady is essentially one of advancing years, somewhat rare before the age of forty, and more commonly seen after fifty or sixty. Exceptional instances, it is true, are now

FIG. 188.—Epithelioma developing from a keratosis, in a case of psoriasis; the keratoses (some of which can be seen in the illustration) appearing after long-continued administration of arsenic.

and then noted, as in the recent cases recorded by Hartzell,[1] Allen,[2] and others, in which the growth presents in earlier years. Local irritation is likewise a recognized exciting agent. This is shown in the cases in which, from the accidental knock or other injury, often trifling, an ordinary wart, fleshy mole, or pigmented nævus of long duration begins to show epithelial development. The disease has also often been noted to start at the site of a scratch, cut, or other accidental traumatism; and the factor of pressure or irritation produced by the pipe-stem or cigar in the production of epithelioma of the lip in many instances is well known. A neglected or irritated senile seborrheic spot or keratosis often is, as already referred to, the starting-point of the disease. It has also developed

[1] Hartzell, "Epithelioma (Rodent Ulcer) in a Boy of Fourteen," *New York Med. Jour.*, Mch. 5, 1898 (refers to several recorded cases, with literature references).

[2] Allen, *Jour. Cutan. Dis.*, 1899, p. 571 (case demonstration, in man aged twenty-four, on the lip); *ibid.*, 1900, p. 122 (case demonstration—patient male, aged twenty-eight—on lip).

at the site of patch or ulceration of lupus vulgaris and syphilis, and exceptionally upon a lupus erythematosus. Hutchinson, White, Hartzell, and others have recorded cases developing, in psoriasis patients, from the keratosis following the prolonged administration of arsenic,[1] this drug, therefore, having apparently a direct—certainly indirect—influence. From time to time various claims as to the discovery of parasitic organisms have been made, but a judicial review of the evidence shows that this field of investigation has not, up to the present, borne convincing results, although it is, doubtless, here that the actual factor is to be found. In a careful paper in which the etiologic factors are gone over Hartzell[2] concludes as follows—a conclusion which the present state of our knowl-

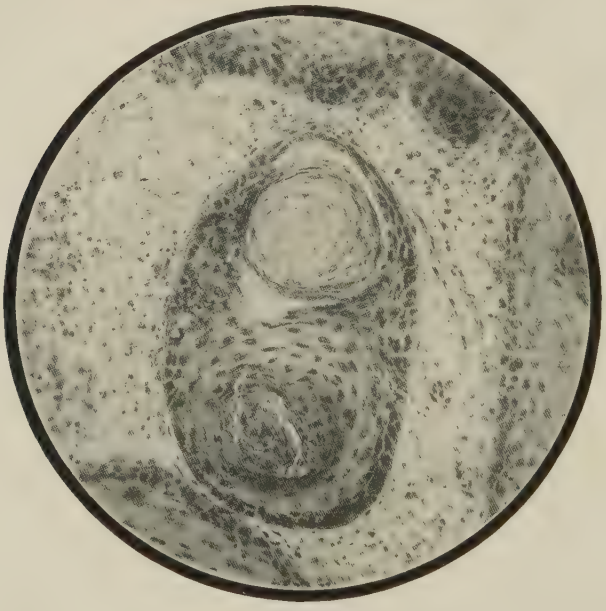

FIG. 189.—From a squamous-celled epithelioma, showing the so-called "pearls," "cell nests," or "globes" (courtesy of Dr. J. A. Fordyce).

edge as to the disease seems to justify: "We may regard it as fairly well demonstrated that carcinoma results from a profound and more or less permanent alteration of the mechanism of cell-division. This alteration may, in my opinion, result from long-continued irritation of a mechanical or chemical kind, including under this latter the effects of toxins resulting from micro-organisms. Accordingly it seems likely that the immediate causes of cancer are multiple."

Fordyce[3] is inclined to the belief that we have to do with an

[1] See dermatitis medicamentosa and psoriasis.

[2] Hartzell, "Etiology and Pathology of Malignant Diseases of the Skin Affecting Epithelial Tissue," *Jour. Cutan. Dis.*, 1900, p. 435.

[3] Fordyce, "Clinical and Pathological Observations on Some Early Forms of Epithelioma of the Skin," *New York Med. Jour.*, June 9 and 23, 1900 (an admirable presentation with case illustrations and histologic cuts).

infective process in which the agent producing the infection is probably the actively growing cells of the parent tumor.

Pathology.—Histopathologic studies of the epitheliomatous process which especially interests the dermatologist, show that it consists, briefly described, in the proliferation of epithelial cells—pavement epithelium—from the epidermis or from the epithelium of the hair-follicles or glandular structures,[1] or from the mucous membrane; the cell-growth takes place downward, in the form of finger-like pro-

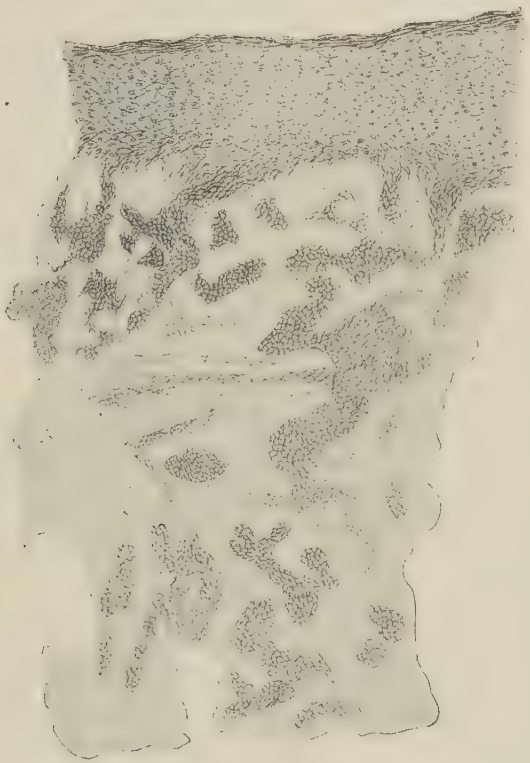

FIG. 190.—Epithelioma—section from the margin of a deeply eating rodent ulcer variety of the eye region; eye already destroyed (courtesy of Dr. A. R. Robinson).

longations or columns, or it may spread out laterally and deeply so as to form rounded masses, the centers of which usually undergo horny transformation, resulting in the formation of onion-like bodies, the so-called "pearls," "cell-nests," or "globes." The rapid cell-growth requires increased nutriment, and hence the blood-vessels become enlarged; moreover, the pressure of the cell-masses and their invasion of other tissues give rise to irritation and inflammation and consequent increased blood-supply, with corresponding serous and round-cell infiltration.

Epitheliomata of the skin histologically present two types, the

[1] As to its origin in the sweat-glands see Fordyce's paper, "Adenocarcinoma of the Skin, Originating in the Coil-gland," *Jour. Cutan. Dis.*, 1895, p. 41 (report of a case with histologic cuts and review and references).

lobulated and the tubular. The former, which is the more frequent, shows, as the name signifies, a massing of the epithelial new growth in the form of lobules, and each lobule is noted to be composed of concentric strata of cells, which correspond in their changes to the several strata of the epidermis—from those of the rete to those of the corneous layer. The innermost cells of the lobule show imperfect cornification, while the outermost cells correspond to those of the basic cylindric cells of the rete, those of between layers showing the various changes from the latter to the former. Owing to the pressure upon the central mass of cells, the onion-like bodies, or cell-nests, already referred to, are produced. These are usually found, at least most abundantly and of typical formation, in the deeper parts. In some instances this central portion undergoes colloid degeneration. Offshoots from the down-growing lobules are frequently noticed, and these present the same characters and undergo the same changes as in the parent lobules. When the epithelial masses are of rapid growth, the cells, from mutual pressure, may, in places, be spindle shaped. In the tubular or cylindric type the epithelial growth is in the form of cylindric processes, which freely anastomose with one another. They run usually more or less perpendicularly to the surface, but in some instances may be parallel to the epidermis and occasionally presenting a pseudoglandular appearance. The cells are composed of smaller cells than those of the other variety, and correspond more closely to those of the deeper layer of the rete. They show practically no tendency to horny transformation and the formation of the cell-nests, which occur in the lobulated types of growth.

The conditions in the rodent ulcer type are essentially those of tubular epithelioma, many observers believing that the epithelial proliferation takes its origin in the epithelium of the rete (Collins Warren, Robinson, Unna),[1] of the hair-follicle (Tilbury Fox, Colcott Fox, Sangster, Hume),[2] sweat-glands (Thin, Walker),[3] sebaceous glands (Thiersch, Butlin). Fordyce[4] views it as a small-celled epithelioma originating from the deep layer of the epidermis or the hair-follicles. Paul, Boyce, Darier, and others regard it simply as a slow-growing epithelioma which may start from the epithelium of any of the skin structures, and this view, judged by the various findings referred to, is probably the correct one.

Bodies thought to be organisms, supposed to be coccidia, have been found in cancer-cells, chiefly by Albarran and Malassez; they occur in very small number, and principally in the very center of the cell-nests, but the investigations and studies of Borrel[5] and Hutchinson, Jr.,[6] have led them to the conclusion that they are not

[1] Collins Warren, *The Anatomy and Development of Rodent Ulcer*, Boston, 1872; Unna, *Histopathology*.

[2] Tilbury Fox and Colcott Fox, *London Patholog. Soc'y Trans.*, vol. xxx., 1879, p. 360 (with histologic cuts); Sangster, *Brit. Jour. Derm.*, 1882, p. 777.

[3] Thin, *loc. cit.*; Walker, *Brit. Jour. Derm.*, 1893, p. 286.

[4] Fordyce, *loc. cit.*, and Morrow's *System*, vol. iii. (Dermatology), p. 655, to whose article I am indebted.

[5] Borrel, "Sur la signification des figures décrites comme coccidies dans les épithéliomes," *Arch. de méd. exper.*, 1890, p. 786 (with colored plate presenting 5 histologic cuts).

[6] Hutchinson, Jr., "On Psorosperms and Skin Diseases," *Brit. Jour. Derm.*, 1891, p. 277.

of parasitic nature. Welch, Noeggerath, Török, and others (cited by Fordyce), have also failed to substantiate the claims. Gaylord's interesting observations as to the presence of organisms are yet too recent and too incomplete to warrant a definite conclusion. Most of the findings so far made by investigators are thought to represent various forms of cell degeneration.

Diagnosis.—The main diagnostic points in epithelioma to remember are: the age of the patient; the usually single character of the growth; its beginning in a wart, mole, nodule, or scurfy spot; the character of the border—pearly, with roll-like elevation or a hard, elevated infiltration; the scant, and, in the later stages, viscid discharge, frequently streaked with blood; its usually slow progress; the frequent situation about the nose, eyelids, or other parts of the face; its finally involving, in many instances, the neighboring lymphatic glands, more especially when the lesion is seated near these structures. Microscopic examination of a section of the tissue is generally conclusive in doubtful cases.

The lesions from which it is to be differentiated are syphilitic ulceration, warts, and lupus vulgaris. The differentiation from the last is given under that disease. The tubercular ulcerating syphiloderm, like epithelioma, is frequently seated upon the face, but it differs in several particulars from the latter. It is usually multiple, consisting of several superficial ulcerations and not, as a rule, rounded in shape, but segmental or irregularly circinate. Tubercles which have not as yet undergone destructive change, or without such tendency, are also commonly seen in association with the syphilitic ulcerations, and with the same disposition to the segmental or serpiginous configuration. Moreover, syphilitic ulcers have, as a rule, quite a free discharge, and generally of distinctly purulent character.

Benign, warty-looking formations and fleshy moles are to be differentiated from those of beginning malignant growths by attention to their history and course; in fact, long-continued observation may be necessary before a positive opinion is warrantable. The appearance of any tendency to crusting, to break down, or ulcerate, is significant of epitheliomatous degeneration. Such a benign-looking lesion, showing, therefore, one or two fissures at the summit or edge of the base, or exhibiting slight abrasions, which are persistent, is to be viewed as a beginning epithelioma.

On the lip a persistent, localized thickening or abrasion of several months' or more duration, especially when on the lower lip, and occurring in an individual over forty, means almost always an epithelioma. The possibility of this region being the seat of the initial lesion of syphilis is not, however, to be forgotten, and in the earliest stage a differentiation is sometimes impossible, but the more rapid development of the latter, with usually but little tendency to active or large ulceration, and with soon the appearance of secondary symptoms of the disease, will serve for final differentiation. About the genitalia epitheliomata practically present the same features as elsewhere, frequently beginning as a warty-looking lesion, and slowly and gradually developing into a spreading infiltrated and destructive epitheliomatous ulcer. It is here to be distinguished from a chancre

and from the tuberculogummatous infiltration and ulceration of later syphilis.

Prognosis.—In an opinion as to prognosis in epithelioma several factors are to be considered—the variety, extent, duration, and rapidity of the process. In all instances the earlier treatment is instituted, the less chance is there of recurrence. In many cases of the more superficial forms, the disease, even if neglected, is slow in its progress, often lasting for ten, fifteen, or more years before seriously threatening the patient's life. Thin[1] records an extreme instance of a

FIG. 191.—Epithelioma of papillomatous type in a woman aged sixty-three.

cancerous ulcer of the rodent type in a woman aged sixty-eight, involving shoulder and upper part of the back, which had begun forty-three years previously as a pimple or wart. In the earliest stages of the cases ordinarily met with in dermatologic practice, when the disease is limited, on the face, and of a superficial type, treatment is almost invariably successful and permanently so. I have had a large number of such cases under my care, and if not far advanced or if not of the rapid, deep-seated, or papillomatous type, with no glandular involvement, the result has been uniformly good. Even when such cases are moderately advanced, the outlook is usually favorable. The same may be said of the deep-seated and papillomatous varieties if not of too long duration, but in these glandular involvement is, after a time, not uncommon, and quite the rule later. Cases in which conspicuous destruction has already ensued, and in which there is considerable surrounding infiltration and of long duration, the prognosis as to successful permanent removal is not so favorable, and particularly so if the glands are already infected. The rodent

[1] Thin, *London Patholog. Soc'y Trans.*, vol. xxix., 1879, p. 237 (was histologically of cylindric type and had apparently started in the sweat-glands).

ulcer type, when allowed to have full sway and neglected, and covering a large area, is of serious nature, removal, unless early and complete, often being followed by recurrence and finally death. Epithelioma of the back of the hand is usually responsive to proper measures, but the prognosis is not so favorable as with the ordinary face cases, and axillary gland involvement sometimes presents early. Epithelioma of the genitalia is always of serious import, although prompt action in the beginning disease is commonly successful.

Treatment.—The object to be kept in view in the treatment of the disease is the thorough destruction or removal of the epitheliomatous tissue. For this purpose operative measures are preferred by the surgeon, while the specialist in dermatologic practice usually favors the caustic plans. To a great extent, I believe this difference of opinion to be due to the fact that those cases coming under our care are relatively superficial and slight, circumscribed, and slow, whereas those coming to the knowledge of the surgeon are for the most part of a more serious, malignant, and extensive nature. The former do well and probably better with caustic methods, the latter with surgical measures. With well-defined, sharply circumscribed epitheliomata, especially if of the deep-seated and papillomatous varieties, surgical removal is to be given the preference, particularly if the lesion is seated upon parts of loose and soft texture, where excision can be followed by approximation of the edges and thus leave but a linear scar. When the neighboring glands are implicated, these, too, should be extirpated. Such cases, however, naturally belong to the domain of surgery. A combination of the surgical plan of thoroughly curetting the area and then following with caustic, such as the application of a 50 per cent. solution of zinc chlorid, or momentary cauterization with caustic potash or with several days' use of a strong pyrogallol salve, to be referred to later, constitutes a successful method, applicable in many instances. This latter plan is to be commended for epitheliomata of moderate size and infiltration. For those instances, however, in which the slightest mention of operative procedure is met with opposition or withdrawal, the caustic plans of treatment can be resorted to; and for the superficial skin cancers, those, as a rule, without glandular involvement, and which often come to the specialist in dermatology, I am convinced, from considerable experience, that the method is not only a practicable one, but usually permanently successful.[1] The effect of the caustic seems to extend beyond the escharotic action produced.

The favorite caustics are pyrogallol, zinc chlorid, caustic potash, and arsenious acid. After their use the subsequent treatment consists, when possible, of the continuous application of poultices until the slough comes away, and then a mild healing ointment of 1 to 2 per cent. pyrogallol salve, one of equal parts of mercurial plaster and petrolatum, or of zinc oxid. When poultices are not practicable, the healing ointment can be immediately applied after the

[1] See papers on the caustic treatment by Robinson, *Internat. Jour. Surg.*, 1892, p. 179, and 1893, p. 164, and *New York Med. Rec.*, Mch. 31, 1900; Gottheil, *The Treatment of Skin Cancers*, New York, 1899; Stelwagon, *Jour. Amer. Med. Assoc.*, Dec. 15, 1900; and Heidingsfeld, *ibid.*, July 13, 1901.

cauterization; in such instances, however, the slough comes away much more slowly. The part is washed once or twice daily, and oftener if there is much discharge. Pyrogallol is applied in the form of a salve of 25 to 40 per cent. strength, in the manner described under lupus vulgaris, and continued for from one to two or three weeks, according to the character of the growth and the rapidity of action. A good formula consists of the following:

℞.	Pyrogallol,	ʒiiss–iij (10.–12.);
	Ac. salicylici,	gr. xxv–l (1.65–3.33);
	Cerat. simp.,	ʒj–ij (4.–8.);
	Petrolati, q. s. ad	℥j (32.).

FIG. 192.—Epithelioma of papillomatous type; showing also old-age changes—freckle-like pigmentation and scurfy patches.

The amount of cerate depends upon the season, whether warm or cold. The formula also mentioned under lupus is equally available, and is sometimes to be preferred on account of greater adhesiveness. Pyrogallol is a relatively painless application, and has its chief field in superficial epitheliomata in old people who cannot bear well the stronger caustics; and also is of great value as a supplementary caustic to curetting, as already remarked. It is, however, a weak caustic and has a limited field. Like arsenic, it generally spares the healthy tissue.

Zinc chlorid is a caustic formerly much in vogue for its destructive action. It is painful and destroys morbid and healthy tissue alike. Its action is peculiar in that it seems to mummify the tissue, and therefore is especially applicable to epitheliomata situated over

blood-vessels. It is most commonly applied as Bougard's paste, but for satisfactory compounding it requires ordinarily somewhat more water than given, although it is advisable to exceed the quantity in the formula as little as possible, so that the paste may be like stiff dough, and then to add at the time of application a sufficient quantity of a saturated solution of cocain hydrochlorate to bring it up to working consistence. The formula is as follows: ℞. Farinæ trit. (wheat flour), pulv. amyli, āā ℥ss (16.); pulv. ac. arseniosi, gr. iv (0.26); pulv. hydrarg. sulph. rub., pulv. ammonii chlorid., āā gr. xx (1.33); pulv. hydrarg. chlorid. corr., gr. ij (0.135); zinci chlorid. cryst., ʒiv (16.); aquæ fervid., ℥j (32.). The first six ingredients are thoroughly mixed, the zinc chlorid dissolved in the water, and the two mixtures rubbed up together secundum artem. This is spread on any suitable material and applied to the growth, extending slightly beyond the border. The depth destroyed is usually one or two times the thickness of the layer of paste. It takes about twenty-four to forty-eight hours for sufficient destruction; it is sometimes necessary to remove the mummified mass by paring it away and reapplying a fresh plaster. There is considerable inflammatory swelling. In superficial lesions rarely more than one application is necessary. The separation of the slough requires from five to twenty days.

Caustic potash is a powerful caustic and must always be used with care. It is rapid in its action, one thorough application usually sufficing to destroy the entire growth. It has its special field in small and beginning cutaneous skin cancers, and in those in which time is important and in which the patient can remain under observation only a short period. The stick should be employed, or the strongest possible solution; the former is preferable. If the surface of the growth is crusted, this should be removed, and the parts outside of the diseased area protected with a layer of vaselin, after which the caustic is applied. If the lesion is small and superficial, the desired effect is usually sufficiently attained in a minute or two, and then further action is to be prevented by the application of dilute acetic acid or vinegar. This caustic is painful, but only at the time of application.

Arsenic is undoubtedly the best caustic to employ in many of these cases. It certainly has, relatively speaking at least, an elective action, ordinarily sparing healthy tissue, so that it is especially applicable in places where unnecessary destruction and disfigurement are to be avoided, as particularly about the nose and in the neighborhood of the eyelids. Marsden, Robinson, Gottheil, and others, including myself, who have employed it frequently, have never seen dangerous absorption from its cautious use. It may be employed in several strengths, according to the case and the effect required. Marsden, advised a paste (Marsden's paste) made of two parts of arsenious acid and one of mucilage of acacia. Robinson recommends two strengths, one of equal parts of arsenious acid and powdered acacia, and one of two parts of the arsenic and one of the acacia, using sufficient water at the time of application to make into a paste of the consistence of stiff butter. I have employed it, in most cases, in about equal proportions; in small and somewhat deep-seated

lesions, using two or three parts of arsenious acid to one of acacia, making up into a paste with a saturated solution of cocain hydrochlorate. It requires from twelve to thirty-six hours for sufficient action, producing a good deal of inflammatory swelling and edema; occasionally a second application is necessary. It is painful, but many patients prefer it to surgical operation. It is the principal ingredient in most of the quack cancer plasters. The slough separates slowly.

Electrolysis has also had occasional advocates for certain mild or slight cases—with the needle in small lesions or recurring small tubercles in the scar after other treatment; and with the small metallic plate, as in lupus vulgaris, in small flat growths. If used with a current of 5 to 20 milliampères, it is capable of active destruction.

The treatment of epithelioma by the Finsen concentrated chemic light method (see lupus vulgaris) has been favorably reported upon by some writers, among whom the latest, Bie,[1] who had, in 16 cases, a good proportion of satisfactory results. Finsen regards it as most favorable in those cases which are superficial and well demarcated. According to these observers, about 30 exposures, of about one hour each, are required, the growth gradually shrinking and healing.

The plan of treatment most in vogue at the present moment is that by the X-ray. The experience of Williams, Pusey, Pfahler, and many others, including myself, attests its favorable and sometimes curative action. It is usually slow, and on this and other accounts is not, as a rule, to be advised as the sole measure of treatment; in superficial forms, especially when involving the neighborhood of the eye, it often acts well and comparatively quickly. Its special field of usefulness is, in my opinion, as a supplementary measure to those methods already practised and described above. To secure a result it must often be pushed to the point of producing a mild erythema or even decided dermatitis. Exposures are made every one to three days, at a distance of 3 to 15 inches, and of six to twenty minutes' duration, depending upon the effect; and in superficial cases or those of but slight or moderate depth with a soft to medium tube. It is not a good plan, however, to use a tube of the same degree of vacuum throughout; otherwise some possible deeper-lying morbid tissue may escape its favorable action. I have found it a good plan to begin the séance with a vacuum equal to about a ½-inch spark, and then to do away with the regulator; the vacuum slightly rises, and the whole depth of tissue gets its share of the full effect of the rays.[2] The surrounding parts are to be protected by thin lead foil. The first effects consist of a drying-up of the secretion and a gradual shrinking of the ulcerated area. Some cases are much more responsive than others, and a few fail to show any marked change. In some cases favorable influence in cancerous growths follows the application of radium,[3] and in a few instances under my own care it has been a help; but while its emanations are doubtless closely similar in their

[1] Bie, *Dermatolog. Zeitschr.*, Aug., 1900, p. 630—abs. in *Brit. Jour. Derm.*, 1900, p. 376.

[2] The details on X-ray treatment are more fully given under General Remarks on Treatment, in the first part of the volume.

[3] Abbe, "Radium in Surgery," *Jour. Amer. Med. Assoc.*, vol. xlvii., 1906, p. 183.

action to X-rays, the effect is relatively slight, much less certain, and limited to the immediate point of application.

From time to time various remedies have been suggested for constitutional administration as having a favorable action in certain instances; arsenic has had the most frequent mention, but, excepting a few observers, it has but little support. Sherwell[1] is convinced of its value, and makes its administration a routine practice, along with proper local measures; Lassar[2] has also reported favorable effects.

XERODERMA PIGMENTOSUM.[3]

Synonyms.—Angioma pigmentosum atrophicum (Taylor); Dermatosis Kaposi (Vidal); Atrophoderma pigmentosum (Crocker); Melanosis lenticularis progressiva (Pick); Liodermia essentialis cum melanosi et telangiectasia (Neisser); Lentigo maligna (Piffard); Epitheliomatose pigmentaire (Besnier).

Definition.—A malignant disease, usually developing in early life, characterized primarily by freckle-like spots, especially upon exposed surfaces, followed by telangiectases, atrophic changes, angiomatous and verrucous lesions, with increased pigmentary deposit, and finally, generally after some years, by epitheliomatous growths and fatal ending.

This malady was not known until Kaposi described it in 1870, but since then new cases have been observed, so that, at the present time, over 80 are on record. In this country cases have been reported by Taylor, Duhring, White, Brayton, Hutchins, A. H. Bowen, and others.

[1] Sherwell, "The Use of Arsenic, etc., in Cancerous and Other Neoplasms," *Med. Record*, Apl. 28, 1900 (strongly advocates the acid nitrate of mercury as a caustic for epithelioma).

[2] Lassar, *Berlin. klin. Wochenschr.*, 1893, p. 83.

[3] Literature: Kaposi, *Wien. med. Jahrbücher*, 1882, p. 619 (with 4 colored plates showing 4 patients, and 3 histologic cuts); and *Wien. med. Wochenschr.*, 1885, p. 1334 (case demonstration, with brief report and a tabulation of 38 cases); Taylor, *Med. Record*, Mch. 10, 1888 (detailed history of 7 cases, extending over fourteen years, and tabulated history and abstract (including his 7) of 40 cases to date); Archambault, "Dermatose de Kaposi," *Thèse de Bordeaux*, 1890 (review of cases); Lukasiewicz, *Archiv*, 1895, vol. xxxiii., p. 37 (with 8 excellent histologic cuts). These several papers cover 73 cases recorded to date. Phillips, *St. Bartholomew's Hosp. Reps.*, 1895, p. 221; West (same case as the preceding), *Brit. Jour. Derm.*, 1896, p. 45, and 1898, p. 57; Crocker, *ibid.*, 1896, p. 442 (case demonstration of one of his previously reported cases); Pringle, *ibid.*, 1897, p. 157 (case demonstration—patient aged three); Falcao, *Trans. Third Internat. Derm. Cong.*, London, 1896—abs. ref. in *Jour. Cutan. Dis.*, 1897, p. 173 (reported case of woman, aged eighty-eight, and refers to 3 others observed by him, aged respectively seventy-two, eighty-nine, and ninety—these are rather suggestive of cases of atrophia senilis); Jamieson, *Brit. Jour. Derm.*, 1898, p. 325 (case demonstration, girl aged six—a younger sister also showing suspicious freckling); Bareldt, *Brit. Med. Jour.*, 1898, ii., p. 1342 (brief report; patient aged two and a half); Bronson, *Jour. Cutan. Dis.*, 1899, p. 572 (case demonstration—girl of eight, first evidence when six months old); Okamura, *Archiv*, 1900, vol. li., p. 87 (report especially as to blood examinations of 3 cases); Hutchins, *Jour. Cutan. Dis.*, 1893, p. 402; Brayton, *ibid.*, 1892, p. 129 (with colored plate), and *Jour. Amer. Med. Assoc.*, Apl. 29, 1899 (3 cases in same family); A. H. Bowen, *ibid.* (1 case). The case by Duhring, *Amer. Jour. Med. Sci.*, Oct., 1878, and 2 (brother and sister) by J. C. White, *Jour. Cutan. Dis.*, 1885, p. 353, are included in Taylor's summary and review; Francoz, *Contribution a l'etude du Xerodermia pigmentosum, Thèse*, Lyon, 1905 (complete bibliography); Nicolas and Favre, *Annales*, 1906, p. 536 (clinical and histologic; 2 cases, 1 a woman aged seventy-one).

Symptoms.—This rare disease begins almost invariably in the first year or two of life, and probably most frequently at the age of five or six months. The first symptom noted consists of lentiginous spots, scarcely, if at all, distinguishable from ordinary freckles. These are more particularly observed in summer or after sun-exposure, and especially upon exposed portions, the disease at this time being more or less confined to the face, scalp, neck, upper shoulders, hand, and forearms. The scalp is not often affected, although sometimes scaly; in Duhring's case, however, this region was notably involved. These lesions may disappear in winter, and reappear the following summer; this may occur once or several times; finally they remain, and become more intensely pigmented. Not infrequently an erythematous condition of the skin due to sun- or wind-exposure precedes the appearance of the freckles. Shortly following the first outbreak, or some months afterward, telangiectases are also noted, and atrophic white spots begin to present, scattered irregularly among the other lesions, and here and there with a tendency toward coalescence, resulting in larger, rounded, or irregular cicatricial-looking areas, upon which the skin is often smooth, shiny, and wrinkled, and sometimes covered with thin scales; or the surface has a stretched, glistening appearance, with, in some areas, a pinkish tinge, and with the veins showing through. The sensibility of the atrophic areas is sometimes lessened, and the sweat-glands are less active. The freckle-like spots, which may be rounded or irregular in outline, gradually increase in numbers and in places seem almost confluent; in others the skin is noted to be considerably darkened in hue, with a freckle-like accentuation here and there. The discoloration is most marked on exposed parts, and primarily, as a rule, only there, but in some instances, especially later on, covered surfaces may display a similar, blotchy pigmentation. The telangiectases are usually upon uncovered surfaces, and consist of minute, red, pin-point to pea-sized spots, vascular twigs, and, particularly later, small angiomatous growths. The vascular lesions are more noticeable in the leukodermic areas.

The malady may thus continue for months or several years. As a rule, sooner or later more positive changes ensue. Some of the pigmented spots become elevated, thickened, and papillomatous, and when small, apparently similar to warts. At this stage, therefore, pigmented, freckle-like lesions, clearly pigmented areas, atrophic, thinned, glistening, or slightly scaly, white, cicatricial spots and plaques, and pit-like depressions, dark warts, and small, dark, warty-looking patches, with scattered telangiectases and some small angiomatous growths, are to be seen—for the most part on the face, ears, neck, upper chest, hands, and forearms, although often to some extent upon other regions. Ectropion and ulcerative keratitis are usual concomitants, and there may also be cicatricial contraction about the nose and mouth. The skin of the affected regions is more or less atrophic, somewhat thinned, stretched-looking, and hence the term xeroderma, or parchment skin. While the various lesions often arise without any dependence one upon the other, in some, according to Kaposi, the pigment spot gradually becomes telangiectatic, and later undergoes sclerosis, atrophy, and whitening. Taylor thought the pigmentation followed

upon the telangiectasis, but Duhring, White, and others recognized that, at least as to most early lesions, there was no interdependence. In some instances the melanoderma has been more or less uniform and wide-spread. The disease frequently remains relatively or completely quiescent for several months or longer,—in one of Crocker's cases for a period of six years,—although, as a rule, there is a steady progress, with a tendency of the sclerosed skin to undergo superficial ulceration. In most cases, after several years or much longer,—ten to thirty years in some instances,—the verrucous and angiomatous growths or the pigmented spots become the seat of malignant changes of an epitheliomatous or sarcomatous character,—so that ulcerating growths, one, several, or more, are added to the already described symptom-complex. The patients, as the disease persists, usually become despondent and depressed, brooding over the disfigurement and hopeless character of the malady.

The case thus progresses, and in rare instances there is malignant involvement of the internal organs. As a rule, however, the process is confined to the integument, sometimes involving the mucocutaneous junctions, and in rare instances insignificant pigment or telangiectatic lesions on the palpebral conjunctiva, lips, and buccal cavity are seen. The general health of the patients, which is often apparently undisturbed in the first years of the malady, now begins to suffer from the pain and the drain of the malignant, ulcerative formations, and a condition of marasmus or exhaustion is gradually engendered, and death finally results, although this does not usually take place until many years after the first appearance of the lesions. In rare cases, after some years, the disease remains stationary. These malignant growths may be scanty in number, or may constitute the chief feature at this time; as soon as they present, the malady immediately becomes a grave one, as the end generally ensues sooner or later. In some instances the tumor growths appear, as in Falcao's case, within a year or so after the first appearance of the disease; in some the pigment spots may be scanty, as in Stern's case, and the tumor element conspicuous; in others the freckling may remain the chief feature of the disease for many years before its serious character develops. In Brayton's case, at the time of his report, the patient had already had the disease sixteen years without serious lesions save the ectropion, and was still enjoying good general health. As a rule, there are no subjective symptoms, although the ulcerative tumors are sometimes quite painful.

Etiology.—The disease has its beginning, as a rule, in early life, although in exceptional instances (Schwimmer, Riehl, Kaposi, Hutchins, and a few others) it has first presented after the fifteenth year. It apparently occurs in both sexes indifferently, and in those variously circumstanced. It is frequently met with in two or more members of a family, and in some instances there seemed a hereditary or congenital predisposition. Five of Taylor's 7 cases occurred in two Jewish families, and 2 of his cases were cousins of 3 others. White's 2 cases were brothers, and a brother of Brayton's 2 cases had died from the malady. Rüder had 7 brothers with the disease in a family of 13 children, and so might be added the records of others, although,

except Rüder's observation, no other instance of more than 3 cases in the same family has been recorded. Some authors are inclined to consider the sunlight as a factor in starting the pigmentary process; in support of this the observation has been made (Lukasiewicz, Eulenberg, and others) that such children frequently develop an erythema solare or similar condition after sun- or wind-exposure. This is scarcely to be considered more than an accidental element, and even with such an assumption there must be a peculiar inherent susceptibility. The behavior of the disease and its frequent occurrence in 2 or 3 members of a family have suggested a parasitic and contagious cause, but the investigations of Funk and others in this direction have disclosed nothing tangible. Kaposi's belief that the malady has its basis upon a congenital formative and nutritive anomaly of the vascular and pigmented portions of the papillary layer is somewhat disparaged by the observation of its occasional beginning in later life. In fact, beyond the significance of its family prevalence, nothing definite is known as to its true etiology.

Pathology.—The disease is an atrophic degenerative process, with, doubtless, an underlying neurosis and congenital tendency. That does not, however, take us very far, and the accruing number of cases now on record—over 80—do not seem to have added much to our knowledge of the subject. The oligocythemia shown by Okamura's blood investigations of 3 cases is, as he suggests, probably due to functional skin impairment, resulting from the integumentary changes, and, therefore, of no special significance. The pathologic histology has been studied by numerous observers (Kaposi, Crocker, Taylor, Vidal, Quinquaud, Unna, Pollitzer,[1] and others), and discloses the usual changes which the different lesions suggest. In fact, there is no distinctive characteristic, the usual conditions[2] found in lentigo, atrophy, verruca, nævus pigmentosus, papillomatous and malignant growths, being correspondingly exhibited in the various lesions of the disease. French observers are inclined to consider the malady of the nature of a pigmentary epithelioma. Pollitzer states that in one section of a tumor growth examined by him characters of epithelioma, sarcoma, myxoma, granuloma, etc., with, however, the features of the first (epithelioma) predominating, could be seen. As already observed, by some the vascular changes are considered primary, by others as secondary.

Diagnosis.—A well-developed case—with the pigmentary spots, telangiectases, atrophy, new growths, etc.—can scarcely be mistaken for any other affection. The earliest stage, with merely the freckle-like lesions, probably is indistinguishable from ordinary freckles, although the distribution over face, neck, shoulders, hands, and forearms might suggest further observation. As a rule, these cases rarely come under notice before the telangiectatic and atrophic tendencies have presented, and the malady is then generally readily recognized. Scleroderma, with its accompanying pigmentation, sclerosis, and atro-

[1] Pollitzer, *Jour. Cutan. Dis.*, April, 1892, gives a good résumé of the histologic findings of the various investigators.

[2] Kaposi has given the different histologic phases in 9 cuts in his article in *Twentieth Century Practice*, vol. v. (Diseases of the Skin).

phy, might, if carelessly considered, be confounded with the disease, but the inception and the extent and characters of xerodèrma are wholly different from the former. It could scarcely be confused with lupus or with macular leprosy.

Prognosis and Treatment.—The prognosis has been touched upon sufficiently; the outlook is unfavorable, the delayed tumor formations indicating long duration, while their early appearance usually foreshadows an early end.

No plan of treatment has yet been noted to have a favorable influence upon the course of the disease. Arsenic, mercurials, potassium iodid, cod-liver oil, etc., apparently have proved without result. The subcutaneous injections of arsenic in increasing dosage might be worthy of a thorough and long-continued trial. The therapeutic management of the disease is essentially palliative; protection against sun- and wind-exposure is advisable. Ulcerative lesions often heal under mildly stimulating antiseptic salves, or used conjointly with curetting; excision of troublesome tumor growths is usually followed by healing. The eye conditions require attention, a boric acid lotion applied freely and often being the most satisfactory. By persistent care the patient is certainly made more comfortable, epitheliomatous development possibly delayed, and life probably prolonged some years.

SARCOMA CUTIS.

Synonyms.—Sarcoma of the skin; Sarcomatosis cutis; *Fr.*, Sarcome cutané; Sarcomatose cutanée.

The cases may be conveniently, but somewhat arbitrarily, divided into three classes: (1) Non-pigmented sarcoma, local or generalized; (2) melanotic sarcoma; (3) multiple pigmented (hemorrhagic) sarcoma, the last being that form originally described by Kaposi. This division corresponds essentially to that adopted by De Amicis, whose observation of sarcomatous cases has been unusually extensive.[1]

Primary Single or Localized Non-pigmented Sarcoma.—This is a relatively less malignant type of sarcoma than other forms, and may remain as a single or localized, slowly growing tumor for some months or years before destructive changes set in or more or less generalized and metastatic growths appear. It varies considerably in size in different cases: it may be small, scarcely larger than a good-sized pea, or more commonly the dimension of an egg or an orange. According to Perrin, the original tumor rarely, if ever, exceeds the latter size. In color it may remain almost that of the normal skin, but is usually pale red or bluish, with often the surface showing dilated

[1] De Amicis, *Trans. Twelfth Internat. Med. Cong.*, at Moscow, 1897; abs. in *Brit. Jour. Derm.*, 1897, p. 440.

Some other valuable general literature: Perrin, "De la sarcomatose cutanée," *Thèse de Paris*, 1886, with review of the subject and bibliography to date; Funk, "Klinische Studien über Sarkome der Haut," *Monatshefte*, 1889, pp. 19 and 60 (with numerous references); De Amicis, *ibid.*, vol. xxv., 1897, p. 309 (with some references); Fordyce gives a good account in Morrow's *System*, vol. iii. (Dermatology); J. C. Johnston (Sarcoma and the Sarcoid Growths of the Skin), *Jour. Cutan. Dis.*, 1901, p. 305, reviews the whole subject, illustrated by many admirable photomicrographs; Lieberthal, *Jour. Amer. Med. Assoc.*, Dec. 6, 1902, p. 1454 (with references); Pernet, Congenital Sarcomata, *Trans. Path. Soc'y*, London, vol. liii., 1902, p. 360.

capillaries. In some instances the blood-vessels of the tumor, which are generally abundant, may be large and well developed—sufficiently so to give to the touch a perceptible pulsation. In shape it may be nodular, encapsulated, mushroom-like, or somewhat diffused in outline, and occasionally pedunculated. In its earliest stage it may be cutaneous or subcutaneous in situation. It originates commonly from some local injury or other formation, such as warts, vascular or pigmented nævi, sebaceous cyst, etc., or in some instances apparently from the healthy skin. It is met with at all ages and in both sexes.

Generalized Non-pigmented Sarcoma.—In this form several or more tumors may appear simultaneously at near or remote points, or it may result from a primary single sarcoma, as already described, or in association with leukemia and pseudo-leukemia. Arning, Joseph, Touton, Wagner, Funk, and others (quoted by Fordyce) have reported, in connection with the latter affection, the general development of pea- to walnut-sized, waxy, dark-red or bluish, cutaneous and subcutaneous tumors, forming adhesions to the skin, with more or less intense itching, and in some instances tending to break down and ulcerate. It is not improbable that some of the cases associated with leukemia reported by Biesiadecki, Kaposi (lymphodermia perniciosa), Hochsinger and Schiff, Besnier, Vidal, and others have been more closely allied to granuloma fungoides than to leukæmia cutis or to true sarcomatosis. Both Vidal and Paltauf[1] have called attention to this point. Some cases, too, of generalized cutaneous distribution doubtless are secondary to an overlooked sarcoma in a visceral organ, in lymph-glands, testicle (Köbner), parotid gland (Holden and Butlin). There are instances, however, in which this type of generalized sarcoma seems primary in the skin. In general non-pigmented sarcomata the skin overlying the tumors may be close to the normal hue, with a reddish or bluish cast, or it may be, especially later in the disease, of a dark-blue color. The growths, which are somewhat variable as to size, as in primary single sarcoma, are seated primarily either in the cutaneous or subcutaneous tissue, and may be present in scanty numbers or extremely numerous, as in Cheever's case,[2] a woman aged sixty-five, in whom all parts except the head were the seat of nodular, ulcerating lesions, some of which underwent involution. In other instances the growths are more or less crowded and limited to one region, a rather remarkable example of which came under the notice of Cohn,[3] in which, in a woman aged fifty-two, the entire scalp and temporal regions were the seat of numerous and bunched, cherry- to egg-sized and larger growths.

This class of sarcomata, in some of its cases, approaches somewhat closely to the third division—the multiple pigmented sarcoma of Kaposi; and in others, especially the cases in which a tendency to ulceration is exhibited, the similarity to granuloma fungoides is

[1] Paltauf, "The Lymphatic Affections of the Skin," *Trans. Second Internat. Derm. Cong.*, Vienna, 1889.

[2] Cheever, *Boston Med. and Surg. Jour.*, Jan. 14, 1885 (also seen by Dr. J. C. White).

[3] Cohn, *Jour. Cutan. Dis.*, 1892, p. 393 (with illustrations).

also striking, this latter being considered by some observers as in reality a variety of sarcoma, a view that clinically, as to the tumor stage, has much apparent support, but which is not borne out by the history, course of the malady, and the histologic findings. Their occasional striking resemblance to granuloma fungoides is recognized in the name proposed by Perrin for this variety of this class,—generalized primitive pseudomycosic sarcomatosis of the skin,—and also that by Funk, of multiple idiopathic gummatoid sarcomata of the skin, a suggestive example of which is reported by Bowen,[1] and another by Minne,[2] and indicative of possible transition cases. The course of generalized sarcomata is a variable one, and, according to Perrin, death usually ensues within two years after the cutaneous growths have appeared. The multiplication of the growths is supposed to be due to dissemination of the morbific cells through the agency of the blood circulation.

Melanotic Sarcoma.—This variety, the second class of De Amicis, is the most malignant, usually running a rapid course. It is often confused with sarcomata of other varieties showing discoloration, but between such and true melanotic sarcoma, as Hartzell[3] states, a distinction must be made; the coloring-matter of the latter is presumably a product of the cells of the neoplasm, which frequently has its origin in tissues normally pigmented, as the choroid and pigmented nævi, whereas in the former the origin of the pigment is, for the most part, hematic. If the conclusions of Unna,[4] Gilchrist,[5] Waelsch,[6] Whitfield,[7] Darier,[8] and a few others[9] are to be accepted,—that the cells in pigmented moles which give rise to melanotic growths are in reality of epithelial origin,—then the tumor of this variety thus originating must of necessity, as these observers contend, be taken from the sarcomatous class and transferred to the carcinomatous. In a recent valuable paper, Johnston[10] takes

[1] Bowen, "Mycosis Fungoides and Sarcomatosis," *Jour. Cutan. Dis.*, 1897, p. 65.

[2] Minne, *Annales*, 1899, p. 751.

[3] Hartzell, "Sarcoma Cutis," *Jour. Cutan. Dis.*, 1893, p. 21.

[4] Unna, *Histopathology.*

[5] Gilchrist (A Case of Melanotic Sarcoma, Primary in the Skin, in a Negro, with Pathology), *Trans. Amer. Derm. Assoc. for 1898.*

[6] Waelsch, *Archiv*, vol. xlix., 1900, p. 249 (with 6 colored histologic cuts).

[7] Whitfield, *Brit. Jour. Derm.*, 1900, p. 267.

[8] Darier, *La Pratique Dermatologie*, vol. iii., 1903.

[9] Schalek (Histogenesis of Melanosarcoma Cutis), *Jour. Cutan. Dis.*, 1900, p. 147, has contributed a valuable, original, and review paper on this subject, based upon examination of several cases. See also paper by Heitzmann (Microscopic Studies on Melanotic Tumors of the Skin), *Jour. Cutan. Dis.*, 1888, p. 201 (with illustrations), which also has some bearing upon this point.

[10] James C. Johnston, "Melanoma," *Jour. Cutan. Dis.*, Jan. and Feb., 1905. A monograph that reviews the whole subject, with case citations, original investigations, numerous histologic cuts, and complete bibliography. His conclusions are: 1. Aside from the natural division into choroid and skin tumors, melanotic neoplasms, which, from their diversity of origin, are best called melanomata, show several varieties. 2. The commonest, and therefore most important, is that derived from soft nævi which are endotheliomata of lymph-vessel origin. Nævomelanoma, whose histogenesis it is not possible to determine, must be referred to the same origin. 3. A second variety exists with the same histologic pictures, which does not spring from nævi, and whose origin is directly traceable to endothelium, probably also lymphatic. This group includes melanotic whitlow and the malignant lentigo of the French. 4. The third division is truly epithelial in origin, although its existence has been denied. These tumors are of various types and show only a very slight tendency to malignancy, a fact sufficient in

issue with the conclusions of these investigators, and joins the German general pathologists in support of the view that has generally been held until recently, that the malignant growth, called by Unna melanocarcinoma, takes its origin from the lymphatic endothelium. In addition to the points of origin named, melanotic sarcoma may originate in any pigmented spot in the skin, although in some instances its source is not readily demonstrable. It not infrequently has its origin on the hands or feet, at the dorsal or lateral aspects, sometimes the first evidence presenting being an easily abraded black superficial blister. Funk states that the initial evidence is sometimes noted to be dilated capillaries or a purpuric spot, or its first step may be the "melanotic whitlow" of Hutchinson, beginning, as this observer and also Duplay and Hallé have described, as a pigmentation around the border of a nail. The first changes in melanotic sarcoma may be slow and insignificant, consisting simply of a dark-colored abrasion with a smooth, irregular, or slightly fungating surface. Or there may be an insignificant tumor growth, pea to small nut in size. In other instances the early appearances, as in Stowers's [1] case, involving the left ear in a girl of eleven, consist of a slate-colored, a somewhat uneven and verrucous area, or the patch may be smooth and slightly thickened. Its course is rapid, general involvement soon ensuing, as illustrated by a case under my care in a woman aged fifty; the development was extreme, numerous tumors not only in the skin, but also in the mouth, throat, and eye, with a general discoloration of the skin and mucous membranes, death ensuing from exhaustion within a year after the disease first presented.

Multiple Pigmented (Hemorrhagic) Sarcoma.—The cases of this, the third, class division made by De Amicis, are those known as multiple pigmented sarcoma of Kaposi,[2] who first described the disease upon a basis of an observation of 5 cases, to which were later added others, making a total in all of 25 patients. The number has been added to by various other observers, among the earliest of whom Vidal, Wigglesworth, De Amicis (11), Semenow (10), Donner, Hardaway, Duhring, Hallopeau, Funk, Schwimmer, and Mackenzie. In more recent years reports of new cases have been made by Fordyce,[3] Sherwell,[4] Brayton,[5] Magliano,[6] Wende,[7] Bernard,[8] Sequeira,[9] and others, so that the aggregate is becoming fairly large.

itself to determine a cardinal difference from the melanoendotheliomata, whose capacity in this connection can hardly be exaggerated. 5. A histologic diagnosis is the only proper method of differentiation between the two.

[1] Stowers, *Brit. Jour. Derm.*, 1893, p. 305.

[2] Kaposi, *Pathologie und Therapie der Hautkrankheiten*, fifth edit., p. 922.

[3] Fordyce, *Jour. Cutan. Dis.*, 1891, p. 1, with colored plate; this and Schwimmer's case report (*Internat. Atlas*, ii., plate iv., 1889) give references to previous cases.

[4] Sherwell, *Amer. Jour. Med. Sci.*, Oct., 1892.

[5] Brayton, *Indiana Med. Jour.*, Nov., 1893.

[6] Magliano, Morgagni, xxxvi., May, 1894—abs. in *Brit. Jour. Derm.*, 1895, p. 196.

[7] G. W. Wende, *Jour. Cutan. Dis.*, 1898, p. 205 (with illustrations and histologic cuts).

[8] Bernard, *Archiv*, vol. xlix., 1899, p. 207 (2 cases with review of the literature).

[9] Sequeira and Bulloch, *Brit. Jour. Derm.*, 1901, p. 201 (case, with colored plate and brief review of subject, with numerous references). Some later reports: Bernhardt, *Archiv*, 1902, vol. lxii., p. 237 (with references); Koehler and Johnston, *Jour. Cutan.*

The malady, with rare exceptions, first presents upon the extremities, and usually simultaneously. The beginning lesions may be small-nodular, discrete, aggregated, or crowded together, and scarcely exceeding a pea in size. In some instances or in some areas, instead of distinct tumor formation there is a thickening or diffused infiltration. In color they may vary from a reddish-blue to a purplish color; on the lower extremities a dark-brown shade or even a blackish hue may be observed. The growths and areas of infiltration are generally of firm consistence, and may be spontaneously painful, or more usually simply tender upon pressure. Occasionally growths are observed somewhat suggestive of angiomata, and which can be made smaller when firmly pressed upon. In some tumors there may be a central depression, probably from partial involution changes or relatively more active peripheral growth. Complete involution is noted at times in some growths, disappearing and usually leaving a somewhat depressed, stained area or scar. Some, after having lasted some months, may exhibit ulcerative tendency, but, as a rule, this is exceptional, and only observed late in the disease. Dilated capillaries around the nodules and interspersed are frequently seen. The progress of the malady is a steady one, new growths and infiltration being added from month to month; the legs, especially below the knees, show much thickening and deformity, presenting a mild degree of elephantiasis-like enlargement. When well advanced, the general health is gravely affected, the mucous membranes are invaded, and, according to the findings of autopsies, the visceral organs are also sooner or later involved. The average duration of the malady is, according to Kaposi, whose experience is the largest, about four years.

Etiology.—Possible etiologic factors have been casually mentioned in describing the several varieties. The causes are yet to be discovered. Beyond the effect of local irritation being an important starting factor in some instances,—more especially the single non-pigmented and melanotic varieties,—nothing is practically known. Scarcely any age is exempt from the malady, although most cases are probably seen under twenty and over forty.[1]

In multiple pigmented sarcoma no light has been thrown upon its origin. It is almost wholly observed in males, and after the age of forty. I have met with 2 instances of the disease, one a male, the other a female, and both past middle life, the disease running a fatal course in four or five years. All of Kaposi's cases were males, and Sequeira (*loc. cit.*), out of 73 cases in the literature, found a record of only 5 females, and was not sure that all of these were examples of the disease. His investigation disclosed also that most of the men

Dis., 1902, p. 5 (with case illustration and histologic cuts); Sellei, *Archiv*, 1903, vol. lxvi., p. 1 (with plate and bibliography); Krzysztalowicz, *Monatshefte*, 1904, vol. xxxviii., p. 215 (includes 2 cases—histologic); Parkes Weber and Daser, *Brit. Jour. Derm.*, 1905, p. 135; and histology of this case and histologic review, with references, by Macleod *ibid.*, 1905, p. 173.

[1] F. A. Packard, *University Med. Mag.*, Apl., 1891, has reported a case of multiple sarcoma (lymphosarcoma) cutis in a male infant of six months, beginning when aged seven or eight weeks by the appearance of two or three pea-sized nodules of purplish color on the back, the disease running a fatal course in six months.

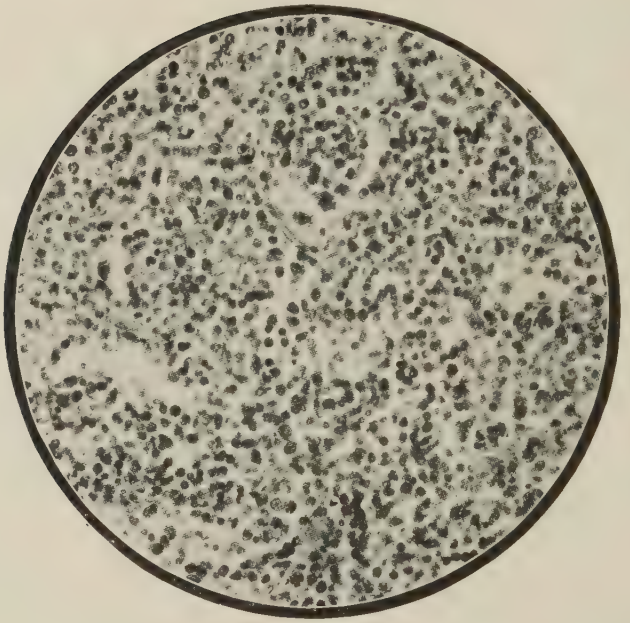

FIG. 193.—Small round-celled sarcoma (× 250) (courtesy of Dr. J. C. Johnston).

were of powerful build. According to Sequeira, in 3 instances the disease began after a chill; gout was present in 4 cases, and rheumatism and valvular cardiac disease were also observed in some instances.

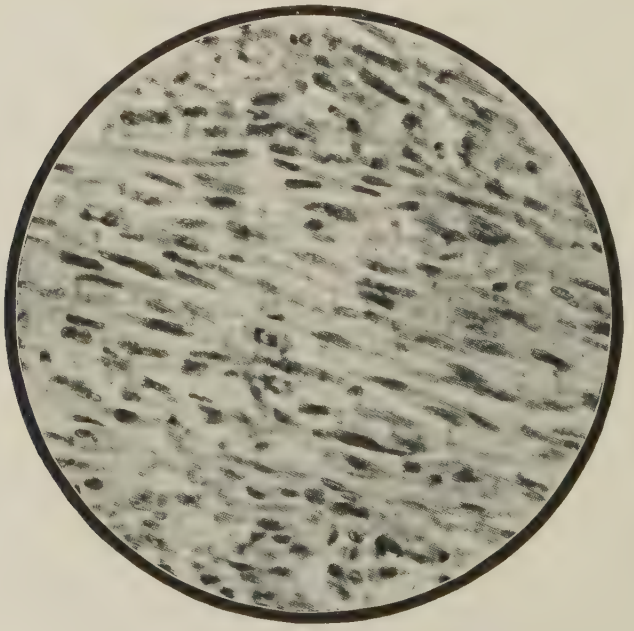

FIG. 194.—Spindle-celled sarcoma (× 250) (courtesy of Dr. B. H. Buxton).

Pathology.—The growths of the non-pigmented variety are made up chiefly of round cells or mixed round and spindle cells. A case of a moderate number of tumors, observed by Crocker,[1] in which the early lesions were all excised, these were typical of alveolar sarcoma, whereas the tumors which subsequently recurred were round-cell sarcomata. Hartzell also noted, in a case under his care of numerous sarcomatous growths on the leg, that the histologic features of these tumors bore but a faint resemblance to those of the growths which subsequently appeared in the stump. In the cases associated with leukemia (leukæmia cutis) and pseudoleukemia (quoting Fordyce), "the structure of the tumors is composed of small round cells of the size and appearance of white blood-corpuscles; in the early stage of development forming nodular collections at the junction of the cutis and subcutaneous cellular tissue." Sarcomata of the spindle-cell and mixed type have also been observed in leukemic subjects. Occasionally growths show a predominant fibrous character (fibrosarcoma) or excessive lymphatic element (lymphosarcoma) or the growths are made up of connective-tissue elements, originating from the adventitia of the vessels, with conspicuous development of new blood-vessels (angiosarcoma).[2] In melanotic sarcoma spindle cells and small and large round cells have been variously observed, although generally the tumors are composed of spindle-shaped cells. These growths have also been noted to be of the alveolar type. The pigment, as already stated, is a product chiefly of the neoplasm cells, the growths usually originating from normally pigmented tissue.

Multiple pigmented sarcoma, Kaposi (*loc. cit.*) states, is a round-cell growth, except that in a few places the characters of spindle-cell sarcoma are seen. The pigmentation is due to the capillary hemorrhages noted. Other observers have found a predominance of fusiform cells—in Fordyce's examination arranged in bundles extending longitudinally, transversely, and obliquely, their transverse sections looking not unlike round cells. Wende (*loc. cit.*) also found spindle-cell nests as a predominant feature. Macleod, from his examination of Weber and Daser's case, clinically characteristic of the affection, states "that histologically it was not a sarcoma, but a growth of organizing connective-tissue cells associated with marked vascular dilatation, edema, and the deposition of blood-pigment." While its classification is not yet definitely decided, it seems closer to the granulomata than to the sarcomata.

Diagnosis.—In the recognition of the various sarcomata the history and course must be taken into consideration, and very frequently a final opinion is possible only upon histologic examination. A pigmented nævus undergoing enlargement or showing irritation is suggestive as to melanotic sarcoma, and when the case is ad-

[1] Crocker, *Diseases of the Skin*, second edit., p. 682.

[2] Cases of somewhat varying character have been recently reported by Winfield (*Jour. Cutan. Dis.*, 1900, p. 113, with illustrations); Fordyce (*Amer. Jour. Med. Sci.*, vol. cxx., 1900, p. 159, with histologic cuts); Johnston, *Jour. Cutan. Dis.*, 1901, p. 126 (with histologic cut); Wolters, *Archiv*, Sept., 1900, p. 269 (with histologic plates); Spiegler, *ibid.*, 1899, vol. l., p. 163 (with colored and other cuts).

vanced, the history of such, together with the melanotic characters of the growths, will usually be conclusive. The maladies ordinarily to be excluded are syphilis, granuloma fungoides, and leprosy.

Prognosis and Treatment.—A fatal issue is to be expected sooner or later in all cases in which generalization has taken place, varying from a few months to several years or longer, depending upon the variety and extent. The melanotic type is the most rapidly fatal; the multiple pigmented form, usually the slowest in its course —Brayton's case over twenty-five years, and Taylor's[1] patient, with a number of sarcomatous growths, was still in good health twenty-four years after its first appearance, and Jackson's[2] case, twenty-one years. Rare exceptions of final spontaneous recovery have been noted, the most remarkable of which was Hardaway's[3] generalized case, which, after lasting for over ten years, entirely disappeared. In 2 cases observed by Bazin and Funk (*loc. cit.*), of a somewhat peculiar variety of the disease, complete involution took place.

Operative measures are usually the sole method in those cases in which the tumors are single or scanty in number. The X-ray treatment has been credited with a favorable influence in exceptional instances. It has sometimes been noted that excision of a melanotic sarcoma seemed to spur the process onward.

Under treatment by arsenic, preferably employed subcutaneously, several instances of cure and marked palliation have been observed,[4] usually in the multiple pigmented variety. Lustgarten[5] saw marked improvement in a case of this type from X-ray treatment.

The fact that some instances of recovery have followed accidental erysipelas led to the somewhat dangerous use, by Coley[6] and others, of the induction of this latter by injections of cultures of the streptococcus of this disease, and also by the combined toxins of this coccus and the bacillus prodigiosus.

[1] Taylor, *Arch. Derm.*, 1875, p. 307.

[2] G. T. Jackson, *Jour. Cutan. Dis.*, 1897, p. 473.

[3] Hardaway, *ibid.*, 1883, p. 97, with colored plate; *ibid.*, 1884, p. 289; *ibid.*, 1890, p. 21.

[4] Köbner (*Berlin. klin. Wochensch.*, 1883, p. 21), case of a girl of eight and one-half years, was wholly relieved by hypodermic injections of 2½ to 4 minims of freshly prepared Fowler's solution with 2 parts water, and was free from a return five years subsequently. Later (*Berlin. klin. Wochensch.*, p. 193), owing to the difficulty of securing freshly made solution, Köbner expressed a preference for a solution of sodium arseniate. Sherwell (*Jour. Cutan. Dis.* (discussion), 1897, p. 141) states that a patient with multiple pigmented sarcoma, the lesions mostly upon the lower extremities, got entirely well under full and increasing doses of Fowler's solution, and was well a year later when last seen. This same observer (*Amer. Jour. Med. Sci.*, Oct., 1892) also reported a multiple case in which the involution of the lesions was markedly influenced, new ones appearing as soon as the patient discontinued the remedy. Hyde (Hyde and Montgomery, *Diseases of the Skin*, fifth edit.) also refers to a case exhibited at the International Dermatological Congress, London, 1896, in which the eruption on the hands disappeared under this plan of treatment. De Amicis (*Monatshefte*, 1897, vol. xxv., p. 309) has reported 1 case cured and 1 greatly relieved. Lassar and Shattuck (both cited by Wende, *loc. cit.*) have also had good results, and Wende's case was showing some favorable influence. Lustgarten (Discussion, *Jour. Cutan. Dis.*, 1897, p. 83), in a case of sternal osteosarcoma with axillary gland involvement in which a prominent surgeon refused operation, saw a complete disappearance in three months under injection of sodium arsenite, administered in a 2 per cent. carbolic acid solution.

[5] Lustgarten, *Jour. Cutan. Dis.*, April, 1905, p. 171 (case demonstration).

[6] Coley, "Treatment of Malignant Tumors by Repeated Inoculations of Erysipelas, etc.," *Amer. Jour. Med. Sci.*, vol. cv., 1893, p. 487, with analytic table and full bibliography.

GRANULOMA FUNGOIDES.[1]

Synonyms.—Mycosis fungoides; Granuloma sarcomatodes; Inflammatory fungoid neoplasm; Fibroma fungoides; Lymphodermia perniciosa; Sarcomatosis generalis; *Fr.*, Lymphadénie cutanée; Mycosis fongoïde; *Ger.*, Multiple Granulationsgeschwülste; Mycosis fungoides.

Definition.—A chronic malignant disease characterized usually by percursory symptoms of months' or years' duration, of an eczematous, urticarial, or erysipelatous aspect, with the subsequent appearance of pinkish or reddish, tubercular, nodular, lobulated, or furrowed tumors or flat infiltrations, which frequently ulcerate and form fungoidal or mushroom-like growths.

Alibert was the first to call attention to this rare affection, although he originally thought it allied to yaws and described it (1814) as "pian fongoïde," but afterward (1832) gave it the name of mycosis fongoïde, on account of its mushroom-like tumors. Among other later writers who have added contributions to the subject may be mentioned Besnier, Vidal, and Brocq, in France; Duhring, Morrow, Hyde, Tilden, Blanc, and myself, in this country; Payne, Galloway, and Macleod, in England; Auspitz, Geber, Köbner, Kaposi, and Schiff, in Germany and Austria; and De Amicis, in Italy.

Symptoms.—As ordinarily observed, the course of the disease may be divided roughly into several stages: The first stage is that of erythematous and slight eczematoid manifestations, comprising, as a rule, fugacious erythematous lesions, such as simple erythema, mild erythematous eczema, and urticarial efflorescences; the second stage (stage of infiltration) is somewhat similar to the first, except that the eruptive phenomena show a degree of infiltration and are not so evanescent in character. The third stage is distinguished by its tumor

[1] Literature, usually with review and bibliography, and together covering the entire subject: De Amicis, "Dermo-linfoadenoma fungoide," Naples, 1882, and *Trans. Internat. Med. Cong.*, Washington, 1887, p. 275; Vidal and Brocq, *La France médicale*, 1885, pp. 946, 957, 969, 983, 993, 1005, and 1018; Tilden, *Boston Med. and Surg. Jour.*, 1885 (with colored plates and histologic cuts), 2, p. 386; Payne, *Trans. London Patholog. Soc'y*, 1886, p. 22, and *Rare Diseases of the Skin*, 1889; Ledermann, *Archiv*, vol. xxi., 1889, p. 683, with 2 cuts, review, and bibliography; Pélissier, "Mycosis fongoïde ou Lymphadénie cutanée," *Thèse de Montpellier*, 1889—abs. *Brit. Jour. Derm.*, 1890, p. 56; Besnier, *Jour. mal. cutan.*, 1892, p. 314; *Annales*, 1892, p. 241; Funk (*loc. cit.*); Stelwagon and Hatch, *Jour. Cutan. Dis.*, 1892, pp. 1 and 51 (with colored plates); Besnier and Hallopeau, *Annales*, 1892, p. 987; Morrow, *Jour. Cutan. Dis.*, 1896, p. 465 (with colored plate and other illustrations); Hyde and Montgomery, *ibid.*, 1899, p. 253 (the last three papers deal more especially with the "premycosic" stage); Galloway and Macleod, *Brit. Jour. Derm.*, 1900, pp. 153 and 187 (with 4 histologic cuts); Joseph, *Archiv*, Ergänzungsband, 1900 (Kaposi's *Festschrift*), with illustration and histologic cuts; Stowers, *Brit. Jour. Derm.*, 1903, p. 47, reports a case, and gives a table of 31 cases (and résumé of 20 of them) reported published during the past ten years; Riecke, *Archiv*, 1903, vol. lxvii., p. 193 (2 cases; 1, d'emblée type, died one-and-one-half years after onset; at autopsy metastatic growths were found in the kidneys, suprarenal glands, retroperitoneal glands, and dura mater; Sereni, *Dermatolog. Zeitschr.*, 1904, p. 41 (girl of sixteen, a mycosis d'emblée, death two-and-one-half years from onset); Greig, *Brit. Jour. Derm.*, 1904, p. 251 (histologic report by Macleod); Hancock, *Jour. Amer. Med. Assoc.*, 1904, vol. xlii., p. 705 (case report, with autopsy and histologic findings); Bozzi, *Policlin* (Rome), 1904, vol. xi., p. 97; Hodara, *Monatshefte*, 1904, vol. xxxviii., p. 490 (3 cases treated by ichthyol internally, with improvement; in two cases investigated found at beginning of the malady a characteristic leukocytosis; Pelegatti (mycosis fungoides and leukemia), ibid., vol. xxxix., pp. 369 and 433; Towle, *Boston Med. and Surg. Jour.*, 1904, vol. cli., p. 629; Schiele, *Petersb. med. Wochenschr.*, 1904, vol. xxix., p. 535; Ullmann, *Monatshefte*, 1904, vol. xxxix., p. 631 (chiefly histologic); Orton and Locke, *Jour. Amer. Med. Assoc.*, Jan. 12, 1907 (2 fatal cases; pathologic findings, and brief review with references).

growths, varying in size from a pea to an orange, with a disposition to become superficially ulcerated and fungoidal; but even these lesions may appear and disappear more or less capriciously. The next stage is that in which the ulcerations tend to become deeper-seated, with a marked fungoidal tendency, and we then have the disease presenting itself as a conglomeration of eczematoid eruption, tumors, fungoid masses, mushroom-like or crateriform ulcers. Exceptionally, the first two stages, which may be considered the premycosic, may be extremely short or entirely wanting. In most instances, however, the first, or earliest premycosic stage, is an ill-defined one, with symptoms, often those of eczematous appearance, patchy or diffused, and usually with remissions or even temporary periods of freedom. Intermingled with the erythematous or erythematosquamous eruption there may be at times some urticarial or hive-like efflorescences, and rarely there may be noted, independently or conjointly with the other manifestations, some papular or even vesicular lesions of an eczematous character, and exceptionally an eruption of a psoriatic aspect.[1] Probably the most frequent early or primary manifestation is an erythematosquamous plaque, usually circinate or well defined, one or several inches in diameter, which may be present scantily or in numbers. In one of my cases there was primarily a single plaque of this character at the axillary fold, which lasted over a year, and then under treatment disappeared, to be followed a few months later by the appearance of several scattered patches. This insidious beginning is not uncommon, and the possibility of the earliest area being the point of infection—if the malady can be so considered—is a matter of considerable interest and import. The eruption may, and usually does, become quite extensive, and to all appearances consists of ill-defined, circumscribed and diffused, reddened areas, with often slight scaliness, and, as a rule, but little, if any, perceptible infiltration. The red color of the eruption is often slightly mellowed by a yellowish tinge.

After thus continuing for months or several years or more, the second stage—the stage of infiltration—is gradually presented. This infiltration is more especially noted with the circumscribed areas. Soon small pea- to cherry-sized, rounded or flattened nodules begin to appear, scantily or in profusion. These, as well as the diffused erythematous patches, may disappear suddenly, to be supplanted by similar lesions on the same or other regions. The color of the eruption at this time is, as a rule, a duller red than in the earliest period, and the red may at times, or in places, have a violaceous or brownish hue.

Sooner or later the next or tumor period is imperceptibly ushered in. The infiltrated patches or nodules become more infiltrated and larger, and lead to the formation of distinct tumors; or these latter arise from apparently normal surface; at first they may be few in number, the earlier cutaneous phenomena still playing the chief rôle.

[1] In the case reported by Biddle (*The Physician and Surgeon*, Jan., 1900) the earlier eruption resembled psoriasis, the body being profusely covered with a brownish-red, slightly elevated, scaly eruption, of a variegated pattern, but with a tendency to irregular oval and gyrate figures.

PLATE XXIX.

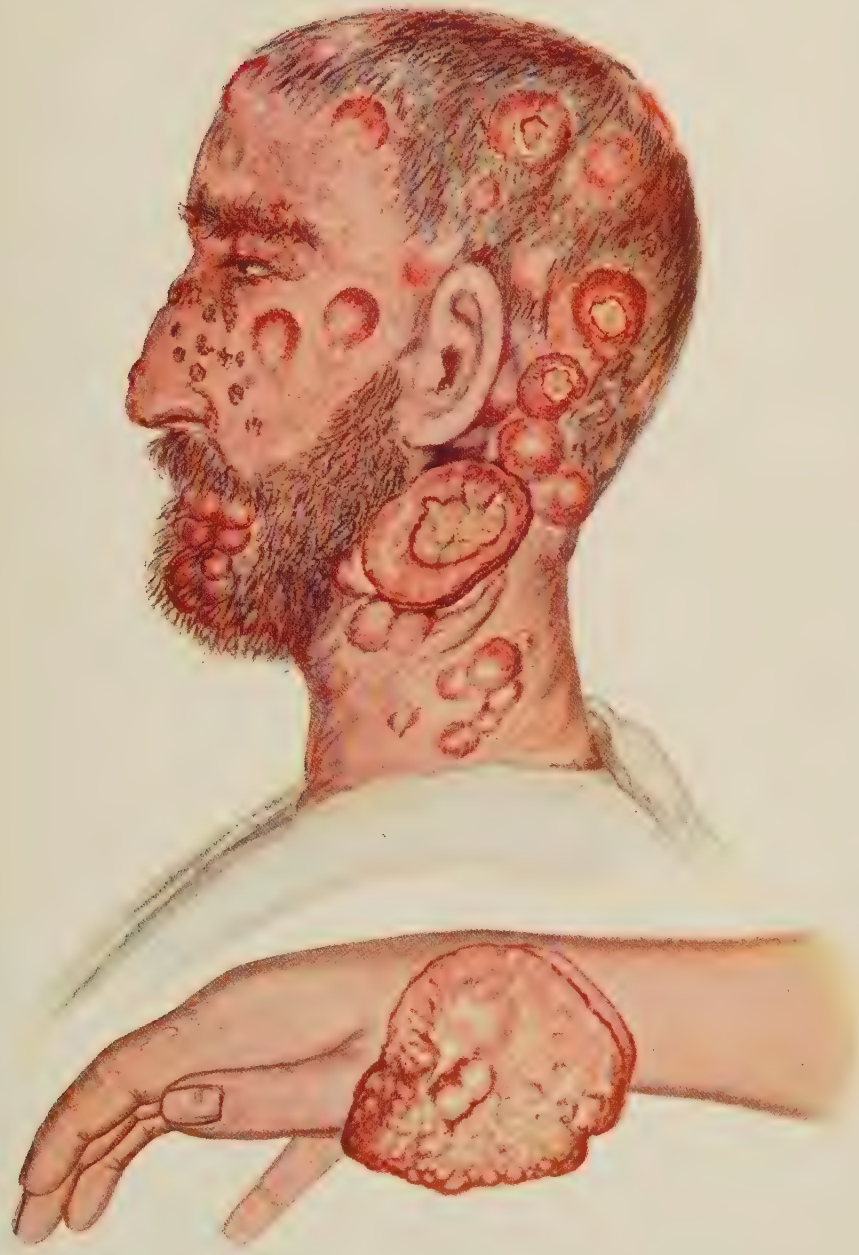

Granuloma fungoïdes. Case shown in the upper illustration was of thirteen years' duration, the tumor stage being present the last fifteen months; the black-and-white text-cut (Fig. 195) is of this same patient. The case shown in the lower illustration was in a woman, the eczematoid symptoms and the tumor growths presenting about the same time, death following a year after their first appearance. (These cases are reported in full in *Jour. Cutan. Dis.*, 1892.)

They are of different sizes, from a cherry to an egg, and exceptionally approaching the size of an orange. As a rule, however, the earliest tumors are small, not usually exceeding the size of a hen's egg. They are solid in character, with rounded or oval configuration, and generally come slowly. They frequently disappear, but others continue to come, ordinarily much more thickly and larger and larger, although they may be present in scant number throughout. In isolated growths, the largest, as a rule, there are sometimes noticed softening and ulceration at the apex. The disease progresses, the tumors are noted to be larger, and show a greater disposition to break down, and the last stage of the disease is entered—the fungoidal stage and what might also be called the cachectic stage. In the previous period the general health seems unaffected, except as to the depression produced by the knowledge of the existence of the malady and the loss of sleep which may result from the itching. In fact, this tempestuousness of the skin disturbance and practical absence of constitutional involvement until a late stage is, in most cases, the most striking characteristic of this strange and essentially fatal malady. This involvement may, indeed, not take place until the latter end of the fungoidal ulcerating stage.

This period has as its special feature the ulcerating tumors; these are frequently numerous, and result from the previously developed growths, which are usually somewhat flattened on top, especially the largest, the surface softening and ulceration extending from the central apex portion almost to the edges. In some cases, however, as in one reported by Whitfield,[1] the eczematoid symptoms continue to be predominant, with but a scanty admixture of ulcerating fungoidal tumors. Some of the tumors may be somewhat pedunculated, the basal portion being slightly or markedly smaller in diameter than the surface and projecting part. The destructive tendency extends somewhat into the growth, but not always uniformly, and in such instances there results a mushroom-like, ulcerating tumor, sometimes with everted edges, or one the surface of which presents a resemblance to the surface of a cut tomato, and with a mucoserous or purulent discharge, often mixed with blood. The disease thus continues, the patient becomes weaker and weaker, and distinctly cachectic, with symptoms common to septicemia, and which lead more or less rapidly to death.

Exceptionally the precursory or premycosic stages are entirely lacking, and the disease first shows itself by the appearance of the peculiar fungoidal tumors, which are, as a rule, few in number, and usually limited to one region—mycosis d'emblée, of the French. In this variety the eczematoid and erythematous symptoms are sometimes subsequently added. The lymphatic glandular system may or may not show special involvement, although in most of the cases enlargement has been noted. The course of the malady is usually slow, except in those cases in which active fungoidal ulcers present at once; the duration before the final end varies within considerable limits from several months (Galliard, Naether, and Debove) to fifteen years or more; in one of my patients thirteen years.

[1] Whitfield, *Brit. Jour. Derm.*, 1898, p. 153 (with 2 illustrations).

Etiology.—The cause of the disease is not known.[1] The literature discloses that it is much more common in males than females; according to Tilden's analysis of 30 cases, 23 of the former to 7 of the latter. In 4 cases under my own observation 3 were males and 1 female. It is an affection of middle adult life, most common between the ages of forty and fifty. In over half of Tilden's tabulated cases it began after forty, and in one-fourth under thirty, but no case before the age of twenty. Demange's patient (quoted by Tilden) was aged sixty-eight. It occurs apparently among all nationalities, is entirely independent of syphilis, tuberculosis, and leprosy, and with no evidence of heredity or contagion; 2 cases have never occurred in a family, and relatives and nurses frequently brought in contact with the patients have remained unaffected. Micro-organisms (variously streptococci, diplococci, micrococci) have been found and described by several or more investigators, notably Auspitz, Rindfleisch, Hoch-

FIG. 195.—Granuloma fungoides in a male aged forty-seven, of thirteen years' duration.

singer and Schiff, Hammer, De Amicis, Murray, Hatch, and myself, but there has been no striking uniformity in the findings; and others, as Kaposi, Payne, Dönitz and Lassar, Köbner, Funk, Maiocchi, Vidal, Brocq, Tilden, Ledermann, and a few others have either failed to find such organisms or, admitting their possible presence, have looked upon them as either pyogenic streptococci or merely fortuitous non-pathogenic forms. The inoculation experiments made by Hatch and myself on 8 guinea-pigs and 8 rabbits were without result.

Pathology.—There seems no longer doubt that granuloma fungoides can scarcely be considered as belonging or allied to the true sarcomata, as Kaposi, Funk, and some others believe; although there are, as Bowen[2] and others have pointed out, many points of similarity, both histologically and clinically, with multiple sarcomatosis of the pure type. The fact that some of the growths may undergo involution is, according to the dictum of Cohnheim, a proof of their

[1] The case reported by McVeil, Murray, and Atkinson, *Glasgow Hosp. Reps.*, vol. i., 1898, p. 53—full abs. in *Brit. Jour. Derm.*, 1899, p. 69, in a farmer aged forty-three, seemed to follow an injury on the temple due to a sheep kicking him while shearing it.

[2] Bowen (Mycosis Fungoides and Sarcomatosis), *Jour. Cutan. Dis.*, 1897, p. 65 (2 cases).

non-sarcomatous nature, but we know now that in some instances of sarcoma, especially the multiple pigmented sarcoma of Kaposi, that such retrogressive changes can also take place. The premycosic or, as Morrow prefers to call it, the prefungoidal stage of granuloma fungoides, taken with the whole clinical course, and to a less extent the histologic data, place it as a distinct affection, although some of the cases of the disease in which the tumor stage is ushered in at once would almost point to connecting or intermediate examples. French observers are inclined to look upon the disease as lymphadenomatous; the majority of German investigators, led by Auspitz, Hochsinger, and Schiff, regard it as granulomatous, and with this view the studies of Payne, Hatch, and myself are in accord. Paltauf[1] has recently put himself in opposition to all the prevailing views, cogently setting forth the reasons against them, and is inclined to include the malady in the class of anomalies of vegetation proposed by Kundrat, which comprises pseudoleukemia and certain forms of lymphosarcoma. In this connection it may be stated that in 3 instances (Biesiadecki, Philippert, Kaposi) there was an associated leukemia. There is no doubt, as Hyde and Montgomery state, that the premycosic eruptions are not truly eczematoid, but are the initial manifestations and distinctly a part of the disease itself. Hardy, Leredde, and others believe, according to the same observers, even apart from the visible beginning symptoms, that the apparently sound skin is also at this early period the subject of characteristic pathologic changes. Excepting the 2 instances (Duhring, Gallaird) in which neoplastic tissue, possibly not related to the disease, was found in the walls of the bladder, visceral involvement has not been observed.[2]

The various lesional formations, especially the tumors, have been histologically studied by many observers (Kaposi, Payne, Paltauf, Fordyce, Joseph, Hyde and Montgomery, Galloway and Macleod, Hatch, myself, and many others), and agree in the main, but, as already stated, the interpretation placed upon such investigations has varied. In the examinations by the majority of observers the epidermis was found thinned, the rete Malpighii a mere wavy line, the papillæ squeezed out by the pressure of the growth from below, making them shorter and broader, and the corium infiltrated with small round cells. All likewise agree in denominating the cells forming the tumors lymphoid, and many have been able to distinguish a fine embryonal connective-tissue network. The sections from the 2 cases, taken when living, investigated by myself and Hatch, were taken from patches of skin approaching the normal, from the simple erythematous locations, from the tumors of moderate size, and from the fully developed growths. In the first, or almost normal sections, a moderate round-cell infiltration was seen in the corium, and the latter was also thinner than normal. In those of the second were found turgescence of the capillaries, with a diapedesis of the red blood-corpuscles and considerable round-cell infiltration, occurring in spots; the epidermis normal, the papillæ intact, the round-cell infiltration being limited above by the rete Malpighi. In

[1] Paltauf (Lymphatic Neoplasms of the Skin), Vienna Congress, 1892 (quoted by Bowen).

[2] Brandweiner, *Monatshefte*, 1905, vol. xli., p. 415 states that in his recent case nodular masses were found in both cerebral hemispheres (colored illustration).

the section of tumors of moderate size a most characteristic feature was the crowding together of the lymphoid cells around the capillaries. In other respects they exhibited about the same structure as the larger growths, save that they presented, in addition, some of the elements of the normal derm. In the fully developed tumors the following presented: the field seemed to be made up entirely of lymphoid cells, having much the appearance of a small round-celled sarcoma, and reposing in a fine, embryonic, connective-tissue stroma.

Diagnosis.—The recognition of the malady in the tumor stage is rarely a matter of any difficulty, for the associated clinical symptoms, usually present, of eczematoid eruptions, small and large nodules, and walnut- to egg-sized or larger, elevated, ulcerating growths, generally of a fungoidal character, and often one or several slightly pigmented areas, showing the sites of tumors which have undergone involution, taken together with the history, make up a picture which is unmistakable and which also serves to distinguish it from sarcomata. In the variety of granuloma fungoides in which the preliminary stages are wanting, the tumors constituting the first signs, there may be strong clinical suggestions of sarcoma and carcinoma, but these latter usually show early glandular involvement, are often spontaneously and acutely painful, and rarely tend to fungoidal ulcerative forms, as do the growths in the former malady. The diagnosis in the premycosic or prefungoid stages is not always possible—indeed, in the earliest period wholly impossible, as at that time the malady may show the clinical aspects of a mixed urticarial, psoriasiform, and eczematous eruption, more usually, however, eczematous in appearance. Inasmuch as Hebra once made the diagnosis of eczema in a case, it can readily be seen that the symptoms are sometimes clearly of this character in appearance, and that such an error might be unavoidable. However, their persistence and capriciousness, the often circumscribed character of some of the areas, with no tendency to yield more than temporarily to therapeutic measures, and, in the earliest stage, often a yellowish cast to the red, are features which may lead to suspicion. To these later is added distinct infiltration, usually of a more solid and well-defined nature than in eczematous or psoriatic eruptions. Later still the small tumors appear, some of which may lead rapidly to larger growths, and the difficulties in the diagnosis disappear. It has also been confused with leprosy, but if necessary the examination for the lepra bacilli would serve in the differentiation.

Prognosis and Treatment.—The disease goes on to fatal termination, the duration, as already stated, varying somewhat widely from some months to fifteen years; after the active tumor stage is entered, the patient can scarcely live more than some months or one or two years at the most, depending principally upon the number of the growths and the degree of ulcerative tendency displayed. A case of recovery after an accidental migrating erysipelas was recorded by Bazin, one after the administration of arsenic by Köbner, and one by Geber. Constitutional treatment consists essentially in the use of tonics and nutritives, together with the continued administration of arsenic, hypodermically, when possible. Jamieson, Stainer, Ormsby, Lustgarten, Carrier, and others have reported remarkable results

from X-ray treatment.[1] The treatment seems especially valuable in controlling the pruritus. Results in some cases occurred without distinct X-ray reaction; in others not till moderate reaction was provoked. Crocker cites a case in which recovery took place apparently from continued purgation. Hodara saw improvement from ichthyol, internally, moderate to full doses. Local measures have in view the maintenance of cleanliness. In the early stages the various antipruritic applications used in eczema can be employed. Later antiseptic applications and dressings to the ulcers, and, when deemed advisable, operative interference.

LEUKEMIA CUTIS; PSEUDOLEUKEMIA CUTIS.[2]

In some cases of leukemia the skin either directly or indirectly shares in the malady. The lesions presented, consisting variously in the cases reported, or in some instances as a medley in the same case, of true leukemic tumors (Biesiadecki, Hochsinger and Schiff, and others), dry, and, less frequently, moist, eczema-like areas, often of more or less general distribution, eczematous or lichenoid papules, infiltrated, thickened, reddish, sometimes pale, areas of skin, with occasionally the lines and folds accentuated (when, on the face presenting an appearance of leontiasis); and in some instances the development of diffuse lymphatic thickening and hypertrophy, with the formation in the lower part of the corium, or subcutaneously, of discrete, crowded, or chain-like pea to cherry-sized or larger, doughy or hard, somewhat flattened nodules. There is usually intense itching, and sometimes a hypersensitive skin, tender upon touch or pressure, or at times spontaneously painful. The eczematous element is variable, being more or less intense at different times or periods, but the tumor-like growths and infiltration are usually persistent, and progressive; exceptionally the eczematoid thickened or lymphatic infiltra-

[1] As to X-ray treatment: Jamieson, *Brit. Jour. Derm.*, 1903, p. 1 (case illustration; disease disappeared from all parts treated); Jamieson and Huie, *ibid.*, 1904, p. 125 (in prefungoid stage; no traces remained); Stainer, *ibid.*, 1903, p. 212 (apparently cured); Marsh, *Amer. Jour. Med. Sci.*, 1903, vol. cxxvi., p. 314 (apparently cured); Ormsby, *Medicine*, 1903, vol. ix., p. 904, and Hyde and Montgomery, *Diseases of the Skin*, seventh edit., p. 779 (prefungoid stage; plaques would disappear under treatment); Lustgarten, *Jour. Cutan. Dis.*, 1904, p. 185 (case demonstration; patches had almost entirely disappeared, with the exception of a few unrayed spots, for which patient was still under treatment; "a single twenty-minute exposure will produce a dermatitis on any part of the body followed by a complete disappearance of the lesion"; Lustgarten believes a dermatitis should be provoked by the rays); Elliot, *ibid.*, p. 187 (discussion; complete disappearance of all lesions); Carrier, *Jour. Cutan. Dis.*, 1904, p. 73 (case illustration; lesions have entirely disappeared); Bulkley, *ibid.* (case demonstration; steady improvement); Dubois-Havenith, *Presse méd. belge*, 1904, vol. lvi., pp. 139 and 423 (symptomatically cured); Belot and Bissérié, *Arch. d'électric méd.*, 1904, vol. xii., p. 855, and translation in *Arch. Roentg. Ray*, 1904-5, p. 139, and Belot, *Annales*, 1904, p. 588 (eruption practically disappeared under treatment); Markley, *Jour. Cutan. Dis.*, 1905, p. 440 (disappeared); Jackson, *ibid.*, 1906, p. 193 (apparent recovery for more than a year—recurrence and death).

C. J. White, *ibid.*, p. 195, has recorded an instance of fatal toxemia apparently resulting from the rapid disappearance of the lesions under X-ray treatment; also refers (with résumé and bibliography) to other reported instances of toxemia following the treatment of other neoplastic growths,—see also Pancoast's paper, *Univ. Penna. Med. Bull.*, Jan. 1907.

[2] The following papers will be found to cover pretty fully, by review and bibliography, the literature of the leukemias; Pincus, *Archiv*, 1899, vol. l., pp. 37 and 177; Nékám, *Ueber die leukæmischen Erkrankungen der Haut*, 1899, Vose, Hamburg and Leipsig; Nicolau, *Annales*, Aug.–Sept. 1904, p. 753, and also in Unna's "Histopathology."

tions give place to atrophic changes. The face, head, arms, and genital and anal regions are frequently favorite situations for the more extreme developments; the face and head in those of limited development. In some of the cases—those in which there is a medley of tumor formations, eczematoid eruptions, and thickened, infiltrated plaques—the resemblance, as to external appearances, to granuloma fungoides is quite striking,[1] but there is rarely any decided tendency to ulceration, and practically none to the formation of the peculiar fungoid growths and ulcers of granuloma fungoides. Cases of the other extreme—in which the visible tumor formation is practically wanting, and only the smaller subcutaneous nodules, together with a dry, eczematoid, somewhat shriveled-looking, reddened, slightly scaly skin, are present—there may exceptionally be a resemblance to pityriasis rubra of Hebra.

Not uncommonly the eczema or eczema-like eruption is the first symptom to which the patient's attention is called, and such a condition is usually persistent, with a disposition to infiltrated plaques, and most intractable to treatment. The itching also seems more or less uncontrollable. In other instances the eczema-like symptoms are lacking, the manifestations consisting of from several to large numbers of variously sized, slightly to prominently projecting, soft, doughy, firm, sometimes roughly lobulated tumors, over which the skin may or may not be movable, and which may be of a normal, pale red, yellowish, or brownish-red color. In these cases the general symptoms of leukemia may have long preceded these cutaneous manifestations. Later the leukemia becomes more profound, and there may also be the development of lymphatic abscesses, with sometimes a tendency to a breaking down of the larger growths, exceptionally into gangrenous ulcers; increasing weakness and prostration of the patient, and finally death.

The histologic characters of the growths have been studied by various observers (Biesiadecki, Hochsinger and Schiff, Kreibich, Pinkus, Nékám, Nicolau, and others). There is found a cellular infiltration in the corium and subcutaneous tissue consisting largely, as is generally conceded, of crowded and heaped-up lymphocytes; although some observers believe the masses are derived from the connective-tissue cells *in situ*, and others that they arise from the exudation of leukocytes from the blood-current.

Pseudoleukemia Cutis.—Pseudoleukemia, known commonly as Hodgkin's disease, like leukemia, sometimes presents cutaneous manifestations (lymphadenoma cutis) closely or practically similar to those observed in the latter disease, and already described. In fact, it is believed by some observers[2] that a pseudoleukemia sometimes develops into a true leukemia.

Diagnosis.—The recognition of the eruptions of the leukemias depends largely upon the recognition of the underlying disease.

[1] Pelagatti, "Mycosis fungoides und Leukämie," *Monatshefte*, 1904, vol. xxxix., pp. 369 and 433 (with histologic cuts), believes granuloma fungoides a leukemia primarily, with skin manifestations secondarily.

[2] Linser, *Beiträge zur Frage des Hautveränderungen bei Pseudoleukämie*, *Archiv*, vol. lxxx., May 1906; Radaeli, "Mykosis fungoides oder Pseudoleukämie cutanea," *ibid.*, 1906, vol. lxxx., July.

Intractable eczematous or eczematoid eruption, especially if at all extensive, with a disposition in places to considerable infiltration, rebellious to treatment, and with a troublesome, persistent, or paroxysmal itching difficult to relieve, should always suggest the possibility of granuloma fungoides, a leukemia cutis, or a pseudoleukemia cutis. Suspicion thus aroused becomes more probable or almost certain if there is any associated tumor formation; and as to leukemia and pseudoleukemia, a careful general examination, as to blood, glands, and internal organs, will usually determine the matter. That there is often a strikingly puzzling likeness in the clinical cutaneous ensemble of these three maladies is to be admitted, so much so as to suggest a possible kinship.[1]

Treatment.—Hopeless as to final outcome as it usually is, a proper general plan of treatment is to be instituted. As to the cutaneous symptoms, exceptionally amelioration and in one or two instances complete relief followed the administration of arsenic, preferably by hypodermic injection. The *x*-ray, more especially in pseudoleukemia, has given encouraging results.[2] The external management of the eruption and tumors is essentially that advised in granuloma fungoides.

LEPRA.[3]

Synonyms.—Leprosy; Lepra Arabum; Elephantiasis Græcorum; Leontiasis; Satyriasis; *Fr.*, La lèpre; *Ger.*, Der Aussatz; *Norwegian*, Spedalskhed.

Definition.—Lepra is an endemic, chronic, malignant, constitutional disease, due to a specific bacillus, characterized by alterations in the cutaneous, nerve, and bone structures, varying in its morbid manifestations according to whether the skin, nerves, or other tissues are predominantly involved, and resulting in anesthesia, ulceration, necrosis, general atrophy, and deformity.

Ill-defined records of the existence of this malady are to be found as far back as the remotest ages. Although its primary origin is unknown, it is not improbable that it was in its earliest history limited to Egypt and the Orient. Mention, sometimes of an indefinite character, is made of it in several parts of the earlier books of the Bible. During the middle ages it was quite rife in Europe, England, and Scotland, declining in the fifteenth century and practically disappearing by the sixteenth. In the last hundred years there seems to have been, in certain places, signs of recrudescence, and the malady

[1] I have met with 3 such puzzling cases in recent years in which the differentiation symptoms were so ill-defined that a positive diagnosis without qualification could scarcely be made; all ended fatally.

[2] A review of the literature of X-ray in the leukemias, with bibliography, will be found in a paper by Pancoast, in *Univ. Pa. Med. Bull.*, Jan. 1907.

[3] Important general literature: Danielssen and Boeck, *Traité de la Spédalskhed*, Paris, 1848; Vandyke Carter, *Leprosy and Elephantiasis*, 1874; Leloir, *Traité pratique et théorique de la Lèpre*, Paris, 1886; Thin, *Leprosy*, London, 1891; *Journal of the Leprosy Investigating Committee*, London, 1890–91; Hansen and Looft, "Die Lepra vom klinischen und pathologischen-anatomischen Standpunkt," *Bibliotheca medica*, D. 2, H. 2; there is an English translation by Walker, London, 1895; *Mittheilungen und Verhandlungen der Internat. Lepra Conferenz zu Berlin*, 1897, Berlin, 1897–98; *Lepra-Bibliotheca internationalis;* Babes, *Die Lepra*, 1901; Santon, *La Léprose*, 1901; *Verhandl. v. Internat. Derm. Cong.*, Berlin, 1904, vol. i. This last contains most recent reports as regards different countries.

has appeared in parts where it had never before existed. It is probable, however, that this alleged increase or recrudescence is more apparent than real, the studies and activity of dermatologic workers in the past several decades in regard to the disease bringing the existent cases and facts more strongly into the foreground. Its distribution is, however, quite extensive, although the aggregated number of cases, as well as the percentage of state and world population, is insignificant compared to that during the early and middle ages. It still exists to-day to a variable extent in Norway and Sweden, Southern Russia, Asia, Japan, along the coasts of Africa, some of the Central and South American States, Mexico, Cuba, and the Sandwich Islands. It is also found in some of the British Colonies,[1] in many of the islands of the Indian and Pacific Oceans, New Zealand, Madeira, and the West Indies. Spain and Portugal, as well as Greece and certain parts of Italy and France, furnish a variable number of cases.

In the United States [2] the earliest cases were found in Louisiana among the French, and in Minnesota and other Northwestern States among the Norwegian immigrants, and a limited number in South Carolina. It also, as known, exists in its colonies recently acquired. In more recent years, as to be expected from our nearness to leprous centers, imported cases, especially Chinese, have been met with in California and the other nearby Coast States. Isolated cases in individuals who have contracted the disease elsewhere are also encountered from time to time in New York, Philadelphia, Chicago, and other cities.

Symptoms.—Leprosy presents varied and manifold symptoms. The clinical aspects in some cases seem totally different from those in others, and in others again are frequently of mixed character. There are, too, in most instances, several stages of the malady, which are, however, often ill defined. Owing to these facts it is customary, and, upon the whole, more satisfactory as to clearness, to describe the distinct types separately. Probably the best arrangement is a division of the subject into: (1) Period of incubation; (2) period of invasion; (3) macular type; (4) tubercular type; (5) anesthetic type; (6) mixed type. One form usually shades slightly, moderately, or decidedly into another, so that it can readily be understood that the manifestations of either form may vary considerably.

[1] See Abraham's paper in *Trans. Internat. Leprosy Conference.*

[2] D. W. Montgomery, "Leprosy in San Francisco," *Jour. Amer. Med. Assoc.*, July 28, 1894; Dyer, "Report on the Leprosy Question in Louisiana," *Proceedings of the Orleans Parish Med. Soc'y*, meeting of June 11, 1894; Dyer, "Endemic Leprosy in Louisiana," *Philada. Med. Jour.*, Sept. 17, 1898; Jones, *New Orleans Med. and Surg. Jour.*, vol. v., 1877–78, p. 673; Morrow, "Matters of Dermatological Interest in Mexico and California," *Jour. Cutan. Dis.*, 1889, p. 147; Hyde, "The Distribution of Leprosy in North America," *Trans. Cong. Amer. Phys. and Surg.*, 1894 (with full bibliography); J. C. White, "Leprosy in the United States and Canada," *Trans. Internat. Leprosy Conference*, 1897, vol. i.; Bracken, "Leprosy in Minnesota," *Philada. Med. Jour.*, 1898, ii., p. 1309; D. W. Montgomery (a white woman who contracted leprosy in San Francisco), *Lepra, Bibliotheca internationalis*, vol. l., Fasc. 4, 1900; Burnside Foster (case contracted in Minnesota), *Jour. Amer. Med. Assoc.*, Aug. 31, 1901; Dyer, *Jour. Amer. Med. Assoc.*, Nov. 7, 1903; "Origin of Louisiana Leprosy," *Med. Library and Histor. Jour.*, Jan., 1904; "Leprosy in North America," *Verhandl. v. Internat. Derm. Cong.*, 1904, vol. l.; Daland, "Leprosy in Hawaiian Islands," *Jour. Amer. Med. Assoc.*, Nov. 7, 1903; Ewing, Leprosy as seen in the Philippines, *Med. Record*, Dec. 15, 1906.

Stage of Incubation.—This is, so far as inference from the known facts shows, extremely variable. The absence of a recognizable primary lesion necessarily limits the field of observation on this point. It has happened, however, that in some instances the malady can be ascribed to exposure consequent upon a short visit to a region where it is prevalent, the affection developing a variable time after the return home—a country free from the disease. Such observations indicate that the period of incubation, from the time of exposure to the first manifestations, may be short or long, varying from several months to some years, depending, doubtless, upon the receptivity and condition of the individual and upon other—unknown—factors. As illustrating the short extreme, Bidenkap, cited by Morrow,[1] observed an instance in which the disease developed a few weeks after the first exposure, and Morrow himself had a case under his care in which the disease appeared within ten months following a short visit to the Sandwich Islands. On the other hand, some observers, among whom Danielssen, Boeck, and Leloir, have recorded cases having an incubation period of ten to forty years. Doubtless the state of the health, the food-supply, climate, and surroundings, as well as the varying resisting power of individuals, are responsible, in great part

FIG. 196.—Leprosy of the maculo-anesthetic type, in a boy of fourteen; with also a thickened macular anesthetic patch on the palm (courtesy of Dr. D. W. Montgomery).

at least, for the great differences in the length of time noted between exposure and the appearance of invasion symptoms. It is not improbable, however, that in most cases of apparent long period of incubation the disease may have already been in existence for some

[1] Morrow, Morrow's *System*, vol. iii. (Dermatology), p. 566.

time, but that the manifestations are of such mild character that they escape observation.

Stage of Invasion.—This period varies within considerable limits, averaging probably from several months to a year. The prodromata of leprosy are frequently ill defined, and, unless occurring in leprous countries or districts, and presenting something characteristic, are often ascribed to simple ill health or considered manifestations of malaria, tuberculosis, or some other malady. Chilliness, febrile action of an intermittent type, malaise, disinclination to exertion, mental depression or hebetude, debility and epistaxis, often associated with pain, alterations in sensibility, and motor weakness, variously present from time to time irregularly. One, several, or all such symptoms may be noted, but, as a rule, those most frequently observed are the chilliness and febrile action, lassitude and debility, and pains, especially in the extremities, and of a more or less paroxysmal character. Instead of chilliness there may be well-defined rigors. The fever,[1] if

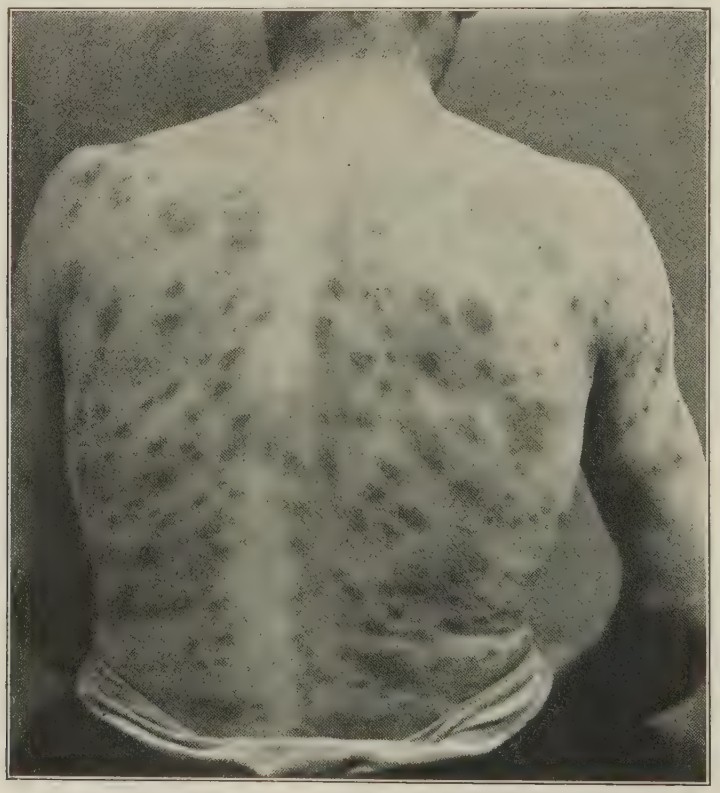

FIG. 197.—Macular leprosy patches, associated with tubercular infiltration of the face; same patient as Fig. 198 (courtesy of Dr. L. A. Duhring).

uncomplicated, is probably always more or less intermittent, and is, as well as other symptoms, due to the presence of the bacilli or their

[1] Lewers, "A Note on Leprous Fever," *Brit. Jour. Derm.*, 1899, p. 388, gives a good brief analytic review of this subject, with citations of opinions from important works on the disease.

toxins. While often an early manifestation, it is frequently more pronounced later, along with the appearance of the cutaneous symptoms. Vertigo and cephalalgia are also not uncommon manifestations in the invasion stage. In the anesthetic variety of the disease, while chilliness, febrile action, and some of the other symptoms named present, there is, as is to be expected, a preponderance of those of a distinctly neurotic character. Morrow considers itching, often of a severe degree, to be one of the most common and characteristic signs of the invasion period. Formication, sensations of tingling and burning, pricking pain, localized soreness or tenderness, a numb or dead feeling, heaviness, stiffness with neuralgic pain, both of a superficial and deep character, are also variously noted.

The import of such symptoms, as well as others of the invasion stage, is often overlooked, however, until cutaneous evidences of the malady show themselves. In many instances, it is true, these latter are the first signs to which the patients give attention, the earlier symptoms having been of a mild or obscure character or practically

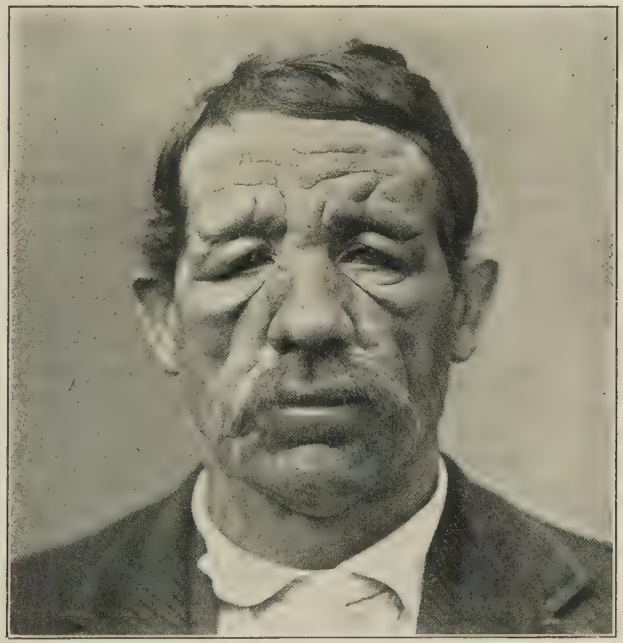

FIG. 198.—Leprosy of the tubercular type, associated with macular variety; the tubercles not defined, but consisting of pronounced infiltration, especially about the eyes and brow; same case as Fig. 197 (courtesy of Dr. L. A. Duhring).

wholly absent. Recent studies indicate, as first pointed out by Morrow, and since emphasized by the observations [1] of Sticker, Jeanselme, and Laurens, that the first manifestations are rather determined toward the mucous membranes of the pharynx and upper air-passages than toward the skin; and betrayed by alterations of the voice, such as husky or rough phonation, rhinitis with an abnormally

[1] Sticker, Jeanselme, Laurens, *Trans. Internat. Leprosy Conference*, Berlin, 1897.

free nasal secretion, sometimes epistaxis, and an increase of the salivary secretion.

Macular Type.—Macular leprosy (**lepra maculosa**) is to be considered more as a forerunner of the tubercular form, and occasionally also of the anesthetic variety, than as a distinct type. The eruptive manifestations may or may not have been preceded by several or more of the invasion symptoms. The cutaneous phenomena consist of variously sized patches, with or without infiltration, of a red, violaceous, brownish, or blackish color. There may be an intermingling of depigmented vitiligo-like spots, striæ, or areas, with those of a hyperpigmented character, and these all may be so ill pronounced as to give the integument a dappled appearance. In fact, this type can be said to be sometimes made up of a mixture of morphea-like patches, leukodermic areas, and more or less pigmented spots and patches. Some may be atrophic, others somewhat thickened or lardaceous and firm. The eruption may be slight and somewhat limited, or in some instances is quite extensive. The color may be brownish or mahogany red or sepia tint, dependent to some extent upon the complexion and race. Occasionally it may suggest an ecchymosis. Patches vary in size from a pin-head to a palm or larger, as a rule being coin- to palm-sized. There is sometimes a deeper shade centrally, in others peripherally. The skin involved may be otherwise apparently normal, slightly atrophic or thickened, and may show slight hyperesthesia or be more or less anesthetic. Not infrequently irregularly scattered blebs appear from time to time, usually scanty in number. The febrile and other general symptoms, already referred to, often present at intervals, at which times there is usually an exacerbation in the cutaneous symptoms. The malady may persist somewhat indefinitely as this type, with sometimes paralytic motor symptoms and sensory disturbances, with variable mixture of more pronounced evidences of the anesthetic type; or infiltration and nodulation begin to present, and it passes partially or more or less completely into the tubercular form.

Tubercular Type (Tubercular Leprosy; Tuberculated or Nodular Leprosy; Lepra Tuberculosa).—This is the more common expression of the disease, and generally the form which is noted in a region when the malady gains its first foothold. Later, after its existence in a community for a long period, the milder or anesthetic type is noted to occur relatively in greater and greater frequency. In tubercular leprosy the brunt of the malady is seemingly borne by the integument. The earliest symptoms are usually those described in the macular variety, which latter, as stated, is generally to be considered an early stage of the disease. The peculiar characters of the tubercular variety consist in the appearance of tubercles and nodules, distinctly defined, or as more or less ill-defined areas of infiltration, with subsequent ulceration. The skin, more especially of the face, ears, and often other parts, is noted to be thickened, seemingly hypertrophic, with an accentuation of the natural lines. The region of the brow, particularly of the eyebrows, commonly shows the earliest evident infiltration. Along with, as well as often preceding, these characteristic lesions, scattered blebs and more or less infiltrated, hyperesthetic or anesthetic, pinkish, reddish, or pale-yellowish macules

make their appearance from time to time, subsequently fading away or remaining permanently.

When well advanced, the tubercular, nodular, or infiltrated masses give rise to great deformity; the face, a favorite locality, becomes more or less roughly leonine in appearance (leontiasis). The hands are also usually the seat of similar lesions, and not infrequently other regions likewise present tubercles or areas of infiltration. As a rule, however, the face, ears, and hands are the parts chiefly so involved.

The tubercles are brownish or brownish-yellow in color, vary in size considerably, often attaining somewhat large proportions. They develop in most instances from macular, usually slightly or moderately infiltrated, areas, although also often arising primarily upon skin seemingly previously unaffected. They persist almost indefinitely without

FIG. 199.—Leprosy, tubercular variety; lesions are also shown upon the cornea (courtesy of Dr. J. A. Fordyce).

material change, or undergo absorption or ulceration; this last takes place most commonly about the fingers and toes. Not infrequently there is a partial or even complete disappearance of one crop of tubercles, to be succeeded by another, and ordinarily of more pronounced character. At such times the fresh outbreak is often preceded by febrile action, chilliness, and other general symptoms. Others may undergo some absorption and be gradually transformed into indurated,

fibrous, pseudokeloidal masses. Some may completely disappear and leave behind atrophic, thinned, pigmented skin or cicatrices. Many tend, however, after a more or less indefinite period, to undergo ulcerative destruction, and this tendency, as already remarked, is most frequently displayed with the tubercles and nodules of the extremities. The resulting ulcerations are of a shallow, indolent character, having a yellowish-brown, viscid discharge, which sometimes dries to brownish, thickish crusts. In some instances the ulcerative action extends deeply and may lay bare ligaments and bones. Others after a time tend to heal, and especially if cleanliness is maintained and antiseptic dressings applied. In the course of time, and more particularly when ulcerative action is pronounced, the lymphatic glands of the neck, groin, and axillæ become enlarged, and not uncommonly finally break down and ulcerate; along with this is noted also swelling of the lymphatics leading to these glands.

In addition to the integumentary changes, the mucous membrane of the nares, mouth, pharynx, and other neighboring parts also shows invasion. The eye likewise often suffers and exhibits surface tubercles or infiltration. The hair, especially of the regions involved, sooner or later shows impaired nutrition and falls out; this is frequently noted about the eyebrows. The scalp hair, however, usually remains, as this region is, according to almost all observers, peculiarly exempt from leprous manifestations.[1] The palms are likewise rarely invaded.[2] The nails do not, as a rule, seem to suffer directly, but their nutrition, as is to be expected, is often impaired, and, as a result, there may be thinning or thickening, irregularity, brittleness, opacity, etc. There is commonly, early in the malady, a disturbance of the functions of the sweat and sebaceous glands; primarily there is often increased activity, but later there is a partial or more or less complete arrest, and this may be localized or somewhat general.

Anesthetic Type (Lepra Anæsthetica; Lepra Nervorum).—Anesthetic leprosy, in which the brunt of the malady is borne by the nervous system, is characterized chiefly by anesthetic and atrophic manifestations. The latter are usually more or less limited to the hands, feet, and face. Its development is an insidious one, and it is not infrequently a part of or a sequence of the macular form. Following or along with the precursory symptoms denoting general systemic disturbance, or independently of any prodromal indications, a hyperesthetic condition, in localized areas or more or less general, is observed. As a rule, febrile attacks, or the pseudomalarial aspect, is not a usual, or at least not so constant, accompaniment of this type. Lancinating pains along the nerves, particularly of the extremities, and an irregular, scattered, pemphigoid eruption are, however, commonly noted. The malady may present nothing further than these various manifestations, often along with occasional attacks, or more or less persistent pruritus, for an indefinite time, ordinarily one to several years. Sooner or later there follows the special eruption,

[1] Morrow, "A Case of Macular Lepride of the Scalp—with Remarks on the Localization of Leprous Lesions," *Jour. Cutan. Dis.*, 1900, p. 10, reports a case in which the scalp showed macular manifestations; Pernet, *Brit. Med. Jour.*, Nov. 11, 1905, p. 1280, reports 2 cases in which the scalp was involved.

[2] D. W. Montgomery, *Jour. Cutan. Dis.*, 1899, p. 445, noted an instance with a maculo-anesthetic leprid upon the palm.

coming out from time to time, and consisting of several or more, usually non-elevated, well-defined, pale-yellowish patches, one or two inches in diameter. They rarely present in numbers, but generally present singly, new areas appearing from time to time. They are found most frequently upon the back, shoulders, dorsal surface of the arms, thighs, about the elbows, knees, and ankles. The face also may show the eruption. There is often a symmetric distribution. Leloir noted an instance of double zoster-like arrangement on the chest. As a rule, they are at first neither hyperesthetic nor anesthetic, but may be the seat of slight burning or itching. They spread peripherally, and tend to clear in the center. The patches eventually become markedly anesthetic, and the overlying skin and the skin on other parts as well becomes atrophic and of a brownish or yellowish color. In many instances when first appearing they are of a sepia-

FIG. 200.—Anesthetic leprosy (after A. C. W. Beecher).

brown shade, and sometimes of a bluish-red color, and usually more pronounced at the border portion. Occasionally if several are close together coalescence gradually takes place, resulting in gyrate patches, with a well-defined, sometimes slightly elevated, reddish periphery, and a pale or leukodermic atrophic central portion. In fact, instead of the eruption presenting itself as yellowish-brown areas, of the features described, the earliest patches may be of a vitiligo-like character. In some cases there is depigmentation, extending over considerable surface.

The areas are frequently preceded by sensory disturbance, such as formication, burning, or stinging sensations. While they are in their first appearance sometimes hyperesthetic, after a variable time, usually soon afterward, there is anesthesia, especially centrally. Not uncommonly the central portion becomes anesthetic, while hyper-

esthesia is noted in the spreading border. In some cases, or in some stages of the malady, the anesthesia does not confine itself to the immediate areas, but may involve considerable surface, or even an entire region supplied by an affected nerve. While ordinarily the nervous disturbance primarily does not compromise the tactile sense, consisting at such period of hyperesthesia, analgesia, and thermo-anesthesia, later the sensory functions are wholly abolished.

As the disease continues and the nerve involvement becomes more pronounced atrophic symptoms are noted to ensue. The subcutaneous tissues, muscle, hair, and nails undergo atrophic or degenerative changes, and these changes are especially observed about the hands and feet. These parts become crooked, thinned, emaciated, and otherwise distorted. Surface ulcers appear, either spontaneously or as the result of knocks or other injuries. The muscles atrophy, the fingers become drawn up and flexed, producing the so-called "leper claw." Finally, the bone tissues are involved, the phalanges dropping off or disappearing by disintegration or absorption (**lepra mutilans**). The toes and feet are similarly affected, and not infrequently, especially in those who go bare-footed, a deep plantar ulcer forms. The process may not stop at disintegration and destruction of the fingers and toes, but the hands and feet may gradually be wholly lost. The ulnar and peroneal nerves and other nerves of the extremities seem to be especially prone to the damaging influence of the bacillus invasion. The ulnar nerve particularly is considerably thickened, either uniformly or irregularly, and can usually be felt as a thick, tense cord, and is often painful upon pressure. In addition, owing partly to the atrophy of the glandular structures and the consequent suppression of the sweat and sebaceous secretions, there is often a thinned, atrophic-looking condition of the skin of the arms and legs, which is generally of a dirty yellowish or brownish color, and presents a somewhat tense appearance, and with thin, flaky, or branny scaliness. Occasionally the skin is somewhat wrinkled. In occasional cases the skin of the trunk likewise exhibits similar changes. The atrophic action also often involves the face, and along with the paralytic symptoms, which sooner or later present, give rise to considerable facial disfigurement. The face is sometimes drawn to one

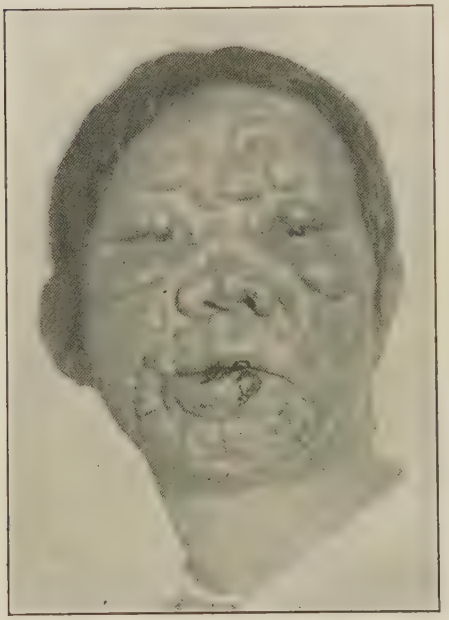

FIG. 201.—Leprosy of the tubercular type, on face, associated with anesthetic type; same case as Figs. 192 and 193.

side. The eyelid muscles are often involved, and, in consequence, and also partly owing to the loss of eyelashes, the eyes not being properly protected, inflammation, ulceration, and opacities ensue.

Ulcerations are not so common a feature of the anesthetic as of the tubercular form, and are chiefly the result of trophic influence, arising principally from dry or moist gangrene, and from knocks or other injuries.

The mucous membrane, especially of the mouth, soft palate, uvula, and back of the pharynx, shows loss of sensibility and other nervous disturbance, and there is serious interference with the act of deglutition, often giving rise to regurgitation through the nostrils.

FIG. 202.—Leprosy, showing paralysis and atrophy of some of the extensor muscles, and the "leper claw" of the anesthetic type; faint macular anesthetic area shows on forearm; same case as preceding, with tubercular type on face.

Mixed Type.—The mixed form of leprosy is, as the name signifies, characterized by features of the several types described. The early lesions are usually, as in the other forms, those of the macular type. Later there is often at first the development into the anesthetic or tubercular expression of the disease, and which may persist as such for a variable time, and then gradually present symptoms of the other variety. The distinctly anesthetic form of the malady may, therefore, sometimes sooner or later have added tubercular and nodular infiltrations, and with subsequent ulceration; the tubercular form likewise may present after a time features of the anesthetic type; not infrequently, however, the clinical features are of mixed character from the beginning.

Course.—Leprosy runs a chronic persistent course, with, in many cases, remissions, or even temporary or more or less prolonged intermissions. Exacerbations in the cutaneous phenomena occur from time to time, and at such periods there are generally preceding and accompanying constitutional symptoms of malaise, debility, febrile action, and chilliness or distinct rigors. These are much less common,

however, in the anesthetic variety, and not infrequently are practically absent. The integumentary lesions become slowly more pronounced and numerous, and while the tubercles and nodular masses and infiltration may undergo absorption, new outbreaks predominate over retrogressive changes. More commonly these lesions show ulcerative changes. The nervous form of the disease, as already described, increases, as a rule, steadily, but is much less rapid in its progress than the tubercular form, usually lasting from ten to thirty years, averaging probably twelve to fifteen.

In tubercular leprosy death results in almost half the cases from the direct effect of the disease, either from exhaustion or involvement of the air-passages or of internal organs. Renal and lung complications carry off almost as great a number. The remainder die from anemia, or enteric complications with colliquative diarrhea. In the

FIG. 203.—Leprosy, with paralysis and atrophy of extensor muscles, and some small ulcerations on toes, and slightly scurfy skin; same case as preceding.

anesthetic form the end comes from the direct action of the leprous poison, from exhaustion, muco-enteritis, long-continued digestive disorders, or other complications. Pulmonary and renal disorders are not encountered as often in this form as in the tubercular variety.

It is not improbable, however, that the pulmonary and enteric maladies which bring the fatal end in leprosy cases are, in reality, not complications, as usually understood, but are themselves of leprous character. Arning believes that the supposed intercurrent pneumonia and tuberculosis, and the diarrhea or dysentery, are due to leprous infiltration—which he denominates respectively *phthisis leprosa* and enteritis leprosa. Beaven Rake's[1] conclusions are practically the same. The culture experiments with fragments of assumedly phthisical lung or tuberculous viscera from lepers have, as he states,[2] so

[1] Beaven Rake, "The Significance of Visceral Tuberculosis in Leprosy," *Brit. Jour. Derm.*, 1890, p. 33 (based upon a study of 90 autopsies).

[2] Beaven Rake, *Brit. Med. Jour.*, Aug. 4, 1888.

far been unsuccessful, this tending to confirm the view that these conditions are leprous and not really tuberculous. As to kidney complication, this same observer[1] found, in 78 autopsies, some form of nephritis in 23 cases, a percentage of 29.4. He noted a much longer duration of life in these cases when occurring in the anesthetic variety than in the tubercular form, which he attributes to the fact that in the latter variety the sweat-glands are involved earlier and to a more serious extent, thus throwing more strain on the kidneys.

Etiology.—The direct cause of leprosy is now accepted to be a specific bacillus—the bacillus lepræ. The discovery by Hansen, in 1874, has completely negatived the hereditary theory formerly so strongly held. It is true that the evidence points to the fact that certain individuals or families may, as likewise now believed regarding tuberculosis, show a readier susceptibility when exposed to invasion. It is certain, too, that the liability to successful implantation of the organism is measurably increased by such predisposing influences as climate, soil, abode, food, and habits. It is known that the malady is most prevalent in tropical and subtropical countries, although it is also common in some cold climates, as Norway, Iceland, and elsewhere. It is, moreover, distinctly a disease of the coast and nearby waterways; it also occurs, however, inland, and in high regions likewise, although to a relatively slight extent.

The method by which the organism gains access is not known.[2] Recent observations (Morrow, Sticker, Jeanselme, Laurens, Babes, von Peterson, Flügge, Besnier, Glück, Schaeffer) indicate that the mucous membrane of the nose, and probably of the mouth also, may be a not uncommon source of communication and infection.[3] Schaeffer[4] refers to experiments on this point. Slides were placed in the vicinity of leprosy patients while they were reading aloud, and subsequently examined, disclosing the presence of large numbers of bacilli. It is not improbable, also, that entrance may take place through some abrasion in the skin (Lassar, Arning, von Peterson, Ehlers, Geill). Geill[5] calls attention to the fact that in tropical countries, with the people who go bare-footed, the first lesions are seen frequently upon the feet—in 50 per cent. of his own cases. Vaccination has exceptionally been blamed for the introduction of the organisms, but there is scant reliable evidence on this point.[6] There is a growing belief that the malady is not directly contagious or inoculable from man to man, but that there is an intermediate host, as now generally believed as to malaria, and it is one that might explain many apparent contradictions. Hutchinson[7] has long held, as is well known, the opinion that in the eating of fish, especially raw or salted, is to be found

[1] Beaven Rake, "The Kidney Lesions in Leprosy Considered in Relation to the Skin Changes," *Brit. Jour. Derm.*, 1889, p. 213 (with citation of the opinion of others as to the complication, with references).

[2] See Morrow's interesting paper, "Sources and Modes of Infection in Leprosy," *Trans. Amer. Derm. Assoc. for 1899*, p. 113; Mugliston, *Jour. Trop. Med.*, 1905, p. 209, suggests that the itch mite may possibly be the means of communication—having the leprous bacillus in or simply on its tissues when it enters the skin.

[3] Mewborn, *Jour. Cutan. Dis.*, 1903, p. 236, found numerous bacilli in the nasal secretion taken from a case observed by Fordyce.

[4] Schaeffer, *Trans. Internat. Leprosy Conference*, Berlin, 1897.

[5] Geill, *ibid.*

[6] See Baum's paper, "Leprosy and Vaccination," *Med. Standard*, 1893, p. 163.

[7] Hutchinson, "Leprosy and Fish-Eating," London, 1906.

the cause of the malady; lately he has added the suggestion that the bacillus may gain access in this way. His views as to this food-cause are negatived by the general observations of others. It is not at all unlikely, however, that its entrance, in some cases at least, may be through the food.

While one, upon going thoroughly over the clinical evidence, must admit the communicability of the disease, yet there are other unknown factors in addition to the active one—the bacillus—which seem to be necessary. Hereditary tissue weakness, climate, food, abode, and habits are, doubtless, therefore contributing. If its successful communicability depended upon the bacillus alone, the examples of the contagiousness of the disease should be common, instead of rare.[1] Its contagiousness, under favoring circumstances, is shown in the rapid spread in Hawaii, and more recently the suggestive increase in Louisiana (Dyer).[2] But even in Hawaii the contributing influence of race, poor food, and other factors is disclosed by the fact that the leper population consists almost entirely of Hawaiians and half castes, less than 3 per cent. are Chinese, with a few other foreigners—British, American, German, etc.—not exceeding a dozen. As von Düring well remarks, however, all negative evidence brought forward as to its non-communicability is valueless in the face of one positive fact to the contrary. And though these positive data are, in my judgment, relatively scanty, still they are sufficient to make us look upon the existence of cases in our midst as of possible danger, although this is in civilized, well-fed, and well-cared-for communities exceedingly remote.[3]

It is generally admitted that the anesthetic type is not so contagious as the tubercular; and it is also commonly believed that the form of the disease in a community which is usually primarily tubercular, gradually, after years, loses its virulent character somewhat, and that it subsequently persists in the anesthetic form. Zambaco[4] and a few others would also have us believe that its virulence

[1] Hutchinson states (*Brit. Med. Jour.*, June 29, 1889) that not a single sporadic case is ever now seen in England; the cases there are all imported. Bronson says (*Jour. Cutan. Dis.*, 1895, p. 428) of New York: "we have had lepers in this city for many years, and yet there is not a single case on record where local contagion has occurred." Lutz (*ibid.*, 1892, p. 477), speaking of his experience and observations in South America and the Hawaiian Islands, says: "Contagion even by intimate and prolonged contact is by no means frequent in families living in a civilized way and in easy circumstances." Hallopeau (*Trans. Internat. Leprosy Conference*, Berlin, 1897) says that "in Paris up to the present no case has been known to arise there"; and Besnier (*ibid.*) also states that "in Paris, at the Hôpital St. Louis, lepers are not isolated, and notwithstanding this no instances of contagion have ever occurred"; Thompson (*Lancet*, Mch. 5, 1898) shows that in Victoria and Australia, where lepers have mingled freely with the community, the disease is on the decrease. Kaposi (*Wiener klin. Wochenschr.*, No. 45, 1898), while admitting that from a pathologic point of view the malady is infectious, holds that clinically it is not contagious. Zambaco, who is still a champion of the hereditary nature of the disease, states that he has never seen a case originating in contagion.

[2] Dyer, *Philada. Med. Jour.*, Sept. 17, 1898.

[3] Bracken, *ibid.*, Dec. 17, 1898, states that it is quite possible, judging from his own observations, for leprosy to die out in certain favored sections of our country, such as Minnesota, without segregation, provided the importation of lepers be discontinued.

[4] Zambaco, *Trans. Internat. Leprosy Conference*, Berlin, 1897; see also Leloir's interesting paper on this point, "Existe-t-il dans des pays réputés non lépreux, en France et en particulier dans la region du nord et a Paris, des vestiges de l'ancienne lépre," *Bull. de l'Acad. de Méd.*, Paris, 1893, p. 215; a good abstract in *Brit. Jour. Derm.*, 1893, p. 129; see also references under Morvan's disease.

becomes still further attenuated, and that the disease is finally exemplified in many cases of the maladies known as syringomyelia, scleroderma, morphea, sclerodactylia, Raynaud's disease, and progressive muscular atrophy (Aran-Duchenne), considering them to be modified or weakened forms of lepra.

Pathology.[1]—The bacillus is now fully accorded the rôle of starting and producing the pathologic changes, and which have in recent years received considerable study by many investigators, more particularly by Virchow, Arning, Carter, Thin, Abraham, Neisser, Unna, Rake, Hansen and Looft, Leloir, and Lie, as well as others. The bacillus is a slender, rod-like, straight or very slightly curved parasite, averaging about $\frac{1}{5000}$ of an inch in length (from one-half to three-fourths the diameter of a red blood-corpuscle); and its thickness is about one-fourth to one-fifth of its length. According to Cornil, the longest are found in parenchymatous organs, while those found in the skin nodules, owing to compression, are, as regards size, less developed. Morphologically they are very similar to tubercle bacilli, and their differentiation is not always easy. Lepra bacilli are, however, in relatively greater abundance in the tissues, usually occur in clumps, groups, or masses, are smaller and less uniform in diameter than the tubercle bacilli. They also exhibit readier reaction to staining agents, "dependent upon microchemical reaction of the investing membrane of the bacillus to acids, alkaline and aniline dyes." They are best demonstrated by staining the section of tissue or débris of a broken-down nodule by Ehrlich's process with fuchsin, and methyl-blue as a contrast (Crocker). While the bacilli are sometimes found more or less generally distributed in the tissues, they have certain predilections. They are usually most abundant in the diffuse and nodular infiltrations, in the connective tissue of the peripheral nerves, in the lymphatic glands and spaces, and sebaceous glands (Babes and Unna). They are also found in the liver, spleen, kidneys, in the testicles (Neisser and others), and, according to Arning, also in the ovary. In fact, in well-advanced cases, more especially in the tubercular form, scarcely any organ escapes. The physiologic secretions remain free so long as the secreting tissue or membrane does not become the seat of leprous deposits. The blood-vessels, except those peripherally involved in the leprous infiltrations or in the last stages of the disease, rarely contain bacilli.

The bacillus, so far, has not been satisfactorily cultured, although Campana and Ducrey, Hansen, Neisser, and a few others have reported moderate success. Neisser states, however, that the growth, which is successful only at body-temperature, is extremely slow; and that he was not able to obtain culture in generation. Experimental animal inoculations (Hansen, Köbner, Damsch, Rake, Campana, Profeta, Vossius, and Melcher-Orthmann) have been, as Neisser in his review of the subject concludes, practically negative, in only a few

[1] For some of the data of this part I am indebted to the several following valuable contributions by Neisser: "Histologische und bacteriologische Lepra untersuchungen," *Virchow's Archiv*, vol. ciii., 1886; "Lepra," in *Ziemssen's Handbook of Diseases of the Skin*, p. 306; and "Inwieweit ist man berechtigt den Leprabacillus als die Ursache der Krankheit anzusehen?" *Trans. Internat. Leprosy Conference*, 1897.

instances a suspicious local growth, and this of doubtful character, being observed. The reported successful inoculation (Arning) in man must also be viewed with suspicion, inasmuch as the subject belonged to a leprous family.

If a section of recent nodule is examined, it is observed to consist (Neisser) of a cell-mass separated by sparse fibrillary intermediate tissue; the cellular elements, mostly rounded in form and primarily like lymph-corpuscles, undergo increase in size and reach four or five times their original volume, constituting the so-called lepra cells and the giant-cells found in leprous tissue. The nucleus, likewise, shows similar increase, and some cells may contain several nuclei. The cells are most plentiful in the neighborhood of the blood-vessels, which are numerous and the vascular supply abundant. Leprous growths are, however, less vascular than ordinary granulation tissue, and therefore undergo retrogressive changes more slowly. The epidermis is not involved in the specific morbid process, and never contains the parasites. The histopathologic changes are especially noted in the papillary layer, in the main body of the corium and the subjacent tissue. According to Neisser and others, a lepra tubercle or nodule is primarily composed of granulation cells. The deepest cellular layer, that in the subcutaneous tissue, is noted to contain, along with many unchanged lymph-cells, the smallest and most recent tumor cells, and but relatively few bacilli. The cells show gradual enlargement in the higher layers. The oldest, topmost, layers are divided from the rete by a stratum of subepidermal connective tissue; the epithelial layer, except as to the disappearance of its interpapillary dippings, is otherwise normal, although showing increased pigmentation. More especially in the upper layers of the tumor are seen peculiar large, rounded, sharply circumscribed accumulations, the so-called "globi," composed of cells very densely infiltrated with bacilli and their products, and undergoing degeneration. Besides the large lepra cells, there are small cells apparently identical with migratory cells; and small connective-tissue cells which show here and there enlargement from infiltration with bacilli.

There is a difference of opinion as to whether the bacilli lie within or without the cells. Virchow, Neisser, and almost all others consider that they are almost exclusively within the large round lepra cells, whereas Unna,[1] Herman,[2] and a few others maintain that they are chiefly found in lymph-spaces, Unna asserting that the lepra cell is nothing more than a glœa-like mass formed by degeneration of the bacilli. Virchow believes the fixed connective-tissue cells to be the mother cells of the subsequent granulation tumor. Thin and Neisser hold the view that the lepra cells develop from emigrated white blood- and lymph-corpuscles.

In the anesthetic variety the chief changes are in the nerves. Virchow, Neisser, and others place the primary pathologic process in the peripheral and cutaneous nerves, due to leprous new formation leading to compression and atrophy of the sensory and trophic

[1] Unna, *Histopathology*.

[2] Herman, "The Bacillus of Leprosy in the Human System at Different Periods of its Growth," *Trans. Internat. Leprosy Conference*, 1897.

fibers. The nerves most frequently affected are the ulnar, median, radial, musculocutaneous, intercostal, humeral, and peroneal. It is generally believed that these changes are practically limited to the peripheral nerves, Hansen, Hillis, Leloir, Neisser, and others finding the spinal cord and brain, in the cases examined by them, normal. In more recent years, however, several observations seem to point to the possibility of central nerve involvement; Chassiotis[1] found in one instance investigated by him bacilli in the spinal cord.

Diagnosis.—The recognition of a well-developed case of leprosy of either type is, as a rule, not attended with difficulty. It is an entirely different matter, however, in many instances in the earlier stages, or in those of advanced period if the disease is atypical.[2] In the invasion and early eruptive stage the prodromal symptoms of chilliness, febrile action, with subsequent free perspiration, so often observed in the tubercular form, may be, and often are, confounded with those of malaria. The erythematous areas may be confused with simple erythema, although they are commonly larger, frequently tend to show infiltration, and are slow in undergoing involution. If to these symptoms could be added sensory disorders, usual in anesthetic leprosy, together with a history of exposure, a strong suspicion could be entertained, and probably a positive opinion reached.

In the anesthetic variety the prodromal symptoms are also usually of variable character and intensity, and the pain and motor weakness often attributed to rheumatism or neuralgia; the other disorders of sensation, such as hyperesthesia, sensations of burning, tingling, numbness, formication, and pruritus, one or several of which may be present, are often wrongly interpreted as pointing to neurasthenia or other nervous disorders. When, however, such a patient is living or has been living in a district where the disease prevails, the possibility of leprosy is to be borne in mind. This would be materially strengthened by the presentation of erythematous patches of a dull red color, and of persistent character, with a tendency to clear centrally while extending at the border, the central part generally becoming whiter than normal and anesthetic. Such areas are, however, to be distinguished from those of morphea and vitiligo.

Later in the course of the malady the tubercular form is to be differentiated mainly from lupus vulgaris, the tubercular syphiloderm, and granuloma fungoides. In the first the eruption is usually quite limited, at least relatively, and most commonly confined to a portion of the face, is of slow development, and frequently spreads from one center. Moreover, it, as a rule, lacks the infiltration generally noted in leprosy. The tubercular syphiloderm is also a limited eruption, and differs materially from that of leprosy by the fact that it tends to occur in segmental, crescentic groups or serpiginous tracts—a formation rarely, if ever, noted in leprous infiltrations or tubercles. Both lupus and syphilis are, moreover, ordinarily wanting in any suspicious prodromal symptoms. Granuloma fun-

[1] Chassiotis, "Ueber die bei der anästhetischen Lepra im Rückenmarke vorkommenden Bacillen," *Monatshefte*, vol. vi., 1887, p. 1039.

[2] Thin (*loc. cit.*) cites numerous examples of errors in diagnosis by observers experienced in dermatology.

goides and well-marked tubercular leprosy have also sufficient in common to give rise to possible confusion, but the early eczematoid manifestations of the former, with the usually accompanying itchiness, its more general distribution, the brighter red color, often serve to differentiate; in the later stage the peculiar fungoidal ulcers would be distinctive.

The anesthetic form in the more advanced stages is to be distinguished chiefly from syringomyelia, to which it sometimes bears a striking similarity. The various sensory disorders, however, when taken together with the lesions of the bones and joints of the extremities, with the mutilations and deformities, commonly observed in advanced stages of leprosy, with the history, often, of preceding pemphigoid eruption, and vitiligo or morphea-like patches, are quite characteristic.

In cases of doubtful nature, whatever the type of the malady, the final decision is often to be based upon the presence of the special bacillus, as determined by repeated examinations. Shepherd[1] advises, when the question of immediate diagnosis is one of great urgency, cutting down on the ulnar nerve, removing a portion, and examining for bacilli.

Prognosis.—The outlook for leprosy patients is unfavorable, a fatal termination with few exceptions being almost invariable, although the end may not be reached for a number of years. The tubercular form is the most grave, the mixed variety next, and the anesthetic the least. The statistics of the Trinidad Asylum, according to Rake,[2] show that the average duration is eight and one-half years. In some instances, especially of the anesthetic variety, it may be fifteen to twenty years or more. Patients are not infrequently carried off by intercurrent disease, although, as already referred to, apparently independent organic affections are often, in fact, due to leprous invasion and infiltration.

There seems scarcely question that mild or abortive types occur, though doubtless but rarely. Hansen and Looft, in quoting Danielssen's observations as to the Norwegian hospital, "that the results of treatment were nothing to boast of, but show that leprosy at its commencement can be cured," add the reservation "that the cure is not due to the treatment, but to the natural development of the disease." One cannot go over the literature without recognizing the fact that in exceptional instances patients recover, or at all events the malady remains permanently quiescent. Impey[3] is strongly of the opinion that some cases, especially the anesthetic, undergo spontaneous cure, and believes that in many so-called lepers the malady has already run its course, and that the effects alone remain, and may go on from the damage done the nerves. He quotes Hansen's studies as showing that the latter observer "had never found bacilli in the nerves of a chronic case, . . . and that he had examined the bodies of many of these patients after death, and found no bacilli in any organ."

[1] Shepherd, "Notes on a Rapid Method of Diagnosis in Leprosy," *Jour. Cutan. Dis.*, 1903, p. 476.

[2] Rake, *Report on Leprosy in Trinidad*, 1885.

[3] Impey, "The Non-Contagiousness of Anesthetic Leprosy," *Trans. Internat. Leprosy Conference.*

Thin, D. W. Montgomery, G. H. Fox, Ehlers, Hallopeau, Dyer, and others[1] have in recent years reported cures of the disease, spontaneously or as the result of treatment.

Under the most favorable circumstances of change of residence to a non-leprous district, improved hygiene, good food, supporting and tonic treatment, cleanliness, and aseptic applications, it seems, therefore, not improbable that exceptionally cases get well, or at least the disease ceases to be active.

Treatment.—The management of leprosy naturally includes a consideration of the means of prevention. There are still great differences of opinion as to the necessity of segregation, and each side of the question has much in its support. The conclusions of the International Leprosy Conference at Berlin, 1897, were, upon the whole, in favor of this, with certain qualifications as to its practice, depending upon local conditions.[2] It is generally recognized that the anesthetic cases are much less dangerous to a community than the tubercular form, and segregation less urgent. The necessity of segregation in districts where the cases are sparse, with no tendency to spread, and where lepers can be properly cared for at their homes, is questioned by many of considerable experience. As already stated, the imported cases in Paris, London, Vienna, Berlin, New York, Chicago, Philadelphia, and other places where the disease is not endemic have never given rise to others.

The treatment of leprosy has first in view the maintenance of the patient's general health by hygienic and other measures, and the employment of such tonics as may seem demanded. The value of change of abode to a non-leprous country, when possible, has already been alluded to, and will in some instances stay, and probably always delay, the progress of the malady. There are certain remedies for which special claims have been made from time to time by different observers.[3] The most important, and those which have received the greatest support, are Chaulmoogra oil (Le Page), gurjun oil (Dougall), and nux vomica or strychnin.

Chaulmoogra oil (oleum gynocardiæ, from the seeds of the *Gynocardia odorata*) is given in doses varying from 5 minims (0.33) to 1½ drams (6.) or more three times daily. It is administered in milk, in emulsion, or in capsules. As a rule, its good effects are obtained only by the larger doses, and these cannot always be reached, owing to the fact that the oil is so prone to disturb digestion, some persons being intolerant of even small quantities. As less irritating to the stomach, the active principle of the oil, gynocardic acid, has been also commended, usually in the form of magnesium or sodium gynocardate, in the beginning dose of ½ grain (0.033), and increasing gradually

[1] Thin, *Brit. Med. Jour.*, May 4, 1901, p. 1074; D. W. Montgomery, *Med. Record*, Apr. 19, 1902 (spontaneous; 6 cases); Hallopeau, *Annales*, 1903, p. 32; Dyer, *Med. News*, July 29, 1905.

[2] As especially bearing upon the control in our own country see papers by J. C. White, "The Contagiousness and Control of Leprosy," *Boston Med. and Surg. Jour.*, Oct. 25, 1894, and Morrow, "Prophylaxis and Control of Leprosy in this Country," *Trans. Amer. Derm. Assoc. for 1900.*

[3] See papers and discussions in *Trans. Internat. Leprosy Conference* for full details of the claims and experimental trials of the various special remedies.

to 3 grains (0.2) three times daily. Unna[1] makes a soap of the oil with soda, and gives this coated in pill form, and states that, according to his observations so far made, in this method of administration there is no disturbing influence on digestion. Conjointly with the internal administration it can also be prescribed by inunction. For this purpose it is mixed with 5 to 15 parts of olive or cocoanut oil, or as a 50 per cent. ointment with lard. It is to be rubbed in thoroughly, and, when possible, one to two hours daily. Before each fresh application the skin is washed with soap and water or by means of a warm bath.[2] Under the favorable influence of this drug the various disease manifestations abate, sometimes slightly, in others, but relatively few, quite decidedly, and exceptionally the malady is halted in its progress.

Gurjun oil (gurjun balsam, wood-oil, from the *Dipterocarpus turbinatus*) has had the warm support of Dougall, Hillis, and some others. It is usually administered in emulsion, composed of 3 to 5 parts of lime-water to 1 of the oil, and of which the dose is 2 to 4 drams (8.–16.) two or three times daily. It is also usually to be conjointly prescribed by inunction, with 1 to 3 parts of lime-water or olive oil, and thoroughly rubbed in one to two hours daily. Strychnin, or nux vomica (formerly as Hoàng nàn, powdered bark of *Strychnos gautheriana*), is another remedy which has had considerable reputation. It is frequently prescribed with one of the above oils. Piffard and G. H. Fox, of our own country, observed in one or two instances practical recovery under their conjoint use. Morrow also speaks well of the action of this drug. These three remedies, together with others which may be demanded by general indications, supported by hygienic measures, frequent baths, good food, open-air life, and, when possible, change of climate, will often accomplish much toward, at least, retarding the progress of the malady.

Many other remedies or plans of treatment have been variously tried or advocated, more especially in recent years. Unna has spoken well of ichthyol internally conjointly with external applications of reducing agents, to be again referred to. Sodium salicylate and salol have also had favorable mention, and arsenic has long been considered of possible value. Although mercury has been more or less considered as detrimental in the disease, lately Haslund and Crocker have reported markedly beneficial influence in several instances, the drug being administered by hypodermic injection deeply into the muscular tissue. Crocker employed the perchlorid of mercury, using $\frac{1}{4}$ grain (0.016) in 20 minims (1.33) of distilled water twice weekly. Carreau, and also Dyer, believe that good effects are sometimes obtainable by increasing doses of potassium chlorate, an observation previously made by Chisholm. Of the various serums tried in the disease but one, Carrasquilla's, has received as yet much attention; the amelioration claimed by this observer has not been verified by others,[3] although Arning, Buzzie, and Herman and Abraham, from their limited observations, consider it worthy of further investi-

[1] Unna, *Monatshefte*, 1900, vol. xxx., p. 139.

[2] Tourtoulin Bey, *Monatshefte*, vol. xl., 1905, p. 88, commends the administration of the oil by subcutaneous injections, preferably into the subcutaneous tissues of the forearm or leg—dosage 75 minims (5.).

[3] See discussion, *Trans. Internat. Leprosy Conference*, Berlin, 1897.

gation. Recently Dyer,[1] and subsequently Woodson,[2] have made a few experimental trials with antivenene (Calmette), or attenuated snake poison, the former being led to its employment by the observation of Carreau, that in a case of leprosy observed by him there occurred, after the patient had been bitten by a snake, marked amelioration in the leprous manifestations. The improvement following in Dyer and Woodson's few cases warrants its further experimental use. Injections of tuberculin and also of the combined toxins of erysipelas and the bacillus prodigiosus have also had some trials, but with negative results. Rost[3] claims a good proportion of cures, and improvement in all, from injections of leprolin. Wilkinson[4] reports a few apparent cures from X-ray treatment.

The external treatment consists essentially in the maintenance of cleanliness and an aseptic condition of the general surface, in order, so far as possible, to avoid the suppurative complications due to infection by pyogenic cocci. Frequent baths, the use of boric acid, formalin, carbolic acid, and resorcin lotions, and sometimes sulphur baths, are some of the measures to this end. Certain remedies have, however, been employed with alleged special influence, such as Chaulmoogra and gurjun oils, already mentioned, the inunctions by which, in addition, however, have in view absorption and some constitutional action. Cashew-nut oil has been similarly employed, both externally and internally. In the opinion of some the good effects of these oils externally used lie, in great part, in the associated prolonged rubbing. Unna has strongly commended, along with the internal administration of ichthyol, the local applications of ointments containing the reducing agents, resorcin, pyrogallol, chrysarobin, salicylic acid, and also ichthyol; a compound formula recently advised by him, consisting of salicylic acid, 2 parts; ichthyol and chrysarobin, each, 5 parts; vaselin 100 parts. To limited areas the pyrogallol can be added in the same quantity as the chrysarobin, or can be substituted for the latter. In some instances excision and curetting of the nodules and infiltrations have been practised, but the results are scarcely such to justify such heroic measures. Ulcerations should be kept thoroughly cleansed, and, so far as possible, aseptic, by the use of hydrogen dioxid washings, weak corrosive sublimate solutions, boric acid lotions, and similar applications. As ointments for applying to open lesions may be mentioned those containing aristol, resorcin, salicylic acid, ichthyol, balsam of Peru, and the like. Robertson[5] commends application of formalin, using it diluted to open wounds, and pure to other lesions. For the relief of the painful neuralgias, sometimes of severe character, Rake and others have reported good results from nerve-stretching. Electricity has been employed with some benefit to anesthetic areas.

[1] Dyer, "A Preliminary Report on the Use of Antivenene in the Treatment of Leprosy," *ibid.*, vol. iii., p. 500; and *New Orleans Med. and Surg. Jour.*, Oct., 1897.

[2] Woodson, "The Treatment of Leprosy by Injection of Calmette's Serum Antivenene," *Philada. Med. Jour.*, Dec. 23, 1899.

[3] Rost, *Indian Med. Gaz.*, May, June, and Dec., 1904, reports that he has succeeded in cultivating the bacillus, and from the cultures has prepared an inoculating fluid, which he calls leprolin.

[4] Wilkinson, "Leprosy in the Philippines, with an Account of Its Treatment with X-rays," *Jour. Amer. Med. Assoc.*, Feb. 3, 1906.

[5] Robertson, *Jour. Trop. Med.*, 1904, p. 26.

CLASS VII.—NEUROSES.

HYPERESTHESIA.

THIS condition is characterized by morbidly acute sensitiveness to external impressions. The painful phenomena occurring in hyperesthesia are started by external factors, while in dermatalgia they arise spontaneously. Like anesthesia, it may be idiopathic or symptomatic, although the far greater number of cases belong to the latter category. As a rule, only a small or a large area of the skin surface may be affected, but the condition may become general. The attacks excited may be only of a mild character, or they may become exceedingly agonizing. They have been compared to electric shocks, and described as pricking, darting, and burning sensations. Hyperesthesia is usually unaccompanied by any local change of temperature. There are a number of possible causes: it may be dependent on functional disturbance or some pathologic change in the brain and spinal cord or other deranged condition of the nervous system; it is frequently met with in hysteria and neurasthenia. In well-marked cases the cutaneous surface is sensitive to an abnormal degree, and even contact with the clothes and the air gives rise to decided discomfort. It varies in duration; it may be only temporary or may become chronic. Occasionally cases of hyperesthesia present themselves in which it is difficult or impossible to determine the *fons et origo mali;* such instances belong to the idiopathic variety.

The prognosis and treatment will depend wholly upon the character of the underlying condition.

Meralgia paræsthetica.—This peculiar, rare condition involving the skin of the outer lower two-thirds of the thigh, to which some neurologists and White[1] have recently called attention, is characterized by perverted sensations somewhat varied in the same case and sometimes different in different cases. The most common sensations seem to be those of tingling, formication, heat and cold. Less frequently, there have also been noted pain, numbness, tension, constriction, distention, hyperesthesia, anesthesia, imaginary movements and pruritus, and rarely a sense of throbbing. They are not, as a rule, constant, and usually occur when the patient is standing or walking. Various causes have been assigned, such as neuritis, rheumatism, gout, alcoholism, and as following infectious diseases, severe colds, etc. The area involved seems to be that supplied by the external femoral cutaneous nerve. Treatment is usually without effect, although massage has given partial and temporary relief in some cases. Goldenberg had prompt cure in a case from the wearing of a metal plate in the shoe for the relief of a flat-foot.

[1] J. C. White, "Meralgia paræsthetica," *Jour. Cutan. Dis.*, 1906, p. 160.

DERMATALGIA.

Synonyms.—Neuralgia of the skin; Rheumatism of the skin; *Fr.*, Dermalgie; *Ger.*, Nervenschmerz der Haut.

Definition.—Dermatalgia, or dermalgia, is characterized by pain in the skin independent of any structural lesion.

The pain is usually localized; it may, however, be more or less general. Various sensations are experienced, such as burning, stinging, pricking, shooting pains, which are generally aggravated during the night. It is spontaneous, and constant or intermittent in character, insignificant or severe. Motion and the slightest contact may give rise to a severe attack. It is seated more commonly in hairy portions of the body, and is most frequently seen in middle-aged females. It is often associated with hyperesthesia, more or less pronounced. It is usually confined to the superficial layers of the skin, which present no perceptible changes, being to all appearances normal in thickness, coloration, and temperature.

It is a difficult matter to decide in a given case whether the pain is idiopathic or attributable to some pathologic change in the nerve-centers. Rheumatism would seem to act as an exciting cause in quite a number of cases; exposure to cold, chlorosis, and hysteria are also factors. Systemic disorders, as syphilis, diabetes, etc., and pathologic alterations of the nervous system, as in locomotor ataxia, play an important rôle in its production.

Causalgia, which is characterized by a burning pain with pain and tenderness at various neighboring points, and accompanied with a glossy state of the skin in the area of a nerve that has been injured, may be regarded as an allied affection.

From neuralgia and muscular rheumatism it may be differentiated by having its seat usually in circumscribed areas of the skin and by being more superficial in character. In pruritus pain is absent and itching is a prominent feature; in dermatalgia, moreover, the area involved is generally limited.

Treatment.—This will be governed by the underlying cause and whether we have to deal with a symptomatic or idiopathic variety of dermatalgia. The general health must be carefully looked after, and if a gouty or rheumatic history is disclosed, the appropriate remedies should be prescribed. In chronic cases careful search must be made for any existing disease of the nerve-centers. Local applications may be resorted to, such as blistering the part; tincture of aconite root and diluted tincture of belladonna or galvanism may be applied to the sensitive area. As a rule, however, external remedies fail to accomplish very much. Quite frequently, after several weeks, the pain disappears spontaneously.

ERYTHROMELALGIA.

Under this title Weir Mitchell[1] described, in 1878, a peculiar condition of the extremities characterized by burning, aching, and neuralgic pain, and associated with, subsequently, the development of redness of the affected parts. Since then other contributions on the subject have been made by Lannois,[2] Senator,[3] Gerhardt,[4] Bernhardt,[5] Dehio,[6] Eulenberg,[7] Staub,[8] Pezzoli,[9] Carslaw,[10] and others. The malady may involve one or both hands or feet or all four extremities, and may be limited to one or several of the toes or fingers. It begins usually in a limited area, and gradually, but as a rule slowly, extends. The temperature of the affected part is generally increased, and there is sometimes an exaggerated sensibility or hyperesthesia, while in other instances this is intact. The pain is noted to be augmented when the part is warm. In extreme development the parts are somewhat swollen, and may present a pseudophlegmonous appearance, and, especially during the pain attacks, there may be noticed venous engorgement and arterial throbbing felt. The paroxysms may come on suddenly, and sometimes are excited by pressure or a knock. There is no regularity, however, as to painful attacks nor to their duration; sometimes frequent, and lasting from several minutes to an hour or more, exceptionally more or less continuous. In occasional instances, as in a case reported by Morel-Lavallée,[11] nutritive disturbances of the nails of the affected part were noted. In some cases attacks of local sweating are noticed.

Etiology and Pathology.—The malady is rare, and may effect either sex and almost all ages. Lannois's analysis shows a marked preponderance of males. According to Hallopeau and Leredde,[12] it is much more common during adolescence and youth. It is apparently in some cases an idiopathic affection, in others a part or symptom of central nervous disease. Machol[13] saw it in a paralytic, and in Gelpe's[14] case symptoms of meningitis and cardialgia had already presented. Collier's[15] study shows multiple sclerosis in 6 cases, tabes in 2, myelitis in 1, and traumatic necrosis in 1; and he cannot, therefore, from his observation as well as an examination of the literature, accept the view of its being an idiopathic vasomotor neurosis, but is of the opinion that it is merely a symptom of central nervous disturbance. This conclusion is not, however, in accord with Mitchell and

[1] Weir Mitchell, *Philadelphia Med. Times*, 1872, pp. 81 and 113, and *Amer. Jour. Med. Sci.*, 1878, vol. lxxvi., p. 17 (presentation of a number of cases and discussion of its relation to allied conditions).

[2] Lannois, *Paralysie vasomotrice des extrémités ou Erythromélalgie*, Paris, 1880 (with citations and references).

[3] Senator, *Berlin. klin. Wochenschr.*, 1892, p. 1127. [4] Gerhardt, *ibid.*, p. 1125.

[5] Bernhardt, *ibid.*, p. 1129. [6] Dehio, *ibid.*, 1896, p. 817.

[7] Eulenberg, *Deutsche med. Wochenschr.*, 1893, p. 1325.

[8] Staub, *Monatshefte*, vol. xix., 1894, p. 10 (with some references).

[9] Pezzoli, *Wiener klin. Wochenschr.*, 1896, p. 1263.

[10] Carslaw, *Glasgow Med. Jour.*, vol. l., 1898, p. 438.

[11] Morel-Lavallée, *Annales*, 1891, p. 708.

[12] Hallopeau and Leredde, *Dermatologie*, 1900, p. 769.

[13] Machol, *Berlin. klin. Wochenschr.*, 1892, p. 1319.

[14] Gelpe, *Correspondenzbl. f. Schweitzer Aerzte*, 1899, p. 14 (case demonstration).

[15] Collier, *Lancet*, 1898, vol. ii., p. 401 (10 cases).

Spiller's[1] study and histologic examination of the tissues in one instance, who found in this case that the malady could be ascribed to a peripheral neuritis, with degenerative changes in the nerves, although they also state that it may have its origin in involvement of the sensory fibers anywhere between the peripheral ramifications and the spinal cord. Morel-Lavallée's case was associated with a mild type of Raynaud's disease.[2]

It is not improbable that the division of the cases of erythromelalgia into three groups, made by Lewin and Benda,[3] is justified by the clinical and etiopathologic facts: (1) Central organic disease; (2) central functional disturbance; (3) peripheral irritation or disease; the last representing the idiopathic erythrodermias with purely local symptoms.

Prognosis and Treatment.—The outlook for the malady is not a very favorable one, although in some cases the symptoms are slight and not very troublesome. Treatment is purely expectant. Cooling applications, such as menthol and salicylate of methyl, give variable relief; favorable influence from faradization (Duchenne, Sigerson, Brocq) and from the continued current (Eulenberg) has also been observed. Weir Mitchell tried stretching and cutting the nerves supplying the affected part, and amputation of the involved toe, but with variable result; the former curing in one instance, but in another gangrene resulted. Sloughing followed amputation in one case, with partial eventual recovery as to the local symptoms. Of internal remedies, some influence is reported from sodium salicylate, antipyrin, and acetanilid.

PRURITUS.

Definition.—Pruritus is a functional affection of the skin, having as its sole symptom itching, burning, or pricking sensations.

Symptoms.—Pruritus, or itching, as an associated symptom of other cutaneous diseases attended by structural changes, is entirely distinct from the affection under consideration. In this malady it is the sole and essential symptom, with no other sign or feature except those which may sometimes arise secondarily. There are, therefore, no primary structural lesions, but in severe and persistent cases the parts sometimes become so irritated by continued scratching and rubbing to which the pruritus gives rise that secondary lesions, such

[1] Weir Mitchell and Spiller, *Amer. Jour. Med. Sci.*, vol. cxvii., 1899, p. 1 (with histologic cuts, review of the subject, and full references).

[2] There is sometimes considerable similarity in the cutaneous symptoms of these various vasomotor and other nerve disorders. **Erythromelia** is another, which, as Pick ("Ueber Erythromelie," Ergänzungsband (*Kaposi's Festschrift*), *Archiv*, 1900, p. 915, with colored plate and references to other cases) states, has in the objective and pathologic characters a slightly suggestive relationship to erythromelalgia, although quite distinct. This peculiar affection, which is rarer than erythromelalgia, Pick summarizes as a symmetric, painless, cutaneous condition, more or less circumscribed, with progressive livid redness radiating from the central part toward the periphery, and seated on the extensor surfaces of the legs and arms, showing venous dilatation, but with no further changes in the skin; Klingmüller and Rille (quoted by Pick) have observed retrogressive atrophy, and others have noted a partial disappearance of the malady.

[3] Lewin and Benda, *Berlin. klin. Wochenschr.*, 1894, pp. 53, 87, 117, and 144 (a critical review with references).

as follicular papules and slight thickening and infiltration may result. As a rule, however, excepting often evidences of scratching, pruritus remains the only recognizable feature of the malady. The character of this symptom varies somewhat in different individuals and sometimes from time to time in the same individual. Most commonly it consists purely of itching of variable degree, from slight to intense, occasionally of almost intolerable severity. In others it is a feeling of tingling, pricking, stinging, heat, or burning. In exceptional cases it is described as similar to formication, as though insects were crawling over or in the skin. It is occasionally constant, with but slight intermitting abatement, but is usually more or less paroxysmal, and, as a rule, much worse toward evening and the early part of the night. The desire to scratch is often irresistible, and in consequence, as already remarked, a variable degree of irritation may in some instances finally be provoked, although commonly nothing more than slight hyperemia, trifling harshness or roughness, with few or many linear scratch-marks or punctate jags made by the finger-nails. It is to be said, however, that in the vast majority of cases the skin remains free from lesions, except possibly scattered excoriations. It is by far more frequent in those of advanced years (**pruritus senilis**), especially those whose integument begins to show some of the old-age changes. The itching may be more or less general (**generalized pruritus; pruritus universalis**), or it may be localized or limited in extent (**local pruritus; pruritus localis**). It is rather exceptional to find it involving the whole surface, but is quite frequently found confined to a large region, such as the trunk, limbs, and especially the legs. Sometimes, on the other hand, it is limited to a small area, such as the nose, the ear, the palms or soles, and other locations to be referred to.

It is not at all uncommon to find it restricted to the genital region. In men the scrotum may be its only seat (**pruritus scroti**), sometimes extending along the perineum; or it exceptionally restricts itself to the urethral orifice. It is probably more frequent during active adult life.

In women the whole vulvar region (**pruritus vulvæ**) may be subject to paroxysmal or more or less persistent itchiness, sometimes chiefly or wholly limited to the labia, clitoris, or even the outer end of the vaginal canal. It may be met with in young children, due to the presence of intestinal worms, but it is usually observed in women of middle or advanced life. The itching is often most distressing, the desire to scratch frequently irresistible, so that such patients are often obliged to shun society. In persistent and severe cases, from the constant scratching or rubbing, a veritable eczema sometimes eventually develops.

Another locality often the site of pruritus is the anus (**pruritus ani**), and here it is often of an intense character, but, as a rule, more or less paroxysmal. The anus often has a sodden look, that is usually associated with a foul-smelling secretion (Bronson). It is not infrequently associated with hemorrhoids (itching piles). All ages and both sexes are liable, but it is more common in active adult life and advanced years and in males. In marked cases of pruritus ani

Adler[1] states that a characteristic condition of the disease is the loss of the natural pigment of the part. In all probability, however, this is merely coincidental.

In addition to the several local varieties named, a few others should be mentioned. **Pruritus hiemalis** (*winter itch*, *frost itch*), to which Duhring[2] originally and subsequently others (Hutchinson, Payne, Porras, Corlett)[3] called attention, is a somewhat peculiar type. It is commonly confined to the lower extremities, although occasionally involving the arms also, and exceptionally other parts. It is observed, as a rule, only in adults, and presents in the beginning cool weather, in October or November, and often persists until late spring. It is not constant, but usually comes on at night, when the patient is disrobing, after having undressed, or just after retiring. The itching varies in different cases, but it is frequently quite intense, and the desire to scratch cannot usually be restrained. After a variable paroxysm, lasting some minutes to an hour or more, during which time the patient often scratches and rubs considerably, relief finally comes. The next night the paroxysm recurs, and so on, in most instances nightly. In some cases there may be a recurrence when the patient rises, and exceptionally it may be more or less persistent during the whole night. It is rarely present or troublesome at other times. As a result of the rubbing and scratching the legs, in severe instances, become somewhat roughed, hyperemic, and excoriated, the hairs often torn or broken off close to their follicles, and in rare examples the parts may finally present a slightly eczematous aspect. The malady often varies in severity, and its intensity is lessened during periods of milder weather, and sometimes disappears entirely during such times, to reawaken as soon as the weather becomes colder. So it continues in most cases all winter, finally disappearing as late spring approaches, and remains in abeyance until the following autumn. In other instances it continues for several weeks and then becomes milder and finally disappears.

It is believed that many of the cases of the so-called *prairie itch*, *swamp itch*, *lumberman's itch*, *Ohio scratches*, *Texas mange*, etc., observed chiefly in our Western and Northwestern States, are examples of pruritus hiemalis, possibly modified or aggravated by the cold and windy, hard, outdoor life, and the rough, and often dyed, character of the cheap woolen underwear. These terms are, however, as Hyde states,[4] "loosely applied to a group of cutaneous symptoms of diverse origin, the most frequent of which is pruritus hiemalis." Many others of this group are doubtless cases of scabies. The few patients who have come to my notice—from the West, where they alleged the same malady was prevailing quite extensively—were cases of this parasitic disease.

[1] Adler, "Etiology, Symptomatology, and Treatment of Pruritus Ani," *Philada. Polyclinic*, 1895, Nos. 39, 43, and 50 (review of the subject, with references).

[2] Duhring, *Philada. Med. Times*, Jan. 10, 1874.

[3] Hutchinson, *Brit. Med. Jour.*, 1875, ii., p. 773; Payne, *ibid.*, May 7, 1887; Morago Porras, *Trans. Internat. Cong. Derm. and Syph.*, 1889, p. 911; Corlett, *Jour. Cutan. Dis.*, 1891, p. 41.

[4] Hyde, "On the Affections of the Skin Induced by Temperature Variations in Cold Weather," *Chicago Med. Jour. and Exam.*, Mch., 1885, and Feb., 1886; also Hyde and Montgomery, *Diseases of the Skin*, fifth edit., p. 758.

Another variety of pruritus (**bath pruritus**)[1] is that associated with baths, a number of examples of which have come to my notice from time to time. The itching or burning immediately follows a bath. The sensation varies greatly even in the same individual, sometimes being relatively slight, at other times intense. The feeling is one of pricking, burning, or almost intolerable itching. It is usually aggravated if the patient yields to the desire to rub or scratch violently. While it may exceptionally be general, it is commonly seated in the legs, from the hips down, and occasionally in the forearms also. The attack lasts from several minutes to half an hour or longer, becoming increasingly intense and then gradually subsiding. It is usually of longer duration when the patient goes directly from the bath to his bed; if his clothing is immediately donned, the pruritus will generally be less unbearable, less marked, and of much shorter duration, especially if he walks about, so as to get the soothing effect of the gentle rubbing of the underwear. It is met with in adolescence and adult life, and, according to my observations, chiefly in males, and in those having an irritable and dry skin.

Etiology.—The most common factors to be considered as of probable import in more or less generalized pruritus are digestive and intestinal derangements, hepatic disorders, intestinal worms, uric acid excess or saturation, Bright's disease, ovarian or uterine functional or organic diseases, diabetes mellitus, carcinoma, tuberculosis, gestation, and a depraved state of the nervous system. Of these, the first two are most frequently causative. It has long been recognized that pruritus is often associated with jaundice. Certain dietetic and medicinal agents, such as named as sometimes etiologic in urticaria, are also occasionally provocative. In those of advancing years (pruritus senilis), as already stated, the degenerative changes which the skin undergoes are doubtless an important factor in these patients. According to Bronson,[2] who has given the subject careful consideration, "Of the general conditions that act as *predisposing causes* of pruritus, whether it occur as an essential disease or is predominated by some other disease of which it is a symptom, by far the most important is *hyperesthesia*. This may be either congenital or acquired, and either local or general. It may be acquired through diseases that affect the economy at large, or that are localized in the skin. The general diseases producing it may be idiopathic neuroses, such as hysteria or hypochondriasis and other affections of the nervous centers, or general nutritive diseases affecting the nervous system secondarily, such as arthritism or diabetes mellitus. In all the cases the primary effect of the general disease is simply greatly to heighten the susceptibility of the peripheral nerves, causing exaggerated sensations from the slightest contacts. The *exciting causes* consist of irritations that may be either indirect and conveyed to the skin from the anterior of the body, or direct, in which case the excitation is

[1] Stelwagon, "Bath Pruritus," *Philada. Med. Jour.*, Oct. 22, 1898.

[2] Bronson, "Etiology of Itching," *Med. Record*, Oct. 24, 1891, and "Itching; Its Occurrence Both as a Concomitant and Cause of Disease, and Treatment," *Med. News*, April 18, 1903. See also papers by McCall Anderson and Brooke, on "The Pathology and Treatment of Pruritus," *Brit. Jour. Derm.*, 1895, pp. 292 and 294.

produced by local irritants, whether arising from extraneous sources or from sources that are intracutaneous."

The causes of localized forms of pruritus have in part been incidentally referred to. Pruritus vulvæ in children may be due to intestinal worms, especially ascarides in the rectum, and exceptionally even in the vagina itself. The same causes are possible, although less likely in women. Leukorrheal discharge is also sometimes provocative. Any irritation or derangement of the utero-ovarian system may likewise serve as a reflex cause. Diabetic urine, by its local irritating action, is sometimes responsible for a vulvar pruritus, although, as a rule, in most instances the itching is merely a part of an eczema which has been thus provoked. It is not at all uncommon at the time of the menopause, during which period it may be a reflex condition brought about by some nearby irritation of the utero-ovarian apparatus, or a part of a general neurosis. In both sexes this localized pruritus is sometimes to be attributed to some genito-urinary disease, such as vegetations or polypi or other irritation or stricture (Bangs) of the urethra, and to vesical calculi. Pruritus ani, in addition to being frequently associated with hemorrhoids, as already stated, may also be due to a fissure, fistula, or to hyperidrosis of the part. Constipation, ascarides in the rectum, varicose condition of the veins of this part of the bowel, and, in occasional instances, the use of hard or printed substances for toilet purposes may excite the malady by the variable irritation thus produced (Adler).

In pruritus hiemalis cold weather is the essential factor, although, according to my observations, it is to be observed chiefly in those whose skin sweats but slightly and is lacking in the natural oiliness. Added to these are to be mentioned gouty tendency and defective digestion, and the irritation of rough woolen underwear. In bath pruritus the actual cause is the water, although certain factors, in some cases at least, have an influence. Strong soaps tend to aggravate it, and mild soaps, if used in too great freedom or if not fully rinsed off, seem also to have a damaging effect. Long continuance in the water will usually promote and aggravate an attack. Very hot or very cold water is also an aggravating influence in some individuals, although, as a rule, the active factor is the bath itself, independently of the temperature of the water. It is observed chiefly, if not entirely, in those who have a naturally dry, harsh, and irritable skin. Those affected are distinctly those of a nervous temperament, weak digestion, and lithemic tendencies.

Pathology.—The disease is a sensory neurosis. There is nerve disturbance, without associated appreciable structural change, and the provocative irritation may be either of reflex origin or direct, and may have its seat at any part of the nervous system from center to periphery. The tissues remain unaltered throughout the entire course of the malady, except so far as secondary conditions are, in some instances, brought about by the persistent scratching and rubbing.

Diagnosis.—The subjective symptom of itching without the presence of structural lesions is diagnostic. In those severe and per-

sistent cases in which excoriations and papules have resulted from the scratching, the history of the case, together with its behavior and course, must be considered. Care should be taken not to confound it with pediculosis, which is possible in those instances of the latter showing relatively slight reactionary irritation; in most cases of pediculosis, however, the excoriations, often with intermingled papules and pustules, and their peculiar distribution, being most abundant on those parts of the body with which the clothing comes in contact, as especially across the shoulders, upper part of the back, around the wrist, and outer aspects of the limbs are quite characteristic. In suspected cases inner garments, and especially the seams, particularly of the neck-band, should be examined for pediculi. The lesions of scabies and the distribution will prevent confusion as to this malady. The possibility of itchiness being due to other parasites, such as bed-bugs, fleas, gnats, etc., must be borne in mind, but in such instances, as in the other parasitic affections already named, the presence of bites, lesions, distribution, and history will usually suffice to prevent error. Urticaria can be distinguished by the presence or history of wheals and its capricious character.

In pruritus of the genital region the first essential is to exclude its being due to pubic lice. In this latter malady (pediculosis pubis), in addition to excoriations, various lesions, such as papules and pustules, are commonly to be found, and a careful search will discover ova on the hair-shafts, and the parasites near or on the skin, usually grasping a hair. Pruritus can scarcely be confounded with eczema, as the lesions, redness, and infiltration of the latter are wanting. The mistake is most likely to occur when about the vulva or anus, as here it is not uncommon for the rubbing and scratching to bring about some infiltration; in fact, in some instances a veritable eczema may be thus provoked.

Prognosis.—This depends, in great measure, upon the discovery of the causes and the possibility of their removal or modification. The malady is usually troublesome and often rebellious, although in the majority of cases the condition responds to proper treatment. Pruritus of the vulva is always obstinate, likewise that of the anus. Pruritus hiemalis can at the best, as a rule, be only palliated or kept in abeyance, but disappears spontaneously toward the advent of mild weather. Bath pruritus permits usually of palliation, but absolute relief can scarcely be promised without considerable qualification. Temporary relief can, however, in all varieties, always be given by external applications.

Treatment.—In the treatment of this disorder the various possible etiologic factors of digestive and intestinal disturbance, hepatic disorders, diabetes mellitus, the uric acid diathesis, renal and utero-ovarian diseases, and a low state of the nervous system must all be considered. The constitutional treatment, if deemed advisable, will therefore depend upon the conclusion reached from a study of the individual case. The diet should be plain and unstimulating, and, when necessary, adapted to any special etiologic conditions which may exist. Alcoholic drinks are usually harmful. In many instances a saline laxative in the morning, with a dose of an alkali

after each meal, will do much toward relieving the patient. Moderately large doses of sodium salicylate, salophen, or of the lithia salts will aid in cases dependent upon gouty or rheumatic conditions. In many instances, it is true, it is difficult to recognize any etiologic factor; in such, constitutional treatment must be wholly experimental, quinin in large doses, pilocarpin, belladonna, strychnin, cannabis indica, lupulin, calcium chlorid (Savill), and even arsenic being tried. Cannabis indica, in the form of the tincture, 10 to 30 minims (0.65–2.) three times daily, as commended by Bulkley, and subsequently by Crocker, can be tried in rebellious cases. Schamberg commends moderate to full doses of carbolic acid. In those in which the itching is intense and not sufficiently controlled by external applications anodynes must be given internally—potassium bromid, chloral, sulfonal, cannabis indica, phenacetin, acetanilid, and antipyrin being variously prescribed. The opium preparations are, as a rule, not well borne, tending usually, after the narcotic effect has passed off, to increase the itching. General galvanization, static insulation, and the application of static electricity by the roller electrode down the spine furnish relief in occasional instances.

The external treatment of pruritus is of great importance, and, indeed, essential in almost all cases. In most patients unirritating underwear, such as cotton, lisle thread, silk, or linen, should be worn next to the skin, as woolen garments are frequently an additional exciting factor in these cases. Among remedial applications lotions are, as a rule, most satisfactory, although in some patients the itching seems to be due to a lack of oiliness of the skin, and, in this latter class, ointments even of an extremely negative character often give relief. The most commonly prescribed local remedial agent is carbolic acid; this is applied usually in the form of a lotion as follows:

℞.	Acidi carbolici,	ʒj–iij (4.–12.);
	Glycerini,	fʒij (8.);
	Alcohol.,	fʒj (32.);
	Aquæ,	q. s. ad Oj (500.).

Or, and more especially in the local varieties of pruritus, in an ointment or oil, from 5 to 20 grains (0.33–1.33) to the ounce (32.) of petrolatum or rose-water ointment or liquid petrolatum. Bronson prefers the use of this drug in oil, and employs it in 12.5 to 25 per cent. proportion, which he states may, with proper precautions, be used with perfect impunity, provided the area to which it is applied is of moderate extent. His favorite formula is 1 to 2 drams (4.–8.) of carbolic acid, 1 dram (4.) liquor potassæ, and 1 ounce (32.) of linseed oil, to which a few drops of bergamot oil can be added. Thymol is another valuable application, used as an ointment, from 5 to 20 grains (0.33–1.33) to the ounce (32.), or as a lotion, from 8 to 16 grains (0.52–1.) to the pint (500.) of water, with sufficient alcohol and glycerin for its solution. Resorcin is also valuable as a wash, from 3 to 10 grains (0.2–0.65) to the ounce (32.), with a few minims of glycerin and alcohol. Liquor carbonis detergens, with from 3 to 20 parts of water; and liquor picis alkalinus, from 1 to 3 drams (4.–12.) to the pint (500.) of water, are both of service in some cases.

To all these lotions the addition of 3 to 10 minims (0.2–0.65) of glycerin to the ounce (32.) is often an advantage, as many of these patients have rather dry skin; it should not be used, however, in large proportion.

Alkaline baths, with from 1 to 4 ounces (32.–128.) of sodium carbonate, bicarbonate, or borate to the 30 gallons of water, in which the patient lies for from ten to thirty minutes, are, more especially in those with oily or not too dry a skin, not infrequently useful; after the bath the patient taps himself dry with a soft towel, and applies a small quantity of petrolatum, cold cream, or a bland oil, plain or medicated, as may seem to be demanded; following this a dusting-powder of starch, rice-flour, or corn-starch is to be freely dusted on. This should be repeated every two or three days. In place of the bath, alkaline lotions containing one of the several alkalis named, of the strength of from ½ grain to 2 grains (0.033–0.13) to the ounce (32.), may be used, also to be followed up with an oily application. A compound lotion, such as the following, although smacking strongly of polypharmacy, has acted well in some cases: ℞. Acidi carbolici, ʒij (8.); thymol, gr. xvj (1.); resorcini, ʒss–j (2.–4.); sodii boratis, ʒss (2.); glycerini, f℥ij (8.); alcohol, f℥j (32.); aquæ, q. s. ad Oj (500.). In some instances acid lotions seem to act well, consisting of 1 part of ordinary vinegar to 5 or 10 parts of water, or of acetic acid 1 part to from 20, 30, or more parts of water. In other cases the free use of a dusting-powder alone seems to protect the skin from the air, and in this manner probably gives relief; powder applications may also be used as supplementary to lotions.

In the local varieties—pruritus vulvæ, pruritus scroti, and pruritus ani—the various remedial applications already named often suffice to give relief. All possible etiologic factors should be considered, and any indicated treatment instituted. In addition to the applications referred to, however, and probably of greater benefit, may be mentioned menthol, applied as an ointment or in liquid petrolatum, from 5 to 20 grains (0.33–1.33) to the ounce (32.); an ointment or solution of cocain, from 1 to 10 grains (0.065–0.65) to the ounce (32.); an ointment made up of from ½ dram to 1 dram (2.–4.) each of chloral and camphor to the ounce (32.) of simple cerate or petrolatum; and one consisting of from ½ dram to 1 dram (2.–4.) of chloroform to the ounce (32.) of simple cerate or petrolatum. Tarry ointments, although disagreeable, are sometimes quite serviceable in pruritus ani; after thoroughly rubbing in, the part is wiped off, and a simple dusting-powder applied. A free action of the bowels should be maintained in pruritus ani, as well as, in fact, in all varieties; in this form the salines or fluid extract of cascara sagrada can be employed, and sulphur as a laxative is also often valuable in these cases. In pruritus vulvæ, especially in cases due to irritating discharges, astringent applications and injections of alum, tannic acid, or zinc sulphate, in the strength usually employed for vaginal injections, will be found of service. Hot-water injections, repeated once or twice daily, will also prove useful in some instances. Another plan of treatment which has done good in some cases of the local forms of pruritus is the application of a sinapism or small blister over the lower lumbar region (Crocker). An occasional painting of the region with a 2 to 5 per

cent. solution of silver nitrate in sweet spirits of niter is of service in some instances. As a temporary expedient to bridge over an intense paroxysm, dousing the part with hot water, as hot as can be borne, can be resorted to. The X-ray has proved of value in some cases of these localized forms of pruritus. In persistent inveterate cases of pruritus vulvæ resection of the supplying sensory nerves has been exceptionally practised (Hirst, Deaver).[1]

In that variety of pruritus due to temperature changes (*pruritus hiemalis*) the several applications already enumerated may be tried; in many instances the skin is dry and harsh and needs oil, and in such the daily application of a plain ointment will give relief; or the addition of 10 grains (0.65) of salicylic acid to the ounce (32.) will be found valuable; or a weak glycerin lotion, from 4 to 8 drams (16.–32.) to the pint (500.) of water, may also act well. A combination that has served me in some of these cases consists of equal parts of lanolin, petrolatum, and benzoated lard, with 10 grains (0.65) of salicylic acid to the ounce (32.); and in others the addition of from 3 to 10 grains (0.2–0.65) of menthol. Underwear of non-irritating character is especially necessary in this form of the malady, with sufficient outer woolen covering, however, for sufficient warmth; cold, especially if combined with high winds, being distinctly etiologic.

In bath pruritus, as to the matter of treatment, unfortunately very often but little more than palliation can be accomplished. The water used should be between tepid and warm, neither hot nor cold. Exceptions to this rule will be observed, and some patients find the attack slight or less severe after a cold bath and some after a hot bath. Soaps should be mild and used sparingly, and be thoroughly rinsed off. The parts should be wiped or preferably tapped gently dry with a soft towel; it seems that if the skin is allowed to dry itself or is incompletely wiped or tapped dry the itching is usually much worse. In some cases the introduction of some substance into the bath, such as salt, in order to bring it up to the specific gravity of the blood, is of value. The bath should be of short duration. Application, by gently rubbing in, of a glycerin lotion or of an ointment of cold cream and lanolin, with or without a minute quantity of carbolic acid or thymol, will frequently lessen the severity of, or exceptionally abolish, the attack. The free use of a dusting-powder following the bath has also at times a palliative influence. The attack will be less unbearable if the bath is taken at such time as the patient immediately dresses and stirs about. Weak alkaline baths are sometimes less exciting than plain or soap-and-water baths. The Turkish bath is not so likely to be followed by the pruritic attack (Hall).[2] Constitutional treatment should be advised, especially if there seems to exist any of the predisposing factors mentioned. The bowels should be kept free, a plain diet enjoined, the digestion carefully looked after, and the nervous system kept in proper tone. In some of the cases antilithemic remedies, especially moderate doses of sodium salicylate, seem of positive value. A physician[3] reports the control of the affection in himself by fair doses of arsenic.

[1] B. C. Hirst, *Amer. Medicine*, 1903, vol. v., p. 785; Deaver (Discussion), *Proceedings of the Philada. County Med. Soc'y*, April 30, 1903, vol. 24, No. 4.

[2] Hall, *Philada. Med. Jour.*, Dec. 24, 1898.

[3] *Ibid.*, Jan. 7, 1899.

ANESTHESIA.

This condition—strictly speaking—belongs to the domain of the neurologist; as it plays a not important rôle, however, in some cutaneous maladies, it may be briefly referred to. Cutaneous anesthesia is central or peripheral in origin. There may exist structural change in the skin, or this may be absent. It may be local or general; usually it is limited to certain areas, or it may affect only one, or even both, sides of the body. There exists numbness in the areas involved, or the sense of feeling may be entirely lost. The sense of touch is also quite frequently impaired, sometimes partially, but probably more commonly completely. It may affect only a single nerve-tract, or several may be involved. In the condition known as analgesia dolorosa of Romberg there is acute pain in the part, yet sensibility is lost. It may be idiopathic or symptomatic, and due to causes acting from without or within. The most usual external causes are cold, the local application of ethyl chlorid, cocain, chloroform, etc. The effects of the administration of internal anesthetics, such as chloroform, ether, nitrous oxid, etc., are too well known to require more than simple mention. Lesions of the nervous system and pathologic conditions of the brain and cord are to be regarded as important factors. It occurs in such diseases as syphilis, scleroderma, and leprosy. The variety known as hysteric anesthesia is not uncommon.

Prognosis and **treatment** of this condition will manifestly depend on its nature and underlying cause.

CLASS VIII.—DISEASES OF THE APPENDAGES.

In the class of diseases of the appendages of the skin it is convenient and customary to include not only affections of the appendages proper,—the hair and nails,—but also those of the glandular structures as well. They can be considered under four heads: 1. Diseases of the nails. 2. Diseases of the hair and hair-follicles. 3. Diseases of the sebaceous glands. 4. Diseases of the sweat-glands.

1. DISEASES OF THE NAILS.

ONYCHAUXIS.[1]

Synonym.—Hypertrophy of the nail.

Definition.—An overgrowth of the nail in any direction.

Symptoms.—The affection may be congenital or acquired, usually the latter. One or all of the nails may share in the process, and the hypertrophy may take place in one or all directions, and this increase may be, and often is, accompanied by changes in shape, color, and direction of growth. It is not uncommon, too, to find conjointly atrophic changes in some nails or parts of one or more nails, along with the hypertrophic growth. Supernumerary nails, though scarcely to be considered an example of hypertrophy, are occasionally noted. In exceptional instances nail-formation has taken place on the stump ends of amputated fingers, etc.

Congenital hypertrophic changes are rare. Nicolle and Halipré[2] had under observation a patient with congenital hereditary malformation of the nails, with an associated atrophic condition of the hair. All the nails of both hands and feet were involved and presented hypertrophic growth, friability, and tendency to split and crack, and in some atrophic changes; there also existed disposition to paronychia. A diseased condition of the nails could be traced through six generations, involving 36 members out of 55. White[3] reports a somewhat similar interesting series, presenting both hypertrophic and atrophic changes, with subungual inflammation, and, in one nail, paronychial inflammation. In this instance, too, with an occasional break, several generations had been affected—in some congenital absence or malformation, in others changes taking place later. The thin, downy,

[1] Literature of diseases of the nails: Heller, *Die Krankheiten der Nägel*, Berlin, 1900 (a most admirable monograph, with many illustrations and a complete bibliography); Shoemaker, *Jour. Cutan. Dis.*, 1890, pp. 334, 388, 419, and 476 (with references and abstracts of interesting cases); Hutchinson, *Arch. of Surgery*, 1891, p. 237; D. W. Montgomery, "Diseases of the Nails," *Twentieth Century Practice*, vol. v. (Diseases of the Skin); Schwimmer, "Nagelkrankheiten," Eulenberg's *Real-Encyclopädie*, vol. xvi., 1898, p. 371; Pollitzer (inflammatory affections), Zeisler (trophic affections), and Grindon (parasitic diseases), Hardawav (treatment), *Jour. Cutan. Dis.*, 1901, pp. 503–527; Leisseur, *ibid.*, 1902, p. 502; C. J. White (clinical study of 485 cases), *Boston Med. and Surg. Jour.*, Nov. 13, 1902; Jackson, *Jour. Cutan. Dis.*, April, 1905, p. 153; Hyde, "The Egg-Shell Nail," *Jour. Cutan. Dis.*, 1906, p. 145 (illustrated).

[2] Nicolle and Halipré, *Annales*, 1895, p. 675 (with illustration).

[3] C. J. White, *Jour. Cutan. Dis.*, 1896, p. 220 (with illustrations).

sparse hair was also noted, as in Nicolle and Halipré's case. A congenital case of upward projecting, thickened, claw-like nails has been recorded by Sympson,[1] in which, too, there was an occasional disposition to soreness. In this instance there was no hereditary tendency.

Acquired onychauxis is, in its milder phases, not uncommon; its extreme type is somewhat rare. The overgrowth sometimes consists of simple thickening, which may be quite marked, or there may be a hypertrophic tendency toward lateral growth, which sometimes results in producing a periungual inflammation—paronychia. This latter may be slight and consists of trifling inflammatory redness, or there may be a good deal of swelling and purulent discharge. Many cases, however, are seen in which no tendency to underlying or surrounding inflammation is observed. In occasional instances the nail thickens enormously and becomes relatively compressed laterally, so that it consists of a thick, horny growth, somewhat flattened basal part, and more or less rounded on the upper side, and either projects upward toward the distal end, downward like talons (claw-nails), or may be slightly or markedly twisted, like a horn—*onychogryphosis*. The large toe-nail is one especially liable to malformed overgrowth. It is also seen on the fingers, and may involve one, several, or more nails; a typical example of the latter has been reported by Ricketts.[2] In some cases the hypertrophied nail is hard and horny, in others more or less friable and easily breakable in part or throughout. The luster is usually lost, the nail-substance becomes opaque, the surface often rough and irregular, and the color a dirty yellow, brown, or even blackish.

Unna[3] describes a persistent condition of the nails which I have occasionally seen, and which he terms "**scleronychia**," characterized by thickening, inelasticity, hardness, roughness, and by being opaque and of a yellowish-gray color, with disappearance of the lunula; there often appear longitudinal furrows, or the surface may be made up of protuberances and depressions; the anterior border is rough and irregular, but there is no tendency to chipping or breaking; it usually involves all the finger-nails simultaneously, and sometimes the toe-nails as well. Moderate degrees of onychauxis are not uncommon in tuberculosis, the nails being slightly or moderately thickened, broadened, with a tendency to curve over the finger-ends. Invasion of the nails by the vegetable fungi (onychomycosis) of ringworm and favus bring about, in some instances, increase in size, along with the granular and friable condition noted. The various inflammatory diseases, such as psoriasis, eczema, etc., involving the finger and nail regions, are often responsible for a slight degree of onychauxis. Very often, however, a thickening of the nail is more apparent than real, the seeming increase in thickness being due to underlying accumulation of epithelium or scaliness. A condition of this kind, independent of any cutaneous inflammatory disease, and involving most of the finger-nails, was observed by Hallopeau and

[1] Sympson, *Lancet*, 1888, i., p. 722 (with illustrations).
[2] Ricketts, *Cincinnati Lancet-Clinic*, i., 1887, p. 302.
[3] Unna, *Histopathology*, p. 1051.

Le Damany,[1] who designated it as a generalized parakeratosis of the nails, the thickness being due to imperfect keratinization of the lower layer. Sometimes the nails, especially in their distal half, are decidedly raised from the nail-bed by a growth of horny material beneath them.[2]

FIG. 204.—A chronic condition of onychia and paronychia with atrophic (and sometimes associated hypertrophic) nail changes, slight bulbous swelling of the finger-ends; occasionally seen as an idiopathic affection, but more usually associated with eczema of the fingers, and occurring most commonly in women, and more particularly in those who have their hands in water a great deal. Occasionally this condition is seen in association with or following impetigo contagiosa, or independently as a staphylococcic infection of the nail-beds and nails; sometimes doubtless of streptococcic origin.[3] It may be occasionally accompanied with arthritis of the distal joints.[4]

In onychauxis knocks and even the free use of the parts sometimes lead, owing to the unyielding characters of such nails, to tenderness or a variable degree of inflammation of the nail-bed (onychia) and the surrounding tissue (paronychia, whitlow). **Onychia** may exist, however, primarily and lead to atrophic or hypertrophic nail change; the matrix is often considerably inflamed, and is sometimes accompanied with a seropurulent undermining, but more frequently the nail-bed and periungual tissue both share in the inflammatory action. The onychial inflammation may be of a malignant character, with destruction of tissue and involvement of the lymphatics; the nail is cast off, and discloses a markedly inflamed, suppurative tissue. The affection rarely involves more than one or two nails.

Simple paronychia is often independent of hypertrophic nail

[1] Hallopeau and Le Damany, *Annales*, 1895, p. 538.

[2] Malcolm Morris, *Brit. Jour. Derm.*, 1901, p. 8, exhibited a striking case of this kind, a boy of twelve; and A. G. Wilson, *ibid.*, Jan., 1905, p. 13 (with illustrations and references), has reported cases of similar character as a hereditary affection—three generations.

[3] Adamson, *Brit. Jour. Derm.*, 1904, p. 165, describes a case following impetigo, with references.

[4] Hartzell, "Diseases of the Nails, Accompanied by Arthritis of the Distal Joints of the Fingers and Toes," *Univ. Med. Bull.*, Oct., 1904 (with two illustrations).

changes, and is commonly seen about a toe-nail, being simply the result of lateral pressure of a normal nail produced by tight-fitting shoes, or from a slight overgrowth laterally (ingrowing nail). It is likewise observed, however, about the finger-nails, and here the paronychial inflammation may be extremely sluggish, quite superficial, consisting of redness and slight, sometimes scarcely perceptible, swelling, and with little, if any, tendency to purulent formation or accumulation; in such cases several or more of the fingers are involved, and this type of the affection is usually observed in those who are obliged to have their hands in water a great deal. A mild degree of onychia may be present. It is also observed in association with eczema of the fingers. In other instances the inflammatory action is more intense, with considerable pain, swelling, and pus-accumulation. The nutrition of the nail often suffers.

Both in onychia and paronychia the involved area may exceptionally be small, consisting of only a part of the nail region, usually forward and laterally, and may so persist, unless treated, indefinitely, sometimes gradually, but scarcely perceptibly, from day to day, extending.

Etiology and Pathology.—The etiology of onychauxis has been already incidentally touched upon. The condition is more common in advancing years. Pressure and warmth, doubtless, are of etiologic importance in hypertrophy of the toe-nails. Lack of proper care is probably contributory. The various chronic inflammatory cutaneous diseases are sometimes responsible both for hypertrophic and atrophic changes.[1] Local irritation or injuries, constitutional disorders, gout, rheumatism, and diseases of the nervous system, or injuries involving the nerves, as in Bowlby's case,[2] may also be, to a varying degree, provocative of hypertrophy. Thickened and enlarged nails are sometimes seen in acromegaly, and may also be observed in some cases of leprosy, syringomyelia, and similar affections, although atrophic conditions are probably more common. An explanation of why, in some cases, the overgrowth should take one direction, in other cases another, and in still others a twisted, horn-like form and character is difficult to find; pressure is, it is true, a directing influence in some instances, but not in all.

Onychia is probably often idiopathic, due to slight traumatism or persistent or repeated irritation from a hypertrophied nail, which serves to give chance to a localized pyogenic infection. Syphilis and tuberculosis are also factors in some cases. The essential causes in

[1] C. J. White, *loc. cit.*, found 404 out of 485 cases to be due to or associated with 6 diseases: eczema (107), trauma or felon (72), paronychia (68), psoriasis (67), occupation dermatitis (62), and syphilis (28). Among comparatively new occupations which may have a damaging influence on the nails, as well as the skin, may be mentioned that having to do with the handling of formalin. Galewsky (*Münch. med. Wochenschr.*, vol. lii., No. 4, Jan. 24, 1905, calls particular attention to these effects, which sometimes, as regards the nails, may not follow till weeks or a few months after exposure. The condition is often accompanied with a burning and boring sensation in the ends of the fingers and the nails. A few instances of such occurrence among surgeons and nurses have come under my own observation.

[2] Bowlby, "Some Trophic Lesions Following Injuries of Nerves," *Illustrated News*, 1889, vol. iv., p. 25 (with colored plate showing marked hypertrophy and transverse furrows).

paronychia are pressure, and possibly a variable but mild local pyogenic infection.

Treatment.—The result of treatment, especially as to permanency, in these various conditions will depend upon a proper recognition of the essential causative element. A coexisting disease, cutaneous or systemic, will often be the clue which indicates the line of constitutional treatment. Cod-liver oil, tonics, and mercurials, with potassium iodid, may, therefore, be variously needed. Arsenic is valuable in some cases, but it must be persisted in to get a result. Unna found it curative, though slowly, in scleronychia. In some cases the cause is found to be purely an external one, and the treatment, therefore, wholly local. In others, again, the disease seems idiopathic, so far as our knowledge goes, and exists without any demonstrable reason, and in such cases the management is purely empirical, usually local and general. For ordinary onychauxis of one or two nails, local measures alone are called for. Proper care and cutting of the nails, the avoidance of pressure, either from tight-fitting shoes or gloves, are essential. Even slight injuries or traumatisms with manicuring implements should be guarded against. The excessive nail-growth should first be thoroughly softened by soaking in hot water, in which a little sodium bicarbonate or borax has been dissolved, and then carefully cut or filed away. Subsequent overgrowth can usually be kept under control by a fine file rather than with the scissors or knife. If there is a tendency to stony hardness and brittleness, a slight soaking nightly, or every second or third night, in hot water, with or without the addition of the alkali, is advisable, the part being subsequently enveloped over night with a plain ointment, such as cold cream or vaselin.

Onychia, if of mild character, can sometimes be managed by frequent washings of the parts with saturated solution of boric acid and continuous applications of a 25 to 50 per cent. ointment of ichthyol. Salicylic acid ointment, with equal parts of lanolin and cold cream, 3 to 10 per cent. strength, is also valuable. If the nail is hard and inelastic, occasional softening by soaking in a warm solution of sodium bicarbonate, 4 or 5 grains to the ounce, is advisable. Occasionally painting thoroughly both around and under the edges of the nail with a 2 to 5 per cent. solution of silver nitrate in sweet spirits of niter proves serviceable; if done carefully, the solution can be well insinuated ("flowed in") under the ends and sides of the nails, and thus come in contact with a great part of the diseased area. Not infrequently, however, removal of the nail may be necessary. If there is undermining suppuration, incisions are advisable, the subsequent applications being the same as above. In these latter cases, instead of ichthyol ointment, after washing with the boric acid solution the part can be enveloped in a thick layer of boric acid powder. The dressings should be changed two or three times daily. In obstinate cases, especially those of distinctly suppurative or pyogenic type, both as to onychia and paronychia, X-ray treatment can sometimes be used to advantage.

Paronychia is to be managed in the same manner as onychia as regards the applications. Unhealthy granulations, if present, can be

modified or destroyed by applications of silver nitrate—stick or solution. If due to apparent side pressure of the nail, the center of the nail should be filed somewhat thin, and a small tuft of cotton or lint, wet with boric acid solution, gently insinuated under the lateral nail-edges to remove the pressure. Occasional softening with bicarbonate of sodium solution is also of value. In most cases, those of mild character, these measures will, if faithfully carried out, usually suffice. If there is considerable lateral pressure, due to nail overgrowth, the side edges can be carefully trimmed off; or if the case is a severe one, avulsion of the nail may be necessary. In operations about the nails complete or relative anesthesia can be produced by cocain. In the milder types, those of sluggish and persistent character, observed about the finger-nails, the several applications referred to, along with general tonic treatment when needed, and keeping the hands out of water, will often bring the affair to an end. Arsenic is useful in some of these cases. Cooks, laundresses, etc., continuously obliged to have their fingers wet a considerable part of the time, should have recourse to rubber gloves while at such work.

ATROPHIA UNGUIUM.[1]

Synonyms.—Atrophy of the nails; Onychatrophia.

Symptoms.—In atrophy of the nails these appendages may show various conditions: they may be soft, thin, and brittle, splitting easily, opaque and lusterless, and sometimes with a worm-eaten appearance. But one of these characters may be present, or several or all may be exhibited. It may be congenital or acquired.

Congenital cases are rare, and in such instances it is not uncommon to find imperfect growth or absence of the hair, and also defective formation of the phalanges. In some of these instances the nails are entirely wanting, as in Eichhorst's[2] case, although the nail-bed and fold were well developed, hair and teeth normal, and no hereditary history. In the congenital hypertrophic cases[3] recorded by Nicolle and Halipré and C. J. White, especially in the series reported by the latter, in addition to hypertrophy, atrophic changes were also noted. Hutchinson[4] had under observation 2 cases—brother and sister—with congenital alopecia and born without nails; at the age of eight and seven respectively, the nails had grown, but the hair was still exceedingly defective.

Acquired nail atrophy in some of its forms is quite frequent. Thinning, with a marked tendency to splitting of the free borders, is often observed along with various chronic inflammatory and squamous skin diseases, and in consequence of some constitutional disturbance, or independently, and without assignable cause. Occasionally one or two nails are noted to be somewhat thin, especially at the free border, and with a persistent central crack or fissure extending

[1] For general literature references see onychauxis.

[2] Quoted by D. W. Montgomery, *Twentieth Century Practice*, vol. v. (Diseases of the Skin), p. 617.

[3] Referred to under hypertrophy of the nails.

[4] Hutchinson, *Arch. of Surgery*, 1891, p. 237.

upward. In fevers and other diseases there is not infrequently an intermittent transverse thinning, forming transverse furrows. Exacerbations of fevers and other severe constitutional maladies are sometimes, as pointed out by Vogel, Longstreth,[1] and others, often marked by transverse atrophy, either by furrows (**furrowed nails**) or white bands. Wilks[2] and Hartzell[3] have both observed transverse atrophic depressions, resulting from sea-sickness, marking the time of its occurrence. Zeisler[4] noted in his own case, following a fracture of the thigh, that the nails of the foot of the affected leg did not grow at all for six or eight weeks, and subsequent observation showed that a deep ridge marked the division between the new-growing part and the old nail, slowly moving forward, dividing it into two portions—a distal one which was thin and clearly atrophic, and a proximal strong and thick one. As Zeisler states, the line of demarcation indicated that the nails, from the moment of the fracture, had evidently ceased to grow for some weeks, the arrest of growth apparently resulting from the malnutrition and general atrophy of the leg due to its constriction by dressings and its horizontal position. The nails of the other foot exhibited normal growth. In fact, it is now well known, and the observation has been made by many physicians, that in depression in the general health, if at all pronounced, the nails thus show participation in the disturbance to nutrition. Longitudinal striæ of scarcely perceptible degree are apparently normal, but sometimes distinct atrophic longitudinal furrows are observed, but their import is not understood. Another form of atrophic thinning is that known as the **spoon-nail,** in which the sides, and to a less extent the free margin also, become everted, making a central spoon-like depression or scoop. Crocker[5] describes such cases, and refers to several observed by others. It is, however, rare, and usually occurring in wasting diseases, although in other instances without explainable reason.

Fig. 205.—Atrophy of the nails.

An atrophic friable or crumbly condition of the nails is most common, sometimes involving one, several, or all the finger-nails, and sometimes the toe-nails also, although this latter is not so frequent. It may begin in any portion—ordinarily, however, at the basal portion.

[1] Longstreth, "On the Changes in the Nails in Fever, etc.," *Trans. Coll. Physicians of Philadelphia*, 1877, p. 113.

[2] Wilks, *Trans. Pathol. Soc'y*, London, 1870, p. 409.

[3] Hartzell, discussion on Disease of the Nails, *Trans. Amer. Derm. Assoc. for 1901.*

[4] Zeisler, "Trophic Dermatoses following Fractures," *Jour. Cutan. Dis.*, 1898, p. 305.

[5] Crocker, *Diseases of the Skin*, second edit., p. 835.

The nails break and crack readily. Poor health, chronic digestive disturbances, diseases of the nervous system, possibly traumatisms, and invasion by the vegetable fungi of favus and ringworm are factors in different cases.

Shedding of the nails occurs sometimes after fevers and nervous diseases. It has been occasionally observed conjointly with alopecia areata and general defluvium capillorum. It is also seen in diabetes, scarlatiniform erythema, and dermatitis exfoliativa, but in other instances without apparent cause. In some cases it is hereditary and even congenital. Montgomery[1] reported a case of a man in whom there had been a constant shedding of the finger-nails since birth, with a history of a similar affection in some of his antecedents. Apparently in certain nervous disorders, diabetes, etc., the great toe-nail most frequently suffers in this respect.

Leukopathia unguium (achromia unguium; leukonychia; flores unguium; white spots; white nails; gift spots; etc.), in its mildest type, is not infrequent, the chalky whiteness being either, and most usually, in the form of spots or in the form of transverse bands, the nails otherwise being quite normal. They appear near the lunula, and gradually move forward with the growth of the nail. Unna,[2] Giovannini,[3] Longstreth,[4] Morison,[5] Stout,[6] Heidingsfeld,[7] and others report marked instances of the band type; Longstreth observed white transverse bands on his own finger-nails after an attack of relapsing fever; the several bands marking the time of the relapses. Giovannini's case followed typhoid fever, and Unna's case was apparently congenital, and associated with partial ringed hair. Morison's patient, a young woman, was in good health, the bands appearing without apparent cause; they had practically disappeared for a time one summer. In Stout's case, a mulatto, in addition to involvement of the finger-nails, a number of the toe-nails exhibited a similar, but slightly less marked, condition; and so far as could be ascertained was probably congenital. Lawrence,[8] quoted by Stout, observed an example of finger-nail bands in a healthy man aged forty-five, apparently congenital, and whose child, aged five, likewise presented a similar appearance, though not so distinctly marked.

FIG. 206.—Leukopathia unguium (the transverse band type); patient manicured herself about every seven to ten days.

[1] D. W. Montgomery, *Jour. Cutan. Dis.*, 1897, p. 252 (with some literature references).

[2] Unna, *International Atlas*, plate xix., 1891.

[3] Giovannini, *ibid.*

[4] Longstreth, *loc. cit.*

[5] Morison *Archiv*,, 1888, p. 3 (with colored plate).

[6] Stout, *Medical News*, Feb. 24, 1894 (with illustrations and some literature references).

[7] Heidingsfeld (7 cases), *Jour. Cutan. Dis.*, 1900, p. 490 (with illustrations and bibliography).

[8] Lawrence, *Australian Med. Jour.*, Oct. 15, 1893.

Etiology and Pathology.—The causes of these various atrophic and other described conditions have in part been incidentally referred to. So far as observation goes, the same etiologic factors responsible for the production of hypertrophy may also lead to atrophic changes. The various inflammatory, and especially scaly, skin diseases, more particularly when involving the hand and fingers, are often etiologic; constitutional diseases, nervous disorders, glossy skin (Weir Mitchell), traumatism, vegetable parasites, etc., are therefore variously found in the different cases; as already stated, heredity is a demonstrable factor in some of the cases. In many, however, it must be confessed, it is difficult to find an adequate explanation for the often persistent and rebellious atrophic manifestation. The immediate factor, exclusive of the parasites, is doubtless trophic in character, but that is about as far as one can get in many instances, and that is more of a cloak for lack of knowledge than a satisfying explanation. Nutritive disturbance of the matrix naturally is followed by imperfect nail-formation, and this part shares in all general enfeebling diseases, especially if profound and long continued.

The white spots and bands are in most cases either due to general disease, such as fevers, nervous disorders (Bielschowsky),[1] or to local traumatisms. In many instances, however, as in that of complete involvement in Joseph's[2] patient, there is no assignable cause. The striated form is rare, although Heidingsfeld's observation of 7 well-marked cases in a comparatively short time indicates that it is not so rare as it apparently seems from the scant literature of the subject. Six of his patients were young women who assiduously manicured their nails, and his studies would indicate that the cuticle knife is a possible cause of these white formations. He gives an illustration of 1 case, showing the nails one-half (new-growing part) normal after disuse of the cuticle knife for forty days. As yet there is some difference of opinion as to the origin or production of the white appearance. Most of the various writers named and other observers consider it due to infiltration of air, filling the minute interstitial spaces between the loosened-up epithelial strata. This is the accepted view. Heidingsfeld, who made careful microscopic examinations of the affected nails, was not able to corroborate this, and he considered that his researches justified the following: Leukoplakia unguium is the result of some pathologic change of structure of a plane of nail-cells, approximating a failure of the affected cells to undergo normal physiologic keratinization; the causes may be trauma, malnutrition, febrile diseases, neuroses, or any agency which disturbs the growth, development, or keratinization of matrix cells in their change to nail structure; an infiltration of air is not present, and there is no rational physiologic basis for such a theory.

Treatment.—The management, in a general way, of nail atrophy is essentially the same as described in treatment of hypertrophy of these structures. A recognition of the causative factor is important for success, but this often seems impossible. In the absence of under-

[1] Bielschowsky (following multiple neuritis), *Neurologisches Centralblatt*, 1890, p. 741.

[2] M. Joseph, "Leukonychia totalis," *Dermatolog. Zeitschr.*, 1894, p. 657.

lying factors which will give indication of constitutional treatment when necessary an empirical plan is the only resort. Arsenic, and also cod-liver oil, often have a favorable influence if persevered in. Small doses—2 or 3 grains (0.135–2.) three times daily—of sulphur in some instances appear to have an alterative effect. The local management consists in the protection of the parts from traumatism and from contact with disturbing materials, such as water, other liquids, and irritating substances. When necessary, disinfection with boric acid solution and applications of the milder salves, such as prescribed in eczema, and those named in the treatment of nail hypertrophy are useful. In cases of nail-splitting, enveloping the part with salve nightly, and wearing over the finger-end a piece of a glove-finger, and keeping the free end of the nail closely cut or filed, will, if persisted in, often get rid of the trouble.

In white nails the treatment is purely upon general indications, with a trial of arsenic in chronic cases, and, if necessary, the concealment of the blemishes by some indifferent stain; for this latter purpose occasionally touching the spots with a 5 or 10 per cent. resorcin lotion will bring about slight discoloration and render the blemish less conspicuous. The treatment of atrophic nails due to the ringworm and favus fungi will be elsewhere considered (see onychomycosis).

ONYCHOMYCOSIS.

Synonyms.—When due to ringworm fungus: Onychomycosis trichophytina; Tinea trichophytina unguium; Trichophytia unguium; Ringworm of the nails; *Fr.*, Onychomycose trichophytique; Trichophytie unguéale; *Ger.*, Onychomycosis tonsurans. When due to favus fungus: Onychomycosis favosa; Tinea favosa unguium; Favus of the nails; *Fr.*, Onychomycose favique; Favus des ongles; *Ger.*, Favus des Nagels.

Definition.—A crumbly, friable, grayish-colored, granular-looking condition of the nail, due to invasion by the ringworm or favus fungus.

Symptoms.—Rarely more than one or two nails are involved, and most commonly the finger-nails. The invasion is, as a rule, insidious, and the development of the malady extremely slow. Usually the lateral distal edge shows the first signs, the part becoming somewhat brittle and friable, grayish or grayish-yellow in color, and often somewhat crumbly. It may be thus limited, scarcely involving more than one-fourth of its substance, and remain so sometimes almost indefinitely. In other instances the greater part of this nail is sooner or later invaded, and it may encroach upon the posterior portion, although most commonly involving the anterior half or two-thirds. In exceptional cases, however, the whole nail is implicated. Beneath the distal portion there is often a variable accumulation of epithelial matter and débris, of a dirty-gray or grayish-yellow color, and in some instances sufficiently great in quantity to lift this part of the nail up from its bed in an irregular manner. In occasional cases the malady seems to be more or less restricted to this underlying part, the horny, or nail substance proper, showing, at first at least, but little involvement, although usually slightly changed in color. While

the free edge or the immediately adjacent side more commonly shows the earliest effects, not infrequently the first involvement is with the lateral or posterior portion, and this probably more frequently from the ringworm fungus than from the favus fungus. The changes produced by these fungi vary but little, although in the disease due to that of favus the evidences first presenting consist in some cases of yellowish, pin-point to pin-head, grain-like bodies. While the nail of any finger or fingers may be attacked, the thumb, the first, and the second are apparently most frequently involved, and this is especially so in favus. The toe-nails are relatively seldom invaded, but much more commonly by the ringworm fungus than with that of favus; Vidal, Zeisler, and a few others have noted instances in which the latter attacked these parts primarily. In exceptional instances the affected nails, more especially those of the toes, are

FIG. 207.—Onychomycosis due to the favus fungus—favus of the nails—in a Russian girl aged seventeen. One year's duration; favus of the scalp since twelve years old (courtesy of Dr. F. J. Leviseur).

increased in volume and become quite hard and horny, sometimes gryphotic and distorted (Geber, Censi).[1]

Etiology and Pathology.—The cause, as already stated, is either the ringworm or favus fungus; the latter much less frequently, and when etiologic, the malady is, as a rule, contracted from the eruptions elsewhere on the surface, usually from the disease on the scalp. This is true in great measure also with that due to the ringworm fungus, although it is not uncommon to find the nails the primary and sole part involved, having been contracted from others who may have the disease on the non-hairy or hairy parts. It may itself be the source of contagion to others.[2] Both the nail and subjacent derma are invaded by these fungi. According to Sabouraud, only the species of trichophyton fungus, known as ectothrix, is found in the nails, the other varieties of ringworm fungus not attacking these structures; but this statement is, however, too absolute, as Pernet found the endothrix in a case under his care. Either fungus can, as a rule, be readily demonstrated in the scrapings of the affected nail substance

[1] Geber, *Ziemssen's Handbook of Skin Diseases*, p. 487; Censi, "Clin. dermosif. d. R. Univ. di Roma," abs. in *Brit. Jour. Derm.*, 1898, p. 423, records 2 instances of onychomycosis trichophytina of the toe-nails, in which the nail was thickened, curved, and nodular, shaped like a bird's claw or a ram's horn.

[2] Fournier, *Jour. mal. cutan.*, 1889, p. 3, has recorded an instance of contraction of ringworm by several members of a family from a servant who had onychomycosis.

by placing on a slide in some liquor potassæ, allowing it to soften for several minutes to an hour or more, and then examining with a power of 400 to 500 diameters. Exceptionally, as noted by Hutchinson and Crocker, the parasite is not easily found, the scrapings requiring sometimes a soaking of ten to twenty hours in the liquor potassæ.

Diagnosis.—With the presence of either ringworm or favus patches elsewhere upon the surface the nail involvement would permit usually of a ready diagnosis. A similar, or closely similar, condition of the nails is, however, seen in connection with psoriasis, eczema, and other chronic inflammatory dermatoses; and, moreover, not infrequently occurs independently, sometimes as the result of impaired general nutrition or trophic disorders, and likewise in those of gouty or rheumatic tendency. The diagnosis, therefore, must often be based upon microscopic examination of the scrapings. It is true, however, that in the parasitic disease rarely more than one or several nails are affected, while in association with or as a result of the maladies mentioned, in most instances, many or all are apt to be more or less involved.

Prognosis and Treatment.—The malady is extremely obstinate, although finally responsive to persistent treatment. If let alone, it continues indefinitely, showing no tendency to spontaneous cure.[1] It usually remains limited, however, to one or two nails; more than several are rarely involved.

In the treatment the parts are to be repeatedly closely pared, pumiced, or scraped. If very hard and brittle, and often also with advantage in other instances, an occasional soaking in an alkaline solution will serve to soften; or liquor potassæ or a stronger solution of caustic potash can be painted on several times. Another method (Pellizzari) of softening and removing the involved nail tissue is by enveloping it with sapo viridis, covering it with a rubber finger-stall, and allowing it to remain for one to several days, during which time it can be renewed. These mildly caustic applications require some care that the surrounding tissue is not unnecessarily acted upon. Along with the removal of the diseased nail substance from time to time in the manner described parasiticide applications are to be made. One of the best plans is to dip the affected finger-ends in a solution of mercuric chlorid, from 1 to 3 grains (0.033–0.2) to the ounce (32.), for five to ten minutes twice daily, allowing it to dry in, and then enveloping the parts with an ointment of white precipitate or calomel, a dram (4.) to the ounce (32.); or the finger-ends may be soaked in a 15 to 20 per cent. solution of sodium hyposulphite, subsequently enveloping them with an ointment of precipitated sulphur, 1 dram (4.) to the ounce (32.). In cases in which the parts are not sensitive or easily irritated enveloping the nail over night in an application consisting of the following may be advised:

℞.	Sulphur præcip.,	ʒij (8.);
	Ac. salicylici,	gr. xxx (2.);
	Saponis viridis,	q. s. ad ℥j (32.).

[1] Crocker, *Brit. Jour. Derm.*, 1899, p. 331, mentions an instance in which one nail had apparently been affected by the ringworm fungus for forty to fifty years; Pernet, *ibid.*, 1902, p. 16, one case in which it had existed for twenty to thirty years.

Frequent applications of a saturated solution of silver nitrate in sweet spirits of niter are of service, but the blackening produced is a disadvantage. Iodin applications, which also prove useful, have the same objection. Sabouraud[1] commends a lotion composed of 15 grains (1.) iodin, 30 grains (2.) potassium iodid, and a quart (1000.) of water; this is applied on absorbent cotton, and kept covered with a rubber finger-stall, and renewed frequently. It is, as all other plans, slow, but the fungus development is completely inhibited, the new-growing nail substance remaining unaffected, and gradually replacing the morbid structure. Crocker has had the most success with Harrison's plan of treating ringworm of the scalp (*q. v.*). In persistently obstinate cases complete avulsion of the affected nail, followed by the use of the above remedies, may be required.

2. DISEASES OF THE HAIR AND THE HAIR-FOLLICLES.

HYPERTRICHOSIS.[2]

Synonyms.—Hypertrophy of the hair; Superfluous hair; Hairiness; Hirsuties; Hypertrophia pilorum; Hypertrichiasis; Polytrichia; Trichauxis; *Fr.*, Poils accidentels.

Definition.—Excessive or abnormal growth of hair, either as regards region, degree, age, or sex.

Symptoms.—Excessive hair growth may be congenital or acquired, and of limited (hypertrichosis partialis) or general (hypertrichosis universalis) distribution.

Congenital hypertrichosis may be either partial or general, although both are rare, the former less so than the latter. In partial cases the hairiness is usually a part of a pigmented nævus—in fact, such are, as a rule, examples of hairy nævi. The skin is commonly found pigmented, and with a variable amount of connective-tissue growth (see nævus pigmentosus). In this variety of congenital cases the lower part of the trunk, especially over the sacrum, is the most frequent localization.

In universal hypertrichosis the growth on those regions where the hair is normally more vigorous is the most pronounced. The situations on which lanugo hair never grows, as, for instance, the palms, soles, etc., remain free, even in instances of markedly excessive general hairiness. Usually at birth there is noted a perceptible down, with considerable hairy growth on the normal localities. In others the downy hairs are noticed only after some months or a few years. These gradually increase in size, become more or less uniformly pigmented, and almost invariably of the same color as the scalp hair. These cases are rare, but quite a number have been recorded, a few of which have been of the female sex. The body

[1] Sabouraud, *Annales*, 1896, p. 33 (describes a case due to ringworm fungus, involving all the nails of the right hand).

[2] Important literature: Jackson, *Diseases of the Hair and Scalp*, New York, 1890; Beigel, *The Human Hair*, London, 1869; Leonard, *The Hair*, Detroit, 1881.

hairiness is often variable as to degree, but always much more pronounced than normally, and ordinarily the growth is conspicuous. The face shows the greatest development of the blemish, being more or less completely covered. This general hairiness is not only usually congenital, but there is, as a rule, a hereditary history. Examples of this condition—the so-called homines pilosi, or hairy people—have been reported by various observers.[1] It is commonly noted that these general congenital hairy individuals show defective development of teeth, as is also observed in cases of congenital absence of hair. In Duhring's patient, however, the teeth were all present and in good condition.

Acquired hypertrichosis, compared to the above-described congenital cases, is a mild affair, but often most harrassing to its subjects, if of the female sex, and these are the only subjects who come professionally under our notice. Exceptionally, however, instances of general acquired hirsuties have been observed.[2] A variable degree of hairiness often develops in certain families as adult and advanced age is reached, but more especially in the male line, although it is not uncommon to see moderate development on some women, not necessarily the face, but on the usual downy sites of the covered parts, especially the arms and legs. These cases, however, rarely seek advice. The examples of acquired hypertrichosis soliciting professional aid are those observed in young and middle-aged women, who find the down of the chin, lip, and sometimes the sides of the face growing stronger, becoming pigmented, and thus constituting a positive blemish. Various degrees and varieties are observed, from that of simple exaggerated down to a conspicuous growth. In others, more frequently in those of advancing years, there may be simply a small number of large scattered hairs or one or two tufts. The growth of these latter is somewhat akin to the growth of hairs usually observed in old men about the nasal, aural, and brow regions. In exceptional instances (transitory hypertrichosis) acquired hair growth on a woman's face has been noted to disappear spontaneously; this has been more especially observed to occur after pregnancy or

[1] Beigel (*loc. cit.*) refers to several instances of recorded cases (with several illustrations), of which the most striking are those of Julia Pastrana and Shwe-Maon (Crawford's case). Julia Pastrana, a Spanish dancer, not only had a fine beard, but the whole body was hairy, and a daughter displayed the same anomaly. Shwe-Maon, one of his daughters, and one of her sons, all displayed universal hairiness, the body hairs of his daughter being, however, chiefly of a downy character. The Russian dog-faced man, Andrian Jeftichjew, whose picture is now well known, and his son, Fedor, both of whom were on exhibition in this country and elsewhere, are additional examples. Duhring (*Arch. Derm.*, 1877, p. 193, with illustration) had under observation a "bearded woman," aged twenty-three, in whom there was full growth, such as seen in men, and also more or less general hypertrichosis, with, however, some parts entirely free. There was no hereditary history, nor did either of her two children up to the time of their death—at the ages of two and four—display this tendency.

[2] Erasmus Wilson (Lectures on Dermatology, London, 1878) refers to an unmarried woman, aged thirty-three, in whom general hairiness began to develop at puberty, and covered the surface, excepting a bald plaque on the vertex of scalp; the woman was a sufferer from amenorrhea. Zarubin (*Jour. Cutan. Dis.*, 1897, p. 74) records a somewhat similar case, in a married woman, appearing at the age of twenty-three, after a miscarriage with her second child and consequent pain (amenorrhea) in the sexual sphere, the menses not appearing again for eleven years; the general hair growth was followed by scalp baldness.

after the reestablishment of normal menstrual flow, following prolonged amenorrhea.[1] The hair growth occasionally seen following local injuries, such as fractures, nerve traumatism, and the like, sometimes falls out subsequently.

The tendency to excessive growth of the beard in men, and of the scalp hair to extreme luxuriance and length in some women, is a matter of occasional observation. This by no means, especially in women, indicates an excessive production on the other natural situations. In rare instances the hairy development on parts other than the scalp takes place early—before puberty, its normal time for active growth—and has resulted in whiskered boys, associated with early development of the pubic hairs, or female children with precociously hairy pudenda.[2]

In connection with hypertrichosis, the anomaly exceptionally observed, of two hairs (Giovannini)[3] and even three hairs (Flemming)[4] emerging from a single follicle, usually on the bearded parts, may be referred to. One is commonly abortive, although they may be equally developed and thick. Giovannini is inclined to believe, from an instance observed by him, that this may give rise to a sycosiform inflammation. I have myself observed in a few cases in isolated follicles the growth of two hairs, but never with coincident inflammation. Doubtless in some instances these double and triple hairs are simply examples of hair-splitting.

The hair has certain normal directions in which it grows, but exceptionally this may be deviated from. The most frequent example of this is with the eyelashes, which may tend inward against the eyeball (**trichiasis**) and give rise to considerable irritation, and sometimes opacity of the cornea, etc. In rare instances are observed in this region two rows of lashes (**distichiasis**), a supplementary inner row curved backward on to the eye, which may extend along the whole lid, but usually only along the outer third of the upper lid. Both trichiasis and distichiasis may result from chronic inflammation of the lid-borders; the latter is, however, sometimes congenital or develops about the age of puberty (de Schweinitz).

Etiology.—Some of the possible causative factors have been already incidentally alluded to. The condition may be congenital in a few instances, and in many a hereditary factor is recognizable. Certain races are more especially prone to strong, coarse, and more

[1] Gottheil has cited an instance, which was also observed by Jackson (Jackson, Morrow's *System*, vol. iii. (Dermatology), p. 841), in which a woman, after having borne several children, was the subject of a persistent amenorrhea, during which time a growth of coarse hair grew on the face; several years later she became pregnant, and, after the birth of the child, the remaining hairs—some had been removed by electrolysis—spontaneously disappeared.

[2] Lesser (*Correspondenzbl. f. Schweitzer Aerzte*, xxvi., p. 355; *Jour. Cutan. Dis.*, 1897, p. 75) cites an instance of a girl of six in whom extensive hair growth began at the age of four, the child developing precociously and menstruating when three years old. In addition to the natural situations there was, however, also growth on face and general body surface (an illustration of this case in Lesser's *Hautkrankheiten*, tenth edit., 1900, p. 220). Beigel (*Virchow's Archiv*, vol. xliv., 1868, p. 418) also recorded a six-year-old girl with mature pudendal development; and Chowne (*Lancet*, 1852, i., p. 421) a boy aged eight, with pubic hairs and a bearded face.

[3] Giovannini, *Archiv*, 1893, vol. xxv., p. 187 (with cuts).

[4] Flemming, *Monatshefte*, 1883, p. 163.

than the usual quantity of lanugo growth, with a tendency to become stronger and coarser. Those of dark complexion are more susceptible. It is true, too, that masculine women are frequently the subjects of this blemish, but such individuals are not very sensitive concerning it and rarely seek advice, so that, according to my experience, the large majority of women coming under actual notice for treatment are in no wise less womanly than those free from facial hirsuties. In fact, I should say that most of my patients have been exceedingly sensitive, refined, frail, and womanly. In the larger number of cases the growth develops most actively at the climacteric period. It is a common observation that the growth is frequently associated with diseases, functional or organic, of the utero-ovarian system. On the other hand, in many instances, there is no apparent cause. It is known that local irritation, as the warmth of fracture dressings, sinapisms, stimulating embrocations, and the like, are quite capable in some subjects of stimulating hairy development. There is a strong belief among women that greasy applications to the face favor hirsutial growth, especially the petroleum ointments, but unless there is an underlying tendency I cannot, from my own observations, think this to be true. Friction and petroleum ointment conjointly might in such subjects have a stimulating influence; but grease of any kind, even with active friction or massage, is often enough, as we unfortunately know, powerless to stay falling hair or to stimulate new growth. The nervous system is probably a factor in some instances; it is not infrequent in insane women, although often in association with menstrual irregularity or abeyance.

Treatment.—There is no treatment for general hypertrichosis. For cases of moderate acquired facial hair growth occurring on women's faces, and for which relief is often urgently sought, full and permanent removal can be effected by electrolysis, a dermatologic procedure the profession owes to Hardaway, who was led to employ it by Michel, who had been successfully using it for the removal of ingrowing eyelashes. Since then Fox, Jackson, Brocq, and others have gone over the details and reported results. The operation is permanent in its effects, but as each hair must be treated individually, it is only practicable in cases in which the hairs are coarse and not too numerous. Owing to the delicate character of the operation, it is natural that a proportion of failures—failure to strike the hair-papilla—should occur; and this experience proves. With a good operator, however, there should not be more than 2 or 3 papillæ missed out of 10. The position of the papilla is usually indicated by the direction of the hair-shaft, but this is not always so, especially under the chin; the proportion of failures in the latter region is therefore greatest. The surface can be gone over a second time, however, and complete removal thus attained. I have always declined to operate on lanugo growth, and have always discouraged the treatment in extensive cases, as in the former the hair is not conspicuously unsightly, and it is possible, just at such time, the operation, by producing irritation, might stimulate the hair; and in the latter the method seems interminable. From about 35 to 50 hairs can be comfortably operated on in an hour. Even in extensive growth, however,

if the subject have persistence, patience, and a full purse, a final favorable result can be brought about. The procedure is somewhat painful, variable as to degree in different individuals, but it is never an obstacle, for the patient is extremely rare who cannot sit and bear the slight pain of the operation much longer than the physician can comfortably operate. The upper lip, especially under the nose, is the most sensitive part. Anodyne applications, usually without effect, need not, therefore, ever be used. A good light is required, for at the best the procedure is trying on the operator's eyes. The patient can be placed on an ordinary chair with a head-rest, or a reclining chair can be used—it is most convenient for the physician, who sits at the side facing the patient, when the part to be depilated is on a level with his eyes.

The object of the electrolytic operation is to destroy the papilla and lower part of the follicle. For this purpose are needed a galvanic battery of 10 to 30 cells, a needle-holder, an extremely fine needle, the ordinary cords, an electrode, a rheostat, and a milliampèremeter. The strength of current required is from $\frac{1}{4}$ to $1\frac{1}{2}$ milliampères, probably $\frac{3}{4}$ of a milliampère being the average. If no meter is used, a current of from 2 to 6 freshly charged cells of a zinc-carbon battery with electropoion fluid, or from 4 to 10 Leclanché cells, or from the same number of the ordinary commercial dry cells, or from 8 to 16 silver chlorid cells will give the required strength; it is better, however, to have a larger number of cells, so that the requisite current can be obtained for some months, as the cells gradually weaken. Moreover, the battery is then available for electrolytic and other purposes which require stronger currents. The needle may be either one of iridoplatinum, suggested by Hardaway, and which I prefer, or a fine steel one. Fox and Jackson both use a jeweler's steel broach. The iridoplatinum needle can be bent in any direction, a convenience when operating in certain regions. The needle-holder should not have an interrupter, although, strange to say, more of these are sold, the general practitioner being the purchaser. The expert buys the one without, as the current should be broken at the positive electrode, and not at the needle—the abrupt breakage by the latter giving rise to flashes, and often giddiness. The holder, with the needle, is to *be attached to the negative pole.* If attached to the positive pole, the needle glues itself slightly in the follicle, and if a steel needle is used, its oxidation, which takes place at this pole, results in a deposit of iron rust in the skin.

The region to be operated upon should be wiped off with a pledget of cotton wet with alcohol, as a mild preliminary antiseptic measure which, I believe, lessens the chance of pustulation. For the operation good light is required; a magnifying lens or a pair of slightly magnifying spectacles will be a help. The needle is introduced into the hair-follicle alongside of the hair, down to the papilla; if the follicle is entered, the needle slips in very readily without puncturing the skin or bringing blood. The depth to which the needle is introduced depends upon the individual case and the individual hair, varying from $\frac{1}{16}$ to $\frac{1}{4}$ of an inch; the sense of resistance met with will usually indicate the proper depth. The circuit is then made by the patient touching the positive electrode, which is covered with wet sponge or wet cotton, with the fingers or palm, the other hand holding

this electrode by an insulated handle; the current is allowed to act for from ten to thirty seconds, during which time the needle is to be moved a trifle, so as to bring it in contact with the sides of the lower part of the follicle. Slight blanching and frothing or bubbling at the point of entrance are noticed while the current is passing. When sufficient action is thought to have taken place, usually in from ten to thirty seconds, the patient removes the hand from the positive pole and the needle is withdrawn. If the papilla has been destroyed, the hair will readily come out with but little, if any, traction. In many instances a small, hive-like spot marks the site of each operation, subsiding in the course of some minutes or hours; in other instances the reaction is extremely slight. If the action has been too severe or the current too long continued, and even under the most favorable conditions in some skins, there is considerable reaction at each of the points of operation, and pustulation and crusting result in one or two days, with sometimes slight or insignificant scarring. As a rule, however, if the operator is practised, careful, and skilful, scarring, in the popular sense of the word, should not take place. There will be less danger of this if the hairs operated upon at the one sitting are not too close together—picking them out here and there, and avoiding closely contiguous hairs. In fact, operating at the one sitting in adjoining follicles is almost sure to produce fusing zones of redness or inflammation, and sometimes positive tissue destruction and scarring. Another precaution is not to reenter the same follicle at the same sitting—a temptation when the first introduction has not been successful. On the upper lip the weakest possible current should ordinarily be used, both on account of the extreme sensitiveness of the part and the greater tendency to tissue destruction. In 2 instances freckle-like pigment spots marked the sites of operation on the upper lip—one case of my own and in one operated on by another physician. Jackson also refers to this possibility—an extremely rare one, however; several weeks or months elapsed before their entire disappearance. The weaker the current, the less chance of too much action, although the needle must be kept in the follicle somewhat longer. After the sitting the part should again be wiped off with alcohol. Two or three times during the next ten or twelve hours the patient is to apply hot water for several minutes; this will reduce any reddening or inflammatory tendency. If there is much reaction, an occasional anointing with cold cream containing 2 or 3 per cent. of boric acid will be of service. The frequency of the sittings will depend upon the amount of surface involved—if limited, a week is allowed to go by before operating again; this will have given ample time for all irritation to subside; if the region is large, sittings can follow closely one after another, a new part or scattered hairs being operated on each time.

Another method which has recently been experimentally tried is that by the X-ray. It has been known for some time that its use was occasionally followed by falling of the hair. Schiff and Freund,[1] Wood,[2] Pusey,[3] and a few others have utilized this fact in treating

[1] Schiff and Freund, *Wiener med. Wochenschr.*, 1898, pp. 1058, 1118, and 1178; and (Freund) *Wiener klin. Wochenschr.*, 1899, p. 966.

[2] Wood, *Lancet*, 1900, i., p. 231. [3] Pusey, *Trans. Amer. Derm. Assoc. for 1901.*

hypertrichosis, and with alleged favorable effects, but numerous exposures are required, and the results can scarcely be said to have been permanent, and it is not without some risk of troublesome dermatitis and of subsequent atrophic changes in the skin. Even its former warmest supporters now recognize its shortcomings. It should be limited, if used at all, to cases not otherwise manageable, and the exposure be at first cautiously given; from 30 to 60, or more, exposures are required. After some months the hair usually regrows, but, as a rule, in less number.

Although electrolysis constitutes the only method of treatment that will yield permanent results, there are several other expedients adopted in such cases which, although only temporary in their effect, can, by repetition, keep the face free from this blemish. These are extraction of the hairs with the tweezers, cutting or shaving, and the use of depilatories. Another method not so commonly used, but which I have found occasionally employed, is that by a smooth piece of pumice-stone; by gently rubbing this over the part every few days the hairs are kept ground off even with the skin. It is popularly believed, and it is probably true, that all these methods tend to make the hair stronger and to promote the growth of the downy hairs. It is even possible that the operation of electrolysis may have this influence on the remaining lanugo hairs. Still, when the latter operation is not available, owing to the necessary expense, time outlay, or other reason, some other expedient is resorted to. For this purpose depilatories are most frequently employed, and, judging by the extensive advertisement of secret preparations of this character, their use must be quite general. One of the best depilatories (Duhring) consists of from 2 to 4 drams (8.–16.) of barium sulphid, with enough zinc oxid and starch to make an ounce (32.). The sulphid should be well and usually freshly made, and kept tightly corked, otherwise its action is unsatisfactory. At the time of application sufficient water is added to make a paste, which is thickly spread over the part, and allowed to remain for a short time, rarely more than a minute or two, and then scraped or washed off, and a little soothing ointment or a dusting-powder applied. A variable amount of redness follows; the object is to allow the paste to remain on only a sufficient length of time to destroy the hair, so as to limit the resulting irritation. Ordinarily a feeling of warmth or slight burning is an indication that the paste has been on long enough. The application is repeated as soon as the hair has reappeared—about every one or two weeks. Böttger's paste, as advocated by Kaposi and Brayton,[1] made by passing hydrogen sulphid into hydrated lime, is also, when well made, a good preparation; it is to be made into a paste at the time of application by the addition of water. Brayton[2] also commends highly a similar one (dry calcium sulphohydrate), made by heating together at a high temperature plaster-of-Paris and granulated wood-charcoal, although the product, like most others in my own experience, seems to vary in efficiency. It is also to be made into a paste at time of application.

In cases in which these various expedients do not seem advisable or eligible, the bleaching properties of hydrogen peroxid, especially

[1] Brayton, *Indiana Med. Jour.*, June and Aug., 1896.
[2] Brayton, *Jour. Amer. Med. Assoc.*, Apl. 16, 1898.

in patients with a dark growth, can be made use of, as suggested by Bulkley[1] at first, in order to avoid the possibility of irritation, diluting with an equal part of water, and gradually increasing. It is to be thoroughly and frequently applied. Bulkley states that it also has the advantage, if constantly employed, of retarding the growth. I can testify as to its value as a bleacher, and thus occasionally serviceable as a palliative, but I have seen no evidence of its retarding influence on the hair growth.

Plica polonica is a term formerly much in use, applied to a condition of the scalp hair, especially observed in Poles, in which entangling and matting were the conspicuous characters. Much was formerly written upon the subject, several varieties and stages were described, and it was even deemed worthy of atlas illustration, but all its interest faded away when it was demonstrated (Hebra), and finally accepted after much controversial discussions, that it was not in itself a disease, but simply the result of lack of cleanliness and care, associated with pediculi, eczematous oozing, and extraneous dirt. Under such circumstances it can be understood how inextricable matting could readily ensue.

Plica neuropathica is an idiopathic matted or felted condition of the scalp hair of which but several cases have been recorded—1 by Le Page,[2] 1 by Pestonji,[3] De Amicis,[4] 1 by myself,[5] and possibly a few others. In the first 2—young women—the matting developed shortly after washing the hair in warm water, and in 1 (Le Page's) was confined to the hair of the right side, and in the other to the sides of the occipital region. These cases were, therefore, of sudden development, and though suspicious as to possibility of artificial production, this element seems to have been carefully eliminated. In De Amicis's case the patient having lost the hair of the scalp in consequence of typhoid fever, the regrowth on the anterior portion was of a bushy, tangled nature, wholly different from the other hair posteriorly. This patient had distinct nervous symptoms as well, leading De Amicis to believe that the condition was a trophoneurotic one. In my own case the felting was limited to a dollar-sized area posteriorly just below the occipital protuberance, and had been a growth of years, forming a rounded, matted, felted lock four feet long. The patient was perfectly cleanly, and the scalp free from dirt or vermin. The other hair exhibited no tendency to similar felting. It is difficult to find an explanation of these cases. In the discussion on my own case White[6] suggested that it might be due to some peculiar arrangement of the cortical cells, similar to those of the hair of animals in which natural felting occurs. Unfortunately, my patient was thoroughly imbued with the superstitious sentiment always associated with these formations, and I was there-

[1] Bulkley, *Jour. Amer. Med. Assoc.*, 1899, ii., p. 1598.
[2] Le Page, *Brit. Med. Jour.*, 1884, i., p. 160.
[3] Pestonji, *Lancet*, 1885, ii., p. 431.
[4] De Amicis, *Trans. Internat. Derm. Cong.*, Vienna, 1892, p. 422; abs. in *Annales*, 1892, p. 1182.
[5] Stelwagon, *Amer. Jour. Med. Sci.*, Dec., 1892.
[6] J. C. White, *Trans. Amer. Derm. Assoc. for 1892.*

fore not able to cut off any for investigation. That exceptionally a curly or other property can be given to one or two locks or a part of the scalp hair without necessarily to the whole region uniformly is also shown by Flesch's[1] case, a boy of six years, in whom were

FIG. 208.—Plica neuropathica (case referred to in the text).

two locks, of about an inch diameter, distinctly curly and light yellow in color, the other hair being smooth, straight, and brown. No other member of the family presented this peculiarity, nor was there any hereditary history of such.

ATROPHIA PILORUM PROPRIA.[2]

Synonym.—Atrophy of the hair.

Atrophy of the hair is a general term employed to cover various varieties of hair changes, of an atrophic or destructive character, which may be due to the invasion of parasites in the hair or about the hair-roots, or which may result from some known or unknown

[1] Flesch, *Verhandl. Berlin. Anthropolog. Gesellsch.*, April, 1886; abs. in *Monatshefte*, 1886, p. 522.

[2] I am indebted to Jackson's book on *Diseases of the Hair and Scalp*, New York, 1890 (with a complete bibliography), for suggestions, etc., in the preparation of the articles on the various atrophic diseases of the hair. The reader is referred to that work for bibliographic references. The small book by Beigel, *The Human Hair*, also contains much interesting matter; also G. Behrend's paper ("Ueber Knotenbildung am Haarschaft," *Virchow's Archiv*, vol. ciii., 1885, p. 437, reviews several atrophic affections and gives numerous references and some illustrations).

general systemic conditions from which the hair, as well as other tissues or organs, may suffer partial nutritive starvation, and thus become weakened and fragile. It is not improbable, however, that even those considered trophoneurotic in origin may be so only so far as it weakens the hair and makes it an easy prey and lodging-place for microbic elements. It is usual to divide the cases into those idiopathic in origin and those symptomatic, but it is purely an arbitrary division, and practically signifies that those belonging to the former class are without recognizable cause, while the latter class includes those apparently due to constitutional disease, such as phthisis, fevers, syphilis, diabetes, and the like, and to such local affections as favus, ringworm, seborrhea, etc. The various conditions found are commonly known as fragilitas crinium, trichorrhexis nodosa, monilethrix, piedra, tinea nodosa, Beigel's disease (chignon fungus), and lepothrix. It is the first three, however, which are usually included under the above heading, the others being characterized by concretions upon the hair-shafts, although some resulting atrophy is generally noticeable.

FRAGILITAS CRINIUM.

As the name signifies, this is a condition of the hair characterized by extreme fragility, which may manifest itself in several ways: the hair may split up into a few or many filaments, either at or toward their free end, or near and sometimes extending into the root, or it may be simply brittle and break off from brushing, combing, or handling. It may be extremely slight or quite pronounced. The scalp hair of women and long beard in men are its usual sites. Duhring[1] described a peculiar case involving the beard, characterized by marked atrophy of the hair-bulb and splitting of the hair substance, the fission taking place within the follicle and producing irritation of the skin and follicular papules. Parker[2] and Hyde[3] each refer to a somewhat similar instance. The most common part, however, for the fission to take place is at the hair-ends, and it may extend some distance up the shaft. In other cases, exceptionally, however, it occurs near the middle of the shaft. The condition may confine itself to scattered hairs, or chiefly to the hairs of a limited region; on the other hand, almost all the hairs may show more or less involvement. The hair is usually noted to be dry and sometimes is of slightly irregular contour.

Exclusive of the cases (symptomatic fragilitas crinium) due to ringworm and favus, in which the short and broken-off hairs are affected, nothing is really known as to the cause of the affection. The patients seem in good health. Kaposi's idea that it is owing to the distance the end is from the source of nutrition scarcely holds when we know that sometimes the process is not limited to the longest hairs, and, moreover, occasionally the same condition takes place in the middle of the shaft, and indeed at the root-end—at the very point of nutritive supply. Gamberini thinks it due to lack of care and excessive length, but these are not always factors. Examinations of the bulb show

[1] Duhring, "Undescribed Form of Atrophy of the Hair of the Beard," *Amer. Jour. Med. Sci.*, July, 1878 (with illustration).

[2] Rushton Parker, *Brit. Med. Jour.*, 1888, ii., p. 1335 (with illustration).

[3] Hyde and Montgomery, *Diseases of the Skin*, fifth edit., p. 548.

some to be normal and some atrophied—the latter was especially noted in Duhring's case, and the medulla was nowhere normal, and the cortical substance in the narrowed portion brittle and dry.

Treatment.—As in all diseases of the skin, the general health should receive attention if there are any indications pointing toward the necessity for such. When involving the shaft or ends the hairs should be clipped off just below the cleft part. The scalp and hair should be kept clean; if shampooing is frequently necessary, a little vaselin should be rubbed into the scalp afterward. If there is a marked disposition to dryness and splitting up, a little oiliness, imparted by a trifling amount of liquid vaselin to the hair, by oiling the comb, and then wiping off the excess, will sometimes lessen the tendency. If occurring on the bearded part at the hair-ends, these should be kept well clipped; and if on the root-ends, constant shaving should be practised for a time.

TRICHORRHEXIS NODOSA.

This name, proposed by Kaposi (1881), is employed for a peculiar nodose condition of the hair, previously described[1] by Wilson (trichoclasia, clastothrix), and more fully by Beigel (1855) and Wilks (1857), Beigel[2] usually receiving the credit for the first clear description. Devergie[3] (tricoptilose) published the first French case. A number of cases have been since reported—in this country by Sherwell, Bulkley, and others. Its chief characteristic is that breakage or fracture of the hair, more or less common to all atrophic hair diseases, always takes place through the nodes. The region commonly the site of the affection is the mustache, although the bearded parts, scalp, and exceptionally other regions may show it. A single hair-shaft may be the seat of several nodes. There are no symptoms except the disfigurement, and this is perceptible only upon close examination. The patient usually becomes aware of it first by feeling, in handling the part, knotty swellings along the hair; in other cases the first discovery is that the hairs break readily and that there are nodular formations on the shafts which suggest nits. On inspection it is then noticed that the hair has apparently burst at the nodular swelling, the fibrillæ being seemingly pushed asunder; it has an appearance as if two small brushes had been jammed together end to end. If the hair has completely broken off, which, when it occurs, is through the middle part of the swelling, there is left a free end of a brush- or broom-like character. While the fracture is usually transverse through the node, Jackson states that sometimes, if there is an excessive amount of medulla present, it is longitudinal. The swellings are whitish or grayish, and, when broken and numerous, the hair at a little distance looks as if it had been incompletely singed. The shafts being markedly brittle, are readily broken by combing or handling. In some hairs the splinter-

[1] Colcott Fox, *Lancet*, 1878, vol ii., p. 803, gives a review of the earlier literature; Heidingsfeld, *Jour. Cutan. Dis.*, June, 1905, p. 246, gives a résumé of the literature, with bibliography.

[2] Beigel, "Ueber Auftreibung und Bersten der Haare," *Sitzungsbericht der Mathem. Naturw. Klasse der Wien*, 1855, vol. xvii., p. 612.

[3] Devergie, *Annales*, 1870–71, p. 5 (case communicated to him by Lagneau).

ing may extend considerably along the length. The nodes are usually most pronounced near the distal end, and although several may be seated along the shaft, the hair remains in its proximal and root portion apparently normal and firmly fixed in the follicle. Loss of hair, therefore, does not ensue, although the condition is persistent and chronic.[1]

Etiology and Pathology.—The disease is rare, and seen usually in males. Raymond, however, states that he has found it quite common on the genital hairs in women. As a rule, the subjects are in good health. I have met with 3 cases—all 3 physicians. Various causes—atrophic and mechanical—have been assigned, but the affection, nevertheless, remains yet a mystery, although the belief is growing that the nodular swelling, bursting, and consequent fracture are due to parasitic invasion. In support of this various observers—Raymond,[2] Hodara,[3] Spiegler,[4] Essen,[5] and Markusfeld[6]—claim to have found organisms, and, with the exception of Raymond, state that they succeeded, by experimental attempts, in producing the disease. Unfortunately, their findings do not all agree, and others (Neisser, Jadassohn, Unna, Bruhns, Pringle, myself, and others) have failed to discover bacteriologic evidence, although personally I am disposed to believe that it is of microbic origin.

FIG. 209.—Trichorrhexis nodosa.

Hodara's investigations are based upon a rather unusual form of the disease, or possibly a distinct, though allied, affection, which he found quite frequent in the scalp hair of women in Constantinople. The nodules are extremely small, and recognizable only upon close examination. It is associated usually with a splitting-up of the hair, which is the first symptom noticed, and which is generally observed at the ends, although it may also occur along the shaft. The hair frequently partly breaks at a nodule, on one side of it, and may thus form an angle, sometimes quite acute, with the main part of the shaft. Either as the result of combing or brushing or spontaneously the hairs readily break off at the joint thus made.

Another fact which seemed to support the parasitic view also was

[1] Jackson, "Two Peculiar Cases of Fragilitas Crinium," *Jour. Cutan. Dis.*, 1903, p. 473, records 2 cases, in men, upon the scalp, characterized by several sharply defined patches, in which the hair was short, broken off, and the remaining portion curled up close to the scalp, presenting an appearance similar to the curly hair of a negro. The malady came on suddenly, each case having been first noticed about four or five weeks before seeking advice. Microscopical examination (G. W. Wende, Mewborn) of the affected hairs in one of the cases disclosed many with evidences of trichorrhexis nodosa. Recovery ensued, in the course of a few months, from application of an ointment consisting of salicylic acid, and tincture benzoin, each 1 part, and neat's-foot oil 50 parts, together with shampooings with tar soap.

[2] Raymond, *Annales*, 1891, p. 568 (diplococcus).

[3] Hodara, *Monatshefte*, vol. xix., 1894, p. 173 (bacillus).

[4] Spiegler, *Wiener med. Blätter*, 1895, p. 599 (bacillus—different from Hodara's).

[5] Essen, *Archiv*, 1895, vol. xxxiii., p. 415 (bacillus—different from Hodara's).

[6] Markusfeld, *Centralbl. f. Bacteriol. u. Parasitenkunde*, abt. 1, vol. xxi., 1897, p. 230 (bacillus—seemed similar to Spiegler's); de Keyser, *Verhandl. V. Internat. Derm. Congress*, Berlin, 1904, vol. 1, part 3, p. 437 (micrococcus; this paper gives bibliography to date).

the observation by Ravenel[1] and myself that the tooth- and shaving-brushes of one affected (Ravenel himself) displayed the same nodosities. This was found to be so in another instance, referred to in Ravenel's paper. Since then the same observation has been made by others (Blaschko, Jadassohn, Bruhns, Saalfeld, and Barlow). In the brushes used by Ravenel and the other patient referred to bristles were found to be severally made up of different hair, one of the shaving-brushes being what is called in the shops "badger" hair, and the other a coarser hair, resembling hog-bristles; while the tooth-brushes were composed of still another kind. This eliminated the suspicion that possibly one variety of brush hair was subject to these changes. The supposition was that the brushes were infected by the patients, inasmuch as numerous other unused brushes examined did not show this condition, nor did it occur in brushes used by our acquaintances. A barber's brush, hair or mustache brush, becoming thus affected, could readily be the means of conveying the disease to others. Unfortunately, however, Barlow's[2] investigations do not accord with those by Ravenel and myself, as he states that he found the same condition of the hairs in brushes used by unaffected individuals. This seems to give some weight to the belief that these formations may be produced mechanically—by external injuries, as Wolfberg's,[3] Sabouraud's, and Lassueur's[4] observations also indicate.

On the other hand, it is possible, as Beigel suggested, that the swellings may be due to gaseous disintegration of the medullary portion pushing out the cortical substance, which finally gives way. He found, as have also Unna and others, that the first stage of the formation consisted in spindle-like swelling of the medulla. A microscopic examination discloses that the cortex is split up into filaments, with, in some instances, changes in the medullary portion; in others the latter is practically undisturbed, or at least remains unbroken and continuous, although somewhat swollen. Pigment granules and other granular débris are usually to be seen between the fibers.

Prognosis and Treatment.—The disease is persistent and rebellious to treatment, and therefore the chances of permanent relief are problematic, although cases do get well, but whether from treatment or spontaneously cannot be definitely stated. If the parasitic view, however, is the correct one, persistent measures should finally be successful. Almost all plans advised—and they are numerous—are practically in line with this theory. If many hairs are involved, and the disease is of the mustache or beard, as commonly observed, frequent shaving and the application daily of a saturated solution of boric acid, with ½ to 1 or 2 grains (0.035–0.135) of corrosive sublimate to the ounce (32.), can be advised. Weak corrosive sublimate lotions have, in fact, been advo-

[1] M. P. Ravenel, "Trichorrhexis nodosa—a Preliminary Note," *Medical News*, Oct. 29, 1892.

[2] Barlow, *Münch. med. Wochenschr.*, 1896, p. 651 (references, especially to papers bearing upon bacteriologic findings, and cites the various culture methods employed).

[3] Wolfberg, *Deutsch. med. Wochenschr.*, No. 31, 1884 (himself the patient).

[4] Lassueur, *Annales*, 1906, p. 911. Both Sabouraud and Lassueur say that these formations can be produced on the moustache of any one with not too coarse hair by frequent (three times daily) washing with soap and water and the associated traumatism of this operation.

cated by several, strongly by Sabouraud, who, however, prescribes it in equal parts of ether and alcohol (1 : 500), and with 5 to 10 grains (0.35–0.65) of resorcin, and 2 or 3 grains (0.135–0.2) of tartaric acid to each ounce (32.). Besnier and Roeser and Brocq speak favorably of extraction of the affected hairs, and touching the part daily with tincture of cantharides, pure or diluted, according to the sensitiveness of the skin, and continuing the application until the hair has well appeared. A 1 per cent. pyrogallol salve has been commended by Jadassohn, and a 2 per cent. aqueous solution of the same drug by Veiel. Schwimmer used an ointment composed of 15 grains (1.) of sulphur, 7½ grains (0.5) of zinc oxid, and 2½ drams (10.) of unguentum simplex.

Crocker states that change of climate has been successful. If there is anything in the trophoneurotic theory of its production, such remedies as arsenic, strychnin, phosphorus, cod-liver oil, etc., should be prescribed if at all indicated, and ought theoretically to have some influence, but experience does not seem to afford substantial proof of their value.

MONILETHRIX.

Synonyms.—Moniliform or beaded hair; Nodose hair (Smith); Aplasia pilorum intermittens (Virchow); Aplasia pilorum moniliformis (Behrend); *Fr.*, Aplasie moniliforme des cheveux et des poils (Hallopeau and Leredde); Nodosité des poils (Brocq); *Ger.*, Spindelhaare.

This rare affection of the hair was first described by Walter Smith, and later by Bulkley, McCall Anderson, Payne, Thin, Lesser, Hallopeau, Beatty,[1] Gilchrist,[2] Morrow,[3] Ruggles,[4] and others. The affection is usually confined to the scalp, and sometimes to a limited portion of it; but exceptionally it has been noted on other regions as well; in the cases described by Gilchrist, Morrow, and Ruggles it was limited to the legs. The hairs are made up of elongated, fusiform-looking nodes and connecting, narrowed atrophic portions, so that the hair has a beaded appearance. In fact, it may appear as if made up of a

FIG. 210.—Monilethrix—hair showing the breaks at the internodes.

series of thin, connected spindles. The nodular parts are much darker than the narrowed portions, the latter being almost colorless, so that the hair has a ringed aspect. The whole shaft is involved from root to the free extremity. The hairs readily break, not at the nodes, as in trichorrhexis nodosa, but at the thin portion, between the

[1] Beatty and Scott, "Moniliform Hairs (Monilethrix)," *Brit. Jour. Derm.*, 1892, p. 171—an excellent review and résumé of all recorded cases to date, 24 in number (Walter Smith (2), Liveing (1), Thin (1), Kaposi (2). Vidal (3), Unna (1), Bulkley (1), Bury (1), McCall Anderson (5), Luce (1), Lesser (1), Payne (2), Hallopeau and Lefévre (1), Arnozan (1), Abraham (1)); and description of an additional new case by Beatty. Literature references are given.

[2] Gilchrist, "A Case of Monilethrix, with an Unusual Distribution," *Jour. Cutan. Dis.*, 1898, p. 157 (with illustrations and an analytic table of all previously published cases (60), with bibliography, which includes cases recently exhibited before Dermatological Society of London by Colcott Fox (1896), Galloway (1896), and Anderson (1897).

[3] Morrow, *ibid.*, 1899, p. 41 (case demonstration).

[4] Ruggles, *ibid.*, 1900, p. 500 (with illustrations).

nodes, and the broken end of which is frayed or brush-like. So fragile are they that most of the hair of the scalp or affected part of it is broken off near or at the surface, and a variable degree of alopecia is noticeable, slightly similar to the conditions observed in some patches of ringworm. This resemblance is somewhat added to by a keratosis pilaris of the parts, which gives an exaggerated appearance of the stuffed follicular openings or goose-flesh surface sometimes observed in recent cases of this latter disease. The baldness may be finally quite extensive. Cases vary somewhat in degree, some being slight, and recognizable only on close inspection, others being quite conspicuous. In some of the hairs there may be continuous thinning, the whole hair appearing simply atrophic.

Etiology and Pathology.—The affection occurs in both sexes. It begins in early infancy,—in the first year or two,—and is looked upon as congenital. There are five exceptions to this on record: one of Smith's cases and Unna's case, and those of Gilchrist, Morrow, and Ruggles, in which the disease appeared much later—in the last 3 cases—all physicians—in adolescent or adult life. McCall Anderson's patients were of a family in which, in six generations, there were 14 cases among 27 persons; and Sabouraud[1] records, in five generations of a family, 17 cases. Payne's 2 cases were brothers, and Hallopeau saw 3 cases in the same family, 3 of whose relatives also were affected. Beatty's case was a brother of one of Smith's patients; and 2 other children, deceased, were affected similarly, and there was a suspicious history of baldness in the maternal uncle and maternal grandmother. At a recent meeting of the Duhring Dermatological Society of Philadelphia I. M. Koch exhibited 2 cases—brothers. While these family tendencies point to a hereditary affection, the possibility of contagion is one that cannot be arbitrarily set aside, although it is true that a contagious disease would ordinarily not be such a rare one. The common view, however, is that the disease is congenital, and that the thinned portions of the hair-shaft result from some defective development, the thicker or node-like portion being scarcely, if at all, beyond the normal thickness. There is much less pigment in the thinner portion—almost *nil*, in fact; the cases of Lesser, Gilchrist, and Ruggles were exceptional in this respect, the thinner part being the darker portion. From Scott's microscopic investigations it would appear that at one time the papillæ over the entire affected region are forming nodes, at another time internodes. There is usually an associated follicular hyperkeratosis—keratosis pilaris. In fact, Brocq, Ledermann,[2] and others think that the malady is closely related to keratosis pilaris. Both Gilchrist and Scott examined for organisms, but without result. Bonnet believes the narrowing due to an intermittent muscular contraction around the follicle just below the point where the sebaceous gland empties into it, and where the young hair-cells are still soft and readily compressed. Virchow, Kaposi, and a few others believe it due to periodic aplasia of the hair. Nervous shock is said to have given the start to the disease in Sabouraud's series and also in Unna's patient.

Treatment.—Very little, if anything, is to be hoped from treat-

[1] Sabourand, *Annales*, 1892, pp. 781 and 830 (good review of the subject).
[2] Ledermann (3 cases), *Berlin. klin. Wochenschr.*, 1903, p. 332.

ment. In one area in Gilchrist's case the disease, after existing for a number of years, disappeared spontaneously. Possibly in the later acquired cases, remedies, both constitutional and local, the former of an invigorating and the latter of a stimulating character, such as prescribed in alopecia areata, might be of service. In all instances in which the hyperkeratosis element is marked, weak sulphur and salicylic acid ointments should be used to lessen or remove this.

PIEDRA.[1]

Synonym.—Fr., Trichomycose nodulaire (Juhel-Rénoy).

This is a condition of the hair, studied by Osorio, Malcolm Morris, Desenne, Juhel-Rénoy, Lion, Behrend, Unna, and others, characterized by minute, pin-head-sized, hard nodules on the hair-shaft—in appearance somewhat suggestive of nits, but much smaller. It is rarely seen outside of Cauca, of the United States of Colombia, South America, although a few instances (Unna, Behrend) have been observed in Europe. It is not improbable that the "chignon disease" (chignon fungus), essentially similar in its symptomatology, described by Beigel[2] and T. Fox,[3] which apparently was at one time not infrequent in Europe, is, as Behrend suggests, identical with piedra. The affection is, with some exceptions, limited to the scalp hairs of the native women; occasionally, however, it is also noted in men, and either on the scalp or bearded parts. Hyde and Montgomery[4] briefly refer to a case of a young girl in whom the nodules were seated on the eyelashes of both eyes. The nodules are dark-colored, gritty, and almost stony hard, and, if numerous, give out, when the hair is combed or shaken, a crepitant or rattling noise. One to ten or more, irregularly placed, may be attached to a single hair-shaft, but, as a rule, the nearest to the scalp is not less than one-half inch distant. The view held by Desenne and Morris that the concretions are due to fungus growths has been confirmed by Juhel-Rénoy, Behrend, Unna, and Trachsler, although some slight differences have been observed. Unna and Trachsler believe that the formations may be due to several forms of fungus, the spores being of various size. The women of Cauca are in the habit of using a mucilaginous oil for a hair-dressing, and Morris considers that this is probably an important factor. The concretions may be either on the side of a hair or may completely encompass it. The structure of the hair does not suffer, as in trichorrhexis nodosa and monilethrix, and this serves well as a differential factor in the diagnosis. Lepothrix occurs only on the axillary and scrotal hairs, nor is it due to a mycelium-forming fungus.

[1] Literature: Malcolm Morris, *London Pathol. Soc'y's Trans.*, vol. xxx., 1879, p. 441; *Med. Times and Gaz.*, 1879, i., p. 409 (with discussion); Desenne, *Compt. rend. de l'Acad. des Sci.*, vol. lxxxvii., 1878, p. 34—editorial abs. in *Lancet*, vol. ii., 1878, p. 165; Juhel-Rénoy, *Annales*, 1888, p. 777 (illustrations of hair and fungus); Juhel-Rénoy and Lion, *ibid.*, 1890, p. 765 (with culture-tube illustrations); G. Behrend, *Berlin. klin. Wochenschr.*, May 26, 1890, p. 464; Unna, *Lewin's Festschrift*, Berlin, 1896; abs. in *Brit. Jour. Derm.*, 1876, p. 111; Trachsler *Monatshefte*, vol. xxii., 1896, p. 1 (with illustrations of hair and cultures).

[2] Beigel, *The Human Hair*, p. 111.

[3] T. Fox, *Jour. Cutan. Med.*, vol. i., 1868, p. 175 (with illustrations).

[4] Hyde and Montgomery, *Diseases of the Skin*, fifth edit., p. 551.

The **treatment** suggested by Juhel-Rénoy and Lion, based upon their culture experiments, consists in frequent washings with hot corrosive sublimate solution, 1 : 1000, the hot water softening the nodules and permitting thorough penetration. The same plans used for softening and detaching nits can also be employed.

TINEA NODOSA.

Under this term Cheadle and Morris[1] described an affection of the hairs of the bearded parts observed in a young man, characterized by irregular nodular incrustations along or around the hair-shaft, of a dull brown or dark-brown color. Crocker[2] also met with a similar case, in which it was limited to one side of the mustache; and that described by Thin,[3] involving the mustache hairs, was possibly a similar or allied affection, although the coating was somewhat continuous and free from nodose elevations. The lower part of the hair is usually free, the root remaining healthy and unaffected. The incrustation is found due to a fungus made up of spores somewhat smaller than those observed in ringworm. The affected hairs are rendered somewhat brittle and inelastic, and tend to break off or split up, although, as a rule, the fungus growth does not invade the hair substance.

In this connection, as bearing trifling resemblance to slight conditions of tinea nodosa, the small, narrow, ring-like sheath of sebaceous and epithelial matter sometimes carried up from the follicle outlet by the growth of the hair can be referred to. It is only occasionally observed, and usually in association with moderate seborrhea. Examined hastily and carelessly, these formations might also be mistaken for nits. Allied to this, too, is doubtless the case described by Grindon,[4] in which in a few limited regions of the scalp, in which the skin was slightly red and scaly, many of the hairs presented "along their length peculiar beaded concretions, grayish white in color, and to the casual glance closely simulating the ova of pediculi, under low power looking like casts of inspissated sebum, three to five times the diameter of the shaft, which they completely inclosed like a sleeve." A careful investigation showed the affection "to consist of an inflammation of the hair-follicle characterized by extrusion of the cells of a portion of the root-sheath proper *en masse*, carried up with the growth of the hair." It was accompanied by a slight redness about the follicular orifice, and was chronic in character. Beigel[5] had previously referred to this condition. This latter observer considered that a hyperplastic action, consequent on irritation or inflammation, exists in the sheaths of the hair-roots, producing an

[1] Cheadle and Morris, *Lancet*, 1879, i., p. 190 (with illustration); Giovannini's disease (*Archiv*, 1887, vol. xiv., p. 1049—with illustrations and some references), was apparently a similar or allied condition.

[2] Crocker, *Diseases of the Skin*, second edit., p. 819.

[3] Thin, *Lancet*, 1882, ii., p. 742 (with illustration); abs. in *Jour. Cutan. Dis.*, 1883, p. 188.

[4] Grindon, "A Peculiar Affection of the Hair-follicles," *ibid.*, 1897, p. 256 (with illustration).

[5] Beigel, *The Human Hair*, 1869, p. 125 (with illustration almost exactly like the condition pictured by Grindon).

abnormal number of cells which are glued together and adhere to the cuticle of the hair while passing through the hair-sac.

Treatment of tinea nodosa consists in frequent shaving or clipping and the application of a mild parasiticide.

LEPOTHRIX.

Synonym.—Trichomycosis palmellina (Pick).

Lepothrix is the name given by Wilson to a peculiar, roughly nodular affection of the hairs of the axilla or genital region, which had been first described by Paxton. The axilla is its usual site. The hairs, examined by the naked eye, are found lusterless, somewhat uneven, and jagged. They usually break readily, especially when dry. Examined more closely, with some magnification, they appear irregularly nodular, the nodular masses being arranged continuously along the whole length of the shaft, or in clumps here and there, but not encompassing the whole surface of the hair. The accumulation increases the thickness of the hair considerably. They are small, grayish-yellow to yellowish-red, rough concretions, their outer edge directed upward toward the end of the hair-shaft. This seems to be due to the fact that the cells of the cuticle, which, shingle-like, overlap in this direction, are probably loosened or softened by the heat, moisture, and sebaceous and sweat secretions of the part, and the bacteria of which the concretions are composed find a convenient place to lodge and multiply. They are firmly attached to the hair, a bacterial secretion probably forming a hard, gluey mass of which the concretions are partly made up. An added micrococcus in the axilla is occasionally observed, which gives the concretions the red color, and by which also the sweat is rendered of the same tinge (Pick, Balzer, Barthélemy, and others); the same concretions are seen on the scrotal hairs without the red color (Crocker). It is a rare affection according to ordinary observations or statistics, but both Behrend and Crocker consider it quite common, but as it seldom gives rise to trouble, advice is not sought, or affected individuals may remain unconscious of its existence. Behrend states that it exists to some degree in 20 per cent. of all people. The disease has been investigated by Behrend, Payne, Patterson, Eisner, Sonnenberg,[1] and others, and the concretions found to be due to parasitic growth. Apparently, however, there is some difference in the findings.

The condition is persistent and it is rebellious to **treatment.** Frequent washings with soap and water and the application of antiseptic lotions, such as one of corrosive sublimate, 1 : 2000 up to 1 : 500, are employed. A preliminary shaving of the part is to be advised.

CANITIES.

Synonyms.—Grayness of the hair ; Gray hair ; Whiteness of the hair ; Atrophy of the hair pigment ; Trichonosis discolor ; Poliosis ; Poliothrix ; Hoariness.

Symptoms.—Canities, or graying of the hair, may be congenital or acquired, usually the latter. Congenital grayness is somewhat

[1] Sonnenberg, *Monatshefte*, vol. xxvii., 1898, p. 538 (with review of the subject and literature references) ; see also literature references under red sweat.

rare, and almost invariably is observed limited to one or several tufts or patches on the scalp; exceptionally general grayness or whiteness is met with, but is then merely a part of that condition known as albinism, and which is described elsewhere. In congenital patchy canities there is often a striking hereditary history, the affection (so-called poliosis circumscripta hereditaria) extending through several generations, as in the examples recorded by Godlee,[1] Morgan,[2] Stricker,[3] and others.

Acquired canities, or graying of the hair, is most commonly a consequence of advancing years (canities senilis), although it is also observed in young and middle-aged adults (canities præmatura). In most instances the development is a gradual one. It may either involve all the hairs, or practically so, a slow and scarcely perceptible progress toward general grayness taking place; or, what is probably more usual, scattered hairs first showing the change, new ones being added to these, and so on until all are involved in the process. In other instances certain parts of the scalp show the depigmentation first, especially toward the temporal region, and, indeed, several parts may gradually grow gray, while others remain but little changed from the original color. Various conditions are, therefore, observed, from those of localized areas to more or less general, and from slight blanching to complete grayness or whiteness. As described in alopecia areata, the new-growing hairs in that disease are light colored, and sometimes remain as whitish locks for some time or almost indefinitely. Blanching also not infrequently ensues in the hairs of vitiligo patches. In ordinary graying of the hair the loss of pigment takes place, as a rule, slowly, and the hairs are often noted, on close examination, to be speckled with gray and various shades from this to the original color. The blanching is probably most commonly noted, in the beginning, at the new-growing portion, although exceptionally the distal ends exhibit the graying changes first. In some instances, too, after a certain degree of grayness or gray sprinkling has ensued, it is apparently stationary for a time, at least; as a rule, however, the blanching is progressive, though it may be scarcely perceptible from month to month. The scalp hairs are usually the first to show the graying tendency; later the bearded parts share in the blanching, although considerable time often elapses after the beginning scalp grayness before the beard change is especially observable. On the other hand, in some instances the bearded parts suffer first. Still later the eyebrows, and finally the other general surface hairs, may undergo depigmentation also, but it is ordinarily slight and often long deferred.

The question of the possibility of sudden graying of the hair is one that has been considerably discussed, and still has many doubters, but the various instances reported by competent observers indicate that such can take place. Apart from historic cases, such as Henry IV. of France, Marie Antoinette, and a few others, which, however, must, I believe, be accepted with considerable reservation as to striking suddenness, there are now to be found in medical literature

[1] Godlee, *Med. Times and Gaz.*, 1884, i., p. 180 (four generations).
[2] Morgan, *Brit. Med. Jour.*, 1890, ii., p. 85 (four generations).
[3] Stricker, *Virchow's Archiv*, 1878, vol. lxxiii., p. 623 (six generations).

a number of examples in which the change to grayness was noted to occur within the space of a few hours or days (Landois, Raymond, Laycock, Brown-Séquard, and others).[1]

Ringed Hair (Synonyms: Pili annulati (Karsch); Leukotrichia annularis; Trichonosis versicolor; *Fr.*, Canitie annellée; *Ger.*, Ringelhaare).—Ringed hair, or ring-like grayness, is an extremely rare condition, first described by Karsch,[2] and subsequently by E. Wilson,[3] characterized by alternate narrow, ring-like, white and pigmented bands, the latter usually being the normal color of the hair, whereas the gray or white segments result from some obscure pathologic changes or from intermittent arrest of the pigment-producing process. The bands are usually extremely narrow—in Wilson's case the white segment being about $\frac{1}{100}$ of an inch in width, and the dark or normal segment about twice as broad. In Karsch's patient, and also in the 2 observed by Crocker[4] and the 1 by Unna,[5] the pigmented and decolorized parts were somewhat irregular. Brayton[6] recently reported 1, and Galloway[7] 2 instances, similar to the uniform ring type described by Wilson. McCall Anderson's[8] case was also regular in the band-like formation, about one line in width, and was observed in a girl aged nine and a half, apparently of short duration, and disappearing after cutting of the hair and the use of a stimulating pomade. Excepting the ring-like aspect detected on close examination, the hairs show no other changes, their shaft being usually of normal and uniform thickness; in this respect it differs from monilethrix, with which it might otherwise be confounded, and further also by the fact that heredity seems to play no part; in Galloway's cases, however,—two brothers aged eight and ten,—it appeared to have been congenital. Various explanations have been given for this peculiar condition, but beyond that it seems attributable to the presence of gaseous material or air-bubbles nothing definite is known. In the reported instances—but several in number—the affection involved the scalp hair, with the exception of one of Crocker's cases, in which the mustache was the part affected and existed conjointly with trichorrhexis nodosa.

Other Color Changes.—In connection with canities the other color changes, in some instances spontaneously, in others as the result of the ingestion or local action of a few drugs, which have been exceptionally observed, may be referred to. In a case described by Smythe,[9] in a man aged forty-seven, the hair, which was of light color up to the age of thirty-five, began to gray, but not uniformly,

[1] Landois, "Das plötzlich ergrauende Haupthaar," *Virchow's Archiv*, vol. xxxv., 1866, p. 575 (patient with delirium tremens—hair changed in one night); Raymond, *Revue de Méd.*, 1882, ii., p. 770 (woman—as a result of sudden financial disaster—changed in one night, and subsequently fell out); Laycock, *Brit. and For. Med.-Chir. Review*, 1861, vol. i., p. 458 (a Sepoy, turned gray in one-half hour); Brown-Séquard, *Archives de Physiol.*, 1869, p. 442 (noticed that several of his own beard hairs daily changed to white).

[2] Karsch, quoted by Landois, *loc. cit.*

[3] E. Wilson, *Trans. Royal Soc'y London*, vol. xv., 1867, p. 406.

[4] Crocker, *Diseases of the Skin*, second edit., p. 790 (1 case); *Brit. Jour. Derm.*, 1893, p. 175 (second case).

[5] Unna, *Histopathology*, p. 1046.

[6] Brayton, *Indiana Med. Jour.*, vol. xvi., 1897–98, p. 10.

[7] Galloway, *Brit. Jour. Derm.*, 1896, p. 437 (case demonstrations).

[8] McCall Anderson, *Diseases of the Skin*, p. 74, in 1887 edit.

[9] Smythe, *Arch. Derm.*, 1880, p. 246.

over the scalp; those hairs which did not undergo this change turned to almost a jet-black color; at the same time his skin assumed a pigmented hue. Reinhard[1] observed periodic change of color from a reddish blonde to a light yellow in an epileptic idiot boy following violent outbursts of temper, the change occurring in about two days, apparently beginning at the distal ends and affecting almost all the hair, and again returning to the normal color in the course of a week or so. A striking example of change of color resulting from drug ingestion is that reported by Prentiss,[2] occurring in a young, blonde-haired woman, with pyelonephritis with anuria, after the administration of pilocarpin hypodermically, the color change being first observed after the twelfth day; under the continued administration of the drug the hair gradually became almost a pure black, the later pigmentation increasing even after the pilocarpin was stopped. It is not impossible that the disease itself had some influence, inasmuch as no other instance of hair coloration from this drug has been since reported.

It is well known that severe illness or strong emotion is exceptionally responsible for color change other than blanching, as in Reinhard's case, already cited, and also in those reported by Rayer, Beigel, and Smyly, quoted by Jackson.[3] In 2 cases of Alibert's of hair fall after fever, cited by Rayer, in one blonde hair was replaced by black, and in the other brown hair was replaced by red. Beigel's case was similar to the former; and in Smyly's patient suppurative disease of the left temporal bone was followed by change of color from a brownish to a reddish yellow in the hair of the opposite side. Such instances are, it is true, exceptional, but similar examples, though few in number, are to be found in literature.

Those rare anomalous cases of green hair, blue hair, and other unusual colors encountered are due to the local action of chemicals or drugs coming in contact with the hair either through occupations, as in workers in copper, cobalt, indigo, etc., or as a result of some medical or tonsorial application. Of the latter may be mentioned the yellowish-red or brown produced by chrysarobin, the yellowish or yellowish-red tinge in light-haired individuals following careless or prolonged use of resorcin hair tonics—in fact, these are in the same class with the ordinary hair-dyes occasionally resorted to. Closely allied to these is the yellowish tinge sometimes seen in jaundice patients.

Etiology.—The causes of canities have in a measure already been touched upon. Almost all cases are the result of age, some prematurely. In the latter a strong hereditary tendency is usually noted. Fevers or other serious illnesses frequently are the turning-point toward beginning grayness. There is no question but that excessive mental work, prolonged anxiety, worry, nervous shock, and other nervous disturbances have an influence in some cases. Reference has already been made to instances of sudden blanching so produced. Other examples following neuralgia, operations, etc., in which

[1] Reinhard, *Virchow's Archiv*, vol. xcv., 1884, p. 337.
[2] Prentiss, *Philada. Med. Times*, July 2, 1881, p. 609.
[3] Jackson, *Diseases of the Hair and Scalp*, p. 74.

the graying has been more or less localized, have also been noted by various observers. The most important factors in the general run of cases, however, are heredity and advancing years. In rare instances, it is true, an explanation of the graying is entirely lacking, as in an instance reported by Ledermann,[1] in a man aged twenty-four, in whom in a space of six weeks the hair of the scalp, beard, thorax, left axilla, and pubis turned gray, the patient's health being good and no hereditary tendency.

Pathology.—Grayness is the result of some lack of pigment production in the hair-papilla, or due to the presence of air in the cortical portion; in many cases both factors are probably operative. Pincus[2] states that in the earliest stage of canities the pigment gradually leaves the under layers of the papilla, and is to be found only in the outer layers, and later is produced only by a portion of the latter, which finally, in complete blanching, fails entirely. Ehrmann,[3] who has contributed valuable papers on the pigment-producing process of the skin, believes, on the contrary, that the pigment is formed, but that there is defective transmission, owing to the absence of transferring cells. Michelson[4] suggests that it might also be assumed that it is not the papilla which has lost the power of producing pigments, but the hair-cells which have lost the capacity of imbibing it, and this pigment, he further adds, intended for the hair, may be taken up again and deposited elsewhere, thus possibly accounting for the abundance of pigment in the senile skin. It is known, however, whatever the amount of pigment contained in the hair, that the color is materially influenced by the quantity of air or air-bubbles inclosed in the substance and cortical portions. It has been found that some gray hairs often contain considerable pigment, but that it is obscured by air, especially in the cortical layers. Indeed, Wilson and Landois have indicated that in this fact is to be found the explanation of sudden blanching—for some reason there is a rapid formation or collection of air-bubbles especially between the cells of the cortical layers, which renders the hair opaque and white, the contained pigment being obscured.

Prognosis.—Canities is usually progressive and permanent, although there are exceptional instances on record where there has been a return of color. For example, the case quoted by Jackson, of a man whose scalp hair and beard changed from black to white and the reverse three times in thirty years, the change to gray being rapid, while that to black again requiring four or five years. Wilson,[5] Leonard,[6] and others also cite cases where there has been a return to the original color. In some instances of graying after an acute disease and neuralgia in persons still young the hair has been noted to

[1] Ledermann (case demonstration before Berlin Derm. Soc'y), ref. in *Annales*, 1895, p. 697.

[2] Pincus, *Virchow's Archiv*, vol. xlv., 1869, p. 129; see also *Archiv*, 1872, vol. ii., p. 1.

[3] Ehrmann, *Allg. Wien. med. Zeit.*, 1884, p. 331; *Archiv*, vol. xii., 1885, p. 507, and vol. xiii., 1886, p. 57.

[4] Michelson, "Anomalies in the Coloration of the Hair," *Ziemssen's Handbook of Skin Diseases*, p. 433.

[5] E. Wilson, *Lectures on Dermatology*, London, 1878.

[6] Leonard, *The Hair*, etc., Detroit, 1880.

become again pigmented. These all are, however, to be considered as curiosities of dermatology, the rule of permanency in graying of the hair being practically absolute.

Treatment.—There is really no treatment for canities, unless the use of hair-dyes for its concealment can be so called. In former years these were quite generally resorted to, but at the present time are entirely out of fashion. I have never advised them, although others have. McCall Anderson[1] states that a good black can be produced by the conjoint use of a corrosive sublimate solution, 2 grains (0.135) to the ounce (32.), and one of sodium hyposulphite, 1 dram (4.) to the ounce (32.), the former being applied and followed by the latter. The nitrate of silver dye is perhaps that most commonly employed; a plain solution, 1 to 3 per cent. strength, will produce a black color, the hair being thoroughly moistened with it and dried in the sunlight. Kaposi[2] gives the following formulæ: For a black dye—℞. Argenti nitratis, gr. lxxv (5.); plumbi acetatis, gr. xv (1.); aquæ colognienses, ♏xv (1.); aquæ rosæ, q. s. ad f℥iij (96.). For a brown color: ℞. Pyrogallol, gr. xl (2.65); aquæ colognienses, ♏lxxv (5.); aquæ rosæ, ℥iij (96.). Leonard gives the conjoint use of these two solutions—No. 1: ℞. Bismuth. citrat., ℥j (32.); aquæ rosæ, aquæ destillat., āā f℥ij (64.); alcoholis, f℥v (20.); ammoniæ, q. s. No. 2: ℞. Sodii hyposulphit., ʒxij (48.); aquæ dest., ℥iv (128.). No. 1 is to be applied in the morning and No. 2 the same evening.

ALOPECIA.

Synonyms.—Baldness; Calvities; *Fr.*, Alopécie; *Ger.*, Alopecie; Kahlheit; Haarschwund.

Definition.—Alopecia is a general term applied to loss of hair, which may vary in extent from slight thinning to complete baldness.

The so-called varieties are essentially based upon etiology, and are known as alopecia congenita, alopecia senilis, alopecia præmatura, and alopecia areata. This last is an entirely distinct affection, presenting a special symptomatology of its own, and differs in many particulars, and is, therefore, considered elsewhere under a separate heading.

Alopecia Congenita (Alopecia Adnata).[3]—Congenital alopecia is a rare condition in which the hair loss may be patchy, or the general hair growth may simply be scanty, incompletely grown, or downy in character. In exceptional instances the hair has been entirely wanting, and in such cases it is usual to find also defective development of other structures, such as the teeth and nails, the latter more rarely.[4] Schede[5] recorded 2 cases, brother and sister, in whom the hair was completely lacking on scalp and elsewhere, and remained permanently

[1] McCall Anderson, *Diseases of the Skin*, p. 77.

[2] Kaposi, *Diseases of the Skin*, p. 487.

[3] A recent paper by Kingsbury, "Alopecia Congenita," *Jour. Cutan. Dis.*, 1906, p. 418, reporting 3 cases in a family with hereditary tendency gives a résumé of many of the recorded cases, with bibliography.

[4] Thurnam reported (*London Med. Chir. Soc'y Trans.*, 1848, p. 71) 2 cases—cousins—who had but little lanugo hair on scalp or general surface, and who had but four teeth; he also quotes additional cases; Danz, quoted by Michelson (*Ziemssen's Handbook*), saw 2 adults who had never had either hair or teeth.

[5] Schede, *Archiv für klin. Chirurg.* vol. xiv., 1872, p. 158 (with histologic illustrations).

so; they were otherwise healthy, as were likewise the parents and their other two children, and with normal hair growth. As Michelson[1] states, however, in some of the congenital cases there is not a permanent arrest of hair growth, but merely delayed, the scalp after a year or so often becoming covered with downy growth, which sooner or later may develop into hair of normal thickness; he refers briefly to an instance under his own observation, and also one observed by Luce. More frequent, probably, are those examples in which the alopecia is only partial, and, according to Michelson, who briefly describes 2 cases, in such instances growth is never to be anticipated. Audry[2] had under observation a case in which the alopecia followed the cranial sutures.

The fact that not infrequently the condition is observed in brothers and sisters, an example of which has already been referred to, furnishes the only known etiologic cause—heredity. Hutchinson's[3] observation of congenital alopecia of the scalp in a boy aged three and one-half years, whose mother had been bald since the age of six, primarily beginning as patchy areas, is also a suggestive instance. As illustrating this fact and other features of this malady, the cases—mother and two daughters—observed by Abraham[4] may be referred to: the mother had complete absence of hair from eyebrows, eyelids, arms, legs, and body, but had a scanty supply on the scalp, pubes, and in the axillæ; at birth she had a little down on the head, but this soon disappeared, and she remained absolutely hairless until the age of eighteen was reached, at which time it began to appear gradually on the scalp, axillæ, and pubes. Her two children—girls—aged respectively five years and fifteen months, were both practically hairless; the older child was born with a little down on scalp, which fell out when she was about three months old, and since then the alopecia had remained nearly complete; the younger child was born with but little real black hair, which fell off at about the same age, and she had remained completely without hair.

The pathologic anatomy has been studied by Schede, Jones, and Aitkens, but inasmuch as the cases vary considerably, little has been learned. Schede found, in his older patient, that the sebaceous glands opened directly on the skin, and that there were no hair-follicles, but in the deeper layers of the corium he found rudiments of such appearing as short, straight, or slightly convoluted tubules, without perceptible internal cavity, their whole structure corresponding to the external root-sheath. Jones and Aitkens, quoted by Michelson, found the epiderm atrophic, the cutis replaced by "cord-like areolar tissue, with interspersed fat-cells and accumulations, between which were altered follicles, and here and there indications of papillæ."

Alopecia Senilis.—Senile alopecia, as its name implies, is that so frequently seen in men developing in advancing years, being rarely seen in women. It is usually preceded by graying of the hair. It may consist of a general thinning, or more commonly of a general thinning with complete baldness of the vertex. Pincus states that if

[1] Michelson, *loc. cit.*, p. 409. [2] Audry, *Annales*, 1893, p. 899 (with cuts).
[3] Hutchinson, *London Med.-Chir. Soc'y Trans.*, 1886, p. 473 (case demonstration).
[4] Abraham, *Brit. Jour. Derm.*, 1895, p. 162 (case demonstrations).

the latter its starting-point is almost always at the very summit or central point of the vertex, and then advances anteriorly, and later also laterally and posteriorly. From this it gradually, and, as a rule, slowly, extends, and in some instances involves a large part of the entire region, generally leaving a fringe of variable width, except anteriorly, where the baldness is, as a rule, complete. The loss of the stiff hair is usually followed by the appearance of down, but this, for the most part at least, soon disappears, and with the atrophic thinning and partial or complete disappearance of visible follicular openings the shiny, billiard-ball smoothness more or less characteristic of the condition results. It is commonly believed, or often alleged, that a certain amount of thinning of the hair also is to be noted on other parts of the body, and this would seem to find support in the investigations by Pincus and Neumann, which indicate that the hair-loss is simply the result of cutaneous atrophic changes concomitant with old age; but this is by no means always the fact, for while sometimes observed, in the most instances, on the contrary, advancing years, according to my own observations, which agree with the views of Michelson and Unna,[1] show a tendency to increased hairiness on other parts—at least on the general body surface. As Unna rightly states, this tendency to increased general hairy growth is observed in women as well as in men. The anatomic structure of the skin in senile alopecia has been studied chiefly by Pincus, Neumann, Michelson, and Unna. As to be expected, atrophic changes are found, and considerable thinning of the cutis proper, and also of the hypoderm; in fact, in its essential features Pincus found the changes more rapid, but similar to those observed in alopecia seborrhoica (alopecia pityrodes), an opinion which Unna shares, the latter diverging somewhat from Pincus, believing that there are no differences further than the simple difference of age, and inclining to the opinion that in reality the condition is only a relatively delayed alopecia due to long-standing seborrheic catarrh. According to Michelson, the atrophic changes are preceded by alterations in the blood-vessels, the cutaneous arteries being narrowed by a fibrous endarteritis, and with a resulting destructive atrophy or destruction of the capillary network. Not much change is noted in the glandular structures; and Unna found a thickening of the panniculus, at the expense of the thinned cutis.

Alopecia Præmatura.—Premature alopecia is conveniently divided etiologically into two varieties—idiopathic and symptomatic. *Idiopathic premature alopecia* may be briefly described as an alopecia, for the most part similar to senile alopecia, and occurring without recognizable cause beyond hereditary influence. At first it is noted that there is a good deal of daily loss, and as this continues, thinning is noticed, and also that the new-growing hairs are less vigorous. While, like alopecia senilis, it often begins at the vertex, it frequently takes its start anteriorly, usually at the temple, and gradually extending backward in elliptic shape, encroaching on sides and the middle of the scalp, so that, when well advanced, the whole anterior portion excepting a small ridge toward the ears and a tongue-like projection

[1] Unna, *Histopathology*, p. 1062.

in the middle is completely bald. Not infrequently it thins both centrally and in the forehead region, and in occasional instances almost the entire scalp may be denuded of hair. As in other forms or varieties, slight or moderate downy growth takes the place of the normal hair, but this, with the exception of a scarcely perceptible tuft here and there, also often disappears. In some instances a seborrhea is added, or goes hand in hand with the hair fall, although such cases usually belong to the symptomatic type, the alopecia being due to the seborrhea. Alopecia præmatura idiopathica presents itself, as a rule, between the ages of twenty and thirty-five, and chiefly in men, occasional cases only being observed in women. It is, as already stated, without recognizable cause except heredity. Family influence is almost always noted, and this is observed, too, in the very form the baldness takes, its starting-point, extent, etc., being often a counterpart of a father, grandfather, or near male relative. Various causes have been assigned, such as wearing hats, especially a stiff hat, which binds the temporal arteries, and, I believe, with Jamieson and others, that this must be considered one of the contributing factors. In consequence also of keeping the scalp sealed against the light and air, contrary to nature's intentions, growth is impaired, the vascular supply in the skin about the roots is thus indirectly lessened, and the hair suffers from want of nutritive material. It is known, too, that premature idiopathic baldness is much more common among mental workers, especially of the professional class, who are a great part of the time indoors. As corroborative of its greater prevalence among the intellectual and educated classes, Eaton[1] found in Boston, in church and opera-goers, that from 40 to 50 per cent. of the men were bald, whereas in the audiences of cheap museums and prize-fights the average was less than half this percentage. It is in the intellectual and brain-working class, too, according to my experience, that the occasional cases of this variety of hair loss or moderate alopecia is noted in women. Ellinger[2] is inclined to the view, in which opinion Jackson[3] apparently concurs, that the habit of daily sousing the scalp with water is a possible contributing factor, inasmuch as he found this to be the custom of 85 per cent. of his patients. Various other causes are often named, but, after all, in these cases the strongest factor is heredity. Pincus[4] ascribes this variety of baldness to the fact that in certain families there is a distinct tendency to sclerosis of the connective tissue underlying the aponeurosis of the occipito-frontalis muscle, in this way gradually atrophic changes in the hair-papillæ and probably also compression and restriction of the vascular supply as well. This accords with my observations that hair thinning is usually noted in those in whom a tightened or spanned condition of the scalp develops.

Symptomatic premature alopecia, in contradistinction to the idiopathic variety, has a recognizable cause, and this may be widely dif-

[1] Eaton, *The Popular Science Monthly*, Oct., 1886.
[2] Ellinger, *Virchow's Archiv*, 1879, vol. lxxvii., p. 549.
[3] Jackson, "Baldness: What Can We Do For It?" *New York Med. Record*, Apl. 7, 1887.
[4] Pincus, *Berlin. klin. Wochenschr.*, 1883, p. 645.

ferent in the various cases. The hair loss takes place either gradually or rapidly, and may be temporary or permanent. The final condition may be such as already described, or it simply consists of more or less general thinning. After fevers or other severe acute systemic diseases, rapid hair-shedding (defluvium capillorum) is, as well known, not infrequently observed, but rarely progresses to baldness. In the active stage of syphilis, several months or so following the contraction of the disease, there is usually hair loss of the character of thinning out, rather than the production of distinct alopecia; it is commonly limited to the scalp, but it is also sometimes observed on other parts as well. The hair loss occurring after these various systemic conditions is rarely permanent, both after fevers and other acute constitutional diseases, as well as after syphilis, a regrowth, with some exceptions, generally taking place unless there is a family tendency to baldness, in which event it is more likely to be permanent. The most common cause of symptomatic premature alopecia, however, is seborrhea or the allied condition, eczema seborrhoicum (alopecia pityrodes, alopecia furfuracea). Elliot's[1] analysis of 344 cases gave 316 in which he attributed the hair fall to seborrheic disease. Jackson[2] found this the exciting cause in about 75 per cent. of his patients. No one can question the important etiologic bearing of this seborrheic affection, but in many instances doubtless it has the aid of a hereditary predisposition. There is usually a general thinning of the scalp hair, usually more marked over the vertex and at the temporal regions; this may continue slowly, without producing perceptible baldness for some time, but sooner or later, in most cases, the usual goal is reached. If seborrheic affections are to be considered communicable, then, as the factor in most cases of baldness, this latter practically becomes so likewise. In fact, in recent years, the hint has been made now and then that baldness, irrespective of the seborrheic factor, is possibly contagious—a conclusion that needs much to support it before it can gain full acceptance. Sabouraud maintains that the essential factor in practically all cases of baldness is his microbacillus of seborrhea. Other diseases of the scalp which are followed by loss of hair, usually circumscribed or partial in character, are chronic and persistent eczema, psoriasis, erysipelas, folliculitis decalvans, lupus erythematosus, ringworm, favus, and late atrophic or ulcerative syphilodermata. Eczema and psoriasis are rarely attended by any pronounced hair loss, and only, as a rule, after long continuance; and after their cure the hair usually regrows; that following erysipelas is seldom permanent. In ringworm the hair loss is temporary; in favus, in which destruction and atrophy of the follicles frequently result, the loss is never entirely made up. The destructive syphilodermata, lupus erythematosus, and folliculitis decalvans bring about follicular destruction, and naturally the effect is lasting. Other diseases, usually of rare occurrence, such as morphea, leprosy, etc., may also be followed by permanent hair loss in the areas involved.

[1] Elliot, "A Further Study of Alopecia Prematura, and its Most Frequent Cause, Eczema Seborrhoicum," *New York Med. Jour.*, vol. lxii., 1895, p. 525.

[2] Jackson, "Loss of Hair: A Clinical Study Founded on Three Hundred Private Cases," *Trans. Amer. Derm. Assoc. for 1900*, p. 50.

Prognosis.—The prognosis has been touched upon in speaking of the individual varieties. Exceptional cases of congenital alopecia finally present permanent growth, although most are hopeless. There is, moreover, no hope in senile alopecia, and but little in pure uncomplicated and apparently causeless cases of idiopathic premature alopecia, especially if the hereditary tendency is pronounced. Much can be done in the symptomatic forms, and if the element of heredity is lacking, a regrowth is not unusual, certainly worth trying for; indeed, all cases of hair falling or lost hair, except those in which distinct atrophic changes are evident, as shown by a thinning and stretched-looking and bound-down condition of the skin and a partial or complete obliteration of the follicular openings, are worth an effort, if not to cure, certainly toward the prevention of further loss. An opinion as to regrowth should, however, in all cases be given with a good deal of reserve. The hair thinning following the acute systemic diseases and active syphilis will usually look after itself, although much more rapidly and more certainly under treatment. The custom of shaving the scalp after fevers is absolutely unnecessary, barbarous, and without common sense to support it. Repeated shaving, at intervals of a few days, and for one or two months, might possibly stimulate growth, but a single operation does nothing except to disfigure and grieve the victim and enrich the wig-makers. Another custom may also be mentioned here, and that is the practice of singeing, alleged "to seal up the hair and prevent the outflow of the hair strength or nutrition"; this is not only a wholly useless measure, solely benefiting the tonsorial establishments, but it has no scientific basis, and is damaging to the hair for an inch or more up beyond the ends to which the heat is applied. It needs only to be mentioned, therefore, to be condemned.

Treatment.—In the treatment of hair loss, both the state of the patient's general health and the scalp must be considered. There are really no specifics as to constitutional remedies, although it has seemed to me that in some instances arsenic, fluid extract of jaborandi, or pilocarpin, and sulphur in small doses—2 or 3 grains (0.135–0.2) three times daily—have an influence. Of the general tonics, when indicated, arsenic, strychnin, iron, and cod-liver oil and the hypophosphites need only be mentioned. The external treatment is the essential part of the management. In cases in which seborrhea or eczema seborrhoicum is the cause or is present, treatment (*q. v.*) is to be directed against that alone, and when this is removed, the usual applications for uncomplicated cases of hair loss can be resorted to to stimulate new growth. Various applications are in favor for this purpose, often failing, however, in accomplishing the end. Most of the remedies used in seborrhea and seborrheic eczema are also often valuable, as hair tonics, especially the resorcin lotions, one containing 15 to 30 grains (1.–2.) to the ounce (32.) of water, of 1 part of alcohol and 3 of water, or alcohol alone; if the former, then with 2 or 3 minims (0.135–0.2) of glycerin; if alcohol, the same quantity of castor oil to the ounce (32). A caution is necessary as to resorcin; it should not be used except cautiously, scantily, and for a short time, in those of white or gray hair, as this drug undergoes change of color, and often gives the hair in

such cases a dingy or dirty yellowish tinge. If used carefully and to the scalp only, keeping it off of the hair, this does not result so readily. Indeed, in all instances remedies are to be employed sparingly, as most of them are dark colored and stain. A compound stimulating lotion which I have used frequently is:

℞.	Resorcin.,	ʒi–ij (4.–8.);
	Ol. ricini,	♏xxx (0.65–1.33);
	Ol. tiglii,	♏iv–xx (0.265–1.33);
	Alcohol., seu spiritus myrciæ,	℥iv (128.).

The croton oil is to be used cautiously, and in smallest quantity at first, although not infrequently it may be increased considerably before undue irritation is produced. Carbolic acid can also be often added to advantage, in the proportion of 5–10 grains (0.33–0.65) to the ounce (32.). Another compound lotion often valuable is: ℞. Resorcin., ʒj (4.); quininæ (alkaloid), gr. xv (1.); ol. ricini, ♏x–xxx (0.65–2.); alcohol, ad f ℥iv (128.). In those of very light or gray hair the resorcin can be omitted. An excellent stimulating tonic, long in general use, is one containing 2 to 4 drams (8.–16.) of tincture of cantharides, 4 to 8 drams (16.–32.) of tincture of capsicum, 20 to 60 minims (1.35–4.) of castor oil, and alcohol to make 4 ounces; or the oil and alcohol can be replaced by bay-rum.

Ointments frequently do better than lotions, and one that seems to be of aid is that composed of: ℞. Ac. salicylici, gr. x–xxx (0.65–2.); β-naphthol, gr. xx–lx (1.35–4.); sulphur. præcip., ʒj–ij (4.–8.); vaselin, q. s. ad ℥j (32.). Another containing coal-tar, a tarry preparation which is free from penetrating and tenacious odor, is: ℞. Liq. carbonis deterg., ʒj–ij (4.–8.); lanolin, ʒiij (12.); vaselin, ad ℥j (32.). The ordinary tars are more valuable, but their odor limits their use: Oil of cade, 1 or 2 drams (4.–8.), 2 drams (8.) of lanolin and vaselin to make an ounce (32.), is one of the best; occasionally, in warm weather, a small proportion of paraffin, to stiffen it, may be needed. Or this oil can be used with 2 or 3 parts of olive oil, liquid vaselin, or alcohol, and in this form is sometimes preferred. Heitzmann[1] commended the crude oleum rusci, made up with vaselin and paraffin, or vaselin and lanolin, in 10 to 20 per cent. strength; this is valuable, but the odor finds many objectors. An ointment containing pilocarpin, 5 to 10 grains (0.35–0.65) to the ounce (32.) of vaselin, can also be used. Lassar,[2] thoroughly believing in the parasitic character of the alopecias, advises, more especially for alopecia furfuracea, the following: first washing the scalp with tar soap, rinsing, drying, and applying a lotion consisting of 3 grains (0.2) of corrosive sublimate and 2 ounces (64.) of alcohol, and 5 drams (20.) each of glycerin and cologne spirits; the scalp is then dried, and an alcoholic solution of naphthol, 0.5 to 1 per cent. strength, is applied; and, finally, a 1.5 per cent. carbolized oil. This is to be done at first daily. It is a method to which, however efficacious, the average hurried American would object. Cottle[3] advises: ℞. Ac. acetici, ʒij (8.); pulv. boracis, gr. xxx (2.);

[1] Heitzmann, *Trans. Amer. Derm. Assoc.*, 1885, p. 32.
[2] Lassar, *Monatshefte*, 1882, p. 131.
[3] Cottle, *The Hair in Health and Disease*, London.

glycerin., ʒiss (6.); spts. vini, ʒij (8.); aq. rosæ, ℥iv (128.); and also ℞. Liq. ammon. acetat., ℥j (32.); ammon. carbonat., gr. xv (1.); glycerin., ʒiss (6.); aq. sambuci, ad ℥iv (128.). Jackson, while not placing much weight upon medicinal applications, speaks well of an ointment of cold cream as the base, with 10 per cent. of precipitated sulphur, and 3 to 5 per cent. of salicylic acid; also of one containing 1 dram (4.) of extract of jaborandi to the ounce (32.); and one suggested by Bronson, of 20 grains (1.35) of ammoniated mercury and 40 grains (2.65) of calomel to the ounce (32.) of vaselin.

The application selected should be made for the first few weeks once daily, later three or four times weekly. Shampooing is necessary from time to time, once every one to two or three weeks, depending in great part upon the care with which the applications have been made—if used freely and carelessly, a certain amount of soiling of the hair the sooner results. For shampooing the most satisfactory soap is one of boric acid or the tincture of green soap, with 10 to 20 grains (0.65–1.35) of resorcin to the ounce (32.).

There are certain other measures to be advised in these cases, which are really often more beneficial than the remedial applications. The scalp should be kept well aired, exposed to light and air as much as possible. Massage should be practised once or twice daily, and this is best done by grasping the scalp with one or both hands laterally, as well as anteroposteriorly, and with some pressure loosening the tissues from the underlying parts and trying to raise it into folds. It can also be gone over with one hand, pinching it up with the extended finger-ends, and producing some vascular flux and a sense of warmth. Simply rubbing the scalp is of very little use, and as done with the amount of friction put on by the average barber, even the good hair can be rubbed out. This procedure,—massage,—which Jackson considers the only one remedy worth the name for stimulating the growth of hair, is one that should not be neglected, and should be an essential part of the treatment, except in cases where there is seborrhea or irritation; if the latter are present, they should at first receive attention, after which massage can be instituted. Another measure of therapeutic importance is the use of electricity. Two or three times weekly or more frequently the scalp can be gone over for five to ten minutes with a metallic brush or comb attached to a faradic battery, using as strong a current as can be comfortably borne; this often produces considerable temporary hyperemia and stimulation. In addition to this the static current is also of value, and, employed with the crown a few inches above the scalp, for five minutes, several times weekly, it has seemed to me to be of value in some cases.

ALOPECIA AREATA.

Synonyms.—Area Celsi; Alopecia circumscripta; Porrigo decalvans; Tinea decalvans; *Fr.*, Pelade.

Definition.—Alopecia areata is an affection of the hairy system, most commonly of the scalp, characterized by one or more, usually circumscribed, rounded or oval patches of complete baldness, unattended by any apparent alteration in the skin.

Symptoms.—In the large majority of cases the malady is limited

to the scalp, but it may invade other parts, as the bearded region, eyebrows, eyelashes, and in rare instances the entire surface. The disease begins either insidiously or suddenly, and usually without any premonitory symptoms. Occasionally patients note a precursory feeling of slight irritation or insignificant itchiness at the point at which the area is to develop, and in some instances the appearance of the patches is preceded for several days or a few weeks by slight or severe headache, itching, burning, or other manifestation of disturbed innervation. As a rule, however, and with but few exceptions, the first evidence of disease is the bald patch. If developing suddenly, the hair falls out with great rapidity, in fact almost as a mass or lock, one or several typical areas being formed within a few hours. If occurring at night, the patient awakes to find a lock of hair on the pillow, slight or considerable in amount. Generally, however, and according to my observations in most instances, several days or a few weeks elapse before the bald spots are sufficiently large to become noticeable. The patches continue to extend peripherally for a variable period, and then often remain stationary for some days or weeks or indefinitely; if there are several, and in close proximity, from gradual extension they may fuse together, and there results a large, irregular, bald area, involving a considerable portion of the scalp. If the patches are numerous, or sometimes when in small number and spreading rapidly, the whole scalp may become involved, and completely or almost wholly devoid of hair. In average cases, however, there are usually two or three areas, and these are commonly, when fully developed, about one to two inches in diameter.



FIG. 211.—Alopecia areata of a common type, in a man of forty-five, of several months' duration; his son, aged twenty, had a short time previously, according to the statement of the patient, the same malady.

FIG. 212.—Alopecia areata, showing a large, elongated area, resulting from the coalescence of several rounded patches. The patient was a woman aged thirty-two, in whom the disease had lasted ten years, areas filling up with regrowth of hair, but with the recurrence of new patches at the same and other parts of the scalp at irregular intervals.

The skin of the affected areas is apparently unaltered, showing no departure from the normal, presenting merely the hair loss, usually with slight depression; it is smooth, milky white, or sometimes, in the early period of formation, faintly pink; at the peripheral part quite frequently some projecting stumps are to be seen, which may be readily extracted, and which are noted to be club-shaped, or, as Crocker says, bears some resemblance to an exclamation point, with the broad end externally and the small end with the constricted neck within the follicle. These stumps are rarely seen in the clearly neurotic cases, such as follow fright, nervous shock, accidents, etc. The bordering hairs, if the patch is still in process of advancing, are found to be loose, or relatively so. There is no inflammation, and, except as an accidental coincidence, there is no scaliness. Not infrequently, however, an oily seborrhea, usually of trifling character, is present. If the disease is of considerable duration, and also in some of the recent cases, the follicles are observed to be less prominent than normally, and slight atrophy or thinning sometimes occurs; the plaques are noted to be slightly depressed, this being more noticeably so at the central part. The malady, which is almost invariably chronic, may continue after well developed, without exhibiting progressive or retrogressive tendency. As a rule, however, after the lapse of a variable period the patches cease to extend, the hairs at the margins no longer exhibit any loosening tendency, and remain firmly fixed in the follicles; sooner or later a fine white lanugo or down shows itself, which is generally of extremely slow growth, and which may continue to develop until it is about one-half inch or so in length, and then disappoint expectations by dropping out again; or it may remain and become stronger, coarser, and pigmented, and the malady thus come gradually to an end. Not infrequently after growing for a time the new hairs fall out, and this may happen once or twice before finally recovery is permanently established. In other patients weeks or months elapse before a disposition to renewal of the hair sets in; and occasionally the new-grown hair remains unpigmented for a long while, and exceptionally indefinitely.

FIG. 213.—Alopecia areata in a young man aged twenty; a wide band-like area involving the outer portion of the entire scalp, beginning as typical plaques similar to that now seen higher up.

Thus run the majority of cases encountered. Occasionally conjointly with or independently of scalp involvement the male bearded region is the seat of one or more variously sized plaques, which follow about the same course as observed in the scalp patches. In

the less favorable instances, in addition to several or more spreading scalp plaques, the eyebrows are invaded, toward the outer side most frequently, and a portion of the hair falls out; or the greater part or all may go. In others, instead of distinct bald spot the eyebrow is noted to undergo general thinning. In more severe cases the lashes also fall out, in part or completely. Even without involving these regions, however, the scalp disease may be of a severe type, may extend, gradually or rapidly, and sweep off every hair. In other cases, still more extreme in degree, not only do the scalp, brow, and eyelid regions become devoid of hair, but the malady may finally invade other parts, as the axilla, pubic region, and, in rare instances, the hairy growth of the entire surface, whether lanugo or coarse hair, disappears (alopecia universalis). In such instances there is usually a cropping-up here and there, but most frequently on the scalp, of sparse, weak, downy hair, scattered or in ill-defined tufts; these, however, often drop out, and thus the case continues, with, in such instances, very little, if any, tendency to recovery.

As a less frequent clinical variety is that in which, instead of well-defined areas, the hair loss is in the form of a band, most commonly occurring about the border[1] of the scalp, although the scalp region in extreme instances of this kind may be completely grooved with these band- or ribbon-like bald patches or streaks. Another variety is that in which there are observed numerous small rounded or irregularly outlined spots scattered over the entire scalp. In other cases,—the universal form,—instead of distinct patch-formation there may be a rapid thinning of the hair on all parts and its final disappearance. In my experience, however, in these latter, there are at first one or two well-defined spots, not necessarily large, and these are soon followed, and rapidly, with general thinning and involvement of the hairs of the entire surface. In another class of cases, instead of irregular distribution of the patches, they occur at or near the site of an injury or in the course of a nerve. In still another group are those first described by Neumann as alopecia circumscripta seu orbicularis, in which the areas are small, quite distinctly depressed, and atrophic, and usually anesthetic, and run a persistent and unfavorable course.

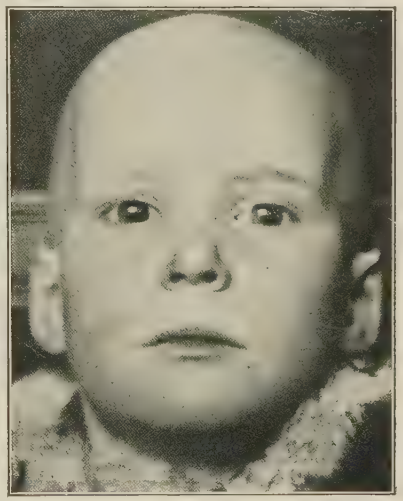

FIG. 214.—Alopecia areata in a female child aged four and one-half years, beginning when two and one-half years old as several typical rounded patches, which extended, and, with new areas, swept off the entire scalp hair; the hair of the right eyebrow has also almost completely gone, and that of the left is already thinned; the eyelashes are also partly involved.

[1] Heidingsfeld's case, *Cincinnati Lancet-Clinic*, Mch. 3, 1900 (with illustration), is a good example, associated with rounded areas.

In some instances associated conditions, neurotic in character, other than those described are noted. Thus occasionally vitiligo has been observed (Besnier, Feulard, Duhring, Senator, Dubreuilh, Thibierge, and others),[1] and the vitiligo areas themselves may be the seat of the alopecia, as in a case recorded by Eddowes.[2] In 2 instances the coexistence of these two diseases has come under my observation, both patients of a nervous type. Nail changes have also been noted, the nails, sometimes of both fingers and toes, becoming white, spotty, granular, several examples of which have been described by Darier and Le Sourd,[3] Audry,[4] Abraham,[5] Crocker, and others.[6] Morphea, another neurotic disease, has also been observed in a few instances to coexist.[7] Quite recently a case came under Eddowes's[8] notice in which alopecia, general in character, was later associated with scleroderma and vitiligo. Its coexistence with disease of the thyroid has also been exceptionally recorded (Bazin, Kaposi, Berliner).[9]

Etiology.—The disease occurs in both sexes, and at almost all ages. It is, however, rare before the age of five, and uncommon after forty, being most frequent between ten and twenty-five. While met with in all stations of life, there is a preponderance, according to my observations, among the poorer classes. Bulkley has found it more common in private practice. The malady is not so frequent in our country—being somewhat less than 1 case in 100—as abroad, more especially in France and England.

FIG. 215.—Alopecia areata in a man of thirty, of about one year's duration, showing in some parts a regrowth of hair which still remains uncolored.

There are two prevailing theories as to the cause of the disease: one of these regards it as parasitic and the other as neurotic. I feel confident that both are right, as a study of the literature, taken with personal observation, would indicate that there are, as regards etiology, two varieties—the contagious or parasitic and the non-contagious or the trophoneurotic.

[1] Feulard, *Annales*, 1892, p. 842, and 1893, pp. 31 and 1311; Besnier, *ibid.*, 1892, p. 845 (discussion also refers to two brothers, one of whom had vitiligo, the other alopecia areata); Dubreuilh, *ibid.*, 1893, p. 375; Morel Lavallée, *ibid.*, p. 376; Thibierge, quoted by Crocker.

[2] Eddowes, *Brit. Jour. Derm.*, 1898, p. 465 (case demonstration).

[3] Darier and Le Sourd, *Annales*, 1898, p. 1009 (1 case fully reported, and Darier refers to 6 others).

[4] Audry, *Jour. des mal. cutan.*, 1900, p. 161 (2 cases).

[5] Abraham, *Brit. Jour. Derm.*, 1900, p. 100 (case demonstration).

[6] G. W. Wende, *Jour. Cutan. Dis.*, 1905, p. 517 (with illustration and review of some other cases reported).

[7] Jamieson, *Arch. Derm.*, 1881, p. 141.

[8] Eddowes, *Brit. Jour. Derm.*, 1899, p. 325, and 1900, p. 137 (case demonstrations).

[9] Berliner, *Monatshefte*, 1896, vol. xxiii., p. 361.

There are numerous cases on record in which the malady followed nervous shock, fright, accidents, etc. Several years ago such an example came under my observation: A man, while driving at night in an open wagon along a country road, was thrown from the vehicle by an overhanging branch, striking upon his head; he was unconscious for some hours; within a week or ten

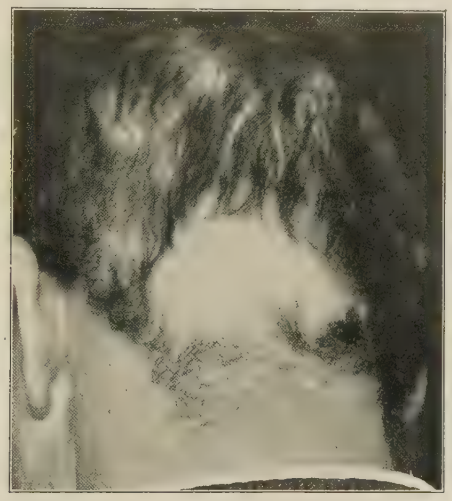

FIG. 216.—Alopecia areata, in a man of twenty-eight, showing a rather common site at the nape, with small ill-defined areas above which have partly filled in with new hair; duration, some months.

days a rapidly spreading alopecia areata had denuded almost the entire scalp, and later involved the eyebrows and eyelashes. A somewhat similar case, in which, however, the hair loss occurred later after the accident, is referred to by Stowers.[1] Instances following injuries to the scalp are also reported by Schütz,[2] and extensive development—universal alopecia—has been recently observed after severe fright by Boisser[3] and Bidon.[4] Malcolm Morris[5] mentions a case in which total alopecia occurred in a woman within forty-eight hours of receiving news of the death of her son. Other examples have been referred to by Duhring, Crocker, Duckworth, Steppe, and many others. Indeed, the clinical proof that fright, shock, accidents, great anxiety, and mental worry, etc., are the causative factors in many cases is overwhelming. In occasional instances of direct scalp injury alopecia does not appear to result so much from the effect, which may be slight, upon the general nervous system, but occurs apparently in consequence of induced local neuritic changes. In 2 of Schütz's cases following scalp wounds the ensuing hair loss was in streaks diverging from the seat of injury. Schütz states that hair loss noted

[1] Stowers, *Brit. Jour. Derm.*, 1897, p. 44 (case demonstration).
[2] Schütz, *Münchener med. Wochenschr.*, 1889, No. 8, p. 124.
[3] Boisser, *La progrés méd.*, June 17, 1899, p. 380.
[4] Bidon, *La France méd.*, 1899, p. 269.
[5] Malcolm Morris, *Diseases of the Skin*, 1894, p. 473.

in German students from wounds received in the sword duels doubtless belongs in the same class. The question of heredity in the extensive or generalized examples has received no attention, and yet, personally, I have observed 2 instances in which the family history disclosed a similar condition in a member of a preceding generation. In these 2 were involved 3 cases, all males, 2 of whom were brothers. The alopecia, beginning as an ordinary case of alopecia areata, in all about the age of three or four years, rapidly spread, and involved the entire scalp, eyebrows, and eyelashes, and the down on some other parts. Inquiry elicited the fact that in both instances a grand-uncle had had the same misfortune, likewise developing it early in life.

On the other hand, one cannot deny that there is also a contagious or parasitic class, and this cause probably accounts for the majority of cases, although the contagiousness, except under some unknown favoring circumstances, is usually extremely slight. These cases are, I believe, commonly represented by the type with the peripheral stumpy hair often noticeable in the early stages, and are generally characterized by one to several small or moderately sized areas, or by numerous scattered pea- to dime-sized rounded or irregularly outlined spots, as in many of the patients in the epidemics reported by Putnam [1] and Bowen.[2] The spread of the disease, starting from one case in one of these epidemics, was remarkable, finally 63 out of the 69 girls in the institution presenting areas. These are the first and, so far as my knowledge goes, the sole epidemics ever recorded in this country. In France epidemics have been observed in schools among children, and in barracks among soldiers. Besnier,[3] Merklen,[4] Brocq,[5] and other French observers have collected a number of instances in illustration of its contagious character. The towels, brushes, barber-shops, and hair-clipping instruments were variously thought to be the means of communication. English observers do not share the extreme views of the French as to its contagiousness, but Crocker [6] is a strenuous advocate of the parasitic and contagious character of most cases. Pye-Smith[7] refers to several instances of its appearance in two or more children in the same family. The Germans have been reluctant to accept this view, but in late years suggestive cases have been reported, and recently an epidemic of the disease in an asylum has been recorded by Ehrenhaft.[8] Plonski [9] and others have observed its transmission from one member of a family to

[1] Putnam, *Archives of Pediatrics*, August, 1892.

[2] Bowen, "Two Epidemics of Alopecia Areata in an Asylum for Girls," *Jour. Cutan. Dis.*, 1899, p. 399; and also concerning first (Putnam's) epidemic, *Brit. Jour. Derm.*, 1894, p. 80; and 3 cases in same family (father and 2 children), *Jour. Cutan. Dis.*, 1904, p. 38.

[3] Besnier, "Sur la pelade," *Bull. Acad. de. Méd.*, 1888, p. 182.

[4] Merklen, "Etiologie et prophylaxis de la Pelade," *Annales*, 1888, p. 813.

[5] Brocq, "Clinical Facts Bearing on the Contagious Nature of Alopecia Areata," Paris letter in *Brit. Jour. Derm.*, 1889, p. 479; Moty describes, *Annales*, May, 1902, epidemics occurring among troops.

[6] Crocker, "Alopecia Areata, its Pathology and Treatment," *Lancet*, Feb. 28, 1891, *Brit. Jour. Derm.*, 1891, p. 197; also in treatise on *Diseases of the Skin*, second edit.

[7] Pye-Smith, *Diseases of the Skin*, 1893, p. 258.

[8] Ehrenhaft, *Klin.-therap. Wochenschr.*, 1899, p. 358; abs. in *Monatshefte*, 1899, vol. xxix., p. 340.

[9] Plonski, *Dermatolog. Zeitschrift*, 1898, p. 371.

another. American dermatologists[1] have, upon the whole, accepted the view of two classes of the disease, the trophoneurotic and the parasitic or contagious, but have very little clinical evidence of the latter to offer. Duhring, Bulkley, and a few others hold strictly to its nervous origin. Crocker believes the disease, as exemplified in the majority of cases, related to ringworm, and Hutchinson's theory as to its occurring in those who had previously had ringworm is well known. Syphilis has been suggested as etiologic in some instances, but cannot, I believe, be considered more than a predisposing or contributing factor, although there is a pervading, but ill-defined, acceptance of such cause in some cases by the general profession, notwithstanding that there is a remarkable dearth of reliable literature observation to support it.

Pathology.—Clinical observations, together with experimental investigation, leave but little, if any, doubt that the malady, or, more properly speaking, the bald areas which we are accustomed to place under the one class name alopecia areata, is the result of at least two pathologic processes,—trophoneurotic and parasitic,—and this is the opinion held by the large majority of dermatologists. In addition to the evidence already quoted in etiology as indicating local or general nerve influence, and the occasional association of other nervous diseases, such as vitiligo, nail changes, Graves's disease, etc., must be mentioned the animal experiments made by Joseph[2] and Moskalenko and Ter-Gregoryanetz,[3] in which, in a large proportion, excision of the second cervical ganglion was followed by bald areas in the region covered by the distribution of the second cervical, the great auricular, and the occipital nerves. While these experiments were also partly confirmed by Mibelli, others—Behrend[4] and Samuel[5]—were not successful. The observations of Pontoppidan[6] and Bender,[7] of the development of alopecia patches after operations on the neck, are somewhat confirmatory of the experimental investigations. Crocker believes the neurotic class can be subdivided into three divisions—alopecia universalis, in which general nervous shock of various kinds is causative, and in some of which cases the nails also suffer; alopecia localis seu neuritica, consisting of but few patches, and presenting at the site of an injury or in the course of a nerve distribution; alopecia circumscripta seu orbicularis, characterized by the marked depression of the bald areas, usually with nail involvement, and of which the causes are unrecognized. As already remarked, his other division of the disease is the largest, and which he designates true alopecia areata, and which

[1] See discussion on "Alopecia Areata," *Trans. Amer. Derm. Assoc. for 1892.* In a recent paper, *Jour. mal. cutan.*, May, 1906, Hallopeau goes over the contagious grounds pretty thoroughly.

[2] M. Joseph, *Monatshefte*, 1886, p. 483, and *Centralbl. für med. Wissench.*, vol. xxiv., 1886, p. 178.

[3] Moskalenko and Ter-Gregoryanetz, *Vratch*, 1899, p. 541; abs. in *Jour. Cutan. Dis.*, 1899, p. 432.

[4] Behrend, *Virchow's Archiv*, vol. cxvi., 1889, p. 173.

[5] Samuel, *ibid.*, vol. cxiv., 1888, p. 378.

[6] Pontoppidan, *Monatshefte*, 1889, vol. viii., p. 51.

[7] Bender, *Dermatolog. Centralbl.*, October, 1898.

he thinks might properly be called alopecia parasitica, or by the old name, tinea decalvans. Leloir,[1] in an analysis of 142 cases, of which 92 were subjected to close inquiry and study, he concluded that some cases must be included under a trophoneurotic class, some under a class in which all etiologic factors seemed wanting, and a third class which comprised the cases which were contagious. In histologic examinations of a case of the trophoneurotic class the nerves presented all signs of a degenerative atrophic neuritis (parenchymatous neuritis).

While doubtless future investigations will finally disclose the true parasitic element in the contagious class, that end can scarcely be said as yet to have been reached. From time to time a specific parasite has been heralded by different observers, but, in the main, that found by each observer was unlike that discovered by the other. Thus Gruby[2] has been credited with the statement that he had discovered it in the "microsporon Audouini," and this may be responsible for some cases of bald plaques, properly belonging, however, to the ringworm group; ringworm cases, according to Sabouraud, are those which Gruby had in mind, and not an investigation of true alopecia areata. Later Bazin (1862) attributed the disease to the "microsporon decalvans," and Thin[3] still later described another fungus,—minute schizomycetes,—which he denominated the "bacterium decalvans." Von Sehlen[4] added still another, which, however, seems similar to that found by Thin. Later Robinson,[5] in an elaborate investigation, found cocci in masses and rows, and chiefly in the lymph-spaces of the corium and subpapillary layer, and also in the root-sheaths of the hair around the affected areas.[6] More recently Sabouraud,[7] after a careful and prolonged investigation, states the disease to be caused by a microbacillus, present in the earliest and progressive stages of the disease, and found in the upper part of the follicle, massed together with the fatty secretion of the neighboring glands and the vestiges of the dead hair. The bacillus is minute, often comma-shaped, $\frac{1}{2}$–1 μ in length, and $\frac{1}{4}$ μ in thickness, lying side by side, or occasionally two or three attached together. It is the same microbacillus found in the sebaceous discharge of seborrhœa oleosa and in comedo, which

[1] Leloir, "Études sur la pelade," *Bull. de l'Acad. de Méd.*, 1888; good abs. in *Brit. Jour. Derm.*, 1889, p. 67, and *Monatshefte* (with some case details), 1888, p. 857.

[2] Gruby, *Compt. rend. d. l' Acad. des Sci.*, 1843, p. 301.

[3] Thin, *Trans. Royal Soc'y*, 1881–82, vol. xxxiii., p. 247.

[4] Von Sehlen, *Virchow's Archiv*, 1885, vol. xcix., p. 327.

[5] Robinson, *Monatshefte*, "Pathologie und Therapie der Alopecia Areata," 1888, pp. 409, 476, 525, 582, 735, and 771 (an exhaustive study of the disease, with a review of the observations and work of others, with numerous references). See also his article on "Alopecia Areata," Morrow's *System*, vol. iii. (Dermatology), p. 862.

[6] These are now believed to be an ordinary skin coccus, and are apparently the same as found by Norman Walker and Marshall-Rockwell ("Alopecia Areata; A Clinical and Experimental Study" (63 cases), *Scot. Med. and Surg. Jour.*, July 1901, p. 12). Their studies lead them to believe in its contagiousness, and that the nervous element in the etiology of the disease is greatly overrated.

[7] Sabouraud, *Annales*, Mch., Apl., May, and June, 1896; good review by Leslie Roberts, in *Brit. Jour. Derm.*, 1896, p. 444; and by Brocq, in Paris letter, in *Jour. Cutan. Dis.*, 1896, p. 366. See also Sabouraud's later paper (on fatty seborrhea and alopecia areata), *Annales de l' Institut Pasteur*, 1897, p. 134.

throws doubt upon its pathogenic influence in alopecia areata, although it is possible that a different degree of virulence might exist, or, in other words, it is possible that though morphologically identical, the toxic nature of their secretions may vary. Sabouraud regards the disease as a seborrhœa oleosa of an acute type. This writer states that he has succeeded in experimental animal inoculations with pure cultures in producing characteristic areas. Jacquet,[1] on the contrary, reports negative results in direct inoculation experiments.

Several investigators other than those here named have also discovered organisms, among whom may be mentioned Bazin, Eichhorst,[2] Malassez,[3] Kazanlï,[4] Vaillard and Vincent,[5] Bowen, Crocker, and a few others.[6] Vaillard and Vincent's investigations of cases from an epidemic affecting 44 soldiers pointed to micrococci as the pathogenic factor; the germ was cultivated in the laboratory, and in experimental animal inoculation it was shown to have peladogenic properties. In Roberts's review he suggests the possibility that we have to do with three organisms which may produce the disease: (1) Bacillary alopecia (Sabouraud); (2) coccogenous alopecia (Vaillard and Vincent, von Sehlen, Robinson); (3) hyphtogenous alopecia—trichophytic alopecia, secondary to trichophytosis capitis (Crocker and others). It is certainly true that perfectly bald plaques, indistinguishable from ordinary alopecia areata, are occasionally seen as the result of ringworm fungi invasion. Such was Hillier's [7] epidemic, so much quoted as examples of epidemic alopecia areata. But that the larger proportion of cases are thus to be explained, as Crocker intimates, is not, I believe, sustained by the experience of other observers.

So far as one is able to draw inference from the somewhat conflicting evidence, it seems probable that the bald areas, which may be more properly considered only as a symptom, result from whatever influences the hair-growing process, be it sudden withdrawal or perversion of the innervation of the part due to shock,[8] etc., to injury of the cutaneous nerves, to peripheral irritation by parasites or their toxins, either directly upon the trophic nerves or primarily upon the tissues. It was formerly believed that no textural or inflammatory changes occurred except slight atrophy in old cases, and to the unaided eye this seems usually true, but histologic investigations (Giovannini, Robinson, Sabouraud, Unna, Harris, and a few others)[9] show that

[1] Jacquet, *La presse méd.*, Dec. 12, 1903 (100 attempts in 6 individuals, with scrapings from areas in several cases).

[2] Eichhorst, *Virchow's Archiv*, 1879, vol. lxxviii., p. 197.

[3] Malassez, *Arch. de phys. norm. et path.*, 1874, p. 203.

[4] Kazanlï, *Vratch*, 1888, p. 763; abs. in *Brit. Jour. Derm.*, 1889, p. 132.

[5] Vaillard and Vincent, *Annales de l' Institut Pasteur*, 1890, vol. iv., p. 446.

[6] See Robinson's paper, *loc. cit.*

[7] Hillier, *Handbook of Skin Diseases*, p. 286; also *Lancet*, 1864, ii., p. 374.

[8] Among these can be, doubtless, included dental irritation and, possibly, visual defects, but scarcely to the extent believed by Jacquet (*Annales*, Feb. and March, 1902) and Trémolieres (*La presse méd.*, June 14, 1902, and Jan. 1, 1903).

[9] Giovannini, *Annales*, 1891, p. 921; Robinson, *loc. cit.*, and Morrow's *System*, vol. iii., p. 865; Sabouraud, *loc. cit.*; Unna, *Histopathology*; Harris, quoted by Crocker, *Diseases of the Skin*, third edit., p. 1226.

primarily the condition is an inflammatory one, involving the corium. In 7 cases investigated by Robinson he always found appearances of inflammation, as well as a perivascular infiltration with round cells; in recent examples lymph had coagulated in the dilated lymphatics, and some of the larger and small arteries contained thrombi. In those of longer standing thickening of the blood-vessels was always noted. Later the sebaceous glands undergo atrophy, and later still the fatty tissue. Robinson considers the primary changes to be in the blood- and lymph-vessels; the subsequent glandular atrophy to be due to the chronic obliterative disease of the vessels. The fall of hair in the beginning he attributes to the acute thrombotic closure of the vessels. The inflammatory process has its seat in the corium, especially in the subpapillary layer. The slight depression noted he believes, like Hutchinson, to be due to the absence of the hair, and does not agree with Michelson, who ascribes it to the loss of fat—this latter not taking place until late in the disease. According to Giovannini, an infiltration of white blood-corpuscles around the deep part of the hair-follicle precedes and accompanies the disease, suggesting to him a deep-lying folliculitis, the other phenomena being secondary to this local leukocytosis. Degenerative changes ensue in the hair-bulb, and also in the suprabulbar part, or the neck of the hair.[1] Similar changes are also noted sometimes in the hair just beyond the neck and follicle, somewhat similar to the fibrillar breaking-up noted in trichorrhexis nodosa.

Diagnosis.—The malady with which alopecia areata is most likely to be confused is ringworm, but in the latter the scaliness, though slight, the broken-off or nibbled-looking hairs, incomplete baldness, rather prominent follicular openings, often stuffed with projecting débris, and often visible inflammatory signs distinguish it from alopecia areata, which, on the contrary, presents smooth, scaleless plaques, generally completely devoid of hair, and with the follicular openings frequently less conspicuous than normally. It is the beginning and spreading circumscribed patches of alopecia areata, with some stumps peripherally, which suggest ringworm, but the other differential features named, with the history of the case, usually indicating rapid development, will, as a rule, suffice to reach a correct diagnosis. The bald type of ringworm is often difficult to distinguish from the patch of alopecia areata, but the beginning features, and often a history of another case in the family presenting the usual ringworm features, will be of aid. In these instances ordinarily the first symptoms are distinctly those of ringworm, later disappearing and leaving the confusing bald plaque. In doubtful cases examination of the border or stump-like hairs can be resorted to (see ringworm). Another disease in which plaque-like hair loss, more or less pronounced, is noted, is favus, but this, unlike alopecia areata, presents crusts, mild inflammatory symptoms, and usually incomplete baldness. If the crusts are temporarily wanting, owing to previous removal by washing, the atrophic or scar-like character of the patch, together

[1] In addition to those referred to, Behrend, *Virchow's Archiv*, vol. cix., 1887, p. 493, has also investigated the hair changes.

with the history, will be sufficient to distinguish it. The bald areas of lupus erythematosus, which are more or less cicatricial, with follicular destruction and a mildly or moderately inflammatory border, can scarcely be confounded with alopecia areata, in which these features are absent. The bald spot or spots left on the scalp of children of the poorer classes from a preceding cutaneous abscess or blind boil might, if the case is carelessly examined and considered, be mistaken for the disease. In folliculitis decalvans the central part of the bald plaque is distinctly atrophic or cicatricial, and the border shows follicular inflammation.

Prognosis.—The outlook for recovery in children and young adults in cases in which but several patches are present is favorable. In such variety, too, in older patients, those not over forty, the result is almost always a regrowth. In more extensive involvement of the scalp the prognosis in those under twenty or thirty is usually good, but in older people an opinion is to be given with considerable qualification. In those instances involving scalp, eyebrows, and eyelashes, if only partial, and in young individuals, recovery may take place, but it is best not to be too positive; when the hair fall on these parts is complete, the chances are much less favorable; in such type in adults past thirty the prognosis becomes even less hopeful. In the more or less generalized cases of the malady one cannot be too cautious in expressing an opinion, as in but few of these instances does a regrowth ever take place. Alopecia areata of the bearded region usually runs a favorable course. A hopeful feature in all instances of the disease is the presence of a downy growth; if no tendency to such appearance, after some weeks or a few months, is manifested, the outlook is not so promising; and it is still less so if atrophic changes have ensued, and the follicular openings become less and less visible. In all cases of the malady, however, the uncertain duration must be borne in mind; several months, and in some instances one or two years, may elapse before complete and permanent restoration of hair takes place. The malady, moreover, is one in which relapses are not uncommon.

Treatment.—The necessity of systemic measures in alopecia areata is somewhat in question at the present day, owing to the diverse views held regarding the nature of the disease. Those who consider it of neurotic origin place great stress upon the value of constitutional treatment, whereas those that contend that the malady is essentially parasitic have recourse to exclusively local measures. Inasmuch as it is now generally admitted that we have cases which may be due to one or the other of these causes, and as in many instances it would be somewhat difficult to classify them, the safer course to pursue is to prescribe both constitutional and local measures; the former having as their object the correction of any defective condition of the general health, and more especially the invigoration of the nervous system, and the local treatment having in view a stimulation of and parasiticide action upon the affected areas. Fortunately almost all, if not all, the external remedies employed are active parasiticides as well as stimulants, and their

use meets, in reality, both the neurotic and parasitic views. The principal remedies prescribed in the constitutional treatment are arsenic, quinin, nux vomica, phosphorus, pilocarpin, ferruginous tonics, and cod-liver oil, the choice depending upon a study of the individual case. Arsenic has been highly extolled by several writers, and Duhring[1] especially is warm in praise of its value in this disease; it appears to be of distinct benefit in some cases, and more especially in those which are apparently truly neurotic in origin. It should be given in moderate dosage, from 3 to 5 drops (0.2–0.33) of Fowler's solution or the solution of sodium arseniate three times daily or its equivalent of arsenious acid, long continued. Nux vomica and ferruginous tonics are also often of service either directly or indirectly, and can be advised conjointly with the arsenic. Pilocarpin or the fluid extract of jaborandi has had some advocates. The former, in the more extensive scalp cases, injected subcutaneously in the affected part, in the dose of $\frac{1}{30}$ to $\frac{1}{10}$ of a grain of the hydrochlorate, is, I believe, occasionally of some service; Pringle,[2] Crocker,[3] and others have also observed a beneficial effect. In debilitated subjects the building-up influence of cod-liver oil is often of marked value. The benefit from outdoor life, relaxation from excessive mental work or worry, is of essential importance in the neurotic cases. Morrow,[4] who is probably next to Robinson, among Americans, firmest in his opinion as to the local nature of the malady, believes, however, especially in cases where the disease is generalized and protracted, the effect of local treatment to be materially aided and energized by the exhibition of tonics and reconstituent remedies; and in all cases where there is evidence of a loss of nerve tone he is accustomed to give the phosphid of zinc and strychnin, a combination of phosphorus, iron, and strychnin, or phosphoric acid with strychnin. Inasmuch as it is possible that occasional cases may have their origin in dental irritation, visual defects, etc., such matter should be given inquiring attention.

While constitutional remedies are, therefore, to be prescribed according to individual indications, with a possible trial of arsenic and pilocarpin, nevertheless external treatment is to be looked upon as an essential part in the management of every case. As some of the cases are contagious, the same measures to prevent its spread and communication as suggested in ringworm are to be advised: the patient should have his own towel, brush, comb, etc., and a weak sulphur or sulphur and naphthol ointment or a carbolic acid wash applied to the scalp generally every two or three days; and once in five to ten days the parts should be washed with the tincture of green soap or with a sulphur-naphthol soap. The object of local treatment is two-fold—a stimulation of the part, promoting a flux of blood and aiding the nutrition of the affected area, and an inhibitive or destruc-

[1] Duhring, discussion in *Trans. Amer. Derm. Assoc. for 1892*, p. 36.
[2] Pringle, *Brit. Jour. Derm.*, 1898, p. 198.
[3] Crocker, *Diseases of the Skin*, second edit., p. 814.
[4] Morrow, "The Treatment of Alopecia Areata—with Cases," *Jour. Cutan. Dis.*, 1891, p. 381.

tive influence upon any possible pathogenic parasite which may be seated there. The skin of the affected areas will usually stand strong remedies and show no irritation compared to that of the immediately adjacent skin. The choice and strength of the application advised will depend upon the extent of the disease and the frequency of inspection. The strong remedies can be used from the start in cases of limited extent, and to small parts successively in the more extensive types, along with the general application of the milder remedies. The loose hairs of the outlying border should, as suggested by Besnier, Morrow, and others, be extracted, which can be done by grasping the hairs between the fingers and exerting gentle traction, the loose hairs alone coming out, while those that are firm slip through the fingers. The remedial application should always be carried one-quarter or one-half inch beyond the patch. In extensive cases or with patients who can be seen only at intervals of one or two weeks, the most efficient local remedies are: ointments of tar and sulphur, weakened and of full strength; 5 to 15 per cent. β-naphthol ointments; the tar oils, either pure or with one or two parts of alcohol, or in ointment form, from 1 to 3 drams (4.–12.) to the ounce (32.); and stimulating lotions containing varying proportions of tincture of cantharides, tincture of capsicum, aqua ammoniæ, or oil of turpentine, such as prescribed in ordinary alopecia. Of these I have most frequently prescribed an ointment made up of both sulphur and naphthol: ℞. Sulphur. præcip., ʒj–ij (4.–8.); β-naphthol, gr. xxx–ʒj (2.–4.); lanolin, ʒij (8.); vaselin, q. s. ad ℥j (32.); and if the tar odor is unobjectionable, an oily application, composed of equal parts of oil of cade, oil of turpentine, and olive oil, lessening the turpentine if the skin is sensitive. In addition, at each inspection of the patient an area of one or two square inches can be treated by a strong application of carbolic acid, chrysarobin, or tincture of iodin containing 2 to 4 grains (0.135–0.25) of biniodid of mercury to the ounce (32.).

If there are but two or three areas, the stronger remedies can be regularly employed. Of these, I place most faith in an ointment of chrysarobin, 10 to 60 grains (0.65–4.) to the ounce (32.) of lard or vaselin, as recommended by Robinson; and painting over the areas with pure liquid carbolic acid, as suggested by Bulkley,[1] or a similar preparation, known as trikresol, recommended by MacGowan,[2] can be used. If in children or those of sensitive skin, the carbolic acid is weakened with 1 to 3 parts alcohol. It is to be painted over, and then gently but thoroughly rubbed in. There is, in some cases, considerable pain, which, however, as a rule, soon subsides. A good deal of irritation results, and the skin gradually exfoliates. An excellent method of applying chrysarobin is as a saturated solution in chloroform, and then over the film resulting, 2 or 3 coatings of collodion. If the chrysarobin ointment is used only occasionally, the strongest is to be employed—60 grains (4.) to the ounce (32.)—

[1] Bulkley, "A Therapeutic Note on Alopecia Areata," *Jour. Cutan. Dis.*, 1892, p. 47.

[2] MacGowan, "A New Agent for the Treatment of Alopecia Areata," *ibid.*, 1899, p. 217.

and well and energetically rubbed in. It is a remedy which requires some caution (see psoriasis). Another strong application which I have found useful is one consisting of equal parts of oil of turpentine, tincture of capsicum, and tincture of cantharides; it is to be employed with care, and often needs weakening with almond or olive oil.

In addition to these measures I now make use of the high-frequency current, both with the vacuum electrode and carbon-point, and apply it long enough to produce considerable reaction. The galvanic current can also be applied, with an electrode pressed upon the patch, and the current gradually increased by means of a rheostat up to several milliampères. Care must be used, however, with this current about the head, and the current increased cautiously and gradually withdrawn—never increasing or decreasing rapidly or breaking it; a rheostat and a milliampèremeter are necessities for its proper application. I have also seen good effects from the application of a static current by means of the pointed electrode, holding this at such distance as to get an extremely mild spark, and going over and over the area until decided redness is produced.

For alopecia areata of the bearded portions and the eyebrows, etc., the same applications as advised for the scalp can be employed, but, as a rule, not more than one-half to two-thirds as strong. Carbolic acid, if used, must be diluted with several parts of alcohol. The sulphur and tar applications are the most satisfactory, all things considered. One of precipitated sulphur, ʒij (8.), salicylic acid, gr. x–xxx (0.65–2.), vaselin, sufficient to make an ounce (32.), is also serviceable.

There are many other local stimulating and parasiticide applications which would probably be as effectual as those mentioned. Morrow, —adopting the plan practised by French observers, Besnier, Vidal, Brocq, and others,—in recent cases, is accustomed to employ chrysarobin, 40 to 50 grains (2.65–3.35), with or without 10 to 25 grains (0.65–1.65) of salicylic acid, in the ounce (32.) of liquor gutta-perchæ or lard; to be applied every three or four days in sufficient strength to excite and maintain a moderate dermatitis.

Hyde and Montgomery[1] give the following formula, the proportions of the various ingredients being varied according to the case and individual peculiarities: ℞. Ol. ricini, f℥ss (16.); acid. carbolic., ʒj (4.); tinct. cantharid., f℥ss (16.); ol. rosmarin., gtt. xv (1.); spts. vin. rectif., ad f℥iv (128.). Jackson[2] speaks well of a pomade of jaborandi made by boiling down the fluid extract to one-half its volume, and adding this to 4 parts of lard; this is to be rubbed in twice daily. He also recommends a lotion of corrosive sublimate, 1½ grains (0.1) to the ounce (32.) of water, not on account of its parasiticide qualities, but solely for its stimulating effect. Hardaway's[3] usual plan is to blister the patches every two weeks with acetic cantharidal collodion after thorough washing with soap and water, and

[1] Hyde and Montgomery, *Diseases of the Skin*, seventh edit., p. 583.

[2] G. T. Jackson, "Alopecia Areata: Its Etiology and Treatment," *New York Med. Jour.*, Feb. 20, 1886.

[3] Hardaway, *Manual of Skin Diseases*, second edit., 1898, p. 489.

in the intervals to rub in morning and evening a lotion consisting of equal parts of tincture of cantharides and glycerin; if there are several areas, and of large extent, the vesicant is applied to one or two places only at a time. Jamieson[1] states that of all the stimulants he has used, the one which has given him the most satisfactory results has been that originally suggested by Sir Erasmus Wilson: ℞. Liq. ammon. fort., chloroformi, ol. sesami, āā ʒss (16.); ol. limonum, ʒss (2.); spts. rosmarini, ad f ℥iv (128.). This is rubbed gently into the bald part at first once, and then, as tolerance becomes established, twice daily, and steadily persevered in. Sabouraud's plan is to blister the patches and then to paint the denuded surface with 5 to 6 per cent. solution of silver nitrate.

It will be noted that all the preparations in common use are those which possess both parasiticide and stimulating properties, and to these can be added lactic acid, with which Rietema,[2] Balzer and Stoianowitch[3] have recently had good results, using it with an equal part of water, and increasing the strength if no positive irritation is produced. Jersild,[4] of Finsen's institute, Copenhagen, has lately published his results from treatment by the concentrated light rays, and which he considered satisfactory; a daily exposure of an hour each, for a period varying from one to seven or eight weeks, being required. For this disease the light from the iron-electrode lamp would be sufficiently penetrating, and would require but several minutes' application to bring about a decided reaction. The X-ray has also advocates.

FOLLICULITIS DECALVANS.

In recent years cases have been reported,[5] chiefly by French writers, under the names folliculite épilante (Quinquaud),[6] folliculites et périfolliculites décalvantes agminées (Brocq),[7] alopécie cicatricielle innominée (Besnier), acné decalvante (Lailler[8] and Roberts[9]), lupoid sycosis (Milton, Brocq), ulerythema sycosiforme (Unna), which represent somewhat varied, but allied, conditions (Ducrey and Stanziale),[10]

[1] Jamieson, *Diseases of the Skin.*

[2] Rietema, "Rep. Netherlands Derm. So'cy," in *Brit. Jour. Derm.*, 1898, p. 268.

[3] Balzer and Stoianowitch, *Jour. des practiciens*, Feb. 11, 1899, p. 81.

[4] Jersild, "Quelques cas de pelade traités par les rayons chimiques concentrés," *Annales*, 1899, p. 20.

[5] I am indebted for some of the information in this article to Robinson's excellent résumé of the subject in Morrow's *System*, vol. iii., p. 873, and also to Hallopeau and Leredde's description, *Traité pratique de Dermatologie*, 1900, p. 391.

[6] Quinquaud, *Bull. de la Soc. Méd. des Hôp.*, 1888, p. 395; *Annales*, 1888, p. 657, and 1889, p. 99.

[7] Brocq, *Bull. de la de Méd. des Hôp.*, 1888, p. 400, and *Annales*, 1889, p. 467.

[8] Lailler, *Annales*, 1889, p. 100.

[9] Roberts, *Thèse de Paris*, 1889.

[10] Ducrey and Stanziale, *Giorn. ital.*, 1892, p. 239; abs. in *Annales*, 1893, p. 498 (8 personal cases and a review of the subject). In a recent valuable paper on alopecias with atrophy ("pseudo-pelade" variety) Brocq, Lenglet, and Ayrignac (*Annales*, 1905, pp. 1, 97, and 209) review and analyze reported cases (29) and 22 new cases (Brocq); about 80 per cent. of the cases were males, and only 1 case was observed in a child; syphilis had no etiologic relationship, but tuberculosis has been a somewhat frequent association; the infiltration was made up chiefly of lymphocytes, but plasma-cells, mast-cells, and eosinophiles were also found, and a number of pigment-cells in the papillary zone and corium was a constant finding; bacteriologic investigations have disclosed nothing definitely.

of which the chief symptom is follicular destruction with scarring. Ulerythema sycosiforme and lupoid sycosis will be found referred to under sycosis. The acné décalvante of Lailler and Roberts and Quinquaud's disease are the same affection. The various cases, not considered elsewhere, can be conveniently divided into two varieties, both doubtless the one disease, with differences in the degree of follicular inflammation.

In one—the variety especially described by Quinquaud (Quinquaud's disease) and which probably furnishes the most cases—the follicular inflammation, sycosiform in character, is a readily perceptible feature of the malady. The scalp, and more especially anteriorly, is its usual site, but it is also observed in the beard, and may even occur in the pubic and axillary regions. On examination the inflammatory lesion is noted to be a small papule, scarcely as large as a pin-head, or merely a red follicular elevation; or it is, as in the typical cases, distinctly a pustule, small, and, like the pustule in sycosis, usually without basal infiltration. These pustules dry to thin crusts. In some instances the lesion appears to be a mere pin-point- to pin-head-sized crusted abrasion. Whatever its character, the center is pierced by a hair, as in sycosis. This soon loosens, however, and falls out, and finally a minute cicatrix results. The lesions may be discrete and scattered, but commonly the adjoining follicles take on the same action, and gradually there presents the picture usually seen when the patient seeks advice: there is a central, dime- to silver-quarter-sized or larger, irregularly rounded, depressed, bald, cicatricial patch, white, and often glistening, usually smooth, and the peripheral portion studded here and there with the minute red follicular elevations, pustules, or crusted points. In this manner the malady advances, leaving destroyed follicles and cicatricial tissue. Occasionally some of the central follicles may have been missed, and the area thus shows one or two islets of hair centrally. The disease is generally extremely slow in its progress, and there may be periods of quiescence; and in some cases, after a time, the malady ends spontaneously, but this is not its ordinary course, for, as a rule, it is slowly progressive or appears at new points. As the follicles are destroyed there is no new hair growth; in fact, the destruction usually involves all the dermic tissues. In most instances there are no subjective symptoms—occasionally, in some cases, slight itching.

FIG. 217.—Folliculitis decalvans (courtesy of Dr. G. T. Jackson).

In the other variety of folliculitis decalvans, the pseudopelade of the French, the follicular inflammation is not so apparent, and the patch simulates alopecia areata. A slight rosy tint or faint redness, with a trifling amount of tumefaction surrounding the follicles, indicative of a mildly inflammatory action, is noted, and the hairs at the involved spot or point can be readily withdrawn, or, as in the other variety, drop out spontaneously. Robinson noted that the extracted hairs have a glossy sheath, which is thickened and extended. The malady may present but one or two spots, or it may be disseminated, and with small areas. The process leaves behind polished cicatricial, hairless areas, smooth and ivory-like. When an area has reached the size of a silver quarter, it usually presents the following appearance: On first sight it strongly suggests alopecia areata; it is observed to be white, smooth, glossy, with cicatricial thinning and obliteration of the follicular openings; depressed, especially centrally, and with, on close examination, a slightly raised, rose-tinted or pale-red, tumefied border, from which some of the hairs can usually be easily extracted; not infrequently there is a slight keratotic tendency in the follicular outlets of the border, and there is, if the part has not been recently washed, a faint suggestion of branny scaliness. The patch bears a slight resemblance also to lupus erythematosus, except that the cicatricial thickening usually observed in this latter affection on the scalp, the dull white color, and the characteristic border are wholly wanting. While the patches are sometimes well rounded, as in an instance recently observed by myself, they are often irregular, and spread by jutting out here and there. Quinquaud observed some cases in which the inflammatory characters were still less marked than here described, or almost entirely lacking, the sole symptoms consisting of falling of the hair, with disappearance of the pilosebaceous glands, and a resulting faintly cicatricial-looking plaque.

Etiology and Pathology.—The malady is rare. It is more common in males, and usually develops between the ages of thirty and forty years (Brocq). Dubreuilh's[1] 4 cases of the pseudopelade variety were women. The few patients under my own care were adult males and past thirty. The cases, for the most part, are found among the working-classes. Payne[2] has, however, recently described a rather markedly inflammatory and somewhat anomalous example in a young girl aged fourteen. Patients usually seem in good health, and it is difficult to assign a cause. Payne's case was the subject of hereditary syphilis. Fournier (quoted by Payne) also observed one similar instance. These 2 instances must, I believe, be considered exceptional, however, as the malady is scarcely suggestive of a syphilitic nature. Besnier believes that gastric, hepatic, and intestinal disturbances have an etiologic bearing. Quinquaud found various organisms, one of which he considered etiologic; animal inoculation experiments were partially, but not wholly, confirmatory of its causative relationship. His findings lack corroborative testimony, however, although there is scarcely a doubt that the disease is a parasitic one.

[1] Dubreuilh, "Des alopécies atrophiques," *Annales*, 1893, p. 329.
[2] Payne, *Brit. Jour. Derm.*, 1895, p. 101.

Histologically, according to this same observer, evidences of a mildly inflammatory process are disclosed; in the earliest stage of the lesion, consisting of a collection of young cells encompassing the hair-follicle, especially at its upper part; the same, but only to less marked extent, is observed about the sebaceous glands, and also in the immediately adjacent rete and corium. The subsidence of the inflammatory action is followed by atrophic changes in all the dermal parts, hair-follicles and sebaceous glands disappearing.

Diagnosis.—The diagnostic characters are the hairless, atrophic, or cicatricial spot or plaque and the bordering inflammatory follicular lesions; these serve to distinguish it from alopecia areata; and these with the other differences, already referred to, from lupus erythematosus.

Prognosis and Treatment.—The malady, as already indicated, is usually a persistent one, with little if any tendency to spontaneous cure. It is also rebellious to treatment, but proper measures are of benefit and may bring about a disappearance of the eruption. Constitutional treatment seems of questionable value, but both cod-liver oil and the hypophosphites with iron and arsenic may prove of benefit. Payne's case improved under potassium iodid and mercury.

The local treatment is essentially that of sycosis, a somewhat kindred affection. The surrounding hair should be clipped, that in the peripheral inflammatory lesions extracted (Pringle), and an advantage also accrues, I believe, from depilating the surrounding healthy follicles. A saturated solution of boric acid, with 3 to 20 grains (0.2–1.35) of resorcin to the ounce (32.), is of service in some cases, supplemented with a resorcin-salicylic acid salve: ℞. Ac. salicylici, gr. v–x (0.33–0.65); resorcin, gr. iij–x (0.2–0.65); ung. aquæ rosæ, ʒiv (16.). Painting on a salicylic acid collodion, 2 to 5 per cent. strength, also occasionally seems to act well. White precipitate, calomel, and sulphur ointments, from 10 to 60 grains (0.65–4.) to the ounce (32.) of vaselin, may also be tried. Hallopeau and Leredde recommend an ointment made up of 50 grains (3.) of β-naphthol, 24 grains (1.5) of salicylic acid, 5 drams (20.) of vaselin, and 2½ drams (10.) of talc. As some of the cases are easily irritated, a smaller quantity of naphthol would be advisable at first. The scalp or affected parts should be frequently washed with soap and water, preferably the tincture of green soap, and a mild antiseptic applied every day or so to the region generally.

SYCOSIS VULGARIS.

Synonyms.—Sycosis; Non-parasitic sycosis; Folliculitis barbæ; Acne mentagra; Mentagra; *Fr.*, Sycosis non-parasitaire; *Ger.*, Bartfinne.

Definition.—A chronic inflammatory affection of the hair-follicles of the bearded and mustache regions, due to microbic infection.

As the disease is now known to be microbic, the term non-parasitic, formerly used to distinguish it from parasitic sycosis or sycosis due to the ringworm fungus, is no longer applicable.

Symptoms.—The disease may involve only a part of the hairy

region of the face, as, for instance, a portion of the upper lip, especially just under the nasal orifices, or the entire mustache region; or it may be more or less limited to the chin or cover the bearded sides of the face; finally, in extensive cases, the whole surface covered by the mustache and beard may be involved, and in extreme instances even the eyebrows also are the seat of the lesions. In my experience the bearded part and the mustache have appeared of about equal frequency in being the sites of the eruption. The disease begins, as a rule, slowly, with the appearance of a variable number of small red papules or papulopustules or tubercles, the most of which, or all, soon become pustular; each lesion is pierced by a hair. The pustules are small, rounded, or acuminated and yellowish in color, with but little tendency to spontaneous rupture. Exceptionally they may remain for the most part papular. At first they may be quite discrete, later, from the accession of the new lesions, the affected part becomes quite crowded, and the inflammation is then usually confluent, with some infiltration and swelling, and beset with the numerous, small, projecting lesions. At first the hairs remain firmly seated, but in most cases in the follicles which

FIG. 218.—Sycosis vulgaris of moderate development, involving chin and to a slight extent upper lip.

undergo more pronounced suppurative action, they loosen and can be readily extracted; and some follicles may suffer complete destruction. As a rule, however, in spite of the rather violent aspect of the disease, but comparatively few hairs are lost, and positive scarring rarely results. When so closely aggregated that it practically amounts to

coalescence, a portion or the entire region may become crusted, under which there may be a slight tendency to fungate. There is often a good deal of infiltration and thickening, and the parts are of a bright or dark-red color, depending upon the type of inflammatory action. There is, however, no distinct lumpiness or large cutaneous swellings as in tinea sycosis (ringworm sycosis).

The lesions in some cases, for a time at least, may remain more or less discrete, and the area of disease may be limited to two or three small patches; in most instances, however, new lesions arise, form new aggregations, and, by still further accessions, the areas become confluent and a large region is involved. The disease may remain somewhat limited, or it may go slowly from worse to worse, involving more and more of the hairy parts. While it is essentially chronic, the inflammatory action being of a subacute or sluggish character, with sometimes slight remissions, there are often acute exacerbations.

The subjective symptoms are rarely marked or troublesome: there may be a variable degree of pain and itching and a sense of burning.

FIG. 219.—Sycosis vulgaris, of several years' duration; involving the entire bearded region.

In rare instances the disease is limited to the outer portions of the bearded region, beginning with all the appearances of an ordinary case; as the process advances it leaves behind a smooth, furrowed, or keloidal scar, total destruction of the hair-follicles and permanent loss of hair. It usually advances in one direction, and, as a rule, with a slightly infiltrated border. This variety or aberrant form has variously been considered a distinct affection, called lupoid sycosis (Milton),

sycosis lupoïde (Brocq), and, finally, and more fully described by Unna,[1] under the name **ulerythema sycosiforme.**

While sycosis is a disease of the bearded and mustache regions, and is so understood when the term is used, in exceptional instances other hairy parts of the body are the seat of similar follicular eruption, which stops short at the hairy borders; when such occurs, it is, as a rule, in connection with eczematous eruption elsewhere.

Etiology.—The essential factor of sycosis is microbic; as Bockhart[2] has demonstrated, the pyogenic cocci (staphylococcus aureus and albus) are the usual causative agents, and hence the name suggested, *sycosis staphylogenes.* In one instance, presenting the symptoms of ordinary sycosis, Tommasoli[3] found that instead of the usual micro-organisms, a bacillus was the morbific agent, and he succeeded, with pure cultures, experimentally in proving this on himself and rabbits; this discovery led to the variety designation *sycosis bacillogenes.*

Accepting the microbic origin, it should be, and indeed probably is, somewhat, though feebly, contagious, although it has never been generally so considered. I have occasionally met with instances in which the barber-shop has apparently been the starting-point, and Brooke[4] and others have given evidence of its contagious character. The disease is, as to be inferred, met with in males only, and usually in those between the ages of twenty and fifty. It is not frequent. It is observed in all walks of life, but is more common among the poor, and especially in those whose health is impaired. In many cases, it is true, the patients seem in good condition. Any constitutional disturbance, such as gout, rheumatism, dyspepsia, etc., may be of contributory influence.

Local irritation is sometimes of etiologic importance. On the upper lip, especially the subnasal region, it is often due to the secretion from a nasal catarrh. Seborrhea is also at times a factor, and occasionally the disease is observed to follow an eczema of the face. Shaving has been suggested as a factor, but inasmuch as this procedure is often a necessary part in the cure of the malady, it can scarcely be considered etiologic. Jackson[5] has observed that those whose occupation is in close dusty rooms, and those in a poor condition of health, furnish the largest number of cases. The disease has its seat essentially upon the bearded and mustache regions, but occasionally the eyebrows share in the eruption. I have met with one instance in which the scalp and hair-follicles of the forearms and dorsal surfaces of the fingers were all involved, presenting the exact symptomatology of the disease as observed on its usual site—follicular, and stopping at the edge of the hairy skin; this was typically shown on the backs of the hands and fingers, intervening hairless parts being entirely free. The cause of ulerythema sycosiforme is not known—probably an ordinary sycosis with an added infective factor.

[1] Unna, "Ueber Ulerythema sycosiforme," *Monatshefte*, vol. ix., 1889, p. 134.

[2] Bockhart, "Ueber die Aetiologie und Therapie der Impetigo, des Furunkels, und der Sycosis," *ibid.*, vol. vi., 1887, p. 450.

[3] Tommasoli, "Ueber bacillogene Sykosis," *ibid.*, vol. viii., 1889, p. 483.

[4] Brooke, "The Contagious Nature of Sycosis," *Brit. Jour. Derm.*, 1889, p. 467.

[5] Jackson, "Sycosis: A Clinical Study," *Jour. Cutan. Dis.*, 1889, p. 13.

Pathology.—The micro-organisms gaining access give rise to the inflammatory changes and the clinical manifestations. It can be readily understood how the process, starting at one point, can soon involve neighboring follicles by continuous and repeated inoculation. Tommasoli's findings indicate that there may be other organisms than the usual pyogenic cocci. The pathology and pathologic anatomy have been especially studied by Wertheim,[1] Robinson,[2] and Unna,[3] whose conclusions, while at variance in minute details, are, in their essential characters, the same. The disease is primarily a perifolliculitis, the follicles and their sheath becoming rapidly involved secondarily in the inflammatory process. The changes are such as are ordinarily observed in vascular tissue inflammation resulting from these organisms. The hair-papilla is, as a rule, not destroyed, so that hair loss, except in very chronic and markedly suppurative cases, does not commonly occur. The resulting pus escapes at the hair-follicle opening, or through the epidermis immediately adjacent. Cocci are usually to be seen in abundance. As Wertheim states, each follicle really becomes a minute abscess. In ulerythema sycosiforme the hair-follicles and hair-papillæ, the glandular structures, and the connective tissue are destroyed and give place to scar tissue.

Diagnosis.—The disease is to be differentiated from eczema, which it sometimes resembles, and with which, by some authors, it is thought to be identical. Eczema rarely stops at the border of the hairy region, and the lesions are, with some exceptions, not pierced by hairs; eczema is apt to involve the entire skin of the affected area, the follicular implication being secondary: sycosis involves the follicles primarily, and only later, when closely aggregated, does the inflammation present a diffused character. When the latter is present and the parts are crusted, it is usually necessary to remove the crusts and sometimes allow a few days to intervene before the case is clear; but in sycosis the follicular involvement becomes again perceptible. Eczema itches, usually intensely: sycosis rarely does to any degree. A history of chronicity, with no tendency to overstep the border-line, and with but little variability, would point to sycosis.

Tinea sycosis can scarcely be confounded in average or severe cases; it begins usually as one or several rings, and continues so, with breaking of the hair, and often their easy extraction; or it begins in this manner, or as several lumpy nodules, and rapidly invades the subcutaneous tissues, and then presents large, nodular swellings, on which the hair may be broken, fall out, or can be readily extracted. Such conditions are entirely different from the beginning and behavior of sycosis. In obscure cases the microscope would decide (see ringworm).

In acne the evident involvement of the sebaceous glands, the scattered lesions, as a rule over the face, evolution, and course, with usually the presence of blackheads, will prevent its being mistaken for sycosis.

Only carelessness could lead to confusion with a syphilitic eruption; early eruptions of syphilis are generalized, with other corrobo-

[1] Wertheim, *Wiener med. Jahrb.*, 1861, ii., p. 87.
[2] Robinson, *N. Y. Med. Jour.*, Aug. and Sept., 1877, and *Manual of Dermatology.*
[3] Unna, *Histopathology.*

rative symptoms, and late syphilodermata are limited, and usually serpiginous or segmental in outline.

Prognosis.—The disease is obstinate and persistent, with no tendency to spontaneous disappearance. The duration, extent, and character of the inflammatory process must all be considered. Under proper treatment, however, recovery takes place, in moderately developed cases, sometimes within two or three months, but frequently longer. In extensive involvement the duration of treatment may be but several months in favorable cases, but this cannot be expected in most instances—it is usually six months to a year. An opinion as to the time required in a given case should always be guarded. A good deal depends upon the patient's care and perseverance in carrying out the treatment. The disease often shows a tendency to recurrence. The hair should not be allowed to grow for months after apparent cure, shaving being persistently practised, experience teaching that this tends to prevent relapses.

Ulerythema sycosiforme is extremely rebellious—much more so than the ordinary sycosis.

Treatment.—The plan of treatment in most instances consists of external means alone. The state of the general health should, however, be inquired into, and proper treatment instituted to bring it up to a normal standard. In some cases there is an underlying constitutional debility, which, unless corrected, seems to add to the obstinacy of the disease; in such cases cod-liver oil is an admirable remedy, the administration of which not infrequently quite perceptibly aids in obtaining a result from local measures. Such tonics as iron, quinin, and manganese will at times also apparently have a favorable influence. Arsenic may be given for its tonic effect, but it has no specific action. A special value has been claimed for calx sulphurata, given in doses of from $\frac{1}{10}$ to $\frac{1}{4}$ grain (0.0065–0.016) three or four times daily, but my experience with this drug has not been especially favorable. Sodium salicylate in underlying rheumatic state and stomachic and digestive tonics in dyspeptic cases will be of service. Alcoholic drinks, indigestible foods, tobacco, excessive coffee- or tea-drinking, and indulging in the many "bromo" compounds now so common—all have a damaging tendency. The bowels should always be kept free. Nasal catarrh, if present, should receive attention. The influence of hygienic living and open-air life and exercise is, without doubt, of value from a therapeutic standpoint. In extremely obstinate extensive cases Wright's plan of opsonic treatment (see Opsonins, p. 108) might finally be cautiously tried.

In the external treatment the first steps are to clip the hair short, free the parts from crusting, if present, and reduce the inflammatory action. If necessary, the crusts can be removed with starch poultices, but, as a rule, frequent bathing with warm water and soap and the application of plain petrolatum or cold cream will accomplish this end in a day or two. Then mild soothing applications are to be made for a few days until the activity of the inflammatory process is somewhat allayed. This may be accomplished by means of applications of an ointment of zinc oxid, of salicylated paste, or, in fact, by means of any of the other mild ointments or lotions mentioned in the treatment of acute eczema. As soon as the inflammatory action has been les-

sened, and, in fact, in almost all cases from the very beginning, shaving every day or every second day should be insisted upon as an essential part of the treatment. This will not be without pain at first, which is by no means unbearable, but after the first two or three shavings the operation is not especially painful. It materially aids in rendering the treatment effective and in shortening the time required for a cure, and this the patient soon recognizes himself. I value this so highly that I should decline to treat a case unless this measure were acceded to. When the follicular inflammation is of a markedly pustular character, and especially if the hair shows a tendency to loosen, depilation may be practised; this tends to prevent the permanent destruction of the follicles. As a routine procedure for the whole diseased area, however, depilation is, in my experience, too painful a practice to take the place of shaving, and I do not believe of greater therapeutic value.

In the management of the external treatment of sycosis it is to be kept in mind that as patients are often obliged to keep to their business, the applications for the day-time should be scanty in quantity, or such as do not conspicuously disfigure. The essential part of the treatment consists in application of antiseptic ointments and lotions. In recent and slight cases the applications to be described will usually be effective; in extensive, long-continued, and obstinate cases, these can also be used, but are to be supplemented by the Röntgen-ray treatment. The former will be referred to first. Ordinarily, the plan of making a slight application in the morning and applying the ointment spread upon linen or lint as a plaster at night may be adopted; in the milder case the night applications may also consist of simple anointing. In mild and sluggish types the ointment, more especially at night, is to be gently, but firmly, rubbed in. When lotions and ointments are used conjointly, the wash is first dabbed on for a few minutes, allowed to dry, and then the salve is applied. The parts should be washed once daily with soap and warm or hot water, in irritable cases using a mild toilet-soap, and in sluggish and obstinate types occasionally using sapo viridis or the tincture of sapo viridis. There is no set guide as to the choice of a remedy among those commonly employed; as a rule, in markedly inflammatory cases the use of a saturated boric acid solution or a mild resorcin lotion, 0.2 to 1 per cent. strength, followed by a soothing ointment, such as the boric acid ointment or diachylon ointment, will be most likely to be well borne. Later other remedies will usually be demanded. Often enough one remedy will fail absolutely to influence the disease favorably, or it may benefit for the first week or two, and then cease to have any favorable effect; in either event the remedy is then to be set aside and another tried; later a change back to an application which had previously benefited can sometimes advantageously be made.

Although occasionally one of the stronger remedies, such as a strong sulphur ointment, can be used at the start, it is advisable, except in the very sluggish cases, to begin with mild treatment, such as just mentioned. A very weak sulphur ointment, 2 to 5 per cent., is, however, a safe beginning application. Or mercury oleate can be

used, and is often of decided benefit, prescribed as an ointment of from 20 grains to 1 or 2 drams (1.3–8.) to the ounce (32.) of ointment base, of equal parts of cold cream and simple cerate, or, if the quantity of the oleate is large, with all cerate. Resorcin is commonly used as a lotion conjointly with a mild salve, as already mentioned, although it may likewise be employed in the form of an ointment. The strength of the lotion in chronic and sluggish cases should be from 1 to 10 per cent.; of the ointment, from 5 to 10 per cent.

One of the most valuable external remedies is precipitated sulphur, employed as an ointment in the strength of from 20 grains to 2 drams (1.3–8.) to the ounce (32.) of petrolatum or cold cream; in the form of a lotion, the Vleminckx's solution applied diluted with from 5 to 15 parts of water and supplemented with a mild sulphur or a boric acid salve or cold cream deserves mention. Owing to its odor, this lotion is not a pleasant remedy, and should be used only when other treatment has proved unsuccessful. Hays[1] has also found it of service. A compound ointment as follows has been especially useful in some cases:

℞. Sulphuris præcipitati,	ʒj (4.);
Balsami Peruvianæ,	ʒj (4.);
Unguenti diachyli,	℥vj (24.).

It should be made up fresh every week or so, as the color becomes gradually darker and the ointment less efficient from chemical change.

Ichthyol is another valuable remedy in the treatment of sycosis, employed usually as an ointment in the strength of from ½ dram to 2 drams (2.–8.) to the ounce (32.) of petrolatum, cold cream, or simple cerate. In weakest proportion it is also a safe application for the beginning treatment. It may also, conjointly with an ointment, be employed as an aqueous solution in from 2 to 10 per cent. strength. It may likewise be used in an ointment of sulphur, with advantage, as follows: ℞. Sulphuris præcipitati, ʒss–iss (2.–6.); ichthyol, ʒj–iss (4.–6.); petrolati, q. s. ad ℥j (32.). Ehrmann warmly advocates the treatment of this disease with a 10 per cent. solution of pyoktanin, introduced into the diseased follicles by catophoresis—the positive electrode, soaked in this solution, is applied to the part, and the cathode held in the hand.

The Röntgen-ray treatment is an exceedingly important addition to our means of treating this obstinate disease, and should be resorted to in persistent, extensive, and obstinate cases. The parts other than those to be treated should be properly protected with lead foil. The first exposure should be at 10 inches distance, with a soft to medium tube, and for not more than 5 minutes' duration. The exposures should be at 2 or 3 days' intervals. It is ordinarily necessary to produce a mild erythematous reaction, and in order to do this the exposures can be gradually and cautiously lengthened, and the distance shortened. Usually after 10 to 12 exposures the hairs fall out, and the disease and the X-ray reaction, in the course of several weeks, will have disappeared. The hairs, after some months, reappear. It need not be added that the use of so potent an agent as the X-ray requires caution.

3. DISEASES OF THE SEBACEOUS GLANDS.

SEBORRHEA.

Synonyms.—Steatorrhea; Stearrhea; Acne sebacea; Ichthyosis sebacea; *Fr.*, Acné sebacée; Séborrhée; *Ger.*, Schmeerfluss; Gneis.

Definition.—A functional disease of the fat-producing glands, characterized by an excessive, and perhaps abnormal, secretion of fatty matter, appearing on the skin as an oily coating, crusts, or scales.

Since the writings of Unna and others on seborrheic eczema, which have led to a withdrawal of many cases (see eczema seborrhoicum) heretofore considered to be rightly placed under seborrhea, there is much confusion as to exactly what conditions are to be properly included in this disease. Oily seborrhea, of course, belongs here, and I believe also all those cases of fatty crusted or scaly conditions which lack all signs of inflammatory action. The division line is, however, an ill-defined one, and there is a growing belief that all cases except those of oily seborrhea show histologically evidences of inflammation.

Symptoms.—Two varieties of seborrhea are usually found, designated, according to whether there is practically only oiliness or oiliness with scale or crust accumulation; the former is that known as seborrhœa oleosa, and the latter, seborrhœa sicca. The qualifying term "sicca," or dry, in my judgment is in the present state of our knowledge an improper one, as those cases in which the accumulation is truly dry—not oily or fatty—are necessarily relegated to eczema seborrhoicum. The term, as here employed, will not refer therefore to such types, but essentially to those in which there is marked or moderate oiliness, with scale accumulation or crusting added, and in which there are no inflammatory symptoms. Such cases, I believe, exist, although, compared to those belonging to seborrheic eczema, in relatively moderate number.

Seborrhœa oleosa (known also as hyperidrosis oleosa (Unna, Brocq), acné sebacée fluente, stearrhœa simplex, seborrhœa simplex, etc.) is observed upon the scalp and face, usually conjointly, although it may be relatively extremely slight in some cases on one or the other of these regions. On the scalp the hair and skin are noted to be oily and greasy; the oiliness may be slight or quite perceptible, and may involve the whole region, or be mainly upon the vertex portion. The hair looks moist, sometimes glistening, and is often slightly sticky, stringy, or with a tendency, in women, to form into uncouth-looking, slightly agglutinated locks; or there is a tendency to bunching or massing together. The skin is oily to the touch, pale, often leaden-looking, and sometimes with, apparently at least, rather patulous gland-ducts. There are no inflammatory symptoms, except in occasional cases when there may be here and there slight hyperemia, patchy in character. Itching is rarely complained of in the oily variety. If of long continuance, there is very often a tendency to hair loss, and in some instances finally of a more or less pronounced character.

On the face, the favorite site for the oiliness is the nose and its immediate neighborhood; not infrequently, however, the forehead is also involved, and occasionally other parts of the face. In fact, in all cases there is, as a rule, a slight oiliness of these several regions, or the entire face, but it may be conspicuously so only on one or two of the regions named. The skin is shiny, glistening, and the gland-ducts often patulous, and the whole face presents a pasty-looking, soiled aspect. Not infrequently the nose is somewhat congested, and usually of a sluggish red tint. In addition, in some patients, comedones and scattered acne lesions are to be seen, and in occasional instances there is a disposition shown here and there, more especially on the scalp, for the secretion to dry and cake, forming thin scaliness of dirty-gray or brownish-gray color. If in women, the malady seems to be often associated with a tendency to hypertrichosis.

Seborrhœa Sicca.—In infants it is at birth more or less general, though variable in quantity, and constitutes the so-called vernix caseosa (also ichthyosis sebacea). It is apt to remain caked on the scalp for some months, and while it must be looked upon as physiologic, not infrequently from irritation produced by decomposition, or from harsh attempts to remove it, an eczema may ensue. In children and adults its usual site is the scalp. In this form, in addition to more or less oiliness, the fatty secretion and the exfoliating epidermic scales, and some possibly from the lining membranes of the gland-ducts, tend to accumulate in an irregular, thin, or somewhat thick, soft, unctuous, waxy-looking, gray or brownish coating. There is usually a variable amount of itching. The skin beneath the crusts is not hyperemic, but of the usual color, or somewhat paler than normal, with, in some cases, a tendency here and there to slight redness and development into eczema seborrhoicum. The gland-ducts are often somewhat stuffed with semisolid fatty matter. The hair is greasy and oily, sometimes massed or bunched, and practically in the same condition as noted in seborrhœa oleosa. In the crusted seborrhea there is a more decided disposition to falling of the hair and consequent alopecia. The disease varies in degree. It may be slight, with a variable amount of oiliness, and small fatty scale or crust specks or small filmy fragments, which are found on the scalp, scattered through the hair, and sometimes falling upon the shoulders. This latter illustrates one variety of the condition known as dandruff—of the oily or greasy form, in contradistinction to the dry variety, pityriasis capitis (one form of eczema seborrhoicum).

A mild degree of crusted or scaly seborrhea is sometimes seen upon the face, occasionally alone, but more commonly in conjunction with the disease upon the scalp; its usual site is about the nose, and sometimes on the bearded region. As a rule, most cases of a greasy, scaly nature about these parts present a slightly or moderately inflammatory basis, and belong to the domain of eczema seborrhoicum. The surface is noted to be oily, and variously coated with a pasty, dried, greasy film, or a thin, cheesy coating, and, especially about the nose, sometimes with dippings down into the glandular openings.

Rarely a similar, apparently non-inflammatory, condition is noted

on the chest, usually over the sternum and between the scapulæ, and is generally of irregular patchy or circinate formation, with projections into the follicles. As a rule, however, an inflammatory element is added in these cases, and the picture is then that of eczema seborrhoicum.

Crusted seborrhea is also sometimes seen upon the glans and corona of the penis, beneath the prepuce, where the secretion is usually relatively active, and if permitted to collect, forms a flaky, irregular, thin, cheesy coating, which undergoes decomposition, and causes more or less irritation or a positive balanitis. The same condition may arise in women, about the clitoris and vulvar folds, unless the parts are frequently cleansed, and a vulvitis results. Occasionally the pubic region, like the scalp and other hairy parts, is the seat of a flaky or thin greasy coating, conjointly with oiliness.

Etiology.—Exclusive of the seborrheic condition in the newborn and early infantile life, the malady is most frequent between the ages of fifteen and thirty, when the glandular structures are usually most active, although it is not uncommon, especially in women, toward the climacteric. It is met with in both sexes, and with, upon the whole, but little preponderance either one way or the other. Those of dark hair and complexion are the usual subjects for the oily variety. General debility, anemia, chlorosis, dyspepsia, and similar disorders are to be variously looked upon as contributory, if not causative. The disease is also noted to develop after severe constitutional diseases, especially after the various exanthemata. Scrofulosis must also be considered as furnishing a good basis for its production. Seborrhea of the nose is apparently due in some cases to intranasal pressure or obstruction (Seiler, Besnier, Doyon, and others). In some instances, it is true, the disease seems to be due to a loss of tone in the glands and skin, and to be entirely independent of any constitutional or predisposing condition. The view advanced in recent years, that the disease is of parasitic nature and contagious (Unna, Sabouraud, and others), has been steadily gaining ground, and its occurrence in several or more members in certain families bears as much upon the question of contagiousness as it does upon hereditary or family tendency.

Pathology.—Seborrhea, as observed in the types just described, is to be considered as a disease, chiefly and probably wholly of the sebaceous glands, and functional in character. Unna and Meissner would have us believe that the coil-glands (sweat-glands) secrete the oil, and that (Unna) the sebaceous glands are not involved in this malady, except secondarily. Unna, therefore, suggests for the oily form the name hyperidrosis oleosa, but Beatty's[1] investigations go to show that at least in the oily form and the vernix caseosa the secretion is not a product of the sweat-glands. While it is, I believe, true that secretion from the sweat-glands does contain oil, at times, at least, nevertheless, one needs but examine a case of seborrhea of the types here defined and the exit from the sebaceous gland-ducts of fatty secretion is at once evident. Moreover, its favorite situations are those

[1] Beatty, "Seborrhea," *Brit. Jour. Derm.*, 1894, p. 161; also "The Functions of the Glands of the Skin," *ibid.*, 1893, p. 97 (both valuable contributions).

where the sebaceous glands are most numerous and most highly developed. Sabouraud[1] does not state it too strongly when he says that seborrhea has two essential symptoms—an overproduction of normal sebum and a dilatation of the sebaceous gland-duct openings.

The oily secretion and the fatty collection found in the gland-ducts and also that upon the surface are chiefly composed of fatty matter, although Elliot[2] found that the plugs in the ducts were composed of epidermic cells, derived from the epidermic lining of the follicular opening, impregnated with fatty hypersecretion. Van Harlingen,[3] who made some careful investigations, concludes that: "(1) The sebaceous secretion is derived from fatty metamorphosis of the enchyma cells of the sebaceous glands. These cells are homologous with those of the stratum mucosum of the skin. They have nothing in common with the cells of the horny layer. (2) Seborrhea is a disease of the sebaceous glands, characterized by the pouring-out of an increased quantity of sebum, more or less altered in chemical and physical composition. In comedo and seborrhœa sicca properly so called, the secretion is condensed to a fatty consistency, while in seborrhœa oleosa it remains in an oily state. In each of these affections, however, microscopic examination shows epithelial cells in a state of more or less complete fatty degeneration, and breaking down into granular débris. Horny cells are found only adventitiously."

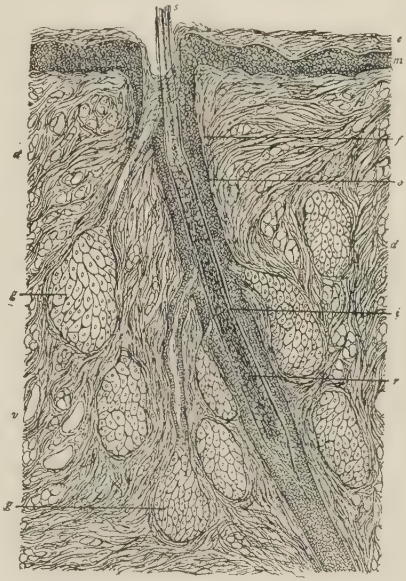

FIG. 220.—Vertical section through the scalp of a new-born child suffering from seborrhœa neonatorum (× 250): *e*, Corneous layer; *m*, rete mucosum; *s*, shaft of hair; *r*, root of hair, cut obliquely; *i*, inner root-sheath; *o*, outer root-sheath; *f*, hair-follicle; *g*, *g*, enlarged sebaceous glands, with ducts; *d*, *d*, corium; *v*, veins in the corium (courtesy of Dr. L. Heitzmann).

Sabouraud believes that seborrhea is due to a short microbacillus. It is always to be found in the upper part of the hair-follicle, and a seborrheic cocoon which develops, containing the bacillary colony, by interfering with the function of the hair-papillæ, gives rise to the secondary hair loss and sometimes permanent alopecia. Further evidence is, however, needed before Sabouraud's conclusions can be admitted. Schamberg[4] found this bacillus in

[1] Sabouraud, *Annales de l'Institut Pasteur*, 1897, p. 134; and *Annales*, 1897, p. 257.

[2] Elliot, Morrow's *System*, vol. iii. (Dermatology), p. 789.

[3] Van Harlingen, "The Pathology of Seborrhea," *Arch. Derm.*, 1878, p. 97.

[4] Schamberg, "Remarks on the Microbacillus of Seborrhea," *Jour. Cutan. Dis.*, 1902, p. 99.

individuals who presented no trace of seborrhea. As the observations of Unna, Sabouraud, Brooke,[1] and others show, the seborrheic process often has an influence in materially influencing other cutaneous eruptions, notably eczema, acne, acne rosacea, syphilis, psoriasis, etc.

Diagnosis.—Oily seborrhea can scarcely be mistaken for any other disease; the oily, greasy character and appearances and the region involved are sufficiently distinctive. The crusted, scaly form is to be differentiated from eczema, eczema seborrhoicum, psoriasis, and possibly ringworm. The rather diffused character of seborrhea, the greasy, oily nature of the scaliness or crusts, the absence of all inflammatory symptoms, the usually dilated gland-ducts, containing sebaceous matter, are points of difference from those of the several diseases named; moreover, in these latter there are noted, except in eczema, rather sharp definition to the areas and inflammatory action. In eczema the inflammatory character is sufficient to prevent error. It is true, however, that the step from seborrhea to eczema seborrhoicum is often a short one.

Prognosis and Treatment.—The prognosis of seborrhea is favorable, although it must be said that the disorder is sometimes obstinate, and that there is a strong disposition to recurrence. In moderately severe and in severe cases of seborrhea of the scalp, of protracted duration, loss of hair is not an unusual sequence, although in most cases, if not too long neglected, a regrowth may be looked for.

In some instances of seborrhea local treatment alone is required; in most cases, however, the general condition is below the normal standard; constitutional remedies are to be administered according to indications. Chlorosis, anemia, and digestive disturbances certainly seem to have a strong predisposing influence, if not directly causative; and a removal of any of these several conditions will often have a favorable action upon the disease, or make it more promptly responsive to suitable local measures. Iron, strychnin, quinin, cod-liver oil, digestives, and laxatives are, therefore, to be prescribed according to the indications in the individual case. Arsenic may be tried in rebellious cases; and ichthyol (the ammonio-sulphate), in doses of 5 to 15 grains (0.3–1.) three times daily, is highly praised by Elliot for the oily variety. Duhring thinks well of calcium sulphid, $\frac{1}{5}$ or $\frac{1}{4}$ of a grain (0.013–0.016) three or four times daily. In instances in which the disease is practically limited to the nose, the possibility of intranasal pressure or obstruction should be eliminated, or, if present, appropriate treatment recommended.

In the management of seborrhea frequent washing with soap and water is usually necessary, in order that the parts can be kept free from the oiliness or crusting, and for this purpose a mild toilet soap can be used, or in those of sluggish, non-irritable skin the tincture of

[1] Brooke, "The Relations of the Seborrheic Processes to Some Other Affections of the Skin," *Brit. Jour. Derm.*, 1889, p. 247; see also literature reference to Sabouraud's papers in connection with acne; also paper by W. Anderson, "On Seborrhea and its Results," *ibid.*, 1900, p. 276; and by R. W. Taylor, "The Seborrheic Process and the Early Syphilitic Eruptions," *Jour. Cutan. Dis.*, 1890, p. 161 (with 2 good cuts).

green soap. In obstinate scalp cases to the latter can be added 10 to 30 grains (0.65–2.) of resorcin to the ounce (32.). The frequency of the washing depends upon the severity of the disease and the character of the remedies employed; if the oil or fatty accumulation is rapid, once every two or three days would be required for the scalp and once daily for the face. In fact, the face requires such washing as a routine measure once daily, and preferably at bed-time and before the application of the selected remedy. When salves are employed, a certain amount of added messiness results, especially upon the scalp, and cleansing becomes more frequently necessary. After the disease becomes less active, the scalp can be washed every three to ten days; as a rule, however, frequent shampooing, conjoined with remedial applications once or twice daily, is often necessary in the scalp cases, especially those of the markedly oily variety. As the condition improves treatment can be less frequent and gradually intermitted, or applications made at intervals of several days. In the removal of the greasy collection in infants care is to be taken that the skin be not irritated, for it is an easy matter in these cases to start up eczema; strong soaps should not be used, and if the crusting is adherent, as it often is on the scalp, it can be softened by oil applications, or, if persistent, with starch poultices (see eczema seborrhoicum).

The chief remedies to be employed in the external treatment of seborrhea are resorcin, sulphur, ammoniated mercury, salicylic acid, and boric acid. Resorcin is the most valuable, and is prescribed more frequently and satisfactorily as a lotion, 1 to 10 per cent. strength, made up with 1 part alcohol and 3 to 6 parts water, or in some cases, especially on the scalp, the pure alcoholic solution seems best. If too drying, glycerin can be added to the aqueous lotion, and castor oil to the alcoholic one—a few minims to the ounce (32.). In those of very light or gray hair, if used, it should be carefully and in scanty quantity; if used freely, the hair becomes wet with it and there often results a dirty or dingy-looking staining. Resorcin may also be used in ointment form, made up with vaselin or cold cream, of about the proportion of 20 to 60 grains (1.3–4.) to the ounce (32.). Both as a lotion and ointment the weaker strength should be tried first, and then the proportion increased—for occasionally this drug is found to act as an irritant. Sulphur is applied in but one form to the disease as it occurs upon the scalp—as an ointment, from ½ dram to 2 drams (2.–8.) of precipitated sulphur to the ounce (32.) of petrolatum or benzoated lard. Ammoniated mercury, in a strength of from 20 to 60 grains (1.3–4.) to the ounce (32.) of ointment, is likewise a valuable application—upon the whole probably less generally useful than the sulphur ointment, but colorless and more elegant. Salicylic acid may also be employed alone in the form of an ointment, from 10 to 30 grains (0.65–2.) to the ounce (32.), but it is more frequently employed with sulphur or ammoniated mercury in compound ointments.

As a rule, the lotions are much more efficacious for the oily form than are ointments, and probably also in the crusted variety, but in

the latter, when scale accumulation is at all rapid, ointments are often demanded, and, indeed, in some instances, act more satisfactorily. A good plan in these cases is to use a lotion up to within a day or two of the time for shampooing, and then to employ a pomade, resuming the lotion after the shampoo. Upon the whole, petrolatum is a good base for the scalp, and often somewhat improved by 1 or 2 drams (4.–8.) of cacao-butter to the ounce (32.); for the face, cold cream can take the place of the petrolatum. In addition to the lotions already named which may be used for the disease upon the face, the sulphur lotions employed in acne are also of service in some instances; they are to be tried in weak proportion at first, as this remedy sometimes irritates in these cases. Carbolic acid as a lotion is also useful in seborrhea of the scalp, but has the disadvantage of odor; it can be prescribed in 1 to 3 per cent. strength, preferably in alcohol, and to which, if found too drying, a few minims of castor oil can be added. A lotion of corrosive sublimate is also sometimes of service, both for scalp and face cases, and of either variety; it may be used in the strength of 1 or 2 parts to 1000, and either alone or with the resorcin lotion as a base.

In the treatment of the disease about the glans penis and vulva frequent ablutions—twice daily at least—should be enjoined. The milder lotions of boric acid and resorcin have special application on these parts. Also weak lotions of zinc sulphate and tannic acid; of the former, 1 to 3 or more grains (0.065–0.2) to the ounce (32.), or of the latter, a saturated solution. A compound lotion, using the boric acid solution as a basis, with the zinc sulphate added, and if there are any abrasions, with the addition of 10 or 15 grains (0.65–1.) of finely powdered zinc oxid or bismuth subnitrate to the ounce (32.), often acts satisfactorily.

ASTEATOSIS.

Synonyms.—Asteatodes; Xerosis; Asperitudo epidermidis; *Fr.*, Astéatose; *Ger.*, Asteatose.

Asteatosis is the opposite of seborrhea, and is characterized, therefore, by a diminution in the amount of sebum secreted by the skin. It can, however, scarcely be called a disease, idiopathic cases being scarcely, if at all, known; but it is a condition which is associated with or secondary to several cutaneous maladies, such as ichthyosis, prurigo, pityriasis rubra pilaris, scleroderma, dermatitis exfoliativa, long-continued scaly eczema, etc. It is also seen in old age, as a part of senile changes in the skin. It is sometimes observed as a local affection due to the use of agents which deprive the skin of the fat secretion, as on the hands and forearms of laundresses, who are obliged to keep these parts more or less constantly in strong alkaline solutions, or who use strong soaps. In such instances, while presenting the ordinary dry, harsh, sometimes slightly desquamating skin which characterizes the affection, the condition is not, in reality, due to a diminution of the sebaceous secretion, but to its repeated removal. It is more than probable, in those naturally having unpleas-

antly dry skin, that the dryness is owing to lessening of the secretion of both sebaceous and sweat-glands.

The **treatment** depends primarily, when possible, on the removal or modification of the etiologic factor,—either a disease such as mentioned or the use of strong alkalies or soaps,—and in supplying to the skin that fat or oil which it needs, by the continuous or intermittent application of some bland oil, such as olive, linseed, or almond oil or liquid petrolatum; or plain ointments are sometimes more satisfactory, the most available being petrolatum, cold cream, benzoated lard, with or without 10 to 20 per cent. of lanolin.

MILIUM.

Synonyms.—Grutum; Strophulus; Strophulus albidus; Tuberculum sebaceum; Pearly tubercles; Acne albida; *Fr.*, Acné miliare.

Definition.—A small whitish or yellowish, rounded, pearly, non-inflammatory formation, situated in the upper part of the corium.

Symptoms.—The favorite sites are about the face, especially about the eyelids, although they may occur, although much less frequently, on other parts, more particularly on the penis and scrotum and on the labia majora and labia minora. The lesions are usually pin-head in size, whitish or yellowish, often with a somewhat pearly luster, and sometimes seemingly more or less translucent. They are rounded or acuminated, project slightly above the surface, and are without aperture or duct. They develop slowly, their appearance being insidious, and after reaching a certain—variable—size, usually remain stationary for years. In number they may be scanty, scarcely more than several being present, or they may exist in greater or less profusion. While almost invariably irregularly disposed, exceptionally a tendency to grouping has been noted (Crocker). Their presence gives rise to no disturbance; there are no subjective symptoms, and unless of large size or existing in numbers, cause but slight disfigurement. Occasionally they attain greater size, or 2 or 3 may become bunched or coalesce, and reach the dimensions of a small pea or larger. In rare instances, and more especially in milia of some size, one or several may undergo calcareous metamorphosis, from the deposit of carbonate and phosphate of lime, and become quite hard and stony, constituting the so-called *cutaneous calculi.*

Etiology and Pathology.—Milia are seen at any age. They are not infrequent in infants (so-called **strophulus albidus**). They are of common occurrence in adolescence and early adult life, especially in women, and in some instances are associated with comedo and acne. They have been noted to occur at the sites of pemphigoid lesions (Bärensprung, Hebra, Hallopeau, Neisser, Behrend, Bowen, and others), after erysipelas, and along the edges of scars. In most cases, however, no cause can be assigned.

The formation is situated just beneath the epidermis, which constitutes its external covering. In the opinion of most writers the affection results from retention of sebaceous matter in one or more

acini of the sebaceous glands, although others, among whom Virchow, Rindfleisch, and Unna, hold its seat to be in the hair-follicles. According to Neumann and others, the covering proper is either the wall of the hair-follicles or sebaceous glands. Robinson believes that two different conditions have been described under this name, and that "where the formation is superficially seated, contains no fatty epithelium, shows no connection with a sebaceous gland, and no duct in connection with it, it is a case of miscarried embryonic epithelium from a hair-follicle or from the rete; the lesion consisting of somewhat lobulated collections of corneous-like cells, the whole collection being surrounded by a more or less perfectly formed capsule, from pressure exercised by the growing new formation, and provided with septa of fibrous connective tissue." Philippson also holds this view.

In most milia the contained mass is made up of closely packed sebaceous matter, with a disposition in some instances to become inspissated and calcareous.

Diagnosis.—Milium is to be distinguished from comedo by the absence of the duct orifice and blackish point of the latter. Somewhat large and flattened milia may present a faint suggestion of xanthoma, but this latter disease (*q. v.*) is of so entirely different nature that a mistake can scarcely occur. The central depression and aperture and larger size of molluscum contagiosum lesions will prevent its confusion with the latter.

Prognosis and Treatment.—Milia are persistent, with little, if any, tendency to spontaneous involution, except in infants, in whom, after a variable time, they usually disappear. They are benign, have no prejudicial influence, and are rapidly amenable to treatment.

Occurring in infants and young children, the free use of soap and water, and the occasional application, by rubbing in, of mild sulphur ointment, from 20 to 40 grains (1.33–2.65) to the ounce (32.), will often suffice to bring about the disappearance of the lesions. In others, and more especially in adults, mild operative interference is necessary. This consists in puncturing the little growths, squeezing out their contents, and in the larger lesions touching the interior with silver nitrate or a weak carbolic acid lotion, from 20 to 30 grains (1.33–2.) to the ounce (32.). Electrolysis is an available and satisfactory method. In the rare cases in which the contents become calcareous superficial curetting or a small incision and shelling out the contained mass will be required, followed by slight cauterization as already indicated. In older children and adults, when the lesions are quite numerous and somewhat closely crowded, the use of a peeling paste (see acne) will commonly cause them to be exfoliated. The careful application of soft soap sufficiently long to produce a mild dermatitis is also likely to have the same result.

STEATOMA.

Synonyms.—Sebaceous cyst; Sebaceous tumor; Atheroma; Wen; *Fr.*, Stéatome; Kyste sébacé; Athérome; *Ger.*, Follikelcyste; Balggeschwulst; Atherom; Breigeschwulst; Grützbeutel.

Definition.—A variously sized, elevated, rounded or semiglobular, soft or firm, painless tumor, having its seat in the skin or subcutaneous tissue.

Symptoms.—The favorite regions for the development of sebaceous cysts are the scalp, face, back, and scrotum. They are usually of slow and insidious growth, often taking months to reach any conspicuous size. After attaining variable proportions, from a pea to that of a walnut or larger, they may remain stationary. The overlying skin is normal in color, or it may be whitish or pale from distention. In some a gland-duct orifice is seen, but, as a rule, this is absent. In the former, which is most commonly observed on the back and neck, the tumor is somewhat flattened, often quite markedly so, spreading out laterally rather than extending upward. In that in which the duct is obliterated the formation is usually semiglobular or well rounded, and often projects considerably above the skin level. A rounded growth similar to this is sometimes observed in connection with the Meibomian glands, and known as *chalazion*, although much smaller in size.

Sebaceous cysts may exist indefinitely without causing any discomfort except their inconvenience and disfigurement. Exceptionally, however, especially in the enormously distended growths, from irritation, traumatism, or some change in their contents, they become slightly or moderately inflamed, the overlying skin reddens, and suppuration and ulceration may result, and rarely such a lesion, in old people, may finally show a papillomatous tendency and even epitheliomatous change. In those in which the duct is not obliterated this at times may close up temporarily, the tumor fill and become more prominent; later the orifice opening again, and some of the contents finding egress, and the growth flattening down somewhat; this may repeat itself from time to time. It is usually from the smaller patulous sebaceous cysts that cutaneous horns sometimes develop. The growths are, as a rule, of somewhat doughy consistence, although with, in the more distended tumors, variable elasticity; in some instances they are quite soft; in others distinctly hard. They are often freely movable. The integument over the larger cysts on hairy parts, especially the scalp, is commonly entirely devoid of hair.

In most cases but one tumor is present, although it is not at all uncommon to see two or three. In exceptional instances—probably mostly examples of **multiple dermoid cysts**[1]—they have been present in numbers, and generally scattered over the surface, and usually scarcely distinguishable clinically from fibroma.

[1] Jamieson, *Edinburgh Med. Jour.*, Sept., 1873, p. 223 (250 tumors); Maclaren, *Edinburgh Med.-Chir. Soc'y Trans.* (1886–87), 1888, p. 77 (132 tumors); Chiari, *Zeitschrift für Heilkunde*, 1891, vol. xii., p. 189, also met with an instance in which several hundred were scattered over the entire surface; Pollitzer, *Jour. Cutan. Dis.*, 1891, p. 281 (150; many yellowish and simulating multiple xanthoma in appearance).

Etiology and Pathology.—The causes of sebaceous cysts are not known, although thought to be due to the same agencies operable in comedo, such as duct occlusion. Török and Chiari's studies, made independently, have led them to believe that the majority, if not more, of steatomata are more properly dermoid cysts, and arise from embryonic remnants in the skin, as previously indicated by the investigations of Heschl and Frank. Virchow, Robinson, and almost all others have classed them with retention cysts, and this is the prevailing view to-day—being cysts of the sebaceous glands. Winiwarter would include them among cysto-adenomata, with primarily a new growth of gland tissue and subsequent transformation into a cystic tumor. The growth consists of a capsule and contents, the former composed of fibrous connective tissue. The contents are found somewhat variable as to consistence and substance; usually made up of hard and friable, or cheesy and soft, sometimes quite fluid, mass, of a whitish or yellowish color, and often with a fetid odor. For the most part they contain sebum, epidermic cells, cholesterin crystals, detritus, and sometimes hairs,[1] and occasionally lime-salts.

Diagnosis.—A sebaceous cyst is usually readily recognized when its course, slow growth, and other features are considered. Those with patulous ducts through which some of the contents can be squeezed out scarcely admit of difficulty. The closed cyst is not to be confused with lipoma, fibroma, and gumma. The lobular character of the fatty tumor will generally serve to differentiate. The sites of fibromata are, as a rule, different from those of sebaceous growths, and they are commonly multiple, whereas the latter are rarely present in greater number than one or two, or, at the most, several. In those exceptional instances—dermoid cysts—a microscopic examination may be necessary. Gummata grow more rapidly, are usually painful to the touch, are not freely movable, and tend to break down and ulcerate. Cold abscesses can scarcely be confounded with steatomata, although those instances of the latter which become inflamed and suppurate bear some suggestive resemblance. The sebaceous tumors should not be confused with the growths of molluscum contagiosum.

Prognosis and Treatment.—The only consequences of the presence of sebaceous cysts are the inconvenience and disfigurement. They are benign formations, but show no tendency to spontaneous disappearance.

The treatment of the tumor is by surgical methods. A linear incision is made, and the mass and enveloping sac are dissected out. If the latter remain, a regrowth almost invariably takes place. Other plans have occasionally been resorted to, such as slight incision, expulsion of the contents by pressure, and the injection of some irritating fluid, such as tincture of iodin or silver nitrate solution. Caustic destruction has also had some use, but the best and safest plan is that by excision. In small or beginning tumors a slight incision and expulsion of the contents, and then the applica-

[1] In a case under my observation (reported in *Philada. Med. Times*, Mch. 24, 1885), the cyst, on the bearded part, contained a coil of hair which, when unwound, was found to consist of two hairs, one 6 inches in length and the other 4½ inches.

tion, at several points of the cavity, of the electric needle (electrolysis), will sometimes suffice to bring about permanent removal.

COMEDO.

Synonyms.—Blackhead; *Fr.*, Comédon; *Ger.*, Comedon; Mitesser.

Definition.—Comedo is a disorder of the sebaceous glands or gland-ducts, characterized by yellowish or blackish, pin-point- or pin-head-sized puncta or elevations, corresponding to the gland orifices.

Symptoms.—Comedones are most usually observed on the face only, upon which they may develop on all parts, but are frequently in greatest number and sometimes solely to be seen about the angles of the nose, the chin, especially near the mouth angles, and at the sides of the temple, particularly toward the outer canthus. They are, however, often seen scattered irregularly over the face region, and may be sparse in number or in great profusion. The back is also a not infrequent site, and in exceptional instances they have been observed upon the penis (Lang). They appear to be yellowish, dirty gray, or black points or dots. They may be on a level with the skin, or scarcely perceptibly depressed or somewhat elevated (acne punctata). They are frequently associated with oily seborrhea, the parts presenting a greasy or soiled appearance. Even without the seborrheic association the blackheads, if numerous, give the face a dingy or dirty aspect. Acne may also be present, either to a slight or marked degree, but they are often observed without a single associated inflammatory lesion. They vary somewhat in size, generally larger near and on the nose and on the back; in the latter region, when present at all, they are almost invariably large and numerous. In such cases, too, the breast, and, in some instances, the abdomen as well, show the formations. There is in the average case scarcely perceptible elevation, unless the amount of retained secretion or accumulation is excessive. Upon pressure this can be ejected, the small rounded orifice through which it is expressed helping to give it a rounded, thread-like shape—hence the names, "flesh-worms" and "grubs." The so-called double or multiple comedo, usually upon the back, and not at all infrequent upon this region, to which Ohmann-Dumesnil[1] first directed attention, consists simply of somewhat closely contiguous blackheads, which are beneath the surface intercommunicable, having a common glandular chamber.

The course of comedo is chronic, the condition persisting indefinitely or being somewhat variable; sometimes the plugs loosen and are dislodged by the muscular motion of the part or by the act of washing. In extremely rare instances slight atrophic scarring is observed to develop at the follicular orifices (Lang, Neumann).[2] Not infrequently, from some alteration in the imprisoned accumulation, either as a consequence of pressure or possibly from a chemical

[1] Ohmann-Dumesnil, *Jour. Cutan. Dis.*, 1886, pp. 33 and 193, and *Monatshefte*, 1888, p. 57 (with 2 plates, containing 13 cuts), and *St. Louis Med. and Surg. Jour.*, 1888, Jan., Feb., Mch.

[2] Cited by Crocker, *Diseases of the Skin*, second edit., p. 749.

change or an added microbic factor, inflammation is excited, and a papular or pustular acne lesion results.

Exceptionally comedones occur as distinct and usually symmetric, densely crowded groups, more especially upon the forehead or the cheeks. This peculiar variety or anomaly was first described by Thin,[1] and subsequently by Crocker[2] and Wetherill;[3] it is, however, extremely rare. There is no tendency to suppuration, and the affection does not seem to bear the relationship to acne that ordinary comedo does. Moreover, they are usually smaller than the latter. Crocker states that dyspepsia is the most common cause, and as "they occur chiefly on those parts where flushing after meals is most marked," this latter is probably of some etiologic influence.

Exceptionally, too, according to the observations of Crocker,[4] Caeser,[5] and Colcott Fox,[6] somewhat densely crowded comedones occur in very young children, usually on the forehead and occipital region, against which the hat-band presses, and also on the cheeks in infants—the part which comes in contact with the mother in nursing. On the forehead, Colcott Fox states, the areas tend to join and form a continuous band, scarcely a follicle escaping. It would appear that warmth and moisture were partly etiologic, and, according to Crocker, Colcott Fox, Haddon, and others, it sometimes develops simultaneously in several of a family, and also in schools, suggesting a contagious or bacterial factor. So far as I know no similar cases have been reported in this country.

Etiology.—The contributory factors of comedo are essentially those of acne—disorders of digestion, constipation, chlorosis, menstrual irregularities, lack of tone in the muscular fibers of the skin, with, often, the infrequent use of soap and working in a dirty and dusty atmosphere. Contact with tar oils and petroleum products are of import in some instances. In some cases a predisposing constitutional element seems entirely wanting. It is most common at the developing age, from puberty up to thirty, when the cutaneous glandular structures are most active. It is observed in both sexes, but more frequently, according to my experience, in males. The microbacillus of Unna, Hodara, and Sabouraud, referred to in acne, is looked upon by these observers as of causative influence. The small parasite—demodex folliculorum (acarus folliculorum) of Henle and Simon—often found in the sebaceous mass is without etiologic significance, as it is also found in healthy follicles, although the same or an identical organism is pathogenic in dogs in provoking a follicular inflammation.

Pathology.—Pathologically the initial step in the production of a comedo is a blocking-up of the gland-opening. Unna believes this to be due to a thickening of the corneous layer, both at the outlet and within the duct; and that the microbacillus may be the exciting factor. Kaposi is inclined to believe that this increase within the duct

[1] Thin, "Grouped Comedones," *Lancet*, 1888, ii., p. 712.
[2] Crocker, "Symmetrically Grouped Comedones," *ibid.*, 1888, ii., p. 813.
[3] Wetherill, "Symmetrically Grouped Comedones," *ibid.*, 1889, i., p. 169.
[4] Crocker, *Lancet*, 1884, i., p. 704.
[5] J. Caesar, *ibid.*, 1884, i., p. 1188 (letter communication).
[6] Colcott Fox, *ibid.*, 1888, i., p. 665.

is due to the irritation of the lanugo hair, which instead of finding egress at the orifice, impinges against the opposite duct-wall; he bases this view upon the demonstration made by Biesiadecki that this latter often happens, due to the fact that the hair-follicle often stands out almost at right angles from the sebaceous gland-duct. It is possible, too, that a relaxed condition of the arrectores pilorum muscles may also be instrumental in their production by permitting the secretion to collect and harden. The comedo plug is composed of epidermic cells and débris with sebaceous matter; this latter may accumulate to a considerable extent within the gland, and from pressure cause atrophic destruction of the structure (Bärensprung). To this pressure atrophy Ohmann-Dumesnil ascribes the origin of the single glandular chamber with the multiple ducts (multiple comedo), although Düring[1] believes that it is due to previous destruction from suppurative acne lesions. The plug frequently contains organisms other than those already named, but of no pathogenic import, and occasionally one or more minute lanugo hairs. The outer layer of the sebaceous mass is usually somewhat firm, composed of epidermic horny material. According to Colcott Fox, in the peculiar comedo eruption in children the plug is apparently formed from the epithelial lining of the follicle and not from sebum. The dark point which ordinarily marks the comedo is probably in some instances due to accumulation of dirt, but as it often occurs in those in whom this is scarcely possible, I am inclined to share Unna's[2] opinion that it is due to pigment (ultramarine) derived from the secretions. It is probable, too, that exposure to air and light may have some influence in its production.

FIG. 221.—Comedo, showing distention of duct and slight glandular disintegration (greatly magnified) (courtesy of Dr. T. C. Gilchrist).

Diagnosis.—A condition so well known, and in which the patients usually make the diagnosis themselves, certainly offers no difficulty in its recognition. It can scarcely be confounded with milium, as in this latter there is no open outlet, no blackish point, and the contents cannot be readily squeezed out, unless the lesions had been previously punctured or incised.

Prognosis and Treatment.—As a rule, with proper management, the tendency to blackhead formation cannot only be materially lessened, but removed. This presupposes, however, persistence

[1] Düring, *Monatshefte*, 1888, p. 401.

[2] Unna, "Woraus besteht der schwarze Punkt der Comedonen?" *Virchow's Archiv*, 1880, vol. lxxxii., p. 175; also Unna's *Histopathology*.

and cooperation on the patient's part. It is true that some cases are obstinate, and the ducts sometimes fill up again and again before success is reached. The general management is practically the same as in acne, the digestion and the condition of the bowels often needing attention, and not infrequently in women advice as to proper regulation and treatment of menstrual irregularities. The most useful and most frequently prescribed remedies are cod-liver oil, in strumous and debilitated subjects, and iron, arsenic, nux vomica, and other tonics; ergot is sometimes useful in those cases in which there is lack of muscular tone. Hygienic measures, such as general and local bathing, calisthenics, and open-air life are of service. Upon the whole, the most commonly efficient general treatment consists of laxatives and digestives, with supervision of the dietary, general bathing, and sufficient exercise.

The local treatment, which is also practically similar to that of acne (*q. v.*), is of essential importance, and in some cases the sole measure indicated. It has in view a removal of the sebaceous plugs and stimulation of the glands and skin to healthy action. A procedure of value consists in steaming nightly the parts for from five to fifteen minutes, or the application of water as hot as can be comfortably borne; washing with ordinary toilet-soap in some cases, and if the skin is not oversensitive, with green soap or its tincture. The soap-washing should precede the steaming or hot-water application. The application, two or three times weekly, of a fairly strong faradic current—sufficiently strong to produce slight muscular action—has been of material advantage in many of my cases. The daily use of an exhaust cup,—cupping-glass not over an inch opening,—going over the face thoroughly, is often of great service not only as a measure of massage, but it tends to empty some follicles and loosen the secretion in others. The plugs are also to be removed by mechanical means—by lateral pressure with the finger-ends or by means of a fenestrated curet-shaped or a watch-key-like instrument now to be had in the shops. Such removal may often be facilitated by first insinuating a fine needle and gently loosening the plug from the embrace of the gland-duct. The ducts should be again emptied as soon as they refill, which may occur several times. Just before the remedial application, after the hot-water washing, etc., the parts should be dashed with cold water. These adjunct and preliminary measures are to be supplemented by remedial applications, which are essentially the same as those employed in the treatment of acne. The sulphur preparations are, upon the whole, the most useful, although exceptionally they seem to aggravate the condition. Of the mercurials, corrosive sublimate is the best, in the strength of from $\frac{1}{2}$ to 3 grains (0.033–0.2) to the ounce (32.) of water, applied nightly, and sometimes twice daily. When slight roughness or bran-like scaliness supervenes or any irritation of the skin arises, active remedial treatment is to be relaxed and soothing applications made for a few nights.

A paste-like application, warmly commended by Van Harlingen[1] as of special value in loosening the sebaceous plugs, is one consisting

[1] Van Harlingen, *Handbook of Skin Diseases.*

of acetum, ʒij (8.); glycerin, ʒiij (12.); kaolin, ʒiv (16.). This is spread over the surface at night, the eyes being kept shut during its application, owing to the pungency of the vinegar. For other applications the reader is referred to the article on acne, the best among which will be found to be the lotion of zinc sulphate and potassium sulphuret, and the stronger resorcin lotions and pastes.

Patulous ducts can often be made somewhat smaller by the electric needle (electrolysis); also by a course (8 to 10) of mild to moderate exposures to the X-ray.

ACNE.

Synonyms.—Acne vulgaris; Acne disseminata; Acne simplex; *Fr.*, Acné; *Ger.*, Acne vulgaris; Akne; Finnen.

Definition.—An inflammatory disease, usually chronic, of the sebaceous glands of the face, face and shoulders, upper trunk, and occasionally of the back, characterized by papules, tubercles, or pustules, and sometimes nodules, or a combination of these lesions, and commonly met with between the ages of thirteen and thirty.

Symptoms.—The most common site for the disease is the face, and it is generally limited to this region; in many cases, however, it is not infrequent to see several lesions, and sometimes a large number, on the neck and shoulders as well, and occasionally some on the upper trunk; exceptionally the back is the chief seat, extending from the neck to the sacrum, and in rare instances the eruption may be limited to this latter region, with lesions also on the anterior surface of the trunk.

The eruption may be insignificant, consisting of but several or more scattered lesions, or it may be abundant; in average cases there are usually 30 to 40 present. Exceptionally the eruption may appear somewhat acutely, a moderate or large number of lesions presenting in the course of one or two weeks; as a rule, however, it begins slowly and insidiously. The eruption is generally made up of small pale red, bright or dark-red pin-head to pea-sized or larger papules and some pustules. The base is slightly, moderately, or markedly inflammatory. Taking a common example of the disease, there will be noted, irregularly scattered over the face, usually more numerous on the forehead, chin, and over the lower jaw, 30 to 50 pin-head- to pea-sized papules, tubercles, or pustules, or, more frequently, a mixture of these lesions (acne vulgaris), and in the various stages of evolution and involution or subsidence; interspersed are usually to be seen comedones (blackheads), and not infrequently the same formation or the blocked-up gland-duct is readily recognizable in the center of the apex of the smaller papules. The lesions may be somewht acute in character, with a hyperemic inflammatory base, or they may be sluggish; or some are distinctly inflammatory and others but sluggishly so. In many of these cases the skin seems relaxed, thick, dirty, and greasy, usually from a slight or moderate oily seborrhea which frequently coexists; in such instances particularly the gland outlets are often large and quite conspicuous. If a pustular lesion is squeezed, a mixture of pus and sebaceous matter is discharged,

and occasionally a small thickened mass which faintly suggests a core. In the course of several days or a few weeks pustular lesions have dried or been broken and discharged and partly or completely disappeared; papules, and tubercles if present, will have gradually vanished by absorption, or, as more commonly occurs, they become pustular, and rapidly or slowly dry or discharge, and disappear, usually without leaving a trace more than a reddish stain, which finally fades. During this time, however, new lesions are presenting and going through the same evolution and involution stages. Thus the case goes on, with slight or marked fluctuations between better and worse—slight and relatively few in number at times, sluggish or inflammatory and the lesions numerous at other periods. In many cases, after some months to several years, or more, the eruption may, and frequently does, begin to decline, the new lesions gradually diminishing in numbers, and finally the patient is entirely free.

FIG. 222.—Acne of small papular and papulo-pustular type, with numerous comedones—"black-heads."

In other instances there may, on the average, be but 5 to 10 lesions present, and with intervals of several days or a few weeks in which no eruption at all is to be seen, several cropping out irregularly when the patient suffers from digestive disturbance, constipation, and in girls and women at the menstrual epochs. On the other hand, in some patients 100 or 200 or more are found, here and there close together or irregularly scattered, not only over the face, but the shoulders and upper part of the trunk. In occasional cases the hyperemic element is quite pronounced, and if the lesions are near together, the condition and appearances approach those of acne rosacea.

The above is the usual picture encountered, and generally no scarring, or no perceptible scarring, results, the patient finally recovering without a trace of the previous eruption. This is, however, unfortunately not always so, as slight tissue destruction or atrophic changes producing permanent marks sometimes occur, and in such cases this tendency distinctly predominates so that the marks are usually quite numerous. The large, purulent, deep-seated lesions

and the dermic abscess type to be referred to often leave very distinct cicatrices.

The so-called clinical varieties are named from the predominant type of lesions present, and from the accidental or coincident character of the inflammatory process and the resulting changes. Thus an acne lesion usually begins by a blocking-up (comedo) of the sebaceous gland outlet and a mild degree of hyperemia and inflammation results, which causes a slight elevation, generally with a central blackish or dirty gray or yellowish point, and the majority or most of the lesions may exhibit but little tendency to advance beyond this stage, and such instances constitute **acne punctata.** As a rule, how-

FIG. 223.—Acne of the papular, pustular, and indurated or boil-like type, with a general "muddy" complexion, in a woman aged twenty-two, of several years' duration; some minute, pit-like scars left by former lesions are noticeable on the cheeks.

ever, the inflammation is of higher grade or the lesion progresses, producing a more prominent, usually small pea-sized, reddish, papular elevation, probably due to perifollicular infiltration, with but little tendency, in most of the papules, to advance to suppuration, and thus is presented **acne papulosa.** If the inflammatory action is still more intense, or continues, or probably if micro-organisms invade the lesions, they or the most of them tend to advance rapidly to central suppuration, especially toward the apex, and pea-sized or larger formations present, which show, under the thinned epidermal covering, pustulation; such cases represent the so-called **acne pustulosa.** In some patients the inflammation begins somewhat deeply, and is felt as subcutaneous nodules, which grow larger and toward the surface,

and then remain as small or large pus cavities, very slowly undergoing resolution, or finally break and discharge, and then may again fill up; others show pustulation, and at the same time the base becoming markedly inflammatory and hard—**acne indurata.** In some instances, fortunately not common, of the smaller lesion cases, usually small papular, or less frequently pustular, as the lesions disappear they leave a pit-like atrophy or depression,—distinct though not large scars,—and this represents the type known as **acne atrophica.** When such tendency does exist, it is exhibited by most of the lesions. On the other hand, in some such cases slight connective-tissue new growth may follow their disappearance and present as minute or

FIG. 224.—Acne of the back—showing pustules, papules, and blackheads; the scarring which is often quite marked in back cases is not conspicuous in this instance (courtesy of Dr. M. B. Hartzell).

small scar-tissue or keloidal elevations—**acne hypertrophica.** In other instances, not overnumerous, and usually observed in those of cachectic and depraved condition, the gland itself seems to be the seat of the chief inflammatory and suppurative changes, and furuncular or sluggish abscess-like formations result, which may show but little, or an extremely slow, tendency to break through; many of these lesions are of the nature of dermic abscesses, usually of a cold, sluggish character, and sometimes of more general distribution—**acne cachecticorum.** Under this latter name, but preferably under the designation of acne scrofulosorum, is also to be included a sluggish papular or papulopustular acne of livid red color, pea- to cherry-sized, observed associated with strumous symptoms, and commonly occupy-

ing the trunk and extremities, and less frequently the face also; slow in evolution, and sometimes slight superficial destruction occurring under the crust and leaving scars.

Acne cases are occasionally encountered in which the eruption is almost entirely or wholly limited to the trunk, usually or more particularly the back and the breast, and in such instances the eruption, as a rule, consists of numerous variously sized papular, papulopustular, more or less indurated sluggish lesions, with, in some, a tendency to the dermic abscess type; many comedones, some double and multiple, are also generally present. The eruption is sluggish and persistent, old lesions going slowly, and new presenting; considerable scarring is sometimes noted.

The lesions in acne are discrete and scattered, but occasionally a tendency is exhibited here and there toward the formation of several somewhat closely set groups; in such the base seems almost continuous, as in some of the iodid and bromid eruptions. In the dermic abscess variety this tendency to contiguous formation is also now and then observed. While most lesions probably have their beginning in a blocking-up of the gland outlet, this is not demonstrable in all, and more especially not in the deep-seated formations.

Acne artificialis is a term applied to the acne-like eruption produced by the ingestion of the iodin and bromin preparations, also named *iodid* or *iodin acne* and *bromid* or *bromin acne;* and from the external use of tar (acne picea, acne picealis) in occasional instances. This latter is likewise met with in those who, in the course of their work, are brought into frequent contact or live in an atmosphere strongly impregnated with tar or tarry products. Tar acne results from a blocking-up of the follicular openings with this product. With tar acne furuncles are often associated. Chrysarobin is noted at times to bring about follicular inflammation and acne-like lesions. Workers in petroleum and paraffin products are also occasionally the subjects of acneiform, furuncular, and abscess formations. These several artificial eruptions, which may be limited or more or less general, are referred to under the head of dermatitis medicamentosa.

Another variety or acne-like eruption, often limited to the face, as in 2 of my cases, sometimes seen on the face, scalp, neck, and shoulders also, and in others upon the extremities as well, and deserving of the name of **acne urticata** (Kaposi, Touton, Löwenbach, and others),[1] already given to it, is that in which the lesions suggest both acne and urticaria. Preceded, as a rule, by itching, they begin as small or ordinary sized pinkish or reddish, urticaria-like elevations or distinct wheal-like lesions, which enlarge somewhat and soon exhibit slight central vesiculation, which dries to a thin crust, during which time the urticaria-like basis usually has entirely disappeared. Beneath the crust some necrotic or atrophic action takes place, and when it drops off, a small depressed scar remains. If the forma-

[1] Kaposi, *Pathologie und Therapie der Hautkrankheiten*, 4. Auflage, Wien, 1893, p. 529; Touton, *Verhandlungen der Deutschen Dermatologischen Gesellschaft*, VI. Congress, 1899, p. 7 (this paper covers all varieties and types of disease described under the name acne, with full bibliography); Löwenbach, *Archiv*, vol. xlix., 1899, p. 29 (with histologic study, reference to allied diseases, and bibliography of same).

tion is squeezed before crusting and desiccation ensue, there appears a small amount of serum, but no pus. The course of a lesion is generally run in from one to two weeks, but new eruption continues to appear and the disease lasts indefinitely. It is not a frequent variety, nor is it, I believe, a true acne, but probably a type (Kaposi) of acne varioliformis; its clinical symptoms and behavior are somewhat similar. Löwenbach's investigations give it a middle position between acne varioliformis and urticaria perstans. The several cases under my care were all neurasthenic girls between eighteen and twenty-five, and of weak digestion. The cause is not known; micro-organisms have been found, but with no uniformity. In all my cases and those of others (Kaposi, Touton) digestive disturbances were noted. Its anatomic seat is about the hair-follicle. The disease is stubborn and rebellious to treatment.

Under the name of **acne keratosa**[1] Crocker has described 4 cases of a rare affection; one of which had been previously recorded by Jamieson, possessing some of the features of acne. The eruption is seen on the face, on the chin and cheeks, and commonly near the corners of the mouth. Red, tender, firm lumps, persistent in character, are first seen, on which pustulation usually presents, and dries to a crust. Sometimes the covering epidermis is detached by the underlying lymph. On removal of the crust, one or several soft or horny conic "pegs," about $\frac{1}{12}$ of an inch long, which produce irritation, are found imbedded; their removal is followed by gradual but very slow disappearance of the lesion, usually leaving scars. New formations appear from time to time, and the disease goes on almost indefinitely. In some cases there is an irresistible desire for the patient to pick at them, resulting in excoriations, as in Brocq's[2] patients. The lesions have their seat in the sebaceous gland or hair-follicle. The cause of the disease is unknown, and treatment, similar to that of ordinary acne, not very satisfactory.

The **course** of acne is almost always persistent, individual lesions disappearing after a variable time—several days to several weeks, according to character, but new lesions making their appearance irregularly from day to day or week to week. In average examples scarring does not result. As already remarked, cases vary much in the number, features, and behavior of lesions. Some are so slight, the lesions so few, and the parts often free, that they scarcely are entitled to be considered a disease; on the other hand, many are troublesome and disfiguring to a repulsive degree. As the patient advances toward full growth and enters adult age, in many instances the tendency disappears, but this is by no means true in all.

Ordinarily there are no subjective symptoms in average acne cases, occasionally slight beginning soreness, and when the inflammation is marked, there may be tenderness, especially upon pressure.

[1] Crocker, "Acne Keratosa," *Brit. Jour. Derm.*, vol. xi., 1899, p. 1; Jamieson, "Peculiar Ulcerative Eruption of the Face, Associated with the Formation of Horny Plugs, Accompanied with Pain and Apparently Developing in the Sebaceous Glands," *ibid.*, vol. v., 1893, p. 141.

[2] Brocq reported, under the name "L'acné excoriée des jeunes filles," Paris, 1898, a somewhat similar condition in which, however, there were no horny pegs.

Exceptionally there is moderate itching, particularly just as the lesion is about to appear.

Etiology.[1]—The disease is a frequent one. The causes are varied. It would often seem that it is a reflex neurosis. It is probable that there is in some lesions or cases an exciting parasitic factor, and this view is maintained by some observers (hence the term, parasitic acne, sometimes met with). The pus-organisms are credited with being etiologic, but recent investigations (Unna, Gilchrist, Hodara, Sabouraud, Beck) point rather to a special bacillus, and that the cocci found are somewhat distinct from the ordinary pus cocci. Sabouraud believes the bacillus brings about the seborrhea often noticed, and to this is added a special coccus (staphylococcus albus butyricus) for the acne. In those infrequent trunk acne cases a parasitic element seems the most plausible explanation. Seborrhea, especially of the oily variety, is often associated, and in some cases seems of influence in producing or keeping up the acne; but the statement (Schütz, Sabouraud, and others) that acne never exists without seborrhea is, I think, a little too sweeping. In acne following oily seborrhea there is a tendency, it is stated (Hallopeau and Leredde), to appear first on the forehead, and later cheeks, nose, and chin. I have not specially observed this.

Even admitting a parasitic agent, which is probable, there are to be considered the predisposing causes which bring about the proper condition of the skin (proper soil) for parasitic invasion or prejudicial action.[2] These seem, indeed, in certain cases, distinctly etiologic; such are digestive disturbances (producing reflex hyperemia of the parts (Crocker)), constipation, menstrual irregularities, chlorosis, general debility, lack of tone in the muscular fibers of the skin, and scrofulosis. And as external factors may be mentioned working in a dusty or dirty atmosphere, lack of cleanliness, the infrequent use or entire abstention from the use of soap for the face. In fact, anything which tends to block up the gland outlet has an etiologic bearing. Drug and trade factors have already been referred to—bromin and iodin preparations, tar, and petroleum products. Indulgence in the so-called "bromo" proprietary headache medicines is

[1] Bearing upon some etiologic factors named: Lomry, "Untersuchungen über die Aetiologie der Acne" (bacteriologic), *Dermatolog. Zeitschr.*, Aug., 1896—full abstract in *Brit. Jour. Derm.*, vol. viii., 1896, p. 453; Hodara, "Ueber die bacteriologische Diagnose der Acne," *Monatshefte*, vol. xviii., 1894, p. 573; Jacques, "De l'état seborrheique de la peau et des ses rapports avec les dermatoses, notamment avec l'acné; étude de pathogénie et de traitement," *Thèse de Paris*, 1892—abs. in *Annales*, 1892, p. 1047; Mitour, "Étude sur la nature et le traitement de la dyspepsie accompagnée acne," *Thèse de Paris*, Jan., 1896; Sabouraud, "La seborrhœe grasse et le pelade," *Annales de l'Institut Pasteur*, 1897, p. 134; Schütz, "Klinisches über Akne und der seborrhoischen Zustand, *Archiv*, vol. xxx., 1895, p. 203; S. Mackenzie, "Etiology and Treatment of Acne" (with discussion thereon), *Brit. Jour. Derm.*, vol. vi., 1894, p. 304; Unna, *Histopathology*, 1896, pp. 357, 361; Gilchrist, *Trans. Amer. Derm. Assoc. for 1899*, p. 97; and *Jour. Cutan. Dis.*, 1903, p. 107 (with histologic and bacteriologic illustrations, review and bibliography as to these subjects).

[2] Gilchrist is firmly convinced by his extensive experimental investigations that the "bacillus acnes," which he was the first to obtain in pure culture, from acne lesions, is the primary cause of acne vulgaris; he has found it pathogenic in mice and guinea-pigs; and has demonstrated that the blood-serum of acne patients agglutinates these bacilli; he further believes that many of the constitutional and other symptoms often found associated with the disease, instead of being predisposing causes, as commonly thought, are, in fact, probably the result of absorption of the toxins of the bacillus acnes.

not an infrequent cause of scanty and irregularly appearing lesions. The not uncommon custom of taking the advertised "blood-purifiers" in the spring, most of which contain potassium iodid, is another element which adds to dermatologic practice. In fact, I have met with several instances in which the administration of the iodids or bromids was the starting causative factor in the production of rather persistent acne. The use of irritating soaps, but more especially soaps containing tar or its derivatives, is a contributing agent in some cases.

The most easily demonstrable causes in many cases, and which patients themselves soon recognize, are constipation and digestive disturbances. Night or day indulgence in indigestible foods, in beer or other alcoholic drinks, will often provoke a fresh outcropping in those with acne tendency. It is probably due to such causes that acne of rather acute character is occasionally met with in patients who have just recovered from a severe illness—the appetite being keen, indulgence and overeating bring about indigestion or result in the absorption of incompletely digested food. It is especially fermentative dyspepsia (Hallopeau, Robin, Leredde, Elliot, Barthélemy, Jacques, Mitour, and others) that is particularly etiologic; dilatation of the stomach (Barthélemy)[1] is also a frequent factor. Excessive tea- and coffee-drinking and too free use of tobacco must also be considered to have influence. Circulatory weakness, as evidenced by cold feet and hands, is credited with influence, but this itself is doubtless often the result of digestive difficulties. Menstrual irregularity or difficulty or other uterine disorders is also a source of aggravation, if nothing more, in some cases, and in those due to such cause a special tendency to appear on the chin and around the mouth has been noted by some observers (Hallopeau and Leredde). Women with acne are almost invariably worse at the menstrual period, and mild cases will often be relatively or entirely free in the interim. Other known facts are that the disease is commonly one which belongs between the ages of thirteen and thirty; exceptionally it begins earlier, and not infrequently it persists after the latter age, but rarely presents for the first time after that period. It is common to both sexes, among rich and poor, but it is somewhat more frequent in individuals of light complexion, and in those leading a sedentary life. Both excessive sexual indulgence and sexual continence have been ascribed as factors, but with scant foundation.

Pathology.—Acne is pathologically an inflammation of the sebaceous glands, which may, from resulting suppurative action, mean more or less follicular destruction. The attached lanugo hair-follicle is usually implicated, and it is alleged by some writers that this is the primary seat of the inflammatory action or irritation. In most lesions an important step in originating the process is a blocking-up of the glandular outlet, either by a comedo formation, as a result of a hyperkeratosis (Unna), or from extraneous material; in the production of

[1] Barthélemy, "Etiologie et Therapie de l'Acné," *Arch. gen. de méd.*, ii., 1889, p. 641; also in *Monatshefte*, vol. ix., 1889, p. 406. In 169 cases especially investigated as to dilatation of stomach Barthélemy claims to have found this condition in 165—dyspepsia in all, the first effect of improper digestion, according to this author, being a seborrheic condition, and then the implantation of a pathogenic organism.

the former, atony of the muscular fibers of the skin, and especially the arrectores pili, is probably an important factor. Blocking-up of the glandular outlet, however, is not sufficient explanation, for it is not invariably observed, and it frequently occurs (see comedo) without any resulting irritation or acne lesion. To this, therefore, must be added as yet an unknown agent, but which may variously be micro-organisms, chemical and irritating change in the secretion within the gland (Virchow), or some poison or irritant eliminated by the glands (Leloir, Hallopeau, Leredde, and others), probably due to imperfect digestion; the first named, in the light of our present knowledge of cutaneous pathology, being most probable as the essential element. The various conditions named in etiology prepare the soil for parasitic invasion, seborrhea holding a prominent place. As also referred to in etiology, ordinary pyogenic or similar organisms, which are sometimes, but not always, present, have been thought to be the pathologic exciting factor, but this has been called in question. More recently, as already stated, a special bacillus, which Gilchrist finds has pus-producing properties, has been found; it is somewhat short and thick, rod-like, straight or curved, and sometimes branching, and occasionally coccoid in form (Unna, Gilchrist). Gilchrist found this bacillus in every acne pustule examined.

According to investigations (Simon, Virchow, Hebra and Kaposi, Biesiadecki, Leloir and Vidal, Robinson, Elliot, Heitzmann, Gilchrist, and others), the inflammation begins either in or around the gland, the vessels showing engorgement; in the latter event the glandular structure becomes secondarily involved. Inflammatory infiltration may be somewhat limited, and chiefly around the gland-outlet, or be periglandular, or it may be quite extensive and diffused, and even involve several glands. Suppuration generally ensues, but this is a secondary result, and not necessarily constant. The infiltration, which may be superficial or deep in the derma, is inflammatory in character, with sometimes plasma-, large fusiform, giant- and mast-cells, and, when suppuration ensues, with leukocytes added. The epithelial lining usually becomes thinned, extended, and may disappear entirely when the glandular walls give way, the lesion being then a small, variably sized, dermic abscess. Leloir and Vidal, who are among those who believe the primary inflammatory changes to be perifollicular, have noted in some instances suppurative foci around the glandular structure, which eventually rupture into the cavity.

The contents are composed of seropurulent fluid, sebaceous matter, and tissue débris. In the larger lesions not only the sebaceous gland partly or completely suffers destruction, but the hair-follicles as well. The character of the lesion is determined by the activity and intensity of the process; inflammatory infiltration around the gland-outlet giving rise to the smaller papules, and, when more extensive and periglandular as well, to larger indurated papules and tubercles; and, when suppurative action ensues, to the pustule. If the suppurative action is abundant, the small dermic abscess results, and when intense, deep-seated, and involving several glands, the large dermic abscesses are formed.

Diagnosis.—There is rarely any confusion possible in acne, if it be remembered that the eruption is always follicular and limited to

certain parts, and commonly the face alone, and that the several stages of the lesions, from the blocked-up gland-outlet, or comedo, to the papule and pustule, are usually present, not grouped, but discrete and irregularly scattered. A history of some duration is ordinarily given. While the lesions of pustular syphiloderm bear some resemblance, these are almost always a part of a generalized eruption, with other symptoms and a different course and history. The tubercular syphiloderm, and also the tuberculopustular syphiloderm, usually late manifestations and somewhat limited, if occurring on the face, are to be differentiated more especially from large papular acne or acne indurata, but they are differently colored,—copper or ham tint,—almost always grouped, and, as a rule, in a circinate, segmental, or serpiginous manner; moreover, they are slow in evolution, and frequently present underlying ulceration, and leaving behind atrophy, staining, or scarring. The dermic abscess variety of acne lesions is entirely different in its evolution, behavior, and course from a gummatous syphiloderm.

An acute outbreak of acne has been mistaken for a beginning variola, but if the distribution of the latter, its prodromal and accompanying constitutional symptoms, are considered, such an error seems scarcely possible. Acne is to be distinguished from acne rosacea by the facts that the latter is more or less diffusely hyperemic, with, as a rule, dilated vessels, and the eruption is usually predominantly about the nose and immediate region; in extensive cases the region involved is an ovalish area, of which the nose is the center, and the outer boundaries, the chin, central forehead, and middle of the cheeks. Acne rosacea is, moreover, much more common after the age of thirty, whereas ordinary acne then becomes much less frequent. Midway types are, however, met with, which partake really of the nature of both diseases.

Acne limited or more or less confined to the back differs from ordinary cases simply in being in an unusual location, but its features are the same, commonly of a more pronounced type than generally seen on the face; there are frequently many comedones.

The possibility of acne-like pustules from bromin and iodin preparations is not to be lost sight of; the lesions are usually a brighter red, with, as a rule, a less pronounced base, and the contents are somewhat thinner, and while lesions are almost invariably on the face, they are often seen also on other parts on which acne is not observed; a safe plan, however, in suspected cases is to make inquiry as to the ingestion of such drugs.

Prognosis.—Acne is often a troublesome disease, sometimes rebellious and obstinate; still, upon the whole, it is, I think, to be considered one of the more favorable of the cutaneous maladies, and one in which the results of well-directed treatment are usually gratifying. The majority of cases respond quite readily, the skin clearing up in the course of a few months; in others again somewhat rapidly at first, and then more slowly, six months to a year or more being required to bring about permanent betterment. Exceptionally it proves, for a time at least, most intractable, relief being slow and often temporary. If untreated, it frequently continues for several years or more, in the majority of patients a spontaneous disap-

pearance setting in as adult age is reached. There are, however, many exceptions to this, and the statement that all cases are well by the time thirty is passed is not supported by the experience of specialists. Many persist indefinitely, and especially those of the indurated and dermic abscess type, and more particularly acne of the back. Scarring, more or less permanent in character, remains in some instances. To a great extent it may be said that cure depends upon a recognition of the predisposing cause or causes and their removal or modification.

Treatment.—Both systemic and local treatment are essential in most cases; in patients approaching full maturity, and showing a tendency to spontaneous disappearance, local applications alone will often suffice. In many instances, however, constitutional medication is of greater importance for permanent effect and should rarely be omitted.

To secure the best results each case must be studied carefully and all possible etiologic elements considered. Constitutional treatment must be selected according to the predisposing influences in the individual patient, remembering that digestive disturbances and constipation are the most common causative factors. The value of exercise in the open air, calisthenics, bathing, and other hygienic measures cannot be overrated. Free bowel action is of essential importance. The diet should be regulated, the food being plain but nutritious; such articles as pork in any form, veal, pastries, sauces, gravies, cheese, pickles, alcoholic drinks, excess of coffee and tea, cocoa, immoderate smoking, etc., should be abstained from. All indigestible or questionable foods are to be interdicted, especially those leading to fermentative indigestion. For dyspeptic patients and for those whose digestion is weak or capricious, bitter tonics, alkalies, nux vomica, acids, pepsin, pancreatin, and saline and vegetable laxatives are to be variously prescribed. Of the laxatives, cascara sagrada, the ordinary aloin-strychnin-belladonna pill, rhubarb root, gray powder, calomel, Hunyadi János, Friedrichshall, and similar waters deserve special mention. A mixture composed of ½ to 2 drams (2.–8.) of sodium benzoate, 2 drams (8.) of tincture of nux vomica, 2 to 4 drams (8.–16.) of fluid extract of cascara sagrada, and tincture of cardamom to make up 3 ounces (96.), of which a teaspoonful is to be taken after each meal, can often be prescribed with advantage. Another combination often of service and in very general use is a saline tonic, known usually as the "mistura ferri acida," made up of 1 ounce (32.) of magnesium sulphate, 4 to 8 grains (0.25–0.5) of iron sulphate, 1 to 2 drams (4.–8.) of dilute sulphuric acid, and mint-water to make 4 ounces (128.), of which a tablespoonful is given in a full tumbler of water about twenty minutes before breakfast. If the dose of this latter should not prove laxative, it can be given also in the evening upon retiring; or, and ordinarily to be preferred, 2 or 3 drams (8. or 12.) of sulphur can be added.

In chlorotic and anemic patients preparations of iron, arsenic, and manganese are useful, but the dose should be small, inasmuch as large dosage of these drugs is likely, by tending to disturb digestion, to aggravate rather than relieve. Arsenic is of benefit in some of the cases of the small sluggish papular type, given in moderately

full doses, but as the state of the digestion is the weak point in many acne patients, its use must be watched. In debilitated subjects, and in those of strumous habit, cod-liver oil, in doses of from $\frac{1}{2}$ to 1 teaspoonful three times a day, is a remedy of great value; it is particularly valuable in the atrophic, indurated, and dermic abscess types, and it is, in my experience, entitled to high place in the treatment of these cases. The dose need not be large, never more than 1 dram (4.) three times daily, and often capsules containing $\frac{1}{2}$ dram will be sufficient in quantity and a satisfactory method of administering it. In those unable to take it, glycerin, a teaspoonful to a tablespoonful at a dose, has been commended (Desquin, Gubler, Buckley), but it is far less valuable than cod-liver oil. In pustular types small doses of calx sulphurata, so much vaunted,—from $\frac{1}{20}$ to $\frac{1}{4}$ grain (0.0032–0.016) three to five times a day,—may be tried, but it is an unreliable remedy, and its administration, in my experience, is usually time wasted. Ichthyol has been commended, especially in those cases in which the congestive element is marked. In those instances in which a constant tendency to active inflammation, with more or less flushing or passive congestion of the parts, is noted, saline laxatives and the alkaline diuretics will be found of great advantage. Sulphur internally, 3 to 5 grains (0.2–0.35) three times daily, is sometimes of service both by its mild laxative action and its alterative influence. Recently Wright and a few others have claimed good results from injection of antistaphylococcic vaccine or serum, dosage and frequency depending upon the opsonic index of the blood (see "Opsonins" p. 108). Acne can, however, be generally managed successfully with the various plans already referred to, and the "vaccine" treatment, with its possible risks, must, moreover, still be viewed with considerable conservatism.

Local or external treatment is of essential importance in the management of acne. The remedies used are of antiseptic character. There are three methods of medication—by powders, by lotions, and by ointments. It will usually be found that no one method of application can be used satisfactorily in a given case without occasionally having recourse to another. The ordinary case will, as a rule, demand for a successful issue a change from lotion to ointment or vice versâ. The method of medication with powders is less efficient and least commonly employed. Upon the whole, the method of treatment by lotions is the most generally satisfactory, intermitting at times, and using an ointment. The action of remedies is enhanced by thorough application. Powders are to be dusted freely over the parts; lotions are to be dabbed on for five or ten minutes, going over and over the affected region several times, and allowed to dry; ointments should be carefully but thoroughly rubbed in for several minutes or more, and the excess then be wiped off. Whatever the method of application selected, as soon as slight irritation or a tendency to scaliness results, the remedy should be intermitted for one or two nights, during which time a mild, soothing ointment, such as cold cream or petrolatum, is to be applied, and all other measures omitted. Scaliness is more frequently a result of the application of stimulating lotions; salves produce at times redness and irritation,

but unless pushed or very strong, the grease constituent keeps the parts free from visible epidermic exfoliation.

There are certain general directions as to the management. The affected part, usually only the face, is to be washed with a mild toilet-soap, or in extremely sluggish cases with green soap or the tincture of green soap instead of the toilet-soap; in indolent types the soap tincture can be medicated with 10 grains (0.065) or more of resorcin to the ounce (32.). The parts are then to be thoroughly rinsed and sponged for from five to ten minutes with water as hot as can be comfortably borne, wiped dry, and then the remedial application made. In many cases, especially when the skin is somewhat oily and sluggish, massaging the face after the washing is a helpful measure; going over the parts with a small cupping-glass (about an inch opening) is the most satisfactory method. This not only massages the face, but tends to empty the ducts; the face is washed again with hot water and soap, rinsed off with hot water, and then dashed for a moment or two with cold water and wiped dry, after which the remedial application is to be made. These procedures are best carried out at night, in the morning washing with tepid water. In severe cases, in patients desiring a rapid impression to be made, this treatment may be repeated night and morning, or even three times daily, until the parts are considerably irritated or roughened, and then soothing remedies are applied for a few days. When such an active method is employed, the patient should, especially if the weather be cold and windy, be more or less confined to the house, or an eczematous dermatitis may be brought about. In addition to these preliminary and adjuvant measures, the blackheads are, as far as practicable, to be removed. This may be accomplished by the patient by pressure with the finger-ends or with a watch key-like instrument procurable in the shops, or best by the physician, and much more easily and satisfactorily with a fenestrated curet-shaped comedo extractor. Application, twice weekly, of the faradic and galvanic currents has seemed to me of positive service, employing the former preferably in those cases of sluggish muscular tone, as usually shown by great tendency to follicular plugging (blackhead formation), and the latter in those in which the evolution of the lesions is slow, and their beginning deep seated. With the faradic current one electrode can be held by the patient and the face gone over with the other, or the stationary electrode can be held in front of the ear. The current should be strong enough to produce slight muscular action. With the galvanic current the negative electrode can be held in the patient's hand, and the positive applied to the face, a current of 5 to 20 milliampères being employed sufficiently strong to bring about slight redness. Opening the smaller pustules is not essential, and even many of the larger pustules will care for themselves, but the treatment is materially aided by puncturing or incising such lesions and pressing out the contents. The cavity of the indurated lesions can be touched with carbolic acid; or these and the dermic abscess type can be washed out with a weak carbolic solution or with hydrogen peroxid. Believing, too, that seborrhea of the scalp, especially the oily variety, is a factor in some cases of acne, when such is visibly present, it is a good plan to give it some attention, more particularly as to shampooing

every five to ten days, using the medicated soap tincture for this purpose.

The remedial applications must, of course, vary somewhat in strength and character with the local conditions. Thus, in cases in which the lesions are acute, markedly inflammatory, hyperemic, tender, and painful, milder applications, such as are of a soothing nature, are called for; the boric acid lotion, calamin-and-zinc-oxid lotion, and similar lotions used in eczema may be temporarily used. One of the most satisfactory is composed of 40 grains (2.65) of calamin, 80 grains (5.35) of zinc oxid, 1 dram (4.) of boric acid, and water to make 4 ounces (128.); to this, if the skin is very dry, can be added 2 to 8 minims (0.13–0.5) of glycerin. Later, when the inflammatory aspect has abated, the addition of 4 to 20 grains (0.27–1.33) of resorcin is advantageous. In the average patient, however, the eruption has usually been of some duration, and the lesions are, comparatively speaking, somewhat sluggish, and will demand, even at the start, remedies of a slightly or actively stimulating character. For sluggish cases, in which the lesions are somewhat superficial, putting the skin on the stretch and scraping it with a blunt-edged curet (G. H. Fox), using more or less pressure, will mechanically break and evacuate the pustules and remove many of the comedones; considerable temporary disfigurement and irritation follow, which may be allayed by soothing applications. As it is also somewhat painful, patients often object to it, but there is no question about the rapid improvement which generally follows.

The most valuable remedy in the external treatment of acne is sulphur or its compounds, and it can be used in most of the cases with variable advantage, sometimes slight, oftener pronounced; in some patients, however, the skin does not bear it well, and irritation results; in others, for some unexplained reason, the follicular openings blacken, and the comedo element of the case becomes more conspicuous; in others again the remedy has no effect whatever. In mild types sulphur may be used as a dusting-powder, either alone or mixed with an equal part of boric acid; it is not, however, very energetic when thus employed. The most commonly prescribed sulphur lotion, and one that is often extremely serviceable, is the following, known to most dermatologists as "lotio alba":

℞. Zinci sulphat.,	
Potassii sulphuret.,	āā gr. xxx–ʒiv (2.–16.);
Aquæ,	℥iv (128.).

The most frequently prescribed strength is 1 dram (4.) each of the salts, and when in this proportion and properly prepared, the sediment which forms will constitute about one-fourth the bulk; when shaken, the lotion is milky in appearance, hence the name; it is entirely free from odor. It seems difficult to have it properly made, due doubtless to a deteriorated or a dried-out potassium sulphuret. The weaker strength is prescribed in irritable or markedly inflammatory cases; the strongest when the others have failed to make an impression. If too drying, 1 or 2 minims (0.065–0.133) of glycerin can be added to the ounce (32.). This lotion may be made still stronger, and in sluggish cases more efficient, by having of the zinc sulphate 6 to

20 grains (0.4–1.33) in excess of the potash salt. Sulphuret of potassium, used alone in lotion form, is also of service, but its odor is disagreeable and cannot be entirely disguised; it is prescribed as follows: 20 to 40 grains (1.33–2.65) of potassium sulphuret, 2 drams (8.) cologne water, 1 dram (4.) of benzoin tincture, and water to make 4 ounces (128.); after solution of the salt, filtering. A lotion containing precipitated sulphur 4 drams (16.), glycerin 20 to 40 minims (1.35–2.65), alcohol 1 or 2 drams (4. or 8.), with 4 ounces of water (128.) is also of value. Another sulphur application (Kummerfeld's lotion) of which I can speak highly is that composed of 4 drams (16.) of precipitated sulphur, 10 grains (0.65) of powdered camphor, 20 grains (1.35) of powdered tragacanth, and 2 ounces (64.) each of lime-water and plain water; if well prepared, this is of somewhat thick, creamy consistence, and when applied, makes a good coating. There remain to be mentioned two other sulphur lotions which have proved valuable in my hands, and also in the experience of other specialists: ℞. Sulphur. lot., ʒiv (16.); ætheris, fʒiv (16.); alcoholis, q. s. ad f℥iv (128.). This is often useful in those cases of indurated and sluggish type, and especially when there is a good deal of oiliness. The other is the liquor calcis sulphuratæ; this should be diluted at first with 10 to 15 parts water, and then rapidly increasing its strength according to circumstances, even up to the pure solution; it is more particularly useful in sluggish, indurated, and dermic abscess cases.

Sulphur, usually the precipitated, is also used in ointment form, and in some cases, although a small minority, it acts better than the lotions; it is prescribed in the strength of 1 to 2 drams (4.–8.) to the ounce of benzoated lard. The English are fond of an ointment of hypochlorid of sulphur, a dram (4.) to the ounce (32.) of lard.

Another sulphur-containing salve which often proves beneficial is made as follows: ½ dram (2.) of potassium sulphuret is dissolved in 1 dram (4.) of water, and to this is added ½ dram (2.) of zinc sulphate, and allowed to react; it is then stirred until the sulphureted hydrogen odor entirely disappears, and finally rubbed up with 2 to 4 drams (8.–16.) of cold cream or cold cream and lanolin.

In recent years ichthyol has been added to the therapeutics of acne, and is often useful. It is employed in lotion or ointment form, usually the latter; as an ointment, 1 to 3 drams (4.–12.) to the ounce (32.) of equal parts of simple cerate and rose-water ointment; or as a lotion, about the same strength with water. It seems to be more especially valuable in acne of a pustular and pustulotubercular type, and in the latter its application as a 25 per cent. plaster is often advantageous. A compound ointment containing both sulphur and ichthyol is also of value:

℞. Sulphuris præcipitati,		ʒss–ij (2.–8.);
Ichthyol,		ʒj–ij (4.–8.);
Adipis vel petrolati,	q. s. ad	℥j (32.).

In extremely sluggish cases this same ointment with 1 or 2 drams (4.–8.) of green soap (sapo viridis) to the ounce (32.) will act more energetically; in fact, sapo viridis may be incorporated in any of the ointments named if a more positive action is desired.

Resorcin, in ointment, 4 to 10 per cent. strength, or as a lotion,

from 5 to 30 or more grains (0.32–2.) to the ounce of water, or of water and alcohol, is a clean and often useful application. It should be cautiously used at first in the stronger proportions, as exceptionally it provokes an eczematoid dermatitis. Boric acid is likewise valuable, either in aqueous solution or, better still, as a strong alcoholic lotion; but much more efficacious is a combined lotion with resorcin. The following has been of service:

℞.	Resorcini,	ʒss–ij (2.–8.);
	Acidi borici,	ʒj–ij (4.–8.);
	Zinci sulphatis,	gr. xx–xxx (1.3–2.);
	Alcoholis,	f℥ss (16.);
	Aquæ destillatæ,	q. s. ad f℥iv (128.).

The lotion of calamin and zinc oxid, already referred to, is often of service in the more stubborn inflammatory types, if strengthened with resorcin, 5 to 20 or more grains (0.35–1.35) to the ounce (32.).

Salicylic acid is a remedy for occasional trial in obstinate cases, from 10 to 60 grains (0.65–4.) to the ounce (32.) of ointment, but is often used as an addition—from 10 to 20 grains (0.65–1.3) to each ounce (32.)—to the other ointments already named; it is to be observed that the addition of this ingredient renders any ointment more active.

As already remarked, sulphur preparations are sometimes without effect, or after a time fail to influence the eruption. In such instances, and also in others, the mercurials are not infrequently prescribed. Corrosive sublimate is the most valuable, and is usually the active agent in almost all the patent toilet lotions. It is, of course, to be specially noted that in changing from a sulphur to a mercurial application or the reverse, several days should be allowed to intervene, or else there occurs a temporary slight staining of the skin from the formation of black mercuric sulphid; the disfigurement showing itself more especially by a darkening at the sebaceous gland outlets.

Corrosive sublimate is employed as a lotion, from ¼ to 4 grains (0.016–0.25) to the ounce (32.) of water, or of water and alcohol; and such a lotion is materially strengthened by the addition of from 3 to 8 grains (0.2–0.5) of zinc sulphate to each ounce (32.). The following is a formula frequently used: ℞. Hydrargyri chloridi corrosivi, gr. ij–xij (0.16–0.8); zinci sulphatis, gr. xx (1.3); tincturæ benzoini, fʒij (8.); aquæ, q. s. ad f℥iv (128.). Mix and filter.

Calomel and white precipitate ointments, 3 to 10 per cent. strength, are also at times of service, and can often be alternated with the corrosive sublimate lotion. The constant application of mercurial plaster is often valuable in hard, deep-seated nodules and beginning dermic abscess lesions; and in cases where several such lesions are closely crowded the cataphoretic application of a corrosive sublimate solution (1–3 : 1000) sometimes acts satisfactorily.

Acne of the back or trunk is, upon the whole, treated with the same preparations as that of the face, but much more energetically, and usually with stronger applications. Green soap or tincture of green soap washing daily, followed by the remedial application, and then a dusting-powder of powdered boric acid, with 20 to 30 grains (1.35–2.) of salicylic acid to the ounce (32.), is valuable. The most useful of the applications named for acne of this region is the liquor

calcis sulphuratæ. Resorcin in strong solution—up to 1 dram (4.) to the ounce (32.) of equal parts of water and alcohol—sometimes acts with energy. The most satisfactory method in my hands has been with formaldehyd (40 per cent. solution), using this in sufficient strength to produce considerable irritation or a mild dermatitis, the plain boric acid powder being used as a dusting-powder. The undershirt should be changed often, and boiled or washed, then put in boric acid or weak formaldehyd solution and dried.

The various plans here outlined will usually suffice to cure most cases, but in some, where more rapid action is desired and when patients remain at home or are in the hospital, the exfoliating pastes or salves can be used. Ordinarily the various applications named, used in greater strength and more frequently, will accomplish the same object—more slowly, but with less dermatic inflammation and less disfigurement. The following are the pastes that are most commonly employed for this purpose: ℞. Beta-naphthol, ʒss–ij (2.–4.); precipitated sulphur, ʒiv (16.); sapo viridis, ʒij (8.); and rose-water ointment, ʒij (8.) (Lassar); and ℞. Resorcin, ℥ss (16.); zinc oxid, ʒj (4.); terra silicea, gr. xij (0.7); benzoated lard, to ℥j (32.) (Unna, Isaak). This is smeared thickly on the face, and is best applied spread upon lint; it is kept on for fifteen to thirty minutes, and then rubbed off with a piece of linen or absorbent cotton greased with oil or cold cream, and then the parts washed with warm water and soap, followed with soothing applications, such as cold cream, vaselin, or talcum powder. It is repeated every night, and in a few days sufficient dermatic irritation has been excited, and is followed by desquamation. The same end can be attained, and in a shorter time, by applications made two or three times daily. Repeated applications, two or three times daily, of a 25 to 50 per cent. alcoholic solution of resorcin act promptly and satisfactorily in some cases in bringing about exfoliation; Bronson has also found this plan efficient. In the use of these peeling applications, as soon as the exfoliation and irritation have disappeared, the treatment is again repeated, and so on until the result is obtained.

As with many other skin diseases, the Röntgen rays have been used in this and, according to the observations of Campbell, Zeisler, Hyde, F. H. Montgomery, Varney, White, Bowen, and others, sometimes with brilliant results. I can add my indorsement of its value. Many cases can be managed just as well without it. I reserve it for persistent, rebellious cases. A soft to medium tube is used. The exposures should be made cautiously, at 10 to 15 inches distance and for three to four minutes' duration, and one to three times weekly, and, owing to the possibility of untoward results, if any improvement is shown, it is best to hold to such cautious employment. In extreme and obstinate cases the tube can be brought somewhat closer, and the time of exposure slightly lengthened. For a result in some cases it is often necessary to carry the treatment to the production of a mild erythema, but, if possible, it is much the better to bring about improvement without pushing it even to this extent. In some instances, when too much action is brought about, and exceptionally in other instances, and sometimes after but a few short irradiations dark freckles result, and occasionally an atrophic, old-age,

somewhat wrinkled condition of the skin. Down is also sometimes according to patients' statements, produced, but I am not convinced of this. These blemishes gradually lessen and disappear, except the atrophic wrinkled condition, which, if pronounced, may remain to some extent.[1] Eyes, eyebrows, and scalp should be properly protected. The protecting disk or box can be so placed as to protect the scalp hair, a thin covered tin- or lead-foil band can be placed over the eyes and eyebrows.

Repeated applications of the high-frequency current recently commended, have also been of service in some of my cases, and to a very large extent has supplanted the faradic and galvanic currents; it is applied by means of a flattened hammer electrode, and this is held $\frac{1}{8}$ to $\frac{1}{4}$ inch from the skin; and the application should be sufficiently long-continued as to produce moderate redness or reaction.

ACNE VARIOLIFORMIS.[2]

Synonyms.—Acne frontalis; Acne rodens (Vidal and Leloir); Acne necrotica (Boeck); Lupoid acne; Necrotic granuloma (Johnston); Acné á cicatrices deprimée (Besnier and Doyon); Folliculites cicatricielles nécrosiques (Hallopeau and Leredde); Tuberculide.

Definition.—An eruption characterized by lesions of a moderately superficial, papulopustular type, discrete or grouped, occurring most commonly on the upper part of the forehead and scalp, sometimes on the extremities and other parts, and leaving scars somewhat similar to those of variola.

This name was given by Hebra, and should not be confounded with the similar name occasionally found in French literature and applied to molluscum contagiosum. The various cases described under the names of acne necrotica (Boeck), acnitis, folliclis (Barthélemy), necrosing folliculitis, impetigo rodens (Devergie), are, I believe, allied to or representative of this disease, or are anomalous examples of it. Acne urticata also bears a suspiciously close resemblance, as do also Pollitzer's hidradenitis suppurativa[3] and Professor Duhring's small pustular scrofuloderm. In the same class, clinically at least, could be included the cases described under the names of acne

[1] For details as to apparatus, technique, etc., see article on radiotherapy in the chapter on general remarks on treatment; and for possible detrimental effects see X-ray dermatitis.

[2] References to the chief literature of this and allied diseases are to be found in Bronson's paper (Notes on Certain Pustular Diseases Attended with Atrophy), *Jour. Cutan. Dis.*, 1891, p. 122, and in Fordyce's articles, *ibid.*, p. 128, and (A Contribution to the Pathology of Acne Varioliformis Hebræ), *ibid.*, 1894, p. 152 (based upon 2 additional cases)—all with illustrations; also in Johnston's paper (The Cutaneous Paratuberculoses), *Philada. Monthly Med. Jour.*, Feb., 1899; and in that by Löwenbach (Acne Urticata), *Archiv*, vol. lxix., 1899, p. 29. These several papers together cover the important literature pretty fully.

[3] Hidradenitis suppurativa: Verneuil, "Hydrosadenite phlegmoneuse et absces sudoripares," *Arch. gén. de méd.*, 1864, ii., p. 537, 1865, i., p. 327; Pollitzer's paper, "Hydradenitis destruens suppurativa," *Jour. Cutan. Dis.*, 1892, p. 9, is the most important on this disease, and reviews the literature of similar or allied diseases, with references to date; and Barthélemy's paper, "De l'acnitis," *Annales*, 1891, p. 1 (disseminated; with colored plates), reads as if it were the same disease, and it is generally so considered, but Barthélemy holds a contrary opinion; Dubreuilh, *ibid.*, May, 1892, and *Arch. de méd. exper. et d' anat. patholog.*, Jan. 1, 1893 (2 cases, with review of literature and histologic study). See also case reported by Bronson (acne varioliformis of the extremities), *Jour. Cutan. Dis.*, 1891, p. 121, and histologic examination by Fordyce, *ibid.*, p. 128.

agminata (usually on face, with tendency to grouping), the acne necrotisans et exulcerans serpiginosa nasi (folliculitis exulcerans serpiginosa nasi) of Kaposi (a grouped and spreading papular eruption on the nose, undergoing necrosis or purulent change, and leaving conspicuous scarring),[1] and the acne telangiectodes of Kaposi (vascular, sometimes lupus-like, papules, intermingled with acne, on face, and frequently terminating in scar formation). Unna's ulerythema acneiforme is also believed by Vidal, Leloir, and others to belong to acne varioliformis. The essential characteristics of these various formations are usually discrete, sometimes aggregated, pin-head- to pea- or bean-sized papules or nodules, slightly elevated, rarely deep-seated, with somewhat flattened top, reddish in color, underlying slight necrotic changes with consequent central depression, and, as a rule, comparatively insignificant pus-formation, followed by slightly depressed or varioliform scars.

My own inclination would be to group all these rare and variously named cases under the one heading of acne varioliformis, as that term carries with it a fairly accurate clinical description; that there may be both pathogenic and histopathologic differences is not improbable, but there is a strong family clinical resemblance; their appearances and behavior are much alike, their course more or less persistent and stubborn, the scarring about similar in character, and the plans of treatment advised essentially the same.[2]

Symptoms.—The eruption, which in average cases is rather scanty, consisting usually of from 10 to 30 lesions, begins by the appearance of small pale-red maculopapules or papules, scarcely rising above the surface; they gradually become larger and more elevated, and of a brighter red, which, commonly, however, soon becomes dull red in hue. In general the papule or small nodule is pierced by a hair, which may be merely downy and scarcely perceptible, or on the scalp and other hairy regions, as the face, it is one of the larger hairs; not infrequently, however, it is entirely free from a hairy filament. The lesion is sluggish in its course, and after reaching its acme, which requires several days to a week or two, it often flattens, and the central part shows pustulation, usually slight in character; just as frequently, however, in my experience, no positive suppuration is noticeable, the apex becoming crusted and sinking down. Sometimes the summit is vesicular or vesicopustular. In

[1] Kaposi, "Ueber einige ungewöhnlichen Former von Acne," *Archiv*, 1894, vol. xxvi., p. 82; E. Finger, "Folliculitis Exulcerans Serpiginosa Nasi," *Wiener med. Wochenschr.*, Mar. 6, 1902, with review of the literature. Brandweiner (blastomycosis and its relations to the folliculitis exulcerans serpiginosa nasi of Kaposi), *Archiv*, 1904, vol. lxxi., p. 49, reports a somewhat questionable case, presumably Kaposi's disease (with literature review), in which he found organisms, apparently blastomycetes, and, on this scant foundation, is led to conclude that these two diseases are most probably identical.

[2] Crocker, *Brit. Jour. Derm.*, 1903, p. 292, showed a case (soc'y demonstration) with lesions of "acnitis" of the face combined with lesions of "folliclis" on the elbows and forearms; and the cases shown as folliclis at the Internat. Derm. Congress, at Berlin, 1904, that I saw certainly corresponded to what Prof. Duhring had described as the small pustular scrofuloderm.

See also interesting report ("Folliclis of the Skin and Conjunctiva," *Jour. Cutan. Dis.*, 1905, p. 337) of a case by Anthony, concerning which there had been several of these various diagnoses made. See further an interesting review by C. J. White, "The Modern Conception of Tuberculosis of the Skin," *Boston Med. and Surg. Jour.*, 1905, vol cliii., p. 291, especially the parts bearing upon "acnitis," and "folliclis."

whatever manner the crust results, it is ordinarily quite adherent, and after some days is detached, accidentally or spontaneously, and uncovers a somewhat puckered depression, red and often abraded-looking; this gradually heals, the redness lessens, and the process is at an end, leaving on its site a pin-head- to large pea-sized-, usually rounded, clean-cut, variola-like scar. The lesions vary considerably as to size and to superficial or deep involvement. When matured, they are from small pea- to bean-sized, and in some cases are extremely superficial, scarcely seeming more than crusted abrasions; in others they seem to pervade the whole depth of the corium. They are often close together—almost bunched in some instances, and in these latter the scarring is quite disfiguring. Exceptionally they are grouped in a linear, circinate, and even serpiginous manner. In other cases they are widely apart, and scattered irregularly over the involved region. The course of the disease is essentially chronic, new lesions appearing from time to time. Occasionally, after a variable period of months, spontaneous cure takes place, but, as a rule, it is chronic and persistent.

The favorite or classic sites are the forehead, just at the edge of the hair, and the scalp. Other parts of the face, and especially the bearded region, are not infrequently its seat, either alone or conjointly with the scalp. The eruption is, however, in some instances found elsewhere, especially about the trunk, anteriorly and posteriorly, and more particularly the upper part. Exceptionally it is also found upon the extremities, usually conjointly with face or scalp involvement. In Pringle's[1] patient the disease began in the interscapular region, and only after some time involved the face, and later still extended upward over the scalp. I have had 2 cases under observation in which the eruption was found on face and upper extremities. In many cases there are no subjective symptoms, but in others there is considerable itching, and sometimes sufficiently marked to be an annoying feature. This seems to be present more frequently in the superficial cases.

Etiology.—The malady is encountered in both sexes, and most commonly between the ages of thirty and fifty, rarely under twenty. Syphilis has been considered to be a factor in some instances, but this I believe to be exceptional; most cases are observed in those entirely free from this disease. Sabouraud[2] believes the malady due to the conjoint action of his microbacillus of seborrhea and staphylococci. The latter were also found by Fordyce and by Touton; Fordyce was inclined to consider them of etiologic importance; Touton, that they may be simply accidental. It is not improbable too, as Johnston and a few others have stated, that in some of these cases, as well as in the variously named allied or aberrant forms referred to, instead of a direct microbic cause, the toxins of the organisms, among which are the toxins of tubercle bacilli, may be etiologic; this latter belief indicating a relationship or a place among the tuberculides.

Pathology.—It seems probable that the eruption is the result of microbic invasion. It is to be considered an inflammation of the

[1] Pringle, *Brit. Jour. Derm.*, 1900, p. 298 (case demonstration).

[2] Sabouraud, "L'acné nécrotique," *Annales*, 1899, p. 841 (with histologic and bacteriologic illustrations).

pilosebaceous structures, with ensuing destruction of the follicle and surrounding derma, Sabouraud, as already intimated, believing that it is a secondary infection upon a seborrheic basis. Fordyce is inclined to the opinion that the more frequent occurrence among the poor, and its appearance, primarily at least, in the majority of cases on the forehead, which is exposed to pressure by unclean hat-bands, would suggest the probability of local infection. The pathologic histology has been studied chiefly by Leloir and Vidal,[1] Touton, Fordyce, Sabouraud. Their gross findings are about alike, the principal difference being as to the depth at which the lesion begins or involves, and this is probably owing to the character, size, and age of the lesion examined. The lesions in Pick's[2] case had no connection with the pilosebaceous follicle, and his findings indicate that this is not always the starting-point. Fordyce found that in the earliest stage the lesion had its seat in the superficial derma, in this respect differing from the hidradenitis suppurativa which originates in the subcutaneous tissue. The majority of lesions were perforated by a hair. The earliest changes noted consisted of a dense round-cell infiltration about the hair follicles, generally above the situation of the sebaceous glands. In some of the sections Fordyce found the sebaceous glands surrounded by the exudation, while in others they were quite free. The sweat-glands were uninvolved, and, in fact, outside of the inflammatory zone. The process extends laterally and upward, invading the papillary and subpapillary areas. Cell disintegration and infiltration of the outer root-sheaths occur, and all the layers of the follicle may share in the destruction produced by the inflammatory process. Usually the destructive action is limited to the upper half of the hair-follicle, the lower part and the sebaceous gland remaining almost undisturbed. The affected tissue is gradually separated *en masse* by a process of dry necrosis, but less markedly so than observed in hidradenitis. The staphylococci were found in the lymph-vessels and free in the tissues, and were especially numerous about the middle and deeper portions of the hair-follicles within the external and internal root-sheaths, in the connective tissue about the sweat-glands, and in the subcutaneous connective tissue.

Diagnosis.—Acne varioliformis is to be distinguished chiefly from a pustular syphilid, acne vulgaris, acne urticata, and hidradenitis suppurativa. Its localization, in a large number of cases, to the forehead and scalp is a differential point of value. Its resemblance to a papulopustular syphiloderm is sometimes striking, but the latter is almost always of wide distribution, and is commonly associated with other symptoms of the disease. The evident involvement of the sebaceous gland in acne, with the usually preceding comedo formation, its localization on the face, its course, and the absence of tendency, in most instances, to scar-formation, are points of difference. Acne urticata, however, closely resembles it in some respects, and suggests, as already stated, a close affinity; but this is ordinarily limited to the face, neck, and shoulders, and the scarring is less depressed and variola-like, and it is always itchy. In hidradenitis suppurativa, another closely allied disease, the lesion begins rather deeply as a hard nodule, which gradually increases in size and breaks down; and

[1] Leloir and Vidal, *Traité descriptif des mal de la Peau*, p. 23.
[2] Pick, *Archiv*, 1889, p. 551.

it is rarely seen on the scalp, and is uncommon upon the face. Folliculitis decalvans can scarcely be confounded with it, as this is only seen on hairy regions, commonly the scalp, leaves cicatricial areas of alopecia, and with the periphery studded with minute inflammatory sycosiform pustules—the characteristic lesions of the malady.

Prognosis and Treatment.—As a rule, most cases yield to remedial measures. It is prone to recur. Untreated it persists, sometimes indefinitely, although in other instances periods of quiescence or entire disappearance are noted.

Treatment consists in the use of antiseptic applications, the most valuable being 3 to 6 per cent. ointment of ammoniated mercury, lotions or ointments of resorcin, 5 to 25 grains (0.35–1.65) to the ounce (32.), and salicylic acid ointment of 3 to 5 per cent. strength. Fordyce found an ointment containing sulphur and naphthol curative. The most satisfactory treatment in my experience is a compound lotion of resorcin in a saturated solution of boric acid for the non-hairy regions, and for the hairy parts the resorcin lotion conjointly with the ammoniated mercury salve. The lotion is to be applied to the parts generally, and the salve subsequently rubbed into the lesion. In view of a seborrheic basis being a possible factor, as contended by Sabouraud, occasional remedial application for this disorder after the acne is cured is advisable, as possibly preventing a relapse. As to constitutional measures, these, if called for, are to be based purely upon indications in the individual case.

ACNE ROSACEA.

Synonyms.—Rosacea; Gutta rosacea; Gutta rosea; Acne erythematosa; *Fr.*, Acne rosée; Acné rosacée; Couperose; *Ger.*, Kupferrose; Kupferfinne.

Definition.—A chronic congestive disease of the face, more commonly limited to the nose or nose and immediate neighboring parts of the cheeks, characterized by passive hyperemia, later by slight or marked capillary dilatation and enlargement, and frequently by more or less acne or acne-like lesions, and in some instances tissue hypertrophy.

Symptoms.—The disease begins with slight passing redness of the part, frequently the nose only at first; this appears after exposure to cold or heat, or after hot drinks, or during an attack of indigestion, or it may appear independently of any recognizable influence. The condition subsides, sometimes in minutes, sometimes hours or a day or two. After a variable number of recurrences, or after weeks or a few months, the hyperemia becomes persistent, showing aggravation upon excitement, exposure, etc. In color it is somewhat variable between bright and dull red, sometimes with a venous tint. A slight or marked oiliness of the nose is frequently to be noted; also sometimes enlarged gland openings. Later, upon close examination, permanently dilated capillaries, several or more in number, can be seen, especially toward the alæ. The redness is of slight degree or quite pronounced, disappearing entirely upon pressure; and the part is somewhat colder to the touch than normal. This condition, representing what is usually described as the first stage of acne rosacea, may persist as such, varying slightly in degree, but with little, if any, tendency to extension or to tissue hypertrophy.

In most cases, however, and often conjointly with the earliest appearance of the passive hyperemia, acne and acne-like papules, nodules, and pustules, at first few, later in numbers, may show themselves. Not infrequently the neighboring part of the face within the malar prominences also exhibits the eruption; and in some instances the middle part of the forehead and the chin are likewise the seat of hyperemia and acne lesions. This area—a long oval with the chin and middle forehead as the end boundaries and the malar bones as the side boundaries—is that beyond which acne rosacea seldom extends to any great degree; it may, however, sometimes, though not frequently, present over the entire face. With the acne lesions there is usually noted, about the nose especially, enlarged gland-ducts containing oily or

FIG. 225.—Acne rosacea of a not uncommon type, showing hyperemia, dilated capillaries, and acne or acne-like lesions.

semisolid sebaceous material, and in occasional cases a slight tendency to mild seborrheic eczema. The enlarged capillaries become more numerous and may be seen on all affected parts, more especially, however, the nose and closely adjacent skin. In this picture is to be found what is usually described as the second stage of the disease, and it rarely, as observed in this country at least, goes beyond this. It varies somewhat, and may measurably improve under favorable conditions. The pustular lesions are somewhat or wholly like those seen in ordinary acne, but the papules or nodules, especially about the nose, seem more like tissue indurations, and the suppuration in the pustule is usually close to the surface and rather slight.

In exceptional instances the disease advances; somewhat soft tissue

hypertrophy, diffused or nodular in character, is noted on the nose, more especially toward the end and at the alæ; the glandular openings are large, the blood-vessel hypertrophy more marked, some small varicosities occasionally presenting, and the whole organ is slightly or considerably enlarged, constituting the so-called third stage of the disease. The same characters are usually to be seen, but to a less degree, in the immediately neighboring skin. In some of these cases the disease is limited to this region; in others the second stage conditions are observed conjointly on other parts of the face; and exceptionally third stage hypertrophy is noted on such regions, more particularly the middle forehead and the chin. In rare instances the hypertrophy of the cutaneous and subcutaneous tissue



FIG. 226.—Acne rosacea (rhinophyma) showing marked hypertrophy.

of the nose assumes disfiguring or even immense proportions, and presents more or less lobulation, and, in extreme cases, pendulous masses—**rhinophyma**. In these hypertrophic types the color is often a deep red or purplish red.

As a rule, there are no subjective symptoms, although there are, at times, in those cases in which acne lesions are numerous, some tenderness and soreness, and exceptionally, more particularly in those exhibiting a tendency to seborrheic eczema complication, slight itching.

Etiology.—Acne rosacea furnishes about 3 per cent. of all skin cases—a less relative proportion in dispensary practice than in private practice. It is closely allied to acne in its etiology, except as to the age at which it is observed; the former is not commonly seen before the thirtieth year, and most of the cases observed earlier are usually

of the nose, and associated with or clearly a part or consequence of oily seborrhea of that organ. The disease, in its milder grades, is thought to be more common in women, although I think not so much so as is generally believed; women, being more sensitive to facial disfigurement, seek advice more frequently. The hypertrophic form is rarely seen in women. Disturbance of the digestive apparatus must be considered the most important etiologic element in the large majority of patients, and such disturbance may be due to improper food or improperly cooked food, excessive indulgence in alcoholic drinks, tea, and coffee, etc. A feeble circulation, debility, and gouty diathesis seem also to be of influence. Inordinate use of tobacco is a possible factor. In addition to this indirect action of alcohol, it has also the effect of producing peripheral vascular dilatation, and its free use is responsible for many cases, and doubtless for almost all of those of marked hypertrophic development. It is by no means, however, as many are inclined to believe, the sole cause of the malady, for not infrequently it is met with not only in those of temperate habit, but in total abstainers, even rhinophyma having been observed in the latter (Hebra, Jr.). In women a not unimportant factor is functional or organic uterine disorder, and in such, as well as in others of this sex free from this element, the disease usually is worse at and preceding menstrual periods. Another cause or contributory factor, in some cases, is to be found in intranasal pressure or disease (Seiler, Brocq, Bergh, Sticker) giving rise to vascular and lymphatic obstruction. Inflammation of the hair-follicles (sycosis) just within the nares, by producing constant hyperemia of the integument, also tends to lead toward the disease (Jarisch, Elliot). There are also external factors in many cases, such as lack of cleanliness, cosmetic and other irritants, exposure to cold winds, as with drivers, cabmen, etc., great heat, and the rays of the sun. In some patients a seborrhea precedes or is seen in the course of the disease, and may in some cases have etiologic importance. Unna gives this factor a high place, or rather considers the malady in many instances a seborrheic catarrh, giving it the name rosacea seborrhoica. With others (Jarisch, Hallopeau, Leredde, and others) I believe the seborrheic condition is often secondary.

Pathology.—The first stage in acne rosacea is a hyperemia, probably angioneurotic (Eulenberg, Simon, Auspitz), but in some cases in consequence of a seborrheic process. In consequence of the persistent hyperemia and irregular periodic aggravations the vessels become permanently enlarged, and there is induced, in many cases, a slight hypernutrition of the skin, which has as a result variable hypertrophic changes. The sebaceous glands become involved, nodules, first of a gelatinous and later fibrous character, and acne or acne-like lesions are usually superadded, either secondarily or as a part of the pathologic process. The pathologic anatomy has been studied by many observers (Simon, Biesiadecki, Hebra, Jr., Leloir and Vidal, Rokitanski, Piffard, Elliot, Dohi, and others).[1] The

[1] Piffard (Wagner's paper), *Archives of Clinical Surgery*, 1876–77, vol. i., p. 21; Hebra, Jr., *Archiv*, 1881, p. 603 (with histologic plate and review of literature with references); Dohi (2 cases), *ibid.*, vol. xxxvii., 1896, p. 371.

markedly hypertrophic forms are especially due, in addition to the above, to connective-tissue growth and enlargement of the sebaceous glands. There is usually noted in the third stage a pronounced hyperplasia of the dermic connective-tissue elements. The increased vascular dilatations are partly the consequence of the chronic hyperemia, and partly doubtless to a blocking-off of some of the return vessels from cicatricial formations resulting from follicular suppuration and destruction. In some of the enlarged vessels the walls are thinned, in others thickened, with considerable surrounding connective-tissue hypertrophy. The veins show enlargement, and sometimes resemble cavernous tissue (Leloir and Vidal). The acne or acne-like lesions are, for the most part at least, similar to those of ordinary acne, to which disease it certainly seems to bear relation, although this is of late denied by others who consider that the nodular and pustular lesions are wholly different from those of the latter malady.

Diagnosis.—The diagnostic characters are the redness, dilated capillaries, and, at times, the connective-tissue and glandular hypertrophy, with, in most cases, acne lesions superadded; the limitation to the face, especially the region of the nose, or nose, chin, and middle forehead; the evident involvement of the sebaceous glands in most instances; the absence of ulcerative tendency and the history of the case—these are points of difference which will usually serve to distinguish it from acne, erythematous and seborrheic eczema, lupus erythematosus, tubercular syphiloderm, and lupus vulgaris.

The distinct hyperemic element is wanting in ordinary acne; its distribution is irregular and general over the face, there are, in most instances, numerous comedones, and there is no dilatation of the vessels, and, as a rule, its subjects are younger. Erythematous eczema is never limited to the acne rosacea region, the skin is somewhat inflammatory and infiltrated, with usually slight or moderate scaliness, and troublesome subjective symptoms, and no dilated vessels, and a different history. Seborrheic eczema is frequently seen in this region, but it is a distinctly oily or scaly disease, with no blood-vessel dilatations, and is ordinarily associated with a seborrhœa capitis; there is often variable itching or burning. Lupus erythematosus is sharply defined, with, as a rule, an elevated border; there is slight or moderate scaliness, a tendency to central thinning, and atrophy. Both the tubercular syphiloderm and lupus vulgaris may bear slight resemblance to the hypertrophic nodular acne rosacea, but they generally tend to ulcerative action and scarring or to atrophic change; lupus vulgaris usually begins in early life, and the lesions of the syphiloderm almost invariably are noted to be circinate or segmentally grouped; dilatation of the capillaries is not an essential feature of either, and the history is different in both diseases.

Prognosis.—The disease is obstinate, but all cases are favorably influenced by treatment; the mild and moderately developed types, under proper management, with the cordial and persistent cooperation of the patient, are usually curable, several months, and sometimes longer, being required, progress toward recovery being more rapid at first. The removability of the etiologic factors will naturally have much to do with the character of the prognosis given, both as

to immediate relief and freedom from recurrence. The hypertrophic forms admit of improvement, and even in those of extreme development much can be accomplished and the disfigurement materially reduced by surgical procedures.

Treatment.—In great measure this is, excepting as to the dilated capillaries and connective-tissue hypertrophy, closely similar to that of acne, both as to its constitutional management and local medication. Considering the possible etiologic factors mentioned, the chief attention is to be directed to supervising the diet, improving the digestion, a free action of the bowels, and the avoidance of the predisposing and exciting influences. In women inquiry is to be made as to the menstrual function and as to possible functional or organic uterine disease. The diet should be plain but substantial, especially avoiding all indigestible food, such as mentioned under acne; the avoidance of more than slight indulgence in tea, coffee, and cocoa, especially the first named, and the absolute prohibition of alcoholic drinks in any form. The use of tobacco should also be kept within moderate limits. As there are no special remedies, the constitutional treatment, if called for, is to be based upon a correct appreciation of the etiologic factors in the individual case, digestives, laxatives, tonics, and cod-liver oil being most usually prescribed. The morning saline mixture and the compound cascara mixture to be found under acne are often of service in those constipated and of weak digestion. In the latter a prescription of hydrochloric acid, strychnin, and pepsin is also of value, along with the daily or occasional administration of a laxative. Ergot and ichthyol are two drugs which have some support for internal administration in this disease, the former in 20- to 60-minim (1.35–4.) doses, and of the latter (Unna, Morris, and others) 3 to 10 minims (0.2–0.7) three times daily, but I have not been able to get the good from their use that others have.

The external treatment of the earlier stages and the hyperemic and inflammatory lesions of acne rosacea are, as already stated, very similar to that of acne. Any existing intranasal pressure or follicular inflammation or a seborrhea should receive attention. The same general directions as to preliminary measures, such as the soap-and-water washing and hot-water sponging, are to be advised; occasional cases in which the slightly scaly seborrheic element is more or less pronounced, as a rule, only admit of the sparing use of soap, which in these and in all others should be employed at night. Applications of the galvanic current are also useful (see acne). Massage is not advisable. While the remedial applications are those employed in acne, there are, however, several of these which, in my experience, are more generally useful than others. In the cases of considerable hyperemia and of wide-spread distribution, of an irritable type, and in which acne lesions are somewhat numerous, a most admirable beginning application is that of the calamin-zinc-oxid lotion. This is to be dabbed on freely and allowed to dry on; in the morning the parts washed off according to the usual custom of the patient, and the lotion again applied; if the patient goes out, the powder which dries on can be gently wiped or rubbed off. Or in the morning a plain talcum powder, made skin color by the addition of a few grains (fractional part of

a gram) of calamin to the ounce (32.). Resorcin added to this lotion, 1 to 5 or more (0.065–0.35) grains to the ounce, increases its strength. This treatment is to be continued as long as it materially benefits, and then recourse be had to the lotion of zinc sulphate and potassium sulphuret, each 20 grains to 2 drams (1.35–8.) to the 4 ounces (128.) of water. In many of these irritable cases this wash can be used from the beginning in the weakest strength, and gradually increasing if it does not irritate. Very often this lotion with 1 minim (0.065) of glycerin to each ounce (32.) will add to its permissibility in irritable types. Later, and in sluggish cases, alcohol, ½ to 1 dram (2.–4.) to the ounce (32.), can be added to advantage, and in such cases very often the preparation, when improvement begins to lag or ceases, can be rendered more active and again beneficial by having an excess of 2 to 6 grains (0.13–0.4) of zinc sulphate over the potassium salt in each ounce (32.). Very often the plan of using the calamin-zinc-oxid lotion in the morning and the stronger wash in the evening has served me well; or they can be used on alternate nights. If irritation or slight scaliness ensues, the wash can be used at night, and cold cream in the morning, wiping it off on going out.

Another application which is especially useful in many instances is the Kummerfeld lotion, formula for which is given under acne; it should be used at night, freely, and several times daily when possible, and occasionally intermitted if roughness or irritation of the skin results; or now and then replacing it with an application of cold cream, or with the calamin-zinc-oxid lotion. In this disease, too, probably even more than in acne, the liquor calcis sulphuratæ (Vleminckx's solution) will be found of benefit, using it diluted with 10 to 15 parts of water at first, and rapidly increasing in strength until irritation or trifling exfoliation is produced, and then reducing slightly and continuing, intermitting occasionally, if necessary, as with other lotions referred to. In those cases in which there is considerable oily seborrhea the sulphur-ether-alcohol lotion (see acne) is often more serviceable. Other lotions referred to in treating acne can also be tried from time to time in obstinate types in which the above are without result or cease to benefit. In this disease, as in many others, an application benefits for a time only, and then is to be set aside; its resumption later will often again prove of value.

Ointments are not so generally useful as lotions, although progress is more rapid in some cases when one temporarily gives place to the other. They are to be applied as described in acne. Precipitated sulphur ointment, 30 grains to 2 drams (2.–8.) of sulphur to the ounce (32.) of cold cream or benzoated lard, acts satisfactorily, for a time at least, in some instances. The ointment made with a strong solution of zinc sulphate and potassium sulphuret, referred to in acne, is also sometimes valuable and deserves a higher position ordinarily than the plain sulphur ointment. Ichthyol (Unna and others) in ointment and lotion of 10 to 25 per cent. strength, is often of striking advantage in this disease, but often fails to make an impression, and exceptionally aggravates; and it is difficult to say in what particular case its best effects are to be expected—probably in those of markedly

hyperemic type, and in which suppurative lesions are numerous. It will often act more satisfactorily as a lotion than as an ointment.

White precipitate and calomel ointments, 20 to 60 grains (1.35–4.) to the ounce (32.) of ointment, have also had a place in the treatment, but are, as a rule, much inferior to the applications already mentioned. Corrosive sublimate lotions (see acne) are at times of service. Mercurial plaster kept applied (Hebra, Kaposi, Neumann) as constantly as possible is often of value in cases in which somewhat hard nodular or papular lesions are present. Ichthyol plaster, 25 per cent., is also of service in such instances. Tannic acid, in lotion or ointment form, is occasionally useful; the former, 5 to 60 grains (0.35–4.) to the ounce (32.) of equal parts of water and alcohol, and the ointment, of 10 to 20 per cent. strength; the lotion is the more valuable. I have used it in the type in which the disease was more or less strictly limited to the nose, with some oily seborrhea and enlarged glandular openings. In this class of cases, too, electrolysis, repeated every few weeks, freely used within the openings and the interspaces, is an adjuvant of considerable value, employing a current of 2 to 5 milliampères; it produces irritation lasting a day or two, and the condition looks temporarily worse. Multiple punctures with a sharp-pointed bistoury are also of value in these cases, but probably no more so than electrolytic punctures; bleeding should be favored by hot-water compresses, followed later by cold compresses. The application of electricity (Cheadle, Piffard, and others) is sometimes beneficial, the galvanic current being the more valuable. It is applied in the same manner mentioned in acne. The Röntgen ray treatment is another recent plan variously commended, and has sometimes proved useful in some of my cases, especially in those of markedly dilated and pustulous gland openings, and those of a hypertrophic character; it is applied in the same cautious manner as in acne. The high-frequency current is also occasionally of positive value.

Under these plans, given above, the most disfiguring elements of average cases—the diffused hyperemia and the acne lesions—can be removed. There remain in many instances, however, the dilated vessels, and in a less number tissue hypertrophy, which require other treatment. The former can be destroyed either with the knife, cutting transversely at several points, or cutting down their length; by a Paquelin microcautery (Unna, Elliot), or preferably and most satisfactorily by electrolysis (Hardaway and others).[1] The electrolytic method is essentially the same as employed in the removal of superfluous hairs (*q. v.*); the needle may, if the vessel is short, be inserted along its length, or if long, may be inserted at several points in its course. It is usual to attach the needle to the negative pole, and, upon the whole, this is the most satisfactory, but in occasional rebellious cases I have used it attached to the positive electrode, and found it sometimes effective; in the latter instances a gold or iridoplatinum needle is to be used, for reasons stated (see hypertrichosis). The strength of the current required is from $\frac{1}{2}$ to 2 milliampères—about 2 to 6 or 8 wet cells and 3 to 12 dry cells. The needle is kept

[1] Hardaway, *Arch. Derm.*, vol. v., 1879, p. 356.

in from several to thirty seconds, according to effect; the blood is noticed to run up the vessel, and the latter thus apparently disappears, but as soon as the needle is withdrawn and the gases generated are absorbed, the blood, if the vessel is long, returns part way; new punctures are to be made in such. The appearance of a distinct blanching at the point of insertion, enlarging to the size of a small pea, should be a signal for withdrawal of the needle, otherwise too much action may follow. Very often, from the resulting hyperemia after a series of punctures, the vessels, if at all near to each other, can no longer be detected, and further operations must then be postponed. Hot-water applications should be made immediately afterward for a few minutes, followed by cold. The electrolytic procedure is to be frequently repeated until the destruction of the vessels ensues. Unfortunately, there often exists a tendency to new vessel-formation or dilatation.

The slight connective-tissue hypertrophy can sometimes be reduced by multiple punctures and scarification (Hebra, Neumann, Veiel, Squire, and others) and by electrolytic punctures (Hardaway); whatever the method, it must be frequently repeated. The moderately hypertrophic and also extreme cases I have sometimes been able to reduce by electrolytic destruction, both by introducing the needle down into the glands (Brocq) and through the skin between the glandular openings, using a current of 3 to 6 milliampères,—about 4 to 10 wet cells, and 6 to 20 dry cells,—and allowing the needle, attached to negative pole, to remain in for twenty to forty seconds, in order that slight destruction may result and cicatricial contraction ensue. Minute galvanocautery punctures (Unna's micro-Paquelin or galvanocautery) are also useful. In these extreme cases of excessive connective-tissue growth, however, the most rapid, and usually quite satisfactory, treatment is by ablation or decortication with the scissors or knife; the condition rarely recurs.[1]

4. DISEASES OF THE SWEAT-GLANDS.

HYPERIDROSIS.[2]

Synonyms.—Excessive sweating; Idrosis; Ephidrosis; Sudatoria; Polyidrosis; *Fr.*, Hyperidrose.

Definition.—A functional disturbance of the sweat-glands characterized by an increased production of sweat, and which may be local or general, slight or excessive, acute or chronic.

The general sweating, which may be a part of a serious illness, symptomatic in character, and common in such diseases as acute rheumatism, malarial fever, tuberculosis, Graves's disease,[3] etc.,

[1] Lassar, "Ueber Rhinophyma," *Dermatol. Zeitschrift*, 1895, vol. ii., p. 485.

[2] An extremely valuable contribution on hyperidrosis and the several varieties of morbid sweating is that by Bouveret (Des sueurs morbides), *Thèse de Paris*, 1880, with a résumé of literature and references; also interesting paper and review of the entire subject and several varieties by Pooley, "Anomalies of Perspiration," *Ohio Med. Recorder*, vol. v., 1880–81, pp. 241, 289, 337, 385, and 441, containing a large number of collected cases, with many literature references.

[3] Dore, "Cutaneous Affections Occurring in Graves's Disease," *Brit. Jour. Derm.*, 1900, p. 353.

although especially interesting in view of the possible excretion of microbic elements or toxins, as indicated by Eiselsberg,[1] Brunner,[2] Geisler[3] and others, scarcely belongs to the domain of dermatology. It is chiefly with those cases which we, in the present state of our knowledge, look upon as idiopathic, that our interest lies, and more especially the local forms which naturally gravitate to dermatologic practice.

Symptoms.—General hyperidrosis as an idiopathic affection is not uncommon, but mostly as a chronic condition, seemingly natural to certain individuals. The sweating may be moderate or excessive, and always more marked, as a rule, on those regions where local hyperidrosis is usually manifested, as axillæ, genitocrural region, hands, and feet. The slightest exertion serves to increase it greatly, and while always most profuse in the hot season, is quite excessive during the winter as well. During the former period especially, an occasional associated miliaria or erythema intertrigo, or even an eczema, due to the irritating action of the moisture itself, as well as to the chemical changes which the sweat may undergo, is not uncommon. Boil-formation also seemed to be favored in such individuals. While the secretion may not have an odor at first, unless frequent changes of linen are made and frequent baths taken, it usually soon becomes offensive (bromidrosis). In rare instances, instead of the sweating being general, it is limited to a small portion of the surface or to the half of the body unilaterally, as described by Teuscher[4] and others, or, as in a case reported by Kaposi,[5] to the upper half or part of both sides. Cases of sweating limited to half the face are less rare, and have sometimes shown an association of the lesions of hydrocystoma.

The chief interest lies, however, in the local forms, especially the excessive sweating of the hands and feet, and for which professional advice is most frequently sought. It often exists on the hands or feet alone, but not infrequently conjointly. The condition limited to both hands (hyperidrosis manuum) is not uncommon, more especially about the palms, and the sweating may be persistently copious or come on at irregular times or in consequence of some excitement or perturbation. The hands are noted to be clammy and cold. In a case recently under my care, at times the hands were perfectly dry, when suddenly, without apparent cause, they would become rapidly wet, the sweat accumulating in drops and dripping on to the floor. In exceptional instances a few deep-seated vesicles are occasionally seen about the fingers and palms (see pompholyx). Such persons are

[1] Eiselsberg, "Nachweis von Eiterkokken im Schweisse eines Pyæmischen," *Berlin. klin. Wochensch.*, 1891, p. 553.

[2] Brunner, "Ueber die Ausscheidung pathogenes Mikroorganismen durch den Schweiss," *ibid.*, 1891, p. 505, and *Arch. klin. Chirurg.*, vol. lxxx., No. 2.

[3] Geisler, "Ueber die Ausscheidung der Typhusbacillen im Schweisse," *Wratsch*, 1893—abs. in Baumgarten's *Jahresbericht*, 1893, vol. ix., p. 238.

[4] Teuscher, *Neurolog. Centralblatt*, 1897, p. 1028 (records several cases of his own and cites other cases with literature references).

[5] Kaposi, "Hyperidrosis spinalis superior," *Archiv*, vol. xlix., 1899, p. 321 (patient a boy aged fifteen, sweating since six; kyphoskoliosis since his eighth year). See also interesting paper by Caldwell (a review of the neuroses of the pneumogastric nerves, with some account of the anatomy, physiology, and pathology of these nerves; also of the vaso-centers and sweat-centers), *Virginia Med. Monthly*, vol. v., 1878–79, p. 565.

unable to wear gloves more than from a few minutes to an hour or so, without their becoming permeated with moisture; and everything touched by them is apt to show a greasy mark. As a rule, the condition is most marked when the patient is tired, nervous, or exhausted. A slight or moderate tylosis of the palms may be associated or develop gradually.

Sweating of the feet (hyperidrosis pedum) is a troublesome and often a disgusting form of localized hyperidrosis. It varies in degree: sometimes moderate, at other times excessive. The feet are constantly damp or wet, the socks or stockings become moist or drenched a short time after they are put on, and the shoe itself often, in severe cases, becomes rapidly water-soaked. It is especially pronounced on the sole and between the toes, and may be limited to these parts. The skin is apt to be macerated and soggy, and exceptionally pompholyx lesions are seen from time to time. In many cases—those of the more severe type—the skin of the sole and neighboring parts is noted to be pinkish-red, sometimes with a violaceous tinge, somewhat puffy or irritated, and in some cases at the border, which is usually sharply defined, slightly inflamed, and showing a few ill-defined vesicular or flattened bullous lesions; or the skin at the edge may be simply macerated and abraded. Unless the foot-wear is frequently changed, an offensive odor soon arises, although in these cases the sweat secretion as it is freshly poured out is free from such characters—differing in this respect from bromidrosis.

In the axillary and genitocrural regions the sweat is often noted to be excessive, and necessitates, more particularly in women, the wearing of dress-shields to prevent soiling of the garment, but which, however, tend to increase the secretion. In extreme cases maceration is also likely to arise, and not infrequently chafing or an eczematous irritation presents as a complication. In these regions the sweat often undergoes rapid chemical change, and a heavy, offensive odor is developed.

The localized forms, just described, as with the general forms, may be acute or chronic in character—more usually the latter. It is naturally more marked during warm weather or after active work or exercise. It may vary somewhat in degree from time to time.

Etiology.—Idiopathic excessive general hyperidrosis is, as a rule, associated with debility, and probably in many cases is in reality merely symptomatic of some underlying unrecognized disease, such as incipient Graves's disease, tuberculosis, malaria, etc. The causes in the local forms are doubtless varied from that of pure idiosyncrasy to grave systemic disturbance; as an example of the former may be mentioned a case of a woman reported by Hutchinson,[1] in whom the slightest indulgence in tea-drinking provoked hyperidrosis of the feet. In some families there is a hereditary tendency to somewhat free general perspiratory secretion, and this is noted to be a factor in some of the localized cases. It is a well-recognized fact that in those of impaired vigor, and especially after some debilitating disease, such as influenza, which leaves great prostration and nervous weakness, that excessive sweating is most frequently observed—both the

[1] Hutchinson, *Archives of Surgery*, 1899, p. 56.

general and local forms. Anything, in fact, which depresses the nervous tone may be of etiologic import. The tendency to abnormal sweating and excitability of the perspiratory function is often observed in neurasthenics. Physical or mental excitement is apparently the starting impetus, and in developed cases always an aggravating and exciting factor. Lesser,[1] as also Morris, Norman Walker, and Pringle, has noted that most patients with hyperidrosis of the feet are "flat-footed;" and Hardaway and Allison[2] also believe that the malady is favored by malpositions of the feet, especially flat-foot and Morton's foot. While the local form may be seen at any age, in both sexes, and in all ranks of life, in my experience it is more common between the ages of twenty and forty, and more frequent in males. Sweating of the feet seems most frequent in those whose occupation necessitates prolonged standing. Circulatory disturbances are observed to be influential in some instances. Some cases of the localized forms have been recorded which were due to some nerve irritation or injury, central or truncal. It has also been noted in connection with malaria.

Pathology.—The close relationship of the nervous system to the sweat secretion, and therefore to its pathologic increase, is well known, both clinically and experimentally. The observations of Fränkel,[3] Raymond,[4] and Ebstein[5] show the association of unilateral sweating with changes in the cervical ganglia; and those of Bloch,[6] Bouveret, and others with disease of the cerebral cortex, as well as by Windscheid,[7] Bloch, and others in connection with facial paralyses. Cases of unilateral sweating of the face associated with headache and flushings have been observed by Campbell[8] and Jamieson.[9] It is also well known, through the experiments of Claude Bernard, that hyperidrosis follows paralysis of the sympathetic; and Brown-Séquard and others have shown that excitation of the sensory nerves would provoke sweating. In addition, Weir Mitchell's[10] observations as to localized sweat disturbances after gunshot injuries, and also Remak's[11] after traumatic neuritis, are added proofs. An added instance to many others not here referred to is that by Dehio,[12] who found in a case of erythromelalgia with hyperidrosis that after resection of the ulnar nerve not only did the excessive sweating cease, but anidrosis followed. It is highly probable, therefore, as stated by Crocker,[13]

[1] Lesser, "Schweissfuss und Plattfuss," *Deutsche med. Wochenschr.*, 1893, p. 1070.

[2] Hardaway and Allison, "Warty Growths, Callosities, and Hyperidrosis and Their Relation to Malpositions of the Feet," *Jour. Cutan. Dis.*, 1906, p. 127.

[3] Fränkel, *Zur Pathologie des Halssympathicus*, Inaug. Dissert., Breslau, 1874.

[4] Raymond, "Des ephidroses de la face," *Arch. de Neurologie*, 1888, pp. 51 and 212 (a good paper with review of the subject and bibliography).

[5] Ebstein, "Ueber einen pathologisch-anatomischen Befund am Halssympathicus bei halbseitigem Schweiss," *Virchow's Archiv*, 1875, vol. lxii., p. 435.

[6] Bloch, "Contribution a l'étude de la physiologie normale et pathol. des sueurs," *Thèse de Paris*, 1880.

[7] Windscheid, "Ueber den Zusammenhang der Hyperidrosis unilateralis mit patholog. Zuständen des Facialis," *Münch. med. Wochenschr.*, 1890, p. 882 (several cases, with review of similar cases and literature references).

[8] Campbell, *Flushing and Morbid Blushing, their Pathology and Treatment*, London, 1890, p. 50.

[9] Jamieson, *Brit. Jour. Derm.*, 1893, p. 137.

[10] Weir Mitchell, *Injuries of Nerves and their Consequences*, Philada., 1872, p. 172.

[11] Remak, "Neuritis and Polyneuritis," Nothnagel's *Specielle Pathologie und Therapie*, vol. xi., 1. Hälfte, 1899, p. 130.

[12] Dehio, "Ueber Erythromelalgie," *Berlin. klin. Wochenschr.*, 1896, p. 817.

[13] Crocker, *Diseases of Skin*, third edit., p. 1090.

that injury or disease which, in any way, either directly or indirectly, disturbs the function of the sympathetic of the affected region, is the proximate cause of the excessive secretion. Very often, however, the underlying pathologic factor is not demonstrable or discoverable.

Robinson,[1] who examined a number of sections from the palm, failed to detect any abnormality either in the size of the glands or in the glandular epithelium. Virchow[2] found, however, in cases of hyperidrosis connected with phthisis, the glands enlarged and the epithelium in a state of fatty degeneration. While the amount of sweat discharged in a day may be considerable, it does not differ chemically from normal sweat.

Prognosis.—The prognosis must be expressed with reservation. As a rule, nothing can be done in the moderate type of generalized sweating, a condition apparently normal in some people. In the excessive generalized variety, usually insidious or acute in developing, the outcome as to betterment depends upon the cause. Localized forms are also persistent and obstinate, although many respond to treatment; the foot cases, if not of too long duration, in my experience offering the most promising chances for relief, in a number of such instances permanent cure having been effected. Change of treatment—local applications especially—is often necessary before a result is attained. Paroxysmal sweating is less favorable than the continuous type. Relapses are, however, not uncommon. In all cases of these localized forms much can be done in the way of improvement.

Treatment.—The excessive general sweating accompanying or following the systemic fevers and debilitated states of the system demands for its care or cure treatment of the particular predisposing or causative condition. Limited areas of sweating occasionally seen in malarial and nervous diseases are likewise to be treated upon general principles. Astringent liquid applications, such as below indicated for regional hyperidrosis, but usually somewhat weaker, are, in a measure, palliative; they can be sprayed on or dabbed on; and sometimes, when followed by one of the dusting-powders, the effect is more marked. By such measures the tendency to miliaria and chafing noticed in these subjects, especially in stout people, can often be kept in abeyance. In generalized cases Fox[3] has had good effects from rubbing on the skin a 1 per cent. alcoholic solution of quinin. In instances of doubtful or unrecognized cause, such systemic remedies as ergot, belladonna, gallic acid, the mineral acids, quinin in full doses, and, when the health is enfeebled, tonics should be tried. A teaspoonful of precipitated sulphur, twice daily, with, if the laxative action is too marked, an astringent, has been extolled by Crocker. I have noticed a favorable action in a few cases.

In the localized forms external applications are essential and more positive in effect than any constitutional treatment that may be prescribed, but the latter should not be ignored in the management. Frequent washing is essential. The external treatment consists in the use of lotions, powders, and ointments. Astringent lotions of zinc sulphate, tannic acid, and alum, from $\frac{1}{2}$ dram (2.) to an ounce (32.) to the

[1] Robinson, *Manual of Dermatology*, p. 77. [2] Quoted from Robinson, *loc. cit.*
[3] G. H. Fox, *Philada. Med. Times*, 1883–84, vol. xiv., p. 849.

pint (500.) of water, are among the most useful at our command, especially the last two. They are to be applied at least twice daily, the parts first having been washed or sponged off; following the lotion a dusting-powder of boric acid with from 5 to 30 grains (0.32–2.) of salicylic acid to each ounce (32.) may be freely dusted over. The free use of a dusting-powder alone, such as that just named, will be found beneficial and sometimes gives considerable, and occasionally complete, relief, especially in the axilla.

Weak lotions of formaldehyd or formalin (40 per cent. solution of the gas), 1 : 100, can often be used with advantage for cleansing purposes, and not infrequently with some therapeutic influence also; but for the latter stronger applications can be carefully used, increasing the strength gradually, the object in view being the production of a slight surface hardening, rather than positive irritation. Duhring[1] warmly commends the application of tincture of belladonna, diluted or full strength, care being observed in its use as to toxic effects. Crocker also speaks well of belladonna as an ointment or liniment. In foot cases, in which there are no abrasions or irritation, Lesser[2] speaks highly of Frédéricq's method of dusting powdered tartaric acid in small quantity in the socks. It is to be employed cautiously in those of delicate skin. I have personally had no experience in its use. Morrow,[3] after reviewing the several methods, states that in foot-sweating he has obtained the best results from the employment of foot-baths of a strong solution of extract of pinus canadensis every night, and the use of powdered boric acid, or salicylic acid mixed with lycopodium, oxid of zinc, or other inert powder constantly applied inside the stockings and shoes. In fact this latter use of boric acid, with or without the addition of salicylic acid, should be employed as an adjuvant whatever the main plan adopted. This is an essential part of Thin's method, useful in this affection, as well as in bromidrosis, for which he especially advises it.

The most valuable ointments in the treatment of hyperidrosis, which are more especially applicable when the disease is about the feet, are diachylon-ointment, advised by Hebra, and tannic acid ointment. The latter I have used with success in a number of cases, and while not equal in value to the diachylon salve, is more readily obtained than a good preparation of the latter. The method of application is the same. The tannic acid ointment consists of from 1 to 2 drams (4.–8.) of tannic acid, with enough prepared suet and petrolatum to make an ounce (32.). The parts should first be washed with soap and water, rinsed, and rubbed dry with a soft towel; then the ointment selected, spread thickly on lint or other suitable material, should be closely adapted to the surface, and a bandage employed to keep it in place. This dressing is to be reapplied at the end of twelve hours, but instead of washing the parts they are then merely to be rubbed dry with a dusting-powder and towel; this is to be repeated

[1] Duhring, *Diseases of the Skin*, third edition, p. 138.

[2] Lesser, *Hautkrankheiten*, tenth edit., 1900, p. 180.

[3] Morrow, *Jour. Cutan. Dis.*, 1887, p. 68 (gives a review of several methods—those of Brandon (liquor anti-hidrorrhoicus), of Frédéricq (finely powdered tartaric acid), and Stewart (permanganate of potassium solution and lead plaster)).

for a period of from ten days to two weeks. The epidermis usually exfoliates after the tannic acid treatment—almost invariably after that by diachylon-ointment. At the end of this time the parts may be again washed, and subsequently the dusting-powder used freely twice daily for one or two weeks. This plan of treatment is often successful, but at times a repetition is found necessary; in other cases it relieves, but fails to cure. For other plans the reader is referred to bromidrosis.

In the localized forms, but more especially of the hands, I have observed in some instances benefit derived from local applications of the faradic and galvanic current. Occasional exposure to the X-ray has also had a drying influence in the few instances in which it was tried. Following Hardaway and Allison's observation, any existing malposition of foot should be corrected.

ANIDROSIS.

Synonym.—Fr., Anidrose.

Definition.—A functional disorder of the sweat-glands characterized by diminution or suppression of the sweat secretion.

Symptoms.—This is rarely, if ever, seen as an idiopathic condition, but it occurs to a varying extent in certain systemic diseases, as in diabetes, and also in some affections of the skin, such as ichthyosis, eczema, pityriasis rubra pilaris, and the like; also in the affected areas in anesthetic leprosy, scleroderma, keloidal growths, etc. In these cases, however, the glands resume their normal activity as soon as the skin returns to its healthy state. Localized sweat suppression has been observed to follow nerve injuries in some instances; and diminished or temporarily suppressed secretion has also been noted as a symptom of some of the graver nervous maladies. In certain persons, however, the skin is noted to be abnormally dry, the sweat-glands apparently being in a state of inaction. In such the integument, unless frequently washed and oiled, and particularly in the cold season, is apt to be slightly harsh, approaching closely to the mildest form of ichthyosis—which it in reality may be. These subjects are frequently, in my experience, sufferers from pruritus, especially during the winter time (pruritus hiemalis); and also not uncommonly after baths (bath pruritus). A dry skin is often noted also to predispose to eczema, and if the parasitic theory of that disease be accepted, it can be readily seen, from the dryness and tendency to cracking of the cuticle and the absence of the oily coating resulting from proper action of the sweat- and oil-glands, that easy lodgment could be effected.

Treatment.—This is to be based upon general principles: warm and hot water or vapor baths, general toning up of the patient, free drinking of liquids, warm clothing, and the careful administration of jaborandi and other diaphoretics. In most cases not much can be accomplished beyond palliation. In some instances the resulting dryness and harshness of the skin are to be remedied by the scanty use of oily or ointment applications.

BROMIDROSIS.

Synonyms.—Osmidrosis; Stinking sweat; *Fr.*, Bromidrose; *Ger.*, Stinkschweiss.

Definition.—Sweat secretion of an offensive odor, either primarily or secondarily from some change after excretion.

Symptoms.—While bromidrosis is most frequently associated with increased secretion (hyperidrosis), it is not necessarily so. The whole body sweat of some persons, even if normal in quantity, possesses a heavy, disagreeable odor, and this is habitual with them, and is even noticeable, but naturally to a less extent, immediately after bathing. In most instances coming under observation the regions commonly involved are the axillæ, genitocrural regions, and feet; the last is most frequent, or is the one for which advice is generally sought. As a rule, it is associated with increased sweating, but this may not be unusually large in amount, as observed in hyperidrosis; it is sufficient in most cases, however, to keep the stockings and shoes damp and the soles of the feet moist and sodden looking. In other instances the secretion is excessive. In addition to the symptoms sometimes presented in cases of hyperidrosis—tenderness, puffiness, pinkish-red periphery, occasionally with vesicles or blebs, at the sides of the foot, just on or close to the edge of the sole—there is an intense, penetrating, characteristic odor, pathognomonic to one who has once known the smell. It is hard to describe, and has been variously likened to the odor of an uncared-for goat, putrid cheese, stale urine, etc. A room or car in which such a patient is or has been soon becomes offensive, and the odor holds for a long time after his exit. The axilla is also often the seat of abundant perspiration with disgusting smell, but never to the same extent nor of the same penetrating and peculiar character as that of the feet.

Etiology and Pathology.—The same factors are to be considered etiologic in this disease as in hyperidrosis, to which it is closely allied. Chlorotic, anemic, and nervous individuals are its most common subjects. It is more frequent between the ages of twenty and forty, and in those who are obliged to stand a greater part of the day, and whose life is within doors. The ingestion of certain drugs is known to give the sweat peculiar odors—some not necessarily offensive. Thus the odors of asafetida, sulphur, onions, garlic, are noted in this secretion as well as exhaled by the lungs; musk, copaiba, benzoic acid, etc., also are detectable in the perspiration. Hammond[1] recorded several cases of nervous disorders in which the odor of violets and pineapple was given off during paroxysms or emotional attacks. It is known, too, that in various systemic diseases the sweat secretion has an odor peculiar to each, as in smallpox, cholera, typhoid, etc.[2]

[1] Hammond, "The Odor of the Human Body as Developed by Certain Affections of the Nervous System," *Med. Record*, vol. xii., 1877, p. 460.

[2] See admirable paper by Monin, "Sur les odeurs du corps humain," Paris, 1885, full abstract translation in *Jour. Cutan. Dis.*, 1885, p. 211. This considers the various human odors in health and disease, and from certain foods and drugs, and in individuals of different climes and nationalities.

Hebra believed that the odor does not reside in the sweat as secreted, but that it is due to some chemical change after excretion, and this doubtless is true in most instances. Thin [1] also took this view, and was, moreover, of the opinion that the odor is not in the feet themselves, but in the socks and shoes, in which the secretion has soaked, and in which develop bacteria—bacterium fœtidum—in large numbers. According to Crocker, similar micrococci can generally be found between the toes without accompanying bromidrosis. Parkes [2] looks upon the foot-wear as the cause, as it has been noted that soldiers with uncovered feet never present the disease. The most probable source of the odor is the decomposition of the fatty acids of the sweat, to the rapidity of which the bacterium fœtidum may materially contribute; the sweat secretion containing some oil, as Unna and Meissner have pointed out.

Prognosis and Treatment.—As the troublesome cases of bromidrosis, those associated with increased sweating, are probably closely analogous to hyperidrosis, or, in most instances, simply examples of the latter with the secretion undergoing rapid decomposition, spontaneously or from an added external bacterial factor, the prognosis is essentially the same as in that disease. The foot cases, which are, as a rule, those which apply for treatment, can always be much benefited, and if an acquired condition of not too long duration, a cure is usually possible. Absolute cleanliness—frequent ablutions—and frequent change of the foot-wear are essential; the subject of the affection should have several pairs of shoes, changing daily, so that the pair worn can be aired or remain unused for a few days before they are again worn. The treatment is practically the same as that employed in hyperidrosis (*q. v.*), the best plans among those there named being with boric acid powder and the ointment method. Thin strongly commended the treatment with boric acid; his plan is as follows: The feet are frequently washed with a saturated solution of boric acid; the stockings changed often, and washed in the solution and dried; cork soles, which are also soaked in the solution and dried, are worn in the shoes; and powdered boric acid dusted freely in the stockings and shoes. This is an effectual plan in some cases, and beneficial in all, lessening or completely abolishing the disagreeable odor.

Various other methods are, however, frequently resorted to. The Germans, especially for use in the army, extol a solution of chromic acid of 5 to 10 per cent. strength; according to action and severity of the disease it is painted on once in three to six weeks; it should be used with care. For the milder cases and as a preventive measure they also commend anointing with a 2 per cent. salicylated mutton suet. Duhring states that a solution of potassium permanganate, 1 to 3 grains (0.065–0.2) to the ounce (32.), used as a wash, often acts happily.[3] The

[1] Thin, *Brit. Med. Jour.*, Sept. 18, 1880, p. 463.

[2] Quoted by Hyde and Montgomery, *Diseases of the Skin*, seventh edit., p. 135.

[3] Weiss, "Hyperidrosis Pedum and Its Treatment by Baths of Permanganate of Potash," *Jour. Amer. Med. Assoc.*, Aug. 6, 1904, also lauds this old remedy highly, both in hyperidrosis and bromidrosis; using it nightly as a foot bath, ankle deep, for fifteen minutes; the next morning applying freely a dusting-powder consisting of 13 parts potassium permanganate, 1 part alum, 18 parts each of zinc oxid and calamin, and 50 parts talc, applying also between the toes, and keeping these slightly separated by absorbent

formaldehyd lotions referred to in hyperidrosis are valuable, and to be tried in obstinate cases. Grosse[1] and Ullmann[2] speak well of a powder of 1 part tannoform and 2 parts talc, both in hyperidrosis and bromidrosis; the parts are first washed and then the powder applied freely. In obstinate cases Grosse uses a plaster made with 25 per cent. of tannoform, and prefers it to Hebra's plan with diachylon ointment. Upon the whole, the most effectual plans in my experience are those with the continuous ointment application, and Thin's method, with 3 to 10 per cent. of salicylic acid added to the powder. Instead of the ointment, strapping with diachylon plaster can be practised. For particulars as to ointment method and for other plans sometimes employed the reader is referred to the article on hyperidrosis. For offensive sweating in the axillæ and in the genitocrural region the powder and lotion applications there referred to are prescribed.

Constitutional treatment, when demanded, is according to indications, chlorosis, anemia, etc., receiving their appropriate remedies. The several special drugs advised in hyperidrosis can also be experimentally tried, among which Crocker considers the best to be sulphur.

CHROMIDROSIS.

Synonyms.—Colored sweat; Ephidrosis discolor; Stearrhœa or seborrhœa nigricans (Wilson and Neligan); *Fr.*, Chromidrose.

Definition.—An affection of the sweat-glands in which the effused secretion is colored.

Several varieties and practically diverse conditions have been from time to time described under this title, all of which, before Leroy de Méricourt's[3] excellent contribution on the subject, were generally looked upon with considerable suspicion and of probable factitious origin. It is now known that the effused sweat may in rare instances be of various colors. Sometimes, however,—pseudochromidrosis, red chromidrosis,—the color, which is thought to be excreted with the sweat, is due to some external factors—microorganisms. Indeed, it is not improbable that future investigation will relegate some of the supposed true cases to the latter class. While in most instances the color is in the sweat-secretion, in others —in the minority, in which there is more or less accompanying greasiness—it is found in the sebaceous secretion.

Symptoms.—In the idiopathic class the most usual color is brownish or blackish (melanidrosis), often with a bluish shade, although it may be bluish (cyanidrosis) or a dirty gray. In the 38 cases collected by Foot,[4] which he believed to be authentic, it was noted

cotton. The bath is 1 per cent. in strength for the first three baths, and then of gradually increasing strength to saturation, in warm to hot water. The only disadvantage is the staining. The average course of treatment is two weeks, but the dusting-powder should be continued longer.

[1] Grosse, *Klin.-therap. Wochenschr.*, 1899, pp. 487 and 527.

[2] Ullmann, *Cent. f. d. ges. Therap.*, 1899, p. 257.

[3] Le Roy de Méricourt, *Memoire sur la Chromidrose*, Paris, 1864.

[4] Foot, *Dublin Quarterly Jour. Med. Sci.*, Aug., 1869, and Dec., 1873 (a good paper with particulars of 38 cases); see also paper by Pooley, *loc. cit.*, who has collected a number of reported cases; and Heidingsfeld, "The Pathology of Chromidrosis," *Jour. Amer. Med. Assoc.*, Dec. 13, 1902 (brief review, histologic study, and bibliography).

to be black, blackish, or brownish in 21, blue, bluish-black, bluish-brown, or violet in 15, and yellowish-brown in 2. In rare instances a red color has been noted, as in a case of a man reported by Dubreuilh,[1] in whom the right thumb and left wrist were the seat of the manifestation. The most common sites are about the eyelids, especially the lower, the forehead, and cheek. The breast, neck, back, hands, axillæ, groins, and genitocrural region are, however, more rarely noted to be the seat of the discoloration. The orbital region is the most usual one, and doubtless many of the suspected cases of artificial penciling of this part are in reality unfortunate victims of this malady. The part becomes discolored, as a rule, slowly, the secretion gradually collecting. Examined closely it is noted to be of a grimy, dirty character, consisting of a powdery or granular deposit, and gives to the cloth used in or wiping it a look of smuttiness, as Mitchell[2] expressed it, as if fine lead-pencil dust were upon it. After thoroughly removing it, which can be done only by rubbing and washing with some force, it again collects slowly, the color becoming gradually more and more pronounced. Instead of remaining localized, it may spread, and it may also be seen involving extensive surface; as a rule, however, the latter is rarely observed, the condition usually limiting itself to a circumscribed region, and, as remarked, most frequently the orbital regions. White[3] records a case, a male, in whom it was unilateral, covering half the trunk, and of a yellow color; the patient was aged twenty. In rare instances the color has been noted to change; and the discoloration has also been observed to move its position.

The secretion never seems very abundant, and is more suggestive of a discolored, oily seborrhea than of a true sweating. Crocker,[4] in 3 cases, noted it to be largely composed of flaky and granular fat, and from appearances more of the nature of seborrhea than sweat secretion. In most subjects the condition is noted to vary somewhat, being more intense when the patient is not in good health or when nervously depressed. In some instances, after lasting for some months or even a few years, it disappears spontaneously; as a rule, however, when once established, it is more or less persistent. Constipation, digestive disturbance, menstrual irregularity, various nervous symptoms, headache, hyperesthesia, neuralgic pains, and distinct hysteric symptoms are associated in many cases.

Etiology.—While in some instances it may be attributed to malingering and is of artificial production, it is now well established that this is not the fact in most cases. The disease is, it is true, ex-

[1] Dubreuilh, *Arch. Clin. de Bordeaux*, Jan., 1894.

[2] J. K. Mitchell, "Seborrhœa Nigricans," *Philada. Med. Jour.*, Jan. 15, 1899, reports a remarkable case involving both eyelids and adjacent parts, and reviews similar cases recorded. Colcott Fox, *London Clin. Soc'y Trans.*, 1881, vol. xiv., p. 211, reports 2 somewhat similar cases, the exudation being of a bluish-black color. Putnam, *New York Med. Jour.*, July 4, 1903, also reports a case of "inky-black" chromidrosis of eyelids, malar regions, upper portion of the nose, and the edge of the mucous membrane of the lips, in a young woman aged nineteen, associated with hysteric paralysis and amenorrhea; final recovery was made, the chromidrosis lasting nine months (case also seen in consultation by Dr. G. W. Wende). See also, for unusual cases, interesting paper by Osler, "Ochronosis, the Pigmentation of Cartilages, Sclerotics, and Skin in Alkaptonuria," *Lancet*, Jan. 2, 1904. [3] J. C. White, *Jour. Cutan. Dis.*, 1884, p. 293.

[4] Crocker, *Diseases of the Skin*, second edit., 1893, p. 722.

tremely rare. Its subjects are mostly women between the ages of sixteen and fifty, and usually of the nervous, neurasthenic class. The immediate exciting cause is often noted to be mental excitement, fright, anxiety, etc. Uterine disturbance[1] and pronounced constipation are also seemingly factors, especially the latter. Mitchell states that in almost all cases in the report of which the habitat was mentioned, the place of residence was near the sea. De Méricourt thought that possibly there was some causal relationship in this fact, to which he also called attention.

It is known, too, that the ingestion or absorption of certain chemicals or drugs has been responsible in rare instances for the production of colored sweat. Thus green sweat has been caused by copper, as noted by Clapton,[2] Halford,[3] and others. Temple[4] noted pink perspiration, which also stained the hair, in a patient taking potassium iodid. In the Kollmann-Scherer[5] case of blue chromidrosis the color was presumed to be due to the iron the patient had been taking, iron protosulphate being found in the sweat.

Pathology.—The pathology of chromidrosis is still involved in obscurity. According to our present knowledge, it must be considered a functional disorder of the sweat-glands, although it is not improbable that the secretion from sebaceous glands may, in some cases at least, be partly responsible. In many instances the disease doubtless belongs among the hysteric neuroses (Besnier and Doyon, Crocker, and others). Indican has been found by various observers (Hoffmann, Bizzio, and others) in the secretion, to the chemical transformation of which in contact with the air the color is supposed to be due. Others, however, have not succeeded in finding this, so that as yet the subject needs further investigation. In Mitchell's case microscopic and bacteriologic examinations of the exudate failed to throw any light on the condition; the material was found to be insoluble in ether and soluble in acids, which seemed to show that it was not a fatty exudate, as Neligan had believed. On the other hand, in White's patient, the coloring-matter was soluble in ether, and the exudate was of an oily nature; careful examinations failed to explain its origin. Heidingsfeld's histologic examination of a single case showed it to be an anomaly of pigmentation, entirely independent of the glandular secretions.

Prognosis and Treatment.—The condition is usually persistent, lasting several years or longer, though it is often variable as to degree. In some cases it has disappeared for a time, to reappear subsequently. Final recovery is, however, to be expected. The underlying condition—most frequently nervous disorders, uterine disturbances, and protracted constipation—is to be treated by appropriate methods. Ordinarily external treatment is of no avail. In White's case, however, the use of an ointment containing boric and salicylic acids brought about a disappearance of the blemish.

[1] Barié, *Annales*, 1889, p. 937 (with review and literature references), records a case of brownish-yellow chromidrosis of the palm and dorsal surface of the hand, recurring alternately on each hand, at several consecutive menstrual periods.

[2] Clapton, *Med. Times and Gaz.*, 1868, p. 658 (a number of cases referred to).

[3] Halford, *London Med. Gaz.*, 1833, p. 211.

[4] Temple, *Brit. Med. Jour.*, Aug. 29, 1891, p. 477.

[5] Quoted by Hoffman, *Wiener med. Wochenschr.*, 1873, No. 13, p. 292.

Red Chromidrosis — Pseudochromidrosis.—As already stated, the effused sweat in these cases is free from color, but it subsequently becomes stained by extraneous micro-organisms. The axilla is the most common site for it, although it is also seen in the genito-crural region; in fact, any warm, moist, hairy region may be its seat. The color is usually orange or red. The investigations of Hoffmann,[1] Babes,[2] Balzer and Barthélemy,[3] and Hartzell[4] go to show that this condition is due to chromatogenous bacteria, which are found attached to the hairs in agglutinated masses—zoöglea—and also, according to Balzer and Barthélemy, in scrapings of the epidermis and in the discolored linen. These latter observers found, both in the cleanly and uncleanly, parasitism of the axilla quite common, but it is not always accompanied by color-formation. Other hairy regions were also noted to be the seat of the same zoöglea, but rarely accompanied by red coloration. Balzer and Barthélemy concluded, from their valuable studies, that there is a form of parasitism which occurs as a transitory or permanent condition in a large number of individuals subject to profuse perspiration, and in whom masses of microbes, generally non-chromatogenous, sometimes chromatogenous, may develop. It is probable, as Van Harlingen[5] states, a change in the character of the secretions, from some unknown cause, affords an opportunity for development, and the germs of the disease assume unwonted vitality; apparently, too, abundant perspiration favors the multiplication of the chromatogenous organisms. According to Crocker, red sweat is always associated with lepothrix.

Treatment consists of the frequent use of soap and water and applications of boric acid and resorcin lotions, as prescribed in eczema. Corrosive sublimate solution, 1 or 2 : 1000, washings with chloroform, aromatic vinegar, and ether are commended by Balzer and Barthélemy. Any faulty condition of the general health should be corrected.

HEMATIDROSIS.

Synonyms.—Bloody sweat; Hemidrosis; Ephidrosis cruenta; Sudor sanguineosa; Hysteric stigmata; Bleeding stigmata; *Fr.*, Hématidrose.

Hematidrosis, or bloody sweat, is an extremely rare condition, and its occurrence has very often been seriously doubted. The valuable contributions and analytic review by Parrot,[6] who collected the records of a large number of cases, have, however, placed the existence of such an affection beyond question. Since then instances have been reported by McCall Anderson, W. T. Mitchell, Hart, Hyde,[7] and others. Almost any part of the body can be the seat of the manifestation, and it may occur at several points simultaneously. The skin

[1] Hoffmann, *loc. cit.* [2] Babes, *Centralblatt für Wissensch.*, 1882, p. 146.
[3] Balzer and Barthélemy, *Annales*, 1884, p. 317.
[4] Hartzell, *University Med. Mag.*, July, 1893.
[5] Van Harlingen, "Chapter on Chromidrosis," *Twentieth Century Practice*, vol. v. (Diseases of the Skin) (an excellent review of the subject).
[6] Parrot, *Gazette Hebdom. de Méd. de Paris*, 1859; Bouveret (*loc. cit.*) has given a good condensed résumé of Parrot's writings.
[7] Hyde, "A Contribution to the Study of Bleeding Stigmata," *Jour. Cutan. Dis.*, 1897, p. 557, reports an interesting case and briefly reviews the subject and gives a complete bibliography.

may be perfectly normal in appearance, or the "bleeding" may be momentarily preceded by slight elevation of the integument. Somewhat allied cases have also been described in which the bleeding was preceded by vesicle or bleb formation and also by erythematous areas, sometimes becoming superficially abraded or gangrenous; some of these latter probably belong among the cases of "neurotic excoriations" of Erasmus Wilson, and which may be open to the suspicion of artificial production.

Hematidrosis is chiefly observed in highly nervous, hysteric women, and an attack usually appears during some intense emotional excitement, and in some instances has been noted to be preceded by neuralgic pain or hyperesthesia of the part. It has in a few cases been attributed to faulty or vicarious menstruation. In Huss's case, a highly nervous woman, quoted by Parrot, the patient could bring on the bleeding by purposely working herself into a state of excitement. In a few instances, too, the condition might be considered as a part or symptom of hemophilia. The quantity of blood discharged is usually small. The affection is in reality scarcely hematidrosis; it is presumed, and probably correctly, that an extravasation of blood takes place into and around the sweat-coils, a purpura of the sweat-glands, as Crocker aptly states, and this mixes and is discharged with the sweat secretion; or it may exude into the sweat-glands by the process of diapedesis. It finds its exit from the sweat-pores, and it is barely possible that there may be at the time coincident increase in the sweat secretion itself.

Treatment is to be based purely upon indications in the individual case.

URIDROSIS.

Synonyms.—Urinidrosis; Sudor urinosus; Urinous sweat; Sandy sweat; *Fr.*, Uridrose; *Ger.*, Harnschweiss.

This term, as the word itself conveys, signifies sweat secretion containing the elements of the urine, more particularly, however, urea.

The normal sweat[1] contains a minute quantity of this latter substance, but exceptionally cases have been observed in which the amount was sufficiently large to be noticeable upon the skin. It is, however, usually observed in connection with renal disease (Kaup and Jürgensen, Leube, Deininger, and Taylor), generally preceded by partial or complete suppression of the urine. It has also been noted in cholera (Schottin and Drasche). According to Djoritch,[2] it is always a grave prognostic sign. The administration of jaborandi has also favored the excretion of large quantities, as in the experiments conducted by Hardy and Ball.[3] It is to be seen upon the skin as a whitish coating, bearing a rough resemblance to hoar-frost or a sprinkling of flour. Under the microscope it is noted to be made up of crystalline or irregular powdery masses. The deposit is generally most abundant upon exposed parts—hands and face; probably because these parts,

[1] See interesting paper by Easterbrook, "The Excretion of Urea by the Skin in Health," *Scottish Med. and Surg. Jour.*, Feb., 1900, p. 120.

[2] Djoritch, "Sueurs d' urée en géneral et dans la maladie de Bright en particulier," *Thèse de Paris*, 1895.

[3] The several observations here quoted are from Duhring, *Diseases of the Skin*, third edit., p. 144, where literature references can be found.

being uncovered, permit freer and quicker evaporation of the sweat excretion. Djoritch believes the exudation of urea comes chiefly from the sebaceous glands. The skin usually gives off a urinous odor.

Phosphoridrosis.—Instances of phosphoridrosis, or phosphorescent sweat, are extremely rare. It has been observed in the later stages of phthisis, in miliaria, and in those who have eaten of putrid fish. As an example of the last cause may be mentioned the case recorded by Panceri,[1] in which, after the eating of phosphorescent fish (putrid?), which sickened the patient, the sweat was noted to be luminous in the dark. Koster[2] refers to a case in which the body linen became luminous after violent sweating. Marsh[3] refers to several instances of its occurrence in the last stages of phthisis, and to a case of a luminous extensive ulcerating cancer of the breast. In all probability the phosphorescence is due to photogenic bacilli; Beyerinck[4] has discovered a number of varieties, chiefly derived from fish.

SUDAMEN.

Synonyms.—Miliaria crystallina; *Fr.*, Miliare crystalline; *Ger.*, Schweissfrieselausschlag.

Definition.—A non-inflammatory ephemeral disorder of the sweat-glands, characterized by pin-point- to pin-head-sized, discrete but usually thickly set, superficial, translucent, whitish vesicles.

Symptoms.—The eruption makes its appearance suddenly, the lesions developing irregularly or in crops, and is seen most frequently and most abundantly on the trunk, especially anteriorly; it may, however, be seen over other parts, and occasionally over the entire surface. Its appearance seems to be most frequent and most abundant where the epidermis is thin. The lesions are discrete, although often closely crowded, but with no tendency to coalescence, and appear as whitish or pearl-colored, translucent, very minute elevations, which bear resemblance to small dewdrops. They are non-inflammatory, without hyperemia or areola, and never assume such characters. The contents remain clear, never becoming purulent, and quickly or gradually disappear by absorption or evaporation, the epidermal covering disappearing by desquamation, which, however, is necessarily extremely slight. There is rarely exhibited any tendency to spontaneous rupture. While the whole process may come to an end in several days to a week, the disease may be more prolonged by the appearance of new lesions. There are no subjective symptoms.

Etiology and Pathology.—The eruption is seen in those gravely debilitated, and especially when associated with high fever. It, therefore, often occurs in the course of typhus, typhoid, rheumatic, puerperal, and hectic fevers; and is probably due indirectly to nerve disturbance. The investigations of Robinson, Haight, and Török show the lesion to be formed between the lamellæ of the corneous layers, usually the upper layers. The formation of the lesion is thought to be due to some change in the character of the

[1] Panceri, *La France Méd.*, Mch. 31, 1877; *Cincinnati Lancet and Observer*, May, 1877, p. 504.
[2] Quoted in Carpenter's *Physiology*, 1876, p. 550.
[3] Marsh, *Provincial Med. and Surg. Jour.*, iv., 1842, p. 170.
[4] Supplement to *Brit. Med. Jour.*, Jan. 1, 1891 (quoted by Crocker).

epithelial cells of the corneous layer, probably from high temperature, causing a blocking of the surface outlet and the escape of the sweat from the sweat-duct into the surrounding tissue of the corneous layer; the contents of the lesion consist of pure sweat (Robinson).

Diagnosis.—The characters of the eruption, with the associated general condition, are sufficiently distinct and pronounced as to make the diagnosis a matter of no difficulty. The absence of all hyperemia and other signs of inflammation serves to distinguish it from miliaria and from vesicular eczema. The lesions of hydrocystoma are somewhat similar, but much larger, deeper-seated, upon the face, and there is no associated febrile or cachectic factor.

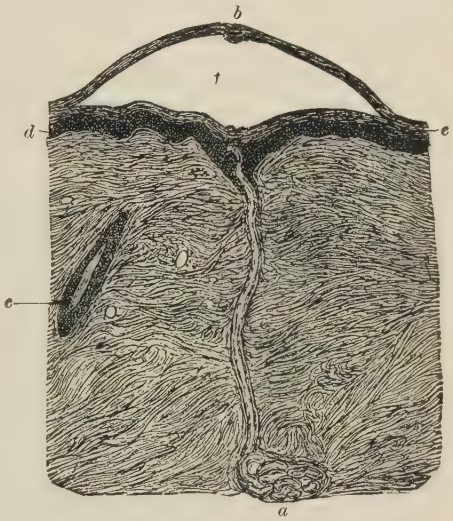

FIG. 227.—Sudamen, showing vesicle (*f*) containing pure sweat, with wall of upper lamellæ of corneous layer (*e*) and sweat orifice, or pore, at *b*; at lower part of vesicle the sweat-duct leading into the corium to the sweat-gland (*a*); *d*, rete; *c*, hair-follicle. The rete and corium are normal (courtesy of Dr. A. R. Robinson).

Prognosis and Treatment.—The condition is usually evanescent, rarely lasting for more than several days, but there may be recurrent crops. The eruption has no prognostic value as to the disease in the course of which it appears. Treatment is often scarcely necessary, but the parts may be sponged with diluted alcohol, one part alcohol to several parts water, and a simple dusting-powder, such as powdered starch, lycopodium, or zinc oxid, or a mixture of these, applied; or the dusting-powder may be used alone.

HYDROCYSTOMA.[1]

Synonyms.—Hidrocystoma; Cysts of the coil-ducts.

[1] Literature: Under the name dysidrosis of the face: Jackson, *Jour. Cutan. Dis.*, 1886, p. 1 (with colored plate); Rosenthal, *Deutsche med. Wochenschr.*, 1887, No. 20—abs. in *Monatshefte*, 1887, p. 615; Jamieson, *Brit. Jour. Derm.*, 1893, p. 134; Hallopeau, "Sur un case de dysidrose du nez," *Annales*, 1892, p. 728. Under the name of hidrocystoma: Robinson, *Jour. Cutan. Dis.*, 1893, p. 293 (with colored plate and histologic examination and cuts, and in *Trans. Amer. Derm. Assoc. for 1884*, and in *Manual of Dermatology*, New York, 1884, under "Sudamen of the Face"; Jarisch, *Verhandl. der Deutsch. dermatolog. Gesell.*, V. Congress, 1895; Adam, *Brit. Jour. Derm.*, 1895, p. 169 (refers to 9 cases; histologic examination, with 7 histologic cuts); Hutchinson, *ibid.*, p. 137 (with colored plate); Morton, *ibid.*, p. 245 (daughter of one of Adam's cases); Thibierge, *Annales*, 1895, p. 978 (4 cases, histologic examination, general review of the subject, and a bibliography); Bassaget, "De L'hidrocystoma," *Thèse de Paris*, July 24, 1896 (gives one new case with histologic study, and reviews previously published cases); Crocker, *Diseases of Skin*, second edit., p. 731, briefly mentions 3 cases, but the blotchy redness, pustular lesions, and, in 1 case, atrophic streaks and pits noted, do not accord with the conditions usually observed; Schidachi, "Experimentelle Erzeugung von Hidrocystoma," *Archiv*, vol. lxxxiii., 1907, p. 3 (with histologic cut).

Definition.—A name applied to a non-inflammatory affection characterized by discrete pin-head- to pea-sized, shining, translucent, somewhat deep-seated, persistent vesicles, appearing on the face.

Symptoms.—When a case comes under observation there are ordinarily a number of lesions to be seen, of various sizes, discrete, occasionally here and there a few crowded closely together. They are rounded or ovoid, translucent, solid-looking, tense, shining, whitish or light-yellowish, projecting vesicles, with, in some of the largest, a bluish tinge peripherally; they have a somewhat thick covering, and show no tendency to spontaneous rupture. The deepest seated, usually the beginning, lesions, as well as those tending to disappear in which the contents have been partly absorbed, look not unlike

FIG. 228.—Hydrocystoma, showing the yellowish-white or pearly, deep-seated cysts or vesicles (courtesy of Dr. G. T. Jackson).

boiled sago-grains. Upon the whole, the same appearances are maintained throughout. There are no inflammatory symptoms. Most of the lesions are of the size of a small pea, but many are smaller and some larger. Exceptionally around the border of the large vesicles there may be a scarcely noticeable hyperemic areola. The face is the seat of the disease. While in occasional cases the manifestation consists of but several lesions, which are scattered or confined to limited area, as the nose only in Hallopeau's case, in most instances there are 30 to 100 or more scattered over this entire region. Exceptionally the lesions are found on one side of the face only, as in Jamieson's patient, and associated with unilateral sweating. They are persistent, and often last for weeks or months, the contents remaining clear and never becoming purulent, and disappearing by absorption or desiccation, leaving no trace or a slight transitory pig-

mentation. There is a complete or partial disappearance during the cold season, and, as a rule, especially if subjected to the causative factors, a reappearance as soon as the warm weather sets in. Increased sweating of the face is often noticed. The eruption gives rise to no trouble except the disfigurement; occasionally a tense feeling or slight smarting is felt. Jackson noted in his case that the skin upon light rubbing became easily hyperemic.

Etiology and Pathology.—With rare exceptions the disease has been observed in middle-aged or older women, and especially in those whose faces are subjected to a warm, moist atmosphere, as washerwomen, and more particularly in those who perspire freely. Of the 30 to 40 patients observed by Robinson, all were women except 1; in Adam's 9 cases were 3 men, and in Thibierge's 4, 1 man. Exacerbation has been noted at the menstrual period, and following emotional or nervous excitement (Hallopeau). The causative factor in the reported cases would seem to be heat and steam moisture, as over the washtub and fire. My own observations of 4 or 5 patients are in accord with these previously observed facts. Inasmuch as out of the thousands of women so exposed but few show the affection, there remains an essential factor other than the above as yet unrecognized. The unilateral sweating noted in a few instances, and the long-continued hemicrania in Hutchinson's case, indicated possible neurotic element. Thibierge has observed joint pains and a disposition to obesity in such patients, as well as a marked neurotic tendency. Adams, on the other hand, contrary to general experience, stated that his 9 patients, except 1, were of the thin, active, wiry type.

FIG. 229.—Hydrocystoma, showing small and large cysts (*a*) in the lower part of the corium, an excretory sweat-duct at *b*, and a sweat-coil at *c*. As the vesicle or cyst enlarges it may extend to near the epidermis (courtesy of Dr. A. R. Robinson).

The lesion is a cyst-like formation of the duct of the sweat-gland, and has its seat within some part of the corium; beginning in the deeper part, and, as it increases in size, encroaching upon the epidermis. The epidermis is normal; nor does the process involve the sebaceous glands or hair-follicles. The cyst-wall is lined with two or more layers of epithelial cells, taking their origin from the normal epithelium of the duct; the contents consist of retained sweat, and are always acid (Robinson).

Diagnosis.—The persistent, pearly-looking, translucent, non-inflammatory projecting vesicles, with their limitation to the face, their occurrence usually in middle-aged women, and the history of

some duration, give a picture that can scarcely be mistaken for any other affection. It should not be confounded with sudamen, pompholyx, vesicular eczema, or adenoma of the sweat-glands. Sudamen bears some resemblance, but the superficial nature and minute size of the lesions, the distribution, generally most abundant on the trunk, and, as a rule, scanty or entirely absent on the face, together with the associated febrile or cachectic state and the short duration, are entirely different from the symptoms of hydrocystoma.

Pompholyx, or dysidrosis, is a disease of the hands, or hands and feet, and is acute in character, inflammatory, and runs a short course. Vesicular eczema can scarcely be confounded with it, with its numerous aggregated or confluent minute vesicles, usually rupturing spontaneously, and the gummy oozing, with the presence of inflammatory symptoms, an entirely different history, and the intense itching—symptoms strikingly different. Adenoma of the sweat-glands bears some similarity on casual inspection, but the history of this formation and the character of the contents are not like those of hydrocystoma. Milium could scarcely be confused with it.

Prognosis and Treatment.—The disease is a mild disorder, and beyond the disfigurement need not be the source of any anxiety. It is, however, as a rule, persistent, with partial or complete abeyance during the winter. With treatment and the avoidance of the exciting causes—moist heat and work or exercise which provokes undue perspiratory action—the condition can be removed. The measures required are purely external, and of a simple character, consisting in puncturing of the lesions, through which the contained liquid can escape or be pressed out, and the application of a bland dusting-powder. Rosenthal saw favorable influence from the use of a 1 to 2 per cent. alcoholic solution of naphthol.

Granulosis Rubra Nasi.[1]—While the first case of this malady was recorded by Luithlen (1900, 1 case), it is especially by Jadassohn (1901, 7 cases), Herrmann (1902, 10 cases), and, later, by Macleod (1903), that attention has been particularly called to this peculiar affection. The present accepted name we owe to Jadassohn. The malady is usually limited to the nose, to the front and sides; exceptionally,

[1] Literature: Luithlen, *Kaposi's Festschrift*, 1900, p. 709; Jadassohn, *Archiv*, 1902, vol. lviii., p. 145; Herrmann, *ibid.*, 1902, vol. lx., p. 77; W. Pick, *ibid.*, 1902, vol. lxii., p. 105; Macleod, *Brit. Jour. Derm.*, 1903, p. 131 (case demonstration), and *ibid.*, p. 197 (full report of same case, with review of the literature and references—I am indebted to this paper). Pringle (case records given by Macleod) demonstrated 2 cases before Derm. Soc'y of London, 1894, under provisional diagnosis of "hydrocystoma." Case reported by Meachen, *Brit. Med. Jour.*, 1903, xv., p. 104 (also cited by Macleod), is also suggestive of this disease. Saalfeld (Soc'y Trans.) *Monatshefte*, 1903, vol. xxxvi., p. 28 (case demonstration—nose and upper lip); Malherbe, *Jour. mal. cutan.*, Feb., 1905; Audry, *Jour. mal. cutan.*, Nov., 1903; Ormsby (Soc'y Trans.), *Jour. Cutan. Dis.*, 1905, p. 183 (case demonstration); Bäumer, *Dermatolog. Zeitschr.*, 1904, vol. xi., H. 9.; Pinkus, "Ueber die Beziehungen des Hidrocystoms zur Granulosis rubra nasi," *ibid.*; Lebet, "Constitution a l'étude de l'hidrocystome (avec une note sur la granulosis rubra nasi)," *Annales*, 1903, p. 273; Marcel Sée, *Annales*, 1904, p. 1037 (case demonstration); Baumer, *Dermatolog. Zeitschr.*, 1904, vol. xi., p. 646 (histology); Colcott Fox, *Brit. Jour. Derm.*, 1906, p. 320 (case report); Macleod, *ibid.*, p. 342 (second case, further history of first case, and résumé, with references of other published cases, with a general consideration of clinical characters, etiology, anatomy, pathogenesis, and treatment); Hallopeau, *Jour. mal. cutan.*, April, 1906 (4 cases, in 1 instance showing heredity, and in other circulatory disturbance (asphyxia) of the fingers and ears).

in addition to involving this part, it has been observed to affect also the upper lip (Macleod), cheek (Jadassohn, Herrmann), and eyebrow (Pringle). Examined casually and not too closely, it bears resemblance in its general aspects to an ill-defined lupus erythematosus or lupus vulgaris. The part is of a bright red color, diminishing in intensity toward the sides of the nose, and fading gradually, without any demarcation, into the adjacent normal skin. Over the area, irregularly distributed, are to be seen pinpoint to pinhead-sized, deep-red or brownish-red specks and papules, the color wholly disappearing upon pressure. There is no disposition to coalescence. The papules gradually develop into pustules and some undergo desiccation. There is in all cases an associated hyperidrosis of the affected area, and sometimes of other parts; the sweat often being seen on the involved region in scattered droplets, giving it a damp, glistening appearance. The course of the malady is exceedingly chronic, but inasmuch as it has never been seen in adults, it apparently disappears as the age of youth is passed, and without leaving scar or trace. Its subjects are all delicate children; and more commonly males (in Jadassohn's 7 cases, between 7 and 16; and 6 of his patients were boys). Pinkus has, however, recently reported what seems to be a case of this malady in a man aged fifty-nine, existing since childhood, associated with both hyperidrosis and hydrocystoma. Lebet also cites a combination of hydrocystoma with the disease; and in one of Jadassohn's cases there were a few hydrocystoma lesions, which he considered purely accidental. Both Lebet and Pinkus believe there is a relationship. Season usually has no influence, but aggravation was noted in Macleod's case in hot weather. Hyperidrosis seems to be a predisposing factor. There is no reaction after tuberculin injections (Jadassohn). The principal pathologic changes are to be found in the corium, and especially about the sweat apparatus; according to Jadassohn and others the histologic findings give the impression that it is a chronic inflammation originating in the vessels around the sweat apparatus. The epidermis, with the exception of a slight parakeratosis in the neighborhood of the sweat pores, is not involved. Herrmann was not able to confirm Jadassohn's histologic conclusions, as to a particular predominance of the process in and about the sweat apparatus, but regarded the condition as purely a perivascular disturbance of an inflammatory type. Treatment seems without positive influence, the malady being resistant to all therapeutic measures so far tried. Malherbe commends linear scarification.

MILIARIA.

Synonyms.—Lichen tropicus; Heat-rash; Prickly heat; Red gum; Strophulus; *Fr.*, Miliare; *Ger.*, Schweissflechte.

Definition.—An acute, mildly inflammatory disorder of the sweat-glands, characterized by numerous pin-point- to pin-head-sized, discrete but closely crowded papules, vesicopapules, and vesicles, or an admixture of these several lesions, and accompanied by more or less pricking, burning, or itching.

Symptoms.—There are two clinical varieties of this affection, one composed wholly or almost entirely of papular lesions, and the

other of vesicular lesions. In the majority of cases, however, while there is a preponderance of one type of lesion there is a distinct admixture of the two. Some lesions, too, are neither pure papules or pure vesicles, but midway between these—vesicopapules. It is especially to the papular type—**miliaria papulosa**—that the names lichen tropicus and prickly heat are given, although these terms, more especially the latter, are often used synonymously with the disease name miliaria, whatever may be the type. It makes its appearance suddenly, occurring upon a limited portion of the body, or, as commonly observed, involving a greater part of the entire integument. The lesions are minute, for the most part pin-head-sized, and rarely exceed the size of millet-seeds. In color they are pinkish or bright red, and closely crowded, although they remain discrete, so that the entire region affected is more or less uniformly hyperemic. While in this type the whole eruption may be entirely made up of papules, it is usual to see an intermingling of vesicopapules and vesicles.

The vesicular variety—**miliaria vesiculosa**—is that variety of miliaria in which the eruption is distinctly vesicular. The lesions are small—for the most part the size of pin-points or pin-heads. They are present in great numbers, are acuminate or conical in shape, never tend to coalesce, and show no disposition to rupture. The lesions have a slight pinkish or red areola, and being so closely crowded, this gives the whole field of eruption its red and inflammatory aspect—**miliaria rubra.** Later the areolæ fade, the transparent contents of the vesicles become somewhat opaque and yellowish-white, and the eruption has a whitish or yellowish cast—**miliaria alba.** Occasionally the contents of some become seropurulent or even purulent.

In all cases of miliaria there is usually a feeling of burning, pricking, or itching, which may be slight, moderate, or intense in character. Sweating generally is noted to precede and accompany the eruption. The lesions tend to disappear in the course of some days or one or two weeks, the papules gradually fading away; the vesicles disappear by absorption or desiccation, the epidermal covering, which is always extremely thin, disappearing by slight, at times scarcely perceptible, desquamation. When the closely crowded vesicular lesions are broken open by rubbing or accidentally, the liberated contents, minute in quantity, dry to insignificant thin crusting. In cases in which the cause continues there are fresh outcroppings, and the disease is thus prolonged, or in such instances it may be transformed into a veritable eczema, although such termination is not common. Not infrequently in these prolonged cases, and more especially in infants and young children, boils and small cutaneous abscesses are seen in association with it.

Etiology and Pathology.—Extreme heat is the essential causative factor; this may be due to the weather temperature or to working in an overheated room, from vapor baths, or from being overclad. Those who perspire freely are its most common subjects, more particularly infants and young children, and middle-aged adults who are overfleshy. In the latter free drinking of beer or other alcoholic drinks is sometimes a factor. In some instances debility seems to be of predisposing influence.

The affection is due to sweat obstruction, with mildly inflammatory symptoms as a cause or consequence; with congestion and exudation, with, at times, sweat effusion about the ducts, leading to the formation, according to the intensity of the process, of papules or vesicles. But there is still some difference of opinion, however, as shown in the following briefly stated views: (1) that it is an inflammatory disease of the epidermis and not an affection of the sweat-glands alone; the lesion occurring around a sweat-duct in the rete and upper part of the corium, with slight inflammatory effusion and usually transudation or retention of sweat, the vesicular lesions all being connected with the sweat-glands (Robinson);[1] (2) that the vesicles are due to dilated sweat-ducts, the papules to the occurrence of cysts filled with cellular elements, and of cysts in the lower region of the rete, and to circumscribed swelling in the immediate neighborhood of a sweat-pore (Pollitzer[2]); (3) that no connection between the sweat-gland and vesicle can be found, and that the lesions are purely of inflammatory origin, or eczematous, probably due to irritation produced by

FIG. 230.—Miliaria, vesicopapule, showing vesicle (*a*) with the excretory sweat-duct in the lower central part, and inflammatory changes in the rete (*b*), and also in the upper part of the corium and deeper down along the blood-vessels (courtesy of Dr. A. R. Robinson).

the sweat on the surface (Török[3]). As all are good observers, it is probable that the lesions vary somewhat in origin and formation.

Diagnosis.—The rapidity of the outbreak, the closely crowded lesions, the mild inflammatory aspect, the preceding and often accompanying sweating, absence of tendency in the vesicles to spontaneous rupture, the external high temperature factor, and absence of constitutional symptoms, are usually sufficiently distinctive. Pap-

[1] Robinson, *Jour. Cutan. Dis.*, 1884, p. 362, and in Bangs-Hardaway's *Amer. Text-book*, p. 1096.

[2] Pollitzer, *Jour. Cutan. Dis.*, 1893, p. 50 (with several cuts), and *New York Med. Jour.*, 1894, vol. lix., p. 12.

[3] Török, abs. in *Monatshefte*, vol. xiii., 1891, p. 437.

ular eczema is in most cases rather limited in extent, the lesions are larger and markedly inflammatory, come out more slowly and are persistent, and, where close together, there is a good deal of inflammatory swelling and infiltration. The same features serve to distinguish vesicular eczema; moreover, in this latter there is distinct tendency to spontaneous rupture of the lesions and characteristic gummy oozing and crusting. There is a resemblance to sudamen, but in this latter there are no inflammatory signs, the vesicles being transparent, whitish, resembling minute dewdrops, and seen in association with some febrile or cachectic state. Miliaria or similar lesions occur sometimes in the exanthemata, but the constitutional symptoms and the accompanying or quickly following characteristic eruption of the latter serve as differential points.

Prognosis and Treatment.—Under favorable conditions at the end of several days or a week or two the disease has come to an end. In some cases the cause persisting, there may be rapidly recurrent attacks, so that the eruption may almost be continuous over several weeks or longer, with or without occasional furuncles, or eventually developing, especially in the folds, into an intertrigo or an eczema.

In the management of the affection its common cause—excessive heat from high temperature or from too much clothing—should be kept in mind. The disorder is thought to be more frequent in those of debilitated constitution, and for this reason treatment of a tonic character is sometimes appropriate. In those of full habit and stout, refrigerant and acid drinks are apparently of service. Saline laxatives should be administered in the beginning, and repeated from time to time in the more persistent cases.

As a rule, however, removal or modification of the cause, and the application of a dusting-powder or cooling and astringent lotions are all that are required in the average case. The dusting-powder may consist of zinc oxid, boric acid, talc, and starch, singly or of equal parts. The simple household remedy of one part vinegar or alcohol to several parts water will also often be sufficient in such instances. In rather extensive cases, in which itching or burning is a prominent symptom, the following lotion may be prescribed:

℞.	Ac. carbolic.,	ʒss (2.)
	Ac. boric.,	ʒij (8.);
	Alcoholis,	f℥j (32.);
	Aquæ,	q. s. ad Oss (256.).

Or one of thymol, 5 to 10 grains (0.35–0.7), sodium borate, 8 grains (0.55), alcohol, 1 ounce (32.), and water enough to make ½ pint (256.), may be employed. In infants or others in whom there is a distinct tendency to furuncular complication, a plain saturated solution of boric acid, with 1 or 2 grains (0.065–0.13) of resorcin to the ounce (32.), is especially to be commended. In some instances one of these lotions, followed immediately by a dusting-powder, is more grateful. In those persons of rather stout condition, who are frequently subject to the affection, and who perspire somewhat freely, the daily use of a dusting-powder of 1 part salicylic acid to 30 to 50 parts boric acid will, if the patient avoid active exercise and overclothing, often prove a preventive.

Miliary fever[1] (sweating sickness; miliary sweat rash; sudor anglicus; English sickness; *Fr.*, suette miliare) is an epidemic disease of rare and scarcely known occurrence in recent years, in which profuse sweating and miliaria are conspicuous symptoms. The last epidemic occurred in France. The earliest symptoms are ill-defined prodromata, such as feverishness, weakness of the legs, and general malaise and nervous symptoms, the last consisting of feelings of epigastric constriction, of suffocation, sometimes paroxysmal, and agitation, delirium, etc., and accompanied by copious sweating. Cramps and constriction of the muscles are also observed. The tongue is coated and the bowels constipated, and in the early stage cough is habitual and epistaxis generally abundant. The eruption soon presents, characterized by two chief features: first, a miliary papule, transformed later into a vesicle, and, secondly, a polymorphous erythema. This latter is of three forms—a morbilliform eruption, a scarlatinoid rash, and purpura. The morbilliform rash first presents, followed by the scarlatinal and purpuric characters. In some instances the eruption remains morbilliform, and in some cases the earliest rash is the scarlatinal.

The eruption appears first on the face, and then spreads to the neck, trunk, and upper limbs, and finally to the legs—the last often being much less involved than the other parts. The veil of the palate is often dotted over with red spots. The eruption frequently shows itself in two or three successive crops, the previous crop disappearing completely and rapidly, to be followed by another. The purpuric spots, however, are apt to remain a long time. As soon as the eruptive stage is pronounced, the general symptoms gradually abate. The so-called "*suette blanche*" variety is composed of papules, which remain hard and opaque, with but little, if any, tendency to vesicular transformation. The final disappearance of the eruption is followed by desquamation. The malady is fraught with danger, the mortality varying from 12 to 33 per cent.

[1] This description is abbreviated from an editorial review, *Lancet*, Oct. 1, 1887, p. 671, of Brouardel's report of "L'epidemie de suette miliare du Poiton," *Bull. Acad. Med.*, 1887.

CLASS IX.—PARASITIC AFFECTIONS.

A. DISEASES DUE TO VEGETABLE PARASITES.

FAVUS.

Synonyms.—Tinea favosa ; Tinea ficosa ; Tinea lupinosa ; Tinea maligna ; Tinea vera ; Porrigo favosa ; Porrigo lavalis ; Porrigo lupinosa ; Porrigo scutulata ; Dermatomycosis favosa ; Porrigophyta ; Trichomykosis favosa ; Crusted ringworm ; Honey-comb ringworm ; *Fr.*, Teigne faveuse ; Teigne du pauvre ; Teigne rural ; *Ger.*, Erbgrind.

Definition.—Favus is a contagious, vegetable-parasitic disease of the skin, characterized by pin-head- to pea-sized, friable, cup-

FIG. 231.—Favus, in a woman aged twenty-three, of some years' duration ; showing hair loss, atrophic thinning of the skin, and the cup-shaped crusts at peripheral portion.

shaped yellow crusts, tending sooner or later to form coalescent, mortar-like masses.

Symptoms.—The common and usual site of favus is the scalp, but it may occur upon any portion of the integument, and occasionally attacks the nails (see onychomycosis). To the latter regions it is usually conveyed from the disease on the scalp, although it does occur sometimes primarily upon the non-hairy surface, and to which

it may indeed be limited. The nails are rarely the primary seat of the malady.

In **favus of the scalp,** sometimes designated tinea favosa capitis, favus pilaris, the affection develops, as a rule, insidiously and slowly, beginning as an insignificant superficial inflammation or merely as a hyperemic spot; in the earliest stage or period this is more or less circumscribed and slightly scaly, the scaliness being usually of a thin, branny character. There is soon noticed the appearance of yellowish points at the hair-follicle outlets, surrounding the hair-shaft. These yellowish points or crusts increase in size, growing slowly, becoming ordinarily the area of small peas; they are cup-shaped, with the convex side pressing down upon the papillary layer of the skin, and the concave side facing externally, constituting the so-called *favus scutulum.* They are raised several lines above the surface level, are friable, sulphur-colored, and usually, in the beginning at least, each cup or disc is pierced by a hair. Some show distinct concentrically disposed furrows. Upon removing the crust the underlying surface is found to be somewhat excavated, reddened, and if the malady has existed for some time, also atrophied; exceptionally it is suppurating. In detaching the discs, more especially those of some duration, slight serous exudation or even bleeding is sometimes noticed. As the disease continues and progresses, the crusted points or spots extend somewhat, new ones arise in the interspaces, and, as a result, the crusts become more or less confluent over the involved area, and form irregular masses of thick, yellow or yellowish, mortar-like accumulations. While the crusts are yellowish, and at first a clear yellow, later, from the admixture of extraneous matter, they often have a brownish tinge. They have, when present in any quantity, a peculiar, characteristic odor, which has been likened to that of stale, musty straw, to that of mice and the urine of cats.

The progress of the malady is exceedingly slow, so that months often elapse before there is much involvement, the disease sometimes limiting itself to an irregular area of one or two inches in diameter. Not infrequently, while the first patch increases gradually, new foci show themselves in one or more near-by or remote parts of the scalp. In some instances, especially near the border of the crusts, are seen pustules or suppurating points, and exceptionally the whole involved area may exhibit slight or moderate suppurative action, by which the accumulated masses are in places loosened and cast off; this latter usually occurring after the malady has been of some duration, during which time the hair of the affected surface, or most of the hairs, have loosened and fallen out.

The hairs, in fact, are involved early in the disease; they become brittle, lusterless, break off, some splitting up, and many falling out. After a time the crusts may disappear here and there over the oldest part, leaving an atrophic, thinned-looking, more or less hairless surface, with scanty or numerous, scattered, yellowish point, cup-shaped discs or small confluent crusted spots; at the border of the area the disease is still noted to be active, and presenting the ordinary symptoms already described. The disease may thus gradually invade

more or less of the entire scalp, and may remain active over the entire involved surface, which is covered with the yellowish, mortar-like masses. In sluggish, long-continued cases, in which, in most parts, the malady has ceased to exist or to be active, there is a more or less general scurfiness, with irregularly dispersed, small, flattened, yellowish, scaly spots; the skin is atrophic, dry, harsh, and relatively or completely hairless, usually, however, with small or large dry tufts here and there.

Favus of the general surface or non-hairy parts, or tinea favosa epidermidis, exhibits symptoms essentially similar to those upon the

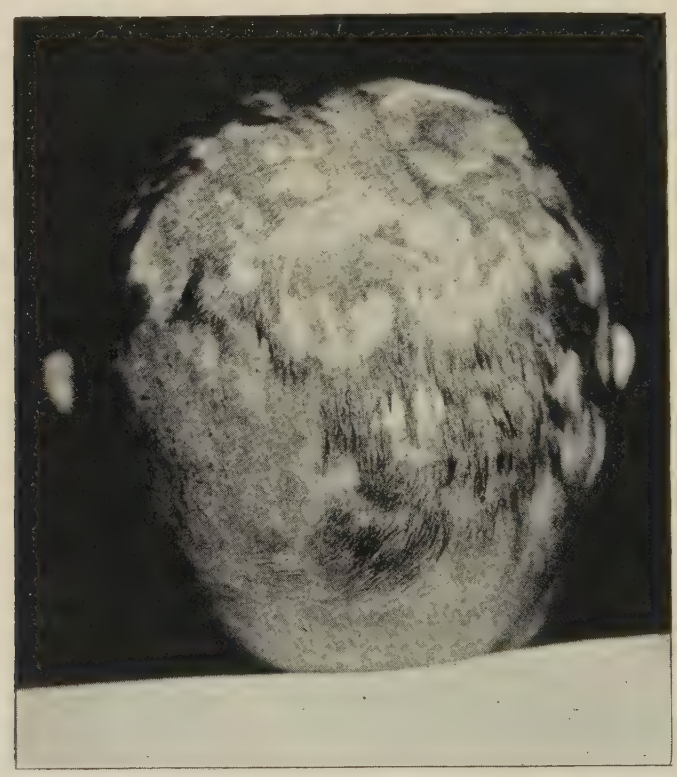

FIG. 232.—Favus, in a Russian boy aged fourteen, of eight years' duration, showing the extensive atrophic, cicatricial, hairless areas left. Disease only active now posteriorly, and to a slight extent to the right anteriorly, from which the crusts have been removed.

scalp, beginning at the lanugo hair-follicles. In some instances, however, there is tendency to the circinate patch (favus circinatus), with the outer part more or less inflammatory, sometimes papulovesicular (favus herpeticus), and studded with small yellow points and favus scutula; the central portion tending to clear up, presenting a resemblance, barring the yellowish points and discs, to ringworm. There may be one or more of such areas. Exceptionally a patch consists of several concentric rings. In most cases, however, the disposition to massing similar to that observed on the scalp is exhib-

ited, although the masses are more apt to have a rough and irregular surface. In most instances, especially if neglected, the malady spreads rather rapidly, and often involves large areas and is somewhat widely distributed.[1] The rapidity of its extension is apparently increased by conditions of ill health.[2] While usually persistent, especially when more or less extensive, it is very much less so than the disease on the scalp; and in extremely limited body cases often tends to spontaneous cure. In some instances marked atrophy of the underlying skin results, and occasionally distinct ulceration.[3]

While favus is a disease of the cutaneous surface, it is possible in rare instances that the mucous membranes may become implicated.[4] It has in a few cases been observed on the glans penis.[5]

The subjective symptoms in favus are rarely pronounced and sometimes entirely absent; itching, varying

FIG. 233.—Favus—generalized—in an Italian boy aged ten; on scalp of several years' duration, on general surface some months.[6]

[1] See paper by Cantrell and Stout, "A Case of Favus of the Head and Body," *Jour. Cutan. Dis.*, 1894, pp. 375 and 419 (with review of similar cases and bibliography).

[2] Malcolm Morris, *Brit. Jour. Derm.*, 1891, p. 101 (with illustration), and Montseret, *La presse méd.*, No. 40, 1898, p. 254, both report a case involving the general surface in phthisical subjects, in whom, during the last stage of the constitutional malady, there was rapid spread of the favus.

[3] In an instance observed by Hallopeau, and one by Vidal, referred to in Wickham's Paris letter to *Brit. Jour. Derm.*, 1890, p. 149, the ulcerative action was quite marked.

[4] Kaposi, *Wien. med. Presse*, 1884, p. 1375, reports a case of generalized favus in which, the patient dying subsequently from gastro-intestinal disease, Kundrat ("gastro-enteritis favosa"), *Wien. med. Blätter*, 1884, p. 1538, found at the necropsy the favus fungus in the esophagus, stomach, and intestine, some of which in the last had undergone putrefactive change.

[5] Glück, *Archiv*, vol. xlvii., 1899, p. 339 (with colored plate), noted an instance in which, in addition to several patches on the outer surface of the prepuce, there were some typical crusts on the corona and glans.

[6] This is the case reported by Cantrell and Stout, entering the Philadelphia Hospital just at the end of Dr. Cantrell's term, coming subsequently under my care.

in degree, is occasionally somewhat troublesome; there may also be in the suppurative conditions some soreness.

Etiology.—Favus is due solely to the invasion of the cutaneous structures, especially the epidermal portion, by the vegetable parasite, the achorion Schönleinii. It is seen in both sexes, but much more frequently in males; it may occur at almost any age, but it is rare for the scalp disease to begin after the age of fifteen. Hutchinson[1] found in 44 cases the latest age at which it began was seventeen; this patient, when coming under notice, was aged twenty-nine, the oldest of the 44, having had the disease twelve years. It is a contagious malady, but relatively much less so than ringworm. It is conveyed from one person to another, or to man from the lower animals, such as cats, dogs, rabbits, fowl, mice, and sometimes cattle[2] and the horse. It is probably communicated quite frequently by cats, the latter contracting it from rats and mice, especially the latter.[3] Its contagiousness seems, however, somewhat variable, single cases often existing in a family for years, without any other member becoming involved, although striking exceptions are sometimes noted.[4] The malady is much more common among certain nationalities than others; it is comparatively frequent in Northern Italy, Southern France, Russia, Poland, Austria, Germany, Hungary, and in Scotland.[5] In England and in the United States it is relatively uncom-

[1] Hutchinson, "Clinical Report on Favus," *Med. Times and Gaz.*, 1859, vol. xix., p. 553 (with analytic table of 44 cases).

[2] Gigard, "Sur une épidémie de teigne faveuse sivissant a Nantoin chez les bêtes cornes et chez les enfants," *Lyon médicale*, vol. xxxiv., 1880, p. 547, recorded its occurrence at about the same time in 16 cows and 4 children in a French village.

[3] See interesting paper by Sherwell, *American Veterinary Review*, Nov., 1892, detailing the contraction of the disease by 4 members of a family through the intermediary of the dog, the latter contracting it from affected mice; Hutchins, *Jour. Cutan. Dis.*, 1895, p. 377, records a case in a negro, who apparently caught it from pet white rats.

[4] Crocker, *Diseases of the Skin*, third edit., p. 1272, noted its occurrence in 3 children of a family, one after another, the disease being primarily contracted from a cat. Robinson (discussion), *Jour. Cutan. Dis.*, 1895, p. 217, had under observation 3 cases in the same family, and Allen, *ibid.*, a case in an Irish woman, whose 3 children contracted the disease. Duhring, *Diseases of the Skin*, third edit., p. 596, refers to an instance where 13 members of one family were in the course of years affected, and another of mother and 2 children, constituting the whole family. In 17 cases observed by J. C. White ("Analysis of 5000 Cases of Skin Diseases"), *Boston Med. and Surg. Jour.*, 1876, vol. xciv., p. 565, more than half were instances where 2 or 3 members of the same family were affected. In 50 cases observed by Bodin, *Annales*, 1894, p. 1220, more than half the patients alleged that they had caught it from others, and 10 had been in contact with affected animals; in 10 cases its origin could not be traced. I have met with several instances of its occurrence in 2 of a family. Crary, *Bull. Lying-in-Hospital*, vol. i., No. 6., New York, May, 1904, reports a case in a child fourteen days after birth, appearing on face, scalp, and elbow; the mother having the disease upon the scalp.

[5] In France its frequency is shown by Feulard, *Trans. II. Internat. Derm. Cong.*, Vienna, 1892, p. 393, and *Annales*, 1892, p. 1118, from statistics taken from the French Army Department; between 1876–80, of those examined for army service (at the age of twenty), 1541 had favus; 1881–85, 1399; 1887–91, 964, the malady showing a somewhat rapid decrease, but it is much more common than these figures indicate, inasmuch as the disease is chiefly seen in children and adolescents.

In Belgium, Thomson (*Clinique*, Brussels, 1894, vol. viii., p. 52—abs. in *Brit. Jour. Derm.*, 1894, p. 156) shows its great frequency in that country; between 1888–92 there were exempted from military service, owing to the disease, 3.03 per 1000, and even with rigid examination of the recruits it exists in the service to the extent of 0.15 per 1000.

In Scotland, McCall Anderson gives (*Lancet*, 1871, ii., pp. 672 and 742) 156 cases in 10,000 consecutive dispensary skin cases, or 15.6 per 1000.

In England, according to Crocker, it is observed in only 1 of 2000 consecutive skin cases.

mon, and with us is seen chiefly among immigrants from the countries named.[1] It is, as the observations of Bergeron,[2] Feulard, Bodin, and Thomson indicate, much more common in the country and suburban districts than in the cities.

Favus of the non-hairy or general surface, except the instances of slight, limited patches sometimes seen, is usually consecutive to the disease on the scalp, and in extensive types almost invariably so, although Lustgarten[3] has reported a case of the latter, the eruption covering a large portion of both legs, in which the scalp was wholly free. The nails (see onychomycosis) are only rarely invaded by the favus fungus, and then almost always secondarily, from scratching the affected scalp.

While favus is met with over the entire world, its prevalence is apparently greatly influenced by nationality, lack of personal cleanliness, neglect of the scalp, and probably some inherent peculiarity of the skin. It is commonly believed that a damp, moist climate favors its occurrence, but this does not seem borne out by the facts. It is essentially a disease of the poor, ill-fed, and uncared for, although occasionally seen in those of fair or good circumstances and surroundings. There is scarcely doubt but what an integument whose resisting power has been impaired by ill health, improper and insufficient food, etc., becomes a readier soil for the successful inoculation and growth of the fungus. Its much more rapid spread in the body cases during the last stages of phthisis in the instances named points to this conclusion.

Pathology.—The achorion Schönleinii is a vegetable parasite first discovered by Schönlein in 1839, and later by Gruby and Wedl, although Remak was the first to confirm its pathogenic character by successful inoculation, and who gave it the name in honor of its discoverer. It consists of mycelium and spores, existing in such profusion that it is readily detected. The spores are usually rounded or ovalish, often somewhat elongated, and vary from 0.0023 mm. to 0.0052 mm. in diameter (Duhring). The mycelium is composed of narrow, apparently flattened tubes or threads, which ramify in all directions without definite arrangement; they average from 0.0023 mm. to 0.003 mm. in diameter, and vary greatly in length, and are straight, curved, bent, or crooked, or inclined to branch in a forked manner; and sometimes they are divided or broken up in such a way as to have the appearance of the links of a chain (Duhring). As the disc-like scutulum and the mortar-like mass are composed almost wholly of the fungus, there is no difficulty in demonstrating its presence. For the examination a portion of the crust is placed on a slide in a few drops of liquor potassæ, the cover-glass placed over it, and allowed to stand for several minutes or longer; the cover-glass is

[1] In the United States the statistics of the American Dermatological Association show 3.43 per 1000, most of the patients, however, being foreign-born. In 36 cases under my care (20 at Philadelphia Dispensary for Skin Diseases in a period of ten years, and 16 in the Philadelphia Hospital in a period of five years, *Philadelphia Hospital Reports*, vol. iii., 1896, p. 176) the patients were of the following nationalities: American born, 5; Russian, 10; Austrian and German, 10; Italian, 3; Irish, 3; Roumanian, 2; Hungarian, 1; English, 1; and Canadian, 1.

[2] Bergeron, "Étude sur la géographie et la prophylaxie des teignes," *Annales d'hygiène publique*, Paris, 1865, vol. xxiii., p. 5.

[3] Lustgarten, *Jour. Cutan. Dis.*, 1895, p. 217 (with illustration).

then pressed down, and an examination made with a power of 300 to 500 diameters. If an affected hair is examined, the same steps are taken, except that a longer time should be allowed for the action of the liquor potassæ, and sometimes a stronger potash solution could be used with advantage.

According to Robinson,[1] as well as to the investigations of others, "the parasite first obtains a lodgement in the funnel-shaped depression in the epidermis through which the hair-shaft emerges upon the surface. It grows luxuriantly in the upper part of the hair-sac, and insinuates itself on all sides between the superficial layers of the epidermis. When it reaches a short distance on all sides of the follicle-mouth, it breaks the looser layers and appears on the surface, giving us the familiar cup-shaped bodies. It also invades the hair-shaft itself, though not to the extent that the ringworm parasite does.

FIG. 234.—Favus fungus—achorion Schönleinii (× about 700; partly diagrammatic).

It penetrates between the cellular layers of the root-sheath, and multiplies in the cortical substance of the hair. The nutrition of the hair is interfered with by the mechanical pressure of the growth upon the papillæ. The hair falls out, and eventually in many cases the papilla atrophies and a new growth becomes impossible. In cases of any standing the parasite may be demonstrated, not only in the cortical, but in the medullary substance of the hair. Splitting of the hair may occur, as in ringworm, but as a usual thing the hair falls out before that occurs." "In the skin itself the parasite usually confines itself to the upper corneous cells, and does not extend to the living tissues. In cases where the surface is covered by irregular, mortar-like masses of the parasite, the entire upper layer of the epidermis will be found infiltrated with the achorion. The corium itself is usually in a state

[1] Robinson, *Manual of Dermatology*, p. 605.

of chronic inflammation, and suppuration, which may be quite abundant, often occurs under the crusts. Even where no pus is found the presence of the parasite causes atrophy of the skin, and at last pit-like depressions or more extensive reddened scars are left. When the glandular structures are entirely destroyed, the achorion no longer finds a suitable nidus, and the disease, at that spot, is at an end."

While the malady is generally considered to be due to the one variety of fungus, there is a growing belief that future investigations may show, as now accepted in ringworm, that there may be several species. On this basis the variable contagiousness shown and the slight variations in the clinical features might find satisfactory explanation. Several observers (Quincke, Frank, Unna, Sabrazés, Bodin)[1]

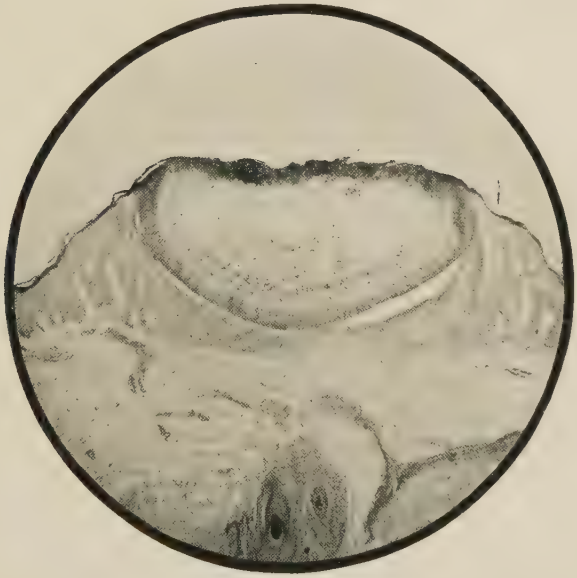

FIG. 235.—Section through a favus scutulum, showing the thinning and atrophy of the underlying surface, presumably as the result of pressure (courtesy of Dr. M. B. Hartzell).

have found several varieties. Both Frank and Unna, from experimental inoculations and cultures, conclude that there are three distinct species which give rise to slightly different clinical pictures. Sabrazé's experiments and observations indicate that there is one variety peculiar to fowls, one to the dog, and the other to man, the three being intercommunicable. On the other hand, other investigators (Elsenberg, Král, Dubreuilh, Danielssen, Busquet, Mibelli)[2]

[1] Quincke, *Monatshefte*, 1887, p. 981; Frank, *ibid.*, vol. xii., 1891, p. 255 (with review); Unna, *ibid.*, 1892, vol. xiv., p. 1; and also in *Brit. Jour. Derm.*, 1892, p. 139 (with colored plate); Sabrazés, "Sur le favus de l'homme, de la poule et du chien," *Annales*, 1893, p. 340; Bodin, *loc. cit.* (with complete review and references).

[2] Elsenberg, *Archiv*, 1889, p. 179; Král (Pick and Král), *ibid.*, 1891, Ergänzungsheft (the fungus described is, however, somewhat different from that commonly found; gives review and references); Danielssen, *Atlas of Vegetable Parasitic Diseases*, Bergen, 1892; Busquet, *Annales*, 1892, p. 916; Mibelli, *Giorn. ital.*, 1892, fasc. ii., iii.,—abs. in *Monatshefte*, 1893, vol. xvi., p. 47.

have either failed to confirm such findings or ascribe the alleged differences to the character of the "soil," culture methods, and other accidental or accessory conditions.[1]

Diagnosis.—The characters of favus—the yellow, and usually cup-shaped crusts, brittleness and loss of hair, the underlying atrophy, together with the history—are generally so distinctive that it is, as a rule, readily recognized. In cases in which the scalp has been thoroughly washed just before seeking advice the peculiar crusts will be lacking, but the other features, especially the atrophic or cicatricial condition of the involved surface, will commonly be sufficient. In such instances hairs from the affected area can be examined with the microscope, or the patient permitted to go and return in a week or ten days, with instructions that in the mean time no application is to be made or the parts washed; by the end of this period there is usually a reappearance of the yellowish points and cup-shaped discs, although the latter may not have acquired any size. But such beginning crusts can be microscopically examined and the matter readily determined. In cases in which the disease has been long continued, the cup-shaped crusts are commonly wanting, the scalp being more or less covered with irregular, mortar-like, yellowish or brownish-yellow accumulations; but the color and odor of the latter, together with the other characters named, especially the atrophy and hair loss, afford means for diagnosis. In some instances—in those in which, from extraneous matter and the coexistence of a seborrhea, the crusts are of a less granular character and brownish in color—there is, on first glance, a possible doubt, but a consideration of the essential features named suffices to clear the difficulty. In doubtful cases the microscope is to be resorted to.

The diseases with which it is most likely to be confounded are eczema, ringworm, seborrhea, and psoriasis. The atrophic and scar-like character, the condition of the affected hair, the hair loss, the odor and history, as well as the other features, will serve to distinguish it from eczema, seborrhea, and psoriasis. In none of these is there a tendency to patchy hair loss. Ringworm lacks the crusting and atrophic changes of favus, and ordinarily shows but slight scaliness and a distinct tendency for the hair to break off, especially near the follicular outlets; moreover, ringworm patches are likely to be fairly well rounded, while the favus areas are commonly somewhat irregular (see ringworm for other differential points). The atrophic, cicatricial areas of lupus erythematosus occurring on the scalp show some resemblance, but they lack the crusting and other features, and the disease is usually seen here in association with characteristic patches on the face. Alopecia areata can scarcely be considered,

[1] Of great interest in this connection also is the observation by Mewborn, *Jour. Cutan. Dis.*, 1903, p. 11 (with culture illustrations, and résumé of pertinent literature, with bibliography), of "A Case of Favus of the Scrotum, Coexisting with Ringworm of the Thigh, Giving Identical Trichophyton-like Cultures" (a megalosporon ectothrix of probable animal origin).

Winfield, *Jour. Cutan. Dis.*, 1897, p. 13 (with illustration of case and fungus), met with an instance of a favus-like eruption on the oral mucous membrane (roof of the mouth), with many points of resemblance in color and crusting to favus, but which was found due to the aspergillus nigrescens.

inasmuch as it has only one feature in common,—the hair loss,—showing no scaling, crusting, or cicatricial formation.

The diagnosis of favus of the non-hairy or general surface rarely, if ever, gives rise to difficulty. The ring-shaped patches sometimes present a similarity to ringworm, but the yellowish points and cup-shaped crusts of the former are not seen in the latter disease. The features of favus of the nails are elsewhere considered (see onychomycosis).

Prognosis.—Favus of the scalp, if at all advanced and of some duration, is a most intractable disease. In some instances it may, indeed, be almost said to be incurable; that is, the time required to bring about permanently favorable results is so long, varying at least from six months to one or two years, and the measures of treatment so irksome and tedious that very few patients among the class in which the disease prevails will be found to be sufficiently persevering. It is true the malady after years tends gradually to wear itself out, and patients will occasionally be seen with the evidences of its ravages, such as atrophic scarring and baldness, in whom, after a duration of five, ten, or fifteen years or more spontaneous cure has resulted, helped, doubtless, by treatment pursued irregularly from time to time. In my earlier experience in dispensary practice I often thought I saw cures resulting after several months' treatment, but a larger observation and returning patients have taught me that while the disease was apparently cured, it was only benefited and somewhat diminished in area; and that a permanent and complete cure requires a much longer period and the employment of actively energetic measures of treatment. Under the latter circumstances the malady in every instance can finally be removed—some cases in five or six months, but most of them in not less than a year. Efficient depilation, if it can be carried out, has a material influence in shortening the duration of treatment. Recent and limited cases are, of course, much more readily responsive, and require less time for their cure.

Favus of the general surface is comparatively easy to cure, and, as a rule, responds to proper measures in the course of one or two weeks in the slight limited cases, to one or two months in those of extensive distribution.

Treatment.—A necessary preliminary in the management of favus of the scalp is the removal of the crusts, which can be accomplished by oily applications and soap-and-water washings, the washings alone often sufficing. An essential part of the treatment is the extraction of the hairs from the diseased areas; the hair of the unaffected parts should be kept closely cropped, so as to permit of the detection of any new foci of disease. The most efficient plan of depilation is by means of the forceps, going over the whole diseased region, taking a small part each day; it is slow and somewhat painful, and must, moreover, be repeated in many cases two or three times before a cure results. It is found, however, that the second or third time, if it is required, need not be so general as the first. The application of a strong carbolic acid wash just before depilation is practised will lessen the pain of this procedure. If this tedious plan is not

feasible, then the hair should be seized, near the scalp, between the thumb and a spatula or similar flat instrument and a moderate amount of tractive force used; the diseased hairs can be thus pulled out, while those sound and firmly seated slip through. It is not so effective as depilation by the forceps. The X-ray treatment has some advocates, both for its depilating and curative action, but should be employed with extreme caution, in the same manner as ringworm (*q. v.*); and unless one is experienced in its use, it is much wiser to hold to the usual plans of treatment.

The whole scalp is to be washed every day with sapo viridis and hot water, the lather permitted to remain for from five to thirty minutes, according to the irritability of the skin, and then rinsed off; after the scalp has been rubbed dry the remedial application is made. These are essentially the same as employed in the treatment of ringworm of the scalp. The most valuable are mercuric chlorid, from 1 to 4 grains (0.065–0.26) to the ounce (32.) of water; sulphurous acid, pure or slightly diluted; ointments of tar, sulphur, and mercury; pyrogallic acid ointment, from ½ to 1 dram (2.–4.) to the ounce (32.); chrysarobin ointment, from 30 to 60 grains (2.–4.) to the ounce (32.). A good compound ointment is the following:

℞.	Ac. carbolici,	ʒj (4.);
	Ungt. picis liq.,	
	Ungt. hydrargyri nitrat.,	āā ʒij (8.);
	Ungt. sulphuris,	ʒiv (16.).

As a certain amount of chemical change takes place in this, it should be made up fresh about once weekly.

Crocker cured one case of twelve years' duration with an ointment consisting of 1 dram (4.) of resorcin to the ounce (32.) of lanolin and oil. If a lotion is selected, it should be rubbed in gently for a few minutes and then dabbed on for four or five minutes and allowed to dry in; caution should be exercised in the use of strong lotions of mercuric chlorid. If an ointment is prescribed, it should be thoroughly worked into the cutaneous structures by more or less vigorous rubbing; and better still, if at bed-time this rubbing in of the ointment is followed by its application as a plaster spread upon lint or any suitable material. After a few months' treatment the remedies should be discontinued for a time in order that the effect may be properly observed. In all cases after several months' active management the malady will be found to be much less extensive in area, and in resuming therapeutic measures this should be taken into account, depilation being practised upon and about the diseased areas only, the hair on other parts of the scalp being kept short for easy inspection. In this manner, if the treatment is energetically pursued and faithfully carried out by the patient or attendant, the surface involved becomes less and less, and a cure will sooner or later result. The new-growing hairs in the affected areas should be examined microscopically from time to time for any evidence of fungus. If there are no signs of a return of scaliness, yellowish points or dulled, lusterless hair in five or six weeks after cessation of treatment, the case may be considered as cured.

In favus of the general or non-hairy surface the crusts are to be washed off with soap and water, or by the conjoint application of softening ointments or oils and frequent washings or alkaline baths. This is usually effected in one or several days. The remedial applications are ointments of sulphur, 1 or 2 drams (4.–8.) to the ounce (32.); of white precipitate, from ½ to 1 dram (2.–4.) to the ounce (32.); of mercury oleate ointment, from 10 to 20 per cent. in strength; of tar, 1 or 2 drams (4.–8.) to the ounce (32.); of pyrogallic acid, from 20 to 60 grains (1.3–4.) to the ounce (32.); of chrysarobin, from 10 to 60 grains (0.65–4.) to the ounce (32.); of resorcin, from ½ to 1 dram (2.–4.) to the ounce (32.); and, in fact, any of the so-called parasiticidal remedies. Sulphurous acid, diluted with 1 or 2 parts of water; a 2 to a 5 per cent. lotion of carbolic acid, and painting with tincture of iodin, will also have usually a promptly curative action. The ointments of mercury oleate and pyrogallic acid are applicable only when the disease is of limited extent.

Constitutional treatment is generally considered uncalled for in this malady, but I am convinced that improvement in the general health and nutrition is of contributory service, although it may be slight. Cod-liver oil, in dose of ½ to 1 dram (2.–4.), along with 3 to 10 grains (0.2–0.65) of sulphur three times daily, have, I believe, some influence; the former by improving the nutrition, the latter by the resulting cutaneous sulphurous exhalation, making the skin a less favorable habitat for the fungus.

RINGWORM.

Synonyms.—Tinea trichophytina; Trichophytosis; Dermatomycosis trichophytina; *Fr.*, Trichophytie; *Ger.*, Herpes tonsurans; Scherende Flechte.

Until somewhat recently ringworm in all its types and in all situations was thought to be due to one fungus—the trichophyton. And yet the admirable work of Sabouraud, independently pursued but a few years back, and by which the plurality of the fungi causing this malady was established, was, as this distinguished investigator subsequently ascertained and generously pointed out, practically an elaboration of what Gruby had indicated fifty years previously, and the significance and brilliancy of whose discovery during all this interim had remained not only unappreciated, but unrecognized.[1] The term porrigo decalvans which he applied to the scalp disease caused by the small-spored fungus,—the microsporon Audouini,—previously employed by Bateman to designate the malady now known as alopecia areata, led to the erroneous belief that Gruby had this latter affection in view, and hence his supposed fungus, always looked for in vain by others in alopecia areata, was soon considered purely mythical. Sabouraud's brilliant investigations, however, have placed Gruby's work in an entirely different light. One of Gruby's fungi was independently discovered by Malmsten in 1844, and denominated by him tricho-

[1] Bazin, *Recherches sur la nature et le traitement des teignes*, Paris, 1853, confirmed Gruby's observations; and in 1891 Furthmann and Neebe, "Vier Trichophytonarten," *Monatshefte*, 1891, vol. xiii., p. 477, advocated the plurality of the causative fungi, and described four varieties.

phyton tonsurans. The common belief was that this fungus was one of the common molds, but Thin, and since, others, have shown that it is a specific fungus. The trichophyton was gradually accepted by most dermatologists as the etiologic factor in all ringworm cases, and this view continued to be held until the result of Sabouraud's studies was announced. His investigations make two chief divisions of the ringworm fungi—the *microsporon Audouini*, or small-spore fungus, and the *trichophyton*, or the large-spore fungus; of the trichophyton there are two main varieties, the *megalosporon endothrix*, and the *megalosporon ectothrix*, and of each of these, but chiefly of the latter, there are several species. Other investigators (Jamieson, Adamson, Colcott Fox and Blaxall, Unna, C. J. White, Malcolm Morris, and others) have, in the main at least, accepted Sabouraud's conclusions, although several, as well as others (Mibelli, Rosenbach, Krösing, Ullmann, Waelsch, Pelagatti, Ducrey and Reale, and others), do not wholly agree with his division of the fungi, or with his views that each fungus tends to produce always a special clinical type of disease. Leslie Roberts classifies the fungi according to their power of digesting horny or keratin tissue; his fungus, which destroys both the cuticle and cortex of the hair, corresponding to the microsporon, and his cortex destroying variety to the trichophyton. He criticizes Sabouraud's division of the latter, as he has himself observed instances in which the "endothrix" may become, under different circumstances, an "ectothrix." The special etiologic bearing of these several fungi will be considered under etiology, and their characters under pathology.[1]

The features, character, and behavior of ringworm vary considerably according to the part involved, whether it be the general, non-hairy surface, the genitocrural region, the scalp, or the bearded region. In a measure the anatomic conditions and physical peculiarities of these various regions are responsible for the difference in the clinical pictures, although in the light of recent research it is not unlikely that they are also to some extent to be attributed to the special fungus which may be etiologically involved. The symptoms and diagnostic characters can best be described under the several regional headings.

[1] The reader desiring to pursue further the investigations and mycology of the ringworm fungi and their asserted relationship to the various clinical forms is referred to the following valuable publications and papers: Sabouraud, "Contribution a l'étude de la trichophytie humaine," *Annales*, 1892, p. 1061; and his later and more complete publication, *Les trichophyties humaines*, Paris, 1894; Rosenbach, "Ueber die tieferen eiternden Schimmel-erkrankungen der Haut und deren Ursache," Wiesbaden, 1894; Leslie Roberts, "The Present Position of the Question of the Vegetable Hair Parasites," *Brit. Med. Jour.*, 1894, ii., p. 685; and "The Physiology of the Trichophytons," *Jour. Pathol. and Bacteriol.*, vol. iii., 1895–96, p. 300; Adamson, "Observations on the Parasites of Ringworm," *Brit. Jour. Derm.*, 1895, pp. 201 and 237; Colcott Fox and Blaxall, "An Inquiry into the Plurality of Fungi Causing Ringworm in Human Beings as Met with in London," *ibid.*, 1896, pp. 242, 291, 337, and 377; and "Some Remarks on Ringworm," *Brit. Med. Jour.*, 1899, ii., p. 1529; Bodin, "Des teignes tondantes du cheval et leur inoculations humaines," *Thèse de Paris*, 1896; Aldersmith, *Ringworm and Alopecia Areata*, fourth edit., London, 1897; Malcolm Morris, *Ringworm in the Light of Recent Research*, London, 1898; Chas. J. White, "Ringworm as it Exists in Boston," *Jour. Cutan. Dis.*, 1899, p. 1.

I. RINGWORM OF THE GENERAL SURFACE.

Synonyms.—Tinea circinata ; Tinea trichophytina corporis ; Trichophytosis corporis ; Ringworm of the body ; Ringworm of the non-hairy surface ; Ringworm of the glabrous skin ; *Fr.*, Herpès circiné ; Herpès circiné parasitaire ; Herpès parasitaire ; Trichophytie circinée ; Trichophytie des parties glabres ; *Ger.*, Herpes tonsurans ; Herpes tonsurans circumscriptus ; Scherende Flechte ; Trichophytie der unbehaarten Hautstellen.

Symptoms.—Ringworm of the general or non-hairy surface, or tinea circinata as it is quite commonly called, may exhibit, as more especially regards its inflammatory characters, some variations. In its typical and most common expression the malady presents as one, several, or more small, slightly elevated, sharply limited, somewhat scaly, hyperemic spots. They spread in a uniform manner peripherally, and as they extend tend to clear up more or less completely in the central portion, assuming a ring-like aspect. Usually, when coming under observation, on the average several days to one or two weeks after their first appearance, the patch or patches are from one-half to one inch in diameter, the innermost or central part pale red, or of apparently normal color, with or without a trifling, often scarcely perceptible, furfuraceous scaliness; and the outer

Fig. 236.—Ringworm (tinea circinata) (courtesy of Dr. M. B. Hartzell).

portion somewhat elevated, but rarely to a conspicuous degree, hyperemic or mildly inflammatory, and somewhat scaly. The hyperemia, inflammatory character, and scaliness are sharply contoured externally, while gradually diminishing on the inner side. The scaliness is seldom more than moderate in amount; usually it is slight.

After reaching a variable size, from a part of an inch to several inches in diameter, they remain practically stationary, or in most instances after a time tend to spontaneous disappearance. After the first several days or a week, more especially when the spreading tendency has about ceased, the color often becomes paler, and even goes into a pale, brownish red. At times, when close together, several may merge and form a large, irregular, gyrate patch. As

FIG. 237.—Ringworm, showing the rather uncommon occurrence of a double ring. Illustration also shows a marked example of freckles.

commonly noted, there are rarely more than several patches present; in some instances only one, in others 5 to 10 or more.[1] In some cases the patches remain small and insignificant, and with but little, sometimes no, tendency to clearing; in such they appear to be more of the nature of rounded, brownish-red or brownish-yellow, scurfy spots, with practically no distinct inflammatory signs, and lacking the sharply defined border. In others the areas consist of ill-defined rings, some segments, and some scurfy spots. Very exceptionally a patch may consist of two or three concentric rings.

The most frequent sites for ringworm are the face, neck, hands, and forearms, although they are quite frequently seen elsewhere. In rare instances the palm is the seat of one or two patches, usually quite inflammatory, the ring-like border being of a vesicopapular or papulosquamous character. The sole of the foot is also a rare site, and here it may appear as just described, or of its ordinary clinical features; or it may simulate flattened, callous-like areas, two such

[1] Colcott Fox and Blaxall, *Brit. Jour. Derm.*, 1898, p. 37, report 2 instances in brothers, aged five and seven, in whom, especially in one (illustration given), the patches were quite numerous and of somewhat general distribution, but none on the scalp; infection probably from a "mangy" cat.

cases have come under my observation. In rare instances a patch in the neighborhood of the lips or vulva has been noted to extend on to the mucous membrane (tinea of the mucous membrane).[1] In very exceptional examples of the mildly inflammatory and slightly or moderately scaly type, the patches are somewhat generalized and quite numerous, sometimes with much less tendency to central clearing than commonly seen, and exemplifying the cases observed in Vienna and described under the name of *herpes tonsurans maculosus*,[2] although most of such cases are, it is believed, examples of pityriasis rosea.

Instead of the malady appearing as slightly inflammatory maculo-squamous rings, sometimes the process is of a severer grade; the peripheral portion is observed to be markedly elevated, red, showing a good deal of inflammatory action, and not infrequently constituted of closely set papules, vesicopapules, or exceptionally vesicles, which may even become pustular. It spreads in the same manner and in other ways is similar, the central portion clearing up; it differs from the common milder type chiefly in the degree of inflammation. In some of these cases as the patch spreads the center clears somewhat, but becomes studded with papulopustules or pustules, as in the accompanying colored plate. In other, rarer, instances the condition, usually consisting of one or several patches, is over the entire area fairly uniform in the character of the inflammatory process, with but little, sometimes scarcely perceptible, lessened activity centrally; the extreme border is, however, rather more elevated. Such patches, with practically no disposition to clear centrally, have a decidedly eczematous aspect, often with considerable infiltration, differing from the latter disease only in the sharply defined character of the border. Such examples might be very appropriately termed parasitic eczema.

Another form only rarely noted is that presenting itself as a somewhat raised, inflammatory patch, beset with crowded follicular papules or papulopustules, and sometimes pustules. Usually but one or two areas are present, of $\frac{1}{2}$ to 2 inches in diameter, and fairly rounded, or irregularly rounded or ovalish in shape, and showing variable, but generally considerable, infiltration and depth. It occurs most commonly on the forearm, back of the hand, and the buttocks, although it may occur on any part. The hairs of the area drop out, as a rule, but regrowth, after cure, takes place. In other exceptional instances a similar but still more advanced inflammatory, deep-seated form is observed, of a somewhat boggy, pseudocarbuncular aspect, with sometimes considerable elevation, and a follicular, seropurulent, or mucopurulent discharge; this is a relatively moderate counterpart

[1] Robinson (case demonstration) and also Cutler (discussion), *Jour. Cutan. Dis.*, 1893, p. 366, record such instances, extending to the lip and mucous membrane of the mouth. Giletti, cited by Malcolm Morris (*loc. cit.*, p. 78), has reported a case of primary ringworm of the mucous membrane of this region.

[2] The general statement so commonly made that all these cases, seen by our Vienna confrères, are examples of pityriasis rosea is by far too sweeping. I recall clearly an instance of extensive distribution involving the trunk chiefly, in Professor Neumann's clinic, when a student of this distinguished teacher, in which the diagnosis was confirmed by the microscope. Jarisch (*Die Hautkrankheiten*, Vienna, 1900, p. 580) is right, I believe, in his opinion that there are two maladies which clinically are often indistinguishable—the one, pityriasis rosea, the other, a type of extensively distributed ringworm, the latter being rare.

of kerion of the scalp, and also of some of the boggy tumors of ringworm of the bearded region. This condition (so-called perifolliculitis suppurative conglomerata) was formerly thought to be an independent affection (first described by Leloir, Quinquaud and Pallier, and Besnier and Doyon)[1] but is now known to belong among the manifestations produced by the trichophyton. Very rarely the deep type extends considerably, the central portion then flattening down, becoming less active while extension is taking place at the periphery, where there is a border of deep-seated inflammatory infiltration, with follicular papulopustules or pustules, so that finally a large, rounded, or irregularly outlined patch may result (*agminate folliculitis*).[2]



FIG. 238.—Ringworm (tinea circinata) of inflammatory, kerion-like type, consisting of 3 patches on forearm; patient a hostler. (The conglomerate pustular folliculitis of Leloir.)

One more form remains to be described, affecting the genitocrural region, and known as **tinea cruris, tinea trichophytina cruris, tinea circinata cruris, eczema marginatum,** which is much more common than the rare varieties just described. It begins here, as a rule, as the ordinary superficial ring type, usually several or more areas soon presenting. Favored by the heat and moisture of the parts the malady develops rapidly, the involved areas become more or less uniformly inflammatory, coalescence takes place, and it soon loses its ordinary clinical appearances. The inflammatory symptoms become predominant, and the whole of the region may be involved, presenting all the symptoms of a moderately or markedly infiltrated true eczema; the border, however, is somewhat elevated, sharply defined, and quite frequently, especially in its earlier existence, one or more outlying patches of the ordinary clinical ring-like type

[1] Leloir, "Sur une variété nouvelle de périfolliculites suppurées et conglomerées en placards," *Annales*, 1884, p. 437; Quinquaud et Pallier, "Des perifolliculites suppurées agminées en plaques," *Thèse de Paris*, 1888; Besnier et Doyon's French translation of Kaposi's *Treatise*, vol. i. p. 795.

[2] See Hartzell's paper, "A Unique Case of Agminate Folliculitis of Parasitic Origin," *Jour. Cutan. Dis.*, 1895, p. 456 (with case illustration and histologic cuts showing the fungus); also paper by Duhring and Hartzell, "A Case of Papulo-ulcerative Follicular Hyphomycetic Disease of the Skin," *Amer. Jour. Med. Sci.*, 1895, vol. cix., p. 283, describing a case of follicular hyphomycetous disease.

of the malady may be seen. It may extend considerably down and outward on the thighs, and in extreme cases well up upon the abdomen, and between and on to the nates. In women it may also extend on to the mucous membrane of the vulva. Occasionally this type is also observed in one or both axillæ (tinea axillaris, tinea circinata axillaris), either along with the disease in the genitocrural region or independently.

Ringworm of the general surface, as commonly encountered, rarely gives rise to any troublesome subjective symptoms—occasionally slight or moderate itching; this in the more inflammatory types, those which show an eczematous aspect, and especially when involving the genitocrural or axillary region, may in some cases be at times quite severe and troublesome.

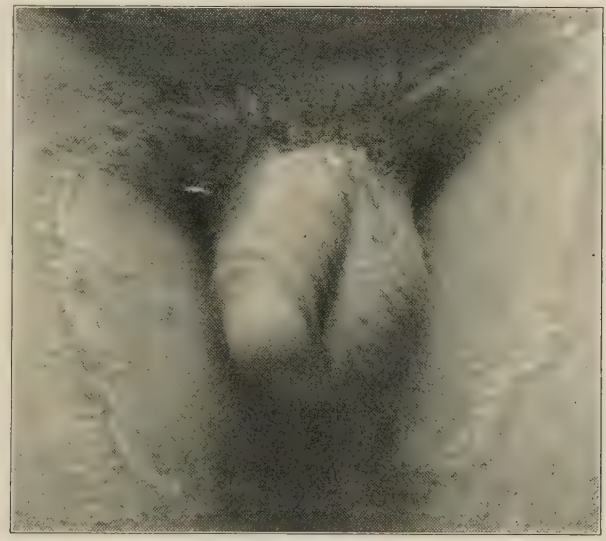

FIG. 239.—Tinea cruris. Ringworm of the genito-crural region.

Diagnosis.—There is no difficulty in recognizing the ordinary cases of ringworm of the general surface, as the growth and characters of the patch, the slight scaliness, the tendency to disappear in the central portion, together with the history, and, if necessary, by microscopic examination of the scrapings from the border of the patch. The ring-like areas of psoriasis bear some resemblance, but it is practically only in the ring appearance, the other features being wholly different (see psoriasis for differential points). The circinate tubercular syphiloderm has sometimes been confused with ringworm, but the greater infiltration of the former, its slow course, long duration, color, and often pigmentation, atrophy, ulceration, or scarring generally serve in the differentiation. Eczema seborrhoicum, especially as it commonly occurs in the sternal and interscapular regions, with the segment-like configuration, is somewhat suggestive, but the scales of this latter are greasy, and often have projections into the glandular openings; moreover, these sites are common for

eczema seborrhoicum, and extremely unusual for ringworm. In the deep-seated types the markedly inflammatory, follicular, and circumscribed character should always suggest ringworm fungus invasion and lead to carefully made microscopic examinations. As Hartzell's case showed, however, sometimes the fungus lies deeply, and must be looked for in a section of the involved tissue. A circumscribed patch suggestive of an exceedingly flat, superficial, mild carbuncular formation should always awaken the suspicion of deep-seated ringworm.

Tinea cruris, and also its counterpart, sometimes occurring in the axillæ, is to be differentiated from eczema and eczema seborrhoicum of these regions. The history of the case, its beginning with rings, its gradual spread and sharply defined elevated border, frequently with outlying typical ringworm patches, will usually suffice, but in some instances careful microscopic examinations of the scrapings from the border are found necessary for a definite conclusion.

II. RINGWORM OF THE SCALP.

Synonyms.—Tinea tonsurans ; Tinea tondens ; Tinea trichophytina capitis ; Trichophytosis capitis ; Trichophytia capitis ; Trichonosis furfuracea ; Herpes tonsurans ; Herpes circinatus ; Porrigo furfurans ; *Fr.*, Herpès tonsurant ; Teigne tondante ; Teigne tonsurante ; Trichophytie circinée ; Trichophytie du cuir chevelu ; *Ger.*, Scherende Flechte ; Herpes tonsurans ; Herpes tonsurans capillitii.

Symptoms.—Ringworm of the scalp, or tinea tonsurans, as it is quite frequently called, in the large number of cases varies but slightly in its characters, except as to the extent of the involvement. In relatively few instances, however, the features, one or all, show a material departure from the ordinary. It begins usually in the same manner as that upon the general surface, as a hyperemic, scaly spot, with practically no tendency to central clearing. In infants or very young children with light, scanty hair, however, it sometimes presents all the characters of that on the latter region, showing, moreover, but little disposition, in the beginning at least, to hair or follicular involvement. Its development is, as a rule, much more insidious. Sooner or later the hairs and hair-follicles are invaded by the fungus, and in consequence the hairs fall out or become brittle and break off, either a little distance from the skin or just on a level with it. The hyperemia or inflammatory action is scarcely, and often not at all, recognizable. The surface is a trifle scaly, rarely conspicuously so. The follicular openings, except in long-standing cases, are slightly elevated and prominent, and the patch may have a puffed or goose-flesh or plucked-fowl appearance. In other instances the surface is somewhat smooth and irregularly scaly, the scaliness being of a furfuraceous character, and of a grayish or dirty-gray color. There may or may not be at times slight or moderate itching, but it is seldom sufficient to give rise to complaint.

A typical fully developed patch of ringworm of the scalp in the majority of cases is therefore noted to be rounded, grayish, somewhat scaly, and slightly, but often scarcely perceptibly, elevated. The follicles, more especially those from which the hairs have fallen, are

somewhat projecting, usually stuffed with grayish epidermic débris; there is more or less alopecia, with here and there over the area broken, gnawed-off-looking hairs, some of which, of a whitish or grayish color, may be broken off above, and just at the outlet of the follicles. Many of the broken hairs and stumps are surrounded within the follicle mouth and somewhat above by a powdery sheath, flattening out slightly at the level of the surface, constituting the so-called circumpilar collarette, which, when numerous, give the patch a powdery appearance. One, several, or more such areas, of different sizes from a fraction of an inch to a few inches in diameter, may be present—in the average case usually two or three. They extend, as a rule, somewhat slowly, those of the larger dimensions named requiring several weeks to a few months or longer. After attaining a variable size, they may remain more or less stationary, and the malady may thus sluggishly continue indefinitely or new spots arise here and there. When several patches are in close proximity, from gradual enlargement coalescence takes place, and a large, irregular area results. The scaliness rarely consists of more than a slight branniness, although exceptionally it is of moderate amount. In some children, after an indefinite duration, sometimes partly as the result of treatment and sometimes spontaneously, the hairs begin to grow in again, the disease in great measure disappears, and there are left small scattered spots, each often scarcely involving more than several follicles, constituting the **disseminated ringworm** of Alder Smith. Occasionally the malady presents itself primarily in this form.

In other instances the inflammatory character is relatively more pronounced, especially at the periphery, the border consisting of contiguous, ill-defined papules or vesicopapules, and in some cases a tendency to pustulation; the main part of the patch being as already described, or distinctly hyperemic and inflammatory. In others the whole patch may show a scanty or abundant number of papulopustules, and in such very often, from time to time, considerable crusting may be seen.

The loss of hair of the involved areas is rarely complete, but in most instances there are no long hairs, those remaining usually having broken off near the scalp; they are lusterless, brittle, some of them often twisted up or bent, and which break upon the slightest attempt at traction. In others most or all of the hairs are broken off just at the follicle mouth, and give the patch a dotted appearance—so-called **black-dot ringworm.** In occasional cases, usually in those of decidedly blonde hair, the hairs are only moderately lost, not sufficiently so to attract attention, those remaining being dry, lusterless, often bent and straggly, and easily broken; the patch is recognizable only on close inspection, the skin being found slightly scaly, and sometimes with scarcely perceptible hyperemia. In exceptional instances, however, the hair loss is not only complete, but it is rapid, the hairs not breaking off at the surface level, but falling entirely out of the follicles, the area developing and extending rapidly—constituting the so-called **bald ringworm** or **bald tinea tonsurans** of Liveing.

Occasionally a type of ringworm of the scalp, of a markedly inflammatory nature, known as **kerion, tinea kerion, kerion ringworm,**

develops either from a preexisting patch of ordinary characters or primarily as such, the inflammation involving the deeper tissues. It presents the appearance of a more or less bald, rounded, inflammatory, edematous, boggy, honey-combed, somewhat prominent, carbuncle-like tumor, discharging from the follicular openings a mucoid or mucopurulent secretion. It is sometimes painful. If neglected, crusting often takes place, and the pent-up discharge may undergo change and become offensive. Those hairs which have not fallen out come away with practically no traction. If pressure is made

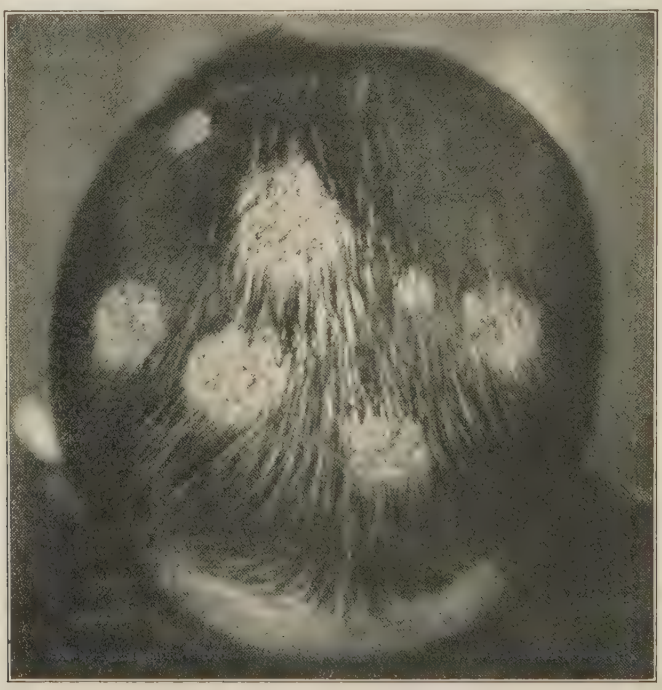

FIG. 240.—Ringworm (tinea tonsurans) of somewhat inflammatory type.

laterally, the thick, glairy, mucoid or mucopurulent secretion can readily be ejected. Very often the intensity of the inflammatory action results in destruction and dislodgment of the fungus, and a spontaneous cure results. This type practically corresponds to the boggy or tumor-like formation frequently seen in ringworm of the bearded region, and also to that rarely encountered on the general surface. To a prominently elevated kerion-like type, appearing as variously sized nodular elevations, and which, instead of discharging through the follicles, gradually breaks down and empties like an abscess, Majocchi has given the name of **granuloma trichophyticum.**[1]

Diagnosis.—Ringworm of the scalp, as commonly encountered, presents a clear and decisive symptomatology; its features—the slight scaliness, broken hair, hair-stumps, the blach dots, often promment follicles, with more or less baldness of the involved area,

[1] Majocchi, *Dermatolog. Zeitschr.*, Oct, 1902, p. 641.

together with the history—are ordinarily sufficiently characteristic to prevent error, and will serve to exclude such maladies as seborrhea, psoriasis, and eczema, in which such a symptom-complex is lacking. The hair loss and nutritional changes in the hair are the most important differential points. Moreover, the scaliness of psoriasis is more abundant, and patches are usually to be found elsewhere. Eczema is commonly diffused, quite itchy, often with considerable scaliness, and frequently with a history of gummy oozing. Seborrhea is, as a rule, general over the scalp, the scales are greasy, and while there may be some thinning out of the hair, this does not occur in patches.

Favus and alopecia areata are the two diseases with which confusion is most likely to be experienced. In favus, although the same tendency to hair loss and the same lusterless and brittle condition of the hairs are noted, the presence of the yellowish, cup-shaped crusts or mortar-like accumulations, and the atrophic character of the involved skin, are wholly different from what obtains in ringworm. Nor are the patches of favus, as a rule, rounded, as they are in ringworm. The incomplete hair loss, the scaliness, the brittle and broken hairs, and the hair-stumps will serve to distinguish the malady from alopecia areata, in which the sole symptom is loss of hair, complete in character, the skin being perfectly smooth and with a shiny and highly polished appearance. As between the rare type, bald ringworm, and alopecia areata, microscopic examination of the hairs from the edge of the patch will usually, if the former disease, disclose fungus, and thus serve to distinguish it. In fact, in all cases of doubt as between ringworm and the several maladies named, the microscope should be resorted to. It is to be remembered that ringworm of the scalp, with extremely rare exceptions, never occurs in the adult.

The inflammatory types of ringworm are rare, and while such instances resemble some of the inflammatory diseases, especially eczema, the hair loss and involvement, the history of the case, its limited area, and, if necessary, microscopic examination, will suffice to differentiate. Kerion should not be confused with carbuncle; a mistake, strange to say, that has been occasionally made by surgeons. The boggy, circumscribed character, the mucoid or mucopurulent discharge from the follicular openings, and frequently a history of its having begun as an ordinary ringworm patch are points of difference.

III. RINGWORM OF THE BEARDED REGION.

Synonyms.—Tinea sycosis; Tinea barbæ; Tinea trichophytina barbæ; Trichophytosis barbæ; Sycosis parasitica; Sycosis parasitaria; Sycosis contagiosa; Sycosis hyphomycotica; Herpes tonsurans barbæ; Mentagra parasitica; Ringworm of the beard; Barber's itch; Parasitic sycosis; Parasitic mentagra; Hyphogenous sycosis; *Fr.*, Sycosis parasitaire; Sycosis trichophytique; Trichophytie sycosique; Trichophytie de la barbe; *Ger.*, Parasitäre Bartfinne; Parasitische Bartfinne.

Symptoms.—Ringworm of the bearded region, or tinea sycosis, as it is commonly termed, is met with infrequently as compared to

the disease on the scalp or general surface. There are two distinct types observed, one which remains superficial, and the other, a deep-seated or nodular form. As a rule, it begins in the same manner as



FIG. 241.—Ringworm (tinea sycosis, superficial type) somewhat suggestive of a spreading circinate syphiloderm (fungus demonstrated).

ringworm on non-hairy parts, as one or more rounded, slightly scaly, hyperemic patches, with, in some or all, the tendency in their earliest formation to be more pronounced peripherally.

In the *superficial variety* it so continues, the areas enlarging and clearing up somewhat centrally, the border being usually quite distinctly elevated. Several near-by patches may coalesce and give rise to a large, irregular area. There may or may not be slight or moderate itchiness. The hairs and follicles are involved to a slight or decided extent, and show similar changes to those observed in the scalp disease; never, however, to so pronounced a degree. They are, in most parts, readily extracted, with but little traction; in fact, in some cases some of them drop out spontaneously. On the other hand, not infrequently they, or the most of them, remain firmly implanted, the disease limiting itself to the epidermis proper. The malady may thus continue, often after a time remaining stationary, or even showing a tendency to disappear without treatment. There is in this form rarely any disposition to pustulation. In other instances the process involves the tissues somewhat more deeply, giving rise to some thickening and infiltration, exhibiting a midway condition between the superficial variety and the deep-seated form, into the latter of which it may finally develop.

Sabouraud describes a superficial form (trichophytie sèche, à forme d'ichtyose pilaire) of the malady in which the skin itself remains uninvolved, the hairs and upper part of the follicles suffering; the hairs are broken off a little distance from the skin, and the base is surrounded by dry epidermic scales or débris.

The *deep-seated variety* begins, as a rule, in the same manner as described, and after remaining superficial a variable time, shows a decided, and often rapid, tendency to extend down into the follicles and tissues; occasionally it begins somewhat similarly to sycosis vulgaris. As a result of such deep involvement more or less subcutaneous swelling ensues, and the affected parts assume a distinctly



FIG. 242.—Ringworm (tinea sycosis) in a hostler, of ten days' duration. Patches are of the deep-seated, kerion-like, or pustulo-inflammatory type, the hairs loosening and falling out; one side of the upper lip also partly involved.

lumpy and nodular condition, often suggestive, when extensively developed, of crowded, sluggish, somewhat flattened, furuncles or cutaneous abscesses, and at times having a carbuncular aspect. The overlying skin is usually considerably reddened, often presenting a glossy appearance, and studded with few or numerous follicular pustules. The nodules ordinarily, after a time, tend to soften and break down and discharge at one or more of the follicular openings, a glairy, glutinous, mucopurulent or purulent material, which may dry to thick, adherent crusts. In some instances, instead of fairly well-defined lumpiness or nodulation, it presents as patchy, diffused, sometimes circumscribed, firm, later boggy, infiltrations. In others

the features are closely similar to those of kerion on the scalp, with which, in fact, the process is in many respects analogous. The hairs themselves may or may not be conspicuously implicated, but, as a rule, as soon as the tumor-like swellings are at all developed they fall out; sometimes, indeed, earlier in the disease. The extent of the involvement varies; it may take in the whole bearded region, being especially well marked just on the chin and under the jaw, producing a good deal of disfigurement; in other cases it may remain more or less limited to the chin, and exceptionally there is but one patch of carbuncular-looking aspect. The upper lip is seldom involved, probably never independently, but along with extensive invasion of the

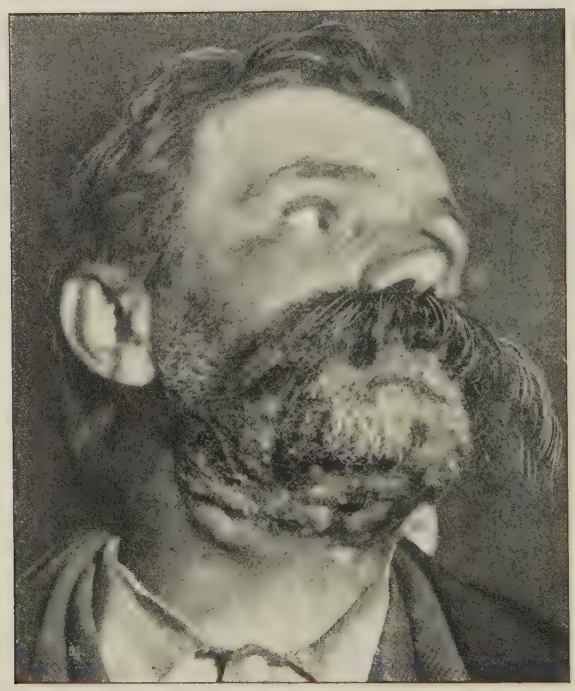

FIG. 243.—Ringworm (tinea sycosis) of the deep-seated, kerion-like, and nodular type. The whole neck and chin are invaded, the hairs loosening and falling out. Three months' duration.

other parts. The process shows but little disposition to spontaneous disappearance, usually continuing, in an irregular, sluggish manner, more or less indefinitely, unless relieved by treatment. As to subjective symptoms, there may be, especially in the earlier stages, slight itching; later possibly burning, and variable soreness and tenderness.

Diagnosis.—The superficial type of ringworm of the bearded region is, as a rule, readily recognized by its ring-like configuration, its method of beginning and extension, and quite usually also by evidences of hair involvement. It might possibly, if consisting of but few ring patches, be mistaken for the circinate tubercular syph-

iloderm. In this latter the border is more infiltrated, is of darker color, and the part traversed frequently shows atrophy or pigmentation, or both; if ulceration or scarring is present, as often noted, it would furnish conclusive proof of its syphilitic character, as these are not seen in the superficial form of ringworm. Moreover, in ringworm the hairs quite commonly exhibit the effects of the fungus invasion, and in doubtful cases can be subjected to microscopic examination. The ring-like characters of the patches and the hair involvement, as well as the history and course, will serve to distinguish it from eczema and seborrhea. These features and the absence of any

FIG. 244.—Ringworm (tinea sycosis) of the deep-seated, kerion-like, and nodular type, of a month's duration, consisting in this instance—comparatively rare—of but one area made up of several confluent, deep-seated, suppurating nodules, with loosening and falling out of the hair. Such cases are occasionally mistaken for carbuncles and abscesses.

special tendency to follicular pustules suffice to exclude sycosis vulgaris.

The deep-seated, nodular form, if at all developed, can scarcely be confounded with other maladies—the peculiar lumpiness of the parts, the involvement of the hair and hair loss, the history, and finally, in doubtful cases, microscopic examination, furnishing conclusive differential points. Sycosis vulgaris is relatively superficial, with no conspicuous infiltration or lumpiness, and the pustules usually small and pierced by a hair; and unless the suppurative action is marked, there is but little tendency for the hairs to fall out. There could scarcely be confusion with the tuberculogummatous syphilo-

derm, as the superficial or deep ulceration, the greenish, purulent, and commonly offensive discharge, as well as the bulky crusts often observed in syphilis, are not to be found in tinea sycosis. In fact, in the latter, although its characters are frequently suggestive of possible destructive action, most cases after recovery show but little marking, often not any at all; in others several or more small insignificant scars. Special care should be exercised not to mistake the single circumscribed tumor-like formation to which exceptionally ringworm limits itself for a carbuncle; a sluggish formation of this kind on the chin region, showing generally much less inflammatory activity than carbuncle, with relatively slighter swelling and pain, should always be, first of all, considered as probably of ringworm fungus origin, and the hairs accordingly examined. Three or four instances have come to my notice in which the growth was opened by surgeons under the impression that it was carbuncular or of the nature of an abscess.

Etiology.—Ringworm is due to the invasion of the epidermic tissue by fungus elements. The fungi that may give rise to the malady, as stated in the preliminary remarks, consisting of two main varieties, the microsporon Audouini or small-spored fungus, and the trichophyton megalosporon or the large-spored fungus; of the latter there are two principal species, the endothrix and the ectothrix. The ectothrix variety is responsible for the markedly inflammatory types. Of the endothrix there are two subspecies, the "resistant" and "fragile"; and of the ectothrix, according to Sabouraud, several or more varieties.

The disease is contagious. It may be conveyed directly by contact, or through the medium of toilet articles and wearing apparel. It is particularly common in children's schools and institutions where there are so many opportunities, direct and indirect, for communication. Day nurseries, "homes," and like charitable havens for infants and children are often quite active centers for its spread. Barber-shops and hair-dressing establishments, "complexion or beauty parlors," laundries, etc., are likewise common sources of the disease. It is also quite frequently transmitted from the lower animals, especially the cat, dog, horses, cows, rabbits, etc.[1] The wearing of underwear brought from the laundry in a damp condition, subsequently having a moldy odor, has, according to my observations, apparently been of etiologic bearing in some cases of body ringworm. Both sexes are liable, and in about equal proportion; and age in a general way, except in certain situations, exercises but little influence, although the malady is seldom seen in those past fifty. Those of fair complexion and whose general nutrition is impaired are thought to be more susceptible, especially as regards the scalp affection, but while seemingly so in many instances, Aldersmith, Crocker, and many others hold the contrary. My own observations indicate that the most stubborn types are more commonly met with in those of rela-

[1] Examples of contagion from the dog, cat, and horse are found quite numerously referred to in literature, and are not uncommon in those with large clinical opportunities. Eddowes, *Brit. Jour. Derm.*, 1898, p. 149, gives an instance in a girl of fifteen of its contraction from a pet hedgehog, the fungus being found in the scrapings from the

PLATE XXX.

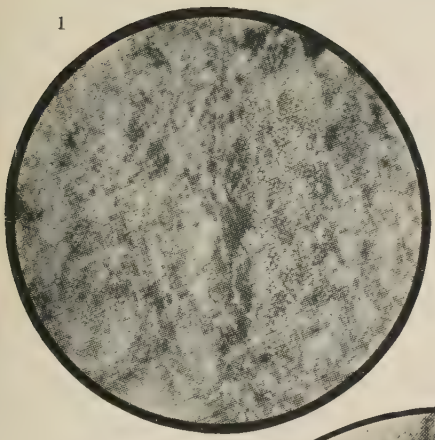

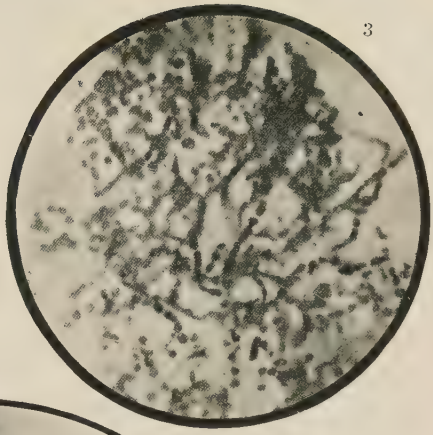



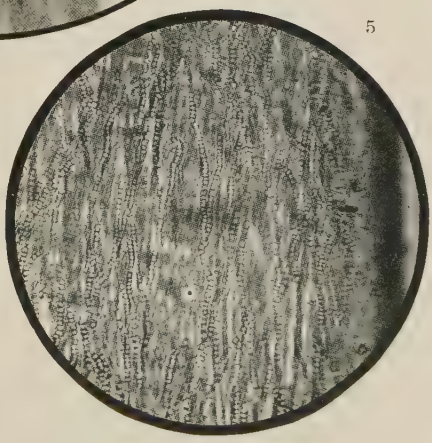

FIGS. 1 and 2 (× about 300).—Microsporon Audouini in the hair; Fig. 1 shows mosaic of spores and also mycelium, the latter seldom seen in these cases; Fig. 2 is a stained specimen.

FIG. 3 (× about 400).—Trichophyton of the endothrix variety—stained specimen. (Courtesy of Dr. Charles J. White.)

FIGS. 4 and 5 (× about 400).—Trichophyton of the variety ectothrix; hairs from a case of ringworm of the bearded region involving also the upper lip—hairs from the latter region. Fig. 4 shows fungus on surface of a hair, and Fig. 5 fungus in the hair. (Courtesy of Dr. M. B. Hartzell.)

tively poor general health, but as to the influence of complexion, I have encountered the malady, in all its situations, but especially on the scalp, quite frequently in negro children, probably as often relatively as in whites. The disease prevails to a somewhat greater extent in some countries than in others, although it is common enough everywhere. Sabouraud's experimental investigations indicate that susceptibility may measurably depend upon the acidity or alkalinity of the sweat secretion, the latter condition largely increasing the proportion of successful inoculations.

Ringworm of the general surface may occur at any age, but is much more frequent in children and young adults; less so in the middle period of life, and rather unusual in advancing years. As typically encountered, it is due to the large-spored fungus, commonly the ectothrix variety. This is also etiologic in the markedly inflammatory and deep-seated types. It is of animal origin. The superficial furfuraceous macular spots or patches seen, with sometimes but little tendency to clearing centrally, and of but slightly hyperemic character, are usually due to the small-spored fungus; and those transitory forms of lenticular rosy macules, often scarcely perceptibly reddened, are caused, for the most part at least, by the endothrix variety of the large-spored fungus, although this latter sometimes, as well as also less frequently the microsporon, are productive of typical examples of the malady.

Ringworm of the scalp is a common affection, but it is one which may be said to be limited to children, seldom presenting or persisting after the fourteenth or fifteenth year, and with rare exceptions never occurring in the adult. I have met with but one such instance in a woman aged thirty. Professor Duhring[1] has "never seen it in persons over sixteen or seventeen years of age." Hyde and Montgomery[2] state that "ringworm in the scalp of the adult and the aged is, indeed, among the rarest of cutaneous accidents." Crocker[3] has observed it beginning in the adult, in 3 instances, one at the age of thirty-four, one at fifty-three, and another at fifty-five; Jamieson[4] in 2 women, one a nursemaid, the other aged thirty-eight; Aldersmith,[5] with his large experience, has seen it in but 5 cases in twenty years. Cases have been reported recently by Colcott Fox,[6] Anderson,[7] and

patient, and also in the prickles of the animal. Busch, "On Ringworm Infection in Man and Animals," *Brit. Med. Jour.*, Feb. 9, 1901, records several examples of animal contagion, among which one from a pet canary; in these instances the observations were confirmed by examination of the animals. Kessler, *Jour. Amer. Med. Assoc.*, Oct. 25, 1902, finds that in stock-raising districts the most frequent source of contagion is from cattle and especially from yearling calves; the farmers call the disease "barn itch"; and Mewborn, "A Case of Ringworm of the Face and Two of the Scalp Contracted from a Microsporon of the Cat; with Some Observations on the Identification of the Sources of Infection in Ringworm Cases by Means of Cultures," *New York Med. Jour.*, Nov. 15, 1902 (with illustrations).

[1] Duhring, *Diseases of the Skin*, third edit., p. 615.

[2] Hyde and Montgomery, *Diseases of the Skin*, seventh edit., p. 843.

[3] Crocker, *Diseases of the Skin*, third edit., p. 1293.

[4] Jamieson, *Diseases of the Skin*, 1888 edit., p. 463.

[5] Aldersmith, *Ringworm and Alopecia Areata*, fourth edit., 1897, p. 22; also an additional case (male, aged twenty-three), reported recently, *Brit. Jour. Derm.*, 1898, p. 5.

[6] Colcott Fox, *ibid.*, 1898, p. 253 (in a man aged forty-two).

[7] Anderson, *ibid.*, p. 156 (resembling alopecia areata).

Abraham.[1] These adult scalp cases—those noted by the last four observers named and also the last one of Crocker's cases—were due to the large-spored fungus, all except Anderson's to the endothrix variety; Anderson's to the ectothrix. In the others the variety of fungus was not known or not stated.

Ringworm of the scalp, however, as observed in children, is preponderantly due to the small-spored fungus, although in a fair proportion the endothrix of the large-spored fungus is etiologic, and the ectothrix is also occasionally causative—the last being commonly responsible for the inflammatory pustular types. In hospital and dispensary practice C. J. White's investigations show the microsporon causative in Boston in 88 per cent. of the cases; Corlett,[2] 90 per cent. in Cleveland; G. W. Wende (cited by Corlett), in 89 out of 90 cases in Buffalo; Colcott Fox and Blaxall give 80 to 90 per cent. in London, where Adamson's observations give a still higher proportion—178 out of 183 cases, and, according to Aldersmith, 78 per cent. in private practice; Sabouraud, 60 per cent. in Paris; in Scotland, according to Norman Walker,[3] the enormous bulk of the cases, and in 18 out of 20 of Jamieson's [4] cases. On the other hand, in Italy, Mibelli[5] has not met with the small-spored fungus in a single instance, the malady being due to the large-spored variety. The trained eye can in many instances usually recognize, by the clinical appearances in a given case, which variety of fungus is likely to be found, but this knowledge is a matter of no import in the practical management of the case.[6]

[1] Abraham, *ibid.*, p. 163 (4 cases since 1885).

[2] Corlett, "Recent Researches in Ringworm," *Jour. Amer. Med. Assoc.*, Mch. 18, 1899.

[3] Norman Walker, *An Introduction to Dermatology*, 1899, p. 150.

[4] Jamieson, *Brit. Med. Jour.*, 1893, ii., p. 470.

[5] Mibelli, "Sur la pluralité des trichophytons," *Annales*, 1895, p. 733.

[6] Those cases of ringworm of the scalp presenting the well-defined rounded patch, with follicular prominences, or goose-flesh appearance, and with light or dirty-grayish colored branny or lamellated scales, and showing a powdery sheath or sheath-like covering (so-called circumpilar collarette) surrounding the whitish or grayish stumps and hairs just within and above the follicular outlet are due to the microsporon. The hairs are grayish, lusterless, and readily broken, and as most have been broken off, the patch has a nibbled appearance. Only rarely is it responsible for the pustular or other inflammatory forms. In that due to the trichophyton of the endothrix variety (in both subspecies, resistant and fragile) the areas are smoother than those due to the microsporon, and sometimes the surface is quite clean-looking, lacking the grayish, frosted look, and only exhibiting broken hairs and hair-stumps, and these usually without the circumpilar collarettes. There may be one or more areas. Sometimes in these cases, especially due to the "resistant" subspecies, there may be present some sebaceous scaliness, suggesting seborrhea. Disseminated ringworm and the "black-dot" ringworm are sometimes due to this latter subvariety, although the "fragile" subspecies is more commonly responsible for these forms, and also for many of the cases of "bald ringworm." When due to the endothrix, more especially the resistant variety, there may be seen very often one or two large areas, with outlying or scattered small patches. It is especially ringworm of the scalp caused by the endothrix that often has associated with it well-marked patches of tinea circinata. Kerion and other markedly inflammatory and pustular types are usually due to the ectothrix variety; Sabouraud says always, but Aldersmith, Colcott Fox and Blaxall, Adamson, Malcolm Morris, and others have found the kerion type quite frequently produced by the small-spored fungus. The ectothrix fungus is also held responsible for the cases of ringworm of the bearded region observed in the male adult, and contracted, either directly or indirectly, from animal sources, the pus-producing variety from the horse. It is therefore much more common in hostlers and those who have to do with these animals and cattle.

PLATE XXXI.

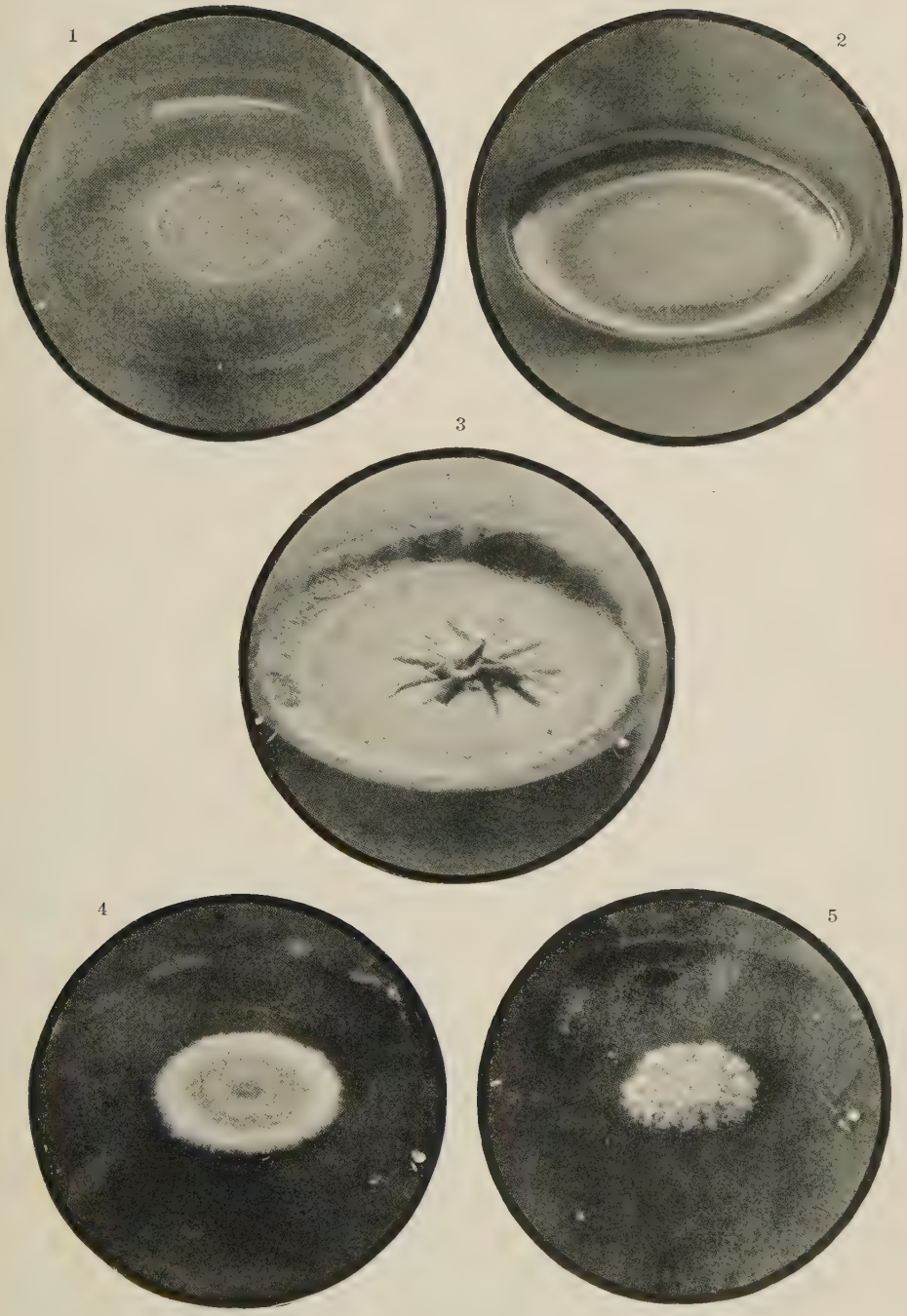

FIGS. 1 and 2.—Cultures of the microsporon Audouini—fungus from different cases; show slight variations.

FIG. 3.—The crateriform culture of the trichophyton of the variety endothrix and form "resistant."

FIGS. 4 and 5.—Cultures of the trichophyton of the variety of ectothrix, from cases of ringworm of the bearded region; Fig. 4 from the superficial, and Fig. 5 from the deep-seated, type of the disease.

(Courtesy of Dr. Charles J. White.)

Pathology.—The pathogenic rôle of the parasitic vegetable organism in provoking the conditions described is at the present day unquestioned. The plurality of the causative fungi is also generally conceded, although few admit the numerous varieties and subspecies of Sabouraud, such careful observers as Leslie Roberts and others considering that the variations, or many of them, at least, are due to the cultural methods and to the quality of the "soil," etc.[1] The fungus invades the epidermis and hair, and in occasional instances the nails (see onychomycosis), and the phenomena observed are due to its mechanical, irritative, and destructive action. In some instances, more especially in the markedly inflammatory types of the malady, fungus elements are found deep in the follicles, in the perifollicular tissue, as well as in the derma proper (Robinson, Pellizari, Campana, Rosenbach, Hartzell). The parasite finds, however, its most suitable habitat and flourishes most luxuriantly in keratinized epithelial structures. The exact botanical position of the microsporon and the trichophyton are still involved in some doubt. Sabouraud contends that the microsporon is distinct from the trichophytons, but is not able as yet to attach it to any particular family; the trichophyton, owing to the tendency to form masses of spores, he is inclined to place among the mucedinous mold fungi, varieties of the family botrytis, or the sporotricha. Other investigators, among whom are Aldersmith and Colcott Fox and Blaxall, believe they are nearly related members of the same family, and that fructification is developed practically on precisely the same plan. The source of the fungi is also as yet not definitely settled. Sabouraud believes that the microsporon is essentially a human parasite. Malcolm Morris states the matter thus: "The origin of the fungi is uncertain. Sabouraud thinks it probable that the trichophytes, or some of them, may exist independently as saprophytes, and this suggests the possibility of direct contagion from moldy vegetable substances. Ectothrix is believed to be exclusively of animal origin (Colcott Fox)—more particularly the horse and cat. Some trichophytes also infest birds. The small-spored fungus is likewise believed to be occasionally derived from the horse, cat, or dog."

In extemporaneous *examination for fungus*, if in ringworm of the general surface, scrapings are taken from the border of the patch and immediately contiguous skin, and put in some liquor potassæ on a glass slide, with the cover-glass lightly placed over it; this is permitted to soak for five or ten minutes or more, and then the cover-glass pressed down and the material flattened out. If ringworm of the scalp or bearded region, an affected hair-stump or broken hair, preferably the former, is carefully removed or picked out of the follicle, and similarly treated, but, as a rule, a much longer soaking is required, and in stiff, thick, and dark hairs a stronger solution. After a variable time the cover-glass is firmly pressed down. Occasionally it is preferable to soak the hair in a shallow vessel containing the potash solution. The specimen can then be examined, for which a

[1] See a valuable and suggestive publication by Leslie Roberts, *An Introduction to the Study of the Mould Fungi Parasitic on Man*, 1893—a good critical review of the same by Norman Walker in *Brit. Jour. Derm.*, 1893, p. 375.

power of 300 diameters or more is required. Jamieson heats the potash solution containing the specimen somewhat by holding the slide over a spirit-lamp for a few seconds, and subsequently washes the alkaline solution out, and examines the specimens in glycerin. They can be mounted in this latter, although after some time they become rather thin, washed-out-looking, and too transparent.[1]

The characters of the fungi vary somewhat. The spores of the microsporon Audouini are usually rounded, occasionally somewhat oval, and, as the result of pressure, sometimes polyhedral. They are often double-contoured, contain granules and liquid, and are from 2 μ to 2.5 μ in diameter. The mycelium consists of sharply contoured, transparent, pale-grayish, branching threads or tubes, showing frequently slight bulging at irregular intervals, and often terminating in mycelial spores. They are jointed here and there with real dissepiments, the septa containing granules and cells. Cultures of this fungus show slight differences in some instances, indicating possible variations in the plant, although for the most part they are practically identical. These differences are slight compared to those observed with cultures of the varieties of the trichophyton. Some trifling variations are noted also in cultures of the various species as found in different countries. The trichophyton, or large-spored fungus, has spores and mycelium larger than those of the microsporon; the spores are from 3 μ to 6 μ in diameter, and are arranged in a ladder-like or bead-like manner, forming band-like mycelium. The mycelium does not branch so much as that of the small-spored fungus. The mycelial filaments, whether sporulated or not, always divide dichotomously (Morris). The mycelium of the ectothrix is large and very abundant in ringworm of the body, and the septa are long—much longer than the septa of either the endothrix and the microsporon. In culture the trichophyton endothrix with the "fragile" mycelium always gives acuminated cultures, while that of the "resistant" mycelium gives crateriform cultures. Sabouraud employs agar maltose as the culture-medium. According to the variety of fungus, its position, arrangement, and manner of the hair invasion are to a variable extent somewhat different,[2] although, according to Colcott Fox and Blaxall, Malcolm Morris, Ravogli, and others, the finer distinctions in the appearances and site of invasion insisted upon by Sabouraud are not to be taken too strictly.

Prognosis.—Ringworm is a curable malady, varying consider-

[1] Malcolm Morris strongly advises the adoption of staining methods for the careful morphologic study of the specimens. His plan, as modified by Norman Walker, is as follows: "The hairs and scales are put on a slide and a drop of anilin-gentian violet or alum gentian-violet 1 to 5 : 100 added. Here it must remain at least five minutes. It is then treated with Gram's solution for three minutes or longer, and then dried with blotting-paper. Then a drop of anilin oil with enough iodin in it to make a dark cherry color is added; and after a little washing to and fro, it is examined under a low power. In most cases this is enough; but if the specimen is to be preserved, it must be washed in pure anilin and then in xylol before mounting." The small-spored fungi, according to Morris, stains much more quickly than the large-spored. The permanent mounting can be made in Canada balsam.

[2] In the microsporon ringworm the fungus lies around the hair, forming the grayish sheath or collarette described by Sabouraud. This observer and Malcolm Morris state

ably in rebelliousness in the several regions involved, and also in the same regions in different individuals. The variety of the fungi that may be etiologic in a given case has in a measure also a bearing, but for practical purposes this can usually be ignored. Ringworm of the general surface is, as a rule, readily manageable, in average cases of but a few patches of the mildly hyperemic and scaly type, from several days to a few weeks' treatment generally sufficing to remove the disease. Exceptionally, however, the patches, especially of the moderately and markedly developed type, are slow in yielding, and new areas continue to spring up irregularly from time to time. The deep-seated variety is the most rebellious, and occasionally, when apparently cured, a recrudescence gradually presents in the same situation after treatment has been discontinued. Such exceptional examples may require a few months' use of somewhat strong remedial applications before permanent freedom is secured.

In the genitocrural parts (tinea cruris, eczema marginatum), as likewise in its analogue in the axillary region, it is usually, even in its

that the cuticle of the hair is first attacked and eaten away; the edges thus frayed and the interior of the shaft invaded and in a downward direction, toward the root. Adamson and Colcott Fox, on the contrary, hold that the epidermis is first attacked. The spores are often arranged in a mosaic-like manner around the hair, with little tendency to form bands, but about the junction of the shaft with the bulbous portion is a terminal fringe of long, plain, narrow, delicate, sometimes branched, mycelial threads, which Colcott Fox regards as quite characteristic. The hair is finally often completely invaded, and the broken ends found swarming with conidia.

With the large-spored fungus, endothrix variety, the hair-root first suffers, and the action extends upward, the spores being arranged in chains, intermingled with short, irregularly jointed mycelium. There is no visible circumpilary sheath, the spores lying sometimes inside and sometimes outside of the hair. The mycelia run up the shaft parallel to its long axis. This variety can usually be recognized microscopically by the large spores and the bead- or ladder-like characters of the chains of spores, and especially by their intrapilar position (Aldersmith). In the resistant variety, in the earliest stage, strings of jointed, ladder-like mycelium are seen outside of the hair and also entering its substance; in the latter first only a few threads, later the hair is more or less infiltrated with it. Finally all parts show fungus invasion—hair-shaft, its exterior, especially between the hair and the root-sheath, and the bulb. There is seen dichotomously branched mycelium with transverse septa in the root-shaft, extending downward toward the bulb. There may be finally a slight circumpilary sheath resulting from the surrounding groups and chains of spores. In the fragile endothrix the conditions found are somewhat similar, but the bands are not so long and continuous, and instead of being ladder-like, have more the appearance of strings of beads or "chaplets," the hair substance sometimes so crowded that, as Sabouraud suggests, it looks like "fish-roe" or a "bag of nuts." The mycelia of the fragile form is less readily disintegrated by liquor potassæ than is the resistant form.

In the ectothrix variety, usually observed in ringworm of the bearded region, the fungus is found principally in the intrafollicular portion, consisting of large long bands with segments at irregular, usually long, distances, and often dividing dichotomously. They run along outside of the hair, slightly invading the cuticular portion, sometimes markedly (endo-ectothrix), although this latter is rarely eroded, as in the small-spored variety. The spores vary considerably in size, from 3 μ to 12 μ in diameter, and are situated around the hairs arranged in chains. Sabouraud states that the hair is not invaded, the fungus remaining outside, but according to Aldersmith, Colcott Fox and Blaxall, the shaft is sometimes, probably always (Fox and Blaxall), implicated to some extent. Ravogli's ("Notes on Ringworm," *New York Med. Jour.*, June 29, 1901) studies showed that both the endothrix and ectothrix could be found vegetating inside of the hair and in the epidermis. In hairs from cases of tinea sycosis, due to the ectothrix, I have often seen the shaft more or less crowded with mycelium, as also shown in accompanying cut by Hartzell. Fox and Blaxall have noted in several instances that the fungus scarcely exceeded that of the microsporon in size. There is a sheath of fungus around the hair at the follicle mouth, but it fits less closely than that observed with the microsporon.

milder varieties, more or less obstinate, not less than several weeks to a few months being required; and if the malady has been of long duration, is extensive and shows considerable infiltration, it is quite refractory, although always finally yielding to persistent measures.

Ringworm of the scalp, while often troublesome, eventually gets well, a regrowth of hair taking place, so that there remains no disfigurement. When limited to one or two areas and of short duration, with prompt, energetic management, it can, in the majority of cases at least, and especially in private practice, be readily cured, requiring on the average a few months' treatment. The same may be said of a small minority of patients when the disease has been of longer duration. On the other hand, in some cases it is extremely rebellious, continued and energetic treatment from six months to a year being necessary to bring about a result, and in not a few instances it is particularly obstinate, and without the methodic and persistent measures such cases last almost indefinitely, or until nature begins to look after the cure as the child verges into puberty, it disappearing spontaneously approaching or shortly after this period. For this reason in those instances in which the malady begins in advanced childhood, if properly treated, it responds, as a rule, rapidly. In very young children also the fungus does not seem to get so firm a hold. It is generally conceded that the small-spored fungus is the parasitic agent in most of the refractory cases. While in those instances due to the large-spored fungus the disease yields, as a rule, much more rapidly, still there are occasional cases which also prove persistently obstinate. As a general thing the markedly inflammatory types, and especially the kerion type, usually due to the ectothrix variety of the large-spored fungus, respond somewhat readily. It may be pretty positively stated, however, that many of the alleged cures of established ringworm of the scalp in a period of less than a few months, whatever the type of the disease, are merely errors of observation, for not infrequently the practitioner pronounces it cured when the hair has begun to fill in in the affected area or areas, whereas the malady in reality may still persist in a less conspicuous but chronic state, and the case remain an active center of contagion for other children. If, however, the favorable reports of the prompt effect of X-ray treatment are realized, the prognosis of chronic cases of the scalp will be materially modified.

Ringworm of the bearded region, although often presenting active and repulsive symptoms, is usually rapidly amenable to proper treatment. All cases are curable, and only in the worst type and in long-neglected instances is there any significant permanent hair loss or other disfigurement. A period of several weeks in the beginning and mild cases, to several months in the severe forms, is required to bring about a cure.

Treatment.—The management of ringworm varies slightly on different parts, not so much as to the remedies themselves, but as regards the strength of applications, although some applications are found more satisfactory in certain situations than in others. While, from the nature of the malady, recourse is had to practically external applications alone, and constitutional treatment usually considered of

no avail, yet, in chronic cases, especially of the scalp, occurring in hospital, dispensary, and other patients of impaired nutrition, it has seemed to me that the administration of cod-liver oil and iron, especially the former, has an influence for good directly upon the general health, and indirectly upon the cutaneous disease—in rendering the "soil" a less desirable one for fungus vegetation, and in this manner lending some aid, although doubtless slight, toward the final cure. It is not unlikely, moreover, that sulphur internally administered, in small doses, by its exhalation through the skin, makes this structure a less desirable habitat for the organism and thus be of contributory value.

Treatment of Ringworm of the General Surface.—The patches are to be kept free from scaliness by soap-and-water washings, using sapo viridis in sluggish and obstinate cases. If temporary disfigurement is not objected to, an excellent plan of treatment consists in painting the patch or patches daily for three or four days with tincture of iodin; in young children the tincture is to be diluted with from a half to one part of alcohol. A solution of sodium hyposulphite, 1 dram (4.) to the ounce (32.); fresh sulphurous acid; a lotion of carbolic acid, from 10 to 20 grains (0.65–1.33) to the ounce (32.); a mercuric chlorid lotion, from 1 to 3 grains (0.065–0.2) to the ounce (32.), are all, as a rule, quickly efficacious. The same may be said of sulphur, white precipitate, and tar ointments, weakened somewhat, or in full strength in obstinate cases. In the latter also I have frequently employed iodin tincture containing 1 to 3 grains (0.065–0.2) of biniodid of mercury to the ounce (32.); and also the plan of painting with a saturated solution of chrysarobin in chloroform, and covering with a coating of collodion. These latter remedies, especially chrysarobin, must be used with care.

Treatment of Ringworm of the Genitocrural Region.—Any of the several applications already named will often be found useful in ringworm in this location. In some cases, however, the eczematous aspect of the disease is quite marked, and at first only the milder remedies are tolerated. For such types the calamin-zinc-oxid lotion with saturated solution of boric acid as the base, and containing 2 to 10 grains (0.133–0.65) of resorcin and 5 to 10 grains (0.333–0.65) of carbolic acid to the ounce (32.) materially benefits and sometimes cures. The salicylated paste, containing 30 to 60 grains (2.–4.) of sulphur and 20 to 40 grains (1.33–2.65) of resorcin to the ounce (32.), also acts satisfactorily in some cases. As a rule, however, even in seemingly irritable cases, the stronger applications may be made use of. It is well to begin with the lotion of sodium hyposulphite already referred to, dabbing it on freely twice daily. If the parts become somewhat dry and harsh from its use, which frequently occurs, after the solution dries on a small quantity of vaselin, cold cream, or a weak sulphur salve, from 20 to 60 grains (1.33–4.) to the ounce (32.), may be gently smeared over. If this fails to cure, a lotion of resorcin, from 15 to 30 grains (1.–2.) to the ounce (32.), is to be tried. If still persistent, a lotion of mercuric chlorid, from 1 to 3 grains (0.065–0.2) to the ounce (32.), is to be applied twice daily, with or without the supplementary application of a plain unguent or the cautious use

of a white precipitate ointment, 20 to 60 grains (1.33–4) to the ounce (32.). In obstinate forms the mercuric chlorid may be applied in tincture of benzoin or myrrh, from 2 to 4 grains (0.13–0.265) to the ounce (32.), as advised by R. W. Taylor. In particularly rebellious cases, occasional shampooing of the parts with sapo viridis and hot water is to precede the remedial application. A valuable remedy in obstinate thickened and sluggish types of the disease is an ointment of chrysarobin, from 20 to 60 grains (1.3–4.) to the ounce (32.), used cautiously and intermittently, for only two or three days at a time; or this drug may be applied as a paint as employed in psoriasis. Paintings, once daily or every other day, with the tincture of iodin, full strength or weakened if the skin is irritable, is also valuable, and applied well at the borders and slightly beyond will sometimes stop the extension of the disease, as well as prove curative; in sluggish cases the biniodid of mercury, 1 to 3 grains (0.065–0.2) to the ounce (32.), can be added. After the disease is seemingly cured, occasional remedial applications are to be advised for a few weeks, in order to guard against a relapse. The same plans of treatment are to be pursued when the disease is situated in and about the axilla.

Treatment of Ringworm of the Scalp.—The hair around the patch or patches should be cut close or even shaved; that of the surrounding scalp is to be kept short, so as to permit of easy inspection, thus facilitating the discovery of any new foci of disease. If there are more than several patches, it is advisable that the hair of the entire scalp should be closely cropped or shaved from time to time. If the area of disease is small, the hair on the patch and that immediately surrounding should be carefully extracted with the depilating forceps. It is not, however, feasible in cases of any extent, and often in limited areas it is difficult to have it properly followed out; and in some instances, too, the broken hairs and hair stumps are so fragile and break so easily that they cannot be readily extracted. For these reasons in late years, except in selected cases, I have made use (Brayton) of a depilatory for ridding the patch of the hair and hair stumps; owing to the nascent sulphuretted hydrogen evolved, the depilatory has also some direct remedial value. One consisting of 3 drams (12.) of barium sulphid and 2½ drams (10.) each of zinc oxid and powdered starch can be employed. At the time of application enough water is added to a sufficient portion to make a paste, and this is spread in a thick layer on the area or areas, slightly overlapping the edges. It is to remain on from several to ten minutes, according to the character of the hair, the sensitiveness of the skin, as well as to the efficiency of the depilatory; as soon as heat of the skin or a burning sensation is felt it is washed off thoroughly, and if it has acted as it should, the hairs, including the stumps, will have been destroyed deep into the follicles, and sometimes possibly to the full depth of the latter. Should there be accidentally much resulting irritation, a soothing ointment can be applied for a few hours or so; as a rule, this is not necessary. The depilatory should be used every five to ten days, depending upon the rapidity of regrowth. It should never be applied to an actively inflammatory patch.

Before taking up the consideration of the remedial applications,

certain adjuvant measures should be referred to. The spread of the disease to other parts of the scalp and to other children should be prevented, as far as this is possible, by certain routine measures, and these can, as a rule, be carried out even when the active remedies are being used upon the patches. With this object in view the scalp is to be washed every second or third day with a medicated sapo viridis such as the following:

℞.	Sulphur. præcip.,	ʒj (4.);
	β-naphthol,	gr. xx–xl (1.33–1.65);
	Saponis viridis,	℥j (32.).

The lather should be permitted to remain on for five to fifteen minutes, as it has in itself an inhibitory or destructive influence upon the fungus.[1] If there is risk of taking cold, the parts may be enveloped with some covering. The lather is subsequently thoroughly rinsed off, the scalp rubbed dry, and then a general parasiticide application made. For this purpose either an ointment consisting of 1 dram (4.) of precipitated sulphur, 30 grains (2.) of β-naphthol, and an ounce (32.) of petrolatum; or a lotion of 2 drams (8.) carbolic acid, resorcin 1 dram (4.), and saturated solution of boric acid 1 pint (500.) can be used. Such a general application should be made once daily. It is possible that the salve is more effectual in preventing the dissemination of the spores, although it is not so agreeable as the lotion. As an additional measure in preventing the spread of the disease paper or any other material, which permits of daily destruction or washing, should be constantly worn as the hat lining. Whatever remedial method is adopted, it should be thoroughly carried out; if a wash is used, it is to be first gently rubbed in for a minute or two, and then dabbed on for five or six minutes; if an ointment, it should be well worked in by gentle but somewhat firm rubbing for five to ten minutes. Besnier, Quinquaud, and Colombini give the area a preliminary gentle surface curetting.

Many remedies have been brought forward from time to time for the rapid cure of ringworm of this region, but those of large experience in its treatment soon learn that it is not so much the remedy selected as it is the thoroughness of its application and the perseverance in its use that bring success. For recent patches the white precipitate ointment, sulphur ointment weakened with one or two parts of lard, tar ointment weakened or of official strength, paintings with tincture of iodin, sulphurous acid, pure or diluted, resorcin in lotion or ointment from 5 to 10 per cent. in strength, an ointment of calomel from 30 to 60 grains (2.–4.) to the ounce (32.), carbolic acid in lotion or ointment, from 20 to 60 grains (1.3–4.) to the ounce (32.), will all be found valuable and frequently curative after several weeks' or a few months' use. An old method of treatment consists in the use of Coster's paint (iodin, ʒij (8.); oil of tar, ʒvj (24.)), one or two coats daily for two days, allowing the crust that forms partly to detach itself, and then gently pulling it off. The application is repeated

[1] See interesting papers bearing upon this point and the influence of other substances upon the vitality of the fungus by Thin, *Brit. Med. Jour.*, 1889, i., p. 397, and Schwengers, *Monatshefte*, 1890, vol. xi., p. 155.

several times and will be found satisfactory, especially in the treatment of recent patches; it should not be used in children under three or four years of age unless the proportion of iodin is lessened. Tar itself, as tar ointment or the oil of cade, is also valuable, but its odor in private practice is an objection. In many of the chronic cases, however, stronger applications will be found necessary. Among the latter may be mentioned mercury oleate, strong sulphur ointment, and a paint or ointment of chrysarobin. Strong carbolic acid ointments, from ½ dram to 2 drams (2.–8.) to the ounce (32.), will also prove useful. A good compound ointment for dispensary practice is that mentioned in the treatment of favus. Mercury oleate in the form of an ointment, from 10 to 25 per cent. in strength, is often in itself a valuable remedy. Mercuric chlorid in solution is also a valuable and frequently used remedy, applied in solution in the strength of 1 to 4 grains (0.065–0.265) to the ounce (32.), preferably of equal parts of water and alcohol; it should not be applied to the entire scalp in its stronger proportion for fear of absorption.

While I have employed most of these remedies with success, the management of these cases has in recent years in my own practice narrowed itself down to the use of sulphur, β-naphthol, iodin, chrysarobin, and croton oil, conjointly with the adjuvant measures already referred to. Sulphur and naphthol are most valuable and appropriate for those cases involving a greater part of the scalp; chrysarobin and iodin for circumscribed areas, and croton oil for those patches which have persistently failed to yield to the other remedies. Sulphur and naphthol are prescribed together in ointment, 2 drams (8.) of the former and 30 to 60 grains (2.–4.) of the latter, with enough benzoated lard or lard and petrolatum to make the ounce (32.), and will prove valuable in recent cases, and especially in young subjects. Occasionally this amount of naphthol, in those of extremely sensitive skin, gives rise to a feeling of considerable burning, and in such instances this ingredient can be reduced in quantity. Exceptionally, also, the quantity of sulphur must be lessened in young children. This ointment can also be satisfactorily employed at the beginning treatment in extensive cases, the more recently affected parts usually soon yielding, leaving the chronic areas for the stronger remedies to be mentioned.

Ordinarily, however, the best application for the patches in young patients and in recent areas in other cases is iodin tincture, containing a small quantity of mercuric iodid, as in the following:

℞. Hydrarg. biniodid.,	gr. j–iij (0.033–0.2);
Tinct. iodini,	℥j (32.).

This is painted on twice daily, two or three coatings at each time, until the areas become somewhat tender or until the film thus formed cracks or begins to loosen. The parts are then anointed with a mild salve, and as soon as the film is detachable it is picked or pulled off. If there is active underlying irritation, which is not usually observed, the same ointment may be applied for a day or so, and the paintings resumed. If the iodin applications seem to be slow in bringing about complete cure, another plan is to be instituted.

Chrysarobin is by far the most valuable application in most of the

cases, but this drug as made by various manufacturing chemists differs considerably in quality; naturally, an efficient preparation is an essential for success. It is also highly indorsed by Duhring, Malcolm Morris, Hutchinson, Unna, Allen, Corlett, and many others.[1] It may be used in all cases, but more especially in those of somewhat limited extent; it must be employed with greater care in patients under the age of three years; in fact, in most of the younger patients the sulphur-naphthol salve or the iodin paintings will suffice to bring about a cure, and are to be preferred. Chrysarobin is most satisfactorily applied as a saturated solution in chloroform, and in the manner described in psoriasis. The areas are painted over with this until well coated with a film of chrysarobin, the chloroform rapidly evaporating. Over this are then painted three or four layers of good collodion. No further application is to be made until the film so formed begins to crack or to detach itself. As soon as it becomes detachable it is gently pulled off, and if there is any active irritation beneath, a mild ointment may be used for a few hours or a day until this is subdued and the paintings resumed. In some instances, but if employed with care not in many, chrysarobin gives rise to a mild or moderately severe dermatitis of the surrounding skin, and under these circumstances it becomes necessary to suspend its use temporarily. In rare instances this tendency to dermatitis may repeat itself, the skin of the patient being intolerant of this remedy, and it must be then set aside and give place to another plan.

In some patients these several methods will fail to bring about a cure; or more frequently will cure most of the areas, but fail to make sufficient impression upon a few patches. It is just in such instances especially that croton oil, so strongly advised by Aldersmith, has its particular field of usefulness. In those cases, too, and in which, for various reasons, a rapid cure is desired, recourse may be had to this application. It is a severe remedy, and the parts are made actively inflammatory; its careless use, and the pushing of the inflammatory action beyond a reasonable limit, would, of course, result in considerable follicular destruction. It must always be used with caution, and it is never to be employed in young children, nor to an area at any one time larger than an inch in diameter; larger areas can be treated in sections. The application should be made by the physician himself or by a trained attendant. With this plan of treatment the use of the depilatory, except as a beginning measure, is to be omitted.

At first it is desirable to have the oil weakened with two or three parts of almond oil, and if it is found that no active inflammation arises, it should be applied stronger. In most cases, especially in older children, the pure oil is required. It should be scantily used, as it seems to have a distinct tendency to spread beyond the part; a little vaselin at the border of the area will circumscribe its action. It is to be applied two or three times daily, and to bring about the desired amount of inflammatory reaction ordinarily requires two to six days. When it is possible to have poultices repeatedly applied after-

[1] See papers by Duhring, "Experience in the Treatment of Chronic Ringworm in an Institution," *Amer. Jour. Med. Sci.*, vol. ciii., 1892, i., p. 109; by Allen, "Treatment of Ringworm of the Scalp in Institutions," *Pediatrics*, 1896, vol. ii., p. 169.

ward, the oil applications may be discontinued as soon as slight swelling and minute pustulation present; the subsequent poulticing will bring about sufficiently pronounced inflammation.

Cases of disseminated ringworm can be treated by active methods—iodin or chrysarobin paintings. If the spots are numerous, the number may be usually brought down by the use of the sulphur-naphthol ointment and then the remaining obstinate spots can be treated with iodin or chrysarobin; if necessary for final cure, the oil can be employed. In such cases many of the areas yield readily with any good treatment, leaving behind several or more obstinate spots. In those instances in which the disease is so extensive as practically to involve the greater part of the scalp, presenting large and irregular areas or confluent sheets, it is advisable to use the stronger sulphur naphthol ointment until it is reduced in extent. Or this can be applied to the parts generally, and small portions treated with the iodin or chrysarobin paintings. Croton oil, if used at all, should be left until the disease is reduced to several circumscribed areas; it is never to be employed in the beginning of treatment in these confluent cases. For the markedly inflammatory types, and particularly kerion, the application of boric acid ointment, or an ointment of sulphur, 30 to 60 grains (2.–4.) to the ounce (32.), or one of white precipitate, 20 to 40 grains (1.33–2.65) to the ounce (32.), is to be advised. After the active inflammatory signs have subsided the same can be continued, or stronger treatment instituted. Ordinarily in kerion the inflammatory process itself is destructive to the fungus, or casts it off and brings about a cure.

Among other remedies and plans which are variously indorsed may be mentioned a 10 to 25 per cent. ointment of oleate of copper (Shoemaker, Crocker); covering the diseased area nightly with a compress wet with a 4 to 5 per cent. solution of calcium chlorid, and enveloping with rubber tissue, followed the next morning by washing with soap and water and the application of diachylon plaster, with twice weekly a painting with tincture of iodin (Sabouraud); applications of formaldehyd in the strength of formalin (40 per cent.) or weakened (Pottevin, Salter, Vidal, Solares, Hutchins, Allen); the application and penetration of corrosive sublimate solution by cataphoresis (Ambrosi, Reynolds, Ravogli, Wessinger), and the Harrison method, consisting of the use of two solutions: No. 1, of ½ dram (2.) of potassium iodid and 4 drams (16.) each of liquor potassæ and spirits of wine; No. 2, of 4 grains (0.265) of mercuric chlorid and 4 drams (16.) each of spirits of wine and water, applying No. 1 at first and following with No. 2. It is a severe method exciting considerable inflammation and occasionally resulting in scars, and has been condemned by some and commended by others.

Jackson[1] gets success in most cases with an ointment made of about a dram (4.) of iodin crystals and an ounce (32.) of goose grease; it is to be applied twice daily until it produces a reaction, which is shown by a slight swelling of the patch, and then once daily; in two to three weeks the hair falls out, which usually presages the cure, the hair finally regrowing and showing no evidence of disease.

[1] Jackson, *Med. Review*, Feb. 1, 1902, and April 11, 1903.

It remains to speak of the X-ray treatment, which was introduced by Sabouraud and Noiré[1] as a remedy that is promptly curative in ringworm of the scalp, and whose favorable experience has been repeated by others. Their method is based upon one measured application of this agent, sufficient to produce depilation, this latter ensuing two to three weeks after exposure, and without, at the most, the production of more than the mildest X-ray erythema.[2] Others have used it cautiously, at intervals of a few days, till falling out of the hair results. Care should be exercised that the slightest reaction is not exceeded, otherwise there is risk of permanent baldness. It is not a method to be used by those inexperienced in the use of the X-ray, and not, in my judgment, to be used except in chronic rebellious cases.

[1] Sabouraud and Noiré, *La presse médicale*, 1904, p. 825, and *Annales*, 1904, p. 80; account also by Bunch, *Brit. Jour. Derm.*, 1904, p. 265, and *Lancet*, Feb. 18, 1905, and in editorials in *Brit. Jour. Derm.*, Feb. 1905, and *Jour. Cutan. Dis.*, April, 1905; and abstract translation of Sabouraud and Noiré's paper by W. S. Fox, in *Brit. Jour. Derm.*, Feb. 1905, p. 67; Macleod, *Brit. Med. Jour.*, Sept. 1905.

[2] The essence of the method of Sabouraud and Noiré (who use static machines for generating the current) consists in giving one exposure sufficiently long to produce depilation, and yet not long enough to be productive of any ill-effects. This is done by employing some means of measuring the quantity of rays, and by keeping the vacuum of the tube at a point equal to about a 3-inch spark gap. A properly constructed milliampère meter (in this instance the D'Arsonval meter) can be inserted in the seoondary circuit; and most important of all, radiometer pastilles of Sabouraud and Noiré—*i. e.*, circular wafers of paper coated with an emulsion of platino-cyanid of barium in a collodion of amyl acetate—one of which is placed on a metal plate (impermeable to the rays) at a distance of 3 inches from the anticathode. These wafers have the property of changing color under the action of the X-rays in proportion to the quantity of rays absorbed. Under similar conditions of current, tube, and atmosphere (the rays act more rapidly when the air is dry) the time required to change the color from its yellowish-green to a standard tint of fawn is that which is requisite to produce complete depilation without dermatitis or danger of permanent alopecia. In short: "To cure a patch of ringworm of the scalp by the X-ray, place the patch at a distance of 15 centimeters from the center of the focus tube, and place at the same time a disk of platino-cyanid of barium paper 8 centimeters from the center of the tube. When this disk has taken the color corresponding to the tint 'B' of Sabouraud and Noiré's radiometer (and to 5 H of Holzknecht's scale), the operation is terminated." There is a risk if this exposure is exceeded. If the exposures are made in daylight, it is necessary to place the pastille in black paper, and the examining must be done quickly, as the pastille returns to its normal color rapidly when exposed to daylight.

In the course of a week after exposure, a faint erythema is usually noted, which is succeeded in a few days by a slight pigmentation; after about two weeks the hair begins to fall out, which process is usually completed in a week. Should (from insufficient dosage or idiosyncrasy) this not take place, after waiting two weeks more, another exposure is made. Inasmuch as the fungus is not destroyed by the X-ray, in order to prevent reinfection, after exposure an ointment of oil of cade is rubbed in nightly, and in the morning the scalp shampooed, and an alcoholic lotion containing tincture of iodin applied to the entire scalp. If there is an impetiginous tendency, an ointment of salicylic acid and sulphur or white precipitate is used instead of the tar ointment. After thirty days a careful search is made to see that no diseased hairs have escaped; and every fifteen days an examination is made until complete regrowth has taken place, which is usually a matter of several months; about two months after exposure the hair is visible, and normal growth complete three months later.

In preparing for the exposure the scalp is carefully examined, and if there are not more than 5 patches, circles are drawn around each patch, going 1 centimeter beyond the diseased area; these areas are then painted with tincture of iodin, and the hair cropped close. Each area is then exposed to the rays seriatum, all on the same day. If the disease is more extensive and scattered, the whole scalp is exposed successively in 6 sections, being careful not to expose any point twice. The parts not treated are, of course, protected by tin or lead foil; or the tube is enclosed with a projected opening adjusted to treat only the part desired. According to Sabouraud and Noiré, only three months are now required for a cure of cases (in l'école lailler, Hópital St. Louis, Paris) that formerly took two years.

In all cases of ringworm of the scalp treatment is to be discontinued temporarily after several weeks or a few months, according to the grade of the disease, for the purpose of noting the progress made. As long as stumps are to be seen and a tendency to scaliness persists, especially the former, a cure has not been effected. If there should be any doubt upon this point several of the suspected hairs and also the new-growing hairs should be subjected to microscopic examination. If it is shown that there has not been any or much progress toward cure, a change of application is to be instituted. If, however, considerable progress has been made, it is advisable to adhere to the same line of treatment.

Ringworm of the Bearded Region.—Extraction of the hairs from the affected areas is a measure that will aid considerably in promoting a cure, and is, therefore, to be considered an essential part of the management of the disease. I am convinced that this procedure will shorten the period of treatment fully one-third, and possibly one-half. The hair on other parts of the bearded region should be kept sufficiently short or shaved to permit of easy inspection, so that any new foci developing will be readily discovered and treated before the fungus is firmly established. Almost any of the applications mentioned in the treatment of the other varieties will, if perseveringly used, prove efficacious in this form also. Experience teaches that the best remedies, however, are the lotions of sodium hyposulphite, and mercuric chlorid, and ointments of white precipitate or calomel, of sulphur, and of oleate of mercury. The treatment in my own practice has gravitated to two plans as being the most promising of rapid results—one a sulphur treatment, and the other a mercurial. Both are, doubtless, in the aggregate of cases, equally efficacious, but in some instances, when progress is slow or unsatisfactory from one plan, a change to the other is found to be of advantage. In the sulphur treatment a lotion of sodium hyposulphite, 1 dram (4.) to the ounce (32.), and an ointment of precipitated sulphur of from 10 to 20 per cent. strength, are conjointly prescribed. The mercurial plan consists in the use of a corrosive sublimate lotion, from 1 to 3 grains (0.033–0.2.) to the ounce (32.), together with the employment of an ointment of 10 per cent. oleate of mercury, 2 or 3 drams (8.–12.) of the oleate with sufficient simple cerate, or simple cerate and lard, to make up the ounce (32.); or, with a 10 to 20 per cent. white precipitate or calomel ointment. The plan being selected, the method of carrying it out is as follows: The lotion is applied freely, being thoroughly dabbed over the affected areas and somewhat less liberally over the whole bearded region—over the latter in order to prevent the infection of new areas; after the wash has dried, the ointment is to be well rubbed in, usually over the diseased places only, but, if there is a decided disposition toward spreading, the ointment as well as the lotion should be applied, once daily at least, to the entire bearded part of the face and neck. The applications should be made morning and evening, and in urgent cases three or four times daily. Before the application, or once or twice daily, the parts should be washed off with warm or hot water and soap. Treatment should be continued vigorously until all vestiges of the disease have disappeared; and then, inter-

mittently or less actively for several weeks, in order that the possibility of a relapse may be guarded against. As in ringworm of the scalp the X-ray can also be employed in this form, but its use always requires caution, and most cases can be as well managed without it.

TINEA IMBRICATA.

Synonyms.—Tokelau ringworm; Scaly ringworm; Bowditch Island ringworm; Chinese ringworm; India ringworm; Burmese ringworm; Malabar itch; Gune (Fox); Cascadöe (Meederwort); Herpes desquamans (Turner); Lafa Tokelau; Tinea circinata tropica; Le peta; Buckwar.

Definition.—A vegetable parasitic disease of moist, tropical countries, characterized by the formation of patches composed of concentrically arranged imbricated scaly rings.

Ill-defined accounts of this peculiar malady are found in the contributions of voyagers, but the first accurate description is that by Fox,[1] a United States medical officer, in 1841. Since then other careful reports have appeared, among which the more recent by Königer,[2] McCall Anderson,[3] Roux,[4] Bonnafy and Mialaret,[5] Manson,[6] Nieuwenhuis,[7] Tribondeau,[8] and Henggeler and others.[9] I shall draw chiefly from Manson's admirable description.[10]

Symptoms.—The malady begins, according to Manson, at one or sometimes at several points, as a brownish spot, slightly raised, and which gradually, in the course of a few weeks, increases in size by peripheral extension to almost a half-inch in diameter, when the central epidermal covering breaks and the epidermis cracks from center toward the border, becomes somewhat detached centrally, and bent upward. Soon this spot is surrounded by a brownish zone of about $\frac{1}{16}$ of an inch wide, which in turn shows the epidermic detachment and curling at its inner side, and so the malady spreads. The renewed epidermis of the central part of the patch goes again through the same process, and in this manner the ever-increasing

[1] Fox, "Narrative of the United States Exploring Expedition, 1838–42, under command of C. Wilkes," vol. v., p. 401, cited by Corlett, Bangs and Hardaway's *American Text-Book.*

[2] Königer, *Virchow's Archiv*, 1878, vol. lxxii., p. 413.

[3] McCall Anderson, *Edinburgh Med. Jour.*, 1880, vol. xxvi., pt. i., p. 204 (with case and fungus illustrations).

[4] Roux, *Traité prat. mal des pays chauds*, vol. iii., 1888, p. 231 (cited by Corlett).

[5] Bonnafy and Mialaret, *Arch. de méd. navale*, 1891, vol. lvi., p. 269.

[6] Manson, *Brit. Jour. Derm.*, 1892, p. 5.

[7] Nieuwenhuis, *Archiv*, vol. xlvi., 1898, p. 163.

[8] Tribondeau, *Arch. de méd. navale*, July, 1899, p. 5, *Compt. rend. de la Réunion Biologique de Bordeaux*, Jan. 19, 1901, and Jan. 13, 1903.

[9] Other recent valuable contributions on tinea imbricata are: R. Koch, "Framboesia tropica und Tinea imbricata," *Archiv*, vol. lix., 1902, p. 5 (with case illustrations); Wehmer, "Der Aspergillus des Tokelau," *Centralbl. f. Bakteriol.*, 1903, xxxv., p. 140; Jeanselme, *La pratique Dermatologique*, 1904, vol. iv., p. 445; Bassett-Smith, *Jour. Trop. Med.*, 1904, p. 265; Paranhos (new process for microscopic diagnosis), *Jour. Trop. Med.*, 1905, p. 341; Henggeler, *Monatshefte*, 1906, vol. xliii., p. 325 (in Summatra; a full critical exposition, with bibliography and an excellent illustration, herein reproduced).

[10] It has been generally believed that this peculiar disease was confined to the Eastern Hemisphere, but Paranhos (*Jour. Trop. Med.*, 1904, p. 153 and Paranhos and Leme, *ibid.*, 1906, p. 129), of Brazil, states that it also occurs in certain tropical parts of South America—in the States of Goyaz, Minas, Matto-Groso, and San Paulo.

area is made up of several or more concentrically arranged imbricated, shingled-like rings. When several such patches are close together, fusion takes place, and the concentric regularity is broken and the pattern becomes more complicated, although the gross features of the epidermic shingles are maintained. The eruption may, in the course of months, invade a great part of the surface. The skin beneath the curling epidermis is noted to be paler than the general surface, whereas at the part attached the surface is, as already indicated, somewhat darker. It will be seen that "all the scales are arranged so that the free border of each is toward the center of the circle or system of circles to which it belongs, and that the attached border is, therefore, toward the periphery. The effect is something like the rings of light and dark surface on watered silk." According to Königer, the patches may at first consist of concentrically arranged, small, itchy papules, which subsequently exhibit the scaliness. In some extreme cases the ring-like configuration is lost, the whole surface appearing as if covered with branny scaliness, and presenting a picture resembling that of a mild ichthyosis, with which it has sometimes been confused (Henggeler). As a rule there are no distinct evidences of inflammatory action. While the malady is persistent, chronic, and progressive, there is no effect upon the general health. There may be a variable degree of itching.

Etiology and Pathology.—The cause of the malady, which is of contagious nature, is a vegetable parasite closely similar to the trichophyton. In fact Nieuwenhuis, Sabouraud, and some others believe the fungus to be the large-spored trichophyton of animal origin. For this reason some have considered it as an aggravated or unusual form of ringworm, a view, however, that is not in consonance with the observations of those who come in contact with the disease. Manson's inoculation experiments always produced the same type, and in 2 instances he inoculated one arm with the ringworm fungus and the other with that of tinea imbricata, the resulting diseases having the distinguishing characters of their respective species. Tribondeau, Bassett-Smith, Paranhos, Wehmer and Henggeler consider the fungus as belonging to the aspergillus.[1] The malady is not uncommon in tropical countries, requiring for its development heat and moisture. While seen at any age, children are especially liable.

The fungus is found in much greater abundance than that of ringworm, although their gross features are admittedly much alike.[2] Its chief field of invasion is the lower part of the corneous layer. The stronger hairs and their follicles are not attacked; Königer states that it appears to cause falling of the body hair, but Manson cannot confirm this, although not able positively to deny it. The rapid development of the organism from the point of invasion apparently causes the separation of the horny layer from the rete and the formation of the uplifted scales.

[1] Tribondeau suggested the name of "lepidophyton" for the fungus; Wehmer, that of "aspergillus lepidophyton" or "aspergillus Tokelau."

[2] In the microscopic examination the same method may be employed as in ringworm.

PLATE XXXII.

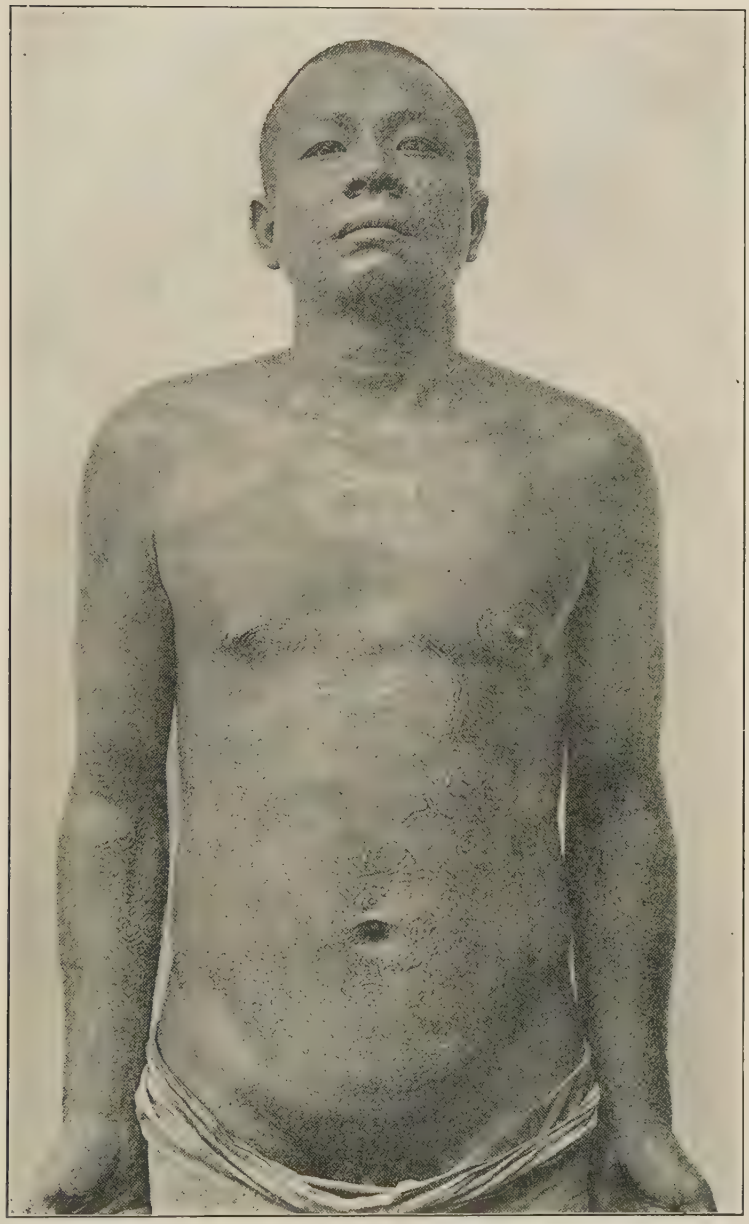

Tinea imbricata (courtesy of Dr. O. Henggeler.)

Diagnosis.—The peculiar, shingled-like characters of the concentric scaly rings are quite characteristic and serve to distinguish it from tinea circinata. The latter seldom presents any pronounced scaliness, and while rarely there may be two or three rings, they are lacking in the other features of those of tinea imbricata, besides usually presenting distinctly inflammatory signs. Moreover, tinea circinata is never extensive, while tinea imbricata sometimes involves a great part of the surface.

Prognosis and Treatment.—The disease is usually readily cured, the fungus lying superficially, but, as Manson states, owing to its profusion and the great extent of surface involved, and consequent saturation of the patient's garments with the fungus elements, relapses very generally occur. The latter can be prevented, however, by burning or boiling the clothing worn during the treatment. Manson finds the application of iodin liniment the most satisfactory remedy, applying it to a part of the body at a time. Bonnafy and Mialaret speak well of sulphur fumigations repeated at intervals for a period of two months or so. Nieuwenhuis refers to the efficacy of petroleum, rubbed on once or twice daily for fourteen days, no bath being taken during the treatment. Almost any of the parasiticides advised in ringworm will, in fact, suffice, if thoroughly employed; a 3 to 10 per cent. chrysarobin salve cautiously used, often being resorted to in obstinate cases. As prophylactic measures may be mentioned extreme cleanliness, the disinfection of the underwear, and oiling of the body.

TINEA VERSICOLOR.

Synonyms.—Pityriasis versicolor; Chromophytosis; Dermatomycosis furfuracea; Mycosis microsporina; Chloasma (of older writers); Liver-spots (of older writers); *Fr.*, Pityriasis versicolore; *Ger.*, Kleienflechte.

Definition.—A vegetable parasitic disease, characterized by variously sized and shaped, furfuraceous, macular patches of a yellowish, fawn color, and occurring for the most part on the upper portion of the trunk.

Symptoms.—The disease begins as one or more yellowish or brownish, macular points, frequently at the follicular outlets (Besnier and Balzer), and commonly upon the chest anteriorly or posteriorly, although the earliest spots are sometimes seen lower down or at or near the axillary folds. Their growth is usually slow, several months or more elapsing before the eruption is of conspicuous extent. The beginning points or spots extend peripherally, and together with other patches that are present or subsequently arise may finally result, in some instances, in an almost continuous sheet of eruption, and involve the greater part of the upper trunk, often extending lower down. In an average case this former region is noted to be the seat of variously sized spots and areas, varying in size from the beginning lesions to large plaques. There is slight, sometimes scarcely perceptible, furfuraceous scaliness, less noticeable in those of naturally moist skin or who perspire easily. The color of the patches is pale-yellow or brownish yellow, exceptionally a yellowish brown; in rare instances, in those of delicate skin, there may be more or less hyper-

emia, and in consequence the eruption is of a pinkish or reddish-yellow tinge, most marked at the edge of the patches. Beyond the disfigurement caused, the disease never gives rise to any trouble, except that slight or moderate itching, especially when the patient is warm or perspiring, is frequently complained of.

While in most patients the eruption is practically limited to the upper half of the trunk, in many instances the whole lower part is also more or less invaded, and in extreme cases the axillæ, portions of the arms, flexures of the elbows, and even the genitocrural region and popliteal spaces are likewise involved. The eruption exceptionally is noted to be, for a time at least, more or less limited to the

FIG. 245.—Fungus of tinea versicolor—microsporon furfur (× about 500; partly diagrammatic).

genitocrural region. Quite frequently it extends from the chest well up on the neck, and in occasional examples still higher on to the lower part of the chin. It is generally believed that the face is never the seat of the eruption, but in occasional instances this has been observed (Biart, Payne, Gottheil, Allen, Sobel, Powell[1]), produc-

[1] Biart, *Jour. Cutan. Dis.*, 1885, p. 73; Payne, cited by Crocker, *Diseases of the Skin*, second edit., p. 892; Gottheil, *Med. Record*, 1901, vol. lix., p. 649; C. W. Allen, *Jour. Amer. Med. Assoc.*, 1901, i., p. 938; Sobel, *Philada. Med. Jour.*, 1901, vol. vii., p. 1061; Powell, *Brit. Jour. Derm.*, 1900, p. 142, states that it is quite common on the face in Assam, and the fungus seems identical with that met in Europe, and which Pernet, to whom scrapings had been sent, demonstrated by examination before the Dermatological Society of Great Britain and Ireland. Castellani, *Brit. Med. Jour.*, Nov. 11, 1905, and *Jour. Trop. Med.*, 1905, p. 252, states that in Ceylon two types are met with: *tinea versicolor nigra*, the eruption being black and lusterless, and found on any part of the body except the face; and *tinea versicolor flava*, of which there are two varieties—one attacking the face, neck, and upper part of the trunk, and the other presenting a lighter yellow or nearly white patches, generally seen on the arms and legs; it is not uncommon to see the different types on the same individual.

PLATE XXXIII.

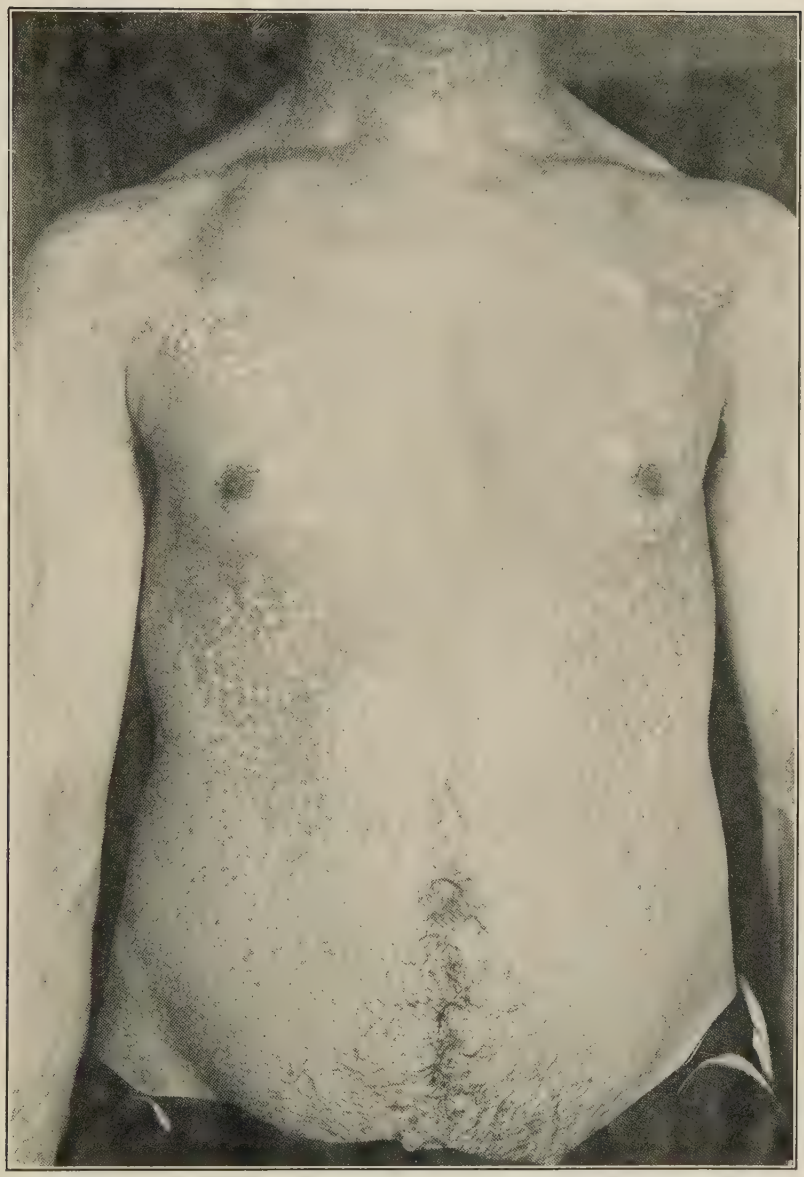

Tinea versicolor, showing the confluent areas and the variously sized patches; of several years' duration. The eruption is not elevated, the chief characteristics being the fawn or brownish-yellow color, upper trunk distribution, and usually a slight, sometimes scarcely perceptible, branny or furfuraceous scaliness. In this instance extends well up the neck and some spots on arms.

ing chloasma-like patches or diffused discoloration, of which one well-marked example has come to my own notice; it is usually, however, in connection with the eruption extensively developed on the favorite situation. While on the face it is essentially similar in color to that on the trunk, it may be somewhat darker, or it may, in the negro, be somewhat lighter, as in Gottheil's case, in which the spots, doubtless owing to the scaliness, were of a dingy-white, vitiligo-like aspect. In Biart's patient the scalp was encroached upon; and in Payne's it was both in the bearded and scalp regions, where it appeared to be a simple furfuraceous scaliness, the scrapings disclosing the fungus. Both his and Biart's patient had the eruption on the trunk also. In my patient, a woman, it had the appearance of an extensive chloasma, for which, unless closely inspected, it could have been readily mistaken. Smith[1] met with an instance of its limitation to the soles, and Gottheil[2] to one palm, probably the only examples on record.

The course of the disease is slow, and usually progressive up to a variable extent, and then it remains more or less stationary, showing little, if any, tendency to spontaneous retrogression.

Etiology and Pathology.—The disease is due to the vegetable parasite known as the microsporon furfur, discovered by Eichstedt in 1846. Both sexes are liable, but men more frequently. It is rarely seen before adolescence or in advanced years. While the fungus is abundant, yet observations show that the malady is but mildly contagious. Not more than two or three instances of its occurrence in two members of a family have come under my own notice. Huble[3] cites 9 cases of contagion from man to wife, or vice versâ. This same writer and several others have been successful with inoculation experiments, but, as a rule, success is only occasional. It is commonly believed, and doubtless true, that those who sweat freely are its more common subjects. It is thought to be relatively frequent in phthisical patients,[4] but this is probably more apparent than real, inasmuch as, owing to the exposure of the chest in such patients for the purpose of physical examination, the eruption is oftener disclosed.

The fungus consists of mycelium and spores, the latter being disposed in distinct groups or masses. It is readily demonstrated by placing some scrapings in a little liquor potassæ on a glass slide, and placing over it the cover-glass, and allowing it to soak for a few minutes; a power of 200 to 500 diameters gives sufficient amplification. The parasite luxuriates in the corneous layer of the epidermis, sparing the rete, hairs, and true skin.

[1] E. D. Smith, *New York Med. Jour.*, 1896, vol. lxiv., p. 583 (on both soles, anteriorly, in male adult, of some duration; nowhere else).

[2] Gottheil, *Med. Record*, 1899, vol. lvi., p. 15 (left palm in male adult, of dark color and some years' duration; illustration); Campana, *Clinica Derm. della Universite de Rome*, 1903, p. 13—abs. in *Jour. Cutan. Dis*, 1904, p. 55—reports a case in which tinea versicolor affected the fingers and finger-nails.

[3] Huble, *Revue méd. de Toulouse*, July 15, 1886; abs. by Thibiérge in *Annales*, 1887, p. 414.

[4] Duguet and Héricourt, "Sur la nature mycosique de la tuberculose et sur l'évolution bacillaire du microsporon furfur, son champignon pathogène," *Compt. rend. Acad. de Sci.*, Paris, 1886, vol. cii., p. 943, have even alleged that the microsporon furfur is etiologic in the production of phthisis.

Diagnosis.—The color, peculiar characters and distribution of the eruption are the diagnostic factors; added to these is the fact that in most cases coming under observation the malady has already lasted for a year or more. These points, as well as the large patchy or sheet-like character usually noted, will serve to distinguish it from the macular syphiloderm. It can scarcely be confounded with chloasma (*q. v.*). It is well to bear in mind, however, that exceptionally the eruption may invade the face and simulate this latter malady. Occasionally, when in profusion, the spared skin looks relatively white and might suggest vitiligo, the fawn color of tinea versicolor being mistaken for the hyperpigmented border of vitiligo patches. The inflammatory characters of eczema seborrhoicum, and the same and the acuteness of pityriasis rosea, will prevent confusion with these maladies. In all doubtful cases recourse should be had to microscopic examination.

Prognosis and Treatment.—Tinea versicolor is, as a rule, a readily curable disease. In some instances the fungus seems to be somewhat deeply and firmly seated, extending into the follicles, and such cases yield more slowly. Unless proper precautions be taken relapses are not infrequent. A plan of treatment that will be found especially satisfactory in many cases is that consisting of soap-and-water washings and the application of a solution of sodium hyposulphite. When the skin is somewhat irritable, ordinary toilet-soap may be used at least once daily for the washing, shampooing the parts pretty thoroughly, and rinsing off and rubbing dry. Immediately afterward, the hyposulphite solution, 1 to 2 drams (4.–8.) to the ounce (32.), is freely rubbed in for a minute or two and then dabbed on and allowed to dry. The solution should be applied twice daily. In those of sluggish skin, instead of plain toilet-soap sapo viridis should be used for the washing; or in obstinate cases instead of plain sapo viridis the following may be employed with advantage:

℞.	Sulphuris præcipitati,	ʒij (8.);
	Saponis viridis,	q. s. ad ℥ij (64.).

In other instances a manufactured soap containing sulphur or sulphur and naphthol will be found efficient. During the treatment the underwear should be thoroughly baked or boiled or soaked in the hyposulphite solution. With the treatment outlined, carefully carried out, a successful result is almost certain in the course of one to three months. After the cure is apparently effected a remedial application should be made once or twice weekly for two or three months, in order to guard against recurrence. In fact, it is a good plan for those who seem especially liable to recurrences to make a practice of using regularly a medicated soap, such as above named, as the body soap. It is to be understood that even in apparent cures some deep-seated fungus may have remained, and if the precautionary measures named are not followed out, this develops and a relapse follows. Attention to these details of the management of the disease will do much toward insuring permanence of the cure. I have been in the habit also of prescribing a few grains of sulphur

daily internally in this disease, believing that its exhalation through the skin makes the tissues a less satisfactory "soil" for the fungus.

Many remedial applications other than that named will likewise act satisfactorily, but need not be specifically mentioned, inasmuch as they are the same as the milder remedies advised in ringworm.

ERYTHRASMA.[1]

Definition.—A vegetable parasitic disease characterized by reddish-brown patches, presenting in situations where there are moist and opposing surfaces, as the genitocrural and axillary regions.

The original observations by Burchardt (1859), Barensprung (1862), and Köbner (1866), which led to the recognition of the individuality of this affection, have been corroborated by the studies of Besnier, Balzer, Dubreuilh, Riehl, Weyl, Köbner, Payne, Boeck, Ducrey and Reale, and others, and have dispelled the belief held by a few German writers as to its kinship with either tinea trichophytina or tinea versicolor.

Symptoms.—The malady is slow in its development, beginning as small spots of a reddish-brown or orange-red color, and usually in the genitocrural region. The color is somewhat like that of the Indian skin. The spots, which may be few or many in number, gradually increase in size, and result in coalescence and the formation of confluent areas or sheets of eruption. In its general aspects, except the shade of coloring and the parts invaded, it bears considerable resemblance to tinea versicolor. The patches are not perceptibly elevated, although the edges are well defined. Scaliness, furfuraceous or mealy in character, is generally so scanty that its existence is scarcely recognizable; it is more readily seen at the border. While the most frequent region involved is the genitocrural, the axillæ are also almost as common a site, these two locations in fact being both affected in most instances. It occasionally extends from these parts, and may cover considerable surface; in a case observed by Riehl extending high up on the pubic region and to the middle of the thighs, and in one by Besnier involving the latter and also the upper arms. Exceptionally patches may arise independently near by or not far distant. The malady is insidious and slowly progressive, but generally, after attaining a variable development, remains

[1] Important recent literature: Besnier, Besnier-Doyon's French translation of Kaposi's treatise, second edit., 1891; Balzer, "De l'erythrasma," *Annales*, 1883, p. 681; Balzer and Dubreuilh, "Observations et recherches sur l'erythrasma et sur les parasites de la peau a l'état normal," *ibid.*, 1884, pp. 597 and 661 (with review and literature references); Behrend, *Lehrbuch der Hautkrankheiten*, 1883, second edit., p. 560 and Eulenberg's *Real-Encyclopædie*, third edit., 1895, vol. vii., p. 360 (with bibliography); Riehl, *Wien. med. Wochensch.*, 1884, pp. 1209 and 1247—full abstract in *Jour. Cutan. Dis.*, 1885, p. 84; Köbner (second paper), *Monatshefte*, 1884, p. 349; Bizzozero, "Ueber die Mikrophyten der normale Oberhaut der Menschen," *Virchow's Archiv*, 1884, vol. xcviii., p. 441 (with review and literature references); Weyl, *Monatshefte*, 1884, p. 33; Boeck, *Archiv*, 1886, p. 119; Payne, *London Patholog. Soc'y Trans.*, 1886, vol. xxxvii., p. 516, and *Observations on Some Rare Diseases of the Skin*, London, 1889 (a clear presentation with review); Pasquale de Michele, *Giorn. internaz. d. sci. med.*, 1890—abs. by Thibierge in *Annales*, 1891, p. 796; Ducrey and Reale, abs. in *Brit. Jour. Derm.*, 1894, p. 126, and abs. of later paper, *ibid.*, 1895, p. 97.

practically stationary. There is rarely any tendency to spontaneous disappearance. Its presence, as a rule, gives rise to no inconvenience, but occasionally there may be slight itching.

Etiology and Pathology.—The disease is rare in our country, but more common in France and Germany. It is seldom seen in those under the age of fifteen. It is caused by the parasite, the microsporon minutissimum, considered a vegetable organism somewhat similar to that of tinea versicolor, although there is some doubt as to its exact status, whether it should be classed among the ordinary tinea fungi or bacteria. Payne believes the organism bears a strong resemblance to involution forms of bacilli, being doubtful as to the presence of any spores, although other observers (Burchardt, Bärensprung, Balzer, Ducrey, Reale, Weyl, Michele, Riehl, Dubreuilh, and others) for the most part are in agreement as to the existence of both mycelium and spores. Some have found several organisms (Weyl, Michele), although Michele's inoculation experiments show the microsporon to be the etiologic one. The alleged successful cultures of the organism by de Michele and Ducrey and Reale are not, however, free from suspicion (Jarisch). Inasmuch as Balzer and Dubreuilh and Ducrey and Reale have found the same organism on apparently normal skin, they are inclined to believe that only under certain unknown conditions does it become pathogenic.

The microsporon, seated in the superficial horny layers, consists of short, jointed threads and spores, being in size about one-third that of the microsporon furfur, and requires, therefore, a somewhat higher power for its recognition. The threads show no disposition to branching, exhibit sometimes cylindric swellings, and, according to Payne, sometimes with slightly bulbous blind extremities. Unlike the fungus of tinea versicolor, as Unna states, it shows no isolated collections of spores.

Diagnosis.—The disease is to be distinguished from tinea versicolor, to which it bears, as already stated, considerable resemblance, although it, unlike the former, has a reddish tinge. Tinea versicolor, however, rarely exists, any length of time at least, on the favorite regions of erythrasma without marked involvement of its common situation, the trunk. Erythrasma, on the contrary, is only exceptionally seen outside of the genitocrural and axillary regions, and then scantily, and, as a rule, only in association with its extensive development on the parts named. In doubtful cases recourse can be had to the microscope, although the treatment of both maladies is the same. The inflammatory characters of tinea cruris (eczema marginatum) and eczema seborrhoicum, not uncommon in the same localities, will prevent error. The peculiar patchy and scaly features of pityriasis rosea, as well as its acute development and distribution, are totally different from those of erythrasma.

Prognosis and Treatment.—The malady is persistent, and with, as in tinea versicolor, a marked tendency after apparent cure to recurrence. The treatment is the same as in the latter disease, and the same measures as to guarding against relapse should also be advised.

DHOBIE ITCH.[1]

In certain tropical countries[2] almost all itching cutaneous affections are apt to be called by the common people "dhobie itch," but with the more intelligent and with physicians the term is ordinarily used to designate any itching, ringworm-like, intertrigo eruption of the crutch and axilla, and by some also a similar eruption about the feet. It consists of a dermatitis of a variable degree, usually with a festooned, irregular border; in hot, moist seasons the inflammation from the active proliferation of the germs and the sweating, heat, and friction of the parts is often so severe that the patient is unable to go about, and even to dress. There is considerable itching, often leading to violent scratching. The parts may become raw, and as a result of secondary bacterial infection, boils and abscesses may be added to the ordinary features. The subjective symptoms are usually worse at night, keeping the subject awake or preventing restful sleeping. Upon the advent of the cool season the dermatitis subsides, the irritation and itching become less marked, and the malady may practically disappear, or remain as a slightly scaly, dry, pigmented eruption, to reappear in its former severity under favoring conditions. In patients returning to a cold climate the disease usually disappears spontaneously.

It is believed the affection is variously due to the trichophyton of ringworm, to the microsporon furfur of tinea versicolor, and to the microsporon minutissimum of erythrasma; and occasionally also to the germ of Manson's pemphigus contagiosus (probably a variety of impetigo contagiosa). In the cases due to this last, the eruption, especially in the beginning, often consists of successive crops of vesicular and bullous lesions. Manson believes that in many of the cases the microsporon minutissimum is the pathogenic agent, and in these the condition is really an inflamed erythrasma. Castellani and some others are, on the other hand, inclined to believe it due to the trichophyton, but, of a somewhat different type from that of tinea circinata. The heat and moisture of a tropical climate seem to be the added factors which make the various parasites more virulent and irritating. The spread of the disease is believed to be by means of the laundry, hence the name "dhobie (laundryman) itch." It is not improbable that some cases might be well considered as eczema seborrhoicum.

The **diagnosis,** in regions where the disease is prevalent, is not difficult, as practically all inflammatory eruptions, especially involving the crutch and axilla, having a more or less festooned border are in-

[1] Recent literature of dhobie itch especially made use of: Manson's *Tropical Diseases*, 3rd edition; Mason, *Trans. Texas Med. Assoc.*, 1903, p. 514; Castellani, *Brit. Med. Jour.*, 1905, ii., p. 1277, and *Jour. Trop. Med.*, 1905, p. 253; Purnell, *Jour. Assoc. Military Surgeons*, 1906, vol. xviii., p. 421.

[2] According to Mason it has in recent years been introduced into our Southern States by soldiers returning from tropical service; it is quite common in the Philippine Islands (Purnell).

cluded in this category. The finding of the fungus or fungi mentioned would be corroborative, but in these cases this is not always easy.

The **treatment** of dhobie itch is usually successful. The most generally used remedies are Vleminckx's solution, tincture of iodin, tincture of the leaves of cassia alata, and 5 to 10 per cent. chrysarobin ointment. In addition to these, Manson commends also 10 per cent. salicylic acid ointment and lotions ($\frac{1}{2}$–1 per cent.) of corrosive sublimate; and Purnell, a 10 per cent. epicarin ointment. Thorough cleanliness is a necessary part of the treatment, and particular attention should be given to disinfection of the underwear. In the pemphigus contagiosus type, vesicles and blebs should be opened twice daily, the parts thoroughly cleansed and disinfected with boric acid lotions or weak corrosive sublimate lotions, and then a drying dusting powder such as equal parts of zinc oxid, boric acid, and starch freely applied (Manson, Mason). In these cases too, however, when well established, it is usually necessary to have recourse to the stronger remedies mentioned, but in all cases of the disease these latter should at first be employed cautiously and in their weaker strength. As prophylactic measures against dhobie itch, Manson advises frequent cleansing of the vulnerable regions, frequent change of the underwear, and daily use of the above-named dusting powder.

PINTA DISEASE.[1]

Synonyms.—Mal del pinto; Mal de los pintos; Tiña (Mexico); Caraate; Cute (Venezuela and Granda); Quirica (Panama); Spotted sickness; *Fr.*, Caraté.

Definition.—A contagious affection of certain tropical countries, due to several fungi, characterized by variously sized and shaped scaly discolorations, occurring mostly on exposed parts.

This peculiar malady, of which the earliest accounts were given by Zéa, Alibert, Rayer, Gomez, and more recent ones by Hirsch, Iryz, Lier, Montoya, and Barbe, is seen chiefly in the tropical portions of South America. It was also prevalent among the Aztec Indians in the lowlands of Southern Mexico, where it had existed for centuries (Corlett).

Symptoms.—The spots appear first most frequently upon the face or neck. They also develop on other exposed regions, as the forearms, hands, lower part of the legs and feet, and upper part of the chest. The palms and soles are not invaded. They quite frequently

[1] Chief recent literature: Hirsh's *Geograph. and Histor. Pathol.*, New Sydenham Soc'y Translation, 1885, vol. ii., p. 379 (with bibliography); Iryz, *Independentia méd.*, Mexico, 1881–82, vol. ii., p. 254; review in *London Med. Record*, vol. x., 1882, p. 175, and *Brit. Med. Jour.*, 1882, vol. ii., p. 903; Lier, *Monatshefte*, 1892, vol. xiv., p. 447; Montoya Y. Florez, "Recherches sur les caratés de Colombie," *Thèse de Paris*, 1898; Barbe, *Annales*, 1898, p. 985 (with colored plate); also an excellent account by this same writer in *La pratique Dermatologie*, vol. i., 1900; Woolley, *Jour. Cutan. Dis.*, 1904, p. 479; Sandwith, *Brit. Med. Jour.*, 1905, ii., pp. 479 and 1270 (with bibliography).

develop upon some other previously existing eruption. Their appearance is sometimes preceded by slight itchiness. Their color varies in different cases from a white to a bluish gray and various shades to a black; in some instances it is of a red hue. The spots may be said (Barbe) ordinarily to pass through two stages: an active or developmental period, or that of coloration, and a second stage, that of retrogression or pseudovitiliginous, of which the traces are indelible. In whites the first evidences consist of a faint erythema, soon becoming coated over with furfuraceous scaliness; in the colored races the spots are of a yellowish, reddish, or grayish color. The spots become larger by peripheral extension, and new points arise near by which in turn extend, so that finally considerable surface may be invaded. The central portion of the patches gradually begins to change color to a bluish, violaceous, or reddish, from two to five years elapsing before they attain their final definite color. The scaliness often becomes more marked, changing from a furfuraceous to that of lamellar character. A variable degree of hyperkeratinization frequently develops. The itching commonly increases in degree as the disease progresses. In extreme instances most parts are invaded, the tongue, buccal, preputial, and vulvar mucous membranes not escaping. Fissures and ulcerations sometimes occur in the flexures. The hairs may loosen and fall out, in consequence, according to Montoya, of the development of a form of folliculitis. The general health does not seem to suffer. Some writers describe the occurrence of precursory symptoms of the gastro-intestinal tract.

The malady is persistent, and in some instances leaves behind prominent atrophic whitish spots. It is seen in both sexes, and in both whites and blacks, although the dark races are its more common subjects. It is due, as Montoya's studies indicate, to several kinds of fungi, of the class aspergillus, each having a distinguishing color. This writer states that he has found similar organisms in certain cereals and plants, in stagnant mine waters, and that the malady is contracted from such sources directly or through the intermedial agency of insects, especially mosquitos. They consist of mycelium and spores, differing somewhat, in minor characters, in the several varieties. The epidermis, especially the corneous layers, is the seat of the parasitic invasion, often involving the rete and causing atrophy of the latter, and finally complete disappearance of the pigment-cells. Iryz states that in some cases the corium is also involved. Recently Blanchard and Bodin have found a trichophyton.

The **treatment** is essentially the same as that employed in the other vegetable parasitic diseases, more especially of ringworm. Tincture of iodin applications seem most in favor for recent patches, and chrysarobin for those of some duration or great obstinacy.

MYRINGOMYCOSIS.

Synonyms.—Myringomycosis aspergillina; Mycomyringitis; Otomycosis; Otitis externa parasitica; Fungous disease of the external ear.

Wreden, in 1867, following the observations of Mayer, in 1844, and Paccini, in 1851, as to the existence of fungi in the external audi-

tory canal, was the first to call particular attention to this affection, and although still of somewhat obscure nature, the later writings by Politzer and Gruber, and in this country by J. O. Green, Roosa, Burnett, and Barclay, have, especially those by the last two, added materially to our knowledge concerning it.[1] Its chief characters consist of a scurfy, moist-looking, blotting-paper-like coating, of a dirty gray or brownish-gray color, with commonly here and there slightly raised, yellowish, brownish, greenish, or blackish points or spots. It is often distinctly moist, and may exhibit a candied-looking or glazed surface, due to the serous effusion provoked. This latter is sometimes present in considerable quantity. The whole canal, including the drum, may be involved, although not infrequently only parts of the meatus are apparently the seat of the disease, the drum being implicated to but a slight degree. It is generally believed, however, that the drum is primarily attacked, and from here it extends along the canal. The former may in some instances be so much damaged as to result in perforation. If the scales or crusts are forcibly removed, the underlying surface is ordinarily noted to be more or less abraded and raw-looking, bleeding easily. The first symptoms consist of itchiness, stinging, sometimes slight or great pain, and a variable impairment of hearing, usually together with a scanty, watery discharge. While there is some difference of opinion as to the specific fungus, it is the common belief that the malady is due to the aspergillus niger and the aspergillus glaucus.

There is no tendency to spontaneous disappearance. If neglected, a variable degree of deafness or permanent damage may result.

Treatment consists in an occasional syringing with a weak alkaline solution to remove the fungus and other accumulations, and the application of a mild parasiticide, such as a 1 per cent. solution of sodium hyposulphite (Burnett) and of alcohol full strength or weakened (Löwenberg). Ointments may have to be used occasionally, if needed to soften any accumulation, but are to be avoided when possible, as, according to Bezold, fatty matter favors the growth of the fungus. When deeply seated or seriously involving the drum, the case belongs more properly to the aurist.

ACTINOMYCOSIS.

Synonyms.—Actinomycosis of the skin; Lumpy-jaw; *Fr.*, Actinomycose; *Ger.*, Aktinomykose.

Definition.—Actinomycosis of the skin is an affection due to the ray fungus, characterized by a sluggish, red, nodular or lumpy infiltration, usually with a tendency to break down and form sinuses, and most commonly involving the cervicofacial region.

The condition known as lumpy jaw and osteosarcoma of the jaw in cattle had long been known, but it was Israel who first recognized the pathogenic rôle of the special fungus, named by Harz the ray fungus. About the same time the existence of a similar-looking

[1] Burnett, *Amer. Jour. Otology*, 1879, vol. i., pp. 10 and 93 (a report of 20 cases with review of the subject and references; Barclay, in Burnett's *System of Diseases of the Ear, Nose, and Throat*, 1893, vol. i., p. 190 (with review and references).

affection in man was described by Israel, and which was subsequently shown by the important contribution by Ponfick to be not only similar to that in animals, but of identical nature. Since then the malady and its fungus have received considerable attention

FIG. 246.—Actinomycosis (courtesy of Dr. W. T. Corlett).

from various observers, among whom Illich, Majocchi, Bertha, Gasperini, Krause, Müller, Poncet and Bérard, Murphy, and many others.[1] While the fungus may gain access to the internal organs and give rise to grave disease, the dermatologist is chiefly interested in the manifestations observed when the integumentary tissues are invaded. The invasion of the latter may be primary, but, as a rule, it is secondary to a deeper-seated involvement.

Symptoms.—The usual situation of actinomycosis of the skin is about the jaw, neck, and face. The organism finds entrance through the mouth, most frequently to the jaw through a decayed tooth. The first evidence is a hard, subcutaneous swelling or infiltration, which may attain moderate or quite conspicuous dimensions, the overlying skin soon becoming of a sluggish or dark-red color. Sooner or later softening is detected, the skin giving way at one or several points, from which there oozes a discharge of a seropurulent, purulent, or sanguinolent and purulent character. Contained in the discharge, recognizable in most instances, are minute, friable, yellowish or yellowish gray bodies, representing conglomerate collections of the fungus. Instead of beginning or continuing as a well-defined single swelling or tumor, the involved and infiltrated area is distinctly nodular, often finally becoming, when at all advanced, quite extensive. It

[1] Poncet and Bérard's monograph, *Traité clinique de l'actinomycose humaine*, Paris, 1898, gives an admirable and exhaustive presentation and review of the subject, with complete bibliography.

is then noted to consist of a variously and irregularly infiltrated and swollen area, dark red or bluish red, beset with several or more distinct nodulations or anthracoid formations, with here and there openings leading down or through the involved mass, with slight, moderate, or profuse discharge.[1] In some cases the surface exhibits ulcerofungoidal and papillomatous characters. Occurring on other parts of the body the same conditions are presented, occasionally involving considerable surface.[2]

The course of the malady may be slow and insidious, or somewhat rapid, usually the former, some months generally elapsing before the involvement is extensive. Sometimes it remains limited to a more or less circumscribed area.[3] As a rule, there are no subjective symptoms, but when suppuration takes place the parts may become quite painful. The lymphatic glands are not implicated except secondarily as a result of the suppurative inflammation. The general health in those instances where the invasion is from a superficial part ordinarily remains uninfluenced unless systemic pyemic infection occurs or the fungus elements find their way to the deeper organs or structures.

Etiology and Pathology.—The disease is due to the ray fungus. It is somewhat rare, and apparently oftener observed in Germany and France than elsewhere. The first cases described in our own country are those by Murphy (1885), Schirmer, Ochsner, and Bodamer (1889).[4] It is contagious by inoculation, and commonly contracted from cattle and horses, and therefore seen most frequently in those who have to do with these animals. It is probable, too, that, in some instances, as in that noted by Baracz[5] from kissing, it may be communicated from one individual to another. As the fungus is also believed to flourish on straw, corn, and other grain, the habit among farmers, dairymen, and others of chewing upon such substances[6] is very likely responsible for the common method of inoculation through the mouth, taking place, as a rule, through a decayed tooth. Successful inoculation ordinarily presupposes an abrasion or break of continuity, and this has usually been noted in

[1] Wallhauser, *Jour. Cutan. Dis.*, 1904, p. 77 (with illustration), reports an extensive case of this kind beginning as a small pimple on point of chin, and gradually involving the whole regions of the upper part of the neck and the jaws.

[2] Pringle, *London Med.-Chir. Soc'y Trans.*, 1895, vol. lxxviii., p. 21 (with colored case illustration), reports an extensive case in a boy of eleven, implicating part of the chest, the back, and hip, and developing secondary to involvement of the pleura.

[3] Sicard, *La presse médicale*, Aug. 15, 1903, reports a case in which it was confined to the finger, and the earliest symptoms (following an accidental cut in a field-worker) were of a vesicular character; Massaglio, *ibid.*, Aug. 31, also a finger case; Thevenot, *ibid.*, vol. lxxvii., 1903, p. 659, reports a case of a nodular type of paronychia of the finger caused by the actinomyces; Wright, *Amer. Jour. Med. Sci.*, July, 1904, p. 74, a tonsil case.

Some later general papers: Sawyer, *Jour. Amer. Med. Assoc.*, March 11, 1901; Ewing, *Bull. Johns Hopkins Hospital*, Nov., 1902; von Baracz, *Annals of Surgery*, March, 1903—abs. in *Jour. Amer. Med. Assoc.*, March 21, 1905; Howard, *Jour. Med. Research*, 1903, vol. ix., p. 301; Dor (researches on fungus), *La presse médicale*, Sept. 16, 1903; Stokes, *Amer. Jour. Med. Sci.*, Nov., 1904, p. 861; Knox, *Lancet*, Oct. 29, 1904.

[4] Bodamer's paper, *Med. News*, Mch. 2, 1889, gives abstract of the others, with references.

[5] Baracz, *Wiener med. Presse*, 1889, p. 6 (man to wife).

[6] Ljunggren, *Nordiskt med. Arkiv*, 1895, No. 27, p. 1—brief abs. in *Annales*, 1896, p. 763, refers to 27 cases (13 personal) occurring in those in the habit of chewing grain or straw; Zeisler's case, *Jour. Cutan. Dis.*, 1906, p. 510, was attributed to the chewing of grass.

those instances, relatively few, in which the integument was primarily involved.[1] The fungus has also been found in bovine vaccine virus (Howard).

The fungus, called the actinomyces, consists of a central network mass of interwoven threads, from which threads, or mycelia, radiate like projecting rays, and terminate in bulbous expansions; these latter are thought to represent the fructifying bodies. One to several may project beyond the others. In tissue-section examination sometimes small, oval, apparently homogeneous bodies are seen lying near the ray fungus, and suggestive of spore forms of the organism (Rosenberger).[2] While previously the fungus was thought to belong to the molds, Bostroem's (1885) investigations seemed to show it to be a variety of cladothrix, of the class schizomycetes, although on this point there is still uncertainty and difference of opinion.[3] Of the various staining methods for its demonstration, that of Gram seems to be most generally satisfactory. The fungus is usually readily demonstrable, both in the discharge (the yellowish grains) and in sections of involved tissue. In some instances, however, especially in the earlier stages, it is not always found (Legrain, Mackenzie, Knox, Galloway, and others),[4] and exceptionally only in the sections from the outlying invading borders.[5]

FIG. 247.—Actinomyces, showing the ray arrangement and the club-shaped ends of the mycelial threads (after Ponfick).

[1] Kopfstein, *Wiener klin. Rundschau*, 1901, p. 21, reports the case of a woman, a farm laborer, who developed the disease in the hand, presumably inoculated while binding corn, through a cut accidentally made a few days previously. He refers also to Müller's case, in which infection was apparently due to the entry of a splinter of wood into the palm of the hand; and another instance (Von Partsch) where it followed a surgical operation, inoculation occurring apparently by means of the surgeon's instruments.

[2] Rosenberger, *Jour. Applied Microscopy*, vol. iii., Nov., 1900, p. 1051.

[3] In an interesting paper on the biology of the micro-organism, J. H. Wright, Publication of the *Mass. Gen'l. Hosp.*, vol. i., No. 1, 1905), thinks from his studies and review that the widely disseminated branching micro-organisms thought by Bostroem and others to be the specific infectious agent of actinomycosis are really quite different, having spore-like reproductive elements and should be grouped together as a separate genus with the name Nocardia and that infection by them should be called nocardiosis, and not actinomycosis; that the term actinomycosis should be used only for those inflammatory processes the lesions of which contain the characteristic granules or "drusen," composed of dense aggregates of branched filamentous micro-organisms and of their transformation or degeneration products—these products including the characteristic refringent club-shaped bodies radially disposed at the periphery of the granule, and which may or may not be present. Apropos of this may be mentioned a recent paper by Kieseritzky and Gerhardt, *Archiv. klin. Chirurg.*, 1905, pp. 835, *et seq.*, shows that some cases clinically resembling the disease, and even containing radiating filaments, are rather negatived by more careful, especially laboratory, investigation; as also Pernet shows (*Brit. Jour. Derm.*, 1905, p. 265), in some cases clinically presenting the picture of actinomycosis, the microscopic examination discloses the characteristic appearances of streptothrix.

[4] Legrain, *Annales*, 1891, p. 772; Mackenzie, *Brit. Jour. Derm.*, 1894, p. 370; Knox, *Glasgow Med. Jour.*, vol. xlv., 1896, p. 382; Galloway, *Brit. Jour. Derm.*, 1895, p. 116.

[5] In a case of a physician, involving the arm, operated upon several times at the Jefferson Medical College Hospital, repeated examinations of the discharge and tissue

Histologically, the nodular and infiltrated mass is made up of granulation tissue, having a resemblance to that of round-celled sarcoma; in some instances epithelioid, giant-cells, and mast-cells are to be seen.

Diagnosis.—The disease is to be distinguished from syphilis, sarcoma, carcinoma, tuberculous affections, mycetoma, and phlegmonous inflammation. The presence of the peculiar yellowish bodies or granules in the discharge would be of conclusive import. The common location about the angle of the lower jaw and neck and cheek, and especially occurring in those who have to do with animals and grain products, should always lead to the suspicion of actinomycosis, which can be verified or disproved by observation and by examinations for the fungus; in doubtful instances repeated examinations should be made for the latter in the discharge, and also in the deeper bordering tissue, before its absence can be accepted as proved.

Prognosis.—Actinomycosis of the skin and superficial parts is usually a remediable disease, although always fraught with the possibility of deeper involvement and grave consequences. Schlange,[1] from a study of a number of patients, takes a rather favorable view of these cases, stating, from his analytic study, that, excepting when involving the internal organs, it has a pronounced tendency to spontaneous recovery. It does, however, in some instances continue almost indefinitely without exhibiting such disposition. The advent of pyemic symptoms is always of serious, and usually fatal, import. Involvement of the upper jaw is more serious than that of the lower jaw or other surface situations, as there is more danger of deep invasion.[2] Involvement of the orbit is also of serious portent. It is a matter of observation that some cases are inherently mild and others more or less malignant, doubtless due to the virulence of the fungus and the varying resisting power of different individuals, and on the influence of accidental secondary infective processes.

Treatment.—The management of this malady consists in the administration of potassium iodid in moderate or large dosage, conjointly with, in obstinate or spreading cases, curetting or excision of the diseased mass. This remedy varies in its effect in different instances, but it has proved beneficial or curative (Carless, Pringle, Morris, Rydygier, Jurinka, Nocard, Netter, Dubreuilh, Audry, Ljunggren, Claisse, Bérard, and many others) in many cases, and should always be given a good trial before operative measures are instituted. According to Bérard and others, its most rapid and brilliant results are in those instances in which the malady is recent and uncomplicated, but when there is associated secondary infection by streptococci, staphylococci, or the bacterium coli commune, the remedy is less satisfactory. Rydygier[3] successfully treated 2 cases by local injections of a 1 per cent. solution of potassium iodid and sodium iodid, injecting at first

from the main portion failed to disclose the fungus, but it was finally found in sections from the extreme outer edge of the spreading border.

[1] Schlange, "Zur Prognose der Aktinomykose," *Verhandl. f. Deutsch. Gesellsch. f. Chirurg.*, 1892, part ii., p. 24.

[2] See paper by Bourquin and de Quervain, "Sur les complications cérébrales de l'actinomycosis," *Rev. méd. de la suisse rom.*, vol. xvii., 1897, p. 145 (with references).

[3] Rydygier, *Wien. klin. Wochenschr.*, 1895, p. 649; also Sawyer, *loc. cit.*

one Pravaz syringeful, later half as much again; one of these cases had been previously treated without result by surgical means and the internal administration of the drug. Bevan[1] and Zeisler report favorably of copper sulphate, $\frac{1}{4}$ grain dose (0.017) four times daily.

The local treatment of the lesions is essentially that of similar nodular ulcerative and suppurative formations—the maintenance of cleanliness and the applications of mild antiseptics, a frequently changed wet dressing of Lugol's solution being one of the best, and probably of some direct inhibitory influence upon the growth or effects of the fungus. I have found the X-ray valuable.

MYCETOMA.[2]

Synonyms.—Fungus foot of India; Madura foot; Tubercular disease of the foot; Podelcoma; Ulcus grave; Morbus pedis entophyticus; *Fr.*, Mycétome; Pied de Madura; *Ger.*, Madurafuss; Mycetoma.

Definition.—An endemic disease, chiefly of India, commonly involving the foot, and characterized by swelling and the formation of tubercular or nodular lesions which tend to break down and form sinuses leading into the subcutaneous structures, and finally resulting in disintegration of the affected part.

Symptoms.—With some exceptions the foot is the site of the disease, only rarely in fact the hand, knee, or other region being attacked. It is observed chiefly in those who go barefooted, generally following a slight injury. It begins, as a rule, as a small papule or nodule, and either upon apparently normal skin or is preceded by slight edematous swelling. The nodule increases slowly in size, new lesions appearing from time to time near by. When at all established, the involved area or part is somewhat reddened, variably swollen, and the seat of scanty or numerous nodular formations, which are usually most conspicuous toward the periphery. The nodules are elevated, some quite firm or hard, others softer or even sluggishly furuncular, and others perforated centrally by an opening which is the external end of a sinus leading down to muscle or bone; from these sinuses is discharged a puriform liquid containing small round, black, gunpowder-like bodies or "grains," or a fish-roe-like substance; in other

[1] Bevan, *Jour. Amer. Med. Assoc.*, Nov. 11, 1905.

[2] Principal literature: Vandyke Carter, *On Mycetoma or Fungus Foot of India*, London, 1874; Fox and Farquhar's *Endemic Skin and other Diseases of India;* Manson, *Tropical Diseases*, 1898, p. 568; Hyde, Senn and Bishop, "A Contribution to the Study of Mycetoma in America," *Jour. Cutan. Dis.*, 1896 (with colored plate case illustration, review, and bibliography; and abstract of case in Canada reported by Adami and Kirkpatrick). In addition to these 2 American cases, 3 others have since been reported: Pope and Lamb, *New York Med. Jour.*, 1896, vol. lxiv., p. 386 (with case and fungus illustrations); Wright, *Trans. Assoc. Amer. Phys.*, 1898, vol. xiii., p. 471; and Arwine and Lamb, *Amer. Jour. Med. Sci.*, vol. cxviii., 1899, p. 393. Libouroux, "Contribution a l'étude de la maladie dite pied de Madura consideré comme une tropho-névrose," Paris, 1886; Kanthack, "Madura Disease (Mycetoma) and Actinomycosis," *Jour. Pathol. and Bacteriol.*, Edinburgh, vol. i., 1892–93, p. 140 (with illustration); Unna and Delbanco, "Beiträge zur Anatomie des indischen Madurafuss," *Monatshefte*, vol. xxxi., 1900, p. 545 (with review, 10 colored histologic cuts, and complete bibliography).

instances the discharge is of a whitish color, and exceptionally of a reddish hue.

Occasionally, in addition to or in place of the papular or nodular lesions, pustules may be seen, and also vesicles, blebs, and abscesses have rarely been noted. The progress of the malady is slow, usually several years or more elapsing before material damage has been done. The sinuses finally encroach upon the bony structures, the latter being eroded and disintegrated by the presence and action of the causative fungus. The local conditions in the advanced disease are also often partly due to secondary infective processes, as from pus cocci, etc.

Etiology and Pathology.—The malady is most frequent in India, and relatively rare elsewhere. Five unquestioned cases have been recorded in our own country. For obvious reasons males are more prone to it, as they are more in the habit of going barefooted. A slight traumatism or break in the continuity of the skin apparently gives access to the pathogenic fungus. The organism is the actinomyces Maduræ, consisting of mycelium of branching threads and hyphæ and ovoid spores. Two varieties of the malady have been noted, based upon the color of the discharged bodies or "granules": the black or melanoid, and the pale, ochroid, or yellow, the former being of greater frequency. The black granules bear resemblance to poppy-seeds or gunpowder, the pale or pale yellowish to fish-roe. These granules microscopically are seen to present a central network of mycelia with radiating mycelial threads, which may terminate in bulbous swellings. In fact, the close resemblance to the fungus of actinomycosis and the gross clinical similarity have led some to believe the maladies identical, but the majority of observers (Hyde, Paltauf, Unna, and others)[1] are satisfied that the etiologic fungi are not the same; that of actinomycosis is highly colored by acid fuchsin, while that of mycetoma is not materially affected.

Section of the tissues of the involved part shows small and large cavities or spaces connected by the sinuses; these spaces contain a fatty or gelatinous substance, which in the black variety is dark colored and hard, and in the pale or pale-yellowish variety soft and ochre-colored. According to Kanthack and others, there are the usual evidences of reactionary inflammation surrounding the fungus collections, and the presence of granulation tissue with epithelioid cells and many vessels, and a scattered formation of pigment; in the later stages the granulation tissue undergoes change into fibrous tissue and the formation of abscesses and fistulæ.

Diagnosis.—The region involved, the character of the discharge, and the absence of any tendency to visceral involvement are usually sufficient to distinguish the malady from actinomycosis. This latter, moreover, is commonly seen in those who have to do with cattle or grain. Microscopic examination of the discharge will show the fungus, which, though presenting some resemblance to that of actinomycosis, stains differently with acid fuchsin.

[1] Unna, "Aktinomykosis und Madurafuss," *Deutsche Medicinalzeitung*, 1897, p. 49; Oppenheim, *Archiv*, vol. lxxi., 1904, p. 209.

Prognosis and Treatment.—The disease pursues a chronic course,—ten to twenty years,—resulting in total disorganization of the affected structures. Instances of spontaneous cure are unknown. Treatment consists in thorough removal of the diseased part by the knife. When of long standing and a large area is involved, amputation is indicated, care being exercised to include all infected points.

BLASTOMYCETIC DERMATITIS.

Synonyms.—Blastomycosis of the skin ; Saccharomycosis hominis ; Dermatitis blastomycotica ; Oïdiomycosis of the skin ; *Fr.*, Blastomycose cutanée ; *Ger.*, Hefenmykose ; Hautblastomykose.

It is especially to the studies primarily of Gilchrist, and later of Hyde, Hektoen, Bevan, F. H. Montgomery, and Ricketts, that the existence of this cutaneous malady has been made known.[1] It begins, as a rule, as a small, pea-sized papule or papulopustule, which slowly, in the course of days or several weeks, has enlarged to the diameter of a dime, flattening down centrally and showing crusting. Upon removal of the crust the surface is noted to be irregular and somewhat papillomatous, with occasionally, at this stage, and almost always later, a variable amount of seropurulent fluid between the papillary projections. The border of the patch is elevated, reddish, usually of a deep red tinge, and well defined by moderate infiltration. Either by increase peripherally, as well as sometimes with the arising of new foci just outside the border, the area covered may in several months or a year or so be considerable in extent. The enlargement may occur in all directions or preponderantly on one side, or it may be somewhat linear in extension. When at all developed, the malady consists of an elevated, irregular,

[1] Gilchrist, *Johns Hopkins Hospital Reports*, 1896, vol. i., p. 269 ; Hyde, Hektoen, and Bevan, *Brit. Jour. Derm.*, 1899, p. 261 ; F. H. Montgomery and Ricketts, *Jour. Cutan. Dis.*, 1901, p. 26 ; Hyde and Ricketts, *ibid.*, p. 44 (with analytic table and references) ; Stelwagon, *Amer. Jour. Med. Sci.*, Feb., 1901 ; and Ricketts, *Jour. Med. Research*, Dec., 1901. This last by Ricketts, which is largely based upon the work and case reports by Hyde and F. H. Montgomery, with their photographs and photomicrographs, gives a presentation of the literature and a résumé of the published cases of Hessler, Wells-Senn, Brayton, Anthony-Herzog, Dyer, and others to date ; F. H. Montgomery, *Jour. Cutan. Dis.*, 1902, p. 195 (2 cases).

Later Literature : F. H. Montgomery, *Jour. Amer. Med. Assoc.*, June 7, 1902 (cases of Hyde and Montgomery; finely illustrated) ; Busch, *Bibliotheca Medica*, vol. ii., part 10, 1902 (illustrations and bibliog.) ; "Second Annual Report of the Cancer Committee to the Surgical Dept. of the Harvard Med. School," *Jour. Med. Research*, 1902, vol. vii., No. 3; Gilchrist, *Brit. Med. Jour.*, 1902, vol. ii., p. 1321 (negro ; with illustrations, review and bibliography) ; Sheldon, *Jour. Amer. Med. Assoc.*, 1902, vol. ii., p. 1356 ; Walker and F. H. Montgomery, *Jour. Amer. Med. Assoc.*, April 5, 1902 (death from systemic infection) ; Dyer, *American Medicine*, Oct. 25, 1902 ; Sequeira, *Brit. Jour. Derm.*, 1903, p. 121 ; Pusey, *Jour. Cutan. Dis.*, 1903, p. 223 (2 case demonstrations, with illustration) ; McCarrison, *Indian Med. Gaz.*, April, 1903 ; Löwenbach and Oppenheim, *Archiv*, 1904, vol. lxix., p. 121 (3 plates) ; F. H. Montgomery, *Jour. Cutan. Dis.*, 1903, p. 19 (followed by systemic tuberculosis and death) ; Ormsby and Miller, *Jour. Cutan. Dis.*, 1903, p. 121 (illustrations ; cutaneous and systemic case ; death ; autopsy) ; Evans, *Jour. Amer. Med. Assoc.*, June 27, 1903 (infection was introduced through a punctured wound inflicted while performing an autopsy on a patient that had died of systemic blastomycosis) ; Shepherd, *Jour. Cutan. Dis.*, 1902, p. 158 ; H. R. Varney, *Detroit Med. Jour.*, 1903–4, vol. iii., p. 73. Fischkin, *Chicago Med. Recorder*, 1903, p. 408 ; Wright, *Northwest. Lancet*, 1904, p. 149 ; Dubreuilh, *Jour. de méd. de*

papillomatous area, of a deep-red or florid color, and with a moderate or tolerably free seropurulent secretion. In places, especially the oldest parts, partial or complete healing may take place, the surface skinning over and exhibiting a thin, atrophic, or scar-like appearance. There is but little tendency to actual ulcerative action. Exceptionally, as in my case, foci of disease present some distance off, as, for example, up the arm when the back of the hand is the site, and may assume the same features or present as a small, flattened, sluggish, carbuncle-like formation, breaking at several points and discharging. In other cases the clinical aspects are closely analogous to those of lupus vulgaris. The general health, except in the rare cases of systemic infection, does not seem to suffer.

FIG. 248.—Blastomycetic dermatitis; man aged forty-nine; duration four years; healing tendency in central portions.

Etiology and Pathology.—The malady is rare, and in about 75 per cent. of the cases is seen in men, and for the most part in those over forty. The family history has shown no special tendency or vulnerability. The investigations have disclosed the presence of the yeast fungus as the causative agent. In a few instances the disease started at the point of a slight abrasion or traumatism. The back of the hand, face, and lower part of the leg are the favorite localities. A blastomycetic infection on other skin diseases is a possibility.

Bordeaux, 1904, p. 529 and *Annales*, 1904, p. 865 (first French case); Unna, *Münch. med. Wochenschr.*, 1904, p. 1367; Clary, *Medicine*, 1904, p. 818; Koehler and Hall, *Jour. Cutan. Dis.*, 1904, p. 581 (in a negro); Eisendrath and Ormsby, *Jour. Amer. Med. Assoc.*, 1905, vol. xlv., p. 1045 (case with systemic involvement, illustrated; with a review of the previously reported cases of generalized infection); Christensen and Hektoen, *ibid.*, vol. xlvii., p. 247, 1906 (2 cases, generalized); Bowen, *Jour. Cutan. Dis.*, 1906, p. 30 (case demonstration); and Bowen and Wolbach, *Jour. Med. Research*, 1906, p. 167 (first Boston case); Sakurane, *Archiv*, 1006, vol. lxxviii., p. 211 (probable case—first Japan case; with case illustrations).

PLATE XXXIV.

Blastomycetic dermatitis. The black-and-white text-cut (Fig. 239) shows the same case at a later period, partly healed on the back of the hand, but extending further on the fingers and with a new centre on the wrist.

The histopathologic characters are in a measure similar to those found in tuberculosis verrucosa cutis. These findings, as shown by the investigations of Gilchrist, Hyde, Hektoen, F. H. Montgomery, Ricketts, and others, are succinctly expressed by Ricketts: "Naked-eye inspection of a cross-section shows, from without inward: (1) A papillary zone, composed of a superficial layer of isolated villiform processes, and a deeper layer of similar processes which are united side by side. (2) A homogeneous, vascularized, grayish-red, cellular zone, in which are formed minute abscesses. (3) An unaltered layer of subcutaneous fat, as the limit of deep extension. . . . Stained sections exhibit the following histologic features: (1) A vast amount of 'carcinomatoid' epithelial hyperplasia. (2) Minute intra-epithelial abscesses. (3) A granulomatous condition in the corium, characterized by masses of

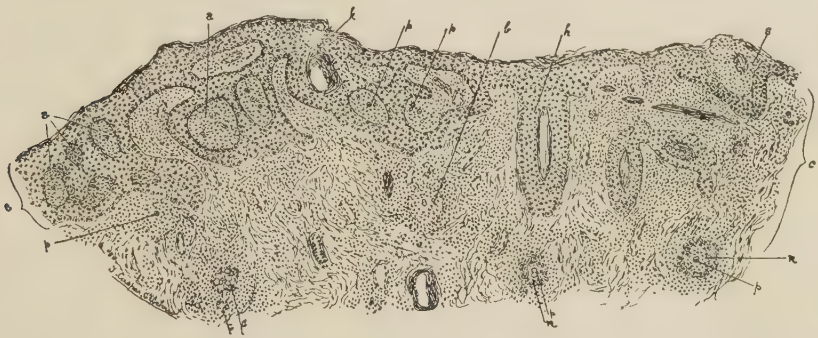

FIG. 249.—Blastomycetic dermatitis, showing hypertrophied epidermis (*e*), numerous miliary abscesses (*a*), which contain parasitic organisms (*p*). In the corium (*c*) are miliary abscesses (*b*), pseudotubercles (*n*), with giant-cells (*g*) and parasites (*p*) (courtesy of Dr. T. C. Gilchrist).

plasma cells, minute abscesses, and tuberculoid nodules and giant-cells. (4) The presence of a spheric, capsulated, budding organism, particularly in the epidermal and subepidermal abscesses, but also distributed unevenly and in small numbers in epithelial masses and granulation tissue." The organism, or fungus,—the blastomyces,—is sometimes but scantily found. It consists of a rounded, doubly contoured, vacuolated body, averaging in size 10 to 12 μ. They are often seen in pairs, and also as budding forms, but in the tissues never exhibit threads, as observed in cultures. Proliferation in the former is by gemmation; it seems probable, also, that endogenous spores may form (Ricketts); Hyde and F. H. Montgomery state that under certain conditions blastomyces multiply by sporulation.[1]

[1] It is now pretty generally believed and conceded that the so-called protozoic disease of Posadas, Wernicke, Rixford and Gilchrist, D. W. Montgomery, and others, Busse's and Curtis's saccharomycosis hominis, and Gilchrist's, Hyde and F. H. Montgomery's blastomycetic dermatitis, are various manifestations of the same disease; and that the organisms isolated from various cases differ in minor respects, but are so closely related morphologically and biologically as to justify their inclusion in a common genus.

In later papers, however, D. W. Montgomery and his associates (see "Dermatitis Coccidioides," by D. W. Montgomery, Rafogel, and H. Morrow, *Jour. Cutan. Dis.*, 1903,

The pathogenic rôle of the blastomyces has been shown by the animal experimental inoculations recorded (Gilchrist and Stokes, Hyde and Hektoen, F. H. Montgomery and Ricketts).

Diagnosis.—The disease is to be distinguished from tuberculosis verrucosa cutis, vegetating syphiloderm, and lupus vulgaris. Its resemblance to the first is striking, but ordinarily the border of the tuberculous eruption has a deeper, usually more violaceous, color, and is less apt to be extensive. Its usual method of beginning, course, and behavior are different from those of syphilis. The latter is, moreover, more distinctly purulent, the discharge having a greenish tinge and often an offensive odor. Lupus vulgaris is relatively slow in its course, with often distinct ulcerative tendency, and frequently rather tough, firm scarring. It is to be stated, however, that a positive conclusion in the differentiation with tuberculosis verrucosa and to a less extent with lupus vulgaris is possible only by microscopic examination, cultures, or experimental animal inoculations.

Prognosis and Treatment.—The ordinary verrucous type, which remains distinctly cutaneous, is not dangerous to life, but it is obstinate and sometimes destructive and distorting. If the cases reported as "protozoan infection" and "coccidioidal dermatitis" are to be included, in such instances the malady is of possible grave character, these cases ending, as a rule, fatally within some months or a year or more.

Treatment consists in the maintenance of cleanliness and the use of antiseptic applications, with, when necessary, the removal of the

p. 5, with illustrations showing the organism; and "Dermatitis Coccidioides; Reasons for Considering It an Independent Disease," by D. W. Montgomery and H. Morrow, *ibid.*, 1904, p. 368) contend strongly against the view that the blastomycetic dermatitis and the coccidial cases are identical. Their principal differences stated are "that in dermatitis coccidioides there is a great diversity in the clinical picture; the skin lesions, which resemble the rotten-tomato-like lesions of the tuberous iodid of potassium eruption, may be scattered widely over the skin, or occur as subcutaneous abscesses; the cutaneous lesions are frequently secondary to internal infection; it tends strongly to become generalized and end fatally; the organism has a double cycle of growth without any feature in common, one in the tissues, and one in culture media; the organism increases by endogenous spore-formation, and budding has not been seen; in fresh specimens the double-contoured sphere may often be seen to be surrounded by a halo of short filaments like the cilia of ciliated epithelium; the organism is larger than blastomyces; the administration of potassium iodid has no control over the disease." In discussing the last paper and the conclusions, Gilchrist, Hyde, and F. H. Montgomery reiterated their already-known changed views, accepting the identity of these various coccidial cases with those of blastomycetic dermatitis, citing cases of the latter which seemed to show phases similar to those described by D. W. Montgomery. In the material from a case (Wright-Bolles case) more recently examined by Wolbach (The Life Cycle of the Organism of "Dermatitis Coccidioides"—*Jour. Cutan. Dis.*, 1905, p. 18), the organism found was identical with that observed by D. W. Montgomery, Ryfkogel, and Morrow, and the writer also believes it a distinct type; D. W. Montgomery, *ibid.*, 1905, p. 115 (The Mould of Dermatitis Coccidioides); Ophüls, Coccidioidal Granuloma (3 cases; with review of similar cases), *Jour. Amer. Med. Assoc.*, vol. xlv., 1905, p. 1291, and P. K. Brown, Coccidioidal Granuloma, *ibid.*, Mar. 2, 1907 (2 cases; with review), also agreed with these observers. (For cases described as *protozoic infection*, see papers by Rixford and Gilchrist, *Johns Hopkins Hosp. Reps.*, 1896, p. 209, D. W. Montgomery, *Brit. Jour. Derm.*, 1900, p. 343, and Ophüls and Moffitt; *Philada. Med. Jour.*, vol. v., 1900, p. 1471.) Somewhat akin to some of the manifestations of protozoic infection and blastomycetic dermatitis are those recorded as **sporotrichial infection**, characterized by refractory subcutaneous abscesses (see papers by Schenck, *Johns Hopkins Hosp. Bull.*, 1898, p. 286, and Hektoen, *Jour. Exper. Med.*, 1900, vol. v., p. 77).

involved tissue by the curet or knife. The external measures are, in fact, similar to those employed in tuberculosis cutis. Before operative measures are decided upon, however, the effect of the administration of potassium or sodium iodid in increasing dosage should be tried, as this has succeeded in decidedly improving some cases and

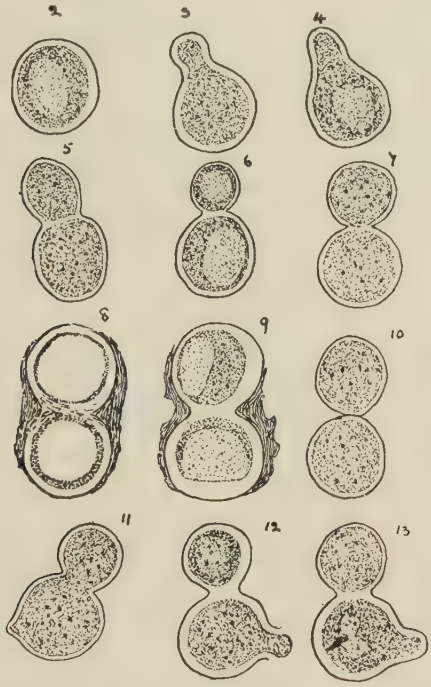

FIG. 250.—Blastomyces—fungus of blastomycetic dermatitis. Nos. 2–13 represent various budding forms found in the sections, Nos. 8 and 9 show the organisms with some form of fibrous coating (courtesy of Dr. T. C. Gilchrist).

curing others (Bevan, Hyde and F. H. Montgomery, Ricketts, Shepherd). The remedy acts slowly, however, and must be continued for some months, the malady in this respect differing materially from the vegetating syphiloderm, which responds rapidly to such treatment. Recently favorable action has been noted to follow X-ray treatment.

B. DISEASES DUE TO ANIMAL PARASITES.

PEDICULOSIS.

Synonyms.—Phthiriasis; Morbus pedicularis; Morbus pediculosis; Malis pediculi; Lousiness; *Fr.*, Phtiriase; Maladie pédiculaire; *Ger.*, Läusesucht.

Pediculosis, while signifying mere lousiness, is commonly understood as a designation of that condition of local or general cutaneous irritation due to the presence of the animal parasite—the pediculus, or louse. The parasite belongs to the class insecta, of the subdivision hemiptera, and the family pediculidæ. Three species of the parasite are encountered, each having its particular field of operation —pediculus capitis, pediculus corporis, and pediculis pubis. The first is found upon the scalp region, and only accidentally and temporarily on other parts; the second has the general body surface, or in reality

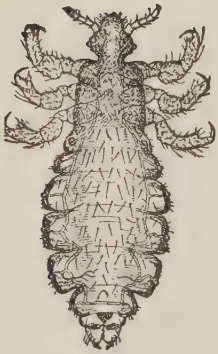

FIG. 251.
Pediculus capitis.

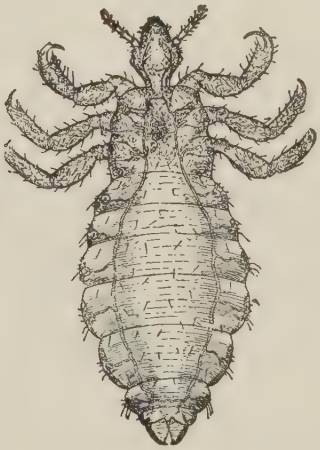

FIG. 252.
Pediculus corporis.

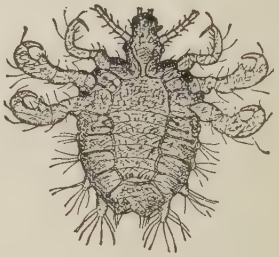

FIG. 253.
Pediculus pubis.

(Female; dorsal surface; × 25) (courtesy of Dr. L. A. Duhring.)

the clothing, as its special habitat, while the pediculus pubis, especially the pubic region, but also other parts where there are short stiff hairs, as the axillæ, the breast and leg hairs, the eyebrows, and the eyelashes. Only rarely do these three parasites invade other than their own special regions named,[1] and then, as a rule, only accidentally and temporarily. Depending upon this fact, three varieties of the malady are presented, named, according to the parts involved, pediculosis capitis, pediculosis corporis, and pediculosis pubis.

In appearance, shape, and other features the head and body lice are practically alike, the former being from $1\frac{1}{5}$ to $3\frac{1}{5}$ mm. in length, or

[1] Grindon, "The Migration of Pediculi," *The Med. Fortnightly*, Mch. 15, 1893, gives a few examples and cites others, with references.

averaging about one-third less in size than the latter, which varies from $1\frac{1}{5}$ to $4\frac{1}{5}$ mm. long. Upon the whole, clinical observation shows the body-louse to be predominantly much the larger—much more so than these figures would indicate. Their breadth is about, or a little less than, half their length. The male is smaller than the female; the sexual organ of the former is on the dorsal surface, and consists of a conic or wedge-shaped, protruding, and relatively large structure; the vaginal opening in the female is on the ventral surface. These pediculi are of an elongate, ovalish shape, having six strongly jointed legs with stout claws coming off from the thoracic portion; the longer abdominal part shows laterally well-defined deep notches. The rounded, acorn-shaped head, somewhat ovalish in the body-louse, has two prominent eyes and two antennæ. Both the head-louse and body-louse are grayish in color, with blackish margins. After feeding, the contained blood imbibed gives the parasite a slight or decided reddish tinge, more noticeable, as a rule, in the pediculus corporis. The pediculus pubis, or crab-louse, averages much shorter than either the head- or body-louse, the thoracic and abdominal portions show apparently no division, and the head seated squarely upon the body. It varies in length from 1 to $2\frac{1}{10}$ mm., and is almost as broad as it is long. In addition to the usual number of jointed claws it has eight strong, teat-shape, prehensile feet going off from the the margin of the abdomen. In color it is grayish, with a yellow tinge, and is more or less translucent. In other respects it is similar to the other varieties, except that there are no well-defined notches laterally. The reproductive capacity of parasites is very great, from fifteen to twenty eggs for the pubic variety to fifty or more for the others. The ova, or nits, are found attached to the hair-shafts in the scalp and pubic varieties, and in the clothing and on the lanugo hairs in pediculosis corporis. The ova are minute, dirty-white or grayish-looking, pear-shaped bodies, visible to the naked eye, and glued to the hair by a chitinous substance, with the projecting butt end pointing toward the distal end of the shaft. They hatch out within a week, and the young are sexually competent in less than two weeks more. It can readily be seen how rapidly they multiply. While the parasites cannot be said to be elective in the choice of subjects, yet some individuals seem to be less desirable as hosts than others.

FIG. 254.—Ova of the head-louse attached to a hair (magnified) (after Kaposi).

The symptoms produced by the parasites primarily or secondarily

vary within considerable limits, and this is not always necessarily dependent upon the number present, but to some extent upon the irritability of the skin and other individual factors. In marked examples of pediculosis, owing to the constant irritation and itching, and sometimes to the consequent disturbed sleep, the general health may be influenced. In fact, in some instances there seems to be an appearance of impaired nutrition, the skin being of a dingy, unhealthy color, and, especially in the scalp variety, the hair dry and lifeless looking. This may possibly be in a measure due to the absorption of some toxic substance from the pediculi themselves, transferred when pricking the skin for nourishment. At all events, the changed general appearance, the healthier tone of the skin, and improved nutrition ensuing upon a cure of the malady are sometimes striking, and scarcely otherwise explainable.

While the symptoms of pediculosis are to a great extent the same in the three varieties of the malady, they are somewhat modified by the locality invaded, and are therefore best described separately.

PEDICULOSIS CAPITIS.

Synonyms.—Phthiriasis capitis; Pediculosis capillitii; Head-lice; Head-lousiness; *Fr.*, Phtiriase de la tête.

Pediculosis capitis, or head-lousiness, due to the presence of the pediculus capitis, occurs much more frequently in children than in adults, although it is quite common in grown girls and women, the occipital region being that predominantly infested. Men, owing doubtless to the shorter hair and fewer opportunities for a successful lodgement of the parasite, are rarely its subjects. In some instances beyond slight itchiness there are no other symptoms, except, of course, the presence of the parasites and their ova attached to the hairs. In many subjects, however, the affection is characterized not only by marked itching, but also by the formation of various inflammatory lesions, such as papules, pustules, excoriations, and small crusted areas—resulting from the irritation produced by the parasites and from the scratching to which the intense pruritus often gives rise. In fact, commonly an eczematous eruption of an oozing and pustular type soon develops, attended with more or less crust formation, and such is often practically limited to or most pronounced posteriorly just at the region of the occiput. Impetiginous lesions over the scalp, and sometimes a few on face or neck, together occasionally with a few excoriations on these parts, may be seen in some cases. In extreme instances, as a result of the exudation and negligence and the collection of extraneous dirt, the hair becomes glued together, forming irregular, tangled, more or less felted masses, and emitting an exceedingly offensive odor. Most of the cases of the so-called *plica*, or *plica polonica*, so common in former times among the poorer classes, especially in certain countries, as in Poland, were unrecognized instances of this kind; some were examples of tangled felting and massing, doubtless resulting from uncomplicated oozing, crusted eczemas.

In addition to the various other symptoms, few or more pediculi can commonly be discovered scattered around in the hair, and ova, or nits, generally in great numbers, are to be seen attached to the hair-shafts. Several or a profusion of them may be found on a single shaft. They are minute, pin-head-sized, pear-shaped, whitish or grayish-white bodies, firmly glued to the hair with the projecting butt end pointing toward the distal extremity of the shaft.

The **diagnosis** of pediculosis capitis is a matter of no difficulty. The pediculi are usually to be found, sometimes requiring some hunting; but even if they exist in small numbers and are not readily discovered, the presence of ova, or nits, on the hair-shafts, always to be seen upon careful inspection, will indicate the nature of the affection. They should not, however, be confused with the minute seborrheic scaly particles quite frequently to be observed scattered through the hair, and occasionally slightly encircling the shaft; nits are firmly attached, while seborrheic scales can be dislodged by light brushing or shaking. In women and girls, pustular eruptions upon the scalp, especially posteriorly, should always arouse a suspicion of pediculosis. There is, of course, the possibility in some cases of the pediculosis being secondary to eczema instead of being the primary exciting factor of the eczematous irritation.

Treatment.—The applications upon which reliance is usually placed consist of crude petroleum, tincture of cocculus indicus, mercuric chlorid lotion, and ointments of white precipitate, sulphur, and β-naphthol, from 20 to 60 grains (1.3–4.) to the ounce (32.) of petrolatum. In slight cases I have found a daily shampooing with a sulphur-naphthol soap a satisfactory method; the lather is always to remain on five to ten minutes. In the use of crude petroleum the scalp is to be soaked with it, and a head-bandage applied or a suitable cap worn; care should be taken that the oil does not run down over the forehead or down the neck, as it is likely to be irritating to these parts. To lessen its inflammability it may be mixed with half its quantity or even an equal part of olive oil or liquid petrolatum. This dressing is to be worn for twelve hours, and the scalp then thoroughly washed with soap and water. As a rule, this will suffice to destroy all the pediculi and the attached ova. If there is any doubt in regard to this, the dressing is to be renewed for another twelve hours. Owing to its inflammability it is not a good plan for practice among the ignorant or careless. Cocculus indicus is commonly employed diluted with one, two, or three parts of water, and sponged on the scalp twice daily for a few days, and associated and supplemented with soap-and-water washings. Mercuric chlorid lotion, in the strength of ½ or 2 grains (0.033–0.13) to the ounce (32.) of water, or equal parts of alcohol and water, is to be applied for two or three days twice daily; it should not be employed if there is much irritation or a raw surface. If the parts are decidedly eczematous, one of the several ointments named may be used instead of the lotions, making the application freely and thickly and enveloping the head in a bandage, and renewing the dressing twice a day for from two to four days. Subsequently to the active treatment, or in association with it, the scalp should be washed once daily with soap

and water or with alkaline lotions or dilute acetic acid (1 part to 10 or 20 of water) in order to free the hair-shafts from the ova or shells that may be attached; frequent combings with a fine-toothed comb will be of service both for this purpose and also for the removal of the pediculi. In the management of pediculosis capitis close cutting of the hair will facilitate the treatment, but it is not essential.

PEDICULOSIS CORPORIS.

Synonyms.—Pediculosis vestimenti seu vestimentorum; Phthiriasis corporis; Vagabond's disease; *Fr.*, Phtiriase du corps.

Pediculosis corporis, or body-lousiness, is due to the presence of the pediculus corporis. It is characterized by more or less general itching, excoriations, together with various inflammatory lesions, some of which may be primary and others secondary. In sensitive skin wheals, usually of evanescent character, sometimes arise at the points where the parasites have inserted their sucking apparatus, or haustellum. This act also produces a peculiar lesion, which may be said to be characteristic, consisting of a minute hemorrhagic punctum on a level with the surface and practically imperceptible to the finger passing over it—in this respect differing from the red, excoriated points resulting from scratched, congested, or irritated follicles. As the parasites live in the clothing, in the seams, and also where the skin is most conveniently reached for purposes of feeding, the various lesions and excoriations are, therefore, to be found most abundantly on those parts with which the clothing comes closely in contact, as, for instance, around the neck, across the shoulders and upper part of the back, around the waist, over the sacrum, and down the outside of the thighs. The parasites, if numerous, are readily found, but if in scanty number are to hunted for in the seams of the collar-band; the ova are also found in the clothing, and sometimes attached to the lanugo hairs, especially of the upper part of the trunk. The irritation produced is often sufficiently intense in this form to lead to more or less violent scratching, so that it is not uncommon to see, here and there, but especially upon the upper part of the back, parallel linear scratch-marks made by several or more of the finger-nails, in efforts to gain relief. The continued irritation, consequent hyperemia, and the excoriations occasionally bring about in places a slight degree of eczema, and also in persistent cases a variable degree of resulting pigmentation, most pronounced on the upper portion of the trunk posteriorly, although in extreme instances it is more or less general and of quite a dark hue, as to suggest the possibility of Addison's disease (see under chloasma).[1]

The violence with which the skin is sometimes scratched is such that the nails not only penetrate to the corium, but into some depth of the latter, as shown here and there, especially on the back, by

[1] The observations of Besnier, Greenhow, and Thibierge (Thibierge, *Bull. et mém. de la Soc. méd. des hôp. de Paris*, Dec. 18, 1891) that in some of these instances pigmentation is also found on the buccal mucous membrane, and also on the glans penis, would seem to indicate that there were other reasons for the integumentary discoloration in addition to those commonly believed. Thibierge remarks that such cases reduce the pathognomonic significance of pigmentation of the mucous membranes in Addison's disease.

scattered, small, irregular, atrophic-looking, or cicatricial spots. These are also to some extent possibly due to the secondary ecthymatous lesions which are occasionally seen. The symptoms vary considerably, however, in different individuals, in some the itching being extremely slight and the effects insignificant, in others of a decided, scarcely bearable character, the patients getting but little rest, and the skin the seat of papules, small and large pustules, and excoriations. Jamieson[1] has recorded a few instances of pyrexia, apparently of reflex nature, due to the presence of body-lice, and in cases in which the cutaneous lesions were insignificant. Pediculosis corporis is commonly seen in adults, and more frequently in those of advancing years. It is rather rare in children. It is observed quite often among the frequenters of lodging-houses and among the cachectic, poor, and uncared-for. Certain individuals are more prone to successful invasion than others. It is readily communicated by transference of either the parasites or their ova.

The **diagnosis** of pediculosis corporis in well-marked examples is comparatively easy, as the distribution of the excoriations and other lesions, as well as often the pigmentation and the usually intense itchiness, and the minute hemorrhagic puncta, are quite suggestive. Parallel linear scratch-marks are also, as a rule, significant. The distribution and absence of hand involvement are generally sufficient to prevent error with scabies (see the latter for other differential points). Careful search will almost invariably disclose one or more pediculi, unless the underwear had been changed just before examination, and in some instances ova can be found attached to the lanugo and other body hairs. In some cases there is a suggestion of urticaria, the wheals arising where the pediculi have inserted the haustellum, as well as sometimes elsewhere in consequence of the reflex irritation. The distribution, however, as well as the other characters mentioned, will generally suffice for the differentiation. In ordinary urticaria the hands and face frequently share in the eruption, parts not involved in pediculosis. The malady is not to be confused with simple pruritus (*q. v.*).

Treatment.—As the lice only go to the skin for the purpose of feeding, the main attention in the treatment of pediculosis corporis is to be directed to the infested wearing apparel and bed-linen, which should be thoroughly baked, boiled, or gone over with a very hot iron in order to destroy the pediculi and their ova. Inasmuch, however, as in some instances the ova are found attached to the lanugo body-hairs, a fact to which Jamieson[2] has directed notice, the surface, therefore, requires treatment also, otherwise a recurrence naturally soon shows itself. An occasional general tub-bath of corrosive sublimate (ʒij–iij (4.–12.) to the bath), if there are not many excoriations, will be destructive to the ova. The employment of a naphthol-sulphur soap in connection with the ordinary bath is also serviceable. Jamieson advises the use of a piece of roll sulphur, the size of a pigeon's egg, in a coarse muslin or canvas bag, and worn

[1] Jamieson, "On Some of the Rarer Effects of Pediculi," *Brit. Jour. Derm.*, 1889, p. 321.
[2] Jamieson, *ibid.*, 1895, p. 248.

next the skin day and night; the heat of the body causes gradual oxidation and the formation of sulphurous acid. This plan can, as Jamieson suggests, also be employed in those of the careless or tramp class, who cannot give proper attention to the apparel. In these instances, too, the use of an ointment of stavesacre, 2 drams (8.) to the ounce (32.), of sulphur, 30 to 60 grains (2.–4.) to the ounce (32.), or of β-naphthol, 20 to 60 grains (1.33–4.) to the ounce (32.), will serve a like purpose. These ointments, if in weaker strengths, also are of benefit to the papular and pustular lesions; but if the skin is decidedly eczematous, a weak carbolized zinc ointment or a saturated solution of boric acid, with 1 or 2 drams (4.–8.) of carbolic acid to the pint (500.), is to be preferred. Carbolic acid, like the other substances named, is likewise distasteful to the parasites.

PEDICULOSIS PUBIS.

Pediculosis pubis, or, as it is sometimes designated, "crab-lice," or "crabs," is due to the presence of the pediculus pubis or crab-louse, and is characterized in most instances by more or less itching about the genitalia, together with excoriations, papules, pustules, and other inflammatory symptoms. Cases vary very widely in the amount of irritation: it may be extremely slight and even wanting, more especially in females, and even when the parasites are present in great number; or, on the other hand, it may be sufficiently severe to exhibit a decidedly eczematous aspect. While the irritation and lesions are practically limited to the pubic region, in some instances the excoriations and other lesions are seen extending up on to the lower abdominal surface. As in the scalp variety, several or more ova can often be found glued to a single hair-shaft. The parasite may be discovered upon close examination seated near the root of the hair, clutching the hair, its head downward, and often slightly buried in the follicle. Sometimes, in association with the malady involving this region, and occasionally independently, the crab-louse is found upon other situations, as the hairy part of the breast, axillæ, the legs, beard, and even the eyebrows and the eyelashes, producing on these regions similar but variable irritation.

Involving the eyelashes (*phthiriasis seu pediculosis palpebrarum*)[1] the appearances are roughly suggestive of an eczema or blepharitis. The parasites, looking not unlike minute scabs, can be detected upon close inspection on the edge of the lid clinging to the hair, and often with the head somewhat hidden in the follicle. Ova attached to the eyelashes are quite easily to be seen. A noticeable feature, and one which first attracts one's attention, is the presence of the excrement —reddish or blackish specks—on and beneath the lower lids, resembling specks of iron rust.

There are lesions associated with pediculosis pubis known as

[1] Both de Schweinitz (*Univ. Med. Mag.*, Mch., 1889) and Jullien (*Annales*, 1891, p. 1006) describe cases and show that it was much more common on this region in ancient times, citing numerous descriptive accounts by older writers. Several instances, of which the first was reported (*Arch. Derm.*, 1881, p. 301), have come under my notice. Winfield (*Jour. Cutan. Dis.*, 1889, p. 331) reported 4 cases and also reviews the subject.

maculæ cæruleæ (*taches ombrées, taches bleuâtres,* of the French). They are pea- to finger-nail-sized, of a steel-gray tint, not elevated, with no thickening, and not disappearing upon pressure, consisting, in fact, simply of stains. They are seen most commonly or typically in those of clear white, transparent skins, usually, therefore, predominantly in blondes; and are found scantily or somewhat abundantly, chiefly on the sides of the thorax, abdomen, and inner aspects of the thighs and upper arms. Inasmuch as in the careful hunt for rose-spots in typhoid fever these lesions were occasionally observed, it was at one time thought they were peculiar to this malady, but it is now known that they are also found in association with other diseases, and also independently.[1] They are simply pathognomonic of the presence of the crab-louse.[2] The view held as to the spots being hyperemias or hemorrhages is not supported by their appearances or behavior. According to Duguet's successful inoculation experiments with the crushed crab-louse, they result from pigment introduced by the parasite in the act of feeding. There is, however, a certain predisposition necessary, as they are by no means observed in all those infested with the pediculus. Duguet was able to produce the lesion experimentally in all instances in those who already had them, but only occasionally in others. Both Jamieson and Payne[3] have noted in these cases a remarkable absence of the signs of scratching or any complaint of irritation.

Pediculosis pubis, as to be readily inferred, occurs chiefly in adults, although also seen in adolescents. Its contraction is generally believed to be through sexual intercourse, but this is by no means always so, for there are many other ways in which the parasite might gain access. In children the crab-louse seems to have as its special field the eyebrows and eyelashes.

The **diagnosis** of pediculosis pubis is to be based upon the region involved, itching, variable amount of irritation, papules, excoriations, etc., and, above all, by the presence of the pediculi and their ova. The former can be detected upon close inspection close to the skin, grasping a hair-shaft, with the head usually downward; the ova are easily found attached to the hairs. It is to be noted that lesions of irritation are quite frequently to be seen beyond the actual markedly hairy limits. The fact, too, that the pubic louse may not confine his presence or effects to the pubic region alone is to be borne in mind. The features of the condition elsewhere are, however, practically the same—if the possibility of such is remembered, a mistake can scarcely occur; the ova and pediculi are always to be discovered, whether in axillæ, on the short body hair regions, on eyelashes, or on eyebrows.

Treatment.—The classic treatment by blue ointment, while efficient, is nasty, and often excites a dermatitis or veritable eczema. The cleanest method is by means of corrosive sublimate lotion, $\frac{1}{2}$ to

[1] See Jamieson's paper (*loc. cit.*) and that by Leviseur, *Jour. Cutan. Dis.*, 1889, p. 414.

[2] The reader interested in the important earlier literature of these spots is referred to the papers by Moursou, "Nouvelles recherches sur l'origine des taches ombrées," *Annales*, vol. ix., 1877–78, p. 198, and Duguet, "Sur les taches bleues; leur production artificielle et leur valeur semeiologique," *Gaz. des hôpitaux*, April 20, 1880, and *Annales*, 1880, p. 544; and by Duguet and Gibier, "Les taches bleues et le phtirius," *Compt. rend. d. la soc. de biol.*, 1882, p. 617, an *Annales*, 1881, p. 357.

[3] Payne, *Brit. Jour. Derm.*, 1890, p. 209.

2 grains (0.033–0.133) to the ounce (32.). Fournier commends one consisting of 1 part of corrosive sublimate, 100 parts alcohol, and 400 parts water; and also one of 1 part of this drug to 300 parts of vinegar, to be applied diluted with one or two parts water. A 5 to 10 per cent. ammoniated mercury ointment or same strength β-naphthol ointment will also prove useful. Repeating washings with vinegar or dilute acetic acid or with alkaline lotions will free the hairs of the ova; a daily shampooing of the parts will accomplish the same purpose. In cases involving many of the body or leg hairs, baths of corrosive sublimate can be employed. Such cases do well with a daily washing with a naphthol-sulphur soap. In pediculosis palpebrarum the best and quickest plan is to remove the parasites and ova with small forceps. A weak citrine ointment can also be carefully applied to the edge of the lids.

OTHER ANIMAL PARASITES, OF MINOR IMPORTANCE, ATTACKING THE SKIN.

Cimex lectularius (acanthia lectularia, *Fr.*, punaise des lits; *Ger.*, Bettwanze), or, as commonly called, the **bed-bug,** is a well-known insect, universal in its distribution, which can produce a good deal of cutaneous mischief. It simply goes to the skin for nourishment, puncturing it and sucking blood; it is said to inject an irritating fluid to increase the flux of blood to this point. An inflammatory papule or wheal-like lesion most commonly results, having often a purpuric tendency, especially at and about the point of puncture. This purpuric or hemorrhagic point or spot remains after the swelling subsides, but finally, in the course of several days or a few weeks, disappears. Very frequently the insect makes several punctures at but short distance apart, so that the lesions are sometimes seen as an irregular group of three, four, or more, and are often covered over with a blood-crust. The legs, especially in the neighborhood of the ankles, are a favorite point of attack, probably because nearest the joints or crevices of the bed. The resulting irritation varies considerably in different individuals, in some *nil*, and in others extremely severe and lasting. The hemorrhagic, wheal-like papules may become pustular and show a good deal of underlying and surrounding inflammation. The condition is not to be confused with urticaria, to which it bears some suggestion, especially if the lesions are somewhat numerous and scattered. The hemorrhagic tendency, central puncture, and persistence of the bed-bug lesions are not seen in urticaria.

Treatment consists in the use of alkaline and carbolic acid lotions, with carbolized ointments if necessary. The various other lotions employed in urticaria are also serviceable.

Pulex irritans (*Fr.*, puce commune; *Ger.*, gemeiner Floh), or common **flea,** is of somewhat general distribution, but more common in some regions, especially in tropical climates; it is capable of exciting varying degrees of irritation. The most usual lesion is a small, ring-like, erythematous spot with a minute, central, hemorrhagic point, marking the place of attack. In exceptional instances the purpuric character has been sufficiently pronounced as to suggest purpura simplex. In some people the lesion is scarcely perceptible and gives rise to no discomfort. In others, who seem to be especially vulnerable to "flea-bites," the resulting lesion is urticarial in character, and more or less persistent, markedly itchy, tender, and painful, with sometimes a fiery, burning feeling. Several or more are frequently to be seen close together, or strung out, marking the travels of a single parasite. When the latter are present in any number, susceptible individuals may suffer somewhat intensely, and may even show some general disturbance. Many American travelers in Europe suffer considerably from this pest, the "foreign flea" seeming to be

especially damaging to the American skin, although such individuals are often unaware of the character of the trouble, believing it to be urticaria due to change of food, etc. The lesions in those of sensitive skin resemble those of the latter malady, but in the former the recent spots show the minute central hemorrhagic point.

In the treatment the various carbolized, thymol, and alkaline lotions employed in urticaria, pruritus, and eczema are of value in relieving the irritation, and their use makes the skin a less attractive feeding-ground for the parasites. In those especially vulnerable to these pests, particularly women, whose manner of dress permits easy access, the wearing of a lump of camphor inclosed in a cheese-cloth bag under the clothing will sometimes furnish variable protection; in extreme instances the wearing of several small, loosely woven bags containing pyrethrum powder, pinned on at different parts of the underwear, will often keep up an efficient atmosphere of protection against attacks.

The **ixodes** (*Fr.*, pou de bois; tique; *Ger.*, Holzbock; Zecke), or **wood-tick,** is a minute parasite which is sometimes parasitic on man, and of which there are several species. It is generally found on bushes or trees, and occasionally drops on an opportune subject to secure blood. In its attack it sticks its proboscis in the skin and sucks blood until several times its natural size, and then falls off; an urticarial lesion marks the site, sometimes more or less persistent, itchy, and painful. If the parasite is caught in the act of attack, it should not be forcibly extracted, as its proboscis may thus be broken off and remain in the skin, and give rise to considerable pain and inflammation. It may be made to relinquish its hold by placing on it a drop of an essential oil or moist tobacco. A thymol or carbolized boric acid lotion will relieve the irritation.

The **dermanyssus avium et gallinæ** (bird-mite; fowl-mite; chicken-louse; *Fr.*, dermanysse des oiseaux; *Ger.*, Vogelmilbe) occasionally attack the human integument and provoke a varying degree of erythematous and papular irritation, which is often added to by the scratching induced. The parasite is small, about the size of a grain of sand, grayish-white in color, with six three-jointed legs, no attennæ, but strong mandibles. They are quite a pest among fowls, and sometimes afflict those who care for them, chiefly attacking the hands and forearms. The treatment is that of similar conditions just described.

Other parasites which attack the human skin for nourishment are the **mosquito** (culex anxifer), **gnat** (culex pipiens), and certain kinds of **flies** and other insects, and give rise to erythematous and urticarial lesions, which vary considerably in different individuals, in some having but little effect, in others quite pronounced irritation. This may, and usually does, subside quickly, although exceptionally the lesions last one to several days. In addition to these insects are to be mentioned those which sometimes attack the skin to inflict injury or in self-defense, such as **bees, wasps, spiders, ants, caterpillars,** etc. With some of these, especially the bees and wasps, if the stings are numerous, the effects may be quite serious, in extreme instances death having resulted. The lesions vary, but are chiefly urticarial in appearance. Some species of spiders can also produce alarming consequences, a poisoned wound developing at the point of attack, and followed by systemic symptoms. For obvious reasons the exposed parts are those attacked, and this fact is of some value in the diagnosis. The central punctum in these lesions, together with the parts involved and history of exposure, are generally sufficient to prevent error.

Treatment is with the various applications already named. Spirits of camphor, weakened ammonia water, and menthol preparations are most efficient in relieving the sting. A 2 or 3 per cent. solution of menthol, oil of eucalyptus, or tar oil is variously used for protection where these parasites are numerous and troublesome. For wasp or bee stings common earth or clay made into a paste with water and applied is a well-known and efficient application.

SCABIES.

Synonyms.—Itch ; *Fr.*, Gale ; *Ger.*, Krätze.

Definition.—A contagious disease due to the invasion of the skin by the acarus scabiei, characterized by itching and lesions of a papular, vesicular, and pustular type, predominantly upon the fingers, hands, wrists, axillary folds, lower abdomen, and genital and anal regions.

Symptoms.—The first evidence of the disease is itchiness, caused by the presence of the itch-mite within the cutaneous tissue, at first being limited to the region where the parasites have gained access. On examination a few papules or vesicles may be discovered. The malady is one of steady progression, getting, unless held in check by daily washings, worse and worse as regards itching and the amount of eruption. As a rule, when the patient seeks advice, the affection has lasted for several weeks ; the itching is more or less general, but more pronounced on certain situations. Inspection discloses the presence of papules, vesicles, and often pustules, in scant or great number upon the hands, especially the fingers, the wrist, about the region of the elbow, at the axillæ, the lower abdomen, the genitalia, cleft of the nates, inside of the thighs, and frequently about the ankles and feet. The region of the nipple in women is also a favorite situation. Scattered excoriations are to be seen here and there. Other parts of the body in well-marked cases likewise show lesions, but they are always predominantly present on the situations just named. The head, except in infants and very young children, rarely shares in the eruption. In addition to these various lesions the **burrow**, or **cuniculus**, is usually to be found, the common situations for it being the interdigital spaces, the flexor surface of the wrist, about the mammæ in the female, and on the shaft and glans of the penis in the male. It consists of a tortuous, straight, or zigzag, dotted, slightly elevated, dark-gray or blackish, thread-like, linear formation, varying in length from $\frac{1}{8}$ to $\frac{1}{2}$ an inch ; at one end slightly more elevated, and appearing as a minute whitish or dark grayish dot is the contained female mite.

The eruptive phenomena may be quite pronounced, especially in the careless and uncleanly ; and in such there may be an abundance of variously sized blebs and pustules, in addition to vesicles, papules, excoriations, and burrows. The inflammatory lesions are also always most marked as regards development in those of irritable skin, and in such individuals the burrows, except evidences on the vesicle, pustule, or bleb-wall, are usually scanty in number and hard to find ; the reactive irritation of the tissue giving rise to a papule, vesicle, or bleb, the mite thus being so soon disturbed the burrow cannot be formed or is soon interfered with and uplifted. In some cases, if of long continuance and neglected, and particularly in those predisposed to true eczema, in addition to the multiform eruption of scabies, an eczematous aspect is presented, especially about the hands, forearms, and axillary folds. Impetiginous lesions and crusts are also often interspersed. Among the lepers in Norway and in others, from neglect

and long duration, more or less massive crusting and calloused formations are sometimes noted—*Norwegian itch.* In other instances, in those who are bathing daily, the eruption is always scanty, and generally consists of scarcely more than several or more insignificant papules or vesicles upon the various favorite regions, with, as a rule, burrows likewise sparse. The itching of scabies, as may be inferred from the common name, "the itch," is usually of an intense character. It is not so marked or violent during the day-time as when the patient gets in bed and the skin becomes thus warmed up, the parasites being apparently more active under such influence. In some cases there is but little, if any, suffering during the day. The degree of pruritus varies somewhat, too, in different cases.

The course of the disease, as already stated, is, as a rule, steadily progressive, but in many instances, owing to frequent baths or soap-and-water washings, the development is only of moderate character. In fact, in many patients as met with in our dispensaries, and in the majority in private practice, the malady never reaches the extent and severity of the cases so common in the European clinics. Nor with most of our patients are the hands ordinarily so predominantly involved as in those seen in the latter countries. In those of certain occupations, such as stone-cutters, brick-layers, polishers, pasters,

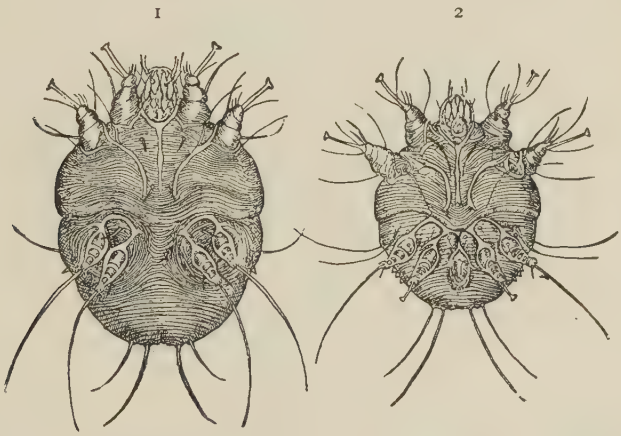

FIG. 255.—Acarus scabiei (ventral surface): 1, Female; 2, male (× 100) (courtesy of Dr. L. A. Duhring).

etc., the hands, from the character of the work and the frequent washing necessitated, are, as a rule, the seat of but sparsely scattered lesions. With private patients, many of whom as soon as they first notice itching begin to wash diligently and frequently, the eruption is almost always scanty, consisting of but a few lesions on wrists, axillary folds, lower abdomen, and penis, and possibly between the fingers.

Etiology and Pathology.—The disease is due to an animal parasite, the **acarus scabiei, sarcoptes scabiei,** sarcoptes hominis, belonging to the class arachnidæ, in the subdivision acarinæ, and family

sarcoptidæ.[1] It is contagious to a marked degree. It is most commonly contracted by sleeping with those affected, or by occupying a bed with unchanged linen in which an affected person has slept. It may, doubtless, be also contracted in many other ways, which will readily suggest themselves. Its contraction is possible, although not so probable, from the use of common towels and other toilet articles, tools, etc., and even from shaking hands. For obvious reasons it occurs usually among the poor, although it is occasionally met with among the better classes. It is seen at all ages and in both sexes. It is much more common in Europe and other countries than with us, but of late our dispensary and private practice records show a marked increase over former years.[2] It is not infrequent in our own country to see many cases among the foreign-born laborers, especially the Italians, Hungarians, and Poles, who, from the natural flocking together and intimate contact, are soon, as the result of the introduc-

FIG. 256.—Scabies, section of skin showing: *B,B,B*, Burrow; *C,C*, corneous layer; *R*, rete mucosum; *Cm*, corium (courtesy of Dr. M. B. Hartzell).

tion of one or two fellows with the disease, largely affected—hence the names sometimes heard, of "Italian itch," "Hungarian itch," "Polish itch." There are the same opportunities for its spread in closely quartered armies, hence the term, "army itch." Some of the

[1] Several other species of sarcoptes or acari which penetrate the skin, deposit eggs, etc., and form burrows, found affecting animals (*animal scabies*), as the horse, dog, sheep, pig, etc., are sometimes transferred to man, and give rise to an eruption similar to that already described. The human skin is, however, not a favorable habitat for them, and the malady rarely lasts more than several weeks or so. Treatment is the same as in ordinary scabies.

[2] See following papers bearing on this point: Greenough, *Boston Med. and Surg. Jour.*, Sept. 23, 1886; J. C. White, *ibid.*, Feb. 14, 1889; Stelwagon, *Med. News*, Sept. 23, 1893.

cases of so-called "prairie itch," "swamp itch," "lumberman's itch," etc., referred to under pruritus, are also examples of this disease.

The eruptive lesions are the result of the irritation produced by the presence and products of the parasite in the cutaneous tissue, reactionary inflammation invoked, papules and vesicles and blebs resulting. Purulent lesions are also produced, doubtless due to secondary inoculation of pus cocci. The constant scratching gives rise to favorable opportunities for integumentary coccus infection.

The female mite is the one which invades the integument, the male never being found in the cutaneous tissue, but in excavations in the skin, and apparently takes no direct part in the production of the symptoms. The general appearances and characters of both are shown in the annexed cuts. It is observed that the male is much smaller than the female; the latter is about $\frac{1}{70}$ of an inch long, and $\frac{1}{3}$ less in width. They have an oval body, the upper surface convex and transversely corrugated, with some spinous projections; the lower or ventral surface is flat, with four anterior and four posterior claws, the former being each provided with a sucker and several hairs, the latter with long bristles. There is a short, projecting head. The male differs from the female only in having suckers also in the two inner posterior claws; it is provided with rather conspicuous genital organs. The parasite does not invade the rete, as has been commonly believed, but, as both Török[1] and Schischa[2] have shown, as previously indicated by Riehl, it penetrates the corneous layer and traverses the middle or lower part of it. This is also well shown in the annexed cut (Hartzell). As the mite burrows it deposits ova, in variable number, finally perishing in the skin. The burrow or cuniculus contains therefore the female parasite, ova, and excrementitious matter; by snipping off this formation and placing under a magnifying-glass or microscope with low power, the mite, ova, and products can be readily seen. The mite can, if one is expert and has good sight, be caught in the blind end of the burrow, where it reposes as a grayish or grayish-black dot, by quickly transfixing it with a pin or needle. The ova gradually hatch out, and thus the malady is continued and its extent increased. It takes, on an average, about five or six days for the larva to develop from the egg, and about twelve to fourteen days more to reach full adult growth; at first the larva has only six legs.

Diagnosis.—But little difficulty need be experienced in the diagnosis of this disease if its characters are borne in mind: these are the distribution, the multiformity of the eruption (papules, vesicles, excoriations, and often blebs and pustules), the itching, usually marked at night when the patient warms up in bed, and quite frequently a history of contagion. The burrow, if carefully looked for between the fingers, in the palms, on the wrist, and on the penis, can usually be found, and when present is diagnostic. The peculiar distribution is likewise commonly sufficient to lead to a correct conclusion. The history of an itching malady, of progressive character, with eruptive

[1] Török, "Zur Anatomie der Scabies," *Monatshefte*, vol. viii., 1889, p. 360.

[2] Schischa, "Zur Anatomie der Scabies, nebst Beitrag zur Histologie der Hornschicht," *Archiv*, vol. liii., 1900, p. 313 (with 3 plates and 11 cuts; with review of the opinions of others).

evidences, such as described, between the fingers and other parts of the hand, on the wrist, about the elbow-joint, axillæ, lower abdomen, genitalia, buttocks, and in women also about the nipples, is always strongly suggestive, and generally conclusive. As the hands share in the eruption this factor, as well as the other distribution, will serve to differentiate it from pediculosis corporis. In this latter the irritation and consequent lesions are found upon covered parts only, especially those regions with which the clothing comes closely in contact, as around the neck, across the upper part of the back and shoulders, about the waist, and down the outside of the thighs—a distribution quite different from that in scabies. Moreover, in pediculosis the parasite can generally be easily found in the clothing, especially in or about the seam of the neck-band. Scabies bears some resemblance to eczema, but with care can usually be readily distinguished from it (see eczema for differentiation), as well as from other itchy diseases.[1]

Prognosis.—The disease is readily and usually promptly cured if the treatment is thoroughly and vigorously carried out. There is no tendency to spontaneous disappearance. As soon as the parasites and their ova are destroyed, the itching and the eczematoid or secondary eruptive lesions as a rule rapidly disappear. In those predisposed to true eczema this latter, which may have been created by the parasites and scratching, may occasionally tend to persist even after the scabies proper has been cured. Generally, however, such cases yield to continued soothing applications.

Treatment.—The treatment of scabies is purely external. There are three remedies which have a special reputation in promptly curing it. These are sulphur, balsam of Peru, and β-naphthol. The first is the one upon which chief reliance is placed, or at least that most frequently prescribed, although either of the others is likewise sufficient to destroy the parasites. Ointments containing two or all these ingredients are commonly found the most satisfactory. For children and those of delicate skin the following may be used:

℞.	Sulphur sublimat.,	
	Bals. Peruv.,	āā ʒij–vj (8.–24.);
	Adipis benzoinat.,	
	Petrolati,	āā q. s. ad ℥iv (128.).

In those of the average dispensary or hospital class, this same combination of full strength can also be satisfactorily employed, or one containing β-naphthol, as in the following:

℞.	Sulphur. sublimat.,	ʒiv–vj (16.–24.);
	Bals. Peruv.,	ʒiv (16.);
	β-naphthol,	ʒj–ij (4.–8.);
	Adipis benzoinat.,	
	Petrolati,	āā q. s. ad ℥iv (128.).

Before the ointment is applied the patient takes a hot bath, using

[1] Luck has reported (*Med. Record*, Aug. 5, 1899) a curious **mucor dermatosis,** with some resemblance to scabies, affecting chiefly the fingers, arms, and axillæ. The eruption was of itchy character, was made up of small elevations connected by channels running under the horny layer of the epidermis, and some small, dark-red pustules and crusted spots. Small filaments protruded from some of the pustules, which on examination were found to consist of fragments of mycelia of a species of mucor, probably the mucor corymbifer. Mercurial, chrysarobin, and ichthyol applications were unsuccessful, but a 3 per cent. ointment of menthol and salol proved curative.

plenty of soap, and if the skin is not oversensitive, sapo viridis. All parts should be thoroughly washed with a coarse wash-cloth, or in those of rather tough skin with a brush; in this way the horny layer is softened and the burrows and other lesions opened up for full action of the remedial application. The ointment is then rubbed in vigorously over the entire surface, below the chin line, rubbing in particularly well in those situations where the eruption is most marked. In infants and very young children in whom the face and possibly other parts of the head may share in the parasitic invasion, these places must also receive attention. The ointment is rubbed in night and morning for two to four days, the patient wearing the same underwear continuously. Ten or twelve hours after the last application the patient takes a bath, changes his underwear, and also the bed-linen. Thoroughly done, one such course will suffice. Itching usually lessens or wholly abates after the first application. Toward the last rubbing, slight itching may have again appeared, due to the irritation excited by the sulphur, but this quickly subsides as soon as treatment is discontinued. Not infrequently the eczematoid eruption provoked by the malady or by the sulphur applications requires soothing remedies, such as named under eczema. Sometimes the irritation excited by the sulphur is mistaken by the overzealous for a continuance of the scabies, and the irritating application still further, but unnecessarily, continued, the dermatitis or eczema thereby provoked being thus kept up.

In exceptional instances of tough skin and marked development of the malady the Helmerich ointment, as modified by Hardy, and in common use in Saint Louis Hospital in Paris, can be resorted to. It consists of 2 parts of sublimed sulphur, 1 part of potassium carbonate, and 12 parts of lard. It is preceded by a prolonged washing or bath with hot water and sapo viridis. Sulphur treatment is sometimes given in the form of a bath, using 3 to 6 ounces (96.–192.) of potassium sulphuret to 30 gallons of water, the patient soaking in this for from fifteen to thirty minutes, rubbing himself thoroughly with a coarse wash-cloth or a scrub-brush; one to three baths are usually necessary. The bath may also be made with liquor calcis sulphuratæ; or this, weakened or full strength, can be rubbed in the skin after an ordinary soap-and-water washing. Sherwell[1] strongly lauds a plan of treatment with sulphur used as a powder as being efficacious and much more cleanly than the ointment method, although somewhat slower. After a bath the powdered sulphur, in small quantity, is lightly rubbed in over the surface; a small quantity is also sprinkled between the bed-sheets. This is repeated every two or three nights, the bed-linen and underwear changed each time. Cure is effected, it is stated, in a week or ten days.

The balsam of Peru itself, as already remarked, is sufficient, and might be employed in those exceptional instances in which the skin is extremely sensitive or predisposed to eczema. It is a routine method in certain foreign centers, and has been warmly commended by Peters, Burckhardt, Nothnagel, Jullien and Descouleurs,[2] and

[1] Sherwell, *Jour. Cutan. Dis.*, 1899, p. 494.

[2] Jullien and Descouleurs, "Trois cents cas de gale traités par le baume du Pérou," *Annales*, 1896, p. 577.

others. Experimentally it has been shown to be much more rapidly fatal to the itch-mite than sulphur. It is brushed over the entire surface, and allowed to remain on over night; in extreme examples somewhat longer, and, if necessary, a fresh application made.

An important point in the management of scabies is the care of the clothing, otherwise the patient is reinfected over and over again. The underwear, as well as the bed-linen, should be boiled, or, if the former is woolen, in order to avoid shrinking, a thorough baking can be given instead. The outer clothing and any other wearing apparel that has had a chance at harboring the parasites must also be baked or ironed with a very hot iron. Moreover, as there are often several members of a family affected before the nature of the malady has been ascertained, it is a matter of course that all should receive attention, otherwise the disease, through constant reinfection, may continue in such a household indefinitely.

OTHER ANIMAL PARASITES, OF MINOR IMPORTANCE, PENETRATING THE SKIN.

Leptus (harvest bug; mower's mite; *Fr.*, Rouget; *Ger.*, Erntemilbe), of which several varieties (leptus autumnalis, leptus Americanus, leptus irritans), with but slight minor differences, are encountered, is a minute, barely macroscopically visible parasite, elongate, pyriform, or ovalish in shape, of an orange-red or brick-red color, and with six long legs. It is found in summer in harvest-fields, in grass, bushes, in swampy regions, and along the river-banks. It buries itself partly or more or less completely in the skin, and gives rise to a good deal of irritation, which may be of an erythematous, urticarial, papular, vesicular, or pustular aspect, and when several or more are close together, may present an eczematous appearance. The lower extremities, especially about the ankles and feet, are the favorite parts, although other regions, such as the hands and arms, are sometimes invaded. One variety (leptus Americanus), according to Duhring, is found in the axillæ and scalp, as well as other parts of the body, and more frequently in children.

Treatment consists in the application of weak ointments of sulphur, balsam of Peru, and other parasiticides. A carbolized boric acid lotion is also useful.

Pulex penetrans (rhinochoprion; chigoe; chigger; jigger; sand-flea; *Fr.*, puce de sable; chique; *Ger.*, Sandfloh) is an almost microscopic parasite, especially of warm and tropical climates, which in its general features resembles the common flea, except that it is furnished with a long proboscis. The impregnated female, which alone is the invader, penetrates and burrows into the skin, producing an inflammatory swelling, vesicle, pustule, abscess, or even ulceration. The feet, especially the toes, are the favorite sites of attack, particularly alongside or just under the nail. Other parts are sometimes invaded, as the knee, scrotum, back, etc. The parasite sometimes gives rise to considerable disturbance, with adenitis.

Treatment consists in the removal of the parasite and applications to relieve the irritation. The former is accomplished by careful extraction, usually with a blunt needle, and the latter by means of carbolized boric acid or alkaline lotions. If the more severe conditions are provoked, these are treated upon general principles. Essential oils are commonly used as a protection against the parasites.

Dracunculus[1] (dracunculus medinensis; guinea-worm; guinea-worm disease; dracontiasis; filaria medinensis; *Fr.*, ver de Guinée; dragonneau; filaire

[1] Some important general literature: Horton, *Guinea-worm or Dracunculus*, London, 1868; Leuckart, *Die Menschlichen Parasiten*, 1876, vol. ii.; Manson, "On the Guinea Worm," *Brit. Med. Jour.*, 1895, ii., p. 1350; Dubreuilh and Beille, "La filaire de Médine," *Arch. clinique de Bordeaux*, 1897, p. 425 (with résumé and references).

de Médine; *Ger.*, Peitschenwurm; Medinawurm).—This parasitic nematode worm is found in tropical countries, especially in upper Egypt, Persia, India, west coast of Africa, Senega, Guinea, etc. When matured, the female, which is the invader, attains from one to several feet in length, averaging about 25 inches, and is about $\frac{1}{15}$ to $\frac{1}{10}$ inch in thickness, being somewhat flattened. It has a slightly convex head and a curved and pointed tail, and is of a milky color. It was formerly thought that it gained entrance in various ways, but it is now known (Fedschenko, Stambolski, Forbes) that the embryos which enter the water gain access to a minute crustacean (cyclops) and undergo larval development, the crustaceans finding their way to man through the drinking-water. The larvæ escape, develop, and the female begins to migrate into the tissues, where it remains, giving rise to no trouble until fully developed. Its migrations may then continue for some months, and even after its appearance near the surface is noted may sometimes continue its travels before it finally seeks exit. At the point where it appears it may present a cord-like appearance under the skin, and in other instances it can be felt as a worm or cord-like mass. Usually, however, the first sign is a local inflammation, developing into a vesicopustular, nodular, or boil-like formation, attended with more or less pain and swelling. This breaks, and at the bottom of the cavity the head of the worm is seen. Through this opening the worm may, with its contained young, gradually be extruded; or it may, if disturbed, or voluntarily, be withdrawn, the opening close up, and a new formation appear elsewhere, usually near by, where it again attempts to find exit. The rupture of the worm, the escape of the embryos into the tissues, and the severance of the head in attempts to dislodge the parasite, leaving the worm in the tissues, are variously stated to be fraught with some danger, such as the development of lymphangitis, gangrene, septicemic symptoms, and death. Sometimes the parasite is destroyed by the suppurative inflammation which may be excited, and with possible untoward consequences. The part at which the worm is commonly seen is the foot, not infrequently on the thigh, occasionally on the hands and elsewhere. In most instances there is but one worm, although two are sometimes present, and exceptionally they may exist in numbers.

In regions where the malady is endemic the appearance of a local inflammatory, boil-like swelling might be suggestive, but no positive *diagnosis* can be made until the worm can be felt or seen.

Treatment practised by the natives in endemic regions consists in securing the protruding head part, and gradually, day by day, winding the worm with gentle traction around some substance until it is all withdrawn, ceasing traction each time that the parasite makes opposition. Perrin[1] states that plunging the part into cold water hastens this process, the parasite temporarily relaxing its hold. This method is, however, unscientific, slow, not without danger, and takes many days. According to Forbes, if the worm is let alone it emerges spontaneously in from fifteen to twenty days from her first appearance. The plan which promises well is that by Émily,[2] of injecting into the forming tumor a solution of corrosive sublimate (1 : 1000); if the head has already protruded, he injects the solution into the body of the worm. This method has since been successfully used by Davoren,[3] Blin,[4] Manson and Boyd.[5] As Manson succinctly states, a "dead aseptic guinea-worm does not act as an irritant to the tissues, and it can be got rid of by absorption like any aseptic animal ligature." The method advocated by Horton has been effective, consisting of the administration of moderate to large doses of asafetida. Tilbury Fox and others also reported success with this plan, the parasite, which the remedy seems to destroy, either being gradually discharged or remaining in the tissues, becoming encysted or slowly absorbed. Forbes states that sulphur internally is likewise efficient.

[1] Perrin, *Annales*, 1896, p. 1315.
[2] Émily, *Arch. de méd. navale*, 1894, No. 6, vol. lxi., p. 460.
[3] Davoren, *Brit. Med. Jour.*, Oct. 17, 1894.
[4] Blin, *Arch. de méd. navale*, Nov., 1895, No. 5, vol. lxiv., p. 368.
[5] Manson and Boyd, *Brit. Jour. Derm.*, 1896, p. 37.

Cysticercus Cellulosæ.—Our first knowledge of the presence of the cysticercus of tænia solium in the subcutaneous tissues we owe to Rokitansky.[1] According to Küchenmeister and Zurn, the proportion of integumental infection compared to that of other organs is about 5 per cent., which Geber[2] considers a rather low estimate. The malady is most frequently encountered in North Germany, where raw or half-cooked pork is a favorite article of diet. The tumor caused by its presence is situated under rather than in the skin, and varies in size from a large pea to that of a walnut, the larger formation dependent upon the reactive inflammation excited. There may be several or many. They are ordinarily not sensitive to pressure unless from reactionary inflammation, although at times they may be spontaneously painful. The integumental covering rarely shows any change. In shape they are rounded or ovalish, smooth and elastic, or even firm and hard, and, as a rule, more or less movable. After reaching a variable size they may remain stationary somewhat indefinitely, although after death of the parasite they become smaller

FIG. 257.—Demodex folliculorum (ventral surface; × 300) (after Simon).

and exhibit a tendency to calcification. The trunk is a favorite locality, likewise the extremities, and occasionally they are seen on other parts.[3]

Their chief interest lies in the *diagnosis*, as the tumors bear some resemblance to other growths, and, in fact, a positive conclusion is, as a rule, possible only by microscopic examination, which reveals the presence of the cysticerci. Examination of the contents, obtained by puncturing, usually suffices, as the hooklets are easily found in the discharge.

Demodex folliculorum (acarus folliculorum; steatozoon folliculorum; entozoon folliculorum; *Fr.*, acare des follicules; *Ger.*, Haarbalgmilbe) is a minute, microscopic parasite, found in the sebaceous glands and hair-follicles, the first knowledge of which we owe to Henle (1841) and Simon (1842). It has most commonly an elongated, worm-like form, made up of a head, thorax, and long abdomen, with eight short stout legs coming off from the thorax; the larva has but six legs. The parasite varies in length considerably, some being much shorter. It is present most abundantly in the sebaceous glands and hair-follicles of the nose, forehead, and cheeks, and is easily found in the pressed-out sebaceous matter. It seldom occurs in infants (Duhring) nor in all adults, but is most frequently to be seen in greatest numbers in those of thick, greasy skin.

It has been thought to be harmless, but recently De Amicis,[4] Majocchi[5] (2 cases), and Dubreuilh[6] have reported instances of pigmentation involving parts of the face due to its presence, the pigmentation being of a fawn or brownish tint, similar to that of tinea versicolor. In Dubreuilh's patient the neck also was the seat of the discoloration, and some spots were found on the breast. The chin and lip regions are apparently favorite situations. There

[1] G. Lewin, "Ueber Cysticercus cellulosæ in der Haut des Menschen," *Archiv*, 1894, vol. xxvi., pp. 70 and 217 (gives complete exposition with review of the literature and references).

[2] Geber, *Ziemssen's Handbook of Skin Diseases*, p. 549.

[3] Pye-Smith, *Brit. Jour. Derm.*, 1892, p. 366, had a case under observation with more than 50 tumors scattered over face, neck, trunk, and limbs; they were quite painless; their true nature was not suspected until the microscope cleared the matter up.

[4] De Amicis, "Demodex folliculorum e ipecromia cutanea," *Giorn. ital.*, 1898, p. 205—brief abs. in *Brit. Jour. Derm.*, 1899, p. 42.

[5] Majocchi, *ibid.*

[6] Dubreuilh, "Pigmentation cutanée causée par le demodex folliculorum," *Jour. de méd. de Bordeaux*, No. 4, Jan. 27, 1901.

was slight, but scarcely perceptible, follicular prominence, due to minute corneous projections from the orifices, associated with, in one or two instances, trifling scurfiness. Dubreuilh noted that the pigmentation started and was most pronounced about the follicular outlet. The clinical appearances suggested tinea versicolor to these observers, but upon microscopic examination the fungus of this disease was not found, but the demodex was discovered in numbers, and this was noticeable only in the pigmented parts. It is well known, of course, that other or allied varieties of this parasite are found in some of the lower animals, and in which it may be productive of considerable mischief.

The *treatment* in De Amicis's case, which was successful, was by washings with soft soap. Dubreuilh tried a stimulating parasiticide application, but without any resulting benefit.

Œstrus (Gad-fly ; Bot-fly).—The larvæ of both the families of the muscidæ and œstridæ[1] are occasionally found invading the human skin, although there is none peculiar to man. Such invasion, especially by the latter, is not uncommon in Central and South America, and is also met with exceptionally elsewhere. The ova of the former are deposited usually in open wounds and ulcers, sometimes creating serious trouble, and naturally come more under the surgeon's observation. The ova of the œstridæ are deposited in the skin in the puncture made by the insect, most frequently on exposed parts, the larvæ developing and giving rise to furuncle-like tumors. These formations generally have a central aperture through which a sanious, seropurulent, or sanguinopurulent fluid exudes. In some instances, as the result of burrowing of the worm, irregular lines resembling inflamed lymphatics, of a purplish or purplish-red color, are produced. In rare cases considerable surface may be traversed by the larva before final suppurative action is excited, an abscess-like tumor formed, and the worm can be pressed out or extracted.[2]

The *treatment* of the formation produced by the œstreus consists in the removal of the parasite by free excision and pressure, and application of antiseptics to the lesion and wound thus made. In the more conspicuous serpiginous cases the larva can sometimes be secured by excision of an area around or just beyond the advancing part.

Creeping eruption (Lee),[3] also named larva migrans (Crocker), hyponomo-

[1] See exhaustive paper by G. Joseph, "Ueber Myiasis externa dermatosa," *Monatshefte*, 1887, pp. 49, 106, and 158, with review of the whole subject and literature references. Joseph places the cutaneous malady variously produced by the different species under the above name, subdividing the cases into two classes: those due to the family muscidæ, *myiasis dermatosa muscosa*, and those due to the œstridæ, *myiasis dermatosa œstrosa;* also that by Strauch, "Myiasis Dermatosa," *Jour. Cutan. Dis.*, 1906, p. 524, (with some references).

[2] McCalman, *Brit. Med. Jour.*, 1879, ii., p. 92, and *Arch. Derm.*, 1880, p. 174; W. G. Smith, *Trans. Internat. Cong.*, London, 1881, vol. iii., p. 181, and abs. in *Arch. Derm.*, 1882, p. 45; and Walker, *Brit. Med. Jour.*, 1870, i., p. 151, report interesting examples.

[3] Lee, "Creeping Eruption," *London Clin. Soc'y Trans.*, vol. viii., 1874, p. 44, and *ibid.*, vol. xvii., 1884, p. 74; Crocker, "Larva migrans," *Diseases of the Skin*, second edit., p. 926; Neumann, "Ueber eine neue Hautaffection," *Verhandl. des V. Cong. d. Deutschen dermat. Gesellsch.*, 1895 (1896), p. 95; Sokolow, "Ueber eine Würmchen, welches in der epidermoidalen Schichte der menschlichen Haut Gänge bildet"—abs. in *Archiv*, vol. xxxviii., 1897, p. 153; Samson-Himmelstjerna, "Ein Hautmaulwurf," *ibid.*, vol. xli., 1897, p. 367; Kumberg, "Ein Fall von Dermatomycosis linearis migrans œstrosa"—abs. in *Dermatolog. Centralbl.*, vol. i., 1897–98, p. 283; Kaposi, *Wiener klin. Wochenschr.*, 1898, p. 399 (case demonstration). Van Harlingen, "Report of Three Cases of Creeping Larvæ in the Human Skin" (Hyponomoderma, Kaposi), *Amer. Jour. Med. Sci.*, September, 1902; Stelwagon, "A Case of Creeping Eruption," *Trans. Section of Cutaneous Medicine and Surgery of the A. M. A.* for 1903, and *Jour. Cutan. Dis.*, 1903, p. 502; "A Second Case of Creeping Eruption," *Jour. Cutan. Dis.*, 1904, pp. 359, 381 (each with illustration); Hamburger, "Creeping Eruption: Its Relations to Myiasis," *Jour. Cutan. Dis.*, 1904, p. 217; Shelmire, "Creeping Eruption; Report of a Case," *ibid.*, June, 1905 (on a finger of a physician); Hutchins, *ibid.*, 1906, p. 270 (2 cases; successful treatment by injection of a drop or two of chloroform); Moorhead, *Texas Med. News*, February, 1906 (cure in 5 cases by freezing the advancing end with ethyl chlorid).

derma (Kaposi), and dermamyiasis linearis migrans œstrosa (Kumberg), is a curious malady, first described by Lee, Crocker, and subsequently by others, and has the peculiar feature of traversing the surface, as the name signifies. The burrow made by the parasite is $\frac{1}{8}$ to $\frac{1}{6}$ of an inch in diameter, and, at least in its extending part, just perceptibly raised, and of a pale rose-pink or reddish color. In the part less recently traversed the line is sometimes a thin, elevated, more or less continuous, broken or bead-like linear vesicle (as in the appended illustration); this in the still older part dries into a thin crust. Sometimes the whole line is merely a slightly raised erythematous thread-like formation, most pronounced at its extending part, and fading away at the older traversed part. The parasite travels at the rate of a fraction of an inch to several inches daily. It may take a tortuous, irregular, or erratic course, and even traverse a great part of the body. Exceptionally, there is more than one parasite present (rarely more than two), as in one of my cases, giving rise to a similar corresponding extending burrow. The formation is due to a minute migrating larva, which

FIG. 258.—Creeping eruption (larva migrans) in a youth aged eleven; there was also an active extending burrow on the back.

Sokolow and Samson-Himmelstjerna claim to have found. According to the latter it is more readily detected by pressing the blood out of the part by means of a flat piece of glass, through which, with the aid of a magnifying lens, the parasite can be seen as a black speck. In one of my cases I was able to corroborate this, but I did not succeed in getting possession of the parasite.

This malady is met with most commonly in Southern Russia; it is rare with us, but during the last several years cases have been recorded, in the order named, by Van Harlingen, myself, Hamburger, and Shelmire. In almost all cases the starting-point of the lesion is on those parts most exposed to inoculation and invasion—hands or lower part of the forearm, the feet or lower part of the leg, and the buttocks or adjacent part of the back. In all of my 4 cases, and also in some instances reported by others, the malady began at or after a

visit to the sea or seashore. According to Sokolow, the parasite, resembling the larva of a fly, is 1 mm. in length, with ten segments, and hooklets, with, at the head-end apparently, two suckers; he considered it the larva of a botfly, or œstreus, of the genus gastrophilus, probably of the species hæmorrhoidal. It was also stated by this observer that black nits could be found adherent to the hairs in the neighborhood of the burrow.

Treatment usually advised consisted in excising or cauterizing an area around or just beyond the advancing part. In my cases I applied catophoretically a solution of mercuric chlorid 2 grains to the ounce (0.13 : 32.) to an inch-and-a-half area around the advancing end of the burrow, and applied a minute quantity of nitric acid to the suspected site of the parasite, just beyond the extreme end of the line; a magnifying glass should be employed to discover this point, as it is slightly in advance of where it appears to be by unaided vision. These cases were all cured within a week by this method, the catophoretic application being repeated two to four times. In the next case I should be disposed to try a sharp application of the high-frequency current with the flat-vacuum electrode, held ⅛ inch from the skin, to the whole suspected area.

Craw-craw is a malady observed chiefly on the west coast of Africa, having to some extent the aspects of scabies, which is caused by nematodes, according to Nielly,[1] a species of the genus leptodera and family anguillulidæ, and in Corre's and O'Neill's[2] opinion to a kind of filaria. The fingers and forearms are always predominantly, and sometimes exclusively, affected. The eruption, as to be inferred from its resemblance to scabies, consists of papules, vesicles, and pustules, discrete or crowded, and frequently with considerable crusting, and is exceedingly itchy. There are no cuniculi, however, as in scabies, nor the samé peculiar distribution. The parasites in craw-craw can be found in the scrapings and in the seropurulent liquid.

The disease is rebellious to treatment, consisting of thorough cleanliness, baths, removal of the crusts, and sometimes the curetting-out of the underlying soft tissue, together with the use of parasiticides.

The **echinococcus** larva, while usually found affecting the internal organs, exceptionally gives rise (echinococcus cutis) to a softish, fluctuating, semitranslucent, projecting tumor, somewhat larger than those of the cysticercus. It is seated in the subcutaneous tissue, and has been found more frequently in women. The covering integument is unchanged. Encapsulation of the parasite takes place; it perishes in one or two years, the tumor undergoing calcification. There are no subjective symptoms except a sensation of tension and heaviness. According to Geber, the semitranslucent character of the tumor, its superficial seat, and projection without alteration of the skin, and the fluctuation are the features of diagnostic value; supplemented by exploratory incision and finding the hooklets of the parasite. Treatment consists of extirpation.

The **distoma hepaticum,** or liver-fluke, has, according to Küchenmeister, been found in the subcutaneous tissues of human beings in three instances, —one woman and two men,—giving rise to a tumor-like formation. In one the site was the region of the ear, another the lower extremities, and the third the trunk. The subjective symptoms varied, being practically *nil*, in one instance painful, suggestive of the pain of a developing abscess. Diagnosis was possible only by finding the distoma.

Ground itch[3] or **uncinarial dermatitis,** observed in certain tropical

[1] Nielly, *Bull. de l'acad. de méd. de Paris*, 1882, p. 395.

[2] O'Neill, *Lancet*, 1875, i., p. 265.

[3] Recent literature of Ground itch: Stiles, "The Significance of the Hookworm Disease for the Texas Practitioner," *Trans. State Med. Assoc. of Texas*, 1903, p. 353 (an excellent, clear, and complete exposition and review); C. A. Smith, "Remarks on the Mode of Infection in Uncinariasis," *Jour. Amer. Med. Assoc.*, 1905, vol. xlv., p. 1142 and *ibid.*, 1906, vol. xlvii., p. 1693; Leonard, "Ankylostomiasis or Uncinariasis," *Jour. Amer. Med. Assoc.*, 1905, vol. xlv., p. 588; Dubreuilh, "L'Ankylostomiase Cutanée," *La Presse Méd.*, Apr. 15, 1905; Ashford, "The Problem of Epidemic Uncinariasis in Porto Rico," *Jour. Assoc. of Military Surgeons*, Jan. 1907, p. 40. These various papers refer to the observations of Looss, Sandwith, Bently, and others.

countries (also called water-itch, water-pox, water-sores, sore feet of coolies, panighao; and in Porto Rico, also, "mazamorro"), consists primarily of an erythematous or an erythemato-papular and papulo-vesicular eruption of the feet due to the irritation of these parts by the larvæ of the hookworm. Uncinariasis, ankylostomiasis, or hookworm disease (also known as dochmiasis, tropical chlorosis), is, as known, a serious, and when untreated, often fatal, constitutional malady characterized by depression of the vital forces, profound anemia and inertia. It is due to the intestinal parasite (probably of several varieties) known variously as uncinaria duodenalis, ankylostoma duodenalis, dochmius duodenalis, uncinaria americana, necator americanus, and belonging to the nematode family Strongylidæ (Stiles). It was formerly thought that the larvæ of the uncinaria found entrance by the mouth in food or water, but it is now known, through the observations and experiments of Looss, Schaudinn, Sandwith and Smith, and others that a common mode of entrance is by way of the skin of the lower extremities in those going barefooted in moist or wet, muddy and sandy soil, the eggs of the parasites finding their way here in the alvine discharges from affected persons. The cutaneous disturbance begins commonly as reddish spots or macules which soon show papulation or vesicles; the latter may coalesce and form small and large blebs, which rupture and expose raw, oozing surface, and often with considerable underlying swelling of the parts. In some instances there is a tendency to pustulation, and even sometimes to the development of ulceration. The eruption, which is usually intensely itchy, is frequently first observed between the toes. It may be limited to a part of one foot or may involve both extensively; the toes and lateral parts are the favorite localities. With good management the cutaneous disturbance subsides in a few weeks, but in those cases in which scratching and secondary coccic infection occur, the eruption lasts much longer and may extend somewhat beyond its usual regional limit, and occasionally lead to obstinate ulcerations, and exceptionally to gangrene. It is not uncommon for a person to have several attacks, each due to exposure to a fresh invasion of the larvæ.

The *treatment* consists in cleanliness, the use of mild antiseptic lotions and ointments such as are used in the acute types of eczema and other types of acute dermatitis; the opening of vesicles, blebs, and pustules, and their cleansing and disinfection. Long soaking of the parts in antiseptic solution, such as boric acid solution and weak corrosive sublimate lotions is commended. The avoidance of going barefooted in the warm, rainy season is a positive preventive measure. It is thought by some observers that in some of the cases of so-called ground itch the malady may be due to bacterial infection other than that of the hookworm larvæ.

SUPPLEMENTARY SECTION

FOR PRESENTATION OF A FEW DISEASES OF THE ADJOINING MUCOUS MEMBRANES NOT ELSEWHERE CONSIDERED.

THE mucous membranes in proximity to and adjoining the skin are quite frequently the subject of diseases corresponding to, and existing conjointly with, those of the latter. These have, to a great extent, been already referred to in connection with the individual cutaneous maladies, such as eczema, lichen planus, pemphigus, erythema multiforme, lupus vulgaris, syphilis, and others. It is the purpose to describe here briefly several other affections of the tongue, vermilion of the lips, and contiguous mucous membrane which come from time to time under dermatologic inspection. For other diseases of the tongue and oral cavity the reader is referred to special works on the subject.[1]

LEUKOPLAKIA.

Synonyms.—Leukoplakia buccalis; Leukokeratosis buccalis; Leukoma; Leukoplasia; Ichthyosis linguæ; Tylosis linguæ; Psoriasis of the tongue;

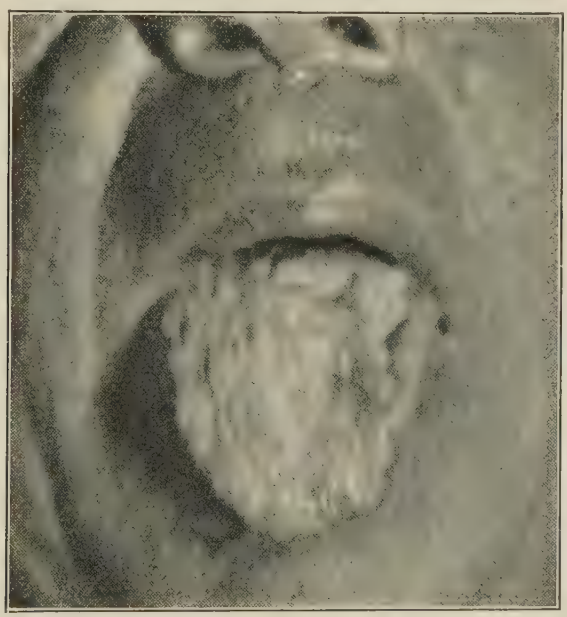

FIG. 259.—Leukoplakia, of slight development, chiefly short streaks and small spots, in a man aged fifty, of several years' duration; also a pale, somewhat diffused, milky color of the main portion of the tongue, and some furrowing; contracted syphilis when aged thirty-five, but has had no manifestations for years.

Smokers' patches; Chronic superficial glossitis; *Fr.*, Leucoplasie; Plaques opalines; Plaques blanches des fumeurs; Plaques blanches de la bouche.

Definition.—A disease of the mucous membrane of the buccal cavity,

[1] See the admirable and largely illustrated monographs by Butlin and Spencer, *Diseases of the Tongue*, 1900, Cassell and Company; and Mikulicz and Kümmel, *Die Krankheiten des Mundes*, Jena, 1898.

commonly of the tongue, characterized by one, several, or more rounded, irregularly shaped or diffused, whitish patches, often more or less thickened, with sometimes a tendency to fissure. Although this not infrequent malady was occasionally alluded to in older writings, Bazin (1866) and his pupil Debove were the first to give a clear description, followed by the classic presentation by Schwimmer,[1] Vidal,[2] Leloir,[3] Besnier and Doyon.[4] These and other contributions have firmly established the individuality of the affection, and demonstrated that it is not necessarily a manifestation of psoriasis or a symptom or consequence of syphilis, but that it may often arise and exist independently of these and other maladies.

Symptoms.—The earliest evidence of a leukoplakia patch is a slightly increased redness, sometimes with a bluish tinge, which is often so trifling as to be recognizable only on close inspection. Sometimes it has a somewhat thinned or abraded look. Occasionally there is also a scarcely perceptible accentuation of the papillæ, peripherally as well as less commonly on the surface of the spot

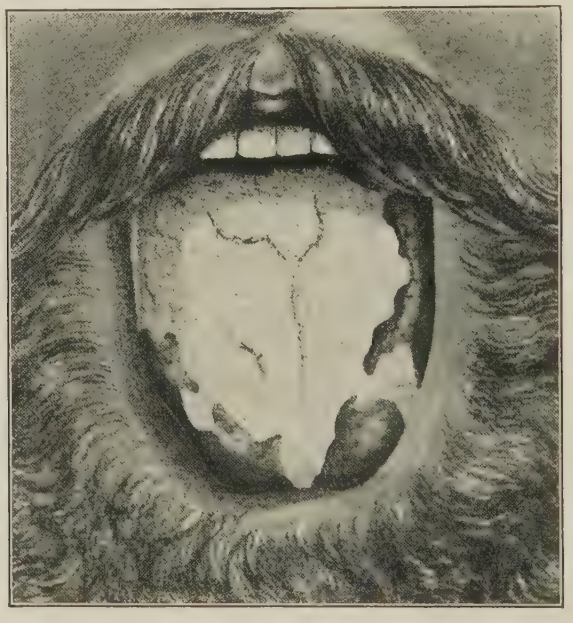

FIG. 260.—Leukoplakia of extensive development, in a man aged forty-five, and of eight years' duration; has been subject of psoriasis for twelve years; never had syphilis (Schwimmer).

itself. At this time there is often some sensitiveness to hot and acid foods. This stage of the malady, which lasts a variable time of weeks or months, frequently escapes observation, the first sign recognized being the white or opaline spot into which it slowly evolves. This consists of a rounded, ovalish, or irregularly shaped patch of a faint pearly, bluish-white, or pale milk color, usually on a level with the surrounding surface, from which it is sometimes bounded by a narrow line of hyperemia. Instead of a well-defined area, it quite often first presents as one, several, or more short or long, straight or

[1] Schwimmer, *Archiv*, 1877, p. 511 (with review of the subject, references, and 4 colored case illustrations).

[2] Vidal, *Union méd.*, vol. xxxv., 1883, pp. 1 and 37.

[3] Leloir, *Arch. de Physiolog.*, vol. x., 1887, p. 86 (with 6 colored histologic illustrations).

[4] Besnier and Doyon's French translation of Kaposi's treatise.

crooked, pale white lines, which may be close together and more or less parallel, of the same or different lengths; or instead of lines there may be scattered or grouped pin-head- to small pea-sized white spots. Contiguous lines, points, or spots may gradually coalesce and form larger areas. There may also be slight papillary hypertrophy. This stage of the malady may continue for some time or almost indefinitely, generally with a tendency to trifling thickening of the affected membrane. There may be a tendency to trifling exfoliation. It is not uncommon, moreover, to find the affected surface, as well as other parts of the tongue, traversed to a variable degree with superficial or deep transverse and longitudinal grooves. These are the so-called "smoker's patches," although this term is likewise applied to the more advanced types also. The extent involved may be small, but one or several patches being seen, or a greater part of the tongue, or of the inside of the cheeks or other parts of the oral cavity, may be involved. In advancing cases the symptoms become, in the course of months or several years, slowly more pronounced, the submucosa variably, often considerably, thickened, the surface rough, rugous, and desquamating, with often a tendency to superficial cracks through the dry, hardened white epithelial coating. The affected area is stiff and less elastic than the unaffected parts. New spots usually present after variable periods, going through the various phases already outlined. In many instances after a certain stage or extent is reached the malady continues at a stand, or progresses so slowly that practically but little change is noted from month to month or even year to year. The cornified, somewhat firmly adherent epithelium is rough, exfoliates, usually in small fragments, from time to time; it can be partly removed only with great difficulty. In other cases the plaques spread, become much thicker, rougher, and even nodular, with short or long cracks, extending more or less deeply, and in places amounting almost to superficial ulceration, giving rise sometimes to considerable pain and discomfort. Slight bleeding may occur now and then. The disease may occupy considerable surface. In still less favorable instances the deep fissures change to ulcerations, show considerable infiltration, and gradually, sometimes rapidly, develop into epithelioma, which in the graver cases sooner or later passes rapidly into a malignant type, with fatal termination As in the earlier stages, there is in most instances in the well-developed malady sensitiveness to hot and irritating substances. The region most commonly the seat of leukoplakia is the tongue, especially the dorsal surface, anteriorly and laterally, but it may occur on any or all sections of this organ, and involve a portion or the greater part of it. The inside of the cheek is another favorite, but less frequent, situation, and the inner aspect of the lips, and even the vermilion border, especially at the commissures, may likewise be occasionally its site. Other mucous surfaces, as of the vulva, and even the glans penis (Dentu, Perrin),[1] are exceptionally the seat of similar formation.

FIG. 261.—Leukoplakia, with development of epitheliomatous changes; patient aged sixty five.

Etiology and Pathology.—The causes of leukoplakia are not clearly established. It is infrequent in women, and is with some exceptions a development

[1] Dentu, Perrin, cited by Shoemaker (Leukoplakia), *New York Med. Jour.*, vol. lxxiv., 1901, p. 958.

of middle life. Syphilis has always been considered of etiologic import, but it occurs frequently enough in non-syphilitics to call this in question. Most of one's patients with leukoplakia, it is true, have had syphilis, but such subjects naturally suspect any manifestations, and immediately seek advice, while those free from guilt in this direction are much less solicitous. Both Debove and Schwimmer met with instances of the disease in those who subsequently acquired syphilis. It is not improbable the mercurial treatment of syphilis may, by its invoking a mild, and though often scarcely perceptible, stomatitis, be a factor of some influence. There is no doubt about the aggravating influence of smoking, and so evident is this that this practice has been considered etiologic. While its damaging, and probably, under some circumstances, its causative, action cannot be denied, yet the fact remains that the malady is also seen in those not addicted to this habit. It has often been looked upon as a

FIG. 262.—Leukoplakia, showing keratosis of the superficial layers of epithelium, and marked inflammatory changes in the subepithelial tissues (courtesy of Dr. J. A. Fordyce).

psoriasis, and is sometimes seen associated with this malady, but it is also seen in association with similar scaly and other skin eruptions, attended with increased cornification; Schütz[1] observed leukoplakia in 2 cases of tylosis and in 5 of scaly eczema. Whatever may be the essential initiative cause, there is no difference of opinion as to the aggravating and contributory influence of smoking, strong alcoholic drinks, hot, highly seasoned, irritating, and acid foods. Sharp, rough, and decaying teeth are also to be considered contributory. A factor of considerable import in my experience is gastric or gastro-intestinal catarrh.[2]

The anatomic changes have been studied by most of the various observers already named, and by Fordyce, Pollitzer, Heidingsfeld, and others. There

[1] Schütz, "Ueber Leukoplakia oris bei Psoriasis und anderen Dermatosen," *Archiv*, vol. xlvi., 1898, p. 433 (a good review with pertinent bibliography); Filarétopoulo, *Jour. mal. cutan.*, 1905, p. 81, also refers to the varied causes or associations.

[2] Hertzka, *Deutsche med. Wochenschr.*, 1880, vol. vi., p. 154, met with the disease in several women in whom gastro-intestinal catarrh seemed etiologic.

is, as is to be expected, but little divergence in the findings, although it is held by some that the earliest changes are in the superficial epithelium, and by others that these are secondary to an inflammatory process in the papillary region. There is found keratosis, with marked thickening of the superficial layers, thickening of the deeper strata, and down-growth of the epithelial processes, and in places there may be more or less obliteration of the papillæ, with the subepithelial tissue showing inflammatory changes and infiltration of round cells. Finally, sclerotic changes may ensue in the submucous and deeper layers. Leloir found that the epitheliomatous changes started from the ulcerations and not from the unbroken hyperkeratotic parts. Fordyce's[1] examinations in instances of epitheliomatous development showed the new growth to belong to the tubular epitheliomata, with but little, if any, disposition to the formation of horny tissue. Heidingsfeld,[2] in a case of long duration, showing as yet apparently no degenerative changes, found the leukoplakic condition to be distinctly preepitheliomatous in character—marked proliferation and down-growth of the epidermis and areas of degeneration, with a nest-like arrangement of the epithelium; a good wall of connective tissue separated it from underlying structures.

Diagnosis.—The beginning features, the history, and slow persistent course are characteristic. Leukoplakia of the tongue is readily recognized. It might possibly be confused with the mucous patch of early syphilis, but there is in the latter no tendency to epithelial hardening, but, on the contrary, it is usually soft, with the surface film generally easily removed and a disposition to superficial abrasion, and not infrequently to more or less ulcerative action. The mucous patch is, moreover, of rapid formation, with commonly, therefore, even though well developed, a history of short duration. Other symptoms of syphilis will, as a rule, be found. Lichen planus patches on the inside of the cheeks, a somewhat rare occurrence, may bear a suggestive resemblance, but they tend to present in irregular streaks or peculiar shape, especially on other parts of the mouth; in addition, lichen planus is rarely, if ever, for any length of time at least, limited to this region, but when occurring there, it is almost invariably with the eruption on some part of the cutaneous surface.

Prognosis and Treatment.—When well developed, the malady is persistent and rebellious. In the early stage of some cases abstention from smoking and irritating foods and drinks will halt its advance and sometimes promote its disappearance. The possibility of malignant development is to be kept in mind. In the treatment of the disease in its earliest existence the prevention of irritation from food, drink, or sharp or decayed teeth, together with the maintenance of good digestion and free action of the bowels, will often accomplish much, or at all events not infrequently stay its progress. The occasional use of mildly astringent and antiseptic mouth-washes is found of service. At this period application every day or two with glycerite of tannic acid, and every two or three weeks with silver nitrate stick, will sometimes prove beneficial. When epithelial thickening has taken place, the same general plan can be advised, but, as a rule, no decided betterment is possible except from active cauterizing applications. These, if employed, however, should be used boldly and thoroughly, otherwise there is likely to result more harm than good. There seems to be considerable unanimity as to the value of thermocauterization, preferably with the galvanocautery. The latter has been in my hands of decided value in several instances. Vidal's favorite application was a 20 per cent. solution of chemically pure chromic acid, and this is also employed by others. Sherwell[3] strongly commends the thorough and prolonged application of liquor hydrargyri nitratis, the surrounding parts being protected by absorbent cotton. Unna, Leistikow, and Schiff[4] speak well of the application of a resorcin peeling paste, such as is used in acne, a thin coating being smeared over daily until exfoliation occurs, and the treatment repeated at intervals of a week or so.

[1] Fordyce, Morrow's *System*, vol. iii. (Dermatology), p. 626.

[2] Heidingsfeld, "Trans. Cincinnati Acad. Med.," *Amer. Medicine*, Mch. 23, 1901, p. 834.

[3] Sherwell, *Jour. Cutan. Dis.*. 1899, p. 185.

[4] Schiff, *Wien. klin. Rundschau*, 1895, p. 113.

Bockhardt[1] states that if patients will abstain from smoking he can bring about a cure with an application, daily or every other day, of balsam of Peru, and frequently repeated (6 to 12 times daily) washing-out of the mouth with a ½ to 3 per cent. salt solution; cure takes three months to two years, according to the case.

As to constitutional treatment, there is a difference of opinion as to the value of antisyphilitic remedies in those cases with a previous syphilitic history, and most observers are inclined to consider it of but little, if any, value, and that it may be even detrimental. With a few exceptions they have proved valueless in my experience. In such instances, however, when the disease has developed but a few years after the contraction of syphilis, and is of rapid development, and especially in those in which there is a suspicion that some of the infiltration may be of a gummatous nature, these remedies, especially potassium or sodium iodid, should be tried. In the aggregate of cases I believe much more is to be accomplished by remedies directed toward any digestive or catarrhal gastro-intestinal disturbance that may, and frequently does, exist.

FURROWED TONGUE.

Synonyms.—Grooved tongue; Wrinkled tongue; Sulcated tongue; Cleft tongue; Fluted tongue; Ribbed tongue; Scrotal tongue; Lingua plicata; *Fr.*, Langue plissée; Langue montagneuse; Langue scrotale; *Ger.*, Gelappte Zunge.

Furrowed tongue is, in most instances, a condition to which some families seem especially prone. It is seen on the dorsal surface, and may consist simply of the deepening of the central furrow, common to many persons, with one or several less distinct parallel linear depressions, or they may be so numerous and deep as to present a veritable network of lines, depressions, and corresponding elevations. When there is a natural or acquired enlargement (macroglossia) of this organ, and the furrows are irregularly longitudinal, transverse, curved, and forked, the general aspect may be suggestive of a miniature of crowded valleys and mountains or sometimes of the convolutions of the brain. The surface of the depressions or clefts is usually smooth and free from fur. When deep, there is a tendency from time to time for minute particles of food to collect in them, undergo change, and produce irritation.

Fig. 263.—Furrowed tongue, with a moderate degree of macroglossia.

The condition, especially in its milder phases, is not very rare. It is in some cases congenital, with a family tendency, but is rarely of marked development in infancy or early childhood. In others it appears later in life, spontaneously or as the result of irritating influences and of various forms of glossitis and other diseases, some of which may be due to syphilis, hereditary or acquired. Their formation is sometimes partly owing to, and made more pronounced by, oversize of the tongue, the organ kept somewhat crowded in its natural bed.

Excepting the appearances and the occasional irritation due to the collection of food-particles in the crevices, and the possibility of the irritation thus repeatedly produced being the starting-point of epithelioma, the affection has no significance. Treatment is rarely sought, but in order to guard against the possible consequences mentioned, it is important that the mouth and tongue should be kept clean, using water freely, and from time to time mild antiseptic solutions, such as one of boric acid and myrrh, the furrows and crevices being separated so as to permit of thorough cleansing.

[1] Bockhardt, *Monatshefte*, 1902, vol. xxxiv., p. 164.

TRANSITORY BENIGN PLAQUES OF THE TONGUE.

Synonyms.—Exfoliatio areata linguæ ; Pityriasis linguæ ; Annulus migrans ; Glossitis areata exfoliativa ; Erythema migrans ; Wandering rash ; Ringworm-like patches of the tongue ; Circinate eruption of the tongue ; *Fr.*, Desquamation aberrant en aires de la langue ; Desquamation épithéliale de la langue (Gautier) ; Glossite exfoliatrice marginée (Fournier, Lemonnier); Lichénoïde lingual (Gubler, Vaniair) ; Eczéma en aires de la langue (Besnier) ; Eczéma marginée desquamitif dè la langue ; *Ger.*, Flüchtige, gutartige Plaques der Zungenschleimhaut (Caspary) ; Landkartenzunge.

Brief mention or account of this rare and strange affection is to be found some years back, but it was not until the more recent clear and fuller descriptions by Bridou, Gubler, Caspary, Vanlair, Barker, Gautier, Unna, Colcott Fox, and others that the matter excited much attention. In our own country there is scant literature, cases having been reported by Kinnier, Hartzell, and Allen.[1]

Symptoms.—The malady shows itself as one or several small, pin-head-sized, grayish, well-defined, slightly elevated spots, of vesicular aspect, on the dorsum of the tongue and most commonly laterally and toward the tip. Exceptionally, as in one of Caspary's cases here pictured, the under surface is also the seat of lesions. The patches spread peripherally, the central part tending to superficial exfoliation or desquamation, and becoming moderately or markedly reddened, often glossy, and sometimes presenting the appearance of a slight abrasion, and with apparently trifling depression. The patch is frequently of a brighter red toward the border. The peripheral spreading portion exhibits the grayish, pseudovesicular aspect of the beginning central point. Sometimes there is a yellowish hue to the border, and sometimes bluish, but generally it is grayish, and even silvery white. Exceptionally, the spot is without the yellowish or whitish border. A patch ordinarily reaches the diameter of a half-inch, frequently greater, and then begins to disappear, the central portion first resuming the natural appearance. From one or two to ten days or more is commonly required for a patch to present, run its course, and disappear,

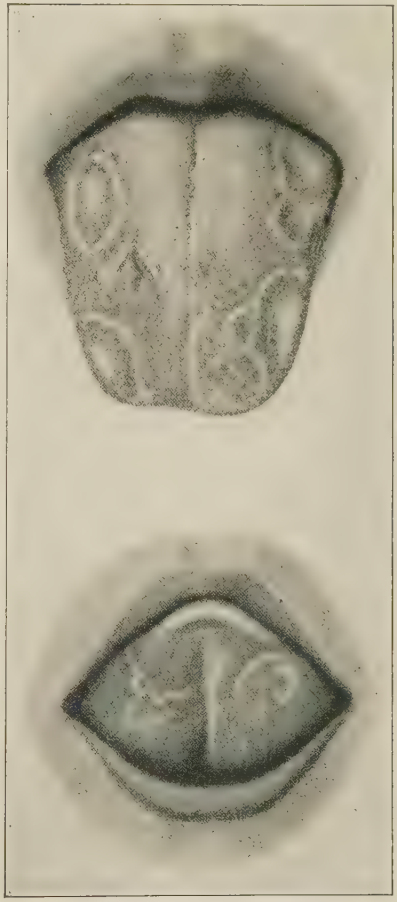

FIG. 264.—Transitory benign plaques of the tongue (Caspary).

[1] Literature: Bridou, "Sur une affection innominée de la muqueuse linguale (état lichénoïde de M. Gubler)," *Thèse de Paris*, 1872; Gubler, *Dict. encycl. d. Sci. méd.*, Paris, 1869, vol. i., p. 211, and *ibid.*, 1876, vol. x., p. 234; Alibert, *Gaz. de shôp.*, 1875, p. 806; Caspary, *Archiv*, 1880, p. 183 (with colored plate); Vanlair, *Revue men. de méd. et de Chirurg.*, vol. iv., 1880, pp. 51 and 227 (with review and some references); Barker, *London Path. Soc'y Trans.*, vol. xxxi., 1880, p. 353, and Holmes and Hulke's *Syst. of Surg.*, third edit., 1883, ii., p. 560; Gautier, *Revue méd. de la suisse romand.*, 1881, p. 589 (with review and references); Parrot, *Progrès méd.*, 1881, p. 191 (31 cases);

and marked development and changes can occur in several hours. In many instances but one or two such areas are present at one time, new ones appearing from week to week or month to month as the old spots fade, and thus the malady may continue indefinitely. There are, however, generally periods of variable duration when the tongue remains entirely free from manifestations. When several are to be seen, from enlargement, coalescence may result, and a peculiar appearance be presented, giving rise to the term "*geographic tongue*" (lingua geographica).

The plaques are usually well rounded, occasionally being somewhat irregular, the irregularity being doubtless due, as suggested by Unna, to the fusing of closely contiguous beginning points at various parts of the border. Guinon saw 1 instance in which a plaque was more or less diffused along the median line. Spots near the side of the tongue sometimes finally become segmental or half-moon-shaped, extension ceasing at the edge of the organ, although they may go beyond on to the under surface. As a rule, the areas are not sore or painful, and give rise to no discomfort. Occasionally, as a ring becomes large, a new one forms at the central parts, and in exceptional cases a patch may show two or three concentric rings. The filiform papillæ are sometimes shed, but the fungiform papillæ may remain and may even appear more prominent by reason of their isolation (Butlin and Spencer). In most instances there have been practically no subjective symptoms, but itching is occasionally noted, and in Barker's 2 cases it was quite marked, and associated with increased salivary flow.

Etiology and Pathology.—The malady is rare. It is most frequent in children under the age of two years; Parrot's 31 cases were under six, Guion's 6 under four, Colcott Fox's 10 under five. The 2 cases under my own observation were under four. It is, however, seen in older children and also in adults (Vanlair, Lailler, Unna, Hartzell, Besnier, Molènes, Allen, Paget), in the latter much more frequently than formerly thought. Of Unna's 14 cases, 12 were adults. Hartzell's patient was aged forty-two, and 1 of Vanlair's sixty-six. It is met with in both sexes.

The cause of the disease is not known. Parrot looked upon it as syphilis, but his experience was with foundlings, and he was inclined to look upon most obscure affections as of suspicious nature. Fournier is disposed to class it among the indirect consequences of syphilis—among his parasyphilides. Almost all others (Vanlair, Lemonnier, Vidal, Caspary, Besnier, Unna, Du Castel, Molènes, Hartzell, Butlin and Spencer, and others) hold, and properly, I believe, that it is in no way related to syphilis. In my own cases there was not a suspicion of such cause. Moreover, both Unna and Du Castel met with patients who contracted syphilis after the spots had presented. Gastro-intestinal disturbance is looked upon (Gubler, Bergeron, Vanlair, Colcott Fox, Molènes, Hartzell, and others) by most observers as of etiologic influence, and such appeared to be of import in my patients. Others, especially Unna, consider it a malady of trophoneurotic origin. Unna, Barker, and Caspary have seen it in delicate children. Spencer's case developed after scarlet fever, and in Bergeron's hospital interne during convalescence from typhoid. Besnier views it as a form of eczema, having seen it associated with seborrheic eczema of the integument. The appearance and manner of spread have suggested ringworm, and Barker found a fungus in one case which both he and Hutchin-

Unna, *Archiv*, 1881, p. 295 (12 cases); Lemonnier, "De la glossite exfoliatrice marginée," *Thèse de Paris*, 1883 (with bibliography to date); Colcott Fox, *Lancet*, 1884, i., p. 842 (10 cases; gives the earliest literature); Butlin, *Diseases of the Tongue*, 1885; Kaposi, *Wien. med. Presse*, 1885, p. 361; Guinon, *Rev. mens. de mal. de l'enfance*, 1887, p. 385 (6 cases); Kinnier, *Jour. Cutan. Dis.*, 1887, p. 56; Hartzell, *Med. News*, vol. li., 1887, p. 502; Mibelli, *Giorn. ital.*, 1888, p. 383; Molènes, *Arch. de laryngol.*, 1889, vol. ii., p. 326 (full review with bibliography); Bayet, *Clinique*, Brussels, 1889, vol. iii., p. 657; Besnier, *Annales*, 1889, p. 320 (case demonstration); Hutchinson, *Arch. of Surg.*, 1892–93, vol. iv., p. 156; Allen, *Jour. Cutan. Dis.*, 1897, p. 159 (case demonstration); Du Castel, *Annales*, 1897, p. 482 (case demonstration); Colleville, *Gaz. hebdom.*, 1898, p. 277; Mikulicz and Kümmel, *Die Krankheiten des Mundes*, Jena, 1898, p. 120 (a good illustration); Böhm, *Sammlung klin. Vorträge*, Leipzig, 1899, No. 249 (innere Medicin, No. 75), p. 1467 (a clear and exhaustive review); Butlin and Spencer, *Diseases of the Tongue*, 1900, p. 94 (with colored plate).

son thought resembled the trichophyton, but this is the only instance, all others having failed to find any special organism. Kinnier saw these tongue spots associated with ringworm patches on the skin. The evanescence and behavior of the areas, as well as their persistent recurrence and the failure to find fungus elements, seem conclusive against this view. A hereditary or family tendency has sometimes been noted; the mother of one of Bridou's patients had it in childhood; Colcott Fox saw it in a brother and sister, Caspary observed it in 2 instances in 2 children in the same family; Gubler has seen a whole family affected. In one of Hutchinson's patients the other members of the family had a tendency to sores on the lips and in the mouth.

According to Parrot, the epithelium is found tumefied and thickened, and the cells of the horny and Malpighian layers augmented, those of the latter showing signs of proliferation; lymphoid cells were found in the papillæ and about the vessels in the subjacent derma. Unna states it to be an epithelial disease, with its seat quite superficial in the horny layer.

Diagnosis.—This is a matter of no difficulty, as the superficial character, their well-defined outline, with the reddish, sometimes desquamating, central portion, and the usually grayish or yellowish border, when taken together with the history, the rapidity of their formation, capriciousness, and recurrence, will serve to differentiate from syphilitic mucous patches, aphthæ, and leukoplakia.

Prognosis and Treatment.—The malady, while benign, is generally persistent, although in children it seems, in most instances, to tend to spontaneous disappearance as they grow older. It is ordinarily rebellious to treatment, although a careful supervision of the dietary and the maintenance of good digestion and free action of the bowels will often have a material influence. In feeble subjects tonics and cod-liver oil may be of service. Hartzell found in his case arsenic, also commended by Vanlair and Brocq, lengthened the intervals between the attacks. Mildly astringent and antiseptic mouth-washes are commonly prescribed. Besnier advises applications of boric acid ointment made with vaselin and with the addition of balsam of Peru. Unna states that he has had most satisfaction from sulphur applications. The most convenient for this purpose is, as Bénard suggests, the natural sulphur water, although Unna employs emulsive liquids containing washed sulphur. In my 2 cases the most benefit seemed derived from attention to digestion and the occasional administration of a laxative antacid, such as calcined magnesia, together with a myrrh and boric acid mouth-wash.

BLACK TONGUE.[1]

Synonyms.—Hairy tongue; Lingua nigra; Hyperkeratosis linguæ; *Fr.*, Langue noire; Nigritie de la langue; Hypertrophie épithéliale filiforme; Langue noire pileuse; *Ger.*, Haarzunge; Schwarze Haarzunge.

This curious malady is rare, although probably not so much so as commonly believed, inasmuch as it practically gives rise to no trouble, and sooner or later

[1] Literature: Dessois, *De la langue noire* (*Glossophytie*), Paris, 1878; Hutchinson, *Med. Press and Circular*, 1883, ii., p. 20; Stokes, *London Path. Soc'y Trans.*, 1884, vol. xxxv., p. 157; Lediard, *ibid.*, 1886, vol. xxxvii., p. 222 (brief note); Roth, *Wien. med. Presse*, 1887, pp. 935 and 987 (2 cases); Brosin, "Ueber die schwarze Zunge," Hamburg and Leipzig, 1888, Ergänzungsheft, *Monatshefte*, 1888 (with illustration, review, and analytic table of cases (23) to date, with references); Curtis, *New York Med. Jour.*, 1889, vol. l., p. 216 (case demonstration); Leviseur, *ibid.*, vol. xlix., 1889, p. 42; Lake, *Brit. Med. Jour.*, 1891, ii., p. 946; Smith, *ibid.*, p. 1043 (letter communication—2 cases); Masters, *ibid.*; Rydygier, *Arch. für klin. Chirurg.*, 1891, vol. xli., p. 767 (with illustration); Ciaglinski and Hewelke, *Zeitschr. für klin. Med.*, 1893, vol. xxii., p. 626 (with review and bibliography); Mourek, *Archiv*, 1894, vol. xxix., p. 369; Sendziak, *Rev. de laryng., otol., et de rhinol.*, 1894, vol. xiv., p. 228, and (same paper) *Monatshefte für Ohrenheilk.*, 1894, vol. xxviii., p. 112 (with review and references); Goodale, *Jour. Boston Soc. Med. Sci.*, 1897–98, ii., p. 204 (histology); Vollmer, *Archiv*, 1898, vol. xlvi., p. 12 (histology, with illustrations); Gottheil, *Arch. Pediat.*, 1899, p. 255 (with illustration of case and fungus found).

passes away spontaneously. The usual situation is immediately in front of the circumvallate papillæ, although exceptionally on other parts of the tongue; in Curtis's patient the patch was behind these papillæ, and in Lediard's and Eve's near the end, and in Lake's at the left side, middle third. The color is generally black, but in an instance observed by Dinkler it was yellow, and one by Mourek, blue. The area forms gradually, as a rule, centrally, and extends peripherally; the reverse takes place in its disappearance. In some instances (Curtis, Ciaglinski and Hewelke, Masters, Lake), however, it develops rapidly, occupying considerable area in from several days to one or two weeks. The condition may consist simply of discoloration (Stokes, Ciaglinski and Hewelke, Sendziak, Gottheil), or, as usually observed, beset with thin, filiform projections, also dark colored or black, which may be likened in appearance to long tendrils, lashes, seaweed (Curtis), or hairs; so much like the last in many instances that they were suspected of being true hairy growths, hence the term hairy tongue. In some cases, as Raynaud (cited by Lake) expressed it, the area looks like "a field of corn laid by wind and storm." These filiform projections can reach considerable length. With the exception sometimes of a mawkish taste when the patch is well developed, there are practically no troublesome subjective symptoms; rarely slight pain, although in Curtis's case this was quite pronounced.

The causes are not known. Syphilis has been suggested as possibly causative, but beyond the fact that it has occasionally been seen (Leviseur, Vollmer) in those who have had this disease there is nothing to support this view. It is not impossible that the resulting stomatitis from mercurial treatment, the use of irritating mouth-washes, excessive smoking, etc., may have some influence in its production. The malady is seen in children and adults, in the former with usually but little, and frequently no, filiform projections. In adults it may also sometimes consist practically of pigmentation alone, but commonly shows variable filiform or hair-like formations also. Its occurrence in one instance observed by Röstowjew[1] in man and wife suggested to this observer the possibility of contagiousness. It occurs in both sexes, but reaches its greatest "hairy" development in male adults. The projecting filaments consist of enormously lengthened filiform papillæ produced by a hyperkeratosis or overgrowth of the epidermis of these papillæ; the edges are usually serrated from imbrication of their investing epithelium. Sometimes these elongated, soft, and wavy or stiff hair-like formations show lateral projections, so strikingly, as in Goodale's patient, as to suggest the comparison to a feather with stem and lateral webs. A reason for this excessive hyperkeratosis is hard to find. The malady has been thought probably due to parasitic influence, and various observers have discovered organisms, but several, and sometimes numbers, are to be found on the tongue, even when this organ is free from disease. The spore-like bodies which Gottheil detected he thought similar to those reported by Dessois, Laveau, Lancereaux, Schech, Gubler, and others. That which Ciaglinski and Hewelke and Sendziak found and cultivated was a black mold consisting of a stalk-like formation having spheric capsules on the end containing black spores; a mushroom-shaped columella developed from the burst spore capsule. Many investigators, however, have failed to corroborate these and other findings reported. It is probable that the color is due to chromatogenous organisms, although this is by no means proved. Goodale attributed the color in his

FIG. 265.—Black tongue, showing the filamentous or hair-like development.

[1] Röstowjew, abs. in *Monatshefte*, 1899, vol. xxiv., p. 41.

case to highly refractile, yellowish-brown granules. Hutchinson was inclined to believe that in his patient (pigmentation only) the color was purposely produced.

Prognosis and Treatment.—The malady is somewhat variable in its behavior in different cases. It may persist for several weeks, months, or years, and then gradually or quickly spontaneously disappear; or, as in Stokes's patient, practically of pigmentation only, the blackness fluctuates in degree and extent. Treatment seems to be of little avail. Shaving and scraping, sometimes practised, will remove the filiform formations, but regrowth usually occurs. Exfoliation can, if thought advisable, be produced by the resorcin peeling paste, by solutions of salicylic acid and weakened lactic acid. Upon the whole, except as to the maintenance of cleanliness, the applications of mild antiseptics and astringents, such as glycerite of tannic acid, the malady is best let alone. It generally disappears spontaneously sooner or later.

CHEILITIS GLANDULARIS.

Synonyms.—Cheilitis glandularis apostematosa (Volkmann); Myxadenitis labialis.

Volkmann[1] was the first to describe this rare malady, his cases being characterized by chronic inflammation of the lower lip, chiefly of the vermilion part, but extending on to the mucous membrane proper, as well as occasionally involving the adjacent skin; the latter was erythematous in appearance. The lip becomes somewhat tense and swollen, and the mucous glands prominent, being the size of a hemp-seed or larger, with follicular openings much dilated, sufficiently marked in some instances to permit the introduction of a fine probe. An opaque mucous or mucopurulent secretion readily exuded upon slight pressure, and there was variable spontaneous oozing, which tended now and then to form more or less crusting. It is not uncommon for the lips to be glued together in the morning. Some of the openings were of a fistulous character, in one case as many as 10 to 15 being found in the inside of the lip, admitting a large probe, and forming irregular, fistulous tracts. Furuncle- and abscess-like inflammatory formations sometimes developed in the fleshy part of the lip, but actual ulcerative action, Volkmann states, did not occur.

Purdon[2] has met with 4 examples of the same malady, all adults—3 males and 1 female. The disease was confined in 3 patients to the lower lip and its mucous lining, beginning gradually, and spreading over the entire surface of the lip. The mucous glands of the lip were swollen, and could be felt with the finger, often as nodular masses. These conditions were most pronounced during exacerbations, at such times the lip becoming tense, swollen, and hard, and, as in Volkmann's cases, with mobility more or less impaired. A turbid and mucopurulent secretion was pressed out of these glands, the ducts of which were dilated. In fact, there seemed, Purdon states, to be also an active catarrhal condition of the lining membrane of the cheeks and gums. There were no fistulous tracts as in some of Volkmann's patients. In 1 patient both lips were affected, and frequently found glued together in the morning. In 1 case the skin of the chin became erythematous. Galloway[3] has reported an instance with some of the features of these various cases, lacking, however, the hypertrophied mucous glands; there was an altered viscid secretion from the mucous and salivary glands of the mouth, and also considerable crusting of the lip in this case. There was an associated seborrhea of the face and scalp.

The cause of the malady is not known. The patients seemed otherwise in good health. Three of Volkmann's cases had just previously suffered from syphilis, but he is not inclined to consider this of any etiologic relationship, believing that the etiologic factor is to be sought for in the catarrhal condition of the mouth and pharynx, the mucous glands of the lip becoming subsequently involved. Purdon's patients were all free from syphilis.

[1] Volkmann, *Virchow's Archiv*, 1870, vol. l., p. 142 (5 cases).
[2] Purdon, *Brit. Jour. Derm.*, 1893, p. 23 (4 cases).
[3] Galloway, *ibid.*, 1895, p. 113.

Prognosis and Treatment.—The malady is persistent and rebellious to treatment.[1] Volkmann cured 3 of his cases in one to two months with potassium iodid internally, gargles of potassium chlorate, and mild cauterization of the parts with silver nitrate. Purdon was not so successful, the disease seeming obstinate to all remedies. What gave most benefit was the local application of lotio nigra and glycerin, with occasional penciling with silver nitrate solution.

FORDYCE'S DISEASE.

Synonym.—Fordyce's disease of the lips and oral mucous membrane.

The first description of this peculiar affection, involving the vermilion of lips and mucous membrane of the mouth, we owe to Fordyce (1896).[2] Since then the same condition has been observed by Montgomery and Hay, Audry, Delbanco, Suchannek, Heuss, Allen, and others.[3] It is characterized by the appearance of whitish or yellowish, scanty or abundant, discrete, aggregated, and often practically coalescent, milium-like bodies, occurring more especially on the inside of the mouth, laterally along the line of the teeth as far back as the last molar, and possibly somewhat less frequently on the vermilion or mucous and

FIG. 266.—Fordyce's disease; lesions are closely crowded (courtesy of Dr. J. A. Fordyce).

inner surface of the lips. There is but slight elevation, but they are more projecting on the oral membrane than on the lips. The color of the formations in

[1] Unna, "Ueber Erkrankungen der Schleimdrüsen des Mundes," *Monatshefte*, 1890, vol. xi., p. 317, reports several cases of a malady (Baelz's disease) in many respects apparently similar, and to which his attention had been previously called by Baelz. The lip, usually the under lip only, was involved, and with the early symptoms above described, but the mucous glandular swelling went on to pronounced suppuration, crusting, and ulceration, and then cicatrization. He found that local treatment with tincture of iodin, a plan pointed out to him by Baelz, acted as a specific, improvement ensuing immediately. Jamieson (*Brit. Med. Jour.*, Dec. 7, 1895 (cited by Fordyce)) has reported a case apparently similar to those described by Unna.

[2] Fordyce, "A Peculiar Affection of the Mucous Membrane of the Lips and Oral Cavity," *Jour. Cutan. Dis.*, 1896, p. 413 (with colored plate, case illustration, and histologic cuts).

[3] D. W. Montgomery and Hay, "Sebaceous Glands in the Mucous Membrane of the Mouth," *Proceedings of the Tenth Annual Session of the Assoc. Amer. Anatomists*, 1897, p. 76; Audry, "Ueber eine Veränderung der Lippen- und Mundschleimhaut bestehend in der Entwickelung atrophischer Talgdrüsen," *Monatshefte*, 1899, vol. xxix., p. 101 (with histologic plate); Delbanco, "Ueber die Entwickelung von Talgdrüsen in der Schleimhaut des Mundes," *ibid.*, pp. 104 and 353 and *Münch. med. Wochenschr.*, 1898, p. 1510 (case demonstration), and *ibid.*, 1899, p. 459 (case demonstration); Heuss, "Ueber postembryonale Entwickelung von Talgdrüsen in der Schleimhaut der menschlichen Mundhöhle," *ibid.*, 1900, vol. xxxi., p. 501 (with review); Allen, *Jour. Cutan. Dis.*, 1897, p. 29 (case demonstration); Suchannek, "Ueber gehäuftes Vorkommen von Talgdrüsen in der menschlichen Mundschleimhaut," *Münch. med. Wochenschr.*, 1900, i., p. 575.

the mouth are also more of the white, with the yellow or yellowish aspect less pronounced than observed in the lip lesions. When numerous and closely crowded, the appearance of a solid, yellowish patch is presented, but the constituent, milium-like bodies can be readily discovered or rendered much more conspicuous by putting the tissues on the stretch. As a rule, there are no subjective symptoms, although occasionally in some instances a feeling of slight burning and itching, accompanied by some stiffness as though the lip were swollen (Fordyce).

Etiology and Pathology.—The condition is not, as at first thought, very rare, but, owing to its comparatively insignificant character, but relatively few individuals affected seek advice. It is seen most frequently in male adults. In 12 cases investigated by Heuss, in a number of which the lesions were in the oral cavity and scanty, the patients were aged between twenty-five and fifty, and there were only 3 women. Montgomery and Hay and Audry saw the development in 1 instance in an infant. Fordyce's patient (a physician) found the lesions in all other members of his family, but they appeared after puberty; he also found them in "half of the negroes examined." The formations have been histologically investigated by Fordyce, Montgomery and Hay, Delbanco, and Heuss. Fordyce first thought they were due to a granular change in the protoplasm of the cells of the affected mucous membrane, but subsequently recognized the correctness of the observations by the others named that they are in reality slightly or moderately, sometimes markedly, developed sebaceous glands. Montgomery and Hay were, by their investigations of these peculiar bodies, the first to show that these glandular structures are sometimes to be found in the mucous membrane of the oral cavity. C. J. White,[1] in still later investigations, claims that Fordyce's original opinion is the correct one, as he found that the sebaceous element, though abundantly present, lies beyond the diseased tissue proper.

FIG. 267.—Fordyce's disease, showing lesions in the mouth (Delbanco).

There is some difference of opinion as to whether these glands are simply a late development of preexisting embryonic elements (Audry), or whether they are purely postnatal in origin (Heuss). This latter observer believes their growth and development are favored by catarrhal conditions, stomatitis, etc., and thinks that their apparent greater prevalence in those who have had syphilis is due to the stomatitis which the mercurial treatment sometimes causes. They have, of course, as all observers agree, no direct connection with syphilis, and it is more than probable that in the cases investigated (Montgomery and Hay, Delbanco, Heuss), in which syphilis had previously existed, their presence was purely a matter of coincidence.

Prognosis and Treatment.—The condition, while benign, is persistent, and shows but little, if any, tendency toward retrogressive changes, although in a few instances the lesions became, in course of time, smaller and less conspicuous. Treatment has not been satisfactory. Fordyce found that when the superficial layer of the epithelium was scraped away, some of the bodies could be pressed out, and the discoloration thus somewhat lessened; the effect was, however, only temporary.

[1] C. J. White, *Jour. Cutan. Dis.*, March, 1905, p. 97 (a report of 65 cases, with histologic cuts and a complete review of the subject, and literature with bibliography).

LA PERLECHE.

Synonyms.—Bridou ; Parasitic disease of the lips.

This is a peculiar affection of the lips, especially of the commissures, observed chiefly in certain districts of France, and first clearly described by Lemaistre,[1] and since by Raymond,[2] Guibert,[3] Planche,[4] and a few others. It occurs almost exclusively in infants and young children. It begins, as a rule, in the angles, bilaterally, first presenting as a blanching of the epithelium and having a somewhat sodden appearance. It extends to a variable distance along the vermilion surface toward the median line, but usually only part way, in some instances invading the neighboring skin, and in most cases the mucous membrane of the inside of the lips as well. There is frequently some underlying and surrounding hyperemia and inflammation, and the mouth-angles are sometimes crusted over. Other parts of the inside of the mouth may also show involvement. In a large number of cases the disease remains limited to the angles of the mouth and the immediately adjacent parts. On the true mucous surface, and also in a great measure at the commissures, the appearances presented are somewhat like those of syphilitic mucous patches. There is a distinct tendency at the commissures of the mouth to the formation of a deep fissure, with often smaller ones nearby, and with a disposition sometimes to bleeding. The epithelium of the lips becomes slightly thickened, macerated, and more or less readily detachable. The condition is aggravated by the child frequently moistening the parts with the tongue in attempts to relieve the dryness and parched and burning feeling. There is also sometimes itching.

The malady is contagious, and spreads quite rapidly in maternity hospitals, foundling and infant asylums, and among young school-children (see Lemaistre and Raymond's papers). It is thought to be conveyed through the medium of the water-supply, drinking-cups and spoons, and other utensils. According to Lemaistre, it is due to an organism named by him streptococcus plicatilis. Raymond, on the other hand, attributes it chiefly to the staphylococcus cereus albus, although admitting that it may be produced by various other organisms, and that the malady usually starts from the inside of the lips. This opinion is also shared by Guibert and Planche. The resemblance to the mucous patch and fissures of syphilis is at times so striking that these several observers agree that in some cases the presence or absence of other symptoms of syphilis must be the determining factor in the differential diagnosis. Raymond considers the diphtheroid-looking spots sometimes seen in the mouths of infants and young children practically the same disease.

Prognosis and Treatment.—The affection generally runs its course in from a few weeks to one or two months, with sometimes a marked disposition to relapse. Treatment consists in frequent cleansing and the occasional application of a weak solution of silver nitrate, copper sulphate, or alum, together with mild ointments or such other remedies as may be indicated. Attention is to be given to the nursing-bottles, drinking-vessels, water-supply, etc.

[1] Lemaistre, "Étude sur l'air de la ville de Limoges ; de la perlèche ; du streptococcus plicatilis," *Jour. soc. de méd. et de la pharm. de la Haute-Vienne*, Limoges, 1886, pp. 41, 55, and 74.

[2] Raymond, "Étude clinique et bactériologique sur la perlèche," *Annales*, 1893, p. 578.

[3] Guibert, "De la perlèche," *Thèse*, No. 142, Toulouse, 1896.

[4] Planche, "La Perlèche," *Thèse de Paris*, 1897 ; Négrié, "Note sur la perlèche," *Cong. de Gynecol. d'obstet. et de pédiat.*, first session, Bordeaux, Aug., 1895, p. 1002.

INDEX.

Abortive zoster, 326
Abrasions, 64
Absorption of skin, 48
Acanthia lectularia, 1096
Acantholysis bullosa, 360
Acanthoma adenoides cysticum, 618
Acanthosis nigricans, 495
Acare des follicules, 1106
Acarus, 37
  folliculorum, 968, 1106
  scabiei, 1099
Achorion Schönleinii, 1029
Achroma, acquired, 578
  congenital, 576
Achromia unguium, 896
Acne, 971
  agminata, 989
  albida, 963
  artificialis, 975
  atrophica, 974
  bromid, 975
  bromin, 975
  cachecticorum, 974
  course, 976
  diagnosis, 979
  disseminata, 971
  erythematosa, 992
  etiology, 977
  frontalis, 988
  hypertrophica, 974
  indurata, 974
  iodid, 975
  iodin, 975
  keloid, 610
  keratosa, 976
  lupoid, 988
  mentagra, 948
  necrotica, 988
  necrotisans et exulcerans serpiginosa nasi, 989
  papulosa, 973
  parasitic, 977
  pathology, 978
  picea, 975
  picealis, 975
  prognosis, 980
  punctata, 967, 973
  pustulosa, 973
  rodens, 988
  rosacea, 992
    diagnosis, 996
    etiology, 994
    pathology, 995
    prognosis, 996
    symptoms, 992
    treatment, 997
Acne rosée, 992
  sebacea, 956
  sebacée cornée, 516
  simplex, 971
  symptoms, 971
  telangiectodes, 989
  treatment, 981
  urticata, 975
  varioliformis, 988
    treatment, 992
  vulgaris, 971
Acné, 971
  cheloidienne, 610
  cicatrices deprimée, 988
  decalvante, 945
  miliare, 963
  sebacée, 956
    cornée, 512
    fluente, 956
  varioliforme, 612
Acneiform syphiloderm, 755
Acnitis, 988
Acrochordon, 660
Acrodermatites continués, 364
  perstans, 364
Acrodynia, 164
Acrodynie, 164
Acromegaly, 564
Actinomyces, 1079
Actinomycose, 1076
Actinomycosis, 1076
  of skin, 1076
  treatment, 1080
Actinotherapy, 125
Addison, keloid of, 551
Adenoma of sebaceous glands, 622
  of sweat-glands, 618, 625
  sébacés, 622
  sebaceum, 622
  sudoriparum, 625
Adenopathy, syphilitic, 773
Adipose tissue, 25
Adiposis dolorosa, 665
Agminate folliculitis, 1040
Ainhum, 593
Akne, 971
Aktinomykose, 1076
Albinism, 576
Albinisme, 576
Albinismus, 576
  complete, 576
  partial, 576
  semi-, 577
Albinos, 576
Aleppo boil, 799
Algidité progressive, 558

Alibert's keloid, 603
Alligator skin, 532
Alopecia, 923
  adnata, 923
  areata, 930
    diagnosis, 940
    etiology, 934
    pathology, 937
    prognosis, 941
    symptoms, 930
    treatment, 941
  bacillary, 939
  circumscripta, 930
  coccogenous, 939
  congenita, 923
  furfuracea, 927
  hyphtogenous, 939
  of syphilis, 734
  pityrodes, 925, 927
  premature, 925
    idiopathic, 925
    symptomatic, 926
  senilis, 924
  treatment, 928
  trichophytic, 939
  universalis, 933
Alopecie, 923
Alopécie, 923
  cicatricielle innominée, 945
Alteratives, 105, 106
Amboyna button, 802
Anal region, eczema of, 304
Analgesic paralysis with whitlow, 598
Analgesics, 109
Anatomic tubercle, 675
Anatomy of skin, 17
Anesthesia, 888
Anesthetic leprosy, 862
Angiectases, 647
Angio-elephantiasis, 648
Angiokeratom, 544
Angiokeratoma, 544
Angioma, 646
  cavernous, 647, 648
  fissural, 650
  infective, 657
  pigmentosum atrophicum, 835
  plexiforme, 647
  serpiginosum, 657
  simplex hyperplasticum, 647
    seu glomeruliforme, 647
  varicosum, 649
Angiome, 646
  cystique, 630
Angioneurotic edema, 176
Angiosarcoma, 845
Anidrose, 1006
Anidrosis, 1006
Animal extracts, 106
  parasites, diseases due to, 1088
  scabies, 1100
Ankylostomiasis, 1110
Annular lichen planus, 194
  syphiloderm, 743
Annulus migrans, 1117
Anthrax, 381, 386
  benigna, 381
Anthrax maligna, 386
  simplex, 381
Antilithemic remedies, 105
Antipruritics, 109, 117
Antiseptics, gastro-intestinal, 104
Ants, 1097
Anus, pruritus of, 880
Aperients, 104
Aphthous sores, 752
Aplasia pilorum intermittens, 914
    moniliformis, 914
Aplasie moniliforme des cheveux et des poils, 914
Appendages, diseases of, 889
Area Celsi, 930
Argyria, 486
Army itch, 1100
Arrectores pilorum, 30
Arthritic purpura, 468
Arznei-exantheme, 417
Aspergillus lepidophyton, 1066
  Tokelau, 1066
Asperitudo epidermidis, 962
Asphyxia, local, 400
Asphyxie locale des extrémités, 400
Asteatodes, 962
Asteatose, 962
Astéatose, 962
Asteatosis, 962
Atherom, 965
Atheroma, 965
Athérome, 965
Athyroidie, 569
Atrophia cutis linearis, 586
    senilis, 584
    universalis, 589
  maculosa et striata, 586
  pilorum propria, 909
  senilis, 584
  unguium, 894
    treatment, 897
Atrophic lines and spots, 586
Atrophies, 576
Atrophoderma neuriticum, 583
  pigmentosum, 835
  senile, 584
  striatum et maculatum, 586
Atrophy, linear, 586
  of hair, 909
    pigment, 918
  of nails, 894
  of skin, diffuse idiopathic, 589
    general idiopathic, 589
    progressive idiopathic, 589
    senile, 584
  unilateral, of face, 553
Autographism, 166

Bacillary alopecia, 939
Bacillus acnes, 977
Bacterium decalvans, 938
Bakers' eczema, 258
Bald ringworm, 1043
  tinea tonsurans, 1043
Baldness, 923
Balggeschwulst, 965
Ballooning colliquation, 456

Barbadoes leg, 561
Barber's itch, 1045
Barn itch, 1051
Bartfinne, 948
Bath pruritus, 882
Bath-house impetigo 370
Baths, 110
Bat's-wing disease, 716
Beaded hair, 914
Beard, ringworm of, 1045
Bearded region, eczema of, 300
  ringworm of, 1045
Bed-bug, 1096
Bed-hairs, 39
Beerschwamm, 802
Bees, 1097
Bettwanze, 1096
Beule von Aleppo, 799
Bird-mite, 1097
Birth-mark, 646, 648
Biskra button, 799
Black tongue, 1119
Black-dot ringworm, 1043
Blackhead, 967
Bläschen, 60
Bläschenflechte, 320
Blasen, 61
Blasenausschlag, 346
Blastomycetic dermatitis, 1083
  treatment, 1086
Blastomycose cutanée, 1083
Blastomycosis of skin, 1083
Blättern, 451
Blebs, 61
Bleeding stigmata, 1012
Blind boil, 377
Blister fever, 347
Blisters, 61
  fever, 320
  little, 60
Blood-vessels, 25
Bloody sweat, 1012
Blutfleckenkrankheit, 466
Blutschwär, 377
Body-lousiness, 1092
Boil, 377
  Aleppo, 799
  blind, 377
  Delhi, 799
  Oriental, 799
Borken, 67
Bot-fly, 1107
Botryomycosis, 461
Bouton d'Alep, 799
Bowditch Island ringworm, 1065
Brandschwär, 381
Breasts, eczema of, 303
Breigeschwulst, 965
Bridou, 1124
Bromid acne, 975
Bromidrose, 1007
Bromidrosis, 1001, 1007
  treatment, 1008
Bromin acne, 975
Buckwar, 1065
Bucnemia tropica, 561
Bug, bed., 1096
Bug, harvest, 1104
Bulb-corpuscles, 29
Bulbs, end-, 29
Bullæ, 61
Bulles, 61
Bullous syphiloderm, 761, 773
  urticaria, 168
Burmese ringworm, 1065
Burns, 402
  x-rays, 411
Burrow, 1098

CACHECTIC gangrene, multiple, 396
Cachexia strumipriva, 571
Cachexie pachydermique, 569
Calamin liniment, 113
Calamin-and-zinc-oxid lotion, 113
Calamin-zinc-oxid liniment, 113
Calculi, cutaneous, 963
Callositas, 500
Callosity, 500
Callus, 500
Calvities, 923
Cancroid, 817
  ulcer, 819
Cancroïde, 817
Canitie annellée, 920
Canities, 918
  præmatura, 919
  senilis, 919
  treatment, 923
Caraate, 1074
Caratë, 1074
Carboncle, 381
Carbuncle, 381, 386
Carbunculus, 381
  treatment, 382
Carbunkel, 381
Carcinoma cutis, 812
  en cuirasse, 812
  epithelial, 817
  lenticular, 812
  melanotic, 813
  nodular, 812
  pigmented, 813
  skin, 817
  spider, 655
  tuberosum, 812
Carrion's disease, 809
Cascadöe, 1065
Caterpillars, 1097
Cauliflower excrescence, 520
Causalgia, 877
Caustics, 118
Cautery, Paquelin, 119
Cavernous angioma, 647, 648
  lymphangioma, 630
Cell-nests, 827
Cells of Langerhans, 22
  Merkel's touch-, 29
  molluscum, 616
  plasma, 696
  prickle-, 22
  wandering, 32
Cellulitis, phlegmonous, 383
Cellulome épithélial éruptif kystique, 618

Ceratum simplex, 114
Chafing, 140
Chalazion, 965
Chalazodermia, 572
Chaleur du foie, 478
Chancre, 728
  extragenital, 728
  non-venereal, 728
  redux, 770
Chapping, 66, 252
Chaps, 66, 252
Charbon, 386
Cheilitis exfoliativa, 311
  glandularis, 1121
    apostematosa, 1121
Cheiropodalgia, 164
Cheiropompholyx, 336
Cheloid, 603
Chéloide, 603
Chicken-louse, 1097
Chicken-pox, 447
Chigger, 1104
Chignon disease, 916
  fungus, 916
Chigoe, 1104
Chilblains, 137, 404
Chinese ringworm, 1065
Chique, 1104
Chitin, 21
Chloasma, 478, 1067
  cachecticorum, 480
  caloricum, 479
  diagnosis, 483
  etiology, 482
  gravidarum, 482
  idiopathic, 479
  pathology, 482
  prognosis, 484
  symptomatic, 480
  symptoms, 478
  toxicum, 479
  traumaticum, 479
  treatment, 485
  uterinum, 481
Chloasme, 478
Chromatophores, 32
Chromidrose, 1009
Chromidrosis, 1009
  pseudo-, 1012
  red, 1012
  treatment, 1011
Chromophytosis, 1067
Chyluria, 564
Cicatrice, 601
Cicatrices, 70
  false, 586
Cicatrix, 601
Cimex lectularius, 1096
Circinate eruption of tongue, 1117
  syphiloderm, 743
  tubercular syphiloderm, 762
Circumpilar collarette, 1052
Circumscribed edema, acute, 167, 176
  lipoma, 664
  scleroderma, 551
Claret stain, 648
Classification, 129–135
Clastothrix, 911
Clavus, 497
Claw-nails, 890
Cleavage, lines of, Langer's, 17
Cleft tongue, 1116
Clefts, 65
Clou, 377
  de Biskra, 799
Coal-tar lotions, 284
Coccogenous alopecia, 939
Coil-ducts, cysts of, 1015
Coil-glands, 32
Cold cream, 114
  freckles, 477
  sores, 322
  sweat, 51
Colloid degeneration of skin, 644
  milium, 644
Colloide degeneration, 644
Colloïdome miliaire, 644
Colored sweat, 1009
Columnæ adiposæ, 25
Comedo, 967
  double, 967
  extractors, 119
  multiple, 967
  treatment, 969
Comedon, 967
Comédon, 967
Compound papillæ, 23
Condyloma acuminata, 520
  broad, 751
  flat, 751
  pointed, 520
Confluent variola, 454
Constitutional treatment, 102
Cor, 497
Corium, 22
Corn, 497
  suppurating, 498
Corne cutanée, 528
Corne de la peau, 528
Cornu cutaneum, 528
  humanum, 528
Corona veneris, 742
Corps ronds, 515
Corpuscles, bulb-, 29
  Krause's, 27, 29
  lymphoid, 25
  Meissner's, 27, 28
  molluscum, 616
  nerve-, Krause's genital, 29
  of Vater, 27
  Pacinian, 27
  tactile, 27, 28
  touch-, 27, 28
  Wagner's, 27, 28
Couperose, 992
Crab-lice, 1094
Crabs, 1094
Crackled eczema, 252
Cracks, 65
Crateriform ulcer, 822
Craw-craw, 1109
Creeping eruption, 1107
Cretinism, sporadic, 571
Cretinoid edema, 569

Croutes, 67
Crusta lactea, 247
Crustæ, 67
lamellosæ, 67
Crusted ringworm, 1024
Crusts, 67
milk, 247
scaly, 67
Crusty scales, 67
Culex anxifer, 1097
pipiens, 1097
Cuniculus, 1098
Curetting, 119
Current, high-frequency, 128
Cutaneous calculi, 963
horn, 528
paratuberculoses, 205
psorospermosis, 813
Cute, 1074
Cuticle, 19
Cuticula, 19
Cutis, 22
hyperelastica, 574
laxa, 572
pendula, 572
vera, 22
Cyanidrosis, 1009
Cystadénomes épithélieux bénins, 618
Cystic epithelioma, multiple benign, 618
lymphangioma, 629
Cysticercus cellulosæ, 1106
Cysts, multiple dermoid, 965
of coil-ducts, 1015
sebaceous, 965

Dactylitis, syphilitic, 772, 773
Dactylolysis spontanea, 593
Dandruff, 957
Darier's disease, 512
Dartoic myoma, 667
Das Fettsklerem, 558
Sklerem der Neugeborenen, 558
Sklerödem, 560
Dead layer, 20
Deciduous skin, 143
Defluvium capillorum, 734, 927
Degeneration, colloid, of skin, 644
colloide, 644
Dégénéréscence colloïde du derme, 644
Delhi boil, 799
sore, 799
Demodex folliculorum, 37, 968, 1106
Der Aussatz, 855
flache Hautkrebs, 819
Dercum's disease, 665
Derma, 22
Dermalgia, 877
Dermalgie, 877
Dermamyiasis linearis migrans œstrosa, 1108
Dermanysse des oiseaux, 1097
Dermanyssus avium et gallinæ, 1097
Dermatalgia, 877
Dermatite exfoliatrice, 183
herpetiforme, 340
polymorphe, 340
Dermatitis, acute general, 183
Dermatitis ambustionis, 402
bullosa, 402
erythematosa, 402
escharotica, 403
artefacta, 416
blastomycetic, 1083
blastomycotica, 1083
calorica, 402
coccidioidal, 1085
coccidioides, 1085
congelationis, 404
contusiformis, 152
epidemica, 188
exfoliativa, 183
epidemica, 188
infantum, 189
neonatorum, 189
factitia, 416
gangrænosa, 396, 398
infantum, 396
general exfoliative, 183
herpetiformis, 340
diagnosis, 344
etiology, 341
pathology, 343
prognosis, 345
symptoms, 340
treatment, 345
iodoform, 408
malignant papillary, 813
medicamentosa, 417
multiformis, 340
papillaris capillitii, 610
papillomatosa capillitii, 610
pyogenic, 369
repens, 363
Röntgen-ray, 411
seborrhoica, 308
traumatica, 405
uncinarial, 1109
vegetans, 354
venenata, 405
treatment, 410
x-ray, 411
Dermatographism, 166
Dermatolysie, 572
Dermatolysis, 572
Dermatomycosis favosa, 1024
furfuracea, 1067
trichophytina, 1035
Dermatomyom, 666
Dermatomyoma, 666
Dermatosclerosis, 547
Dermatoses psoriasiformes, 204
Dermatosis Kaposi, 835
papular persistent, 193
Dermatosyphilis, 729
Dermoid cysts, multiple, 965
Desmoids, 661
Desquamation aberrant en aires de la langue, 1117
épithéliale de la langue, 1117
Desquamative exfoliative erythema, 142
Dhobie itch, 1073
Diabetic gangrene, 399
Diagnosis, general, 84
Diffuse lipoma, 665

Dilatations, acquired vascular, 654
Discoloration, 56
Dissection wounds, 384
Disseminated gangrene, 398
  ringworm, 1043
Distichiasis, 903
Distoma hepaticum, 1109
Diuretics, 104
Double comedo, 967
Dracontiasis, 1104
Dracunculus, 1104
  medinensis, 1104
Dragonneau, 1104
Dressings, fixed, 116
Drug eruptions, 417
Dry eczema, 243
  tetter, 243
Duhring's disease, 340
Durillon, 500
Dusting-powders, 112
Dysidrose, 336
Dysidrosis, 336

Ear, eczema of, 297
  external, fungous disease of, 1075
Echinococcus cutis, 1109
  larva, 1109
Ecthyma, 373
  gangrænosum, 396
  infantile gangréneux, 396
    gangrenous, 396
  syphilitic, 758
  térébrant, 396
  treatment, 375
Ecthymaform syphilid, 758
  syphiloderm, 758
Eczem, 240
Eczema, 240
  acute, 242
  ani, 304
  articulorum, 302
  aurium, 297
  bakers', 258
  barbæ, 300
  capitis, 293
  chronic, 242
  constitutional causes, 255
  crackled, 252
  craquele, 252
  craquelé, 307
  crurale 305
  crurum, 305
  crustosum, 249, 250
  diabeticorum, 257
  diagnosis, 264
    differential, 265
  dry, 243
  epidemic, 188
  epitheliomatosa, 813
  erythematosum, 243
  etiology, 253
  external causes, 257
  faciei, 294
  fissum, 251
  fissured, 251
  follicular, 246, 249
  folliculorum, 249
Eczema, furrowed, 252
  generalized, 306
  genitalium, 303
  gouty, 255
  grocers', 258
  humidum, 243
  ichorosum, 249
  impetiginosum, 249
  infantile, 292
    treatment, 280
  intertrigo, 245, 302
  iodoform, 260, 408
  labiorum, 297
  madidans, 250
  mammæ seu mammarum, 303
  manuum, 300
  marginatum, 272, 1040
  mercuriale, 260
  moist, 243
  mucosum, 245
  narium, 296
  neurotic, 257
  nurses', 259, 408
  œdematosum, 248
  of adjoining mucous surfaces, 307
  of anal region, 304
  of bearded region, 300
  of breasts, 303
  of ear, 297
  of face, 294
  of feet, 301
  of flexures, 302
  of genital region, 303
  of hands, 300
  of legs, 305
  of lips, 297
  of nails, 301
  of nares, 296
  of nostrils, 296
  of scalp, 293
  of umbilicus, 303
  palmarum, 301
  palpebrarum, 294
  papulosum, 246
  parasitic, 252
  pathologic anatomy, 262
  pathology, 260
  pedum, 301
  plantarum, 301
  prognosis, 274
  psoriasiforme, 251
  psoriatic, 221, 251
  pustulosum, 249
  regional and infantile, 292
  rimosum, 251
  rhagadiforme, 251
  rubrum, 249
  sclerosum, 252
  scrofulous, 242
  seborrhoicum, 253, 308
    diagnosis, 316
    etiology, 313
    pathologic anatomy, 315
    pathology, 314
    prognosis, 318
    symptoms, 307
    treatment, 318

Eczema siccum, 243
solare, 259
squamosum, 251
surgeons', 259, 408
surgical, 259
sycosiforme, 249
symptoms, 240
trade, 258
treatment, 275
tuberculous, 242
tyloticum, 252
umbilici, 303
unguium, 301
universal, 306
universale, 245, 306
varicose, 250
varicosum, 243, 305
verrucosum, 252
vesiculosum, 247
washerwomen's, 258
weeping, 243
Eczéma, 240
en aires de la langue 1117
marginée desquamitif de la langue, 1117
Eczematoid epitheliomatosis of nipple, 813
Eczéme, 240
Edema, acute circumscribed, 167, 176
non-inflammatory, 176
angioneurotic, 176
cretinoid, 569
febrile purpuric, 468
of new-born, 560
Einrisse, 65
Ekzem, 240
Elastic skin, 574
Elastic-skin men, 574
Electricity, 110
Electrolysis, 120
Eleidin, 21
Elephant leg, 561
man, 660
Elephantiasis, 561
Arabum, 561
cruris, 563
diagnosis, 568
etiology, 565
genitalium, 563
Græcorum, 855
indica, 561
nævoid, 564
pathology, 566
prognosis, 568
symptoms, 561
telangiectodes, 564, 648
treatment, 568
Éléphantiasis, 561
End-bulbs, 29
Endemic ulcer, 800
English sickness, 1023
Enteritis leprosa, 866
Entozoon folliculorum, 1106
Éphélide lentiforme solaire, 476
Ephelides, 476
Ephidrosis, 1000
cruenta, 1012
discolor, 1009
Epidemic eczema, 188
Epidemic roseola, 445
skin disease, 188
Epidermal exfoliations, 66
Epidermis, 19
exfoliating, 66
of hair-follicle, 41
Epidermolysis bullosa, 360
hereditaria, 360
Epithelial cancer, 817
fibers, 22
layer, 19
Epithelialkrebs, 817
Epithelioma, 817
adenoides cysticum, 618
contagiosum, 612
deep-seated variety, 820
diagnosis, 829
etiology, 825
molluscum, 612
multiple benign cystic, 618
of lip, 823
pathology, 827
prognosis, 830
superficial variety, 818
symptoms, 818
treatment, 831
Épitheliomatose pigmentaire, 835
Épithéliomatose sébacée, 823
Epithéliome, 817
de Paget, 813
Eponychium, 43
Equinia, 385
Erbgrind, 1024
Erectores pilorum, 30
Erntemilbe, 1104
Erosions, 64
Eruption, circinate, of tongue, 1117
creeping, 1107
erythematopapular, 55
erythematous, 774
macular, 774
maculopapular, 55, 774
papulopustular, 58
papulosquamous, 58
papulovesicular, 58
pustulovesicular, 61
vesicobullous, 61
vesicopapular, 58
vesicopustular, 61
Eruptions, drug, 417
feigned, 416
médicamenteuses, 417
medicinal, 417
vaccinal, 460
Erysipelas, 389
ambulans, 391
chronic, 391
faciei perstans, 718
migrans, 391
treatment, 393
white, 390
Érysipéle, 389
Erysipeloid, 394
Erythema, 136
ab igne, 137
annulare, 147
bullosum, 147

Erythema bullosum vegetans, 352
caloricum, 137
congestivum, 136
desquamative exfoliative, 142
elevatum diutinum, 159
endemicum, 161
epidemicum, 164
exsudativum multiforme, 146
fugax, 138
gangrænosum, 396, 398
gyratum, 147
hyperæmicum, 136
induratum, 156
scrofulosorum, 156
treatment, 159
infectiosum, 138
intertrigo, 140
iris, 147
læve, 138
marginatum, 147
migrans, 394, 1117
multiforme, 146
treatment, 151
nodosum, 152
treatment, 155
nuchæ, 137
papulatum, 146
paratrimma, 137
pernio, 137
perstans, 147
scarlatiniforme, 142
scarlatinoides, 142
recidivans, 142
serpens, 394
simplex, 136
solare, 137
traumaticum, 137
tuberculatum 147
urticans, 138
venenatum, 137
vesiculosum, 147
Erythematopapular eruption, 55
Erythematopapules, 55
Erythematous eruption, 774
spots, 55
syphilid, 735
syphiloderm, 735
Erythéme exsudatif multiforme, 146
induré des scrofuleux, 156
noueux, 152
chronique des membres inférieurs, 156
polymorphe, 146
scarlatiniforme desquamatif, 142
scarlatinoïde, 142
Érythémes tuberculeux, 205
Erythrasma, 1071
Erythrodermias, resistant maculopapular scaly, 204
Erythrodermie exfoliante, 183
pityriasique en plaques disseminées, 203
Erythromelalgia, 878
Erythromelia, 879
Etiology, general, 73
Exanthem, lichenoid, 204
psoriasiform, 204
Exanthemata, 430
Exanthematic tuberculosis, 674
Exanthematous syphilid, 735
syphiloderm, 735
Excessive sweating, 1000
Excoriationen, 64
Excoriationes, 64
Excoriations, 64
Exfoliating epidermis, 66
Exfoliatio areata linguæ, 1117
Exfoliations, epidermal, 66
External ear, fungous disease of, 1075
Extractors, comedo, 119

Face, unilateral atrophy of, 553
False cicatrices, 586
Farcin, 385
Farcy, 385
buds, 385
Fat-globules, 25
Fatty neck, 665
tumor, 664
Favus, 1024
circinatus, 1026
des Nagels, 898
ongles, 898
diagnosis, 1032
etiology, 1028
herpeticus, 1026
of general surface, 1026
of nails, 898
of non-hairy parts, 1026
of scalp, 1025
pathology, 1029
prognosis, 1033
scutulum, 1025
symptoms, 1024
treatment, 1033
Febbre scarlatina, 431
Febrile purpuric edema, 468
Febris bullosa, 347
Feet, eczema of, 301
sore, of coolies, 1110
sweating of, 1002
Feigned eruptions, 416
Feigwarze, 520
Fetus, harlequin, 534
Feu sacré, 389
Feuergürtel, 324
Feuermal, 646, 648
Fever blisters, 320
sores, 322
Fibers, epithelial, 22
Herxheimer's spiral, 22
Fibrom, 658
Fibroma, 658
fungoides, 847
hard, 661
lipomatodes, 634
molluscum, 658
pendulum, 658, 659
soft, 661
treatment, 664
Fibromatosis tuberculosa cutis, 678
Fibrome, 658
Fibrosarcoma, 845
Fig-wart, 520
Filaire de Médine, 1105
Filaria medinensis, 1104

Finnen, 971
Finsen hollow compressing lens, 125
  lamp, 125
Finsen-Reyn lamp, 127
Fischschuppenausschlag, 531
Fish-skin disease, 531
Fissural angioma, 650
Fissured eczema, 251
Fissuren, 65
Fissures, 65
Fixed-dressings, 116
Flea, 1096
  foreign, 1096
  sand-, 1104
Flecke, 55
Fleckenmal, 489
Flesh-worms, 967
Flexures, eczema of, 302
Flies, 1097
Flores unguium, 896
Flüchtige, gutartige Plaques der zungenschleimhaut, 1117
Fluted tongue, 1116
Follicle, hair-, 40
Folliclis, 988
Follicular eczema, 246, 249
  muscles, 30
  syphilid, 739
  syphiloderm, 739
Folliculite épilante, 945
Folliculitis, agminate, 1040
  barbæ, 948
  cicatricielles nécrosiques, 988
  decalvans, 945
  et perifolliculites décalvantes agminées, 945
  exulcerans serpiginosa nasi, 989
  necrosing, 988
  nuchæ sclerotisans, 610
Follikelcyste, 965
Foot, fungus, of India, 1081
  Madura, 1081
  perforating ulcer of, 596
  tubercular disease of, 1081
Football impetigo, 370
Fordyce's disease, 1122
    of lips and oral mucous membrane, 1122
Foreign flea, 1096
Fowl-mite, 1097
Fragilitas crinium, 910
    symptomatic, 910
Frambesia, 802
Freckles, 476
  cold, 477
French measles, 445
Fressende Flechte, 682
Frost itch, 881
Frost-bites, 404
Function, heat-regulating, of skin, 49
  protective, of skin, 46
  respiratory, of skin, 48
  secretory, of skin, 50
  sensory, of skin, 47
Fungoid neoplasm, inflammatory, 847
Fungous disease of external ear, 1075
Fungus, chignon, 916
Fungus foot of India, 1081
Furfuraceous scales, 66
Furoncle, 377
Furrowed eczema, 252
  nails, 895
  tongue, 1116
Furrows, 17
Furuncle, 377
Furunculosis, 378
Furunculus, 377
  treatment, 379
Furunkel, 377

GAD-FLY, 1107
Gale, 1098
Galvanocautery, 119
  needle, knife, and spiral points, 709
Gangrene, diabetic, 399
  disseminated, 398
    hysteric, 398
  multiple cachectic, 396
  of skin, multiple disseminated, in infants, 396
    in adults, 398
    spontaneous, 396, 398
  symmetric, 400
Gangrenous ecthyma, infantile, 396
  zoster, 398
Gassa button, 799
Gastro-intestinal antiseptics, 104
Gefässmal, 646
Gelappte Zunge, 1116
Gemeiner Floh, 1096
General exfoliative dermatitis, 183
Genital nerve-corpuscles of Krause, 29
  region, eczema of, 303
Genitocrural region, ringworm of, treatment, 1057
Geographic tongue, 1118
German measles, 445
Germicides, 107
Geschwülste, 59
Geschwüre, 68
Giant urticaria, 167, 176
Gift spots, 896
  of nails, 43
Glanders, 385
Glandulæ glomiformes, 32
  sebaceæ, 35
  sebiferæ, 35
  sudoriferæ, 32
Glassy layer of hair-follicle, 41
Gleoscleroma, 669
Globes, 827
Globules, fat-, 25
Glossite exfoliatrice marginée, 1117
Glossitis areata exfoliativa, 1117
  chronic superficial, 1111
Glossy skin, 583
Gnat, 1097
Gneis, 956
Gouty eczema, 255
Grains, 515
Granular layer, 21
Granuloma fungoides, 847
    diagnosis, 852
    etiology, 850

Granuloma fungoides, pathology, 850
prognosis, 852
symptoms, 847
treatment, 852
pyogenicum, 461
sarcomatodes, 847
trichophyticum, 1044
Granulosis rubra nasi, 1018
Gray hair, 918
Green soap, 112
Grocers' eczema, 258
Grooved tongue, 1116
Ground itch, 1109
Grubs, 967
Grutum, 963
Grützbeutel, 965
Guinea-worm, 1104
disease, 1104
Gum, red, 1019
Gumma, 768
scrofulous, 679
tuberculous, 679
Gummatous syphiloderm, 768
Gune, 1065
Gürtelausschlag, 324
Gutartiges epithelioma, mit kolloider Degeneration, 618
Gutta rosacea, 992
rosea, 992

HAARBALGMILBE, 1106
Haarschwund, 923
Haarzunge, 1119
Hæmorrhœa petechialis, 466
Hair, 37
atrophy of, 909
beaded, 914
bed-, 39
color, 39
changes, 920
development, 39
diseases of, 901
gray, 918
hypertrophy of, 901
moniliform, 914
nodose, 914
pigment, atrophy of, 918
ringed, 920
root-sheath, 42
superfluous, 901
whiteness of, 918
Hair-bulb, 38, 42
Hair-follicle, 40
dermic or external coat, 40
diseases of, 901
epidermic or inner coat, 41
epidermis of, 41
glands, 35
glassy layer, 41
hyaline membrane, 40
prickle-cell layer, 41
vitreous membrane, 41
Hair-papilla, 43
Hair-root, 38
Hair-shaft, 38
Hairiness, 901
Hairy tongue, 1119
Hands, eczema of, 300
sweating of, 1001
Hard fibroma, 661
Harlequin fetus, 534
Harnschweiss, 1013
Harvest bug, 1104
Hautabschürfungen, 64
Hautblastomykose, 1083
Hauthorn, 528
Hautkrebs, 817
Hautrose, 389
Hautschrunden, 65
Head-lice, 1090
Head-lousiness, 1090
Heat, prickly, 1019
Heat-rash, 1019
Heat-regulating function of skin, 49
Hedge-hog skin, 535
Hefenmykose, 1083
Hématidrose, 1012
Hematidrosis, 1012
Hemiatrophia facialis, 553
Hemidrosis, 1012
Hemorrhages, 466
Hemorrhagic sarcoma, 842
variola, 455
Hémorrhagies cutanées, 466
Henle's sheath, 42
Henoch's purpura, 468
Hereditary syphilis, cutaneous manifestations, 771
treatment, 797
Herpes circinatus, 1042
bullosus, 340
desquamans, 1065
facialis, 320
febrilis, 322
gestationis, 340
iris, 147
labialis, 320
phlyctænodes, 340
præputialis, 322
progenitalis, 321
simplex, 320
tonsurans, 1035, 1037, 1042
barbæ, 1045
capillitii, 1042
circumscriptus, 1037
maculosus, 179, 1039
zoster, 324
diagnosis, 332
etiology, 328
gangrænosus, 326
hæmorrhagicus, 326
pathology, 329
prognosis, 332
symptoms, 324
treatment, 333
Herpés circiné, 1037
parasitaire, 1037
tonsurant, 1042
vulgaire, 320
Herpetic fever, 321
Herxheimer's spiral fibers, 22
Hide-bound skin, 547
Hidrocystoma, 1015
High-frequency current, 128

Hirsuties, 901
Hives, 164
Hoariness, 918
Holzbock, 1097
Honey-comb ringworm, 1024
Horn, cutaneous, 528
Hornauswuchs, 528
Hornplättchen, 66
Horny excrescence, 528
  layer, 19, 20
  tumor, 528
Hühnerauge, 497
Hungarian itch, 1100
Hutchinson's crateriform ulcer, 822
  teeth, 772
Huxley's sheath, 42
Hyaline layer, 21
  membrane of hair-follicle, 40
Hyaloma, 644
  der Haut, 644
Hyalome, 644
Hybrid measles, 445
Hydradénomes éruptifs, 618
Hydroa æstivale, 334
  bulleux, 340
  herpetiforme, 340
  puerorum, 334
  vacciniforme, 334
Hydrocystoma, 1015
  treatment, 1018
Hyperemias, 136
Hyperesthesia, 876
Hyperidrose, 1000
Hyperidrosis, 1000
  manuum, 1001
  oleosa, 956
  pedum, 1002
  treatment, 1004
Hyperkeratose figureé centrifuge atrophiante, 541
Hyperkeratosis eccentrica, 541
  figurata centrifuga atrophicans, 541
  linguæ, 1119
Hypertrichiasis, 901
Hypertrichosis, 901
  acquired, 902
  congenital, 901
  partialis, 901
  transitory, 902
  treatment, 904
  universalis, 901
Hypertrophia pilorum, 901
Hypertrophic scar, 71, 601, 605
Hypertrophie épithéliale filiforme, 1119
Hypertrophies, 476
Hypertrophy of hair, 901
  of nail, 889
Hyphogenous sycosis, 1045
  alopecia, 939
Hypoderm, 24
Hyponomoderma, 1107
Hyponychium, 43
Hysteric gangrene, 398
  stigmata, 1012

Ichthyose, 531
Ichthyosis, 531
Ichthyosis, acquired, 536
  congenita, 531, 533
  diagnosis, 538
  etiology, 536
  follicularis, 512
  hystrix, 534
  intra-uterine, 533
  linguæ, 1111
  mixed variety, 535
  nacrée, 532
  nigricans, 532
  nitida, 532
  palmaris et plantaris, 501
  pathology, 537
  prognosis, 539
  sauroderma, 533
  scutelata, 533
  sebacea, 534, 956, 957
    cornea, 512
  serpentina, 533
  simplex, 531
  symptoms, 531
  treatment, 539
  vera, 531
Idiopathic atrophy, diffuse, of skin, 589
    general, of skin, 589
    progressive, of skin, 589
  chloasma, 479
  premature alopecia, 925
Idrosis, 1000
Ignis sacer, 324
Impetigiform syphilid, 757
  syphiloderm, 757
Impetigo circinata, 367, 369
  contagiosa, 367
    bullosa, 368
    treatment, 373
    varieties, 367
  figurata, 367, 369
  football, 370
  herpetiformis, 375
  parasitica, 367
  rodens, 988
  simplex, 365, 367, 369
  sparsa, 365, 367
  staphylogenes, 367, 369
  streptogenes, 367
  syphilitica, 757
  vulgaris, 367
Impetigos, the, 365
Index, opsonic, 108
India, fungus foot of, 1081
  ringworm, 1065
India-rubber men, 574
Infantile eczema, 292
    treatment, 280
  gangrenous ecthyma, 396
  syphilis, 771
Infants, multiple disseminated gangrene of skin in, 396
Infective angioma, 657
Inflammations, 146
Inflammatory fungoid neoplasm, 847
Insensible perspiration, 50
Intertrigo, 140
Intra-uterine ichthyosis, 533
Iodid acne, 975

Iodin acne, 975
Iodoform dermatitis, 408
  eczema, 260, 408
Italian itch, 1100
Itch, 1098
  army, 1100
  bakers', 258
  barber's, 1045
  barn, 1051
  dhobie, 1073
  frost, 881
  grocers', 258
  ground, 1109
  Hungarian, 1100
  Italian, 1100
  laundryman, 1073
  lumberman's, 881, 1101
  Malabar, 1065
  Norwegian, 1099
  Polish, 1100
  prairie, 881, 1101
  swamp, 881, 1101
  water-, 1110
  winter, 881
Itching, 53
Ivy poisoning, 409
Ixodes, 1097

Jacob's ulcer, 820
Jaw, lumpy-, 1076
Jigger, 1104
Juckblättern, 191

Kahlheit, 923
Kandahar sore, 799
Kelis, 603
Keloid, 71, 603
  acne, 610
  Alibert's, 603
  lupus, 684
  of Addison, 551
Kelos, 603
Keratoangioma, 544
Keratodermia eccentrica, 541
  symmetric, 501
Kératodermie plantaire et palmaire, 501
Keratohyalin, 21
Keratolysis neonatorum, 189
Keratoma, 500, 501
  diffusum, 533
  palmare et plantare hæreditarium, 501
Keratose pilaire, 508
Keratosis follicularis, 512
    contagiosa, 516
  palmaris et plantaris, 501
      treatment, 504
  pigmentosa, 518
  pilaris, 508
    treatment, 510
  senilis, 505
  treatment, 507
Kerion, 1043
  ringworm, 1043
  tinea, 1043
Kleienflechte, 1067
Knollen, 59
Knötchen, 57
Knoten, 58
Kohlenbeule, 381
Krätze, 1098
Kraurosis vulvæ, 592
Krause's corpuscles, 27, 29
  genital nerve-corpuscles, 29
Krusten, 67
Kummerfeld's lotion, 985, 998
Kupferfinne, 992
Kupferrose, 992
Kyste sébacé, 965

La lèpre, 855
La perlèche, 1124
La rose, 389
La Verruga, 809
Lafa Tokelau, 1065
Lamellæ, 67
Lamp, Finsen, 125
  Finsen-Reyn, 127
Land scurvy, 469
Landkartenzunge, 1117
Langerhans, cells of, 22
Langer's lines of cleavage, 17
Langue montagneuse, 1116
  noire, 1119
    pileuse, 1119
  plissée, 1116
  scrotale, 1116
Lanugo, 38
Larva, echinococcus, 1108
  migrans, 1107
Lassar's paste, 115, 286
Laundryman itch, 1073
Läusesucht, 1088
Laxatives, vegetable, 104
Layer, dead, 20
  epithelial, 19
  glassy, of hair-follicle, 41
  granular, 21
  horny, 19, 20
  hyaline, 21
  malpighian, 19
  mucous, 19
  papillary, 23
  prickle, 22
  prickle-cell, of hair-follicle, 41
  shining, 20
  thorny, 22
  translucent, 20
Le peta, 1065
Leberflecken, 478
Leg, Barbadoes, 561
  eczema of, 305
  elephant, 561
  ulcer, 250
  weeping, 250
Leichdorn, 497
Leiomyoma, 666
L'endurcissement athrepsique, 558
Lenticular papular syphilid, 741
    syphiloderm, 741
Lentigo, 476
  maligna, 835
Lentilles, 476
Leontiasis Satyriasis, 85
Leper claw, 864

Lepidophyton, 1066
Lepothrix, 918
Lepra, 214, 855
alphos, 214
anesthetic, 862
Arabum, 855
course, 865
diagnosis, 871
enteritis, 866
etiology, 867
macular, 860
mixed type, 865
mutilans, 864
nervorum, 862
nodular, 860
pathology, 869
phthisis, 866
prognosis, 872
stage of incubation, 857
of invasion, 858
symptoms, 856
treatment, 873
tubercular, 860
Leprosy, 855
Lombardian, 161
Leptus, 1104
Americanus, 1104
autumnalis, 1104
irritans, 1104
L'érythéme pellagreux, 161
Lesions, configuration, distribution, and other features, 71
consecutive, 64
elementary, 55
primary, 55
secondary, 64
Leucoplasie, 1111
Leukæmia cutis, 845
Leukasmus, 578
congenital, 576
Leukemia cutis, 853
Leukoderma, 578
congenital, 576
syphilitic, 737
Leukokeratosis buccalis, 1111
Leukoma, 1111
Leukonychia, 896
Leukopathia, 578
acquired, 578
congenital, 576
unguium, 896
Leukoplakia, 1111
buccalis, 1111
treatment, 1115
Leukoplasia, 1111
Leukotrichia annularis, 920
Lice, crab-, 1094
head-, 1090
Lichen, 58
agrius, 246
annularis, 195
annulatus, 311
circumscriptus, 246, 311
gyratus, 311
lividus, 206
obtusus, 196
pilaris, 508, 511
planus, 194
hypertrophicus, 196
treatment, 201
verrucosus, 196
psoriasis, 194, 208
ruber, 208
acuminatus, 208
moniliformis, 196
planus, 194
scrofulosorum, 205
scrofulosus, 205
treatment, 208
simplex, 246
syphilitic, 739
tropicus, 1019
urticatus, 167
variegatus, 204
Lichenification, 58
Lichenoid exanthem, 204
Lichénoïde lingual, 1117
Lineæ albicantes, 587
gravidarum, 587
Linear atrophy, 586
nævus, 491
scarifications, 119
Lines, atrophic, 587
of cleavage, Langer's, 17
Lingua geographica, 1118
nigra, 1119
plicata, 1116
Linimentum exsiccans, 289
Linsenflecken, 476
Linsenmal, 489
Liodermia essentialis cum melanosi et telangiectasia, 835
Lip and oral mucous membrane, Fordyce's disease of, 1122
eczema of, 297
epithelioma of, 823
parasitic disease of, 1124
Lipoma, 664
circumscribed 664
diffuse, 665
Liquor carbonis detergens, 284
picis alkalinus, 291
Liver-fluke, 1109
Liver-spots, 478, 1067
Local asphyxia, 400
Lombardian leprosy, 161
Loose skin, 572, 573
Lotio alba, 984
Lotion, Kummerfeld's, 985, 998
Lotions, 113
calamin-zinc-oxid, 113
coal-tar, 284
Louse, chicken-, 1097
Lousiness, 1088
body-, 1092
head-, 1090
Lues, 728
venerea, 728
Lumberman's itch, 881, 1101
Lumpy-jaw, 1076
Lunula, 44
Lupoid acne, 988
sycosis, 945
Lupus, 682
disseminatus, 688

Lupus elephantiasicus, 685
elevatus, 685
érythémateux, 714
fixé, 716
erythematodes, 714
erythematosus, 714
course, 719
diagnosis, 722
discoides, 715
disseminatus, 715, 718
etiology, 720
of mucous membrane, 719
pathology, 721
prognosis, 723
symptoms, 714
treatment, 724
exedens, 683
exfoliativus, 684
exulcerans, 683
hypertrophicus, 684
keloides, 684
lymphaticus, 630
maculosus, 682
nævus, 657
nodosus, 685
œdematosus, 685
of mucous membranes, 686
papillomatosus, 685
pernio, 717
planus, 685
sclerosus, 684
sebaceus, 714
serpiginosus, 685
tuberculeux, 682
tumidus, 685
verrucosus, 685
vorax, 682
vulgaire, 682
vulgaris, 682
course, 691
diagnosis, 699
etiology, 692
pathology, 694
prognosis, 702
sclerosus erythematoides, 687
symptoms, 682
treatment, 703
Lustseuche, 728
Lymph tumors, 564
Lymphadénie cutanée, 847
Lymphadenitis, syphilitic, 773
Lymphadenoma cutis, 854
Lymphangiectasis, 544, 627
Lymphangiectodes, 630
Lymphangioma, 626
capillare varicosum, 630
cavernosum, 630
cavernous, 630
circumscriptum, 630
treatment, 633
cystic, 629
simple, 628, 630
superficiale simplex, 630
tuberosum cutis multiplex, 629
Lymphangiome circonscrit vesiculeux, 630
Lymphangitis tuberculosa cutanea, 678
Lymphatics, 26
Lymphodermia perniciosa, 847
Lymphoid corpuscles, 25
Lymphosarcoma, 845
Lymph-scrotum, 564

Macrocheilia, 629
Macroglossia, 629
Maculæ, 55
atrophicæ, 586
cæruleæ, 1095
Macular eruption, 774
leprosy, 860
syphilid, 735
syphiloderm, 735
Macules, 55
Maculopapular eruption, 55, 774
Maculopapules, 55
Madura foot, 1081
Madurafuss, 1081
Mal de los pintos, 1074
Mal de Meleda, 504
Mal de misère, 161
Mal del pinto, 1074
Mal del Sole, 161
Mal des pieds et des mains, 164
Mal perforant du pied, 596
Mal Rosso, 161
Malabar itch, 1065
Maladie de Carrion, 809
de morvan, 598
de Paget, 813
de Paris, 164
pédiculaire, 1088
Malassez's spores, 314
Malignant papillary dermatitis, 813
pustule, 386
syphilis, 731
Malis pediculi, 1088
Malleus, 385
Malpighian layer, 19
Malum perforans pedis, 596
Mammillaris maligna, 813
Mange, Texas, 881
Marmoraceous pigmentary syphilid, 738
Masern, 440
Matrix of nail, 44
Mazamorro, 1110
Measles, 440
catarrhal symptoms, 441
complications, 441
diagnosis, 443
eruption, 440
etiology, 442
fever, 441
French, 445
German, 445
hybrid, 445
pathology, 442
prognosis, 443
symptoms, 440
treatment, 444
Mechanical measures, 119
Medicated soaps, 112
Medicinal eruptions, 417
Medinawurm, 1105
Megalosporon ectothrix, 1036
endothrix, 1036

Meibomian glands, 36
Meissner's corpuscles, 27, 28
Melanidrosis, 1009
Melanoderma, 479
Melanosis lenticularis progressiva, 835
Melanotic carcinoma, 813
  sarcoma, 841
Melasma, 479
Mentagra parasitica, 1045
Meralgia paresthetica, 876
Mercurial eczema, 260
Merkel's touch-cells, 29
Microcautery, 119
Microsporon Audouini, 938, 1036
  decalvans, 938
Miliare, 1019
  crystalline, 1014
Miliaria, 1019
  alba, 1020
  crystallina, 1014
  papulosa, 1020
  rubra, 1020
  treatment, 1022
  vesiculosa, 1020
Miliary acuminated pustular syphiloderm, 754
  fever, 1023
  papular syphilid, 739
    syphiloderm, 739
  sweat rash, 1023
  tuberculosis of skin, 672
Milium, 963
  colloid, 644
Milk crust, 247
Milky exudation of scrotum, 564
Milzbrand, 386
Milzbrandcarbunkel, 386
Mineral waters, natural, 109
Mite, bird-, 1097
  fowl-, 1097
  mower's, 1104
Mitesser, 967
Moist eczema, 243
  papule, 750
  tetter, 243
  wart, 520
Mole, 489
  pigmentary, 489
  warty, 518
Molluscum body, 616
  cell, 616
  cholésterique, 634
  contagiosum, 612
    treatment, 618
  corpuscle, 616
  epitheliale, 612
  fibrosum, 658
  giganteum, 613
  non-contagiosum, 658
  pendulum, 658
  sebaceum, 612
  simplex, 658
  vrai, 658
Monilethrix, 914
Moniliform hair, 914
Morbilli, 440
Morbus elephas, 561
Morbus maculosus Werlhoffii, 469
  pedicularis, 1088
  pediculosis, 1088
  pedis entophyticus, 1081
Morococcus, 314
Morphea, 551
Morphœa guttata, 551, 589
Morvan's disease, 598
Morvansche Krankheit, 598
Morve, 385
Mosquito, 1097
Moth patches, 478
Mother wart, 517
Mother's mark, 489, 646
Motor nerves, 30
Mower's mite, 1104
Mucor dermatosis, 1102
Mucous layer, 19
  membrane, lupus erythematosus of, 719
    lupus of, 686
    tinea of, 1039
  orifices, sebaceous glands, 35
  papule, 750
  patch, 750 751
  surfaces adjoining, eczema of, 307
Mulberry nævus, 649
Multiple benign cystic epithelioma, 618
      treatment, 622
    tumor-like new growths, 633
  cachectic gangrene, 396
  comedo, 967
  dermoid cysts, 965
  disseminated gangrene of skin in infants, 396
  gangrene of skin in adults, 398
  Granulationsgeschwülste, 847
  pigmented sarcoma, 842
Muscle tumor, 666
Muscles, 30
  arrectores or erectores pilorum, 30
  follicular, 30
  non-striated, 30
  smooth, 30
  striated, 30
Mycetoma, 1081
Mycétome, 1081
Mycomyringitis, 1075
Mycosis fungoide, 847
  fungoides, 847
  microsporina, 1067
Myelosyringosis, 598
Myom, 666
Myoma, 666
  dartoic, 667
Myome cutané, 666
Myringomycosis, 1075
  aspergillina, 1075
Myxadenitis labialis, 1121
Myxedema, 569
Myxœdem, 569
Myxœdème, 569

Naevi epitheliaux kystiques, 618
  vasculaires et papillaires, 622
Nævoid elephantiasis, 564
Nævus araneus, 648, 655
  flammeus, 648

Nævus, linear, 491
lipomatodes, 490
lupus, 657
molluscoide, 658
mulberry, 649
pigmentaire, 489
pigmentosus, 489
treatment, 494
pilosus, 489
pulsating, 648
sanguineus, 646
simplex, 648
spider, 648, 655
spilus, 489
tuberosus, 649
vasculaire, 646
vascularis, 646
vasculosus, 646
treatment, 651
venous, 649
verrucosus, 490
Nail-bed, 44
Nail-body, 43
Nail-fold, 43
Nail-groove, 43
Nail-root, 43
Nail-skin, 43
Nail-wall, 43
Nails, 43
atrophy of, 894
claw-, 890
development, 45
diseases of, 889
eczema of, 301
favus of, 898
furrowed, 895
gift spots, 43
hypertrophy of, 889
matrix, 44
ringworm of, 898
shedding of, 896
spoon-, 895
white, 896
spots, 43
Narbe, 601
Narben, 70
Nares, eczema of, 296
Nässende Flechte, 240
Natal sore, 799
Neck, fatty, 665
Necrosing folliculitis, 988
Necrotic granuloma, 988
Nerve tumor, 668
Nerve-corpuscles, Krause's genital, 29
Nervenschmerz der Haut, 877
Nervenschwamm, 668
Nerves, 27
motor, 30
trophic, of skin, 47
vasomotor, 30
of skin, 47
Nervous papillæ, 24
Nesselausschlag, 164
Nesselsucht, 164
Nettlerash, 164
Neuralgia of skin, 877
Neurofibromatosis, 661
Neurom, 668
Neuroma, 668
Neuroses, 876
Neurotic eczema, 257
Névrome, 668
New growths, 601
multiple benign tumor-like, 633
New-born, edema of, 560
scleroma of, 558
Nigritie de la langue, 1119
Nipple, eczematoid epitheliomatosis, 813
Paget's disease of, 813
Nodose hair, 914
Nodosité des poils, 914
Nodular carcinoma, 812
leprosy, 860
syphilid, 761
syphiloderm, 761
Nodules, 58
Noli me tangere, 817, 819
Norwegian itch, 1099
Nostrils, eczema of, 296
Nurses' eczema, 259, 408

Œdema angioneuroticum, 176
circumscriptum, 176
cutis circumscriptum acutum, 176
neonatorum, 560
Œdème aigu, 176
Oeil de perdrix, 497
Œstrus, 1107
Ohio scratches 881
Oïdiomycosis of skin, 1083
Oil-glands, 35
Oils, 116
Ointments, 114
Onychatrophia, 894
Onychauxis, 889
Onychia, 891
in syphilis, 734
Onychogryphosis, 890
Onychomycose favique, 898
trichophytique, 898
Onychomycosis, 890, 898
favosa, 898
tonsurans, 898
trichophytina, 898
when due to favus fungus, 898
to ringworm fungus, 898
Opaline patches, 752
Operative measures, 119
Opsonic index, 108
Opsonins, 108
Oriental boil, 799
sore, 799
Orientbeule, 799
Oroya fever, 809
Osmidrosis, 1007
Otitis externa parasitica, 1075
Otomycosis, 1075

Pachydermatocele, 572
Pachydermia, 561
Pacinian corpuscles, 27
Paget's disease, 813
of nipple, 813
treatment, 817

Paget's Krankheit, 813
Palmar syphiloderm, 744
Panaris analgésique, 598
Panighao, 1110
Panna hépatique, 478
Panniculus adiposus, 25
Papilla, hair-, 43
Papillæ, 23
  compound, 23
  fungiformes, 29
  nervous, 24
  vascular, 24
Papillary layer, 23
  varices, 655
Papilloma, 517
  of sole, 518
Papillomatous syphilid, 765
  syphiloderm, 765
Papular eczema, 246
  persistent dermatosis, 193
  syphilid, 739
    acuminated, 739
    lenticular, 741
    miliary, 739
  syphiloderm, 739
    acuminated, 739
    flat, 741
      large, 741
      small, 741
    lenticular, 741
    miliary, 739
Papule, moist, 750
  mucous, 750
Papules, 57
  squamous, 58
Papulopustular eruption, 58
Papulopustules, 58, 63
Papulosquamous eruption, 58
  syphilid, 744
  syphiloderm, 744
Papulotubercular syphiloderm, 761, 763
Papulovesicles, 58
Papulovesicular eruption, 58
Paquelin cautery, 119
Parakeratosis variegata, 202
Paralysis, analgesic, with whitlow, 598
Parangi, 802
Parapsoriasis, 204
  guttata, 204
  lichenoides, 204
Parasitäre Bartfinne, 1045
Parasites, animal, diseases due to, 1088
  vegetable, diseases due to, 1024
Parasitic acne, 977
  affections, 1024
  disease of lips, 1124
  eczema, 252
  mentagra, 1045
  sycosis, 1045
Parasiticides, 117
Parasitische Bartfinne, 1045
Paratuberculoses, cutaneous, 205
Paronychia, 890, 891
  in syphilis, 734
  simple 892
Pars papillaris, 23
  reticularis, 24
Paste, Lassar's, 286
  peeling, 987
  salicylic acid, 286
Paste-pencils, 117
Pastes, 115
Pathologic scars, 601
Pathology, general, 82
Pearls, 827
Pearly tubercles, 963
Peau lisse, 583
Pediculosis, 1088
  capillitii, 1090
  capitis, 1090
  corporis, 1092
  pubis, 1094
  vestimenti seu vestimentorum, 1092
Peitschenwurm, 1105
Pelade, 930
Peliosis rheumatica, 468
Pellagra, 161
Pellagre, 161
Pemphigus, 346
  acutus, 347
    neonatorum, 349
  chronicus, 350
  circinatus, 340
  composé, 340
  contagiosus, 349
  diagnosis, 357
  epidemicus, 348, 349
  etiology, 355
  febrilis, 347
  foliaceus, 351
  gangrænosus, 396
  hæmorrhagicus, 351
  neonatorum, 349
    contagiosus, 349
  pathologic anatomy, 357
  pathology, 356
  prognosis, 359
  prurigineux, 340
  pruriginosus, 340, 351
  symptoms, 347
  syphiliticus, 761
  treatment, 359
  vegetans, 352
  virginum, 347
Pendjeh sore, 799
Perforating ulcer of foot, 596
Perforirendes Fussgeschwür, 596
Perifolliculitis suppurative conglomerata, 1040
Perionychium, 43
Perspiration. See *Sweat.*
Peruvian warts, 809
Petechial variola, 455
Petite-vérole, 451
Phlegmona diffusa, 383
Phlegmonous cellulitis, 383
Phosphoridrosis, 1014
Phthiriasis, 1088
  capitis, 1090
  corporis, 1092
  seu pediculosis palpebrarum, 1094
Phthisis leprosa, 866
Phtiriase, 1088
  de la tête, 1090

Phtiriase du corps, 1092
Phymata, 59
Physiology of skin, 46
Pian, 802
  fongoïde, 847
Piebald negroes, 576
  skin, acquired, 578
Pied de Madura, 1081
  negroes, 576
Piedro, 916
Pigment, 31
  hair, atrophy of, 918
Pigmentary mole, 489
  syphilid, marmoraceous, 738
    retiform, 738
  syphiloderm, 737
    retiform, 738
Pigmented carcinoma, 813
  sarcoma, multiple, 842
Pigmentflecken, 478
Pigmentmal, 489
Pigmentnævus, 489
Pili annulati, 920
Pimples, 57
Pinto disease, 1074
Pityriasis capitis, 308
  linguæ, 1117
  maculata et circinata, 179
  pilaris, 208, 508
  rosé, 179
  rosea, 179
  rubra, 183, 184
    pilaire, 208
    pilaris, 208
      treatment, 214
  versicolor, 1067
  versicolore, 1067
Plantar syphiloderm, 744
Plaques blanches de la bouche, 1111
    des fumeurs, 1111
  jaunâtres des paupières, 634
  muqueuses, 750
  opalines, 1111
  ortiées, 56
  transitory benign, of tongue, 1117
Plasma cells, 696
Plaster-mulls, 116
Plaster-muslins, 116
Plica, 1090
  neuropathica, 908
  polonica, 908, 1090
Pocken, 451
Podelcoma, 1081
Poils accidentels, 901
Pointed condyloma, 520
  wart, 520
Poisoning, ivy, 409
  rhus, 409
Poliosis, 918
  circumscripta hereditaria, 919
Poliothrix, 918
Polish itch, 1100
Polyidrosis, 1000
Polypapilloma tropicum, 802
Polytrichia, 901
Pomphi, 56
Pompholyx, 336
Pompholyx, treatment, 339
Porcupine men, 535
Porokératose, 541
Porokeratosis, 541
Porrigo contagiosa, 367
  decalvans, 930
  favosa, 1024
  furfurans, 1042
  lavalis, 1024
  lupinosa, 1024
  scutulata, 1024
Porrigophyta, 1024
Port-wine mark, 647, 648
  stain, 648
Postmortem pustule, 384
Potash soaps, 112
Pou de bois, 1097
Powder-stains, 488
Pox, 728
Prairie itch, 881, 1101
Premature alopecia, 925
    idiopathic, 925
    symptomatic, 926
  canities, 919
Prickle layer, 22
Prickle-cell layer of hair-follicle, 41
Prickle-cells, 22
Prickly heat, 1019
Protective function of skin, 46
Protozoic disease, 1085
Prurigo, 191
  agria, 191
  ferox, 191
  mitis, 191, 192
  summer, 335
  treatment, 193
Pruritus, 53, 879
  ani, 880
  bath, 882
  diagnosis, 883
  etiology, 882
  generalized, 880
  hiemalis, 881
  local, 880
  pathology, 883
  prognosis, 884
  scroti, 880
  senilis, 880
  symptoms, 879
  treatment, 884
  universalis, 880
  vulvæ, 880
Pseudochromidrosis, 1012
Pseudoleukemia cutis, 853, 854
Psoriasiform exanthem, 204
Psoriasis, 214
  annulata, 217
  circinata, 217
  course, 221
  diagnosis, 226
  diffusa, 217
  discoidea, 216
  etiology, 221
  guttata, 216
  gyrata, 217
  inveterata, 217
  lichen, 194, 208

Psoriasis nummularis, 216
of scalp, treatment, 238
of tongue, 1111
ostreacea, 217
pathology, 223
prognosis, 228
punctata, 216
rupioides, 217
seborrheic, 221
symptoms, 214
treatment, 229
universalis, 217
verrucosa, 218
Psoriatic eczema, 221, 251
Psorospermose folliculaire végétante, 512
Psorospermosis, 512
cutaneous, 813
Puce commune, 1096
de sable, 1104
Pulex irritans, 1096
penetrans, 1104
Pulsating nævus, 648
Punaise des lits, 1096
Punch, 119
cutaneous, 488
Punctate scarifications, 119
Purpura, 466
arthritic, 468
diagnosis, 472
etiology, 469
fulminans, 469
hæmorrhagica, 469
Henoch's, 468
pathology, 471
prognosis, 472
rheumatica, 468
scorbutica, 474
senilis, 467
simplex, 467
symptoms, 466
treatment, 473
urticans, 467
Purpuric variola, 455
Puru, 799
Pusteln, 62
Pustula maligna, 386
Pustulæ, 62
Pustular eczema, 249
scrofuloderm, large flat, 679
small, 680
syphiloderm, 753, 775
large acuminated, 755
flat, 758
miliary acuminated, 754
small acuminated, 754
flat, 757
Pustule, malignant, 386
maligne, 386
postmortem, 384
Pustules, 62
Pustulocrustaceous syphilid, 757, 759
syphiloderm, 757, 759
Pustulo-ulcerative syphilid, 760
syphiloderm, 759
Pustulovesicular eruption, 61
Pyodermatitis, 369
Pyodermia, 369
Pyodermitis, 369
Pyogenic dermatitis, 369

Quaddeln, 56
Quincke's disease, 176
Quinquaud's disease, 946
Quirica, 1074

Radiotherapy, 120
Radium, 124
Rash, heat-, 1019
miliary sweat, 1023
tooth, 256
vaccination, 460
wandering, 1117
Raynaud's disease, 400
Raynaud'sche Krankheit, 400
Recklinghausen's disease, 661
Recurrent summer eruption, 334
Red chromidrosis 1012
gum, 1019
Rents, 65
Resistant maculopapular scaly erythrodermias, 204
Respiratory function of skin, 48
Rete, 19
malpighii, 19, 21
Reticulating colliquation, 449, 456
Retiform pigmentary syphilid, 738
syphiloderm, 738
Rhagaden, 65
Rhagades, 65
Rheumatism of skin, 877
Rhinoceros skin, 535
Rhinochoprion, 1104
Rhinophyma, 994
Rhinoscleroma, 669
Rhinosclérome, 669
Rhus poisoning, 409
Ribbed tongue, 1116
Ridges, 17
Rimæ, 65
Ringed hair, 920
Ringelhaare, 920
Ringworm, 1035
bald, 1043
black-dot, 1043
Bowditch Island, 1065
Burmese, 1065
Chinese, 1065
crusted, 1024
disseminated, 1043
honey-comb, 1024
India, 1065
kerion, 1043
of beard, 1045
of bearded region, 1045
diagnosis, 1048
etiology, 1050
symptoms, 1045
treatment, 1064
of body, 1037
of general surface, 1037
diagnosis, 1041
symptoms, 1037
treatment, 1057
of genitocrural region, treatment, 1057

Ringworm of glabrous skin, 1037
of nails, 898
of non-hairy surface, 1037
of scalp, 1042
diagnosis, 1044
symptoms, 1042
treatment, 1058
pathology, 1053
prognosis, 1054
scaly, 1065
sycosis, 950
Tokelau, 1065
treatment, 1056
yaws, 805
Ringworm-like patches of tongue, 1117
Risipola Lombarda, 161
Ritter's disease, 189
Rodent ulcer, 819
Röntgen-ray dermatitis, 411
treatment, 120
Root-sheath, outer or external, 41
proper, of hair, 42
Rosacea, 654, 992
Rose, 389
Roseola, 138
epidemic, 445
scarlatiniforme, 142
syphilitica, 735
Roséola épidémique, 445
Rosolia, 440
Rötheln, 445
Rothlauf, 389
Rotz, 385
Rotzkrankheit, 385
Rougeole, 440
Rouget, 1104
Rubella, 445
Rubeola, 440. See also *Measles*.
Rupia, 760, 761
escharotica, 396

SACCHAROMYCOSIS hominis, 1083
Salicylated paste, 286
Salicylic acid paste, 286
Salines, 104
Salt rheum, 240, 243
Salve-mulls, 116
Salve-muslins, 116
Salve-pencils, 117
Salzfluss, 240
Sandfloh, 1104
Sand-flea, 1104
Sandy sweat, 1013
Sapo mollis, 112
viridis, 112
Sarcoma cutis, 839
treatment, 846
generalized non-pigmented, 840
hemorrhagic, 842
localized non-pigmented, 839
melanotic, 841
multiple pigmented, 842
of skin, 839
primary single non-pigmented, 839
Sarcomatose cutanée, 839
Sarcomatosis cutis, 839
generalis, 847
Sarcome angioplastique réticulé, 657
cutané, 839
Sarcoptes hominis, 1099
scabiei, 1099
Sauriasis, 531
Savill's disease, 188
Scabies, 1098
animal, 1100
treatment, 1102
Scabs, 67, 68
Scales, 66
crusty, 67
furfuraceous, 66
Scalp, eczema of, 293, 294
favus of 1025
psoriasis of, treatment, 238
ringworm of, 1042
Scaly crusts, 67
ringworm, 1065
Scar, 601
hypertrophic, 601, 605
Scarf-skin, 19
Scarifications, linear, 119
punctate, 119
Scarifier, multiple, 710
single, 710
Scarlatina, 431
diagnosis, 437
etiology, 435
pathology, 435
prognosis, 437
sine eruptione, 432
surgical, 436
symptoms, 431
treatment, 438
Scarlatine, 431
Scarlet fever, 431
Scars, 70
hypertrophic, 71
pathologic, 601
traumatic, 601
Scar-tissue, 601
Scharlachfieber, 431
Scherende Flechte, 1035, 1037, 1042
Schleimhautpapeln, 750
Schmeerfluss, 956
Schönlein's disease, 468
Schuppen, 66
Schuppenflechte, 214
Schwarze Haarzunge, 1119
Schweissflechte, 1019
Schweissfrieselausschlag, 1014
Sclerema, 547
neonatorum, 558
of new-born, 558
Sclérème des adultes, 547
des nouveau-nés, 558
Scleriasis, 547
Sclerodactylia, 549
Scleroderma, 547
circumscribed, 551
diagnosis, 556
etiology, 553
neonatorum, 558
pathology, 554
prognosis, 556
symptoms, 547

Scleroderma, treatment, 557
Sclérodermie, 547
Scleroma adultorum, 547
Scleronychia, 890
Scorbuto alpino, 161
Scorbutus, 474
Scratch-marks, 64
Scrofulide érythémateuse, 714
  tuberculeuse, 682
Scrofuloderm, large flat pustular, 679
  small pustular, 680
Scrofuloderma, 678
Scrofulogummata, 679
Scrofulous eczema, 242
  gumma, 679
Scrotal tongue, 1116
Scrotum, lymph-, 564
  milky exudation of, 564
  pruritus of, 880
Scurvy, 474
  land, 469
  sea, 474
Sebaceous cyst, 965
  glands, 35
    adenoma of, 622
    diseases of, 956
    of mucous orifices, 35
  secretion, 51
  tumor, 965
Seborrhea, 956
  treatment, 960
Séborrhée, 956
Seborrheic psoriasis, 221
  wart, 518
Seborrhœa congestiva, 714
  corporis, 308, 311
  figurée, 311
  nigricans, 1009
  oleosa, 956
  papulosa seu lichenoides, 311
  sicca, 308, 957
  simplex, 956
Sebum, 51
Secretory function of skin, 50
Segmental tubercular syphiloderm, 762
Senile atrophy of skin, 584
Sensible perspiration, 50
Sensory function of skin, 47
Serpiginous tubercular syphiloderm, 762
Shedding of nails, 896
  of skin, 143
Shingles, 324
Shining layer, 20
Skin, alligator, 532
  blastomycosis of, 1083
  cancer, 817
  deciduous, 143
  disease, epidemic, 188
  elastic, 574
  glossy, 583
  hedge-hog, 535
  hide-bound, 547
  loose, 572, 573
  rhinoceros, 535
  senile atrophy, 584
  wrinkled, 573
Skin-shedding, 143
Sklerodermie, 547
Small-pox, 451
Smegma, 37
Smokers' patches, 782, 1111, 1113
Smooth muscles, 30
Soaps, 111
  green, 112
  medicated, 112
  potash, 112
  soda, 112
  superfatty, 112
Soda soap, 112
Soft fibroma, 661
Sole, papilloma of, 518
Sommersprossen, 476
Sore feet of coolies, 1110
Sores, aphthous, 752
  cold, 322
  fever, 322
Spargosis, 561
Sphaceloderma, 396
Spider carcinoma, 655
  nævus, 648, 655
Spiders, 1097
Spindelhaare, 914
Spiradenoma, 625
Spiral fibers, Herxheimer's, 22
Spirochæta pallida, 777
Spiroma, 625
Spitzblattern, 447
Spirtzencondylom, 520
Spitzenwarze, 520
Splenic fever, 386
Spontaneous gangrene of skin, 396, 398
Spoon-nail, 895
Sporadic cretinism, 571
Sporotrichial infection, 1086
Spots, 55
  atrophic, 586
  erythematous, 55
  gift, 896
    of nails, 43
  liver, 478, 1067
  moth, 478
  white, 896
    of nails, 43
Spotted sickness, 1074
Squamæ, 66
Squames, 66
Squamous eczema, 251
  papule, 58
  syphilid, 744
  syphiloderm, 744, 763
St. Anthony's fire, 389
Stains, 55
  claret, 648
  port-wine, 648
  powder-, 488
Stearrhea, 956
Stearrhœa nigricans, 1009
Steatoma, 965
Stéatome, 965
Steatorrhea, 956
Steatorrhœa simplex, 956
Steatozoön folliculorum, 1106
Stigmata, bleeding, 1012
  hysteric, 1012

Stinking sweat, 1007
Stinkschweiss, 1007
Stratum adiposum, 25
  corneum, 19, 20
  granulosum, 19, 21
  lucidum, 20
Strawberry-mark, 649
Striæ atrophicæ, 586
  et maculæ atrophicæ, 586
Striated muscles, 30
Stories atrophiques, 586
Strophulus, 963, 1019
  albidus, 963
  prurigineux, 191
Subcutaneous tissue, 24
Sudamen, 1014
Sudatoria, 1000
Sudor anglicus, 1023
  sanguineosa, 1012
  urinosus, 1013
Sudoriparous glands, 32
Suette blanche, 1023
  miliare, 1023
Sulcated tongue, 1116
Summer eruption, recurrent, 334
  prurigo, 335
Superfatty soap, 112
Superfluous hair, 901
Suppurating corn, 498
Surgeons' eczema, 259, 408
  scarlet fever, 436
Swamp itch, 881, 1101
Sweat, bloody, 1012
  cold, 51
  colored, 1009
  composition, 51
  insensible, 50
  rash, miliary, 1023
  sandy, 1013
  secretion, 50
  sensible, 50
  stinking, 1007
  urinous, 1013
Sweat-glands, 32
  adenoma of, 618, 625
  diseases of, 1000
Sweat-pore, 33
Sweating, excessive, 1000
  of feet, 1002
  of hands, 1001
  sickness, 1023
Sycosis, 948
  bacillogenes, 951
  barbæ, 1045
  contagiosa, 1045
  frambœsiformis, 610
  hyphogenous, 1045
  hyphomycotica, 1045
  lupoid, 945
  non-parasitic, 948
  parasitaire, 1045
  parasitaria, 1045
  parasitica, 1045
  ringworm, 950
  staphylogenes, 951
  trichophytique, 1045
  vulgaris, 948
Sycosis vulgaris, treatment, 953
Symmetric gangrene, 400
  keratodermia, 501
Symptomatic chloasma, 480
  fragilitas crinium, 910
  premature alopecia, 926
Symptoms, constitutional, 53
  general, 53
  objective, 54
  subjective, 53
Syphilid, 729
  acuminated papular, 739
  annular, 736
  circinate, 736
  ecthymaform, 758
  erythematous, 735
  exanthematous, 735
  follicular, 739
  impetigiform, 757
  lenticular papular, 741
  macular, 735
  marmoraceous pigmentary, 738
  miliary papular, 739
  nodular, 761
  papillomatous, 765
  papular, 739
  papulosquamous, 744
  pustulocrustaceous, 757, 759
  pustulo-ulcerative, 760
  retiform pigmentary, 738
  squamous, 744
  tuberculogummatous, 769
  varicelliform, 753
  vegetating 765
Syphilide cornée, 747
Syphilis, 728
  acquired, cutaneous manifestations, 729
  benign, 731
  congenital, 771
  cutanea, 729
    bullosa, 761
    gummatosa, 768
    maculosa, 735
    papillomatosa, 765
    papulosa, 739
    squamosa, 744
    tuberculosa, 761
    vegetans, 751, 765
    vesiculosa, 753
  diagnosis, 781
  etiology, 776
  general observations and diagnostic characters, 731
  hereditary, cutaneous manifestations of, 771
    treatment, 797
  infantile, 771
  malignant, 731
  of skin, 729
  pathology, 778
  præcox, 768
  prognosis, 781
  treatment, 782
Syphilitic adenopathy, 773
  dactylitis, 772, 773
  ecthyma, 758
  leukoderma, 737

Syphilitic lichen, 739
lymphadenitis, 773
Syphiloderm, acneiform, 755
acuminated papular, 739
annular, 736, 743
bullous, 761, 773
circinate, 736, 743
tubercular, 762
ecthymaform, 758
erythematous, 735
exanthematous, 735
flat papular, 741
follicular, 739
gummatous, 768
impetigiform, 757
large acuminated pustular, 755
flat papular, 741
pustular, 758
lenticular papular, 741
macular, 735
miliary acuminated, pustular, 754
papular, 739
nodular, 761
non-ulcerating tubercular, 763
palmar, 744
papillomatous, 765
papular, 739
papulosquamous, 744
papulotubercular, 761, 763
pigmentary, 737
plantar, 744
pustular, 753, 775
pustulocrustaceous, 757, 759
pustulo-ulcerative, 759
retiform pigmentary, 738
segmental tubercular, 762
serpiginous tubercular, 761
small acuminated pustular, 754
flat papular, 741
pustular, 757
squamous, 744, 763
tubercular, 761, 775
tuberculogummatous, 764, 769
tuberculopustular, 763
tuberculosquamous, 763
tuberculosum, 761
ulcerating tubercular, 763
varicelliform, 753
varioliform, 755
vegetating, 751
vesicular, 753
Syphiloderma, 729
bullosum, 761
erythematosum, 735
frambœsioides, 751
maculosum, 735
papulosum, 739
pigmentosum, 737
vesiculosum, 753
Syphiloma, 768
Syringadenoma, 626
Syringo-cystadénome, 618
Syringocystoma, 618
Syringomyelia, 598

Tache de feu, 648
hépatique, 478
Tache pigmentaire, 489
Taches, 55
bleuâtres, 1095
de rousseur, 476
ombrées, 1095
Tactile corpuscles, 27, 28
Tar preparations in eczema, 289
Tattooing, 487
Tattoo-marks, 487
Teeth, Hutchinson's, 772
Teigne du pauvre, 1024
faveuse, 1024
rural, 1024
tondante, 1042
tonsurante, 1042
Télangiectasie, 654
Telangiectasis, 654
Telangiectatic elephantiasis, 564
warts, 545
Tetter, 240
dry, 243
moist, 243
Texas mange, 881
Thorny layer, 22
Tick, wood-, 1097
Tiña, 1074
Tinea axillaris, 1041
barbæ, 1045
circinata, 1037
axillaris, 1041
cruris, 1040
tropica, 1065
cruris, 1040
decalvans, 930
favosa, 1024
unguium, 898
ficosa, 1024
imbricata, 1065
kerion, 1043
lupinosa, 1024
maligna, 1024
nodosa, 917
of mucous membrane, 1039
sycosis, 1045
tondens, 1042
tonsurans, 1042
bald, 1043
trichophytina, 1035
barbæ, 1045
capitis, 1042
corporis, 1037
cruris, 1040
unguium, 898
vera, 1024
versicolor, 1067
flava, 1067
nigra, 1068
treatment, 1070
Tique, 1097
Tissue, adipose, 25
subcutaneous, 24
Tokelau ringworm, 1065
Tonga, 802
Tongue, black, 1119
circinate eruption of, 1117
cleft, 1116
fluted, 1116

Tongue, furrowed, 1116
geographic, 1118
grooved, 1116
hairy, 1119
psoriasis of, 1111
ribbed, 1116
ringworm-like patches of, 1117
scrotal, 1116
sulcated, 1116
wrinkled, 1116
Tonics, 104
Tooth rash, 256
Touch-cells, Merkel's, 29
Touch-corpuscles, 27, 28
Toxi-tuberculides, 205
Trade eczema, 258
Transitory benign plaques of tongue, 1117
hypertrichosis, 902
Translucent layer, 20
Traumatic dermatitis, 405
scars, 601
Treatment, constitutional, 102
general remarks on, 101
local, 110
Trephine, cutaneous, 119, 488
Treponema pallidum, 777
Trichauxis, 901
Trichiasis, 903
Trichoclasia, 911
Trichœpithelioma papillosum multiplex, 618
Trichomycose nodulaire, 916
Trichomycosis palmellina, 917
Trichomykosis favosa, 1024
Trichonosis discolor, 918
furfuracea, 1042
versicolor, 920
Trichophytia capitis, 1042
unguium, 898
Trichophytic alopecia, 939
Trichophytie, 1035
circinée, 1037, 1042
de la barbe, 1045
der unbehaarten Hautstellen, 1037
des parties glabres, 1037
du cuir chevelu, 1042
sèche, à forme d' ichtyose pilaire, 1047
sycosique, 1045
unguéale, 898
Trichophyton, 1036
Trichophytosis, 1035
barbæ, 1045
capitis, 939, 1042
corporis, 1037
Trichorrhexis nodosa, 911
Tricoptilose, 911
Trophic nerves of skin, 47
Tropical ulcer, 800
Tubercle, anatomic, 675
Tubercles, 58
pearly, 963
Tubercula, 58
Tubercular disease of foot, 1081
leprosy, 860
syphiloderm, 761, 775
circinate, 762
non-ulcerating, 763
Tubercular syphiloderm, segmental, 762
serpiginous, 762
ulcerating, 763
Tubercules, 58
Tuberculide, 988
Tuberculides angiomateuses, 544
gommeuses, 680
Tuberculogummatous syphilid, 769
syphiloderm, 764, 769
Tuberculopustular syphiloderm, 763
Tuberculose ulcéreuse, 672
Tuberculosis cutis, 671
diagnosis, 699
etiology, 692
orificialis, 672
pathology, 694
prognosis, 702
treatment, 703
constitutional, 703
local, 705
operative, 709
vera, 672
disseminata, 673
exanthematic, 674
fungosa cutis, 678
of skin, 671
miliary, 672
ulcerosa, 672
verrucosa, 675
cutis, 675
Tuberculosquamous syphiloderm, 763
Tuberculous eczema, 242
gumma, 679
Tuberculum sebaceum, 963
Tuberose carcinoma, 812
Tumeurs, 59
Tumor, 59
fatty, 664
horny, 528
lymph, 564
muscle, 666
nerve, 668
sebaceous, 965
small, 58
Tumores, 59
Tumor-like new growths, multiple benign, 633
Tyloma, 500
Tylosis, 500
gompheux, 497
linguæ, 1111
palmæ et plantæ, 501
Tysonian glands, 36

Ulcer, 68
cancroid, 819
crateriform, 822
endemic, 800
Jacob's, 819
leg, 250
papillary variety, 822
perforating, of foot, 596
rodent, 819
tropical, 800
Ulcera, 68
Ulcerating tubercular syphiloderm, 763
Ulcerations, 68

Ulcère, 68
cancreux, 819
Ulcus exedens, 819
grave, 1081
rodens, 819
varicosum, 250
Ulerythema acneiforme, 989
centrifugum, 714
sycosiforme, 945, 951
Umbilicus, eczema of, 303
Uncinarial dermatitis, 1109
Underwood's disease, 558
Unguentum acidi borici, 115
aquæ rosæ, 114
simplex, 114
Unguis, 43
Uridrose, 1013
Uridrosis, 1013
Urindrosis, 1013
Urinous sweat, 1013
Urticæ, 56
Urticaire, 164
Urticaria, 164
bullosa, 168
bullous, 168
chronic, 167
factitia, 166
giant, 167, 176
hæmorrhagica seu purpura urticans, 167
œdematosa, 167, 176
papulosa, 167
perstans, 167
pigmentosa, 173
treatment, 176
treatment, 171
tuberosa, 167

Vaccinal eruptions, 460
Vaccination, 460
rashes, 460
Vaccinia, 460
Vagabond's disease, 1092
Vajuolo, 451
Varicella 447
gangrænosa, 396
Varicelliform syphilid, 753
syphiloderm, 753
Varices, papillary, 655
Varicose eczema, 250
veins, 656
Varicosities, 656
Variola, 451
confluent, 454
diagnosis, 456
etiology, 455
hæmorrhagica pustulosa, 455
hemorrhagic, 455
pathology, 455
petechial, 455
prognosis, 458
purpuric, 455
symptoms, 451
treatment, 458
Variolæ spuriæ, 447
Variolette, 447
Varioliform syphiloderm, 755
Varioloid, 453
Varix lymphaticus, 564
Vascular dilatations, acquired, 654
papillæ, 24
Vasomotor constringents, 108
nerves, 30
of skin, 47
Vater, corpuscles of, 27
Vegetable laxatives, 104
parasites, diseases due to, 1024
Vegetating syphilid, 765
syphiloderm, 751
Végétation dermique, 520
Vegetations vasculaires, 622
Veins, varicose, 656
Venereal wart, 520
Venerische papillome, 520
warze, 520
Venous nævus, 649
Ver de Guinée, 1104
Vergetures, 586
Verhärtung, 500
Vernix caseosa, 957
érole, 728
Verruca, 517
acuminata, 520
digitata, 519
filiformis, 520
necrogenica, 675
plana, 518
juvenilis, 518
plantaris, 518
senilis, 518
treatment, 525
vulgaris, 517
Verrue, 517
mére of Vidal, 517
Verrues télangiectasiques, 544
Verruga peruana, 809
Vesicles, 60
Vesicobullous eruption, 61
Vesicopapular eruption, 58, 61
Vesicopapules, 58
Vesicopustular eruption, 61
Vesicopustules, 61, 63
Vesiculæ, 60
Vesicular miliaria, 1020
syphiloderm, 753
Vesicules, 60
Vitiligo, 578
acquisita syphilitica, 737
syphilitica, 581
treatment, 582
Vitiligoidea, 634
Vitreous membrane of hair-follicle, 41
Vogelmilbe, 1097
von Recklinghausen's disease, 661
Vulva, kraurosis of, 592
pruritus of, 880

Wagner's corpuscles, 27, 28
Wandering cells, 32
rash, 1117
Wart, 517
fig-, 520
flat, 518
moist, 520
mother, 517

Wart, Peruvian, 809
pointed, 520
seborrheic, 518
telangiectatic, 545
venereal, 520
Warty mole, 518
Warze, 517
Washerwomen's eczema, 258
Wasps, 1097
Water, 110
Water-itch, 1110
Water-pox, 447, 1110
Water-sores, 1110
Weeping eczema, 243
leg, 250
Wen, 965
Wheals, 56
White erysipelas, 390
nails, 896
spots, 896
of nails, 43
White-spot disease, 589
Whiteness of hair, 918
Whitlow, 891
analgesic paralysis with, 598
Winter itch, 881
Wood-tick, 1097
Worm, flesh-, 967
guinea-, 1104
Wounds, dissection, 384
Wrinkled skin, 573
tongue, 1116
Wundrose, 389

Xanthelasma, 634
Xanthelasmoidea, 173
Xantho-erythrodermia perstans, 204
Xanthoma, 634
diabeticorum, 641
treatment, 644
multiplex, 635, 636
palpebrarum, 634
planum, 634
treatment, 640
tuberculatum seu tuberosum, 635
Xanthome, 634
Xeroderma, 531
ichthyoides, 531
pigmentosum, 835
Xérodermie pilaire, 508
Xerosis, 531, 962
X-ray burn, 411
dermatitis, 411
treatment, 120

Yaws, 802
ringworm, 805

Zecke, 1097
Zona, 324
Zoster, 324
abdominalis, 327
abortive, 326
brachialis, 327
capillitii, 327
colli, 327
faciei, 327
femoralis, 327
frontalis, 327
gangrenous, 398
nuchæ, 327
ophthalmicus, 327
pectoralis, 327

SAUNDERS' BOOKS

on

Skin, Genito-Urinary Diseases, Chemistry, and Eye, Ear, Nose, and Throat

W. B. SAUNDERS COMPANY

925 WALNUT STREET PHILADELPHIA

9, HENRIETTA STREET, COVENT GARDEN, LONDON

MECHANICAL EXCELLENCE

NOT alone for their literary excellence have the Saunders publications become a standard on both sides of the Atlantic: their mechanical perfection is as universally commended as is their scientific superiority. The most painstaking attention is bestowed upon all the details that enter into the mechanical production of a book, and medical journals, both at home and abroad, in reviewing the Saunders publications, seldom fail to speak of this distinguishing feature. The attainment of this perfection is due to the fact that the firm has its own Art Department, in which photographs and drawings of a very high order of merit are produced. This department is of decided value to authors, in enabling them to procure the services of artists specially skilled in the various methods of illustrating medical publications.

A Complete Catalogue of our Publications will be Sent upon Request

Stelwagon's Diseases of the Skin

A Treatise on Diseases of the Skin. For Advanced Students and Practitioners. By HENRY W. STELWAGON, M. D., PH. D., Professor of Dermatology in the Jefferson Medical College, Philadelphia. Handsome octavo volume of 1135 pages, with 258 text-cuts and 32 full-page colored lithographic and half-tone plates. Cloth, $6.00 net; Sheep or Half Morocco, $7.50 net.

JUST ISSUED — NEW (5th) EDITION

FIVE LARGE EDITIONS IN FIVE YEARS

The demand for five editions of this work in a period of five years, and the many gratifying review notices indicate beyond a doubt the practical character of the book. In preparing the work the predominant aim kept in view was to supply the physician with a treatise written on plain and practical lines, giving abundant helpful case illustrations. In this edition the section on Tropical Skin Diseases has been very thoroughly revised and a number of unusual illustrations added. It is the most up-to-date work on skin diseases published.

PERSONAL AND PRESS OPINIONS

John T. Bowen, M.D.,

Assistant Professor of Dermatology, Harvard University Medical School, Boston.

"It gives me great pleasure to endorse Dr. Stelwagon's book. The clearness of description is a marked feature. It is also very carefully compiled. It is one of the best text-books yet published and a credit to American dermatology."

George T. Elliot, M. D.,

Professor of Dermatology, Cornell University.

"It is a book that I recommend to my class at Cornell, because for conservative judgment, for accurate observation, and for a thorough appreciation of the essential position of dermatology, I think it holds first place."

Boston Medical and Surgical Journal

"We can cordially recommend Dr. Stelwagon's book to the profession as the best text-book on dermatology, for the advanced student and general practitioner, that has been brought strictly up to date. . . . The photographic illustrations are numerous, and many of them are of great excellence."

DeSchweinitz's Diseases of the Eye

Just Issued—The New (5th) Edition, Enlarged

Diseases of the Eye: A HANDBOOK OF OPHTHALMIC PRACTICE. By G. E. DESCHWEINITZ, M.D., Professor of Ophthalmology in the University of Pennsylvania, Philadelphia, etc. Handsome octavo of 894 pages, 313 text-illustrations, and 6 chromo-lithographic plates. Cloth, $5.00 net; Sheep or Half Morocco, $6.50 net.

WITH 313 TEXT-ILLUSTRATIONS AND 6 COLORED PLATES

For this new edition the text has been very thoroughly revised, and the work enlarged by the addition of new matter to the extent of some one hundred pages. There have been added, amongst other subjects, chapters on the following: X-Ray Treatment of Epithelioma, Xeroderma Pigmentosum; Purulent Conjunctivitis of Young Girls; Jequiritol and Jequiritol Serum; X-ray Treatment of Trachoma; Infected Marginal Ulcer; Keratitis Punctata Syphilitica; Uveitis and Its Varieties; Eye-ground Lesions of Hereditary Syphilis; Macular Atrophy of the Retina; Worth's Amblyoscope; Stovain, Alypin; Motais' Operation for Ptosis; Kuhnt-Müller's Operation for Ectropion; Haab's Method for Foreign Bodies; and Sweet's X-Ray Method of Localizing Foreign Bodies. Other chapters have been rewritten. The excellence of the illustrative feature has been maintained.

PERSONAL AND PRESS OPINIONS

Samuel Theobald, M.D.,

Clinical Professor of Ophthalmology, Johns Hopkins University, Baltimore.

"It is a work that I have held in high esteem, and is one of the two or three books upon the eye which I have been in the habit of recommending to my students in the Johns Hopkins Medical School."

W. Franklin Coleman, M. D.,

Professor of Diseases of the Eye, Postgraduate Medical School, Chicago.

"I am very much pleased with deSchweinitz's work and will recommend it to the members of my class as a most reliable, complete, and up to date text-book."

British Medical Journal

"A clearly written, comprehensive manual. One which we can commend to students as a reliable text-book, written with an evident knowledge of the wants of those entering upon the study of this special branch of medical science."

GET THE BEST

American Illustrated Dictionary

THE NEW STANDARD

Just Issued—New (4th) Edition

The American Illustrated Medical Dictionary. A new and complete dictionary of the terms used in Medicine, Surgery, Dentistry, Pharmacy, Chemistry, and kindred branches; with over 100 new and elaborate tables and many handsome illustrations. By W. A. NEWMAN DORLAND, M. D., Editor of "The American Pocket Medical Dictionary." Large octavo, nearly 840 pages, bound in full flexible leather. Price, $4.50 net; with thumb index, $5.00 net.

WITH 2000 NEW TERMS

In this edition the book has been subjected to a thorough revision. The author has also added upward of two thousand important new terms that have appeared in medical literature during the past few months.

Howard A. Kelly, M. D.,
Professor of Gynecology, Johns Hopkins University, Baltimore.

"Dr. Dorland's Dictionary is admirable. It is so well gotten up and of such convenient size. No errors have been found in my use of it."

Theobald's Prevalent Eye Diseases

Prevalent Diseases of the Eye. By SAMUEL THEOBALD, M. D., Clinical Professor of Ophthalmology and Otology, Johns Hopkins University. Octavo of 550 pages, with 219 text-cuts and several colored plates. Cloth, $4.50 net; Half Morocco, $6.00 net.

JUST READY—FOR THE PRACTITIONER

With few exceptions all the works on diseases of the eye, although written ostensibly for the general practitioner, are in reality adapted only to the specialist; but Dr. Theobald in his book has described very clearly and in detail those conditions, the diagnosis and treatment of which come within the province of the general practitioner. The therapeutic suggestions are concise, unequivocal, and specific. It is the one work on the Eye written particularly for the general practitioner.

Charles A. Oliver, M.D.,
Clinical Professor of Ophthalmology, Woman's Medical College of Pennsylvania.

"I feel I can conscientiously recommend it, not only to the general physician and medical student, for whom it is primarily written, but also to the experienced ophthalmologist. Most surely Dr. Theobald has accomplished his purpose."

Wells' Chemical Pathology

Chemical Pathology. Being a Discussion of General Pathology from the Standpoint of the Chemical Processes Involved. By H. GIDEON WELLS, PH.D., M.D., Assistant Professor of Pathology in the University of Chicago. Octavo of 549 pages. Cloth, $3.25 net; Half Morocco, $4.75 net.

JUST ISSUED

Dr. Wells here concisely presents the latest work systematically considering the subject of general pathology from the standpoint of the chemical processes involved. It is written for the physician, for those engaged in research in pathology and physiologic chemistry, and for the medical student. In the introductory chapter are discussed the chemistry and physics of the animal cell, giving the essential facts of ionization, diffusion, osmotic pressure, etc., and the relation of these facts to cellular activities. Special chapters are devoted to *Diabetes* and to *Uric-acid Metabolism and Gout.*

Wm. H. Welch, M. D., *Professor of Pathology, Johns Hopkins University.*

"The work fills a real need in the English literature of a very important subject, and I shall be glad to recommend it to my students."

American Text-Book of Eye, Ear, Nose, and Throat

American Text-Book of Diseases of the Eye, Ear, Nose, and Throat. Edited by G. E. DE SCHWEINITZ, M. D., Professor of Ophthalmology in the University of Pennsylvania; and B. ALEXANDER RANDALL, M. D., Clinical Professor of Diseases of the Ear in the University of Pennsylvania. Imperial octavo, 1251 pages, with 766 illustrations, 59 of them in colors. Cloth, $7.00 net; Sheep or Half Morocco, $8.50 net.

This work is essentially a text-book on the one hand, and, on the other, a volume of reference to which the practitioner may turn and find a series of articles written by representative authorities on the subjects portrayed by them. Therefore, the practical side of the question has been brought into prominence. Particular emphasis has been laid on the most approved methods of treatment.

American Journal of the Medical Sciences

"The different articles are complete, forceful, and, if one may be permitted to use the term, 'snappy,' in decided contrast to some of the labored but not more learned descriptions which have appeared in the larger systems of ophthalmology."

Brühl, Politzer, and Smith's Otology

Atlas and Epitome of Otology. By GUSTAV BRÜHL, M. D., of Berlin, with the collaboration of PROFESSOR DR. A. POLITZER, of Vienna. Edited, with additions, by S. MACCUEN SMITH, M.D., Professor of Otology in the Jefferson Medical College, Philadelphia. With 244 colored figures on 39 lithographic plates, 99 text illustrations, and 292 pages of text. Cloth, $3.00 net. *In Saunders' Hand-Atlas Series.*

INCLUDING ANATOMY AND PHYSIOLOGY

The work is both didactic and clinical in its teaching. A special feature is the very complete exposition of the minute anatomy of the ear, a working knowledge of which is so essential to an intelligent conception of the science of otology. The association of Professor Politzer and the use of so many valuable specimens from his notably rich collection especially enhance the value of the treatise. The work contains everything of importance in the elementary study of otology.

Clarence J. Blake, M. D.,
Professor of Otology in Harvard University Medical School, Boston.

"The most complete work of its kind as yet published, and one commending itself to both the student and the teacher in the character and scope of its illustrations."

Haab and deSchweinitz's Operative Ophthalmology

Atlas and Epitome of Operative Ophthalmology. By DR. O. HAAB, of Zurich. Edited, with additions, by G. E. DE SCHWEINITZ, M. D., Professor of Ophthalmology in the University of Pennsylvania. With 30 colored lithographic plates, 154 text-cuts, and 375 pages of text. *In Saunders' Hand-Atlas Series.* Cloth, $3.50 net.

RECENTLY ISSUED

Dr. Haab's Atlas of Operative Ophthalmology will be found as beautiful and as practical as his two former atlases. The work represents the author's thirty years' experience in eye work. The various operative interventions are described with all the precision and clearness that such an experience brings. Recognizing the fact that mere verbal descriptions are frequently insufficient to give a clear idea of operative procedures, Dr. Haab has taken particular care to illustrate plainly the different parts of the operations.

Johns Hopkins Hospital Bulletin

"The descriptions of the various operations are so clear and full that the volume can well hold place with more pretentious text-books."

Haab and DeSchweinitz's External Diseases *of the* Eye

Atlas and Epitome of External Diseases of the Eye. By DR. O. HAAB, of Zürich. Edited, with additions, by G. E. DESCHWEINITZ, M. D., Professor of Ophthalmology, University of Pennsylvania. With 98 colored illustrations on 48 lithographic plates and 232 pages of text. Cloth, $3.00 net. *In Saunders' Hand-Atlas Series.*

SECOND REVISED EDITION—RECENTLY ISSUED

Conditions attending diseases of the external eye, which are often so complicated, have probably never been more clearly and comprehensively expounded than in the forelying work, in which the pictorial most happily supplements the verbal description. The price of the book is remarkably low.

The Medical Record, New York

"The work is excellently suited to the student of ophthalmology and to the practising physician. It cannot fail to attain a well-deserved popularity."

Haab and DeSchweinitz's Ophthalmoscopy

Atlas and Epitome of Ophthalmoscopy and Ophthalmoscopic Diagnosis. By DR. O. HAAB, of Zürich. *From the Third Revised and Enlarged German Edition.* Edited, with additions, by G. E. DESCHWEINITZ, M. D., Professor of Ophthalmology, University of Pennsylvania. With 152 colored lithographic illustrations and 85 pages of text. Cloth, $3.00 net. *In Saunders' Hand-Atlas Series.*

The great value of Prof. Haab's Atlas of Ophthalmoscopy and Ophthalmoscopic Diagnosis has been fully established and entirely justified an English translation. Not only is the student made acquainted with carefully prepared ophthalmoscopic drawings done into well-executed lithographs of the most important fundus changes, but, in many instances, plates of the microscopic lesions are added. The whole furnishes a manual of the greatest possible service.

The Lancet, London

"We recommend it as a work that should be in the ophthalmic wards or in the library of every hospital into which ophthalmic cases are received."

Barnhill and Wales' Otology

A Text-Book of Modern Otology. By JOHN F. BARNHILL, M. D., Professor of Otology, Laryngology, and Rhinology, and EARNEST DE W. WALES, M. D., Associate Professor of Otology, Laryngology, and Rhinology, State College of Physicians and Surgeons, Indianapolis. Octavo of 600 pages, with 300 original illustrations.

JUST READY

The authors, in writing this work, kept ever in mind the needs of the physician engaged in general practice. It represents the results of personal experience as practitioners and teachers, influenced by the instruction given by such authorities as Sheppard, Dundas Grant, Percy Jakins, Jansen, and Alt. Much space is devoted to prophylaxis, diagnosis, and treatment, both medical and surgical. Great pains have been taken with the illustrations, in order to have them as practical and as helpful as possible, and at the same time highly artistic. A large number represent the best work of Mr. H. F. Aiken.

Grünwald and Grayson on Larynx

Atlas and Epitome of Diseases of the Larynx. By DR. L. GRÜNWALD, of Munich. Edited, with additions, by CHARLES P. GRAYSON, M. D., Clinical Professor of Laryngology and Rhinology, University of Pennsylvania. With 107 colored figures on 44 plates, 25 text-cuts, and 103 pages of text. Cloth, $2.50 net. *In Saunders' Hand-Atlas Series.*

British Medical Journal

"Excels everything we have hitherto seen in the way of colored illustrations of diseases of the larynx. . . . Not only valuable for the teaching of laryngology, it will prove of the greatest help to those who are perfecting themselves by private study."

Saxe's Urinalysis

Examination of the Urine. By G. A. DE SANTOS SAXE, M. D., Pathologist to Columbus Hospital, New York City. 12mo of 391 pages, fully illustrated. Flexible leather, $1.50 net.

RECENTLY ISSUED

This work is intended as an aid in diagnosis, by interpreting the clinical significance of the chemic and microscopic urinary findings.

Francis Carter Wood, M. D.,
Adjunct Professor of Clinical Pathology, Columbia University.

"It seems to me to be one of the best of the smaller works on this subject; it is indeed, better than a good many of the larger ones."

Gradle's
Nose, Pharynx, and Ear

Diseases of the Nose, Pharynx, and Ear. By HENRY GRADLE, M. D., Professor of Ophthalmology and Otology, Northwestern University Medical School, Chicago. Handsome octavo of 547 pages, illustrated, including two full-page plates in colors. Cloth, $3.50 net.

INCLUDING TOPOGRAPHIC ANATOMY

This volume presents diseases of the Nose, Pharynx, and Ear as the author has seen them during an experience of nearly twenty-five years. In it are answered in detail those questions regarding the course and outcome of diseases which cause the less experienced observer the most anxiety in an individual case. Topographic anatomy has been accorded liberal space.

Pennsylvania Medical Journal

"This is the most practical volume on the nose, pharynx, and ear that has appeared recently. . . . It is exactly what the less experienced observer needs, as it avoids the confusion incident to a categorical statement of everybody's opinion."

Kyle's
Diseases of Nose *and* Throat

Diseases of the Nose and Throat. By D. BRADEN KYLE, M. D., Professor of Laryngology in the Jefferson Medical College, Philadelphia; Consulting Laryngologist, Rhinologist, and Otologist, St. Agnes' Hospital. Octavo, 669 pages; over 184 illustrations, and 26 lithographic plates in colors. Cloth, $4.00 net.

JUST ISSUED—THE NEW (4th) EDITION

Four large editions of this excellent work fully testify to its practical value. In this edition the author has revised the text thoroughly, bringing it absolutely down to date. With the practical purpose of the book in mind, extended consideration has been given to treatment, each disease being considered in full, and definite courses being laid down to meet special conditions and symptoms.

Dudley S. Reynolds, M. D.,

Formerly Professor of Ophthalmology and Otology, Hospital College of Medicine, Louisville.

"It is an important addition to the text-books now in use, and is better adapted to the uses of the student than any other work with which I am familiar. I shall be pleased to commend Dr. Kyle's work as the best text-book."

Greene and Brooks' Genito-Urinary Diseases

A Text-Book of Genito-Urinary Diseases. By ROBERT H. GREENE, M. D., Professor of Genito-Urinary Surgery at Fordham University; and HARLOW BROOKS, M. D., Assistant Professor of Pathology, University and Bellevue Hospital Medical School. Octavo of 550 pages, profusely illustrated.

JUST READY

This new work covers completely the subject of genito-urinary diseases, presenting *both the medical and surgical sides.* It has been designed as a work of quick reference, and has therefore been written in a clear, condensed style, so that the information can be readily grasped and retained. *Kidney diseases* are very elaborately detailed, and especially well presented is surgery of the kidney. The text is profusely illustrated with original line-drawings.

Gleason on Nose, Throat, and Ear

A Manual of Diseases of the Nose, Throat, and Ear. By E. BALDWIN GLEASON, M. D., LL. D., Clinical Professor of Otology, Medico-Chirurgical College, Philadelphia. 12mo of 556 pages, profusely illustrated. Flexible leather, $2.50 net.

JUST ISSUED

Anatomy, physiology, and pathology of the upper respiratory tract and ear have been carefully presented, the author rightly believing such knowledge essential to the efficacious treatment of diseases of these organs. Methods of treatment have been simplified as much as possible, so that in most instances only those methods, drugs, and operations have been advised which have proved essential. A valuable feature consists of the collection of formulas.

American Text-Book of Genito-Urinary Diseases, Syphilis, and Diseases of the Skin. Edited by L. BOLTON BANGS, M. D., late Professor of Genito-Urinary Surgery, University and Bellevue Hospital Medical College, New York; and W. A. HARDAWAY, M. D., Professor of Diseases of the Skin, Missouri Medical College. Octavo, 1229 pages, 300 engravings, 20 colored plates. Cloth, $7.00 net.

Mracek *and* Stelwagon's Diseases of the Skin

Atlas and Epitome of Diseases of the Skin. By PROF. DR. FRANZ MRACEK, of Vienna. Edited, with additions, by HENRY W. STELWAGON, M. D., Professor of Dermatology in the Jefferson Medical College, Philadelphia. With 77 colored plates, 50 half-tone illustrations and 280 pages of text. *In Saunders' Hand-Atlas Series.* Clo., $4.00 net.

RECENTLY ISSUED—NEW (2nd) EDITION

This volume, the outcome of years of scientific and artistic work, contains, together with colored plates of unusual beauty, numerous illustrations in black, and a text comprehending the entire field of dermatology. The illustrations are all original and prepared from actual cases in Mracek's clinic, and the execution of the plates is superior to that of any, even the most expensive, dermatologic atlas hitherto published.

American Journal of the Medical Sciences

"The advantages which we see in this book and which recommend it to our minds are: First, its handiness; secondly, the plates, which are excellent as regards drawing, color, and the diagnostic points which they bring out."

Mracek *and* Bangs' Syphilis and Venereal

Atlas and Epitome of Syphilis and the Venereal Diseases. By PROF. DR. FRANZ MRACEK, of Vienna. Edited, with additions, by L. BOLTON BANGS, M. D., late Prof. of Genito-Urinary Surgery, University and Bellevue Hospital Medical College, New York. With 71 colored plates and 122 pages of text. Cloth, $3.50 net. *In Saunders' Hand-Atlas Series.*

CONTAINING 71 COLORED PLATES

According to the unanimous opinion of numerous authorities, to whom the original illustrations of this book were presented, they surpass in beauty anything of the kind that has been produced in this field, not only in Germany, but throughout the literature of the world.

Robert L. Dickinson, M. D.,

Art Editor of "The American Text-Book of Obstetrics."

"The book that appeals instantly to me for the strikingly successful, valuable, and graphic character of its illustrations is the 'Atlas of Syphilis and the Venereal Diseases.' I know of nothing in this country that can compare with it."

Holland's Medical Chemistry and Toxicology

A Text-Book of Medical Chemistry and Toxicology. By JAMES W. HOLLAND, M. D., Professor of Medical Chemistry and Toxicology, and Dean, Jefferson Medical College, Philadelphia. Octavo of 592 pages, fully illustrated. Cloth, $3.00 net.

RECENTLY ISSUED

Dr. Holland's work is an entirely new one, and is based on his thirty-five years' practical experience in teaching chemistry and medicine. Recognizing that to understand physiologic chemistry, students must first be informed upon points not referred to in most medical text-books, the author has included in his work the latest views of equilibrium of equations, mass action, cryoscopy, osmotic pressure, dissociation of salts into ions, effects of ionization upon electric conductivity, and the relationship between purin bodies, uric acid, and urea. More space is given to toxicology than in any other text-book on chemistry.

American Medicine

"Its statements are clear and terse; its illustrations well chosen; its development logical, systematic, and comparatively easy to follow. . . . We heartily commend the work."

Grünwald *and* Newcomb's Mouth, Pharynx, and Nose

Atlas and Epitome of Diseases of the Mouth, Pharynx, and Nose. By DR. L. GRÜNWALD, of Munich. *From the Second Revised and Enlarged German Edition.* Edited, with additions, by JAMES E. NEWCOMB, M. D., Instructor in Laryngology, Cornell University Medical School. With 102 illustrations on 42 colored lithographic plates, 41 text-cuts, and 219 pages of text. Cloth, $3.00 net. *In Saunders' Hand-Atlas Series.*

INCLUDING ANATOMY AND PHYSIOLOGY

In designing this atlas the needs of both student and practitioner were kept constantly in mind, and as far as possible typical cases of the various diseases were selected. The illustrations are described in the text in exactly the same way as a practised examiner would demonstrate the objective findings to his class. The illustrations themselves are numerous and exceedingly well executed. The editor has incorporated his own valuable experience, and has also included extensive notes on the use of the active principle of the suprarenal bodies.

American Medicine

"Its conciseness without sacrifice of clearness and thoroughness, as well as the excellence of text and illustrations, are commendable."

Jackson on the Eye

A Manual of the Diagnosis and Treatment of Diseases of the Eye. By EDWARD JACKSON, A.M., M.D., Professor of Ophthalmology, University of Colorado. 12mo volume of 615 pages, with 184 beautiful illustrations. Cloth, $2.50 net.

JUST ISSUED—NEW (2d) EDITION

The Medical Record, New York

"It is truly an admirable work. . . . Written in a clear, concise manner, it bears evidence of the author's comprehensive grasp of the subject. The term 'multum in parvo' is an appropriate one to apply to this work."

Grant on the Face, Mouth, and Jaws

A Text-Book of the Surgical Principles and Surgical Diseases of the Face, Mouth, and Jaws. For Dental Students. By H. HORACE GRANT, A. M., M. D., Professor of Surgery and of Clinical Surgery, Hospital College of Medicine, Louisville. Octavo of 231 pages, with 68 illustrations. Cloth, $2.50 net.

Annals of Surgery

"The book is well illustrated, the text is clear, and on the whole it serves well for the purpose for which it is intended."

Friedrich *and* Curtis' Nose, Larynx, and Ear

Rhinology, Laryngology, and Otology, and Their Significance in General Medicine. By DR. E. P. FRIEDRICH, of Leipzig. Edited by H. HOLBROOK CURTIS, M.D., Consulting Surgeon to the New York Nose and Throat Hospital. Octavo volume of 350 pages. Cloth, $2.50 net.

Boston Medical and Surgical Journal

"This task he has performed admirably, and has given both to the general practitioner and to the specialist a book for collateral reference which is modern, clear, and complete."

Ogden on the Urine

Clinical Examination of Urine and Urinary Diagnosis. A Clinical Guide for the Use of Practitioners and Students of Medicine and Surgery. By J. BERGEN OGDEN, M. D., Late Instructor in Chemistry, Harvard University Medical School; Formerly Assistant in Clinical Pathology, Boston City Hospital. Octavo, 418 pages, 54 illustrations, and a number of colored plates. Cloth, $3.00 net.

SECOND REVISED EDITION—RECENTLY ISSUED

In this edition the work has been brought absolutely down to the present day. Important changes have been made in connection with the determination of Urea, Uric Acid, and Total Nitrogen; and the subjects of Cryoscopy and Beta-Oxybutyric Acid have been given a place. Special attention has been paid to diagnosis by the character of the urine, the diagnosis of diseases of the kidneys and urinary passages; an enumeration of the prominent clinical symptoms of each disease; and the peculiarities of the urine in certain general diseases.

The Lancet, London

"We consider this manual to have been well compiled; and the author's own experience, so clearly stated, renders the volume a useful one both for study and reference."

Vecki's Sexual Impotence

The Pathology and Treatment of Sexual Impotence. By VICTOR G. VECKI, M. D. From the Second Revised and Enlarged German Edition. 12mo volume of 329 pages. Cloth, $2.00 net.

THIRD EDITION, REVISED AND ENLARGED

The subject of impotence has but seldom been treated in this country in the truly scientific spirit that its pre-eminent importance deserves, and this volume will come to many as a revelation of the possibilities of therapeutics in this important field. The reading part of the English-speaking medical profession has passed judgment on this monograph. The whole subject of sexual impotence and its treatment is discussed by the author in an exhaustive and thoroughly scientific manner. In this edition the book has been thoroughly revised, and new matter has been added, especially to the portion dealing with treatment.

Johns Hopkins Hospital Bulletin

"A scientific treatise upon an important and much neglected subject. . . . The treatment of impotence in general and of sexual neurasthenia is discriminating and judicious."

American Pocket Dictionary

Fifth Edition, Revised
Just Issued

THE AMERICAN POCKET MEDICAL DICTIONARY. Edited by W. A. NEWMAN DORLAND, M. D., Assistant Obstetrician to the Hospital of the University of Pennsylvania. Containing the pronunciation and definition of the principal words used in medicine and kindred sciences. Flexible leather, with gold edges, $1.00 net; with thumb index, $1.25 net.

James W. Holland, M. D.,

Professor of Medical Chemistry and Toxicology, and Dean, Jefferson Medical College, Philadelphia,

"I am struck at once with admiration at the compact size and attractive exterior. I can recommend it to our students without reserve."

Stelwagon's Essentials of Skin

Sixth Revised Edition
Recently Issued

ESSENTIALS OF DISEASES OF THE SKIN. By HENRY W. STELWAGON, M. D., PH.D., Professor of Dermatology in the Jefferson Medical College, Philadelphia. Post-octavo of 276 pages, with 72 text-illustrations and 8 plates. Cloth, $1.00 net. *In Saunders' Question-Compend Series.*

The Medical News

"In line with our present knowledge of diseases of the skin. . . . Continues to maintain the high standard of excellence for which these question compends have been noted."

Wolff's Medical Chemistry

Sixth Edition, Revised
Recently Issued

ESSENTIALS OF MEDICAL CHEMISTRY, ORGANIC AND INORGANIC. Containing also Questions on Medical Physics, Chemical Physiology, Analytical Processes, Urinalysis, and Toxicology. By LAWRENCE WOLFF, M. D., Late Demonstrator of Chemistry, Jefferson Medical College. Revised by SMITH ELY JELLIFFE, M. D., PH.D., Professor of Pharmacognosy, College of Pharmacy of the City of New York. Post-octavo of 222 pages. Cloth, $1.00 net. *In Saunders' Question-Compend Series.*

Martin's Minor Surgery, Bandaging, and the Venereal Diseases

Second Edition, Revised

ESSENTIALS OF MINOR SURGERY, BANDAGING, AND VENEREAL DISEASES. By EDWARD MARTIN, A. M., M. D., Professor of Clinical Surgery, University of Pennsylvania, etc. Post-octavo, 166 pages, with 78 illustrations. Cloth, $1.00 net. *In Saunders' Question-Compend Series.*

Senn's Genito-Urinary Tuberculosis

TUBERCULOSIS OF THE GENITO-URINARY ORGANS, MALE AND FEMALE. By N. SENN, M. D., Ph. D., LL. D., Professor of Surgery in Rush Medical College. Octavo of 317 pages, illustrated. Cloth, $3.00 net.

Wolf's Examination of Urine

A LABORATORY HANDBOOK OF PHYSIOLOGIC CHEMISTRY AND URINE-EXAMINATION. By CHARLES G. L. WOLF, M. D., Instructor in Physiologic Chemistry, Cornell University Medical College, New York. 12mo volume of 204 pages, fully illustrated. Cloth, $1.25 net.

British Medical Journal

"The methods of examining the urine are very fully described, and there are at the end of the book some extensive tables drawn up to assist in urinary diagnosis."

Jackson's Essentials of Eye

Third Revised Edition

ESSENTIALS OF REFRACTION AND OF DISEASES OF THE EYE. By EDWARD JACKSON, A. M., M. D., Emeritus Professor of Diseases of the Eye, Philadelphia Polyclinic. Post-octavo of 261 pages, 82 illustrations. Cloth, $1.00 net. *In Saunders' Question-Compend Series.*

Johns Hopkins Hospital Bulletin

"The entire ground is covered, and the points that most need careful elucidation are made clear and easy."

Gleason's Nose and Throat

Third Edition, Revised

ESSENTIALS OF DISEASES OF THE NOSE AND THROAT. By E. B. GLEASON, S. B., M. D., Clinical Professor of Otology, Medico-Chirurgical College, Philadelphia, etc. Post-octavo, 241 pages, 112 illustrations. Cloth, $1.00 net. *In Saunders' Question Compends.*

The Lancet, London

"The careful description which is given of the various procedures would be sufficient to enable most people of average intelligence and of slight anatomical knowledge to make a very good attempt at laryngoscopy."

Gleason's Diseases of the Ear

Third Edition, Revised

ESSENTIALS OF DISEASES OF THE EAR. By E. B. GLEASON, S. B., M. D., Clinical Professor of Otology, Medico-Chirurgical College, Phila., etc. Post-octavo volume of 214 pages, with 114 illustrations. Cloth, $1.00 net. *In Saunders' Question-Compend Series.*

Bristol Medico-Chirurgical Journal

"We know of no other small work on ear diseases to compare with this, either in freshness of style or completeness of information."

Wilcox on Genito-Urinary and Venereal Diseases

Recently Issued

ESSENTIALS OF GENITO-URINARY AND VENEREAL DISEASES. By STARLING S. WILCOX, M. D., Professor of Genito-Urinary Diseases and Syphilology, Starling Medical College, Columbus, Ohio. 12mo of 313 pages, illustrated. Cloth, $1.00 net. *Saunders' Compends.*

Stevenson's Photoscopy

Just Ready

PHOTOSCOPY. (Skiascopy or Retinoscopy) By MARK D. STEVENSON, M. D., Ophthalmic Surgeon to the Akron City Hospital. 12mo of 126 pages, illustrated. Cloth, $1.25 net.

Dr. Stevenson's work fully and clearly explains the use of this objective test and elucidates the reasons of the various phenomena observed. The illustrations have been drawn with special attention to their practical usefulness.

3 2044 040 033 565
DR.
COM
OTTAWA CAR WORKS.

3 2044 040 033 565